

Original Article

Low expression of RECK in oral squamous cell carcinoma patients induces a shorter survival rate through an imbalance of RECK/MMPs

Jian Yuan^{1,2*}, Wen Li^{1,2*}, Jinxiao Zhu³, Shuli Deng^{1,2}, Xuejin Tao⁴

¹Department of Conservative Dentistry and Endodontics, The Affiliated Stomatology Hospital, Zhejiang University School of Medicine, Hangzhou, Zhejiang, China; ²Key Laboratory of Oral Biomedical Research of Zhejiang Province, Zhejiang University School of Stomatology, Hangzhou 310006, Zhejiang, China; ³Department of Stomatology, Wuxi Children's Hospital, Wuxi, Jiangsu, China; ⁴Center of Stomatology, Tongji Hospital Affiliated to Tongji Medical College Hua Zhong University of Science and Technology, Wuhan, Hubei, China. *Equal contributors.

Received January 12, 2020; Accepted February 7, 2020; Epub March 1, 2020; Published March 15, 2020

Abstract: Background: RECK, as a negative MMP regulator, is extensively expressed in normal cells but decreased in tumors. In OSCC, the relationship between RECK and MMPs and the potential prognostic impact remains unclear. In this research, for the first time, we investigated the expression of RECK associated with MMPs during OSCC carcinogenesis in a large sample and its association with 5-year survival rate. Material and Methods: Immunohistochemical SP technique was applied to study the expression of RECK and MMP-2 and MMP-9 in 108 cases of OSCC and 30 normal oral mucosae. Univariate and multivariate Cox regression analysis was utilized for disease-free survival and overall survival, and analyzed by Kaplan-Meier method regarding RECK expression in patients of OSCC. Results: We found lower expression of RECK in OSCC was 51.85% (56/108) compared with 93.33% (28/30) in the control group. However, the higher expression of MMP-2 and MMP-9 was 74.07% (80/108) and 70.37% (76/108) in OSCC, respectively, compared with 20% (6/30) and 13.3% (4/30) in the control group. Furthermore, the decrease of RECK expression and the increase of MMP-2, and -9 expression were significantly correlated with the loss of histologic differentiation, the occurrence of lymphatic metastasis, and the increase of OSCC clinical stage ($P < 0.05$). OSCC patients with a low level of RECK expression had a lower rate of 5-year survival. Conclusion: RECK may prevent metastasis and improve OSCC patients' prognosis through a RECK/MMP-2, and -9 imbalance. Furthermore, RECK is a prospective prognostic indicator and therapeutic target for cancer molecular targeting therapy. Low expression of RECK may be a significant negative prognostic predictor.

Keywords: RECK, MMP-2, MMP-9, OSCC

Introduction

Oral squamous cell carcinoma (OSCC) is one of the most invasive tumors associated with a low survival rate, and ranks sixth in cancer incidence in the world. It has a higher rate of lymph node metastasis which is caused by adhesion molecules and matrix-degrading enzymes. In a series of malignant tumor invasion and metastasis processes, matrix metalloproteinases (MMPs) take a vital role in the decomposition of extracellular matrix (ECM). MMPs come from a wide range of sources that can be produced by almost all cells, and participate in diversified

physiologic and pathologic procedures, such as tissue formation, angiogenesis, and the inflammatory response [1, 2]. In addition, MMPs interact with the ECM in tumor cells, such as by destroying the connective tissue matrix, resulting in tumor invasion, invasion through the basement membrane into small blood and lymphatic vessels, and tumor metastasis [3]. Researchers have confirmed that MMPs expressed in tumors play important roles in tumor invasion and metastasis through uncontrolled decomposition of tissue basement membranes and the ECM, providing a prerequisite for tumor invasion and migration [4]. Clinical

studies have also reported that high expression of MMP-2 and MMP-9 exist in patients with OSCC [5]. Additionally, the activities of MMPs can be controlled by MMP inhibitors such as reversion-inducing cysteine-rich protein with Kazal motifs (RECK). RECK is a type of tumor suppressor, which is involved in the negative regulation of MMP-2 and MMP-9 activities by preventing the breakdown of the ECM [6]. Previous studies have confirmed that RECK is extensively expressed in normal cells and tissues but reduced in many tumor types [6-9]. However, related studies in OSCC are limited, especially as to five-year survival rate.

MMP inhibitors work together with MMPs to maintain a dynamic balance between ECM degradation and synthesis, and play a decisive role in the process of tumor cell invasion and metastasis [10]. A significant high expression of MMP-2, and -9 and low expression of RECK have been confirmed in squamous cell carcinoma [11]. Therefore, RECK may produce a marked effect in inhibiting the destruction of ECM components through the dynamic imbalance of RECK/MMP-2, and -9 in the occurrence and metastasis of OSCC. This view is further demonstrated in our study.

In patients with OSCC, due to a lack of available tumor proliferation and invasion factors, tumor progression is unpredictable. Therefore, searching for specific markers can help us evaluate the prognosis. Moreover, it may be helpful for cancer molecular targeting therapy of OSCC in the future. In this study, we analyzed the expression of RECK and MMP-2, and -9 in OSCC and normal tissues to assess their effect and interrelationships. This is the first study to explore the RECK immunohistochemical expression in connection with clinicopathologic characteristics and five-year survival rate in a large sample of OSCC patients.

Materials and methods

Materials

Tumor tissues were acquired from 108 patients who underwent OSCC surgical resection and complete resection with lymphadenectomy immediately after surgery from the Center of Stomatology, Tongji Hospital of Tongji Medical College from August 2006 to September 2009. And normal oral mucosa was obtained during extraction of lower impacted mandibular third

molars. Ethics Committee approval was obtained from Tongji Hospital of Tongji Medical College. All patients denied preoperative radiotherapy and chemotherapy. A total of 64 males and 44 females aged 27-72 years (average 52.4 years) were included in this study. Among them, 62 cases were well-differentiated, 46 were moderately-differentiated or poorly-differentiated. There were 50 cases of cervical lymphatic metastasis and 58 cases without cervical metastasis. Of these patients, 62 cases were stage I and II, 46 cases were stage III and IV on the basis of clinical stages. 30 cases of normal oral mucosa were also obtained, which included 18 men and 12 women. According to the Helsinki Declaration and our agency's guidelines, all samples were obtained after patients signed informed consent.

Immunohistochemical staining

The specimens were fixed by 4% formaldehyde solution, dehydrated conventionally and embedded in paraffin. Then cut into 4 μ m sections, and used for immunohistochemistry (IHC). Immunohistochemistry was conducted by the streptavidin-peroxidase method following the manufacturer's guidelines to assess the expression level of RECK and MMPs. Immunohistochemical reagents include the goat anti-human polyclonal RECK antibody (Santa Cruz, 1:75) and the mouse anti-human monoclonal MMP-2 and MMP-9 antibodies (Boshide, China, 1:100). DAB (diaminobenzidine) staining incubation at room temperature for 2-5 minutes until brown precipitation occurs. Substitution of PBS for primary antibody as negative control.

The positive staining of RECK and MMP-2, 9 located in intra cytoplasm of cells. The deposits were straw yellow, or brown; IHC staining of RECK and MMP-2, -9 were estimated according to the score of intensity and proportion. At 200 \times magnification, at least three regions were randomly selected to analyze the staining results, which were calculated independently and blindly by two investigators. The final scores are calculated by the sum of intensity score and proportion score, which is between 0 and 6. The intensity score was as below: 0 = no staining; +1 = weak staining; +2 = moderate staining; and +3 = strong staining. The proportion score based on the percentage of staining was as below: 0 = no positivity tumor

Low RECK induces a shorter survival rate

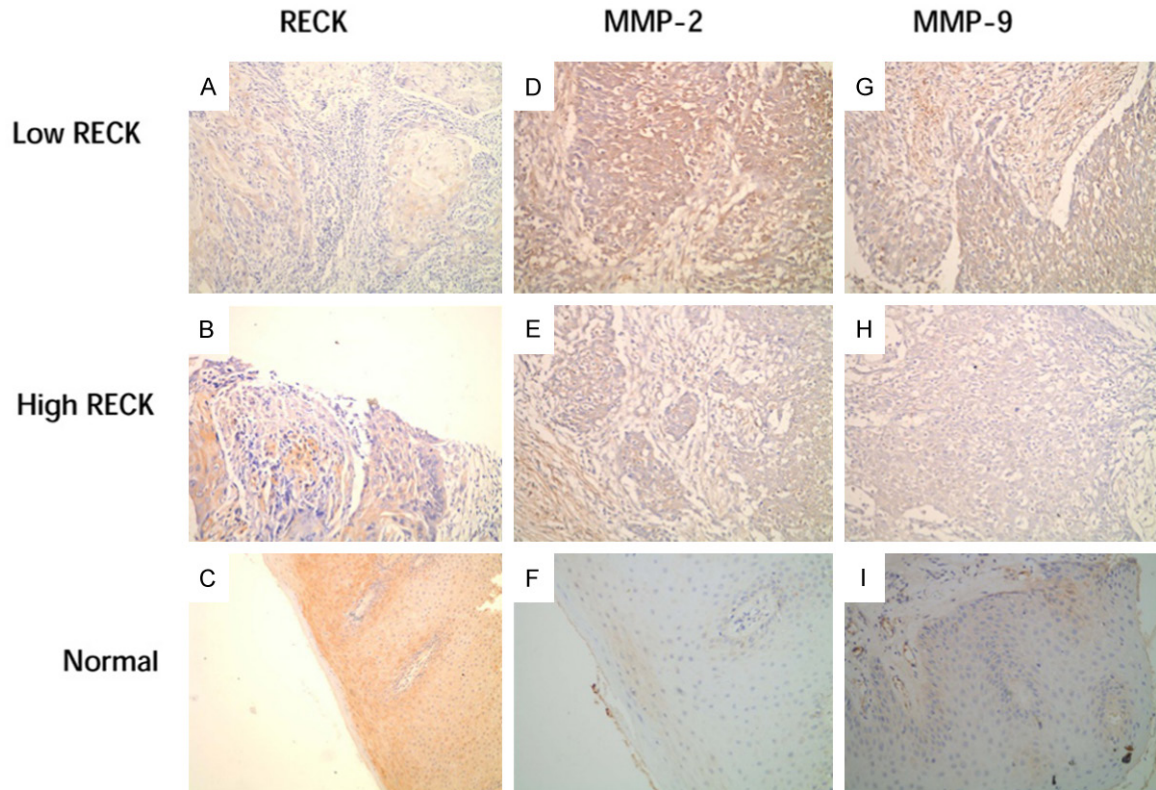


Figure 1. Immunohistochemical staining of OSCC and control group. IHC staining of RECK is shown in (A and B); MMP-2 in OSCC tissues is shown in (D and E); and MMP-9 in OSCC tissues is shown in (G and H). IHC staining of RECK, MMP-2 and MMP-9 in normal oral mucosa is exhibited in (C, F and I).

cell; +1 = <25% positivity; +2 = 26-50% tumor cell positivity; and +3 = >50% tumor cell positivity. Then the positive species of RECK and MMP-2, -9 were divided into low expression and high expression based on the sum of the score [8].

Statistical analyses

All statistical data were analyzed by SPSS 23.0 software. Chi-square test was used to analyze the relation between the expression of RECK, MMP-2, -9 and clinicopathological features. Fisher's exact test for not applicable Chi-Square Test. Spearman's rank correlation was used to appraise the correlation between variables. Disease-free survival (DFS) or overall survival (OS) was analyzed by univariate and multivariate Cox regression. Survival curves were calculated by Kaplan-Meier method and analyzed by logistic rank test.

Follow-up

Patients in this study were regularly followed for 5 years. All patients in our study were routinely

followed up until death or study deadline (December 8, 2016). DFS and OS are two evaluation methods for prognostic analysis. The former measures the first recurrence at any site, and the latter measures the death in any case. During the follow-up period, patients with other malignant tumors were not considered to have recurrent cancer.

Results

We explored the expression levels of RECK, MMP-2, and MMP-9 in OSCC patients, and their relationships with the clinicopathologic findings of the patients. Furthermore, we elucidated the effect of RECK expression level on 5-year survival in OSCC patients.

Immunohistochemical expression of RECK, MMP-2, and MMP-9 in OSCC and normal tissue

Immunohistochemical staining for RECK, MMP-2, and MMP-9 are shown in (Figure 1). IHC staining of RECK, MMP-2, and MMP-9 were mainly located in the cytoplasm, with a straw

Low RECK induces a shorter survival rate

Table 1. The expression of RECK, MMP-2, and MMP-9 in OSCC

	n	RECK		P
		Low	High	
MMP-2				
Low	28	5	23	0.000 ^a
High	80	47	33	
MMP-9				
Low	32	6	26	0.000 ^a
High	76	46	30	

^a $P < 0.0001$.

yellow, or brown color. The expression of RECK in OSCC was significantly lower than that in the control, while the expression of MMP-2, or MMP-9 in OSCC was increased. The positive expression levels of MMP-2 and MMP-9 increased with the loss of histologic differentiation, the occurrence of lymphatic metastasis, and the increase of OSCC clinical stage ($P < 0.05$) (Table 2). A high expression level of RECK was negatively correlated with a high level of MMP-2 and MMP-9 ($P < 0.001$, $r = -0.653$) (Table 1).

Correlation of RECK expression with clinicopathologic characteristics in OSCC patients

In our total of 108 OSCC cases, 56 (51.9%) had high expression of RECK and 52 (48.1%) were low. The high expression rate was reduced with the loss of histologic differentiation, occurrence of lymphatic metastasis, and increase in clinical stage ($P < 0.05$). The correlations between RECK expression and clinicopathologic characteristics in OSCC patients are shown in (Table 2). The expression level of RECK was significantly correlated with the loss of histologic differentiation ($P < 0.000$), occurrence of lymphatic metastasis ($P < 0.000$), and increase of clinical stage ($P < 0.05$).

Clinical results

In our study, 108 OSCC patients with an average age of 52 years (ranging from 27 to 72 years, with median age of 48 years) were included. The average follow-up period was 58 months (median, 59 months; range, 4-156 months). By the time our study was completed, 38 (35.2%) patients had died and 70 (64.8%) were still alive.

Univariate analysis for DFS

Univariate analysis and clinicopathologic features of RECK, MMP-2, and MMP-9 expressions are shown in (Table 3). Univariate analysis for DFS using Cox regression analysis was used to validate the univariate analysis for DFS which proved low level expression of RECK ($P < 0.05$), high level of MMP-9 ($P < 0.05$), loss of histologic differentiation ($P < 0.05$), occurrence of lymphatic metastasis ($P < 0.05$), and increase of clinical stage ($P < 0.05$) were significant negative prognostic predictors in OSCC patients.

Cox multiple regression analysis

Cox multiple regression analysis was used to evaluate the prognostic value of all variables in patients with OSCC. We concluded that low RECK expression and histologic differentiation were independent prognostic factors, indicating a worse prognosis ($P < 0.05$) (Table 4).

Kaplan-Meier survival analysis

According to the expression level of RECK in OSCC, Kaplan-Meier analysis was used for DFS and OS, as shown in (Figures 2 and 3). Patients with high RECK expression ($n = 56$) showed higher DFS ($P = 0.013$, log-rank test) and OS ($P = 0.008$, log-rank test) rates than patients with low RECK expression ($n = 52$).

Discussion

We discovered an imbalance of RECK and MMPs expression in OSCC patients. Immunohistochemistry showed that the expression of RECK was significantly inhibited in OSCC tissues compared to the normal control group. In contrast, the expression of MMP-2 and MMP-9 was significantly increased in OSCC. The results of the univariate survival analysis showed that the low expression of RECK, the high expression of MMP-9, the loss of histologic differentiation, the occurrence of lymphatic metastasis, and the increase of clinical stage served as significant negative prognostic predictors in OSCC patients. Cox multiple regression analysis was used to evaluate the prognostic value of all variables in patients with OSCC. Thus, we concluded that low RECK expression and the loss of differentiation degree were independent important prognostic factors, indicating a worse prognosis.

Low RECK induces a shorter survival rate

Table 2. Relationship between expression of RECK, MMP-2, MMP-9 and clinicopathologic features

Variables	Category	RECK			P	MMP-2		P	MMP-9		P
		low	high			low	high		low	high	
Gender	male	64	30	34	0.94	14	50	0.247	12	52	0.012
	female	44	22	22		14	30		18	26	
Age	<60	44	20	24	0.642	9	35	0.164	16	28	0.099
	≥60	64	32	32		19	45		14	50	
Differentiation	well	62	18	44	0	24	38	0.001	28	34	0
	mod/poor	46	34	12		4	42		2	44	
Lymph node metastasis	yes	50	38	12	0.019	6	44	0.002	7	43	0.003
	no	58	14	44		22	36		23	35	
T stage	T1, T2	62	18	44	0	26	36	0	28	34	0
	T3, T4	23	34	12		2	44		2	44	

P<0.05.

Table 3. Univariate analysis of prognostic factors in the Cox proportional hazards model

Variable	Category	Risk ratio	Univariate	P
			95% confidence interval	
Gender	male/female	1.923	0.676-5.989	0.194
Age	<60/≥60	0.449	0.067-3.987	0.542
Differentiation	well/mod, poor	0.675	0.257-4.743	0.018
Lymph node metastasis	yes/no	2.334	0.908-6.556	0.039
T stage	T1, T2/T3, T4	0.656	0.584-6.981	0.027
MMP-2	high/low	2.113	0.711-6.918	0.063
MMP-9	high/low	2.409	0.809-5.878	0.040
RECK	positive/negative	0.494	0.278-0.878	0.016

P<0.05.

Table 4. Multivariate regression analysis

Variable	B	OS			P	B	DFS			P
		Hazard Ratio	95% Confidence Interval				Hazard Ratio	95% Confidence Interval		
RECK expression	-1.785	9.564	0.047-0.510	0.002	-1.438	4.564	0.064-0.9864	0.037		
Histologic differentiation	-2.397	13.754	0.028-0.343	0.000	-1.556	4.987	0.049-0.898	0.030		

P<0.05.

RECK expression is significantly downregulated in different types of tumors, such as non-small cell lung cancer, colorectal cancer, and esophageal cancer, and is closely related to high expression of MMP-2 and MMP-9 [12-14]. Increasing the expression of RECK to inhibit metastasis and progression of tumors seems to yield a better prognosis. Recent studies have also shown that there are several ways to up-regulate RECK expression such as, inhibiting RECK methylation to abate the expression of MMPs, and ultimately inhibiting the invasion and metastasis of tumors [15, 16]. By up-regu-

lation of RECK, AKT and other signaling pathways can be inactivated, ultimately inhibiting the proliferation and invasion of cancer cells [10].

Down-regulation of RECK leads to the overactivation of MMP-2 and MMP-9, which are secreted by cancer cells and are positively correlated with tumorigenesis and progression, including invasiveness of angiogenesis, metastasis, and shortened survival time of patients [17-19]. This idea is further supported by our findings. In our study, the immunohistochemical results

Low RECK induces a shorter survival rate

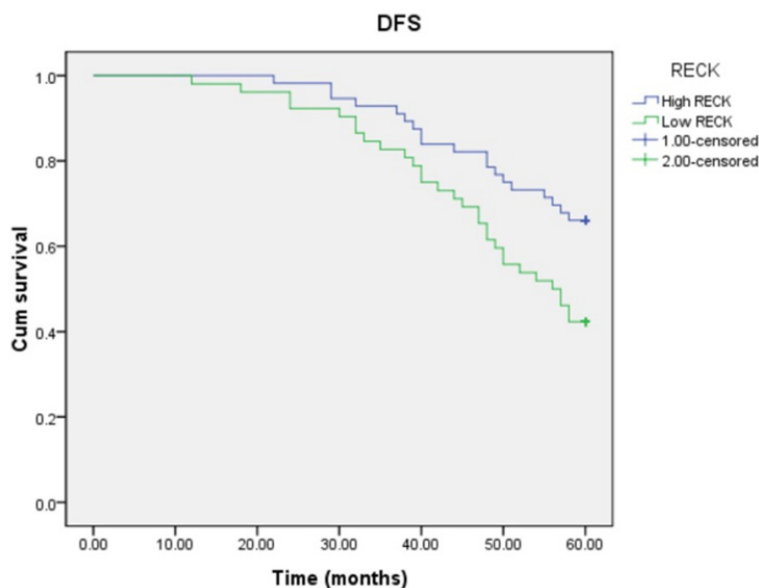


Figure 2. Kaplan-Meier methods for DFS analysis ($P = 0.013$, log-rank test).

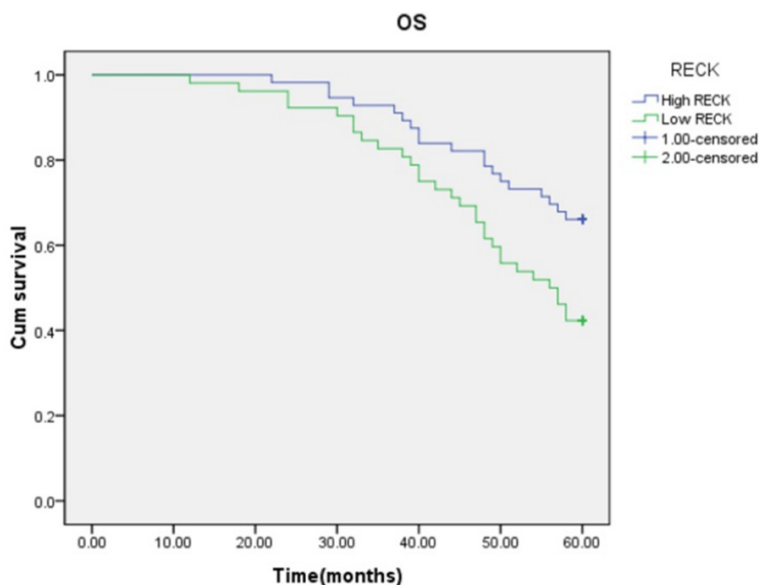


Figure 3. Kaplan-Meier methods for OS analysis ($P = 0.008$, log-rank test). Patients with high RECK expression had a significantly higher survival rate than those with low RECK expression (dotted line) ($P = 0.016$, Log-rank test).

indicated that RECK was down-regulated. In addition, we also found that patients with low expression of RECK had a lower 5-year survival rate than those with high RECK expression for OS and DFS. This suggests that the level of RECK expression of OSCC may play an important role in predicting cancer outcome and the recurrence risk.

Since RECK is a recognized tumor suppressor, exploring the mechanism of its down-regulation is very important to tumor treatment. The mechanism might be downregulation of RECK-activated oncogenic P53 or Ras signaling, closely associated with the presence of the rs16932912 (G/A) SNP, including ERK1/2, Mekk/Sek/Jnk, and Raf/Mek/Erk pathways [20-24]. Many recent studies indicate that microRNAs can accelerate tumor proliferation and metastasis by targeting RECK [25, 26]. Therefore, the tumor signaling pathway activated by RECK and microRNA targeting RECK to inhibit the proliferation of OSCC also deserve further verification.

In a number of clinical samples, it was found that the RECK/MMPs imbalance was already present in other types of tumors [27, 28]. Our research showed low expression of RECK and high expression of MMP-2, and MMP-9 were positively correlated with loss of histological differentiation, occurrence of lymphatic and increased clinical stage of OSCC. We proposed that, for the first time to our knowledge, low RECK expression is a poor prognostic factor in OSCC patients. RECK may inhibit MMP-2, and MMP-9 through the imbalance of the ratio of RECK/MMP-2, MMP-9 in the occurrence and metastasis of OSCC, providing a prognostic factor for the prognosis of OSCC. The imbalance of RECK/MMPs in OSCC, provides a new research prospect for the expression and regulation of MMPs. The regulation of the RECK/MMPs imbalance could be a vital new approach for the prevention and treatment of OSCC, as well as a therapeutic target for novel drug development.

Conclusion

RECK may prevent metastasis through a RECK/MMP-2, -9 imbalance and improve OSCC patients' prognosis. Low expression of RECK presents a significant negative prognostic predictor. In addition, RECK may be a promising prognostic indicator and a potential therapeutic target for cancer molecular targeted therapy.

Acknowledgements

Thanks to the Department of Pathology, Tongji Hospital Tongji Medical College to provide tumor specimens for our research.

Disclosure of conflict of interest

None.

Address correspondence to: Dr. Shuli Deng, Department of Conservative Dentistry and Endodontics, The Affiliated Stomatology Hospital, Zhejiang University School of Medicine, 395 Yanan Road, Hangzhou 310006, Zhejiang, China. Tel: +86-571-87217437; E-mail: Dengshuli@zju.edu.cn; Dr. Xuejin Tao, Center of Stomatology, Tongji Hospital Affiliated to Tongji Medical College Hua Zhong University of Science and Technology, Wuhan 430030, Hubei, China. Tel: +86-27-83662688; E-mail: 93767345@qq.com

References

- [1] Page-McCaw A, Ewald AJ and Werb Z. Matrix metalloproteinases and the regulation of tissue remodeling. *Nat Rev Mol Cell Biol* 2007; 8: 221-33.
- [2] Parks WC, Wilson CL and López-Boado YS. Matrix metalloproteinases as modulators of inflammation and innate immunity. *Nat Rev Immunol* 2004; 4: 617-29.
- [3] Egeblad M and Werb Z. New roles for matrix metalloproteinases in cancer. *Nat Rev Cancer* 2002; 2: 163-176.
- [4] Thammineni KL, Thakur GK, Kaur N and Banerjee BD. Significance of MMP-9 and VEGF-C expression in North Indian women with breast cancer diagnosis. *Mol Cell Biochem* 2019; 457: 93-103.
- [5] Nishio K, Motozawa K, Omagari D, Gojoubori T, Ikeda T, Asano M and Gionhaku N. Comparison of MMP2 and MMP9 expression levels between primary and metastatic regions of oral squamous cell carcinoma. *J Oral Sci* 2016; 58: 59-65.
- [6] Noda M, Oh J, Takahashi R, Kondo S, Kitayama H and Takahashi C. RECK: a novel suppressor of malignancy linking oncogenic signaling to extracellular matrix remodeling. *Cancer Metastasis Rev* 2003; 22: 167-175.
- [7] Alexius-Lindgren M, Andersson E, Lindstedt I and Engström W. The RECK gene and biological malignancy-its significance in angiogenesis and inhibition of matrix metalloproteinases. *Anticancer Res* 2014; 34: 3867-3873.
- [8] Discacciati MG, Gimenes F, Pennacchi PC, Faião-Flores F, Zeferino LC, Derchain SM, Teixeira JC, Costa MC, Zonta M, Termini L, Boccardo E, Longatto-Filho A, Consolaro ME, Villa LL and Maria-Engler SS. MMP-9/RECK imbalance: a mechanism associated with high-grade cervical lesions and genital infection by human papillomavirus and chlamydia trachomatis. *Cancer Epidemiol Biomarkers Prev* 2015; 24: 1539-47.
- [9] Lee HN, Mitra M, Bosompra O, Corney DC, Johnson EL, Rashed N, Ho LD and Collier HA. RECK isoforms have opposing effects on cell migration. *Mol Biol Cell* 2018; 29: 1825-1838.
- [10] Jian Y, Xu CH, Li YP, Tang B, Xie SH and Zeng EM. Downregulated microRNA-30b-3p inhibits proliferation, invasion and migration of glioma cells via inactivation of the AKT signaling pathway by upregulating RECK. *Biosci Rep* 2019; 39.
- [11] Wang N, Wang Q, Chi J, Xiang F, Lin M, Wang W, Wei F and Feng Y. Carcinoembryonic antigen cell adhesion molecule 1 inhibits the antitumor effect of neutrophils in tongue squamous cell carcinoma. *Cancer Sci* 2019; 110: 519-529.
- [12] Shen J, Wang B, Zhang T, Zhu N, Wang Z, Jin J, He Y and Hu M. Suppression of non-small cell lung cancer growth and metastasis by a novel small molecular activator of RECK. *Cell Physiol Biochem* 2018; 45: 1807-1817.
- [13] Iseki Y, Shibutani M, Maeda K, Nagahara H, Fukuoka T, Matsutani S, Hirakawa K and Ohira M. MicroRNA-96 promotes tumor invasion in colorectal cancer via RECK. *Anticancer Res* 2018; 38: 2031-2035.
- [14] Lu Y, Zabihula B, Yibulayin W and Liu X. Methylation and expression of RECK, P53 and RUNX genes in patients with esophageal cancer. *Oncol Lett* 2017; 14: 5293-5298.
- [15] Yang F, He K, Huang L, Zhang L, Liu A and Zhang J. Casticin inhibits the activity of transcription factor Sp1 and the methylation of RECK in MGC803 gastric cancer cells. *Exp Ther Med* 2017; 13: 745-750.
- [16] Jia W, Deng F, Fu W, Hu J, Chen G, Gao X, Tan X, Li G, Liu G and Zhu S. Curcumin suppresses wilms' tumor metastasis by inhibiting RECK methylation. *Biomed Pharmacother* 2019; 111: 1204-1212.

Low RECK induces a shorter survival rate

- [17] Deryugina EI and Quigley JP. Matrix metalloproteinases and tumor metastasis. *Cancer Metastasis Rev* 2006; 25: 9-34.
- [18] Noda M, Oh J, Takahashi R, Kondo S, Kitayama H and Takahashi C. RECK: a novel suppressor of malignancy linking oncogenic signaling to extracellular matrix remodeling. *Cancer Metastasis Rev* 2003; 22: 167-175.
- [19] Levin G, Coelho TM, Nóbrega NG, Trombetta-Lima M, Sogayar MC and Carreira ACO. Spatio-temporal expression profile of matrix metalloproteinase (MMP) modulators RECK and Sparc during the rat ovarian dynamics. *Reprod Biol Endocrinol* 2018; 16: 116.
- [20] Zhang X, Wang J, Liu H, Zhang Y and Dong F. The clinicopathologic relevance of RECK gene polymorphisms in ameloblastoma. *Arch Oral Biol* 2017; 79: 77-86.
- [21] Chang HC, Liu LT and Hung WC. Involvement of histone deacetylation in ras-induced down-regulation of the metastasis suppressor RECK. *Cell Signal* 2004; 16: 675-9.
- [22] Hsu MC, Chang HC and Hung WC. HER-2/neu represses the metastasis suppressor RECK via ERK and Sp transcription factors to promote cell invasion. *J Biol Chem* 2006; 281: 4718-25.
- [23] Liu Y, Li L, Liu Y, Geng P, Li G, Yang Y and Song H. RECK inhibits cervical cancer cell migration and invasion by promoting p53 signaling pathway. *J Cell Biochem* 2018; 119: 3058-3066.
- [24] Ning S and Ma X. Dephosphorylation-induced EZH2 activation mediated RECK downregulation by ERK1/2 signaling. *J Cell Physiol* 2019; 234: 19010-19018.
- [25] Pan, Y, Liang, H, Chen, W, Zhang, H, Wang, N, Wang, F, Zhang S, Liu Y, Zhao C, Yan X, Zhang J, Zhang CY, Gu H, Zen K and Chen X. microRNA-200b and microRNA-200c promote colorectal cancer cell proliferation via targeting the reversion-inducing cysteine-rich protein with Kazal motifs. *RNA Biol* 2015; 12: 276-89.
- [26] Shen B, Yu S, Zhang Y, Yuan Y, Li X, Zhong J and Feng J. miR-590-5p regulates gastric cancer cell growth and chemosensitivity through RECK and the AKT/ERK pathway. *Onco Targets Ther* 2016; 9: 6009-6019.
- [27] Jacomasso T, Trombetta-Lima M, Sogayar MC and Winnischofer SM. Down-regulation of reversion-inducing cysteine-rich protein with Kazal motifs in malignant melanoma: inverse correlation with membrane-type 1-matrix metalloproteinase and tissue inhibitor of metalloproteinase 2. *Melanoma Res* 2014; 24: 32-9.
- [28] Reis ST, Pontes-Junior J, Antunes AA, de Sousa-Canavez JM, Dall'Oglio MF, Passerotti CC, Abe DK, Crippa A, da Cruz JA, Timoszczuk LM, Srougi M and Leite KR. MMP-9 overexpression due to TIMP-1 and RECK underexpression is associated with prognosis in prostate cancer. *Int J Biol Markers* 2011; 26: 255-61.