




Since January 2020 Elsevier has created a COVID-19 resource centre with free information in English and Mandarin on the novel coronavirus COVID-19. The COVID-19 resource centre is hosted on Elsevier Connect, the company's public news and information website.

Elsevier hereby grants permission to make all its COVID-19-related research that is available on the COVID-19 resource centre - including this research content - immediately available in PubMed Central and other publicly funded repositories, such as the WHO COVID database with rights for unrestricted research re-use and analyses in any form or by any means with acknowledgement of the original source. These permissions are granted for free by Elsevier for as long as the COVID-19 resource centre remains active.



## Incidence of thrombotic complications in critically ill ICU patients with COVID-19

F.A. Klok<sup>a,\*</sup>, M.J.H.A. Kruip<sup>b</sup>, N.J.M. van der Meer<sup>c</sup>, M.S. Arbous<sup>d</sup>, D.A.M.P.J. Gommers<sup>e</sup>, K.M. Kant<sup>f</sup>, F.H.J. Kaptein<sup>a</sup>, J. van Paassen<sup>d</sup>, M.A.M. Stals<sup>a</sup>, M.V. Huisman<sup>a,1</sup>, H. Endeman<sup>e,1</sup>

<sup>a</sup> Department of Thrombosis and Hemostasis, Leiden University Medical Center, Leiden, the Netherlands

<sup>b</sup> Department of Haematology, Erasmus University Medical Center, Rotterdam, the Netherlands

<sup>c</sup> Department of Anesthesiology and Critical Care, Amphia Hospital Breda and Oosterhout the Netherlands and TIAS/Tilburg University, Tilburg, the Netherlands

<sup>d</sup> Department of Intensive Care Medicine, Leiden University Medical Center, Leiden, the Netherlands

<sup>e</sup> Department of Adult Intensive Care, Erasmus Medical Center, Rotterdam, the Netherlands

<sup>f</sup> Department of Intensive Care, Amphia Hospital, Breda, the Netherlands

### ARTICLE INFO

#### Keywords:

COVID-19  
Pulmonary embolism  
Deep vein thrombosis  
Stroke  
Thromboprophylaxis

### ABSTRACT

**Introduction:** COVID-19 may predispose to both venous and arterial thromboembolism due to excessive inflammation, hypoxia, immobilisation and diffuse intravascular coagulation. Reports on the incidence of thrombotic complications are however not available.

**Methods:** We evaluated the incidence of the composite outcome of symptomatic acute pulmonary embolism (PE), deep-vein thrombosis, ischemic stroke, myocardial infarction or systemic arterial embolism in all COVID-19 patients admitted to the ICU of 2 Dutch university hospitals and 1 Dutch teaching hospital.

**Results:** We studied 184 ICU patients with proven COVID-19 pneumonia of whom 23 died (13%), 22 were discharged alive (12%) and 139 (76%) were still on the ICU on April 5th 2020. All patients received at least standard doses thromboprophylaxis. The cumulative incidence of the composite outcome was 31% (95%CI 20–41), of which CTPA and/or ultrasonography confirmed VTE in 27% (95%CI 17–37%) and arterial thrombotic events in 3.7% (95%CI 0–8.2%). PE was the most frequent thrombotic complication ( $n = 25$ , 81%). Age (adjusted hazard ratio (aHR) 1.05/per year, 95%CI 1.004–1.01) and coagulopathy, defined as spontaneous prolongation of the prothrombin time  $> 3$  s or activated partial thromboplastin time  $> 5$  s (aHR 4.1, 95%CI 1.9–9.1), were independent predictors of thrombotic complications.

**Conclusion:** The 31% incidence of thrombotic complications in ICU patients with COVID-19 infections is remarkably high. Our findings reinforce the recommendation to strictly apply pharmacological thrombosis prophylaxis in all COVID-19 patients admitted to the ICU, and are strongly suggestive of increasing the prophylaxis towards high-prophylactic doses, even in the absence of randomized evidence.

COVID-19 may predispose to both venous and arterial thromboembolic disease due to excessive inflammation, hypoxia, immobilisation and diffuse intravascular coagulation (DIC) [1–4]. Remarkably, thrombotic complications have hardly been described [1–4]. Precise knowledge of the incidence of thrombotic complications in COVID-19 patients is important for decision making with regard to intensity of thromboprophylaxis, especially in patients admitted to the intensive care unit (ICU) who are at highest thrombotic risk.

We evaluated the incidence of the composite outcome of venous thromboembolism (VTE) and arterial thrombotic complications in all COVID-19 patients admitted to the ICU of 2 Dutch university hospitals

and 1 Dutch teaching hospital. Our composite outcome consisted of acute pulmonary embolism (PE), deep-vein thrombosis (DVT), ischemic stroke, myocardial infarction or systemic arterial embolism. Importantly, in all participating hospitals, diagnostic tests were only applied if thrombotic complications were clinically suspected. We calculated the cumulative incidence of the composite outcome, as well as for the venous and arterial thrombotic complications separately. The index date was the moment of ICU admission. Patients were followed until ICU discharge, until they died, or until April 5th 2020, whichever came first. We performed backward conditional regression analyses to identify relevant determinants. The Institutional Review Boards of the

\* Corresponding author at: Department of Thrombosis and Hemostasis, Leiden University Medical Center, Albinusdreef 2, 2300RC Leiden, the Netherlands.

E-mail address: [f.a.klok@LUMC.nl](mailto:f.a.klok@LUMC.nl) (F.A. Klok).

<sup>1</sup> equally contributed as senior authors.

**Table 1**  
Characteristics of included patients.

Age (Mean, standard deviation)	64 (12)
Male sex (number, %)	139 (76)
Body weight (mean, standard deviation)	87 (16)
Active cancer (number, %)	5 (2.7)
Coagulopathy during admission <sup>a</sup> (n, %)	70 (38)
Therapeutic anticoagulation at admission (n, %)	17 (9.2)
Renal replacement therapy during admission (n, %)	23 (13%)

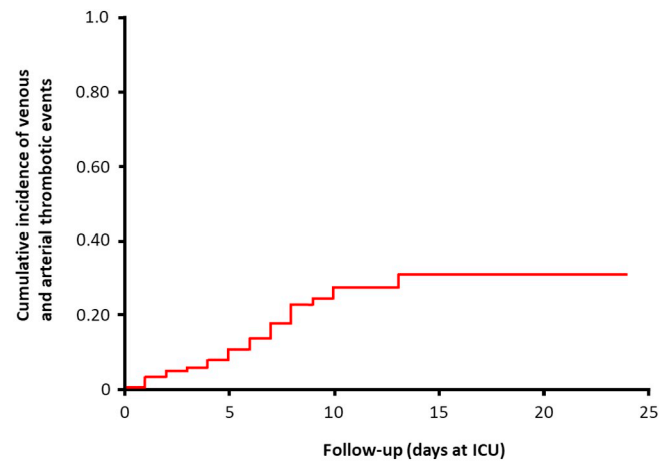
<sup>a</sup> Defined as: spontaneous prolongation of the prothrombin time (PT) > 3 s or activated partial thromboplastin time (APTT) > 5 s.

participating hospitals waived the need for informed consent due to the observational nature of our study.

We studied 184 patients with proven COVID-19 pneumonia (Table 1) admitted to the ICU between March 7th and April 5th 2020. Of those, 23 died (13%), 22 were discharged alive (12%) and 139 (76%) were still on the ICU on April 5th 2020. The median duration of the observation per patient was 7 days (IQR 1-13). All patients received at least standard doses thromboprophylaxis, although regimens differed between hospitals and doses increased over time (Table 2). The cumulative incidence of the composite outcome was 31% (95%CI 20-41%; Fig. 1, Table 3), of which CTPA and/or ultrasonography confirmed VTE in 27% (95%CI 17-37%) and arterial thrombotic events in 3.7% (95%CI 0-8.2%). PE was the most frequent thrombotic complication (n = 25, 81%). Age (adjusted hazard ratio (aHR) 1.05/per year, 95%CI 1.004-1.01) and coagulopathy, defined as spontaneous prolongation of the prothrombin time > 3 s or activated partial thromboplastin time > 5 s (aHR 4.1, 95%CI 1.9-9.1), were independent predictors of thrombotic complications.

Despite systematic thrombosis prophylaxis, the 31% incidence of thrombotic complications in ICU patients with COVID-19 infections is remarkably high and well comparable to the VTE incidence in other patient categories with overt DIC [5]. Notably, none of our patients actually developed DIC.

What are the consequences of our observations? First, they represent a conservative estimation, because the majority of patients was still on the ICU and therefore at risk after the described observation period. Also, VTE is more difficult to recognize in intubated patients with a higher threshold to perform diagnostic imaging tests because of strict isolation. If VTE screening had been applied, the incidence could



**Fig. 1.** Cumulative incidence of venous and arterial thrombotic complications during the course of intensive care unit admission of patients with proven COVID-19 pneumonia.

have been even higher. We have to acknowledge that due to the design of the study, we could not adjust our findings for the actual administered doses of nadroparin, nor study the effect of the changes in the local protocols for thromboprophylaxis indicated in Table 2. In view of this, our findings reinforce the recommendation to strictly apply pharmacological thrombosis prophylaxis in all COVID-19 patients admitted to the ICU, and are suggestive of increasing the prophylaxis towards high-prophylactic doses, e.g. going from enoxaparin 40 mg OD to 40 mg BID, even in the absence of randomized evidence.

Finally, we propose that, rather than treating all patients with COVID-19 infections at the ICU with therapeutic anticoagulation, physicians should be vigilant for signs of thrombotic complications, and order appropriate diagnostic tests at a low threshold [5].

**Author contributions**

FAK, MJHAK and MWH designed the study based on the observations of HE and DAMPJG. FAK, MJHAK, FHJK, MAMS, NJMvdM and KMK gathered data. FAK and MVH performed the analyses drafted the first version of the manuscript. All authors revised the manuscript

**Table 2**  
Local protocol for thromboprophylaxis in participating centres for patients admitted to the intensive care unit during the study period.

Site	
Leiden University Medical Center	nadroparin 2850 IU sc per day or 5700 IU per day if body weight > 100 kg
Erasmus University Medical Center	Nadroparin 5700 IU per day; nadroparin 5700 IU sc twice daily from April 4th 2020 and onwards
Amphia Hospital Breda	Nadroparin 2850 IU sc per day or 5700 IU per day if body weight > 100 kg; nadroparin 5700 IU sc per day from March 30th 2020 and onwards

**Table 3**  
Description of thrombotic complications.

Type of event	Number of cases	Relevant details
Pulmonary embolism	25	– 18 cases with at least PE in segmental arteries, 7 cases PE limited to subsegmental arteries
Other venous thromboembolic events	3	– 1 proximal deep-vein thrombosis of the leg – 2 catheter related upper extremity thrombosis
Arterial thrombotic events	3	– All ischemic strokes

Note: acute pulmonary embolism was diagnosed with CT-pulmonary angiography, deep vein thrombosis/upper extremity vein thrombosis was diagnosed with ultrasonography, strokes were diagnosed with CT.

critically for important intellectual content and agree with the final version.

#### Acknowledgements

None.

#### Disclosures

Frederikus Klok reports research grants from Bayer, Bristol-Myers Squibb, Boehringer-Ingelheim, Daiichi-Sankyo, MSD and Actelion, the Dutch Heart foundation and the Dutch Thrombosis association, all outside the submitted work. Menno Huisman reports grants from ZonMW Dutch Healthcare Fund, and grants and personal fees from Boehringer-Ingelheim, Pfizer-BMS, Bayer Health Care, Aspen, Daiichi-Sankyo, all outside the submitted work. Marieke Kruip reports

unrestricted research grants from Bayer, Boehringer-Ingelheim, Daiichi-Sankyo, Pfizer, Sobi, and The Netherlands Organisation for Health Research and Development (ZonMW). The other authors having nothing to disclose.

#### References

- [1] T. Chen, D. Wu, H. Chen, et al., Clinical characteristics of 113 deceased patients with coronavirus disease 2019: retrospective study, *Bmj* 368 (2020) m1091.
- [2] W.J. Guan, Z.Y. Ni, Y. Hu, et al., Clinical characteristics of coronavirus disease 2019 in China, *N. Engl. J. Med.* (2020), <https://doi.org/10.1056/NEJMoa2002032>.
- [3] D. Wang, B. Hu, C. Hu, et al., Clinical Characteristics of 138 Hospitalized Patients with 2019 Novel Coronavirus-Infected Pneumonia in Wuhan, China, *Jama*, 2020.
- [4] F. Zhou, T. Yu, R. Du, et al., Clinical course and risk factors for mortality of adult inpatients with COVID-19 in Wuhan, China: a retrospective cohort study, *Lancet* 395 (2020) 1054–1062.
- [5] M. Levi, M. Scully, How I treat disseminated intravascular coagulation, *Blood* 131 (2018) 845–854.