



Since January 2020 Elsevier has created a COVID-19 resource centre with free information in English and Mandarin on the novel coronavirus COVID-19. The COVID-19 resource centre is hosted on Elsevier Connect, the company's public news and information website.

Elsevier hereby grants permission to make all its COVID-19-related research that is available on the COVID-19 resource centre - including this research content - immediately available in PubMed Central and other publicly funded repositories, such as the WHO COVID database with rights for unrestricted research re-use and analyses in any form or by any means with acknowledgement of the original source. These permissions are granted for free by Elsevier for as long as the COVID-19 resource centre remains active.

Biology and Diseases of Swine

Kristi L. Helke, DVM, PhD, DACVP^a, Paula C. Ezell, DVM, DACLAM^b, Raimon Duran-Struuck, DVM, PhD, DACLAM^c and M. Michael Swindle, DVM, DACLAM, DECLAM^d

^aDepartments of Comparative Medicine and Pathology and Laboratory Medicine, Medical University of South Carolina, Charleston, SC, USA ^bIntuitive Surgical, Inc., Norcross, GA, USA ^cColumbia Center of Translational Immunology, Department of Surgery; Institute of Comparative Medicine; Columbia University Medical Center, New York, NY, USA ^dMedical University of South Carolina, Department of Comparative Medicine and Department of Surgery, Charleston, SC, USA

OUTLINE

I. Introduction	695	III. Diseases	709
A. Taxonomy	696	A. Infectious Diseases	709
B. Availability and Sources	696	B. Metabolic/Nutritional Diseases	752
C. Laboratory Management and Husbandry	696	C. Iatrogenic Diseases	754
D. Use in Research	699	D. Neoplastic Diseases	755
II. Biology	699	E. Miscellaneous	755
A. Unique Physiologic Characteristics and Attributes	699	Acronyms Used in Chapter	755
B. Nutrition	700	Acknowledgments	756
C. Reproduction	700	References	756
D. Behavior	704		
E. Immunology and Use of Swine in Xenotransplantation	704		

I. INTRODUCTION

Swine are used in biomedical research both as general large-animal biological models in teaching and research, and for the study of specific disease conditions due to their anatomic and physiological similarities to humans (Swindle, 2007; Helke and Swindle, 2013; McAnulty, 2012; Swindle *et al.*, 2012; Kobayashi *et al.*, 2012; Matsunari and Nagashima, 2009; Critser *et al.*, 2009). Over the last

decade, swine have become the default model for surgery models as well as translational research, which bridges the gaps between basic science research and clinical applications. The Swine Genome Sequencing Consortium has completed the sequencing of the pig genome, which will help researchers find the putative genes needed to facilitate model development in areas such as cardiovascular disease, xenotransplantation, and neurodegeneration. Textbooks specific to the use of swine as laboratory

animals are available as are websites and proceedings from symposia on the use of swine in research (McAnulty, 2012; Swindle, 2007; Bollen *et al.*, 2010; Minipigs, 2010; Forum, 2013; Tumbleson, 1986; Swindle *et al.*, 1992). Images of all disease entities are available online on several websites (Cornell Veterinary Medicine, 2012; Iowa State University, 2014; Veterinarians, 2013).

While this chapter covers many porcine diseases, many are included for completeness. Some of the diseases have been eradicated from the United States (US) and European Union (EU) and are mentioned here because they are reportable. Also, most readers of this chapter will purchase research animals from a vendor providing specific pathogen-free (SPF) swine. This suggests that there is some essence of biosecurity in place and that many of the diseases are rarely, if ever, seen in the research population. The most important factors to consider when encountering disease in research pigs are as follows: (1) research and husbandry personnel – in this era of global travel, we need to consider reverse zoonosis (especially with swine influenza virus (SIV)), and also protecting people in contact with the animals which may be harboring these diseases, and (2) emerging diseases – since the last iteration of this chapter, we have added porcine circovirus-2 (PCV2), Nipah virus, porcine lymphotropic herpes virus, Ebola virus, and others, some of which were discovered only after human infection.

A. Taxonomy

Order: Artiodactyla (even-toed ungulates)
Family: Suidae
Species: *Sus scrofa domestica*

B. Availability and Sources

Commercial breeds of domestic swine raised for meat production are available worldwide. There is extensive variability in the health status of the various herds. In the US, the designation SPF has a proprietary connotation. It is a program based on management procedures that reduce or eliminate diseases that stunt growth. Pigs designated SPF are a good source for biomedical research; however, the designation does not mean that the animals are completely free of diseases that may interfere with research. It is best to purchase animals from a herd in which the institutional veterinarian has screened for research-complicating diseases. Commercial breeds have limited availability from commercial suppliers of laboratory animals (Safron and Gonder, 1997; Swindle *et al.*, 1994).

When using domestic breeds of swine, the growth rate is a major consideration. Swine reach sexual maturity and a commercial slaughter weight of approximately 115–130 kg at 5–6 months of age. At birth, they weigh approximately 1.4 kg (average); consequently, there is an

exponential growth phase during the adolescent period. Most swine used in research programs are 15–30 kg and are 8–12 weeks of age. Weight gain during this period may be 2–5 kg per week. When selecting a model, age and maturity factors must also be considered. Consequently, domestic swine are rarely used for long-term projects unless the study includes the effect of growth and maturity factors or the animals are involved in agricultural research. Generally, most projects involving a length of >3 weeks would best be performed in miniature swine (Swindle, 2007; Fisher, 1993; Swindle *et al.*, 1994).

Miniature swine are available from commercial breeders of laboratory animals. Commonly used breeds include Yucatan, Hanford, Sinclair, Hormel, and Göttingen. Other breeds of miniature pigs are available in limited quantities from some market areas and include the Panepinto, Vietnamese potbellied, Ohmini, Pitman–Moore, and Chinese dwarf. Generally, the health status of these animals is higher than that of SPF animals, and they are suitable for most biomedical research projects. These animals range from 30 to 50 kg in body weight at sexual maturity and, consequently, are more amenable than larger commercial breeds to long-term projects (Fisher, 1993; Swindle, 1998, 2007; Panepinto, 1986).

C. Laboratory Management and Husbandry

Individual shipments of swine are best separated by time and distance and, in particular, mixing animals from multiple vendors is poor practice. Swine should be purchased from vendor herds that are validated brucellosis-free and qualified pseudorabies-negative by the U.S. Department of Agriculture (USDA). Commercial sources typically implement a vaccination and parasite-control program beginning at weaning age and dependent on the intended experimental use of the animal, such efforts may or may not need additional attention at the research facility. Quality source suppliers will deworm piglets at 4- to 6-week intervals and administer preventive treatments for ectoparasites. Weanling animals are commonly vaccinated against erysipelas and leptospirosis, and breeding animals should be vaccinated in addition against porcine parvovirus, *Bordetella bronchiseptica*, *Pasteurella multocida*, and *Escherichia coli*. Newly received animals should be given a minimum of 72 h to adjust to the new environment during which time physical exams and screening tests for parasites can be performed (Smith and Swindle, 2006). Ideally, diet changes should be gradual over several days, with increased fiber if stress-induced diarrhea develops. Adult swine that are housed long term should have, at a minimum, periodic physical exams that include weight and parasite checks. Vaccination programs for adult swine should be implemented based on risk assessment that considers how the animal will be used in research, what

the housing conditions are, and how close the research herd is to incoming animals of uncertain health status. Ideally, pigs should be purchased from one source with established health status to take advantage of natural herd immunity. The value of good herd health management is illustrated by the observation that swine herds that maintain SPF status have an odds ratio of 0.2 relative to that of conventional herds for the development of diarrhea (Moller *et al.*, 1998).

Swine are best housed in pens rather than in cages. Pens may be constructed of either chain-link fencing or stainless steel or aluminum bars. Wood is best avoided because of pigs' ability to chew it and the difficulty of sanitation. The chosen material should be of sturdy construction because swine can be very destructive. It is best to provide them with indestructible toys or balls to preoccupy them and to satisfy their rooting instincts (Swindle, 2007).

Flooring for swine deserves special consideration. Smooth flooring, such as seamless epoxy, is best avoided. Swine have difficulty with firm footing on these floors, especially when the floors are wet. If contact flooring is used, it should have a rough surface to provide traction and provide wear on the hooves or it should be covered with deep wood-chip bedding. Wood-chip bedding keeps swine clean and satisfies their rooting instinct. However, wood-chip bedding is eaten by swine, especially when they are fasted. Raised flooring has been found to be satisfactory in many laboratory situations. Plastic-coated metal grids are sturdy and easy to sanitize. However, if a cut becomes apparent in the plastic, swine will strip the flooring and eat the plastic. Slatted fiberglass floors with grit to provide hoof wear are generally ideal in most situations. They are lightweight and easy to remove from pens for sanitation (Swindle, 2007).

Swine readily use automatic watering systems. The system should be checked daily to ensure that the water supply is functional because swine are susceptible to 'salt poisoning,' which results in a neurologic syndrome when they are deprived of water. Individual feeding bowls will reduce food aggressive behavior. Food dishes should be secured to the cage or flooring. Swine will tip movable dishes and lose their feed, especially on raised flooring. They will also chew their feeders, which are best made of an indestructible material such as stainless steel (Swindle, 2007).

Swine prefer to have contact with other members of their species. They may be housed together in groups, but dominance fighting will occur unless animals are socialized. Providing cage walls that allow visual and snout contact between animals (Swindle, 2007; Fisher, 1993; Panepinto, 1986) may also satisfy this social instinct. New guidelines require attempts to be made to house social animals in stable pairs or compatible groups unless single housing is scientifically justified

or behavioral issues prohibit cohabitation (Institute of Laboratory Animal Resources (U.S.), Committee on Care and Use of Laboratory Animals, 2011).

Swine can be restrained in slings, such as the Panepinto sling (Panepinto *et al.*, 1983). This method is more humane than agricultural methods such as snout tying and is therefore preferable. Small swine can also be restrained manually in a manner similar to that of dogs. Swine may be trained to walk on a leash and can also be restrained against the side of the cage with portable handheld panels (typical size 60 × 80 cm) (Swindle, 2007).

Intramuscular injections may be administered in the neck or hind limb. Venous access sites include the following veins: auricular, cephalic, external and internal jugular, anterior vena cava, lateral saphenous, cranial abdominal (mammary), and femoral (Figs 16.1–16.8).

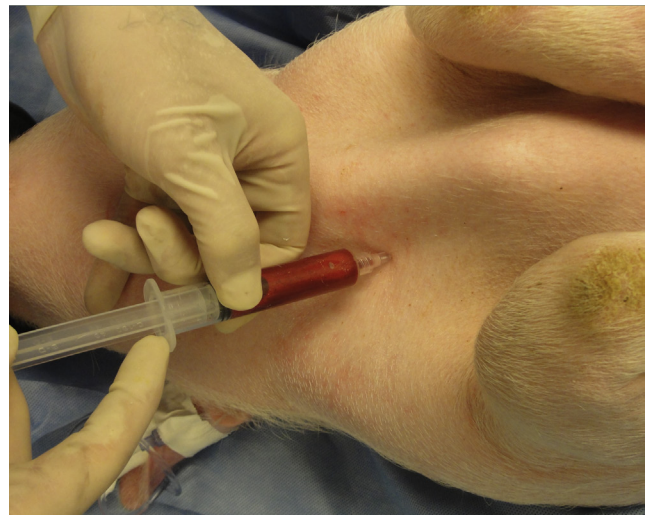

FIGURE 16.1 Blood collection from the cranial vena cava. To prevent damage to the recurrent laryngeal nerve, samples should only be collected from the right side.

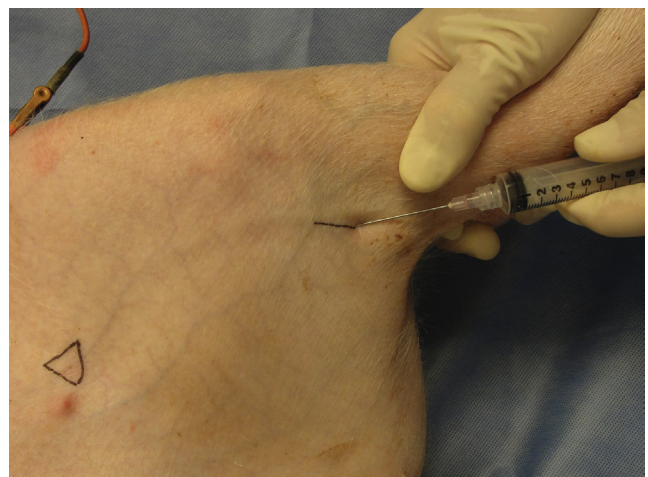

FIGURE 16.2 Venipuncture site of the left saphenous vein.

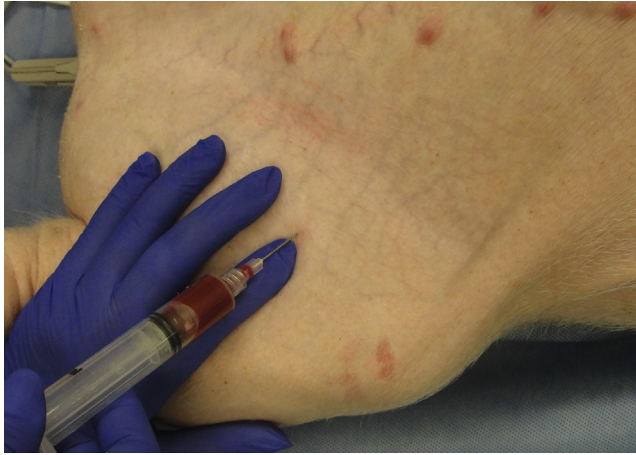

FIGURE 16.3 Venipuncture of femoral vein. Palpate the pulse with a finger and then guide needle into vessel. The vessel is not visualized on the surface.

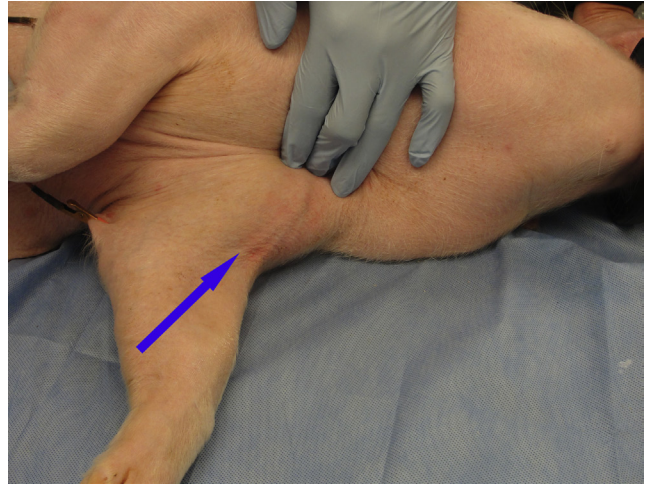


FIGURE 16.6 Venipuncture site of the cephalic vein. The vessel courses from the forelimb into the thoracic inlet. Two branches of the vessel are visible.

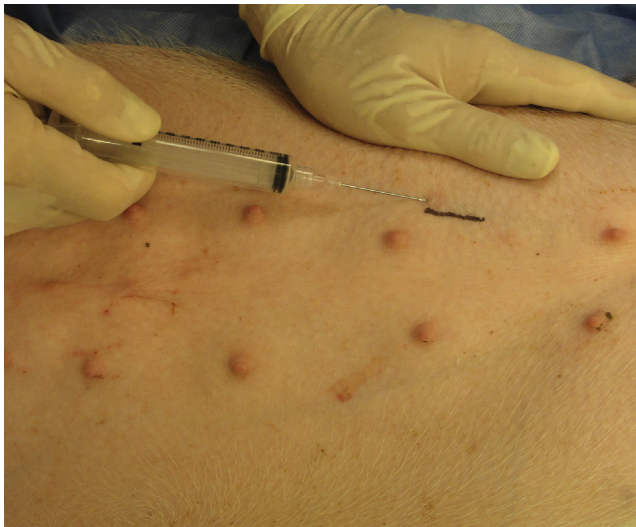

FIGURE 16.4 Venipuncture site of the mammary vein.

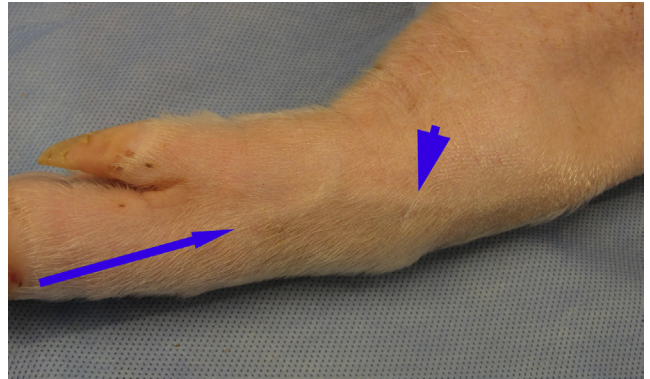


FIGURE 16.7 Venipuncture sites for accessory cephalic vein (arrowhead) and common dorsal digital vein (arrow).

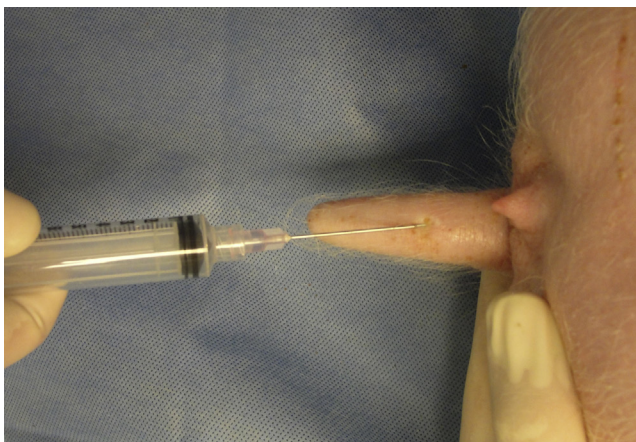


FIGURE 16.5 Venipuncture site of the tail vein.

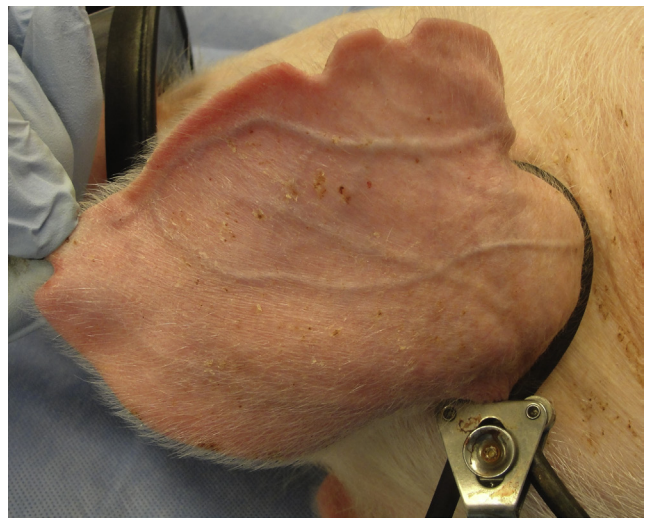

FIGURE 16.8 Dilatation of auricular veins using a tourniquet.

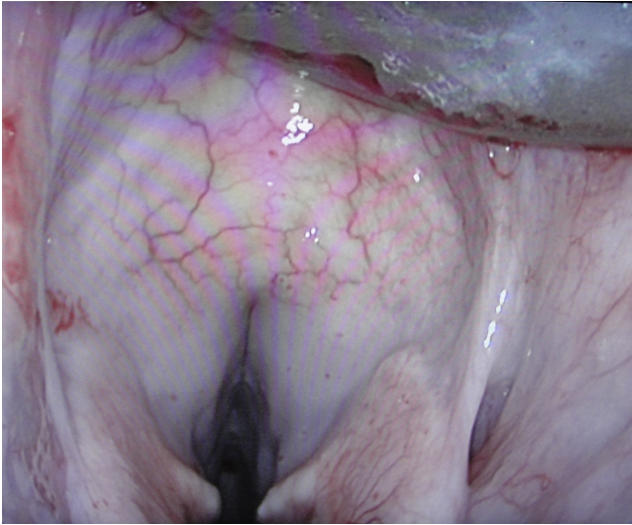

FIGURE 16.9 Visualization of vocal folds using a laryngoscope with animal in dorsal recumbency.

Most of the peripheral vessels are deep and not visible; consequently, knowledge of their anatomic location is essential. Most of the vessels can be accessed with standard-sized needles and a 20-gauge 1.5-inch needle is the largest size that will be required in swine up to 50 kg (Swindle, 1998; Bobbie and Swindle, 1986).

Surgical procedures, anesthesia, and anatomy, including surgical approaches for vascular access and fistulation procedures, are described in detail in other references (Swindle, 2007). A common problem is intubation of the pig. Intubation can easily be performed with the pig in dorsal recumbency using a laryngoscope to lift the tongue and mandible to visualize the vocal cords (Fig. 16.9).

D. Use in Research

Swine have been used mainly for research involving the cardiovascular system because of their unique anatomy and physiology, which makes them similar to humans (Swindle, 2007; Stanton and Mersmann, 1986). Cardiovascular diseases in which the pig is a useful model include atherosclerosis, coronary arterial stenosis and infarction, congenital heart disease, volume- and pressure-overload heart failure, electrophysiology, and testing of grafts, stents, and interventional devices. Swine are also susceptible to atherosclerosis. There are several models, the Rapacz familial hypercholesterolemia model, and induced models where feeding of high-cholesterol and fat-enhanced diets to standard breeds induces the disease (Bahls *et al.*, 2011, 2013). Some breeds are much more susceptible to diet-induced atherosclerosis than others. A more rapid form of atherosclerosis may be induced by damaging the endothelium with a balloon catheter (balloon endarterectomy). The induced

form has the advantage of producing a lesion in a specific anatomic area. Genetic models of high-membranous ventricular septal defect (VSD) and von Willebrand's disease are also available (Swindle *et al.*, 1990).

Nutritional and gastrointestinal models in swine are studied because of the physiology of their digestion, which is similar to that of humans, and their omnivorous diet. Areas of study include nutrient absorption and growth, gastrointestinal transport, hepatic metabolism, total parenteral nutrition, and necrotizing enterocolitis.

Renal diseases are another area of interest in research. Swine have been used in studies of renal hypertension, vesicoureteral reflux, intrarenal reflux, and urinary obstruction.

Swine have been increasingly used in research and teaching studies that involve surgery, both as a substitute for dogs and as a model based on physiologic characteristics (Swindle, 1986). Swine are the model of choice for most of the laparoscopic and endoscopic procedures because of their size and anatomy. Catheter delivery of interventional devices has also been studied extensively in swine. Transplantation research has been performed on the heart, lung, liver, kidney, and viscera. The size of the organs, the surgical anatomy, and the response to immunosuppressive therapy make them ideal for many of these studies. Swine are being developed as models and donors for xenotransplantation, which has included the development of transgenic strains (Swindle, 1998). The anatomic and physiologic characteristics of the skin have made swine a definitive plastic surgery model. Swine have also been developed as models in a wide variety of other surgical procedures, including fetal surgery and procedures in the musculoskeletal, central nervous, gastrointestinal, urogenital, and cardiopulmonary systems.

Many other biological models have been developed in swine, including the areas of systemic and dermal toxicology, septic and hemorrhagic shock, immunology, diabetes, malignant melanoma, malignant hyperthermia, and gastric ulceration. An exhaustive list of all the developed and potential models in swine is beyond the scope of this chapter. Extensive reviews of that information may be found in general reference and proceedings books.

II. BIOLOGY

A. Unique Physiologic Characteristics and Attributes

References with complete descriptions of swine anatomy and physiology are available (Swindle and Swindle, 2007). However, some of the unique characteristics of swine will be covered in this section.

The cardiovascular system is similar to that of humans, especially the coronary anatomy (Swindle and

Swindle, 2007). The blood supply from the coronary artery is right-side dominant and does not have pre-existing collateral circulation. This makes the coronary blood flow situation similar to 90% of that of the human population, unlike that in other species such as the dog. The electrophysiological system is more neurogenic than myogenic, and there are prominent Purkinje fibers. The left azygous (hemiazzygous) vein drains the intercostal vessels into the coronary sinus unlike in most other species. This vessel may be ligated or blocked with a balloon catheter to provide total coronary venous drainage into the coronary sinus. The aorta has a true vaso vasorum like that of humans. Normal values for hematology and serum chemistry and urine physiology for swine are listed in Table 16.1.

The gastrointestinal tract has unique anatomic characteristics (Swindle and Swindle, 2007). The stomach has a muscular outpouching, the torus pyloricus, near the pylorus. The bile duct and pancreatic duct enter the duodenum separately in the proximal portion. The anatomic divisions between the duodenum, ileum, and jejunum are indistinct. The mesentery is thin and friable. The mesenteric vessel branches form their vascular arcades in the sub-serosa of the intestine rather than in the mesentery as in other species. The majority of the large intestine is arranged in a spiral colon in the left upper quadrant of the abdomen. This series of centrifugal and centripetal coils includes the cecum and ascending, transverse, and majority of the descending colon. Tenia and haustra are present on the cecum and large intestine. In spite of the anatomic differences from humans, the physiology of digestion and intestinal transport are very similar.

Other unique anatomic features need to be considered (Swindle and Swindle, 2007). The lymph nodes are inverted with the germinal centers being located in the internal portion of the node. The thymus is located on the ventral midline of the trachea near the thoracic inlet rather than proximal to the larynx, and has fused lobes and appears as a single organ. A major portion of the thymus is located in the neck, and the single pair of parathyroid glands is located in the medial aspect of this gland near the larynx. The penis is fibromuscular with a corkscrew-shaped tip located in a preputial diverticulum near the umbilicus. The penis has a sigmoid flexure as it exits the pelvic canal. The male accessory glands include the prostate, vesicular gland, and bulbourethral glands. The female reproductive system is composed of a bicornuate uterus with lengthy tortuous fallopian tubes. The pancreas is bilobed and surrounds and encompasses the superior mesenteric vein. The liver is organized into lobules by microscopic fibrous septae. The cytochrome P450 system is similar to that in humans, but many subtle differences exist which may impact toxicity studies (Helke and Swindle, 2013).

B. Nutrition

A comprehensive text on swine nutrition has been published (Lewis and Southern, 2001). There is considerable variation of the genetic capacity for accretion of lean body mass among the various breeds of swine utilized in biomedical research. The 'farm swine' include breeds developed for meat production and at 6 months of age may have a lean body weight five- to sixfold greater than that of a micropig breed. The published research on swine nutrition is focused on farm swine and maximization of lean growth (Table 16.2). The majority of mini- and microswine nutritional research is proprietary and is reflected in the commercially available formulations offered by feed companies. In general, the nutrient requirements of these breeds are similar; however, the small breeds often require fixed-quantity feeding to control obesity, especially for long-term research studies. This in turn necessitates a higher margin of safety for many nutrient concentrations to prevent deficiencies, since most commercially available diets are designed for free-choice feeding. Diets formulated for the mini- and microbreeds generally have lower energy and higher fiber concentrations. The daily energy and quantity of feed required by farm pigs is quite different from that which is required by mini- and microbreeds.

Swine, unlike ruminants, do not require elemental sulfur in their diets when adequate sulfur-containing amino acids (methionine and cysteine) are available. Sulfur is essential for synthesis of various body compounds such as taurocholic acid, chondroitin sulfate, glutathione, and lipoic acid. Methionine alone can meet the total sulfur-containing amino acid requirement in swine because cysteine can be synthesized from methionine. The amino acid requirements (Table 16.2) refer to the L-isomer, which is the most biologically active form in swine and most common form found in plants and animals (National Research Council (U.S.), Committee on Nutrient Requirements of Swine, 2012).

C. Reproduction

1. Reproductive Physiology

Swine reach sexual maturity at 3–7 months of age, with most miniature breeds becoming sexually mature at 4–6 months of age. Litter size varies among breeds, with domestic swine usually having an average of eight to 12 pigs per litter and miniature breeds, four to six pigs. Litter size also varies with parity, being smallest at the first parity, increasing to a maximum between the third and seventh parities, and then remaining stable or decreasing (Kirkwood *et al.*, 2012).

The pig is polyestrous with an average estrous cycle of 21 days with a range of 17–25 days. Estrus typically lasts 48 h (range 1–3 days). Prior to the onset of estrus,

TABLE 16.1 Porcine Hematology and Clinical Chemistry Values

	Farm pigs ^{a,b,c}	Hanford ^a			Gottingen ^{d,e}	
		Male	Female	Yucatan ^{a,e} micropigs	Male	Female
RBC	5–8	6.6–9.3	6.4–8.3	5.6–8.8	7.1–8.5	7.2–8.4
Hemoglobin	10–16	11.4–12.8	11.4–13.5	13.1–17.0	11.2–12.8	10.9–12.9
Hematocrit	32–50	35–55	38–56	36.3–53.7	36.7–41.5	36.3–41.7
MCV	50–68	48.1–63.1	54.1–63.9	58.2–72.5	46.1–54.7	46.0–53.6
MCH	17–21	13.7–18.6	15.9–18.8	18.9–24.3	13.9–16.9	13.8–16.6
MCHC	30–34	30.8–33.7	31.7–33.1	31.1–34.5	29.8–31.2	29.6–31.4
Platelets	320–520	172–845	152–751	217–770	406.1–628.1	460.8–666.4
Reticulocytes	0–1	18.9–235.0	18.4–251.0		0.8–2.6	0.6–1.6
Plasma proteins	6–8					
Fibrinogen	100–500				5.6–8.2	4.2–5.4
WBC	11,000–22,000	21,300–32,400	16,800–26,700	6900–21,200	8800–13,600	9200–13,000
NEUTROPHILS						
Band	0–880	10,800–24,600	7600–19,500	0.0–200		
Segs	3080–10,450			1800–6400	2500–5600	1900–4900
Lymphocytes	4300–13,600	7190–17,980	5590–17,330	2100–7100	5100–8500	5600–8600
Monocytes	200–2200	240–1320	140–1470	200–1500	200–300	300–500
Basophils	0–440	50–210	50–500	0–500	0–100	0–100
Eosinophils	55–2400	10–1490	10–1190	0–1300	0–200	0–200
Glucose (mg/dl)	65–95	94–118	91–123	56–153	85.5–115.1	84.1–116.1
BUN (mg/dl)	8–24	12–17	10–16	10–29	7.4–11.2	5.7–9.9
Creatinine (mg/dl)	1.0–2.7	0.5–1.1	0.6–0.8	1.2–2.0	1.0–1.2	1.0–1.1
Phosphorus	4.0–11.0	5.6–7.3	7.7–10.7	5.0–8.3	7.9–9.9	7.2–10.0
Calcium (mg/dl)	11.0–11.3	10.4–11.4	10.0–11.4	9.3–11.6	10.9–11.9	10.9–11.7
Total protein	7.9–8.9	6.1–7	5.8–6.6	6.3–9.4	4.9–5.7	5.0–5.8
Albumin	1.8–3.3	3.3–4	3.1–4.3	4.1–5.6	2.9–3.5	2.9–3.5
Globulin	5.3–6.4	2.4–3.7	2.1–3.5	1.4–3.6	1.9–2.3	2.0–2.4
A/G		0.9–1.7	0.9–1.9	1.11–3.49		
Sodium (mEq/l)	139–152	140–146	139–144	142–153	142.7–149.3	139–147
Chloride (mEq/l)	100–105	99–102	98–102	95–114	102.1–106.3	99.6–105.4
Potassium (mEq/l)	4.9–7.1	4.7–6.8	4.6–6.3	3.9–5.2	6.3–7.7	5.9–7.3
CO ₂	18–26	24–28	20–29			
AGAP		12–17	14–20			
Total bilirubin	0.1–0.2	0.11–0.41	0.09–0.16		0.2–0.4	0.1–0.3
Indirect bilirubin	—	0.09–0.41	0.07–0.15			
Alkaline phosphatase	26–362	166–484	206–576		189.1–345.9	199.7–303.3
GGT(IU/l)	10–52	31–75	29–49	20.4–46.8	68.8–93.2	68.9–96.4
AST (U/l)	9–113	42–90	33–59	15–53	21.7–43.9	23.0–36.8
LDH (U/l)	380–630	510–758	490–593			
CK (U/l)	0–500	270–735	221–628		13.6–591.8	107.2–470.6
Na/K	—	21–30	23–31			

^aFrom Fox (2002).^bStuddert et al. (2012).^cJackson and Cockcroft (2007).^dMinipigs (2010).^eSwindle (2007).

TABLE 16.2 Daily Nutrient Requirements of Growing Swine^a

Parameters (body weight in kg)	10–20	20–50	50–80
Digestible energy of diet (kcal/kg)	3400	3400	3400
Estimated digestible energy intake (kcal/day)	3400	6305	8760
Metabolizable energy of diet (kcal/kg)	3265	3265	3265
Estimated metabolizable energy intake (kcal/day)	3265	6050	8410
Estimated feed intake (gm/day)	1000	1855	2575
Crude protein (%)	20.9	18.0	15.5
Water (l) (2.5l/kg feed consumed)	2.5	4.6	6.4
Fatty acid requirements – linoleic acid (g)	1.0	1.86	2.58
AMINO ACID REQUIREMENTS (G/DAY) (TOTAL BASIS)			
Arginine	4.6	6.8	7.1
Histidine	3.7	5.6	6.3
Isoleucine	6.3	9.5	10.7
Leucine	11.2	16.8	18.4
Lysine	11.5	17.5	19.7
Methionine	3.0	4.6	5.1
Methionine + cystine	6.5	9.9	11.3
Phenylalanine	6.8	10.2	11.3
Phenylalanine + tyrosine	10.6	16.1	18.0
Threonine	7.4	11.3	13.0
Tryptophan	2.1	3.2	3.6
Valine	7.9	11.9	13.3
MINERAL ELEMENTS			
Calcium (g)	7.0	11.13	12.88
Phosphorus, total (g)	6.0	9.28	11.59
Phosphorus, available (g)	3.2	4.27	4.89
Sodium (g)	1.5	1.86	2.58
Chlorine (g)	1.5	1.48	2.06
Magnesium (g)	0.4	0.74	1.03
Potassium (g)	2.6	4.27	4.89
Copper (mg)	5.0	7.42	9.01
Iodine (mg)	0.14	0.26	0.36
Iron (mg)	80.0	111.3	129.75
Manganese (mg)	3.0	3.71	5.15
Selenium (mg)	0.25	0.28	0.39
Zinc (mg)	80.0	111.3	129.75
Vitamins			
Vitamin A (IU)	1750	2412	3348
Vitamin D ₃ (IU)	200	278	386

(Continued)

TABLE 16.2 (Continued)

Vitamin E (IU)	11	20	28
Vitamin K (menadione) (mg)	0.5	0.93	1.29
Biotin (mg)	0.05	0.09	0.13
Choline (g)	0.4	0.56	0.77
Folacin (mg)	0.3	0.56	0.77
Niacin, available (mg)	12.50	18.55	18.03
Pantothenic acid (mg)	9.0	14.84	18.03
Riboflavin (mg)	3.0	4.64	5.15
Thiamin (mg)	1.0	1.86	2.58
Vitamin B ₆ (mg)	1.5	1.86	2.58
Vitamin B ₁₂ (ng)	15.00	18.55	12.88

^aFox (2002).

sows will exhibit signs of vulvar reddening and swelling, mucous discharge, nervousness, and increased activity. During estrus, sows will stand immobile when pressure is applied to the rump (Braun, 1993). Silent estrus is common in swine, but the presence of a boar can facilitate estrus detection (Kirkwood *et al.*, 2012).

Optimal fertilization rates occur when insemination takes place 12 h prior to ovulation. However, the variability in the interval between onset of estrus and ovulation makes it difficult to determine when females ovulate. As a result, commercial producers usually breed sows twice during estrus to maximize conception rates. Litter size also tends to increase with multiple matings per estrus. In pen mating, the sow and boar are left together during estrus. Hand mating involves placing the sow and boar in the same pen at 12- to 24-h intervals during estrus until the female is no longer receptive (Kirkwood *et al.*, 2012). Swine may also be bred by artificial insemination; however, conception rates are typically 10–15% lower compared to natural service. Satisfactory results are obtained if sows are inseminated 10–30 h after the beginning of estrus (Einarsson, 1980).

2. Pregnancy

Failure to return to estrus 18–24 days following mating is the first sign of pregnancy. Non-estrous sows are most easily detected by daily exposure to a boar during this time. In pregnant sows, rooting, walking, standing, and general activity decrease with increases in inactivity and time spent sleeping (Marchant-Forde and Marchant-Forde, 2004). These changes may be subtle and determination of pregnancy can also be based on whether or not the physical and behavioral changes of estrus are observed approximately 21 days post assumed mating date (Braun, 1993). Estrus detection has been reported to be 98% accurate and can be used to determine pregnancy status soon after failure of conception or death of a litter (Kirkwood *et al.*, 2012).

Other pregnancy detection procedures include the use of ultrasound and hormone assays. Ultrasound is <90% accurate and cannot be performed prior to the fourth week of gestation. Amplitude-depth ultrasound units can be used to detect pregnancy reliably between 30 and 90 days and as early as 18 days with some equipment. They are handheld devices that detect interfaces between fluid and tissues, which is the reason why they lose sensitivity at either early or late gestation. Doppler ultrasonography can be used from 4 weeks until farrowing and can also be used to determine litter size as well as fetal viability in late gestation (Kirkwood *et al.*, 2012; Braun, 1993).

Activity of the corpora lutea can be measured by progesterone assays. Progesterone concentrations of <1ng/ml on days 17–19 of the estrous cycle are typical of non-pregnant females. An elevated progesterone concentration on day 18 after breeding is indicative of pregnancy. Estrone sulfate assays are more accurate for determining pregnancy status than progesterone assays. Estrone sulfate, produced by the fetus, reaches peak blood levels at 23–30 days gestation (Braun, 1993).

3. Parturition and Neonatal Care

Swine have a diffuse epitheliochorial placenta necessitating colostrum for maternal antibody protection of the piglets from infectious agents. The gestation period of miniature pigs and commercial pigs is typically 114–115 days. Signs of impending parturition are usually evident during the last week of gestation. The vulva becomes swollen and more reddened during the last 3–4 days. Development and distension of individual mammary glands occur during the last 2–3 days of gestation, and drops of clear or straw-colored fluid can be expressed. This is followed by the initiation of milk secretion. Characteristically, abundant milk can be expressed at the onset of farrowing. The interval between the initiation of milk flow to parturition is typically 6–12h and provides a somewhat reliable sign of farrowing. Increased respiratory rate is most reliable. Behavioral changes occur during the 24h preceding farrowing and include restlessness and nesting. Frequent urination, defecation, and chewing or biting on surrounding objects may also be noted. However, just prior to birth, this activity diminishes and the sow becomes recumbent (Braun, 1993; Day, 1980).

Use of a farrowing crate is seldom necessary. The week prior to the anticipated farrowing date, sows should be placed in a quiet room in a stall with abundant bedding material for nest building. Wood chips are ideal for farrowing stalls since they allow the sow to engage in nesting behavior. They also help maintain the neonates' body temperature since newborn piglets lack the ability to effectively thermoregulate. Environmental temperature should be 85–95°F with a supplemental heat source

in the stall that results in a temperature of approximately 90°F at pig level (Fisher, 1993). Hanging heat lamps are commonly used and should be positioned to be effective without causing burns. The sow's comfort level is approximately 68–70°F, which is the reason for having a supplemental heat source just for the neonates. Newborns should not be exposed to drafts or moisture.

The duration of farrowing ranges from less than 1 h up to 8h, but typically lasts 3–4h; larger litters may have a longer farrowing duration. The sow displays little physical exertion during the birth process. Sows generally remain laterally recumbent while giving birth but will occasionally change to a standing or ventrally recumbent position. The interval between the birth of piglets is typically 15min. Assistance should be provided if more than 30–60min elapse between the delivery of piglets (Day, 1980; Braun, 1993).

The most important factors that contribute to neonatal survival are the ability of the piglets to receive colostrum within the first 12h of birth, adequate nutrition, and appropriate environmental conditions (Reeves, 1993). Competition is normal among littermates during nursing and can result in inadequate colostrum and milk intake in less dominant animals. Neonates must consume colostrum within the first 12–24h before their gut loses the ability to absorb immunoglobulins. Neonates will compete for, and establish, teat order on their day of birth. This hierarchy remains until weaning (Sawatsky, 1993). If necessary, the technique of split suckling can be used to ensure that all animals can nurse. This involves removing half of the litter comprising the largest piglets three to four times a day to allow the smaller animals to nurse adequately (Kirkwood *et al.*, 2012; Reeves, 1993). The sow's milk supply should be checked daily to prevent piglet deaths from dysgalactia. Commercial pig milk replacers are available and should be provided to piglets by bottle or pan feeding if the sow is unable to produce an adequate milk supply.

One nutrient requirement that is particularly important for newborn piglets is iron. Nursing piglets require 21 mg of iron for each kilogram of growth and sow's milk contains approximately 1 mg of iron per liter (National Research Council (U.S.), Committee on Nutrient Requirements of Swine, 2012; Brady *et al.*, 1978). Therefore, a microcytic, hypochromic anemia can develop. Nursing piglets can obtain some additional iron if allowed access to the feces of the sow; however, deficiency is still a common clinical problem. Consequently, it is routine practice in most swine herds to give 100–200mg of iron dextran IM within 48h of farrowing to prevent iron deficiency anemia.

Prewaning mortality is enzootic in most herds, but mortality varies depending on the prevalence of the various causes, which include poor viability at birth, chilling, starvation, trauma, diarrhea, and other diseases

(Kirkwood *et al.*, 2012). Trauma includes incidences of piglets that are stepped on, suffocated when lain on, and savaged by the female. Savaging is a behavior observed occasionally in individual animals, resulting in injury to and/or death of the piglets. The only recourse is to remove the piglets from the sow and to cull her from the breeding herd.

Day 1 care for piglets includes disinfection of the navel, clipping of the canine or 'needle' teeth, injection of an iron supplement, identification of individual animals, weighing, and clinical exam (Reeves, 1993; Fisher, 1993). The environmental temperature should remain at 85–90°F for animals up to 3–4 weeks of age. Animals 4–8 weeks old can be housed in rooms with temperatures at 75–80°F. Swine are generally weaned at 3–5 weeks by allowing them access to a solid ration.

D. Behavior

Swine are highly social and intelligent animals. They have a highly developed sense of smell, but poor eyesight. Group-housed swine are frequently observed vocalizing to each other. Pigs have an innate need to root, which can become destructive if they are not provided with an adequate outlet for expression. Housing strategies should accommodate swine behavioral needs as much as possible within the constraints of experimental design. Group housing or housing two animals per cage can be used to allow social interactions among animals. If individual housing is necessary, cages should be close together, and their design should include openings at the bottom to facilitate contact. Providing bedding material such as wood shavings is an excellent way to satisfy pigs' rooting behavior. Bedding material has the additional advantage of absorbing excreta but can be more labor-intensive for the husbandry staff than slatted or mesh flooring. Alternatively, a variety of toys, such as balls, chains, or hoses, can be supplied to help provide cage enrichment (Fisher, 1993; Sawatsky, 1993). Rotation of toys can keep the enrichment experience novel. Providing environmental enrichment that promotes species-specific behavior can enhance the well-being of swine and reduce fighting. Minipigs and farm pigs prefer toys that are chewable and can be easily misshapen. A recent environmental enrichment study indicated that minipigs prefer soft, pliable toys over hard, nonpliable toys (Smith *et al.*, 2009).

Swine are readily trained and respond well to positive reinforcement in contrast to conventional agricultural handling practices. This characteristic can be used to advantage in the research setting when animals must be handled or restrained for research manipulations. Acclimating and training swine to tolerate research equipment that will be used on them should be a standard procedure and can include the use of various types of food rewards given for reinforcing wanted behaviors. Gentle

handling and the use of a humane restraint sling are warranted whenever swine need to be transported from their home cages or when restraint is necessary during noninvasive procedures. Many pigs respond to gentle rubbing of the ventral abdomen by rolling over onto their sides, enabling caregivers to perform such minor procedures as wound cleansing or suture removal without restraining the animals. This type of handling is very effective for positively reinforcing contact between pigs and their caretakers and has a calming effect on most animals.

E. Immunology and Use of Swine in Xenotransplantation

1. Immunology

Normative data for the swine immune system, such as lymphoid tissue weights and percentages of cell subsets represented in different tissues, are influenced by the animal health status, as data derived from animals of conventional health status (i.e., farm environments) differ significantly from data derived from those housed under SPF, gnotobiotic, or axenic conditions.

The pig has a large population of what were initially considered 'null' cells, which lack expression of CD2, CD4, or CD8, but are known to express CD3, classifying them as T cells. The lymphoid population is largely comprised of $\gamma\delta$ T cells and is found in large numbers in various tissues, especially mucosal sites (such as the uterus). These are also highly prominent in the newborn. $\gamma\delta$ T cells from swine are similar to the ones described from ruminants (Davis *et al.*, 1998). Expression of CD4 (T-helper) and CD8 (T-cytotoxic) is mutually exclusive in most species, but swine (similar to human and monkey) have a unique lymphocyte subset that expresses both CD4 and CD8 (Thome *et al.*, 1994). The CD8 marker that is expressed is part of α (and not β) chain. CD4⁺ CD8⁺ ($\alpha\alpha$) upregulation is commonly present in activated T cells. This subset may represent a type of memory cell or a lineage that differentiates from CD4⁺ CD8⁻ to CD8⁺. In combination with CD45 and CD62L markers, central versus peripheral and naive versus activated T cells can now be identified in swine. There has been an increase in the identification of cluster of differentiation (CD) markers to phenotype lymphocyte subsets. Many homologous CD markers have now been identified, and a limited number are available commercially from the American Type Culture Collection (Manassas, Virginia) and Pharmingen, Inc. (San Diego, California).

Many hybridomas are available for the research community at the Massachusetts General Hospital Transplantation Biology Research Center. A monoclonal antiporcine CD3 antibody has been identified that is capable of activating or depleting T cells *in vitro* and inducing an immunosuppressive state *in vivo*, which will

greatly facilitate studies of the swine immune system, in particular, induction of tolerance in xenotransplantation research (Huang *et al.*, 1999). These have the CD3 antibody linked with diphtheria toxin. Other swine-specific T-cell-depleting antibodies such as CD4 and CD8 have also been used (Pennington *et al.*, 1988). Bone marrow (BM) of swine is more similar to that of humans than of rodents, especially when dealing with toxicity in response to lethal irradiation. This has allowed studies that have demonstrated the benefit of T-cell depletion of donor tissues in preventing graft-versus-host disease (Sakamoto *et al.*, 1987). Immunological rejection is the major barrier to advancement in several areas of swine research. Therefore, thorough understanding of the complex intricacies of the swine immunological system is paramount to facilitating research in disciplines such as cancer, allotransplantation, and xenotransplantation research. A greater understanding of the swine immune system will help researchers develop translational models.

Immunoglobulins (Igs) of the pig are the most studied of those in farm species (Ober *et al.*, 1998). Neonates are colostrum dependent because maternal immunity is not conferred through the placenta. Access to IgG-rich colostrum within the first 6 h postpartum is most critical for 3-week survival rate and weight gain. Colostral leukocytes, largely neutrophils and T cells, are also absorbed by intercellular migration. Intestinal closure for absorption of colostrum is complete by 24–48 h of age. In contrast to most other species, the pig lacks the gene for IgD, which is a precursor immunoglobulin in the differentiation pathway to IgM. The pig does have a large number of IgG subclasses: IgG₁, IgG_{2a}, IgG_{2b}, IgG₃, and IgG₄. IgA circulates as a dimer in blood and tissues and as a monomer in mucosal secretions; IgE is found in serum and mucosal tissues. High endothelial venules of transplanted swine tissues express adhesion molecules, but information on the relative homology of these ‘addressins’ is limited in scope due to lack of reagents.

Cytokines and lymphokines in the pig have been studied in models associated with inflammation, such as sepsis, atrophic rhinitis, erysipelas, arthritis, and viral infections (Murtaugh, 1994; Ober *et al.*, 1998). Reports on swine cytokine regulation and function suggest that the biology is similar to that of humans and mice and that there is some limited homology; swine lymphocytes will respond to recombinant human interleukin (IL)-2 *in vitro* and also *in vivo* (Whary *et al.*, 1995). When injected into pigs, upregulation of regulatory T cells for the induction of tolerance has been attempted as a bridge to preclinical human transplantation. Rejection is observed when injected at high concentration. For cancer studies, the use of IL-2 has been controversial as depending on the dose, it may enhance antitumor responses, or if T regulatory

cells are unevenly upregulated, then relapse may occur. The swine leukocyte antigens (SLAs), the equivalent of the human major histocompatibility complex (MHC), have been cloned and sequenced and are located in chromosome 7 in swine. Like all other MHC-I molecules, the SLAs are expressed by all nucleated cells and function to restrict CD8+ T-cell activation, particularly antiviral immune responses. The SLA class II (MHC-II) genes have been cloned and are restricted to professional antigen presenting cells such as B cells, macrophages, and dendritic cells. Contrary to mice and similar to humans, SLA class II genes are also expressed in lymphocytes and vascular endothelium. Upregulation of MHC-II does occur during inflammatory processes. The number of SLA class III genes that have been cloned is lower than that found in other species. Member genes of the SLA class III complex function in the complement system, which in the pig is closely aligned with the human systems of classical and alternate pathways of complement activation. One difference between swine and humans is that elimination of antigen–antibody immune complexes occurs through the lung in the pig, in contrast to the target organs of the liver and spleen in humans (Davies *et al.*, 1995).

Red blood cell (RBC) antigen classification is very complex in the pig, with 16 genetic systems having been developed that consist of 78 blood factors, which are either antigens of the RBC itself or become cell-associated from other tissues when serum concentrations are high (Pescovitz, 1998). Knowledge of red cell surface expression is important during transplantation as disparities between donor and recipient can induce antibody-mediated hyperacute rejection, and thus, it is important to match blood types when working with MHC-characterized miniature swine.

Swine have been used as a model of allotransplantation including pancreatic islet, kidney, intestine, liver, composite tissue antigen, lung, heart, and bone marrow (Huang *et al.*, 2001). Currently, a new method has demonstrated that combining donor bone marrow with skin or solid organ transplant may contribute to tolerance induction (Horner *et al.*, 2008).

Immunodeficient swine are available in which human xenografts are not rejected. Acquired immunodeficient states can also be surgically induced by thymectomy, splenectomy and use of strong pan-immunosuppressants. Management-related or spontaneous cases of immunodeficiency have been attributed to inadequate colostrum, stress, or poor nutrition (Pescovitz, 1998). Autoimmune disease in swine is largely undocumented except for hemolytic disease in neonates related to postnatal absorption of maternal Igs (erythroblastosis fetalis) and two forms of glomerulonephritis. One form appears to be inherited in Norwegian Yorkshire swine, and a second involves spontaneous IgA nephropathy reported in Japanese slaughter pigs (Ober *et al.*, 1998).

2. Use of Swine in Xenotransplantation

About 120,000 people are currently waiting on the organ transplant list in the US. In 2012 a total of 6115 patients died while waiting for a compatible transplant (Sharing, 2013). There are several major concerns regarding the use of swine for xenotransplantation particularly zoonotic risks and ethical issues. First is the risk for acquired zoonoses, particularly in recipients already immunosuppressed by illness and chemotherapy. Second are the anticipated risks associated with normal flora, environmental contaminants, and true pathogens. And third is the concern regarding the unknown risks of viral latency, viral recombination, and endogenous retroviruses (Levy *et al.*, 2000). Risks can be minimized by ensuring that donor animals must be free of potential zoonoses and other complicating diseases (Ye *et al.*, 1994). The term 'xenograft-defined flora' rather than SPF should be used to designate the appropriate health status of donor animals in order to avoid confusion with existing standards (Swindle, 1998).

Although swine have fewer endogenous retroviruses than other vertebrates, and porcine endogenous retrovirus (PERVs) infections have not been documented, vigilant screening is paramount to minimize the risk of zoonotic infection. Despite these concerns, the transplantation community continues to grow, driven by the increasing demand for donor cells, tissues, and organs. There are ethical concerns, however, including public acceptance of these alternatives and regulatory issues. A plethora of organizations throughout the world have been established to address these issues. The World Health Organization has stressed the importance of developing checks and balances for future clinical trials. The Ethics Committee of the International Xenotransplantation Association was founded to promote xenotransplantation as a safe, ethical, and effective therapeutic modality (Anderson, 2006; Yang and Sykes, 2007; Schuurman *et al.*, 2012). As this field develops, guidelines and regulations expand; the European Parliament and Council, the Food and Drug Administration, and the Public Health Service have all published guidelines. Significant steps forward in the process have been accomplished with the completion of swine genome mapping and the creation of transgenic pigs. Further research to understand the intricacies of swine immunology are instrumental in developing tools for xenotransplantation research. The comparable anatomy and physiology of the pig and human, defined herd health status, and the recent finding that over 100 porcine protein sequences share the same amino acids as their human orthologs, have indicated that with targeted genetic modification, the pig may be an ideal model for xenotransplantation. The experimental use of swine organs or tissues for humans faces significant scientific challenges however. These include, but are not restricted to, overcoming hyperacute, acute

and chronic rejection by the host. Nonetheless, despite all of these factors the pig, specifically the miniature pig, continues to be considered the prime candidate for xenotransplantation.

Optimization of miniature swine has been attempted in the last several decades. Development of disease-resistant swine organs has been promoted as a strategy to circumvent failure of transplanted organs resulting from human centric infectious agents such as hepatitis B virus (Mueller *et al.*, 1999).

One important resource has been the cross-breeding of outbred miniature swine from the Andes and the Rockies to develop three lines of miniature swine which are homozygous for different SLA alleles. Once the alleles were identified, the swine were designated as SLA^{aa}, SLA^{cc}, and SLA^{dd}. The 'B' allele was either lost through the breeding process or was never present in the founder animals. These three lines are fixed at the SLA loci and are heterozygous at minor histocompatibility loci. Thus, MHCs matched with minor mismatches or full mismatch transplants are now possible which can reliably emulate clinical paradigms. Pairing donor and recipient within a line is used to model for transplants between MHC identical human siblings, between swine lines as a model for MHC full mismatches, and between F₁ hybrids for haplo-identical transplants, also known as parent-to-offspring transplants. Several recombinant strains have been bred where different SLA MHC-I or MHC-II recombinants exist. These intra-SLA recombinant strains have permitted the study of SLA class I and II differences and demonstrated the relevance of different SLA specific mismatches on graft survival of various tissues. As an example, it is easier to develop tolerance to a full MHC-I mismatched kidney than a full MHC-II. MHC-II is thought to permit optimal function of regulatory T cells, which are dependent on MHC-II matching (Griesemer *et al.*, 2008). Matching of SLA skin grafts without immunosuppression typically has a survival of 7–12 days. The SLA^{dd} line was further inbred (brother sister matings) and currently has >95% consanguinity (Mezrich *et al.*, 2003). Skin grafts between these swine survived more than 340 days before rejection occurred. These animals are several generations away from being fully inbred and the presence of developmental abnormalities has slowed the development of the line.

Pig studies have also been pivotal in the identification of the tolerogenic (or resistance to rejection) properties different organs may have. Some can now be ranked for their 'tolerogenicity'. Though the specifics are beyond the scope of this review, the transplant hierarchy of tolerance (from greater to lesser) is as follows: liver > kidney > heart > lung > skin.

The swine-to-baboon xenotransplantation model holds the promise of future technology transfer to enable

swine-to-human solid organ and tissue/cell transplantation. Lack of long-term graft acceptance due to the potent immunological barriers encountered between disparate species has forced the field to generate multiple strategies to minimize rejection. Understanding of the different rejection processes of xenotransplantation is needed. The most immediate and serious causes of graft loss are now better understood and some can be prevented. The mechanisms responsible for hyperacute rejection (seconds to minutes) are no longer a problem. Thus, in some instances the swine grafts have lived in nonhuman primates (NHPs) for several months before being rejected (Yamada *et al.*, 2005), and in some cases, even without evidence of rejection at the time of death (by other causes). When discussing xenogeneic rejection, one must differentiate between humoral and cellular driven processes. Of the two, humoral rejection has been the cause of immediate graft loss known as hyperacute rejection (HAR). HAR is driven by natural antibodies that recognize the sugar moiety Gal α 1-3Gal β 1-4GlcNAc (α 1,3Gal) which is present in porcine endothelium. This sugar is produced by the enzyme α -1,3-galactosyltransferase which is present in most mammals but not in humans and old world monkeys. The enzyme was lost through evolution, possibly through the selective advantage of preventing infections by many bacterial pathogens that express α -1,3-Gal. Antibody-mediated recognition of this epitope on the swine vascular epithelium after transplantation triggers the complement cascade (Saadi and Platt, 1999). If HAR is avoided by either absorbing natural anti-Gal antibodies or using grafts deficient of the Gal antigen, a second potent antibody mediated response, inducing acute humoral xenograft rejection (AHXR) is observed. This is generally caused by non-Gal xenoreactive antibodies. The graft is eventually lost over several days/weeks by complement activation. However, other non-complement-mediated mechanisms are also capable of inducing graft loss. This was demonstrated by transplantation of decay accelerating factor DAF $-/-$ (CD55 $-/-$) donor mice into Gal-T KO mice (Shimizu *et al.*, 2006).

Resolution of humoral responses hindering induction of immunological tolerance is paramount; however, other factors of the innate and adaptive immune system elicit slower rejection of xenografts such as T-cell-mediated rejection and rejection caused by natural killer (NK) cells, macrophages, and neutrophils. Delayed rejection of xenografts through cell-mediated responses develops over 3–4 days, involving activation of endothelial cells of the graft as in the acute rejection response (Brouard *et al.*, 1999). Activation leads to loss of thrombomodulin and adenosine triphosphate diphosphohydrolase, which leads to prothrombosis, proinflammatory gene activation increasing the expression of adhesion molecules, prothrombotic factors, and

cytokines. Adoptive cell transfer experiments in immunodeficient rodents have demonstrated that engrafted human CD4+ T cells mediate rejection of porcine xenografts as do NK cells and monocytes (Friedman *et al.*, 1999). T-cell-mediated rejection has not been as well characterized as humoral responses because of the difficulty avoiding HAR and AHXR. However, the development of Gal-knockout (KO) pigs has permitted the study in large animals of other non-humoral xenograft rejection mechanisms. Control of CD4+ T-helper cells is not only an important part of a T-cell-mediated response, but will provide control of AHXR (Sachs, 2005). CD8+ T-cell-mediated cytotoxicity continues to be a potent method of xenograft rejection. Pharmacological and nonpharmacological approaches to minimize their lytic function are crucial.

Activation of cells of the innate immune system via pathogen-associated molecular patterns potentiates NK cell and macrophage xenograft rejection. NK cells function by sensing inhibitory signals through MHC ligation. Because xenogeneic MHC cannot provide the necessary 'inhibitory' signals to the NK cells (when compared to allogeneic responses) NK-cell-mediated xenograft rejection is more potent in this context. (Sachs, 2005). Addition of human MHC expression on Gal-KO pigs will be able to better avoid NK-cell-mediated rejection. Another common NK-cell-mediated kill mechanism is via antibody-dependent cell cytotoxicity (ADCC). Both natural and IgG-specific antibody responses can induce ADCC-mediated xenogeneic rejection (Gourlay *et al.*, 1998). Macrophages are also involved in xenograft rejection, and they phagocytose the target tissues if they do not receive a negative signal through the interaction of CD172 (SIRP α) on the macrophage and CD47 on the cell surface molecule. This provides a common 'do not eat me' signal. Interspecies incompatibilities induce macrophage-mediated xenograft rejection (Wang *et al.*, 2007).

a. Methods to Prevent Rejection of a Xenograft

Removal of natural anti-Gal xenoantibodies can be performed by immunoabsorption. This method is efficient, but incomplete, and often xenoreactive natural antibodies rebound relatively quickly (Kozlowski *et al.*, 1998). There are two approaches for the elimination of natural antibodies: *in vitro*, using α -Gal immunoaffinity columns, or *in vivo*, by extracorporeal perfusion of a donor organ (often the liver is chosen based on its size and vascularity). There is no swine breed available with inherently low α -Gal or animals which have spontaneously lost the α -Gal gene (Chae *et al.*, 1999). Identification of such animals would have been crucial to starting a low α -Gal or α -Gal-deficient herd. In another approach, Brenner *et al.* reported that nonspecific depletion of the majority of recipient immunoglobulins of all isotypes

by column immunoadsorption significantly improved graft survival of pig hearts in baboons (Brenner *et al.*, 2000). This strategy is clearly not clinically applicable as patients would not be able to survive long term without antibody-mediated protection.

Based on these facts, Sachs and colleagues knocked out the gene in the most inbred of the MGH miniature swine (the 'D' haplotype) (Kolber-Simonds *et al.*, 2004). These pigs were devoid of α -Gal from the SLA^{dd} pigs. Thus, these KOs have become the most likely donors to be used in clinical xenotransplantation.

Though beyond the scope of this chapter, there are currently several additional approaches to eliminating xenoantibodies. Anti-CD20 monoclonal antibodies which kill B cells have been used (McGregor *et al.*, 2005), but there are B cells that do not express CD20, and thus are not eliminated. The use of cobra venom factor has been a common (yet toxic) method for preventing activation of complement (Dwyer *et al.*, 2002). The use of pigs expressing human complement inhibitory molecules such as CD46, CD55, and CD59 has also been tried (Dwyer *et al.*, 2002). Transgenic expression of CD59, a human complement regulatory protein, has promoted survival of swine lungs in a pig-to-primate model (Kulick *et al.*, 2000; Yeatman *et al.*, 1999).

The development of immunological tolerance is theorized to be the most effective method to circumvent xenograft rejection (Li and Sykes, 2012). This approach addresses humoral and T-cell-mediated responses and has shown promise in the induction of donor-specific tolerance using bone marrow transplantation to create hematological chimeras. Tolerance to fully MHC-mismatched allografts has been demonstrated in mice and primates after first creating a mixed allogeneic hematopoietic chimerism by engrafting donor bone marrow cells into the recipient. However, this hematopoietic chimerism has been difficult to achieve in the discordant pig-to-primate xenogeneic model, most likely due to species-specific differences in regulatory cytokines and elements of the stromal microenvironment (Sablinski *et al.*, 1999; Emery *et al.*, 1999).

Representative of a typical experimental protocol and illustrative of the complexities involved, recipient primates undergo whole-body irradiation prior to infusion of pig bone marrow. This method was modified to minimize irradiation-induced inflammatory responses. Primate anti-pig xenoantibodies were immuno-adsorbed by extracorporeal perfusion of recipient blood through a pig liver immediately before the intravenous infusion of porcine marrow. In addition to cyclosporine and 15-deoxyspergualin, recombinant pig stem-cell factor and IL-3 were given. Other calcineurin inhibitors such as FK506 (Tacrolimus) are now being used instead. Anti-thymocyte globulin and/or anti-CD2 monoclonal antibodies to target T cells have also been

used. This permits, in part, the decrease of irradiation dosage. Thymic specific irradiation to prevent host resident thymic T cells from rejecting new bone marrow donor-derived thymic emigrants has been performed. Recipient primates required 4 weeks to recover from pancytopenia from whole body irradiation, and anti-pig IgM and IgG antibodies were temporarily depleted by the liver perfusion for 12–14 days. About 2% of the myeloid progenitors in the bone marrow of the recipient were of pig origin, and chimeras were unresponsive (or hyporesponsive) by mixed lymphocyte reaction when challenged with pig-specific stimulators. The first report of long-term survival of discordant xenogeneic bone marrow is in a primate recipient (Sablinski *et al.*, 1999). Others have reported on the poor function of porcine hematopoietic cells in primate marrow microenvironments. Warrens *et al.* found differences between swine and human bone marrow cultures in function of two well-characterized ligands known to be important in hematopoiesis, CD44 and very late antigen-4 (VLA-4), but they concluded that the differences were not significant enough to explain lack of effective porcine hematopoiesis in the primate marrow, suggesting that other unknown interactions may be important (Warrens *et al.*, 1998).

Gene therapy to express swine SLA class II antigens on baboon autologous bone marrow cells has had limited success (Ierino *et al.*, 1999). Transcription of the transgene was transient, and xenografts were rejected after 8–22 days. This experiment was important because it demonstrated that transfer and expression of xenogeneic class II transgenes can be achieved in baboons, and this therapy may prevent late T-cell-dependent responses to porcine xenografts, which include induced non- α -Gal IgG antibody responses. The use of porcine thymic grafts in immunodeficient mice has been found to support normal development of polyclonal, functional human T cells, and these T cells were specifically tolerant to SLA antigens of the porcine thymus donor, suggesting thymic transplantation may be an approach to achieve tolerance in pig-to-human xenotransplantation (Nikolic *et al.*, 1999). Indeed, this approach, by providing a thymokidney graft by Yamada *et al.*, demonstrated that baboon thymic precursors were developing in the pig thymus posttransplant (Yamada *et al.*, 2005).

The bone marrow chimerism tolerance approach is the one which has provided the longest survival and donor-specific tolerance. Refinement of this protocol will likely be the pathway that will lead swine xenotransplantation to the hospital floors. Before swine organs can be utilized as a successful alternative to human organ transplant, further research will be required to determine mechanisms to facilitate xenograft compatibility.

III. DISEASES

A. Infectious Diseases

Incidence of infectious disease in the research laboratory is greatly reduced when pigs are purchased from herds with defined health status, newly introduced animals are adequately quarantined and conditioned, and husbandry conditions are optimum. Veterinarians responsible for swine herd health should be familiar with both classical swine diseases and, more importantly, health problems that can emerge from opportunistic agents in animals stressed by experimental manipulation. Many of the diseases discussed below are in fact rare in the majority of modern, commercially reared pigs and will not be found in the commercially supplied miniature swine herds of high health status. However, new diseases continue to emerge and diseases that were once thought to be geographically isolated can spread.

Implementing treatment of infectious problems should be considered cautiously and is best reserved for those problems with minimal impact on the research use or health status of the research herd as a whole. In the following discussion of infectious diseases, classes of drugs are listed and culture and sensitivity is recommended before selecting and starting treatment. Likewise, the reader is referred to veterinary formularies (Plumb, 2011) for specific doses. Many of the drugs listed are extra-label use in swine; hence, veterinarians must determine a dose from experience with other species.

1. Polysystemic Diseases

a. Porcine Circovirus-2

A relatively new agent has emerged within recent years to cause a multitude of disease manifestations within the porcine world. The virus is often associated with other infectious agents. The disease syndromes are widely varied and affect all organ systems.

In 1998 the first report described porcine circovirus-2 (PCV2) as a causative (or cofactor) agent in porcine multisystemic wasting disease (PMWS) (Ellis *et al.*, 1998; Allan *et al.*, 1999). Many poly-systemic diseases have since been described which were determined to be multifactorial, the common denominator being that animals were nearly always co-infected with PCV2. Since then, PCV2 has been identified as causing or being associated with disease pathogenesis of many porcine syndromes including PMWS, porcine dermatitis and nephropathy syndrome (PDNS), PCV-associated disease (PCVAD), porcine respiratory disease complex (PRDC), acute pulmonary edema (APE), PCV2-associated neuropathy (PAN), reproductive failure, granulomatous enteritis, necrotizing lymphadenitis, and exudative epidermitis.

Etiology Porcine circovirus (family Circoviridae, genus *Circovirus*) is a nonenveloped RNA virus, the

smallest virus to infect mammals. Since its initial discovery in cell culture in 1974, another serotype has been discovered (PCV2) which causes disease *in vivo*, and has been further divided into PCV2a and 2b (Tischer *et al.*, 1986). PCV2a and 2b often result in coinfection (Opriessnig and Langohr, 2013). PCV2c, 2d, and 2e have also been identified in various countries and further studies are ongoing on these subtypes (Wang *et al.*, 2009; Opriessnig and Langohr, 2013).

The differences between PCV2a and 2b are only two nucleotides, which have been proposed to lead to differences in pathogenesis. Disease severity has been shown to differ between PCV2a and 2b with 2b infection being associated with pulmonary edema, granulomatous enteritis, as well as lymphoid necrosis and depletion yet it remains unknown whether these differences are due to viral or host factors (Gillespie *et al.*, 2009). However, some studies have found no difference in pathogenicity (Trible and Rowland, 2012).

Epizootiology and Transmission PCV is highly prevalent in the worldwide pig population, and greater than 50% of feral swine are positive for PCV2 antibodies (Rose *et al.*, 2012; Sandfoss *et al.*, 2012). PCV has prolonged shedding in respiratory and oral secretions and is highly resistant within the environment. Complete inactivation is difficult and extended exposure times to disinfectant agents are required (Kim *et al.*, 2009b; Rose *et al.*, 2012). PCV is transmitted via feces, urine, and direct transmission as well as transplacentally, through the colostrum, and via seminal fluid (Gillespie *et al.*, 2009; Rose *et al.*, 2012). After the virus gains access, tonsils and lymph nodes of the head are infected. Initially, type B lymphocytes are infected followed by T cells and peripheral blood mononuclear cells (Gillespie *et al.*, 2009). Animals are typically 4 weeks old before clinical signs appear, suggesting that maternal antibodies are protective (Gillespie *et al.*, 2009). There is evidence of a global shift from PCV2a to PCV2b, which is reported to be associated with more severe disease, and for which the current vaccines are not protective (Rose *et al.*, 2012).

Pathogenesis The pathogenesis of PCV2-associated syndromes remains unclear and has not been fully elucidated (Darwich and Mateu, 2012; Gillespie *et al.*, 2009). Many factors are involved, most of which have been investigated, yet no clear unifying mechanism has yet been discovered (Darwich and Mateu, 2012). Many multisystemic diseases have been attributed to PCV2. Lesions are often only seen when animals are coinfecting with other agents such as porcine parvovirus (PPV), porcine reproductive and respiratory syndrome virus (PRRSV), or *Mycoplasma hyopneumoniae*, which prime or activate the immune system. Studies in caesarian-derived, colostrum-deficient pigs inoculated with PCV2 alone can cause lesions, albeit only with immunostimulation via adjuvants.

Current thought is that PCV2 infects macrophages, or endothelial cells directly. PCV2 has been shown to infect endothelial cells resulting in activated phenotype, degeneration of endothelial cells, perivascular and intramural edema, fibrinoid necrosis, and vascular thrombi (Opriessnig and Langohr, 2013). In conventional pigs infected with PCV2a or 2b alone, clinical disease is not observed, nor is there any difference between animals infected with a single serovar. When archival tissue collected from pigs before the advent of PMWS was examined and tested, PCV2 was present, albeit avirulent (Krakowka *et al.*, 2012). Mutational events within a specific epitope led to the increased virulence of PCV2 (Krakowka *et al.*, 2012).

Macrophages in bone marrow, thymus, and thymic lymphocytes label positive for PCV2 in infected animals (Hansen *et al.*, 2013; Nauwynck *et al.*, 2012). Viral replication is present in both thymus and bone marrow (Hansen *et al.*, 2013). Lymphoblasts support active viral replication and while PCV2 is found within macrophages, this is suspected to be due to phagocytosis and not active infection of the cell (Nauwynck *et al.*, 2012). Heparin sulfate and chondroitin sulfate B are PCV2 attachment receptors (Misinzo *et al.*, 2006). The molecule or pathway triggered has not yet been identified (Mankertz, 2012). However, cytoskeleton maintenance, intracellular signaling, and RNA processing have all been implicated in pathogenesis (Mankertz, 2012). PCV2 targets fetal myocytes and hepatocytes (Nauwynck *et al.*, 2012). The virus requires cells in S-phase for DNA replication as the virus replicates faster in active cells (Gillespie *et al.*, 2009). Lymphocytes are most active postvaccination and when infected with another pathogen, thus leading to increased pathology (Gillespie *et al.*, 2009; Nauwynck *et al.*, 2012).

Genetic (Breed Factors) All breeds are susceptible, yet differences exist in degree of susceptibility. Landrace are more susceptible to lesions and disease compared to Durocs and Large Whites (Meerts *et al.*, 2005; Opriessnig *et al.*, 2006).

Other Infections/Immunomodulation Most (98%) pigs with PCVAD have coinfections (Pallares *et al.*, 2002). The most common agents in coinfections are PRRSV, *M. hyopneumoniae*, PPV, and septicemia (Pallares *et al.*, 2002). Other coinfective agents which have been shown to lead to PCVAD are Torque teno virus (TTV), porcine epidemic diarrhea virus (PEDV), SIV, porcine endogenous retrovirus, PCV1, pseudorabies virus (PRV), *Lawsonia intracellularis*, *Salmonella*, and bovine viral diarrhea virus (BVDV) (Opriessnig and Halbur, 2012; Langohr *et al.*, 2012).

PRRSV has been shown to be present in cells containing PCV2 kidney, lymph node, and tonsil using double labeling techniques (Choi and Chae, 2001).

Clinical Signs and Necropsy Findings differ with each syndrome and will be discussed in sections below.

Diagnosis To diagnose PCV2-related diseases or syndromes, a complete tissue set needs to be examined. This includes lymphoid organs, lung, digestive system, kidney, reproductive system, skin, cardiovascular and central nervous systems. Viral detection is typically via immunohistochemistry, *in situ* hybridization, or polymerase chain reaction (PCR) (Opriessnig and Langohr, 2013). Diagnosis is not as straightforward as with other agents, not only because PCV2 is associated with so many syndromes, but also since animals may be infected without showing clinical signs. Diagnosis of a PCV-related syndrome requires presence of three criteria: (1) compatible clinical signs, (2) characteristic microscopic lesions, and (3) PCV2 within lesions (Chae, 2004; Rosell *et al.*, 2000).

Differential Diagnosis Differentials for vasculitis in pigs include PRV, African swine fever (ASFV), classic swine fever (CSF), ovine herpes virus, PRRSV, *Actinobacillus pleuropneumoniae* (APP), *Actinobacillus suis*, *E. coli*, *Pasteurella multocida*, *Salmonella*, and *Streptococcus* spp. (Szeredi *et al.*, 2012).

Prevention/Control Several inactivated subunit vaccines based on PCV2a are commercially available and are effective in controlling and preventing disease, but continued evolution of the virus may evade current vaccines (Opriessnig and Langohr, 2013; Beach and Meng, 2012). Vaccine failure has been reported recently, which prompted examination of the cause which was found to be the presence of PCV2b (Xiao *et al.*, 2012). Since PCV2b has been growing in prevalence over the past few years, vaccines for this serovar are under development (Beach and Meng, 2012). Also, since most cases of clinical PCV2 have coinfections, the vaccine mitigates only the contribution of PCV2, not the coinfection agent.

Research Complications PCV2 also manifests as subclinical disease which results in decreased average weight gain without overt clinical signs (Segales, 2012). More importantly, since overt disease is often seen only with immunomodulation in conjunction with PCV2, research manipulations may result in immunomodulation, thus precipitating overt disease. Many organ systems are potentially susceptible and studies may be compromised due to the presence of PCV2.

Syndromes Postweaning Multisystemic Wasting Syndrome (PMWS).

Pathogenesis An increased number of actively replicating cells within the lymph node correlates with upregulation of virus production (Krakowka *et al.*, 2001). Severe alterations of hematological parameters are seen with PMWS such as anemia, lymphopenia with decrease of CD8+ and IgM-producing cells, monocytosis, and neutrophilia (Darwich *et al.*, 2003). There is cytokine dysregulation with overexpression of IL-10 in the thymus, which is associated with thymic depletion and atrophy, and overexpression of interferon (IFN)- γ in

the tonsils (Darwich *et al.*, 2003). The following cytokines are decreased: IL-2 and IL-12p40 in the spleen, IL-4 in tonsils, and IFN- γ , IL10, IL-12p40, and IL-4 in peripheral lymph nodes (Darwich *et al.*, 2003).

These cytokine changes are indicative of T-cell immunosuppression (Darwich *et al.*, 2003).

Clinical Signs/Diagnosis Age at onset of disease differs between the US (7–16 weeks) and EU (5–12 weeks), which is hypothesized to be due to differences in vaccination regimens (Gillespie *et al.*, 2009). First described in 1991, clinical disease includes progressive weight loss, lethargy, jaundice, respiratory disease, diarrhea, lymphadenitis, and anemia (Segales, 2012; Gillespie *et al.*, 2009; Krakowka *et al.*, 2001).

In gnotobiotic piglets, PCV2 alone causes asymptomatic infection without overt evidence of PMWS; however, after activation of the immune system using incomplete Freund's and an immunogen, piglets develop moderate to severe PMWS (Krakowka *et al.*, 2001). PMWS is an acquired immunodeficiency (Darwich and Mateu, 2012).

Necropsy Macroscopic lesions consist of generalized lymphadenopathy, hepatitis with icterus, edema, nephritis, and pneumonia (Krakowka *et al.*, 2001). Lungs fail to collapse and are mottled white to tan (Gillespie *et al.*, 2009). Enlarged lymph nodes have lymphoid depletion with histiocytic replacement (Gillespie *et al.*, 2009; Rosell *et al.*, 2000). Other common lesions include interstitial pneumonia (Figs 16.10, 16.11) and interstitial nephritis, granulomatous inflammation in the liver, spleen, tonsil, thymus, and Peyer's patches (Chae, 2004). Intracytoplasmic botryoid inclusion bodies (Fig. 16.12) are common in epithelial cells of the bronchi, renal tubules, and bronchial glands as well as within macrophages (Huang *et al.*, 2008).

Lesions are typically angiocentric with lymphoplasmacytic and histiocytic to granulomatous inflammation, and multinucleate giant cells (Chae, 2004; Krakowka *et al.*, 2001). In the liver, PCV2 antigen is found in Kupffer cells, hepatocytes, and inflammatory cell infiltrates (Rosell *et al.*, 2000). Renal lesions may consist of tubulointerstitial, lymphoplasmacytic nephritis, interstitial granulomatous nephritis, or mixed patterns (Sarli *et al.*, 2008). Viral load is related to the amount of lymphoplasmacytic inflammation (Sarli *et al.*, 2008).

Porcine Dermatitis and Nephropathy Syndrome Porcine dermatitis and nephropathy syndrome (PDNS) associated with PCV2 has been reported in a purpose-bred research pig (Phaneuf *et al.*, 2007).

Pathogenesis The current hypothesis is that immune complex deposition is involved in pathogenesis (Wellenberg *et al.*, 2004). This disease is not always

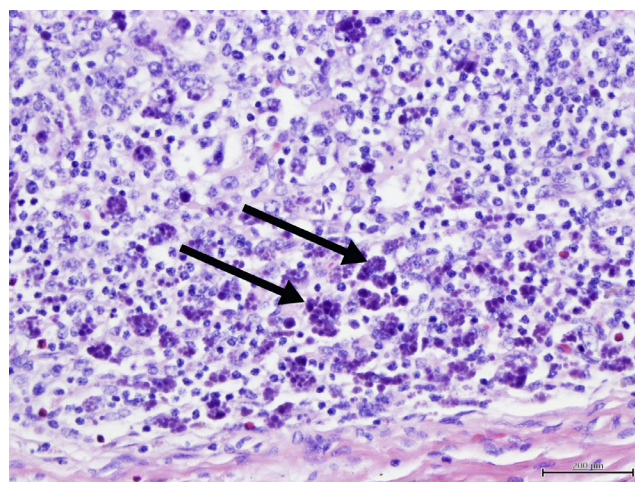


FIGURE 16.11 Porcine circovirus. Macrophages containing botryoid inclusions within the cytoplasm (arrows). Courtesy of J. Haruna.

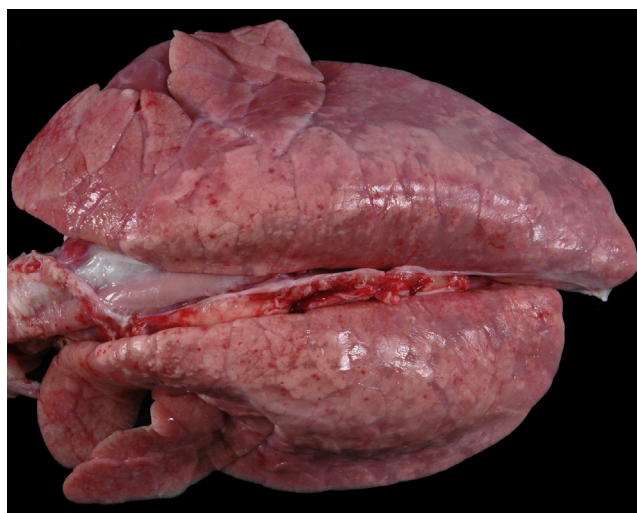

FIGURE 16.10 Porcine circovirus. Lungs with interstitial pneumonia. Lungs are rubbery and fail to collapse. Courtesy of T. Cecere.

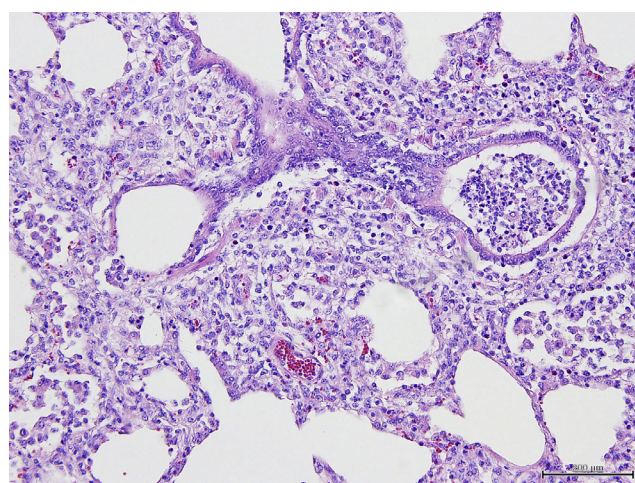


FIGURE 16.12 Porcine circovirus. Lung, broncho-interstitial pneumonia. Bronchi contain inflammatory cells and the interstitium is expanded by inflammatory infiltrates. Courtesy of J. Haruna.

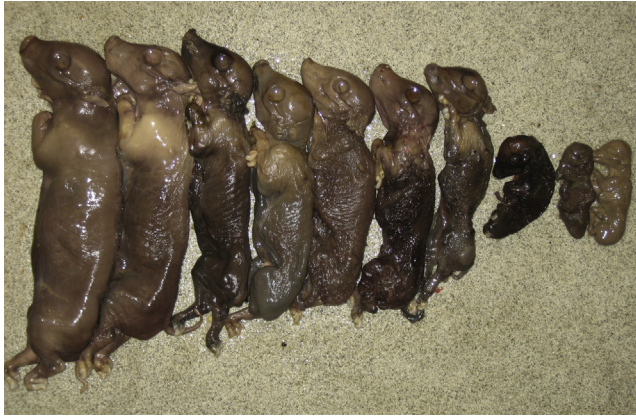

FIGURE 16.13 Porcine circovirus. Reproductive failure with mummification at different gestational ages. Courtesy of ISU Veterinary Diagnostic Laboratory.

associated with PCV2, but may also be caused by co-infection of PRRSV and TTV (Krakowka *et al.*, 2008).

Clinical Signs/Diagnosis PDNS is characterized by fever, lethargy, and raised purple lesions on the skin, especially the rear legs (Gillespie *et al.*, 2009) (Fig. 16.13). Skin lesions consist of dark red papules/macules multifocally, primarily on the hind limbs and peri-anal areas (Segales, 2012).

Necropsy The kidneys are enlarged, tan, and waxy with petechial hemorrhages (Segales, 2012; Choi and Chae, 2001; Gillespie *et al.*, 2009). Gross and histological lesions are present in the skin and kidney, but there may also be pulmonary congestion, and multiorgan fibrinoid necrotizing vasculitis with prominent lesions in the dermis, subcutis, stomach, kidneys, lung, spleen, and liver (Phaneuf *et al.*, 2007; Chae, 2005; Choi and Chae, 2001). Cutaneous lesions consist of severe necrotizing vasculitis in dermis and subcutis with leukocytoclastic inflammation of capillaries, small- and medium-sized venules, and arterioles with associated epidermal necrosis, ulceration, and dermal hemorrhage (Choi and Chae, 2001). Renal lesions consist of exudative to fibrinonecrotic glomerulonephritis, interstitial nephritis, and necrotizing arteritis (Segales, 2012; Chae, 2005). Renal and inguinal lymph nodes are also typically enlarged and reddened with necrosis of lymphocytes in the cortex and paracortex with infiltration of multinucleated giant cells (Choi and Chae, 2001; Chae, 2005). Systemic vasculitis is a hallmark lesion of PDNS. Histologically, the vasculitis is similar to type III hypersensitivity.

Porcine Respiratory Disease Complex PCV2 was the most commonly identified pathogen in a study that examined porcine pneumonia, and detection of PCV2 positively correlated with vascular lesions, with PCV2b being the dominant subtype (Szeredi *et al.*, 2012).

Pathogenesis Damage to the lymphoid system after infection is important in the pathogenesis of

porcine respiratory disease complex (PRDC) (Szeredi *et al.*, 2012). *In vitro*, activation of endothelial cells has been shown along with diminished coagulation time *in vivo* (Szeredi *et al.*, 2012). Co-infection of animals with PCV2 and another pathogen occurs in most cases, and pathogenesis is thought to occur from virus-induced damage to the immune system (Szeredi *et al.*, 2012). It is suspected that blood vessels play a role in PCV2 pathogenesis, but exact mechanism is not yet known (Szeredi *et al.*, 2012).

Clinical Signs/Diagnosis Animals with PRDC have a decreased growth rate, decreased feed efficiency, lethargy, anorexia, fever, cough, and dyspnea (Chae, 2005; Gillespie *et al.*, 2009). Disease may be due to coinfections with PCV2, PRRSV, SIV, *Mycoplasma hyopneumoniae*, APP, or *Pasteurella multocida* (Chae, 2005).

Necropsy The hallmark lesion is granulomatous bronchointerstitial pneumonia with peribronchial and peribronchiolar fibrosis (Chae, 2005). Mild to severe necrotizing ulcerative bronchiolitis is also seen (Gillespie *et al.*, 2009). Vascular lesions include lymphohistiocytic vasculitis, necrotizing vasculitis, vasculitis with fibrinoid necrosis, intravascular thrombi, along with acute edema, hyaline membranes and acute hemorrhage in the lung (Szeredi *et al.*, 2012). PCV2 antigen is present in endothelial cells, smooth muscle cells of the tunica media, within infiltrating white blood cells (WBCs), intravascular and perivascular macrophages, and intravascular monocytes (Szeredi *et al.*, 2012).

Reproductive Failure

Pathogenesis Infection of piglets is transplacental from PCV2-infected sows (Mateusen *et al.*, 2007). Target cells depend on age. Myocardocytes are the target cell of fetuses, whereas lymphoid tissues are targeted in neonates (Mateusen *et al.*, 2007). As the fetus develops, replication of virus decreases (Nauwynck *et al.*, 2012).

Clinical Signs/Diagnosis The time of gestation at which the sow is infected determines the course of disease. If the sow is infected at 57 days of gestation, there is increased viral replication with edema, hepatomegaly, and congestion of the fetus, whereas if infected around 90 days of gestation, there are increased reproductive abnormalities (Gillespie *et al.*, 2009). PCV2 infection of pregnant sows can cause fetal death leading to mummification or late-term abortion, stillbirths, mummification (often in the same litter), and preweaning mortality (Fig. 16.14) (Mateusen *et al.*, 2007; Gillespie *et al.*, 2009; Segales, 2012).

Necropsy Dams with reproductive failure show no pathological changes or histological lesions (Opriessnig and Langohr, 2013; Chae, 2005). In piglets, the heart is the most common organ affected and superficial lymph nodes may be enlarged (Mikami *et al.*, 2005; Opriessnig and Langohr, 2013). Histological examination reveals myocardocyte degeneration, necrosis, fibrosis and

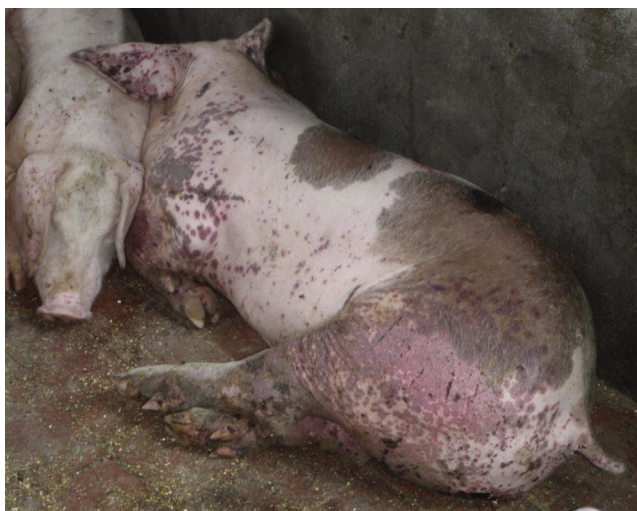

FIGURE 16.14 Porcine circovirus. Porcine dermatitis and nephropathy syndrome (PDNS). Multifocal raised red to purple areas covering hind limbs, forelimbs, and ears. Courtesy of ISU Veterinary Diagnostic Laboratory.

mineralization with surrounding lymphocytes, plasma cells, and macrophages (Mikami *et al.*, 2005; O'Connor *et al.*, 2001; Gillespie *et al.*, 2009; Segales, 2012). Intranuclear botryoid inclusion bodies, positive for PCV2 antigen, may be found within the cardiomyocytes (O'Connor *et al.*, 2001). Lymphoid organs often display depletion of lymphocytes with infiltration of multinucleated giant cells containing PCV2 antigen (Mikami *et al.*, 2005).

Granulomatous Enteritis

Pathogenesis The pathogenesis is currently unknown. When samples were submitted with clinical history suggestive of *Lawsonia intracellulare*, some had dual infection with PCV2, whereas others were infected with *L. intracellulare* only or were infected with PCV2 only (Jensen *et al.*, 2006).

Clinical Signs/Diagnosis Clinically, PCV2-associated granulomatous enteritis affects 2- to 4-month-old pigs and resembles chronic ileitis with diarrhea, unthriftiness, decreased growth, and increased mortality (Chae, 2005; Gillespie *et al.*, 2009). Differentials are *L. intracellulare*, *Brachyspira hyodysenteriae*, *B. pilosicoli*, *Salmonella*, and *E. coli* infection (Jensen *et al.*, 2006).

Necropsy Lesions are of a necrotizing ileitis and colitis indistinguishable grossly from proliferative ileitis caused by *L. intracellulare* (Jensen *et al.*, 2006). Mesenteric lymph nodes are enlarged and the intestinal mucosa is diffusely thickened (Gillespie *et al.*, 2009). Histologically, there is granulomatous enteritis, composed of epithelioid cells and multinucleated giant cells along with PCV2-type lesions in Peyer's patches but not in other lymphoid tissues (Gillespie *et al.*, 2009; Chae, 2005). Inflammation is primarily in the ileum, but occasionally also found in the colon and cecum (Opriessnig and

Langohr, 2013). There is occasional gastric ulceration (Opriessnig and Langohr, 2013). Other lesions include cytoplasmic inclusion bodies, proliferation of immature enterocytes, and edema in the mesocolon (Jensen *et al.*, 2006).

Acute Pulmonary Edema With this syndrome, all animals were seropositive for PCV2, with PCV2b being most prevalent (Cino-Ozuna *et al.*, 2011).

Clinical Signs Animals display a rapid onset of respiratory distress followed nearly immediately by death with no indications of previous disease (Cino-Ozuna *et al.*, 2011). Peracute death in PCV2-vaccinated herds has been associated with PCV2 infection (Cino-Ozuna *et al.*, 2011). Nursery and young finisher pigs are most commonly affected (Cino-Ozuna *et al.*, 2011; Segales, 2012).

Necropsy Clear fluid accumulates within the thorax with wet, heavy lungs and expansion of interlobular septae with edema (Cino-Ozuna *et al.*, 2011). Cranioventral lobes are consolidated (Cino-Ozuna *et al.*, 2011). Histological changes include diffuse interstitial macrophages and lymphocytes, fibrinoid necrosis of blood vessel walls, and surrounding edema (Cino-Ozuna *et al.*, 2011). Most affected animals display diffuse lymphoid depletion (Cino-Ozuna *et al.*, 2011).

PCV2-Associated Neuropathy PAN is currently under investigation (Gillespie *et al.*, 2009).

Clinical Signs Animals display wasting and neurologic deficits which may be associated with congenital tremors, but this has not been confirmed (Seeliger *et al.*, 2007; Gillespie *et al.*, 2009; Opriessnig and Langohr, 2013).

Necropsy Lesions consist of acute hemorrhages and edema of cerebellar meninges and parenchyma due to necrotizing vasculitis resulting in degeneration and necrosis of the gray and white matter (Seeliger *et al.*, 2007; Gillespie *et al.*, 2009).

Other syndromes which may be associated with PCV2 include exudative dermatitis and necrotizing lymphadenitis (Chae, 2005). Animals with PCV2-associated exudative dermatitis may have concurrent PPV or *Staphylococcus hyicus* (Opriessnig and Halbur, 2012; Opriessnig and Langohr, 2013). Necrotizing lymphadenitis differs from other PCV2-associated diseases in that there is no granulomatous inflammation (Chae, 2005).

b. Salmonellosis

Salmonellosis can be subclinical or present with multiorgan involvement, including septicemia, pneumonia, meningitis, lymphadenitis, abortion, and enterocolitis which can be acute or chronic (Carlson *et al.*, 2012).

Etiology There are over 2400 serotypes in the genus *Salmonella*, although there are only two species, *Salmonella enterica* and *S. bangori*. *Salmonella* nomenclature is constantly being updated and this chapter uses the current CDC guidelines.

All members of this genus are motile, non-spore-forming, facultative anaerobic, gram-negative bacilli possessing peritrichous flagella. There are three serotypes that are typically etiologic agents of clinical disease in swine and numerous others that are occasionally associated with disease.

S. enterica ser. Choleraesuis var. *kunzendorf* contains large drug-resistance plasmids and is the most frequent serotype in some parts of the world causing disease in swine, and infection is usually manifested as septicemia and/or pneumonia. *S. enterica* ser. Typhimurium is the most frequently isolated serotype in North America and typically causes enterocolitis. *S. enterica* ser. Typhisuis is associated with localized epizootics characterized by chronic wasting, caseous lymphadenitis, diarrhea, and pneumonia. It is very common to isolate more than one serotype from an individual pig; however, it is unusual that primary disease would be caused by a serotype other than *S. enterica* ser. Choleraesuis or *S. enterica* ser. Typhimurium. *Salmonella* enterocolitis is usually attributed to *S. enterica* ser. Typhimurium and less frequently, *S. enterica* ser. Choleraesuis.

Epizootiology and Transmission The source of *S. enterica* ser. Choleraesuis for swine is typically other swine and environments contaminated by swine (or other animals). Feed and feed ingredients have also been shown to be a source of serotypes that can cause disease in swine (Harris *et al.*, 1997). Transmission is both vertical and horizontal by fecal–oral spread or nasal secretions. The incubation period ranges from 2 days to several weeks, and survivors become carriers that shed the bacteria in feces for several months. Some form of stress, including shipping, food deprivation, concurrent diseases, research protocols, and mixing pigs from different sources, usually precedes clinical disease. Stress also increases shedding by inapparent carriers. *S. enterica* ser. Choleraesuis is fairly host-specific for swine, but *S. enterica* ser. Typhimurium is not host-specific (Carlson *et al.*, 2012). *S. enterica* ser. Typhimurium is also transmitted via the oronasal route following which organisms have been found in the cecum, colon, and ileal Peyer's patches within 3 h (Fedorka-Cray *et al.*, 1995).

Pathogenesis Salmonellae have over 200 virulence factors including those involved in adhesion, invasion, cytotoxicity, and resistance to killing (Carlson *et al.*, 2012). They synthesize over 30 proteins that are specific to evading intracellular killing by macrophages. Invasive ability of the organism along with neutrophil recruitment and transmigration are important in pathogenesis. *S. enterica* ser. Typhimurium-secreted proteins activate pathogen elicited epithelial chemottractant and protein kinase C which promotes secretion of IL-8, as well as many other pathways (Lee *et al.*, 2000; Vitiello *et al.*, 2008; Galdiero *et al.*, 2003). Outer membrane proteins such as lipid A and lipopolysaccharide are important mediators of cell

damage and microvascular thrombosis and endothelial necrosis which often lead to mucosal ischemia.

S. enterica ser. Typhimurium infection downregulates host local inflammatory response, specifically, TH1 response genes, genes involved in cytoskeletal reorganization, and chaperone proteins (Uthe *et al.*, 2007). Different serovars of salmonella result in different cytokine activation within the host (Skjolaas *et al.*, 2006; Paulin *et al.*, 2007).

The lungs are the site of initial *S. choleraesuis* infection in oronasally exposed pigs (Gray *et al.*, 1996). In pigs exposed via the oral route, *S. enterica* ser. Choleraesuis also can invade the mucosa of the ileum where it is taken up by macrophages. The predominant portal of entry is within the Peyer's patches, specifically through M cells (Meyerholz and Stabel, 2003; Meyerholz *et al.*, 2002). This invasion is followed by dissemination to the spleen and liver via CD18(+) macrophages (Vazquez-Torres *et al.*, 1999). It produces both Shiga-like and cholera-like endotoxins that are responsible for the microthrombosis and ischemia of vessels in the lamina propria and resulting necrosis of the enterocytes. Rectal strictures, particularly of the cranial hemorrhoidal artery, are an outcome of porcine anatomy since pigs have poor to no collateral circulation to the rectum (McGavin and Zachary, 2007). Diarrhea is malabsorptive with extensive fluid loss from the necrotic lesions (Carlson *et al.*, 2012).

Clinical Signs/Diagnosis Signs characteristic of *Salmonella* septicemia in pigs less than 5 months old include respiratory signs of cough, dyspnea, pneumonia, and cyanosis of the ears and ventral abdomen. Lethargy, anorexia, pyrexia of 40.5–41.6°C, and sometimes jaundice followed by watery yellow diarrhea is also evident. Cyanosis of the extremities and abdomen may also be seen. Diarrhea may be seen, but not until 3–4 days after the other signs are manifest. It can cause abortion in breeding sows.

In *S. enterica* ser. Typhimurium infections, the initial diarrhea is usually watery, yellow and sporadically hemorrhagic and lasts less than a week but may recur. Diarrhea containing blood or mucus is not a prominent feature as it is in diseases such as swine dysentery. Anorexia, pyrexia, and dehydration are seen concurrently with diarrhea. A distended abdomen due to rectal strictures can be a sequela to septicemia. The majority of affected pigs recover; however, some will be carriers and shed the organism for several months. Death may occur in severely affected animals.

Enzyme-linked immunosorbent assays (ELISAs) are available for detection, but definitive diagnosis is achieved via bacterial isolation in conjunction with pathological lesions consistent with *Salmonella* sp. infection (Carlson *et al.*, 2012).

Differential diagnoses for septicemic form include erysipelas and *Streptococcus enterica* ser. Suis as well as

other causes of septicemia. A differential list for diarrhea includes other causes of gastroenteritis in recently weaned swine, including colibacillosis, *Lawsonia intracellularis*, *Serpulina hyodysenteriae*, transmissible gastroenteritis (TGE), PCV2, rotavirus, *Trichuris suis* and coccidiosis.

Treatment Clinical salmonellosis should not be treated because recovered pigs remain carriers and some isolates may be pathogenic for humans. If absolutely necessary, treatments should be based on susceptibility testing.

Prevention/Control Swine may shed *Salmonella* for 5 months or more. Clinically affected swine should be euthanized and the facility sanitized. Removing stressors to minimize fecal shedding by carriers and practicing good sanitation to minimize exposure to the bacteria may help reduce clinical disease. Common surface disinfectants that are efficacious for this bacterium include chlorine, iodine, and phenols. Modified live attenuated vaccines for *S. enterica* ser. Choleraesuis are protective and are thought to be effective because they stimulate cell-mediated immunity. For *S. enterica* ser. Typhimurium, killed bacterins are available and may provide protection. Medication of feed or water with appropriate antibiotics (e.g., carbadox, neomycin) in conjunction with improvements in husbandry, management, and environment may have a prophylactic benefit.

Necropsy *S. enterica* ser. Choleraesuis infection leads to severe pleuropneumonia; cyanosis of the ears, feet, tail, and abdomen; splenomegaly and hepatomegaly; edematous enlarged mesenteric lymph nodes; erosion of the fundic mucosa in the stomach; and a focal to diffuse necrotic typhlocolitis with or without a necrotic ileitis (Turk *et al.*, 1992). Microscopic lesions include paratyphoid nodules in the liver; necrotic lesions involving the intestinal mucosa, submucosa, and lymphoid follicles; and a bronchopneumonia or hemorrhagic pleuropneumonia (Turk *et al.*, 1992; Carlson *et al.*, 2012).

With *S. enterica* ser. Typhimurium, lesions include enterotyphlocolitis involving the ileum, cecum, spiral colon with thickened edematous walls, red roughened mucosa, and multifocal to coalescing erosions and ulcers covered with pseudomembranous gray–yellow fibrinonecrotic debris, with or without button ulcers. Rectal strictures with mural fibrosis and resultant distention of the colon with fecal matter are also seen. Acute lesions include necrosis of Peyer’s patches, but later in disease they may be hyperplastic.

Research Complications Pigs proven to be clinically ill or shedding *Salmonella* should not be maintained in a research facility because of chronic fecal shedding and zoonotic risks. *Salmonella* are present at a low subclinical level in the majority of conventional swine herds. Outbreaks of clinical disease are associated with immunosuppression or stress, including experimental stress. Clinical disease caused by *S. enterica* ser. Choleraesuis

has up to 60% morbidity and up to 30% mortality, which would seriously impact any research project (Schwartz, 1991).

c. Glasser’s Disease (Haemophilus, Porcine Polyserositis, Infectious Polyarthrititis, Fibrinous Polyserositis, and Arthritis)

Etiology *Haemophilus parasuis*, a member of the Pasteurellaceae family, are a small gram-negative pleomorphic coccobacilli. There are currently 15 recognized serovars. Both pathogenic and nonpathogenic strains of the organism exist. Exposure to nonpathogenic strains can induce protective immunity.

Epizootiology and Transmission *H. parasuis* is one of the earliest isolates to be cultured from the nasal cavities of swine in conventional herds. In endemic herds it can be cultured when animals are 1 week of age and is commonly cultured from the upper respiratory tracts of healthy pigs and may be part of normal flora (MacInnes and Desrosiers, 1999). Experimental evidence suggests that the first site of colonization in piglets is the nasal mucosa (Vahle *et al.*, 1995). It is only known to infect swine, suggesting that introduction by other carrier species is unlikely. The role of *H. parasuis* as a respiratory pathogen is not well established; however, some report that it may be a primary etiologic agent in fibrinosuppurative bronchopneumonia (Aragon *et al.*, 2012).

Pathogenesis This organism is an opportunistic pathogen with PRRSV, PCV2, and *B. bronchiseptica*. Organisms adhere to epithelial cells of the upper respiratory tract, which induces apoptosis and cytokine release (Bouchet *et al.*, 2009). Resistance to phagocytosis is likely associated with the capsule and enhances virulence (Aragon *et al.*, 2012). The severity of disease is dependent on *H. parasuis* strain.

Clinical Signs/Diagnoses In conventional herds where *H. parasuis* is enzootic, the clinical signs will be mild with low morbidity. In susceptible herds, the clinical signs occur within a week after exposure and consist of some or all of the following: pyrexia 40–41.7°C, anorexia, coughing, depression, swollen joints with lameness, neurological signs, dyspnea, and sudden death. A markedly increased WBC and decreased packed cell volume (PCV) have been reported in experimentally infected SPF piglets (Wiegand *et al.*, 1997). Long-term sequelae include abortion and chronic arthritis. An oligonucleotide-specific capture plate hybridization assay has been developed and is reported to be specific and more sensitive than culturing for *H. parasuis* from lesions and nasal swabs (Calsamiglia *et al.*, 1999). Differentials include *Mycoplasma hyorhinis* and other bacterial septicemic conditions that affect swine including *Erysipelothrix rhusiopathiae*, *Salmonella choleraesuis*, and *Streptococcus suis*.

Treatment Parenteral antibiotics should be started as soon as clinical signs become evident. Oral antibiotics

are less effective. High doses of penicillin should be given to those with and without clinical signs. Several other antibiotics (cephalosporins, fluoroquinolones, potentiated sulfas, tetracyclines, tylosin) are also effective. Resistance to tetracycline, erythromycin, and penicillin in some strains is increasing.

Prevention/Control Practices to increase immunity by the use of bacterins and reduction of experimental, environmental, and shipping stress are helpful in prevention and control of disease. Herd-specific autogenous vaccines should be considered, as it is unlikely that any one commercial bacterin will induce immunity to all pathogenic strains in the population (Aragon *et al.*, 2012). Medicated early weaning can be successful if high doses of both parenteral and oral antibiotics are utilized (Aragon *et al.*, 2012). Antimicrobial medication of feed or water of groups of swine at risk may be beneficial.

Necropsy Gross lesions may include cyanosis of the ears and tail, polyarthritis of one or more joints, fibrinous pleuritis, pericarditis, peritonitis, and leptomeningitis (Fig. 16.15) (Little and Harding, 1971; Aragon *et al.*, 2012). Histopathologic lesions in peracute disease consist of fibrin thickening of alveolar walls and capillary thrombosis of glomerular tufts. Acute disease lesions consist of fibrinopurulent arthritis and synovitis, fibrinous to fibrinopurulent serositis, and fibrinopurulent leptomeningitis (McGavin and Zachary, 2007; Aragon *et al.*, 2012).

Research Complications This disease will confound cardiovascular studies because the chronic form can produce congestive heart failure and fibrinous pericarditis.

d. Erysipelas (Swine Erysipelas)

Etiology Swine erysipelas (SE) is caused by *Erysipelothrix rhusiopathiae* is a gram-positive bacillus

that has 28 serotypes. The majority of isolates from swine are serotypes 1 and 2.

Epizootiology and Transmission The domestic pig is the primary reservoir of *E. rhusiopathiae*, and probably 30–50% of conventional swine are carriers (Opriessnig and Wood, 2012; Cowart, 1995). These pigs harbor the bacteria in lymphoid tissues (tonsils, Peyer's patches) and shed it in nasal secretions, saliva, and feces. Individuals with acute SE will shed large quantities into the environment, and those with the chronic form are a long-term source of contamination. Additionally, contact with infected sheep, turkeys, chickens, ducks, and emus is a potential source of infection for swine. Swine older than 3 months and younger than 3 years of age are most likely to develop clinical disease. Passive antibodies obtained from the sow protect the young, and acquired immunity from subclinical infections protects the mature animals. This bacterium typically gains entry into the body through contaminated food and water (oral route) and skin wounds.

Pathogenesis The organisms gain entry to the body via the palatine tonsils or gut-associated lymphoid tissue, and through skin wounds via direct contact or arthropod bites (Chirico *et al.*, 2003). The pathogenesis of the lesions is not completely understood, but virulence factors are currently only partially characterized, but the most important factors include neuraminidase, capsular polysaccharides, and surface proteins (Wang *et al.*, 2010).

Clinical Signs/Diagnosis Animals with acute SE may have no clinical signs or have a combination of classical rhomboid or diamond-shaped urticarial (pink to purple) skin lesions on the snout, ears, abdomen, and thighs; fever of 40–42°C; anorexia; depression; stiff, stilted gait; sitting posture; abortion; and sudden death. Skin lesions appear 2–3 days post exposure and are erythematous, raised, and palpable, measure 1–8 cm across, and vary in number from few to many (Fig. 16.16)

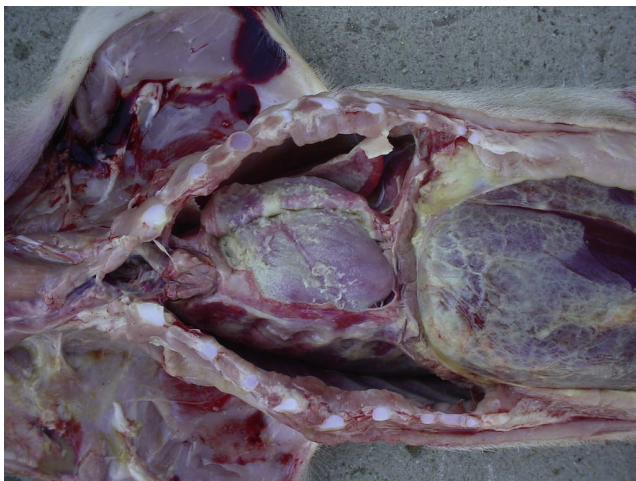

FIGURE 16.15 *H. parasuis* (Glasser's disease). Thoracic and peritoneal fibrinoserositis. Courtesy of ISU Veterinary Diagnostic Laboratory.

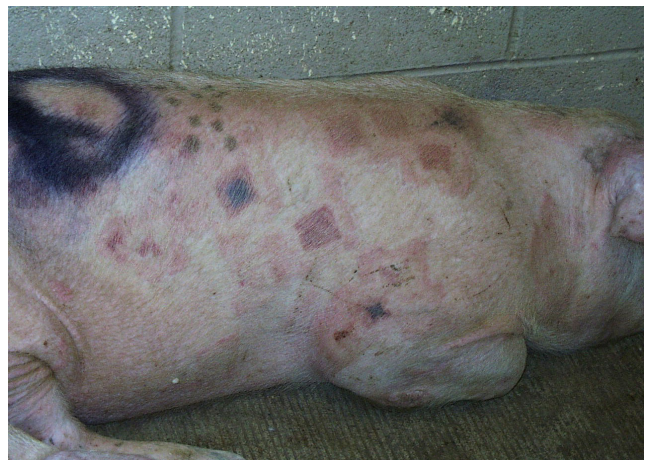

FIGURE 16.16 *E. rhusiopathiae* (diamond skin disease). Multifocal red to purple rhomboid lesions in the skin. Courtesy of ISU Veterinary Diagnostic Laboratory.

(Amass and Scholz, 1998). The fever and skin lesions will usually resolve within 1 week.

Enlarged, stiff joints resulting in slight to non-weight-bearing lameness characterize the chronic form of SE. The hock and carpal joints are usually the most visibly affected in those with chronic arthritis. In some cases cardiac insufficiency manifested by exercise intolerance and sudden death may result. Chronic SE may follow subclinical, subacute, and acute forms, sometimes within 3 weeks.

PCR assays can be used, as can formic acid and immunohistochemistry (IHC) to diagnose SE (Brooke and Riley, 1999).

Differentials for the acute form include any bacterial septicemia and PDNS caused by PCV2. The diamond-shaped skin lesions are characteristic. Differentials for chronic SE include other causes of lameness in swine, including *Haemophilus* polyserositis, mycoplasmal polyserositis, and trauma and other bacterial septicemias such as *Actinobacillus suis*.

Treatment Penicillin is the treatment of choice for the acute form of SE. Most strains are susceptible to several classes of antibiotics such as beta lactams, fluoroquinolones and cephalosporins (Yamamoto *et al.*, 2001). Hyperimmune serum has been used historically and can be effective if given early in the course of the disease, especially in suckling piglets. This will provide about 2 weeks of passive immunity. Anti-inflammatory drugs can be used to treat the arthritis associated with chronic SE (Opriessnig and Wood, 2012; Cowart, 1995).

Prevention/Control Vaccination is worthwhile, although neither attenuated vaccines nor bacterins are successful at preventing chronic SE (Cowart, 1995). Immunization with purified protein antigen P64 is protective against experimental challenge (Yamazaki *et al.*, 1999). The surface protein SpaA has potential as an antigen for new vaccines (Makino *et al.*, 1998; Imada *et al.*, 1999; Shimoji *et al.*, 1999). Attenuated vaccines can be injected, given orally in drinking water, or delivered by aerosol with special equipment. Antibiotic treatment should be stopped 10 days prior to giving attenuated live vaccines. Due to the ubiquitous nature of *E. rhusiopathiae*, the ultimate prevention plan is to obtain SPF animals via cesarean derivation or preweaning medication and to maintain them in a barrier facility (Opriessnig and Wood, 2012).

Chronically infected animals should be eliminated from the facility. Routine use of common disinfectants, including hypochlorite, quaternary ammonium, phenolic, and alkali, is important as these bacteria can survive in the environment for long periods.

Necropsy Acute-phase gross lesions are those of a bacteremia and generalized coagulopathy (Wood, 1984). Characteristic rhomboid or rectangular-shaped, slightly raised, firm skin lesions are most commonly found on the skin of the abdomen but also on the thighs, ears, snout, throat, and jowls. There is congestion of the

spleen, lungs, and liver, and there may be petechial to ecchymotic hemorrhages in the cortex of the kidneys, on the atrial epi- and myocardium, and within lymph nodes (Wood, 1984; Opriessnig and Wood, 2012). Microscopic lesions in the acute phase are the result of damage done to endothelial cells in capillaries and venules. In the dermal papillae these lead to fibrin deposition, microthrombi, lymphocytic and plasmacytic perivascular infiltrates, and focal necrosis. Chronic lesions are manifested as a proliferative, nonsuppurative synovitis and arthritis that results in enlarged joints, most commonly involving the stifle, hock, and carpal joints (Wood, 1984; Opriessnig and Wood, 2012).

Research Complications Acute SE can potentially complicate research protocols involving small numbers of swine by causing losses due to sudden death. The chronic form will affect orthopedic and cardiovascular studies since proliferative, nonsuppurative arthritis and vegetative proliferation on the heart valves can result. *E. rhusiopathiae* is a zoonotic disease which in most cases is self-limiting; however, care must be taken to protect personnel when working with infected pigs.

e. Streptococcosis (Streptococcal Meningitis)

Etiology *Streptococcus suis* (Lancefield's group D) is a gram-positive oval cocci found as diplococci or short chains. Capsular types 1–9 are most often associated with clinical disease in swine, with type 2 being the most common (Aarestrup *et al.*, 1998a; Gottschalk, 2012b).

Another streptococcus species, *S. equisimilis*, may be recovered from cases of septicemia associated with subsequent development of swollen joints (Gottschalk, 2012b).

Epizootiology and Transmission Transmission between herds is via flies and carrier animals (Enright *et al.*, 1987). Newborns are infected during parturition and suckling by direct contact, aerosols, and fomites (Berthelot-Herault *et al.*, 2001). Most piglets of carrier sows are colonized before weaning age (Torremorell *et al.*, 1998).

Subclinical carriers harbor the organism in their tonsillar crypts, nasal cavity, and reproductive and gastrointestinal tracts. When a carrier is introduced to a susceptible herd, the signs are usually first evident in recently weaned young between 5 and 12 weeks of age. This bacterium has been cultured from a variety of other animals, including birds, and wild boars (Baums *et al.*, 2007; Devriese *et al.*, 1994). Simultaneous infection with other pathogens, including PRRSV and PRV, can increase the severity of clinical signs (Cowart, 1995; Gottschalk, 2012b).

Pathogenesis The pathogenesis of *S. suis* is believed to begin via colonization of the palatine and pharyngeal tonsils. It is then spread extracellularly or attached to monocytes via the blood or lymph (Gottschalk, 2012b;

Madsen *et al.*, 2002). Pathogenesis is still not fully understood. Most studies are done on serotype 2, but use different animal models. There are different virulence factors between serotypes, but these are not always consistently involved in disease. Hemolysin (suilysin) is one of the best-characterized virulence factors and is toxic to epithelial, endothelial, and phagocytic cells (Gottschalk and Segura, 2000). Bacteria and suilysin colocalize within neutrophils and macrophages localized to meningeal lesions (Zheng *et al.*, 2009).

Clinical Signs/Diagnosis Manifestations of meningitis are the most characteristic signs of *S. suis* type 2 infections in swine, and swine aged 5–16 weeks are most commonly affected. Pyrexia to 42.5°C is usually the initial sign, followed by anorexia, depression, ataxia, paddling, opisthotonus, convulsions, and death. Additional signs of *S. suis* infection include pneumonia, rhinitis, polyarthritides, and less commonly, stillbirths, abscesses, vaginitis, and myocarditis (Gottschalk, 2012b; Staats *et al.*, 1997). Otitis interna has been reported as a sequela to *S. suis* meningitis with involvement of perilymphatic ducts (Madsen *et al.*, 2001).

A PCR assay developed for the detection of strains of serotypes 1 and 2 in tonsillar specimens and an ELISA based on a purified polysaccharide antigen are specific and sensitive to diagnose presence of *Streptococcus* sp. (Wisselink *et al.*, 1999; Kataoka *et al.*, 1996). Isolation of the organism from an area other than the nasal or oral cavity (where organism is part of normal flora) is required, with serotyping being an important part. Isolates from different geographical areas may be genotypically different and make diagnosis more difficult (Rehm *et al.*, 2007). Differentials include other streptococcal infections, *H. parasuis*, *E. rhusiopathiae*, *S. enterica* ser. Choleraesuis, and salt poisoning or water deprivation.

Treatment Treatment should be with a parenteral antibiotic to which the particular herd strain has been shown to be susceptible by testing. Resistance to several antibiotics, including tetracycline, tylosin, and sulfonamides, is a developing concern (Aarestrup *et al.*, 1998b; Rasmussen *et al.*, 1999; Gottschalk, 2012b).

Prevention/Control Rederivation by hysterectomy or hysterotomy and maintenance in a barrier facility will eliminate *S. suis* from an infected herd (Gottschalk, 2012b). The natural history and epizootiology of the disease is such that depopulation with subsequent repopulation with clean animals is a feasible method of control and prevention within a research facility. Antimicrobial therapy and early weaning did not eliminate the tonsillar carrier state (Amass *et al.*, 1996; Macinnes and Desrosiers, 1999).

Minimization of environmental and experimental stress, good sanitation, prophylactic antibiotics, and use of bacterins will help control clinical disease. *S. suis* is susceptible to common disinfectants. Mixing swine

from different sources and of different ages should not occur. Oral medication of feed or water has been shown to be beneficial in controlling streptococcal meningitis. Penicillin, amoxicillin, florfenicol, and gentamicin antimicrobials are often effective, however culture and sensitivity should be performed on isolates (Marie *et al.*, 2002). Bacterin vaccines, including autogenous and whole-cell, have had variable success. Live avirulent strains and vaccines against cell-wall proteins or extracellular proteins, particularly suilysin, have produced protective immunity in swine, yet are inconsistent (Busque *et al.*, 1997; Jacobs *et al.*, 1996; Gottschalk, 2012b).

Necropsy Necropsy findings may include evidence of encephalitis, cerebral edema, and fibrinous pleuritis/pericarditis. Histopathologic findings include suppurative meningitis, choroiditis with hyperemic blood vessels, and fibrinopurulent to suppurative epicarditis (Gottschalk, 2012b).

Research Complications Direct losses from fatal meningitis will certainly affect all types of research. Cardiovascular studies will be confounded by the development of endocarditis and myocarditis. *S. suis* type 2 is zoonotic to humans (Erickson, 1987).

f. Pseudorabies

PRV, also known as Aujeszky's disease, was not considered important in the US prior to 1960. However, since that time new and more virulent strains have emerged. PRV is a reportable disease. In January 1989, the US implemented a national PRV eradication program and in 2005 was declared to be free of the disease (Agriculture, 2008). This program included test and removal, offspring segregation, and depopulation and repopulation. The majority of industrialized nations also have eradication programs.

Etiology The disease is caused by suid herpesvirus 1 in the genus *Varicellovirus*, subfamily Alphaherpesvirinae, family Herpesviridae (Davison *et al.*, 2009). Herpesviridae are known for the ability to establish latent infections, particularly in the sensory ganglia of the nervous system.

Suid herpesvirus 1 can affect a variety of animals, including pigs, cattle, sheep, goats, dogs, cats, rodents, macaques, and marmosets. Reports of human infection are limited and poorly documented (Mettenleiter *et al.*, 2012). Pigs may host subclinical and latent infections whereas infection of all other animals results in death.

Epizootiology and Transmission The single most important mechanism contributing to disease spread is the movement of swine which are shedding the viral particles. Transmission can occur via direct contact, fomites, insemination, inhalation of aerosolized particles, or transplacental transmission. Infective levels of virus can persist for up to 7h in air with relative humidity of 55% (Schoenbaum *et al.*, 1990). Infective levels of

viral particles can also be present in tissues of animals that have died from the disease. Consuming infected carcasses or feed that has been contaminated with the virus is another means of transmission. Evidence indicates that avian species are not a significant contributor to the spread of the virus, and the role of insects in the transmission process has not been adequately evaluated (Zimmerman *et al.*, 1989). Animals other than pigs, which are considered dead-end hosts, typically die within 3 days of being infected.

Pathogenesis In natural infections, the virus enters via the mucosal epithelium in the nasopharynx and tonsils and replicates in the epithelium. The virus gains access to neurons of the facial region (olfactory, trigeminal, glossopharyngeal nerves), and reaches neuronal cell bodies via axonal retrograde transport, and then spreads to the medulla and pons where it replicates in neurons and spreads to other parts of the brain resulting in latent infection of the trigeminal ganglia (Mettenleiter *et al.*, 2012). Viremia disseminates virus to many other organs (Kritis *et al.*, 1999; Mettenleiter, 2000).

Clinical Signs/Diagnosis The clinical signs associated with PRV are related to the age of the swine affected, although the strain of virus and infectious dose also play a role. The virus predominantly impacts the respiratory and nervous systems. Neonatal pigs typically respond to exposure with acute signs related to the central nervous system (CNS). Affected pigs will tremble, hypersalivate, stumble, and exhibit nystagmus and opisthotonus, often with epileptiform-like seizures. Because of posterior paresis, the animals may be observed sitting like a dog. Other signs include circling and paddling, vomiting, and diarrhea. Once CNS signs start, death usually follows within 24–36 h, and mortality approaches 100% in neonates and young piglets; mortality may decrease to 50% by 4 weeks of age. As the pigs age, the clinical signs become less severe, fewer pigs develop CNS involvement, and mortality declines. Respiratory signs characterized by sneezing, nasal discharge, and cough become the hallmark of pigs that are infected at greater than 9 weeks of age. Morbidity rate is high, but mortality is low with uncomplicated CNS signs such as muscle tremors that occur only sporadically. The duration of clinical signs is usually 6–10 days, with rapid recovery unless the disease has progressed to pneumonia or a secondary bacterial pneumonia has been initiated. Coinfection with other viruses (PRRSV, PCV2, SIV) may result in severe proliferative and necrotizing pneumonia in weanling and postweanling pigs (Morandi *et al.*, 2010). When CNS signs are exhibited, the clinical diagnosis of PRV becomes much more facile. Sows and boars also develop primarily respiratory signs, although pregnant animals in the first trimester resorb the fetus, and in the second to third trimester, abort.

Serum neutralization is the standard test, but ELISA and latex agglutinations are also commonly used to diagnose. Virus isolation allows for a definitive diagnosis, with the brain, tonsils, and lung being the organs of choice. Trigeminal ganglia, olfactory ganglia, and tonsils are the preferred tissues for isolation/detection of virus using IFA, IHC, or *in situ* hybridization. The main differential diagnoses are SIV, rabies, CSF, ASFV, porcine teschovirus (PTV), Nipah virus, and many others.

Prevention/Control Modified live, killed, and gene-deleted vaccines with foreign-gene insertions are available to aid in the control of PRV (Mulder *et al.*, 1997). The vaccines protect pigs against clinical signs and mortality but do nothing toward eradicating the disease; the vaccine does not eliminate the virus in infected animals, nor does it prevent animals from becoming infected with the virus. Animals that are vaccinated, however, do shed lesser amounts of virus and have limited tissue invasion by the organism. The gene-deleted vaccinations offer the advantage of producing vaccinated animals that lack antibody against the specific protein coded for by the deleted gene to allow the vaccinated pigs to be differentiated serologically from infected pigs.

Necropsy Gross lesions may be minimal or may include a fibrinonecrotic rhinitis; necrotic foci in the tonsils, liver, spleen, lungs, intestines, and adrenals; occasional leptomenigeal hyperemia; endometritis; and necrotizing placentitis (Thomson, 1988). Microscopic lesions include a nonsuppurative meningoencephalitis and ganglioneuritis involving both gray and white matter. Eosinophilic intranuclear inclusions may be found in neurons, astrocytes, oligodendroglia, and endothelial cells (Thomson, 1988). There is a necrotizing bronchitis and alveolitis, necrotizing tonsillitis, lymphohistiocytic endometritis, and necrotizing placentitis with inclusion bodies in necrotic and epithelial cells around the foci of necrosis (Mettenleiter *et al.*, 2012).

Research Complications This is a reportable disease, and as such affected animals need to be euthanized.

g. Encephalomyocarditis Virus

Etiology Encephalomyocarditis virus (EMCV) is found in the genus *Cardiovirus*, family Picornaviridae.

Epizootiology/Transmission Outbreaks of the acute myocarditis form have been reported most frequently in Europe and are often clustered in endemic areas (Koenen *et al.*, 1999; Maurice *et al.*, 2007). Rodents are thought to be a reservoir and can infect food and water that pigs ingest (Alexandersen *et al.*, 2012). Infection of pigs is not uncommon, but clinical disease is infrequent. Infected pigs can excrete virus, and dead pigs are also potential sources of infection.

Pathogenesis Oral exposure is most likely, with virus subsequently found in myocardiocytes, tonsils, intestinal tract and macrophages.

Clinical Signs/Diagnosis There are two forms of disease caused by EMCV, an acute myocarditis and reproductive failure in sows. In young pigs the only clinical sign may be sudden death. Other signs in young animals may include anorexia, listlessness, trembling, staggering, paralysis, or dyspnea. Infected sows may abort or have mummified or stillborn fetuses.

EMCV is diagnosed via virus isolation, virus neutralization, and ELISA. There is currently no treatment for EMCV.

Prevention/Control Vaccines are available to prevent disease caused by EMCV. Minimizing stress will help control disease.

Necropsy In acute infections, heart lesions are prominent. Epicardial hemorrhage may be the only lesion noted, although hydropericardium, hydrothorax, and pulmonary edema are often noted (Alexanersen *et al.*, 2012). Myocardial lesions are most prominent in the right ventricle and are grayish-white in color. Histological lesions of nonsuppurative myocarditis or encephalitis are indicative of EMCV disease (Alexanersen *et al.*, 2012).

Research Complications The virus has only recently been associated with human disease, and it is known to infect and cause disease in nonhuman primates (Czechowicz *et al.*, 2011). The risk of human infection may increase if porcine-to-human xenografts are performed.

h. Porcine Teschovirus

Etiology Teschen disease is caused by porcine teschovirus, a member of the family Picornaviridae, genus *Teschovirus*. There are several PTV serotypes which present with different disease manifestations.

Epizootiology/Transmission The only known host of PTV is the pig. The virus is ubiquitous worldwide, with no herd shown to be free of virus. Disease occurs sporadically. Transmission is primarily fecal-oral, although fomite transmission also occurs. Virus particles remain active in the environment and are highly resistant to inactivation (Derbyshire and Arkell, 1971).

Pathogenesis The virus replicates in the tonsil and intestinal tract. In some animals, there is a viremia, which allows spread to the CNS.

Clinical Signs/Diagnosis Polioencephalomyelitis, reproductive disease, enteric disease, pericarditis, myocarditis, and pneumonia are all signs of PTV, depending on serotype.

Teschen disease is caused by a highly virulent PTV-1 strain: All ages are affected and the main presentation is polioencephalomyelitis although other signs include fever, anorexia, ataxia, opisthotonus, coma, and paralysis. Death is common 3–4 days post initial clinical signs.

Talfan disease is caused by a less virulent PTV-1 strain. Signs are milder than in Teschen disease and typically consist of benign enzootic paresis.

PTV also may cause abortion in swine (Bielaaski and Raeside, 1977). Although there have been reports of enteric disease, pericarditis, myocarditis, and pneumonia associated with PTV, studies have been inconsistent in reproduction of these lesions (Alexanersen *et al.*, 2012).

Reverse transcriptase PCR (RT-PCR) is used to detect viral RNA. The virus can be found in the spinal cord, brainstem, or cerebellum of animals with Teschen disease. Other disease manifestations may be more complicated to isolate virus from.

Treatment Animals with mild disease may recover, but there is no effective treatment.

Prevention/Control Prevention of import of animals from enzootic areas helps control spread of Teschen disease. Elimination of PTV proves difficult, as the viruses have been isolated from SPF herds, and gnotobiotic pigs may be infected due to transplacental transmission (Alexanersen *et al.*, 2012).

Necropsy No specific lesions have been associated with PTV. Histological lesions consist of diffuse chromatolysis and are present throughout the CNS, but especially in the ventral columns of the spinal cord, cerebellar cortex, and brain stem (Alexanersen *et al.*, 2012; Koestner *et al.*, 1966; Holman *et al.*, 1966).

Research Complications Teschen disease is a reportable disease (Health, 2013b).

2. Respiratory Diseases

a. Atrophic Rhinitis

Etiology Toxigenic strains of *P. multocida*, *B. bronchiseptica*, and *H. parasuis* are the bacterial agents of the multifactorial disease atrophic rhinitis (AR). Porcine cytomegalovirus (CMV), which is the cause of inclusion body rhinitis, does not cause nasal turbinate atrophy; however, it may damage the nasal mucosa, predisposing it to colonization with one of these bacterial agents. Environmental air pollutants, namely, high ammonia levels (50–100 ppm) and dust (Hamilton *et al.*, 1999), and genetic factors also play a role. *P. multocida* strains A and D produce *Pasteurella multocida* toxin (PMT), which causes progressive nasal turbinate atrophy. *B. bronchiseptica* produces a heat-labile dermonecrotic toxin (DNT) which alone will produce a moderate self-limiting form of the disease in which damaged tissues may regenerate in time (Roop *et al.*, 1987). *H. parasuis* reportedly causes a mild turbinate atrophy (Coward, 1995). Combined infections of toxigenic *P. multocida* and *B. bronchiseptica* produce the most severe form of AR. Typically, two or more infectious organisms are required to produce clinical disease with permanent nasal distortion and turbinate atrophy. Recently, the term ‘nonprogressive atrophic rhinitis’ (NPAR) has been applied to the form caused by *B. bronchiseptica* alone, and the term ‘progressive atrophic rhinitis’ (PAR) to *P. multocida* alone and combined infections

with *B. bronchiseptica* (Register *et al.*, 2012; Brockmeier *et al.*, 2012).

Epizootiology and Transmission The majority of conventional swine herds are infected with *B. bronchiseptica*, and a smaller proportion also have strains A and D of *P. multocida*, the bacterial etiologic agents of atrophic rhinitis.

B. bronchiseptica is spread from pig to pig by aerosol droplets, which probably first occurs with snout-to-snout contact between a sow and a newborn piglet, followed by horizontal spread among littermates; however, transmission can occur at any age. Piglets infected in the first week of life will generally develop more severe lesions than those infected at 4 weeks or later. Those infected at 9 weeks show almost no lesions (Brockmeier *et al.*, 2012). The quantity and quality of passive antibody obtained from the sow also affects the severity of lesions. In SPF herds, the mode of transmission is often the introduction of new carrier animals to the herd. *B. bronchiseptica* can be isolated from many domestic and wild species; however, these strains are usually less pathogenic for swine. This bacterium is commonly cultured from most swine herds and is not always associated with disease.

P. multocida infection in SPF herds typically occurs by the introduction of carrier pigs. Once introduced into a seronegative herd, these bacteria spread quickly by direct contact and aerosols. The pharynx, especially tonsils, and vagina of sows are sources of infection for piglets. Age of first infection inversely affects the severity of lesions; however, older pigs (3–4 months) will still develop lesions, which is in contrast to infection with *B. bronchiseptica* (Brockmeier *et al.*, 2012; Register *et al.*, 2012).

Pathogenesis *B. bronchiseptica* colonizes the ciliated epithelial cells in the nasal epithelium, where it results in loss of cilia. Sequential virulence factors are expressed only at temperatures greater than 77°F (Beier and Gross, 2008). These toxins include DNT, which impairs bone formation; adenylate cyclase toxin (ACT), which is responsible for disruption of innate immune function; tracheal cytotoxin (TCT), which interacts with LPS and is responsible for impaired ciliary function; and others (Horiguchi *et al.*, 1995; Brockmeier *et al.*, 2012). It also produces a toxin that is believed to penetrate the lamina propria and initiate an inflammatory infiltrate and atrophy of the osseous cores (Brockmeier *et al.*, 2012). *B. bronchiseptica* is cytotoxic for alveolar macrophages (Brockmeier and Register, 2000). IgG and IgA are both required for complete clearance of the respiratory tract of *B. bronchiseptica*.

P. multocida has been shown to produce a toxin that results in necrosis of osteoblasts and stimulation of osteoclastic bone resorption in the nasal turbinates, leading to turbinate atrophy (Dominick and Rimler, 1988).

In order for *P. multocida* to colonize, decreased ciliary function or increased mucous is typically required. These

changes are commonly caused by increased ammonia or infection with other agents such as *B. bronchiseptica* and CMV (Register *et al.*, 2012). Experimental evidence has shown that continuous exposure of piglets to 20 ppm ammonia for 2 weeks will markedly exacerbate *P. multocida* colonization in the upper respiratory tract (Hamilton *et al.*, 1998). Once *P. multocida* colonizes, it produces toxins including PMT, which disrupts G-protein and rho-dependent pathways and stimulates mitogenesis resulting in degenerative and hyperplastic changes, especially within the bony turbinates of the nasal cavity (Register *et al.*, 2012). These toxins incite inflammatory cell infiltrates in the lamina propria and cause atrophy of mucosal glands, osteolysis, and replacement of turbinate bones by fibrous connective tissue. PMT may induce turbinate atrophy via alterations in cytokines and soluble factors affecting osteoclast number and or inhibition of osteoblastic bone formation (Gwaltney *et al.*, 1997).

Clinical Signs/Diagnosis The clinical signs of pure *B. bronchiseptica* infection (NPAR) generally appear in nursery pigs less than 4 weeks of age and consist of sneezing, snuffling, and a mucopurulent nasal discharge. In older pigs, these signs are mild or nonexistent. In very young pigs (3–4 days old), a severe bronchopneumonia can result. This form is much more rare than the nasal infections. Infected animals display a mild fever (39.5–40°C), marked ‘whooping’ cough, and dyspnea, with high morbidity and mortality possible if untreated. The organism is frequently isolated from pneumonic lesions of older pigs; however, its role as a pathogen in this setting is questionable (Brockmeier *et al.*, 2012).

The clinical signs of *P. multocida* (PAR) typically begin at 1–3 months of age and consist of sneezing and snuffling, which progresses to more violent sneezing with mucopurulent nasal discharge. In some cases epistaxis is seen. Inflammation of the nasolacrimal duct, which causes occlusion of the duct and subsequent tear staining visible at the medial canthus, frequently occurs. The most characteristic clinical sign is the dorsal and/or lateral deviation of the snout as the pig grows. This is caused by abnormal bone growth due to unequal nasal turbinate atrophy. Brachygnathia superior is the most common form seen and is due to slower bone growth in the upper jaw which gives it an upturned appearance. Significant turbinate atrophy can be present without visible snout abnormalities. In the more severe cases, whole-body growth rate will be decreased, which may be due in part to the possibility that PMT affects the growth of the skeletal system (Brockmeier *et al.*, 2012; Ackermann *et al.*, 1996). Coinfection with *B. bronchiseptica* and *P. multocida* can lead to severe upper respiratory signs including epistaxis, brachygnathia, and lateral deformity of the snout.

PCR assays directed at the gene that encodes for the PMT produced by toxigenic strains of *P. multocida* are

reportedly specific and sensitive when used on nasal and tonsillar swabs and colostrum (Kamp *et al.*, 1996; Lichtensteiger *et al.*, 1996; Levonen *et al.*, 1996). PCR and ELISAs may be used for herd-health monitoring, facility biosecurity, and clinical diagnosis.

Differentials for PAR include other causes of facial deformities, including paranasal abscesses and breed variations. Other diagnoses to rule out for *B. bronchiseptica* include CMV and other causes of sneezing and rhinitis.

Treatment Once lesions are present, there is no cure. AR is a disease best prevented.

Prevention/Control A treatment plan for NPAR and PAR should include a combination of environmental and husbandry improvements followed by a vaccination and antibiotic program tailored to the facility. One approach is to medicate the feed of sows during the last month of gestation to reduce the bacterial load and source of initial exposure for suckling piglets. The oral antibiotics of choice include tilmicosin, sulfonamides, and tetracyclines (Olson and Backstrom, 2000). Piglets can be given weekly or biweekly parenteral injections of oxytetracycline, potentiated sulfonamides, ceftiofur, or penicillin/streptomycin, preferably based on culture and susceptibility, for the first month of life. Medication of feed or water in older weaned pigs at risk for PAR for periods of at least 4–5 weeks will help control clinical signs (Register *et al.*, 2012; Brockmeier *et al.*, 2012).

Vaccines for both *P. multocida* and *B. bronchiseptica* are available as bacterins and toxoids and are considered effective against atrophic rhinitis (Sakano *et al.*, 1997). PMT is an important component of the vaccine to prevent disease. Vaccines are generally given to the sow pre-farrowing, as improved colostrum immunity is considered more important than piglet vaccination.

Practices such as disinfection between groups of animals housed in a facility, adequate air changes to reduce ammonia levels, good temperature control, adequate nutrition and pen space, and control of concurrent diseases and experimental stress will help. *P. multocida* and *B. bronchiseptica* are sensitive to most common disinfectants.

Development and maintenance of an SPF swine facility using cesarian section, medicated early weaning, and segregated early weaning are the most satisfactory methods of prevention. The focus should be on ensuring freedom from toxigenic *P. multocida* since this is the most pathogenic etiologic agent of this multifactorial disease.

It is possible to keep herds free of significant clinical disease through good sanitation, husbandry, and management.

Necropsy *B. bronchiseptica* – lesions in young pigs are catarrhal rhinitis, varying degrees of atrophy of the turbinates (most severe in the ventral scroll of the ventral turbinate) (Fig. 16.17), and a bilateral suppurative

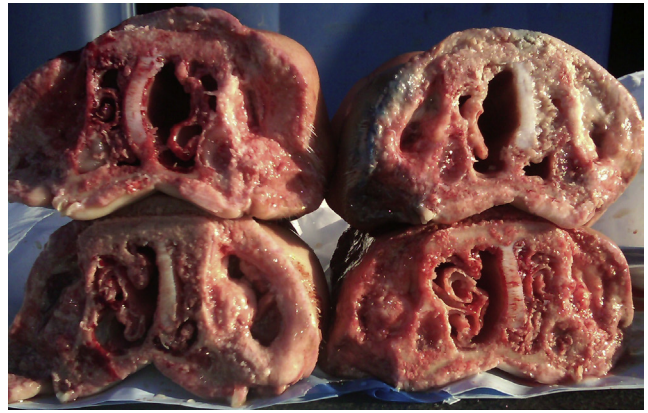

FIGURE 16.17 Atrophic rhinitis. Cross sections of nasal turbinates with loss of turbinate scrolls and deviation of septum. Courtesy of ISU Veterinary Diagnostic Laboratory.

bronchopneumonia involving the apical and cardiac lobes (Brockmeier *et al.*, 2012; Duncan *et al.*, 1966b). Commonly, the turbinate atrophy is subjectively measured at necropsy by visual scoring of a section at the level of the second premolar. Techniques for objective quantification of this atrophy by digital image analysis or digitization and computed tomography have been published (Shryock *et al.*, 1998; Gatlin *et al.*, 1996). In the lungs, there is a severe vasculitis, endothelial cell hyperplasia, hemorrhage, and alveolar and perivascular fibrosis (Duncan *et al.*, 1966a).

P. multocida – there are varying degrees of deformity of the snout and the nasal septum. Distortion and atrophy of the turbinates are most severe in the ventral scroll of the ventral turbinates but can also involve the dorsal scroll of the ventral turbinates, dorsal turbinates, and ethmoid turbinates. Microscopic changes include atrophy of the osseous cores of the turbinates and replacement by fibrous connective tissue, metaplasia of respiratory epithelium to stratified squamous, and inflammatory cell infiltrates in the lamina propria (Register *et al.*, 2012).

Research Complications The toxin produced by severe infections of toxigenic strains of *P. multocida* will induce liver and kidney lesions as well as damage nasal turbinates. *B. bronchiseptica* can induce pneumonic lesions in very young piglets. Therefore, PAR has the potential to affect most chronic research studies.

b. Pasteurellosis

Etiology *P. multocida* is a gram-negative coccobacillus and a facultative anaerobe. Capsular serotypes A, B, and D have been reported in swine, with A being the most common in pneumonic lungs and B causing the most severe disease (septicemic). The role of toxin production by *P. multocida* as a virulence factor in pneumonic pasteurellosis is not clear; however, it has a defined role in causing atrophic rhinitis.

Epizootiology and Transmission *P. multocida* is a common inhabitant of the upper respiratory tract of swine. It can be cultured from the nose and tonsils of healthy pigs from most herds, including SPF herds (Register *et al.*, 2012). Transmission is by direct contact and aerosols.

Pathogenesis *P. multocida* is not usually a primary agent but results in disease when adherence is facilitated by the presence of other agents such as *M. hyopneumoniae*, PRV, hog cholera, PRRSV, parasites, or *B. bronchiseptica*. *P. multocida* is poorly phagocytized by swine alveolar macrophages and the capsule of the organism interferes with uptake by neutrophils (Register *et al.*, 2012).

Clinical Signs/Diagnosis The predominant signs of the acute form of the disease are dyspnea, cough, anorexia, and fever to 41.7°C. Sudden death is not typical. Morbidity and mortality are variable, and typically pigs will lose weight and have a decreased rate of growth. The chronic form of the disease is characterized by intermittent cough and low fever of 39.5–40°C.

The acute form is clinically similar to pleuropneumonia (APP) without the frequency of sudden death; the chronic form is similar to mycoplasmal pneumonia of swine (MPS). *S. enterica* ser. Choleraesuis should also be considered. *Metastrongylus elongatus* and *Ascaris suum* are additional differentials for the chronic form (Coward, 1995; Register *et al.*, 2012).

Treatment Animals showing clinical signs should be treated with a parenteral antibiotic based on susceptibility testing. Alternatively, oxytetracycline, ceftiofur, penicillin, florfenicol, enrofloxacin, or doxycycline dosed in the feed has been shown to be effective at controlling pneumonia caused by *P. multocida* and *M. hyopneumoniae*; however, development of resistance to antibiotics is a concern (Burton *et al.*, 1996; Bousquet *et al.*, 1998; Hormansdorfer and Bauer, 1998).

Prevention/Control It is essential to identify and treat or manage any concurrent pathogens since *P. multocida* is usually the secondary agent. Typically, pasteurization is a complication of *M. hyopneumoniae* infection. High-quality control of environmental air temperature, humidity, and ammonia levels is critical. Vaccination and medicated feed (tetracyclines, tylosin) and water may be beneficial.

Necropsy Gross findings in the lungs are usually confined to the cranioventral aspects of the lobes and include red to gray areas of consolidation, frothy exudate in the trachea, suppurative pleuritis and pericarditis, pleural adhesions, and pulmonary abscesses (Pijoan and Fuentes, 1987; Register *et al.*, 2012). The histopathologic lesions in the lungs are a severe suppurative bronchopneumonia, with interstitial thickening, fibrinosuppurative pleuritis, and well-defined abscesses.

Research Complications Bronchopneumonia-associated accumulation of purulent fluid in airways

will complicate general anesthesia. Severe infections produce fibrinous pleuritis and pericarditis, which will confound most cardiovascular and respiratory system research studies.

c. Pleuropneumonia

Etiology *Actinobacillus pleuropneumoniae* (APP), previously designated as *Haemophilus pleuropneumoniae* or *H. paraaemolyticus*, is the cause of pleuropneumonia of swine. This bacterium is a gram-negative encapsulated coccobacillary rod, which requires nicotinamide adenine dinucleotide (NAD or factor V) for growth. There are currently 15 recognized serotypes (1–15) (Gottschalk, 2012a). Extracellular hemolytic toxins ApxI, ApxII, and ApxIII are some of the more important virulence factors of the *A. pleuropneumoniae* strains that produce them (Reimer *et al.*, 1995; Kamp *et al.*, 1997). All serotypes secrete more than one Apx toxin. There are differences between serotypes as well as differences in geographical prevalence of serotypes (Gottschalk, 2012a).

Epizootiology and Transmission The disease is prevalent worldwide, different countries tend to have a different set of serovars, and multiple serovars can be found in one facility. Transmission is primarily by snout to snout and by aerosol. Recovered swine may become chronic carriers and are a source of transmission within and between herds. Some exposed animals may become subclinical carriers. The spread is likely related to the movement of animals since artificial insemination and embryo transfer are unlikely sources of introduction (Gottschalk, 2012a). Pleuropneumonia is more prevalent in facilities that bring in swine from multiple sources on a regular basis. Typically, in herds where APP is endemic, the piglets are infected in the farrowing pen and a carrier sow is the source. All age groups are affected, and morbidity and mortality are linked to environmental quality, stress, and concurrent infection with other pathogens.

Pathogenesis Inoculation of pigs may result in death in as little as 3 h (Gottschalk, 2012a). Infection with other agents may enhance disease progression of APP. Virulence is also dependent upon serotype specific Apx toxins, LPS, etc. APP binds squamous cells of the tonsil followed by type I pneumocytes of the lower respiratory tract (Chiers *et al.*, 1999; Bosse *et al.*, 2002). Interactions between virulence factors and host immune system, especially macrophages, and neutrophils, along with released cytokines determine pathologic outcome (Cho *et al.*, 2005). Primary damage to the capillary endothelium in alveoli may be the result of endotoxin produced by APP in acute and peracute infections. This results in severe edema and fibrin deposition as well as in thrombosis of capillaries and ischemic necrosis of pulmonary parenchyma (Bertram, 1985). Tissue damage is primarily caused by the host immune response and from lytic

factors released from these cells when they are killed by Apx toxins released from APP, whereas death is primarily due to endotoxic shock from APP LPS (Gottschalk, 2012a).

Clinical Signs/Diagnosis The clinical signs of APP can be categorized into peracute, acute, and chronic forms. The peracute form is characterized by rapid development of fever to 41.7°C, anorexia, and depression. There is increased heart rate and the skin becomes cyanotic beginning at the extremities with terminal open-mouth breathing. Near death, there is foamy blood tinged nasal/oral discharge (Gottschalk, 2012a). Animals may be found dead with no prior signs. In the acute form, pigs have fevers of 40.5–41.1°F, depression, anorexia, reddening or congestion of the skin, severe dyspnea with a marked abdominal component, and sometimes death within 36 h. The chronic form is characterized by variable cough, decreased rate of body-weight gain, and other complications (pleuritis, abortion, endocarditis, arthritis, abscesses). Serotype 2 has been connected with lameness due to necrotizing osteomyelitis and fibrinopurulent arthritis in 8- to 12-week-old pigs (Jensen *et al.*, 1999). All three forms may be found in the same group of animals. A list of diagnoses to rule out includes *A. suis*, MPS, pasteurellosis, PRRS, *S. enterica* ser. Choleraesuis, and combinations of these agents.

Treatment Parenteral antimicrobials, including ceftiofur, penicillin, tetracyclines, and enrofloxacin, can reduce mortality in the acute stage of the disease (Burton *et al.*, 1996). Marked resistance to amoxicillin, oxytetracycline, and metronidazole and others have increased in recent years (Gottschalk, 2012a). Medicating feed and water with an antimicrobial at a low minimum inhibitory concentration (MIC) for members of an affected group that are still eating and drinking may be successful. A combination of parenteral and oral medication often yields the best results, as many affected animals do not eat. If treating via medicated feed, intake needs to be monitored closely for this reason. Injectable antibiotics may be more reliable. Antimicrobial therapy will not eliminate the chronic form or carrier animals from the herd (Gottschalk, 2012a).

Prevention/Control The most satisfactory prevention program is to maintain a closed, APP-free herd through strict isolation. Artificial insemination and embryo transfer can be utilized when introduction of new genetics is required. Alternatively, only known SPF animals that have been validated by serologic testing (ELISA, CF, or PCR) are added. An ELISA utilizing the *A. pleuropneumoniae* ApxII antigen is useful for this purpose (Leiner *et al.*, 1999). In addition, PCR on mixed bacterial cultures from swine tonsils may be more sensitive than culture for detection and is useful in determining serotype (Gram *et al.*, 1996). Segregated early-weaning practices can potentially eliminate APP; however, this

is difficult because this bacterium is an early colonizer (MacInnes and Desrosiers, 1999). Depopulation and restocking with hysterectomy-derived SPF animals is the most satisfactory means of prevention.

Vaccination of seronegative animals prior to introduction with killed whole-cell, cell-free antigens, or subunit type along with maintaining optimal ambient temperature, ventilation, and humidity may reduce morbidity and mortality (Gottschalk, 2012a; Buettner *et al.*, 2011; Oishi *et al.*, 1995). Oral immunization with live or inactivated *A. pleuropneumoniae* serotype 9 has been shown to provide partial clinical protection from aerosol challenge (Hensel *et al.*, 1995). A vaccine strain of *A. pleuropneumoniae* produced by insertional inactivation of the ApxII operon can be delivered live intranasally and provide cross-serovar protection (Prideaux *et al.*, 1999). Subunit vaccines against ApxI/ApxII/ApxIII have been developed and provide protection against all major serotypes (Ramjeet *et al.*, 2008). Additional control measures include good husbandry practices, including use of disinfectants and minimization of stress.

Necropsy The gross findings in pigs with APP are dependent upon time course and include fibrinous pleuritis, pulmonary edema, and the presence of bloody froth or clotted fibrin plugs in the trachea and bronchi. The lungs contain bilateral lesions that are dark red and firm with a predominance of lesions in the dorsal aspects of the caudal lobes, and there may be a bloody nasal discharge (Didier *et al.*, 1984; Bertram, 1985; Nielsen, 1973). Lung lesions are well-defined abscesses and necrotic areas in the lung. Histopathologic lesions are a necrotizing, fibrinous, and hemorrhagic pneumonia that is predominantly lymphocytic and histiocytic, as well as a vasculitis with thrombosis of vessels and lymphatics (Didier *et al.*, 1984; Nielsen, 1973). Cases of bone necrosis with lysis of growth plates and suppurative osteomyelitis have also been associated with APP serotype 2 (Jensen *et al.*, 1999).

Research Complications APP will affect any research involving the respiratory or cardiovascular systems since pleurisy, pneumonia, and pericarditis may result. If animals survive illness, lungs often contain bacterial sequesterae. The mortality associated with the acute form may terminate most studies.

d. *Actinobacillus Suis*

Etiology *Actinobacillus suis* is a gram-negative bacterium in the Pasteurellaceae family.

Epizootiology/Transmission *A. suis* colonizes the upper respiratory tract with many herds infected, all of which do not always show clinical signs.

Pathogenesis *A. suis* produces toxins similar to APP, but less virulent.

Clinical Signs/Diagnosis Animals may present with septicemia, sudden death, dyspnea, cough,

lameness, fever, weakness, wasting, abscesses, neurological signs, abortion, cyanosis, or diffuse hyperemia. There are three forms of disease dependent on the age of animals affected (Yaeger, 1995). The first form is a septicemia affecting suckling and recently weaned piglets where the only signs may be that animals are found dead. The second form is respiratory disease seen in growers and finishers with clinical signs including cough and fever, but they may also be found dead. The third form is an acute septicemia that affects adults with lethargy, anorexia, fever, rhomboid skin lesions, and abortion in pregnant sows.

Diagnosis is based on clinical signs and gross lesions, and confirmed by bacterial culture. Differentials include APP, causes of septicemia, and erysipelas.

Treatment Antibiotics are the treatment of choice and there are no reports of resistance in the literature (Gottschalk, 2012a).

Prevention/Control Vaccines have variable results.

Necropsy Lesions include erysipelas-like lesions, petechiae to ecchymoses in the lung, kidney, heart, liver, spleen, skin, gastrointestinal tract, and petechiae on the ears, abdomen, skin. In acute disease, hemorrhages in multiple organs and serofibrinous exudates in thoracic and abdominal cavities are common. Histological changes include necrotic foci in numerous organs with bacterial thromboemboli. In the form affecting growers and finishers, necrohemorrhagic pneumonia with petechiae in serosal surfaces of abdominal and thoracic organs are seen. Multifocal petechiae and serofibrinous exudates in the thorax and abdomen are seen in the septicemic form that affects adults.

e. Mycoplasmal Pneumonia: Enzootic Pneumonia, Mycoplasmal Pneumonia of Swine

Etiology *M. hyopneumoniae* is a common pathogen that colonizes the ciliated epithelium of the porcine respiratory tract. Mycoplasmas are small (0.2–0.3 µm), lack a cell wall, and are nonmotile, fastidious, gram-negative facultative anaerobes. They belong to the class Mollicutes and are the smallest free-living cells.

Epizootiology and Transmission Enzootic disease is what is most commonly seen. Epizootic infection is uncommon as it affects naive herds. The spread of MPS is primarily by direct contact with respiratory secretions and aerosols from carrier swine. Generally, it is transmitted from infected sows to suckling piglets prior to weaning; however, pigs of all ages are susceptible. It is probably the most common cause of chronic pneumonia in swine, and most conventional herds are affected.

Pathogenesis *M. hyopneumoniae* is not a significant sole cause of disease. *M. hyopneumoniae* adhere to the cilia and apical plasma membrane of the respiratory epithelium in the trachea, bronchi, and bronchioles which results in loss of cilia, ciliostasis, and filling of

alveoli with cell debris and exudate and prevent airway clearance of other pathogens (Ackermann *et al.*, 1991). Organisms further suppress innate and acquired pulmonary immunity allowing other bacteria to proliferate, or they can potentiate disease from some viruses (Thacker and Minion, 2012; Thacker *et al.*, 2001). Humoral immunity has an important role in infection and macrophage activity is altered by *M. hyopneumoniae* (Sarradell *et al.*, 2003). IL-10, IL-12 and IL-18 are increased, but IFN-γ is decreased (Thanawongnuwech *et al.*, 2001; Muneta *et al.*, 2006). Tissue damage is due to inflammatory cell factors, not direct damage from the *M. hyopneumoniae* organism (Thacker and Minion, 2012).

Clinical Signs/Diagnosis There are two disease presentations, epizootic and enzootic. Epizootic disease is characterized by coughing, respiratory distress, pyrexia, and death. Enzootic disease manifests via a dry cough, typically when animals are aroused. They also have decreased appetite and fever with endemic disease (Thacker and Minion, 2012). Although younger pigs may be affected, generally clinical signs are not obvious until pigs are 3–6 months of age. Uncomplicated MPS is generally characterized by a reduced growth rate and a chronic cough precipitated by exercise. In some affected animals, the cough may not be readily evident. Morbidity is typically high and mortality low unless complicated by concurrent viral or bacterial infections, or stress of any form. It plays an important role in PRDC when concurrent infection with PRRSV or PCV2 occurs (Thacker *et al.*, 1999; Thacker and Minion, 2012). In these complicated infections, malaise, anorexia, fever, labored respirations, and possibly death may result (Thacker and Minion, 2012). Bacteria that frequently complicate MPS leading to enzootic pneumonia are clinical differentials and include *P. multocida*, *B. bronchiseptica*, *A. pleuropneumoniae*, *S. enterica* ser. Choleraesuis, and *S. suis* (Bousquet *et al.*, 1998; Cowart, 1995).

Culture is not usually feasible since mycoplasmas and *M. hyopneumoniae*, in particular, are difficult to isolate and grow. IFA or IHC and PCR have all been used in diagnosis (Opriessnig *et al.*, 2004). ELISAs are also currently in use to diagnose *M. hyopneumoniae* (Okada *et al.*, 2005).

Treatment Antimicrobials, including lincomycin, tetracyclines, doxycycline in feed, tiamulin, and several quinolone antibiotics, have been shown to be efficacious in reducing the severity of pneumonia and weight reduction due to MPS (Bousquet *et al.*, 1998). This beneficial effect is generally attributed to controlling complicating bacterial infections. Experimental evidence has shown that doxycycline has greater *in vitro* activity than oxytetracycline against *M. hyopneumoniae*, *A. pleuropneumoniae*, and *P. multocida* (Bousquet *et al.*, 1997).

Prevention/Control The most satisfactory form of prevention is to allow only SPF swine into the facility.

M. hyopneumoniae-free herds may be derived by hysterotomy or hysterectomy, medicated early weaning, or segregated early weaning (Dritz *et al.*, 1996). The success of these techniques should be monitored by a combination of ELISA testing of serum or milk, PCR assay of bronchoalveolar lavage fluids or lung tissue, and examination of lungs at necropsy (Baumeister *et al.*, 1998; Stemke, 1997).

Control of clinical disease in infected animals is best accomplished by providing optimal environmental conditions with respect to ammonia levels, humidity, temperature control, air changes, overcrowding, and reduction of stress. Protective immunity will develop in swine recovered from MPS, and vaccines may help alleviate disease, but not colonization (Thacker *et al.*, 2000; Thacker and Minion, 2012). Maternally derived antibodies have been found to inhibit response to *M. hyopneumoniae* vaccination, and the timing of the dosing to avoid this interference varies from herd to herd (Hodgins *et al.*, 2004).

Necropsy In acute disease, the lungs fail to collapse and there is edema of the lungs. The lungs contain pale gray or dark-red foci of consolidation that are most commonly found in the apical lobes and the cranioventral aspects of the middle, accessory, and caudal lobes (Fig. 16.18). Additionally, there may be catarrhal exudate in the bronchi. In enzootic pneumonia, in which secondary bacteria are present, the lungs are mottled by exudate-distended alveoli and the exudate is mucopurulent (Thacker and Minion, 2012). Microscopic lesions consist of perivascular, peribronchial, and peribronchiolar infiltrations of large numbers of lymphoreticular cells, which in chronic lesions may include lymphoid nodules (Piffer and Ross, 1984; Thacker and Minion, 2012). Additionally, differentiation of cuboidal epithelium to pseudostratified epithelium in bronchioles occurs (Ackermann *et al.*, 1991).

Research Complications Uncomplicated infection with *M. hyopneumoniae* will directly interfere with research involving the respiratory system, and complicated infections may also interfere with cardiovascular studies since pericarditis may result. This agent has been found in purpose-bred animals.

f. Mycoplasmal Polyserositis and arthritis

Etiology *Mycoplasma hyorhinis* is probably the easiest of the porcine mycoplasmas to isolate, is a common contaminant of cell culture lines, and is ubiquitous in the swine population. This pathogen has been diagnosed in research swine via PCR.

Epizootiology and Transmission This organism is harbored in the respiratory tract of carrier swine, often without clinical disease. The most likely first exposure for baby pigs is from aerosolization or direct contact with nasal secretions from the sow prior to weaning. The

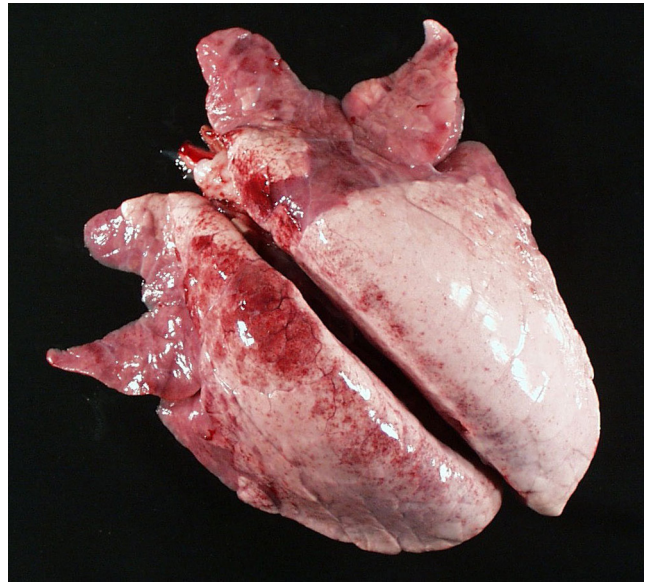


FIGURE 16.18 *M. hyopneumoniae*. Consolidated and red apical lung lobes. Courtesy of ISU Veterinary Diagnostic Laboratory.

organism will spread rapidly through group-housed pigs and typically will not cause clinical disease unless the animals are stressed. Stress will induce septicemia and its subsequent lesions (Thacker and Minion, 2012).

Pathogenesis The organism adheres to cilia similar to *M. hyopneumoniae* and is considered normal flora of the respiratory tract. The mechanisms that the organism uses to induce systemic disease is still not known, but once the organism gains entry to other sites, it causes polyserositis and polyarthritis in pigs less than 8 weeks old. In older pigs (3–6 months old), only arthritis is caused (Potgieter *et al.*, 1972; Potgieter and Ross, 1972).

Clinical Signs/Diagnosis The age group most commonly affected is 3–10 weeks of age. Clinical signs typically begin about 1 week after some form of stress or initial exposure to the etiologic agent. The acute signs are lethargy, anorexia, labored respirations, arched back with tucked-up abdomen, lameness, and slight fever and swollen joints. These signs abate in about 2 weeks except that the lameness with swollen joints may persist for several months. Experimental *M. hyorhinis* intranasal inoculation has been shown to cause eustachitis and occasionally otitis media (Morita *et al.*, 1998, 1999). *H. parasuis*, *S. suis*, and *M. hyosynoviae* should be ruled out for this clinical presentation.

Treatment Prophylactic treatment of the entire herd by medicating food or water with lincomycin or tylosin may be beneficial. Antimicrobial treatment of clinically affected swine is unrewarding (Thacker and Minion, 2012; Cowart, 1995).

Prevention/Control Eliminating stress of any type can best prevent clinical outbreaks of disease.

This includes eliminating other diseases, controlling temperature and humidity fluctuations, and avoiding shipping and invasive research protocols. Concurrent infection with *M. hyorhinis* and PRRSV has been found to cause severe pulmonary lesions with respiratory distress (Kawashima *et al.*, 1996) and underscores the need to eliminate other pathogens.

Necropsy Acute lesions include serofibrinous or fibrinopurulent pleuritis, pericarditis, and peritonitis, as well as serofibrinous arthritis with increased synovial fluid and swollen reddish yellow synovial membranes (Ross *et al.*, 1971). The joints most frequently involved are the stifle joints, but the tibiotarsal, cubital, coxofemoral, and shoulder joints may also be involved (Ross *et al.*, 1971). In chronic cases, pannus, erosions of articular cartilage, and fibrous adhesions may be present (Thacker and Minion, 2012).

Research Complications Although mortality is low and morbidity typically less than 25%, clinical disease will confound cardiovascular studies and surgical models because it causes pericarditis, pleuritis, and peritonitis. Orthopedic studies may be compromised by arthritis.

g. Inclusion Body Rhinitis

Etiology Inclusion body rhinitis (IBR) is caused by porcine cytomegalovirus (PCMV) and is found throughout the world. The causative agent is a member of the subfamily Betaherpesvirinae, genus *Proboscivirus* that produces cytomegaly with hallmark basophilic intranuclear inclusions in cytomegalic cells of nasal mucosa. The agent is species-specific and is able to induce latent infection, with shedding of virus occurring even in the presence of circulating antibodies.

Epizootiology and Transmission The virus can be recovered from nasal and ocular secretions, urine, fluids associated with pregnancy, and male reproductive organs. The virus can also be transmitted transplacentally. Dissemination of the agent most commonly occurs via nasal secretions and urine. Viral excretion is highest at 3–8 weeks of age; however, reactivation of excretion can occur when animals are stressed. Lung macrophages are the reservoir of infection.

Pathogenesis The virus enters the body through the mucosa, where it replicates inside the epithelial cells of the mucosal, Harderian, and lacrimal glands. Subsequent viremia results in seeding of mucosal glands, renal tubular epithelium, hepatocytes, and duodenal epithelium, and in neonates or fetal pigs, the reticuloendothelial cells and capillary endothelium (Mettenleiter *et al.*, 2012; Edington *et al.*, 1976). The virus inhibits T-cell function and thus modifies the host defense mechanisms (Kelsey *et al.*, 1977).

Clinical Signs/Diagnosis This disease is usually subclinical in pigs more than 3 weeks of age and may

even be totally inapparent in young animals if good management practices are being followed. The clinical sequelae typically associated with this disease include unexpected fetal and piglet death, runting, rhinitis, conjunctival discharge, pneumonia, sometimes neurological signs, and poor weight gain in young pigs (Edington *et al.*, 1977). Some piglets may be born anemic, with edema noted around the jaw and tarsal joints. Adult animals that are exposed to this agent for the first time may develop mild anorexia and lethargy. Coinfection with PCMV and PCV2 exacerbates PRDC (Hansen *et al.*, 2010).

The presence of this disease can be confirmed using a serum ELISA. Virus isolation or PCR can be done on nasal secretions or scrapings, or on whole blood. The virus can be isolated from the nasal mucosa, lung, and kidney. Differential diagnoses include PPV, PCV2, PRRSV, CSF, PRV, and enterovirus.

Prevention/Control Supportive therapy to prevent secondary bacterial infections is important in the face of a viral disease outbreak. Caution should always be taken when introducing new animals into an established grouping as new animals may expose susceptible animals or may stress existing groupings to stimulate resurgence of a latent infection.

Necropsy Gross lesions in piglets are found in the nasal passages, where there is serous rhinitis in early stages of the disease and purulent exudate in older lesions (Thomson, 1988). There may also be sinusitis, and if the disease becomes systemic, there are petechial hemorrhages and edema in the lungs, lymph nodes, subcutaneous tissues, along with pericardial and pleural effusions. The kidneys may contain petechiae, or may be dark purple (Mettenleiter *et al.*, 2012). Histologic findings characteristic for this disease are the presence of large basophilic intranuclear inclusions in the epithelial cells in both the mucosa and the mucosal glands (Thomson, 1988; Edington *et al.*, 1976). If disease is systemic, there may be pneumonia and foci of necrosis in the liver, kidney, CNS, and adrenals, with inclusions in capillary endothelium and sinusoidal cells throughout the body (Thomson, 1988).

Research Complications The virus may be passed to humans in porcine to human xenotransplantation, the consequences of which are currently unknown (Mueller *et al.*, 2004).

h. Swine Influenza

Etiology Swine influenza, first identified in 1918, is caused by a type A influenza virus. The agent is distributed worldwide, and antibodies to the virus are found in about 45% of the sampled pig populations. Influenza A viruses belong to the family of RNA viruses, *Orthomyxoviridae*. The type A viruses are further classified based on the glycoprotein spikes that extend from

the viral particle (hemagglutinin [H] and neuraminidase [N]). The antigenic characteristics of these spikes provide the basis for dividing these viruses into subtypes. Antigenic comparison of the H1N1 swine viruses has shown, in contrast to human strains, that there has been little antigenic variation over the last 50 years (Sheerar *et al.*, 1989). This could be attributed to the fact that the virus is able to propagate in an ever-present population of nonimmune pigs. Strains H3N2 and H1N2 are also prevalent in swine and they may also be infected by H3N3, H4N6, H5N1, H5N2, and H9N2 (Van Reeth *et al.*, 2012).

Epizootiology and Transmission Swine influenza typically appears as a result of new animals entering the herd. Outbreaks rapidly spread through all animals within a group. Once the virus gains purchase within a population of swine, the disease is likely to recur unless the grouping is totally depopulated. Distribution of different subtypes/genotypes varies widely and is dependent on geographical location.

The primary route of transmission is via direct contact with the viral particles present within nasal secretions. There is no evidence that supports a carrier state, and the widespread occurrence and persistence of the virus is attributed to its continued passage to young susceptible animals or animals that have lost protective antibody titers.

The swine influenza viruses (SIVs) have a very wide host range, including humans and birds, and interspecies transmission readily occurs. It can cause acute respiratory disease in humans. It also infects wild boar, domestic turkeys, and free-ranging waterfowl (Van Reeth *et al.*, 2012).

Pathogenesis The virus enters via the respiratory epithelium. The viral hemagglutinin attaches to host cells via sialic acid containing receptors. Viral replication occurs in both upper and lower respiratory tracts. Virus positive cells are only within the respiratory tract and consist of bronchial and bronchiolar epithelial cells (Jung *et al.*, 2002; De Vleeschauwer *et al.*, 2009). Neutrophils subsequently infiltrate the lungs. Subclinical infection versus disease is determined by viral load and cytokines released. Disease and inflammation are precipitated by increased IFN- α , IFN- γ , tumor necrosis factor (TNF)- α , and IL-1, IL-6, and IL-12 (Van Reeth *et al.*, 1998, 2002; Kim *et al.*, 2009a; Barbe *et al.*, 2011). There may be secondary infection by *H. parasuis*, *P. multocida*, *A. pleuropneumoniae*, *M. hyopneumoniae*, or *S. suis*-2.

Clinical Signs/Diagnosis Animals appear very ill with anorexia, labored open-mouthed breathing, and a strong reluctance to move. The animals have fever, rhinitis, and nasal discharge, and during recovery, will cough. Despite the apparently severe clinical signs, the animals typically recover rapidly within 5–7 days of developing clinical signs. Morbidity is nearly 100% with less than

1% mortality. Clinical signs are similar between common swine serotypes (H1N1, H1N2, H3N2) (Van Reeth *et al.*, 2012).

A definitive diagnosis can be made through isolation of the virus by swabbing nasal mucosa, or virus isolation from bronchoalveolar lavage, nasal, tonsil, or oropharyngeal swabs. Diagnosing weanling pigs via serology is difficult as maternal antibody persists up to 4 months, yet may still be infected and shed viral particles. The main differentials include bacterial pneumonias, porcine respiratory coronavirus, *M. hyopneumoniae*, and PRRSV.

Treatment Although not field-tested, amantadine has been shown to reduce the febrile response and the shedding of virus in experimentally infected pigs. This drug is used for treatment and prevention of influenza in humans. Proper nursing care, avoidance of stress, and antibiotics to prevent secondary bacterial infections are recommended.

Prevention/Control Currently, there are several vaccines licensed for use in the US and Europe. Other means of control include preventing influx of animals from unknown sources and preventing contact with birds and infected humans. PPE use by personnel in contact with pigs is quite important with this disease.

Necropsy There is fibrinous to mucopurulent exudate in nasal passages, trachea, bronchi, and bronchioles (Thomson, 1988), and sharply demarcated dark-red to purple firm foci of consolidation in apical and cardiac lobes of the lung along with interlobular edema (Van Reeth *et al.*, 2012). Microscopic lesions consist of a necrotizing bronchitis, bronchiolitis, and bronchio-interstitial pneumonia, with airways filled with cell debris and neutrophils (Thomson, 1988).

Research Complications SIV is primarily a pulmonary disease and may affect lung studies. It is a zoonotic disease as well as a reverse zoonosis in that personnel may infect research animals if they are carrying influenza virus.

i. Verminous Pneumonia (Verminous Bronchitis)

Etiology Natural infections of swine with *Metastrongylus* spp. include one or more of *M. salmi*, *M. pudendotectus*, or *M. elongates apri*, with the latter being the most common. Adults are white, with males averaging 25 mm in length and females, 50 mm. Their eggs are oval, 40–50 μ m in diameter, and larvated.

Adult *Ascaris suum* (ascarids) are pinkish-yellow nematodes. Males are 15–25 cm in length and females, 20–40 cm. The eggs are oval, 40–60 μ m in width and 50–80 μ m in length, and have a rough or mammilated appearance (Greve, 2012). Both *Metastrongylus* spp. and *A. suum* may cause verminous bronchitis in pigs.

Epizootiology and Transmission *M. elongatus* (lungworm) has an indirect life cycle and requires an earthworm as an intermediate host. Eggs are coughed

up from the lungs, swallowed, and excreted in the feces. Swine eat an earthworm that contains infective larvae, which then migrate to the mesenteric lymph nodes and on to the right heart and lungs. They mature in the bronchi and bronchioles of the diaphragmatic lung lobes. The prepatent period is 28 days.

Ascarids have a direct life cycle and thus can be a problem even in indoor facilities. Ingested larvated eggs hatch in the small intestine and invade the wall of the cecum and colon. The larvae then migrate through the liver and lungs (Murrell *et al.*, 1997). In the lungs, the larvae enter the alveoli and migrate up the airways. They are coughed up and swallowed and then return to the small intestine where they molt into adults. The prepatent period ranges from 40 to 53 days. The presence and migration of these two parasites exacerbate the clinical signs and disease of other viral and bacterial pneumonias of swine.

Pathogenesis *M. elongatus* larvae migrate through the lung parenchyma, causing alveolar hemorrhage followed by inflammation and consolidation of the lungs. Maturing larvae migrate to the bronchioles and bronchi as they mature into adults, where they copulate and lay eggs which produce more irritation and inflammation (Jones and Hunt, 1983).

Migrating *A. suum* create liver lesions, which are seen grossly as white spots that peak at about 1 week post infection and heal in 3–8 weeks (Roepstorff, 1998). The pathogenesis of the lung lesions is similar to that of *M. elongatus*; however, the larvae are coughed up and then swallowed and mature into adults in the small intestine.

Clinical Signs/Diagnosis The clinical signs consist of dyspnea and decreased weight gain. Icterus can be seen if ascarids migrate into the common bile duct. An ELISA for anti-*A. suum* IgG is more sensitive and probably provides a more realistic assessment of the prevalence than fecal examination for oocysts (Roepstorff, 1998). Differentials should include all bacterial, mycoplasmal, and viral causes of pneumonia in swine.

Treatment *M. elongatus* is susceptible to doramectin, ivermectin, benzimidazoles, and levamisole (Logan *et al.*, 1996; Yazwinski *et al.*, 1997; Cowart, 1995). Antibiotic therapy may be indicated to treat primary or secondary bacterial pneumonia in swine showing respiratory signs.

A. suum is susceptible to numerous anthelmintics, including avermectins, ivermectin, benzimidazoles, pyrantel, piperazine, levamisole, dichlorvos, and hygromycin B (Logan *et al.*, 1996; Stewart *et al.*, 1996; Saeki *et al.*, 1997). Doramectin SQ has persistent activity of at least 7 days against a challenge with embryonated *A. suum* eggs (Lichtensteiger *et al.*, 1999).

Prevention/Control In indoor research facilities, the life cycles of both these parasites can be broken by frequent (minimize animal contact with infected feces) and thorough sanitation procedures (steam will kill the

eggs) (Stewart, 2007). Neopredisan (*p*-chloro-*m*-cresol) disinfectant has been shown to be a very efficacious ovi-cide and larvicide for *A. suum* (Mielke and Hiepe, 1998). This coupled with a strategic or continuous anthelmintic treatment program should eliminate clinical disease. If outdoor pens are utilized, housing on concrete or bringing the animals indoors to prevent access to earthworms and to facilitate sanitation and anthelmintic treatment is worthwhile. Feral *Sus scrofa* in the US and EU have *A. suum* and *Metastrongylus* spp. and are a potential reservoir in areas where contact is possible (Gipson *et al.*, 1999; Henne *et al.*, 1978).

Necropsy Adult *M. elongatus* can be found in the trachea, bronchi, or bronchioles, and larvae may be found in the lung parenchyma at necropsy (Jones and Hunt, 1983). Characteristically, mucoid plugs containing adults and eggs obstruct the bronchioles in the diaphragmatic lobes, producing atelectasis (Greve, 2012).

Adult *A. suum* are found in the small intestine, including the common bile duct, and white focal hepatic lesions (scarring) indicative of ascarid migration and sometimes called ‘milk spots’ are typically found at necropsy (Wagner and Polley, 1997). Larval migration through the lungs produces hemorrhage, inflammation, and emphysema, and may lead to secondary bacterial pneumonia (Greve, 2012).

Research Complications If untreated, these infections will damage the lungs, liver, and other tissues during migration. *A. suum* is a public health concern because it can cause visceral larval migrans. Appropriate PPE should be worn when staff work with potentially infected pigs (Stewart, 2007).

3. Gastrointestinal Diseases

Young swine commonly develop diarrhea associated with shipping stress, changes in diet, primary or mixed infection with a variety of enteric pathogens, or the peri-operative use of antibiotics that may upset the balance of normal gut microbiota. The morbidity and mortality associated with enteritis make clinically affected pigs unsuitable for experimental use, and residual lesions in recovering animals may interfere with experimental assessment of the gastrointestinal tract. The following is a summary of the infectious diarrheas that may be encountered when young swine are managed within research facilities (Table 16.3).

a. Swine Dysentery

Swine dysentery is a severe mucohemorrhagic diarrhea of pigs of postweaning age.

Etiology *B. hyodysenteriae*, a gram-negative anaerobic spirochete, is the primary etiologic agent of swine dysentery and is one of six *Brachyspira* spp. known to infect swine (Boye *et al.*, 1998; Stanton, 2006). Because disease is less severe when gnotobiotic pigs are experimentally

TABLE 16.3 Common Infectious Causes of Enteritis in Swine (Newborn to Postweaning Age)^a

Disease	Clinical signs	Age	Etiology	Gross lesions	Histological signs	Diagnosis
Colibacillosis	Acute death, clear watery to white–yellow or hemorrhagic, diarrhea	Newborn to postweaning	<i>Escherichia coli</i> ETEC, EPEC (AEEC), EHEC	Nonspecific dilation and congestion of small intestine, blood-tinged contents	Congestion, hemorrhage, acute inflammation, villous atrophy, adherent bacteria	Culture, serotyping
Swine dysentery	Watery, mucoid, and hemorrhagic diarrhea, rarely acute deaths	1 week and older	<i>Serpulina hyodysenteriae</i>	Large bowel edema, hyperemia, mucofibrinous exudate on mucosa	Mucosal edema, mucofibrinous enteritis with superficial erosions, hemorrhage	Culture, Warthin–Starry-positive spirochetes in colonic crypts, PCR
Proliferative enteropathy	Acute death, anorexia, loose watery to hemorrhagic diarrhea	Postweaning	<i>Lawsonia intracellularis</i>	Gross thickening of distal ileum, cecocolic junction; cecum, edema, exudate	Hyperplasia of glands and epithelium, intracellular bacteria on EM	In situ hybridization, tissue culture isolation, electron microscopy
Clostridial enteritis	Acute death, pink mucoid to severe hemorrhagic diarrhea	Newborn to postweaning	<i>Clostridium perfringens</i>	Severe hemorrhagic involvement of small intestine, gas, bloody fluid in abdomen	Necrotic villi, adherent gram-positive bacilli, profuse hemorrhage	Culture, toxin assays on cecal contents, Gram stain of mucosal smears
Salmonella enterocolitis	Watery, yellow diarrhea with fever, anorexia, depression	Postweaning	<i>Salmonella typhimurium</i> , <i>S. choleraesuis</i>	Focal or diffuse necrotic typhlocolitis, enlarged mesenteric lymph nodes, other organ involvement	Necrosis of enterocytes, inflammatory infiltrates, thrombi, lymphoid atrophy or hyperplasia	Culture, clinical signs, necropsy lesions
Transmissible gastroenteritis	Vomiting, severe diarrhea, high mortality	Any age	TGE virus	Thin-walled small intestine distended with yellow fluid	Villous atrophy ulceration of Peyer's patch dome epithelium	Rising serum titers, viral isolation, PCR
Rotavirus	Profuse watery, white/yellow diarrhea, fever and vomiting	Most severe within days of birth	Porcine rotavirus	Nonspecific dilation of small and large intestine with yellow to gray watery fluid	Villous atrophy	Rising serum titers, viral isolation, PCR, <i>in situ</i> hybridization
Balantidiasis	Asymptomatic to severe ulcerative enterocolitis	Any age	<i>Balantidium coli</i>	Variable, secondary to other primary diseases	Ciliated trophozoites, flask-shaped ulcers	Histology, fecal direct smears
Giardiasis	Asymptomatic to anorexia with diarrhea	Any age	<i>Giardia intestinalis</i>	None to nonspecific enteritis	None to nonspecific enteritis, adherent comma-shaped	Histology, fecal direct smears
Coccidiosis	Asymptomatic to severe diarrhea	1–2 weeks of age	<i>Isospora suis</i>	None, severe cases may have fibrinonecrotic membrane in jejunum and ileum	Villous atrophy, villous fusion, hyperplasia of crypts, necrosis	Fecal flotation
Whipworms	Asymptomatic to severe mucoid or hemorrhagic diarrhea with mortality	Postweaning	<i>Trichuris suis</i>	Edema, nodules containing exudate, fibrinonecrotic membrane, hemorrhage, anemia, adult worms attached to mucosa	Migrating larva in submucosa, adult worms attached to mucosa	Fecal flotation, necropsy
Small intestinal threadworms	Asymptomatic to severe diarrhea with mortality	Nursing pigs	<i>Strongyloides ransomi</i>	Nonspecific, presence of adult worms in small intestine	Encysted larvae	Fecal flotation, necropsy

^aFox (2002).

infected, other microorganisms normally found in the lower bowel are believed to contribute to lesion development. Additionally, nutritional factors are important; diets rich in rapidly fermentable carbohydrates may exacerbate clinical signs whereas highly digestible diets, or those high in inulin are protective against disease (Pluske *et al.*, 1996; Hansen *et al.*, 2010; Thomsen *et al.*, 2007).

Epizootiology and Transmission In natural outbreaks of swine dysentery, *B. hyodysenteriae* is transmitted by fecal–oral contact, either by direct contact between naive and infected pigs or by use of contaminated housing, equipment, or clothing. The organism can survive up to 60 days in moist ground or feces but is readily eliminated by disinfection in the absence of organic material. Recovered pigs may continue to shed *B. hyodysenteriae* in their feces.

Pathogenesis *B. hyodysenteriae* is very efficient at penetrating mucus and attaching to the colonic epithelium. These organisms do not invade the gut wall below the lamina propria. The organism produces a hemolysin that is cytotoxic and an endotoxin. Diarrhea caused by *B. hyodysenteriae* is the result of colonic malabsorption from failure of colonic epithelial cells to transport sodium and chloride from the lumen to the blood (Argenzio *et al.*, 1980; Schmall *et al.*, 1983). The mechanism of diarrhea is therefore very different from that of *Salmonella*, *Shigella*, and *E. coli* (Schmall *et al.*, 1983). Dehydration and fluid loss are due to the failure to reabsorb endogenous secretions (Hampson, 2012).

Clinical Signs/Diagnosis Rarely, swine dysentery may cause peracute death without premonitory signs. More commonly, severe diarrhea and fever with accompanying dehydration, weight loss, and weakness develop over several days. Diarrhea of acute onset is usually watery with large amounts of mucus accompanied by flecks of blood and white, mucofibrinous exudate. Pigs with chronic diarrhea may pass red to black soft stools that contain mucus. Nursing pigs are typically not affected but may develop catarrhal enteritis without hemorrhage. Mixed infections with *Yersinia pseudotuberculosis*, *S. enterica* ser. Typhimurium, or *B. pilosicoli* commonly result in more extensive lesions, affecting the cecum as well as the colon, and may prolong recovery time from swine dysentery (Thomson, 1988).

Diagnosis of *B. hyodysenteriae* infection can be confirmed by culture or PCR (Atyeo *et al.*, 1998). Hemorrhagic diarrhea in piglets that are newborn to several weeks of age could also be caused by *Clostridium perfringens*. In older pigs, other causes of hemorrhagic enteritis include *Salmonella*, *L. intracellularis*, and *Trichuris suis*.

Treatment If indicated, therapy should consist of fluid and electrolyte replacement along with antibiotics. Carbadox, tiamulin, and lincomycin have all been

reported to be effective in treatment and/or prevention of swine dysentery.

Prevention/Control Swine dysentery is usually introduced to a facility by the purchase of an asymptomatic carrier pig. Wild rodents are also reservoirs. Pigs should be purchased from herds SPF for *B. hyodysenteriae* or alternatively, from herds in which drugs or vaccines that may only suppress infection are not used.

In the biomedical research setting, pigs affected with swine dysentery should be quarantined and treated or euthanized. Sanitation of the facility and associated equipment along with review of rodent control and vendor health status should be adequate to avoid reintroduction. Valuable pigs can be segregated by health status and treated with antibiotics. Nursing pigs are protected by colostrum from previously infected sows and can be a source of *Brachyspira*-free pigs if weaned early and housed in a clean facility.

Necropsy Pigs that have died from swine dysentery are dehydrated and may have rough or fecal-stained coats. The gross lesions vary in distribution but are confined to the large bowel (Hughes *et al.*, 1977). Early lesions include reddening and edema of the gut wall, mucosa, and mesenteric lymph nodes, as well as a fibrinous, blood-flecked membrane covering the mucosa (Hampson, 2012). Older lesions are less edematous, but there is a thick mucosal pseudomembrane composed of fibrin, mucus, and blood (Hampson, 2012). Microscopic lesions consist of elongated colonic crypts, goblet cell hyperplasia, and necrosis of sheets of epithelial cells resulting in damage to exposed capillaries and exudation of fluid, fibrin, blood, and inflammatory cells from the lamina propria (Hughes *et al.*, 1977). Large numbers of spirochetes can be found in the crypts as well as in the lumen.

Research Complications The morbidity and mortality associated with swine dysentery make clinically affected pigs unsuitable for experimental use.

b. *Brachyspira Pilosicoli*: Porcine Intestinal/Colonic Spirochetosis

Brachyspira pilosicoli is a relatively newly recognized species of pathogenic intestinal spirochete that causes porcine colonic spirochetosis, a nonfatal diarrheal disease that affects pigs during the growing and finishing stages (Duhamel *et al.*, 1998).

Etiology *B. pilosicoli* was first identified in 1993 as *Anguillina coli* as a cause of porcine diarrhea and loss of condition (Lee *et al.*, 1993).

Epizootiology/Transmission *B. pilosicoli* can be found in contaminated water and colonizes chickens, wild ducks, and immunocompromised humans. Transmission is fecal–oral.

Pathogenesis Organisms attach only to mature apical enterocytes and not immature cells within crypts

(Trott *et al.*, 1996). Similar to *B. hyodysenteriae*, disease may be influenced by dietary factors. Non-pelleted diets result in reduced prevalence of disease, whereas pelleted diets increase the risk of colonization (Steger *et al.*, 2001; Lindecrona *et al.*, 2004).

Clinical Signs/Diagnosis Clinical signs develop soon after weaning or when swine are placed on a new diet (Duhamel *et al.*, 1998). Signs include loose stool in finishers, but younger animals often have watery green to brown mucoid diarrhea with flecks of blood (Duhamel *et al.*, 1998). Concurrent diseases that may lead to exacerbation include swine dysentery, salmonellosis, proliferative enteropathy, or PCV2 infection (Duhamel *et al.*, 1998).

Diagnosis is usually via specific PCR tests in conjunction with clinical signs consistent with the disease. Disease associated with *B. pilosicoli* may be concurrent with disease from *B. hyodysenteriae*, salmonellosis, *L. intracellularis*, *E. coli*, *Yersinia* spp., *T. suis*, PCV2, or nonspecific colitis which are all also differentials for *B. pilosicoli* (Duhamel *et al.*, 1998).

Treatment/Prevention/Control Treatment includes antimicrobials, decreasing stress within the animal's environment, and change of diet. Vaccines may ameliorate disease symptoms, but do not prevent infection.

Necropsy Gross lesions are limited to the cecum and colon, which are flaccid and fluid-filled, with enlarged associated lymph nodes. Serosal edema, congestion of the mucosa with erosions, and necrotic areas are common. Histological changes include dilated elongated crypts distended with mucus, cellular debris, degenerate inflammatory cells, and occasional Brachyspiral organisms (Jensen *et al.*, 2000). Organisms may also be found within goblet cells. The lamina propria is commonly distended with neutrophils and lymphocytes.

Research Complications This organism may colonize immunocompromised humans, so PPE is important when there is contact with pigs.

c. Proliferative Enteropathy

Based on the excessively proliferative lesions found at necropsy in the terminal ileum, proliferative enteropathy (PE) of the pig has historically been referred to as porcine intestinal adenomatosis, terminal or regional ileitis, intestinal adenoma, and porcine proliferative ileitis. Proliferative enteropathy affects multiple species (Cooper and Gebhart, 1998).

Etiology PE is associated with the presence of abundant intracellular organisms in enterocytes. The organisms are difficult to work with because they can be grown only in tissue culture. Koch's postulates have been fulfilled using a pure culture of the microaerophilic bacterium, *L. intracellularis* (Lawson *et al.*, 1993; McOrist *et al.*, 1995a). Variations in infectivity when attempting cross-species transmission suggest that two biovars exist

(Jasni *et al.*, 1994; Murakata *et al.*, 2008; McOrist and Gebhart, 2012).

Epizootiology and Transmission PE is present worldwide and affects many species, including the pig, hamster, dog, fox, ferret, horse, rat, and rabbit. Consequently, other animals, such as rodents, could be the sources of new infection. *Lawsonia* is shed in feces, and transmission is by fecal-oral contact. In endemic areas, 15–30% of the herds are estimated to be affected with a 5–20% infection rate within a herd. There is risk of environmental contamination, as *L. intracellularis* can remain viable in feces for at least 2 weeks (Collins *et al.*, 2000). *L. intracellularis* has also been reported in wild pigs which may also serve as a source of infection (Tomanova *et al.*, 2002).

Pathogenesis *L. intracellularis* is an obligate intracellular organism. Animals become infected as a result of consuming fecal-contaminated material (McOrist *et al.*, 1995a). *L. intracellularis* is endocytosed by cells via a vacuole which rapidly breaks down, liberating organisms which multiply freely within the cytoplasm (McOrist and Gebhart, 2012). The mechanism resulting in cells continuing to divide without maturing is currently unknown (McOrist and Gebhart, 2012). The organisms enter the immature, proliferating crypt epithelial cells and multiply within the apical cytoplasm with no discernible inflammatory reaction, and in fact, the number of CD8(+) T cells decreases within 14 days of infection (Macintyre *et al.*, 2003). The infected crypt cells fail to mature and are not shed, so the crypts become elongated and tortuous resulting in decreased nutrient absorption (McOrist and Gebhart, 2012). Pathogenesis for acute hemorrhagic proliferative enteropathy has not been fully elucidated.

Clinical Signs/Diagnosis Clinical disease attributed to PE is most often observed in postweaned pigs between 6 and 20 weeks of age. Clinical signs range from none to marked dullness, anorexia, and diarrhea. Diarrhea is typically moderate with loose to watery stools of normal color. Failure to grow at a normal rate may be the only clinical sign that is detectable *ante mortem*. Young adults may present with more severe hemorrhagic enteritis, acute death, or anemia secondary to acute hemorrhagic diarrhea, or a more chronic form associated with passage of black tarry feces. Pregnant animals may abort.

Diagnosis is achieved via fecal PCR or use of a specific antibody incorporated into a fecal immunoassay, serological diagnosis via ELISA, or demonstration of intracellular organisms in histological section using immunohistochemistry (McOrist and Gebhart, 2012). Differential diagnoses depend on the form of the disease presented, but include rotavirus, coronavirus, *S. enterica* ser. Typhimurium, *B. hyodysenteriae*, PCVAD, nutritional causes, and esophogastric ulceration.

Treatment Proliferative enteropathy can be self-limiting with spontaneous improvement after several weeks. Antibiotics are commonly used to control clinical signs. Treatment of this disease is problematic because of the lack of *in vivo* or *in vitro* data on antibiotic sensitivities of *Lawsonia*. In tissue culture, penicillin, erythromycin, difloxacin, virginiamycin, and chlortetracycline were the most effective antibiotics (McOrist *et al.*, 1995b). Tylosin phosphate can be effective for prevention and for treatment of PE (McOrist *et al.*, 1997).

Prevention/Control Swine should be purchased from a vendor with a herd-health history that is free of PE. Newly introduced pigs should be quarantined and housed separately to avoid contact with feces of other swine that may be shedding *Lawsonia*.

An oral, attenuated live vaccine is commercially available, provides protective immunity, and is effective at controlling disease and provides protective immunity (Kroll *et al.*, 2004). Clinically affected pigs should be quarantined and treated or euthanized, based on severity of disease and the intended use of the animal. Control efforts should include sanitation of equipment and the housing area, review of rodent control, and treatment with antibiotics of pigs at risk of clinical disease (McOrist *et al.*, 1996). Absence of clinical signs does not guarantee freedom from disease or infection with *L. intracellularis*.

Necropsy The gross lesions of PE are found in the ileum, cecum, and the most proximal one-third of the spiral colon and consist of a markedly thickened gut wall and mucosa containing multiple transverse or longitudinal folds (Fig. 16.19) (McOrist and Gebhart, 2012). In mild cases, the distal most 10 cm of the ileum is the most likely site of infection and should be examined carefully (McOrist and Gebhart, 2012). Microscopic lesions consist of markedly elongated branching crypts lined by

immature epithelial cells and lack goblet cells (Fig. 16.20). Varying numbers of silver-staining organisms that also exhibit acid-fast staining with a modified Ziehl–Neelsen stain are found free in the apical cytoplasm of the lining cells (Fig. 16.21) (McOrist *et al.*, 1995a). Inflammatory response in the lamina propria may be minimal. In more severe cases, lesions may include coagulative necrotic enteritis with caseous mats adherent to the jejunal/ileal mucosa (McOrist and Gebhart, 2012).

The gross lesions of the hemorrhagic form of the disease are confined to the ileum and rarely involve the large bowel. These consist of a thickened, reddened mucosa that does not contain erosions but may be covered by a fibrinous membrane, and the lumen may contain

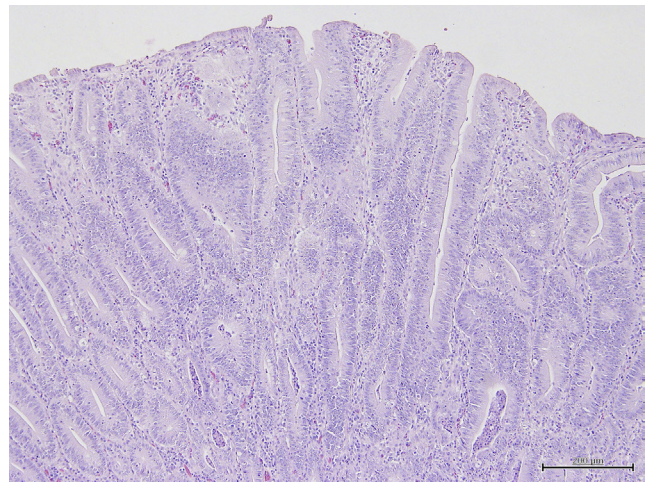


FIGURE 16.20 *Lawsonia intracellularis*, proliferative enteritis. Glands of the intestine are elongated. Courtesy of J. Haruna.

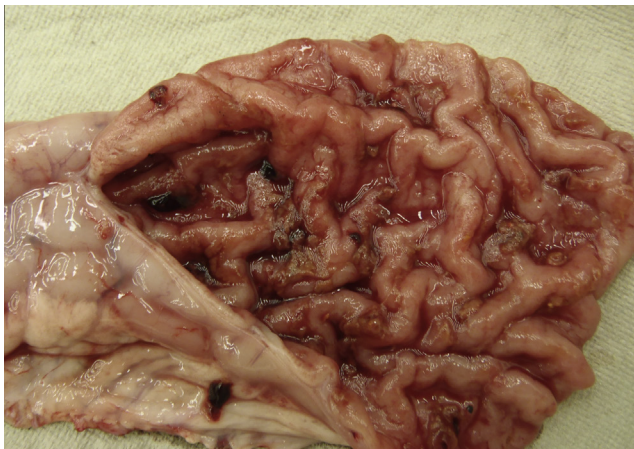


FIGURE 16.19 *Lawsonia intracellularis*, proliferative enteritis. The wall of the intestine is diffusely markedly thickened. Courtesy of ISU Veterinary Diagnostic Laboratory.

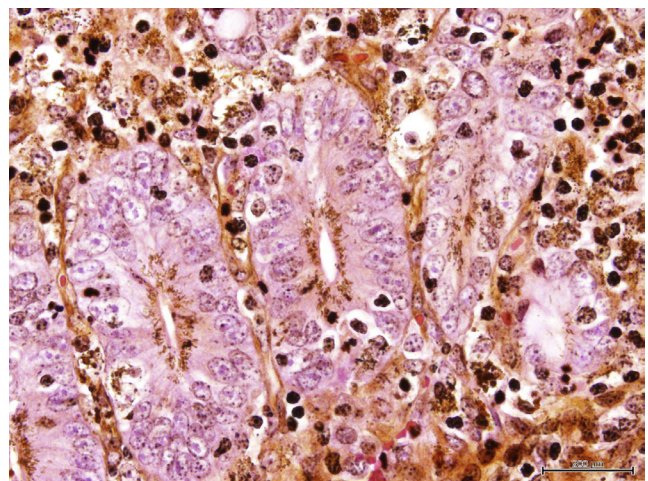


FIGURE 16.21 *Lawsonia intracellularis*, proliferative enteritis. Organisms are present within the apical cytoplasm of intestinal glandular enterocytes. Courtesy of J. Haruna.

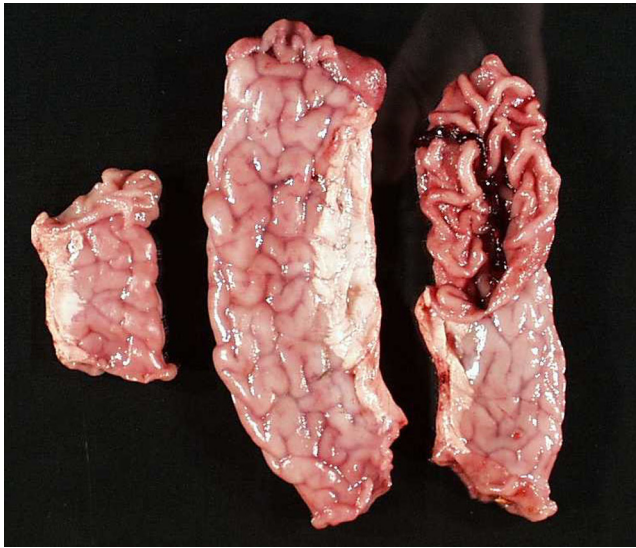


FIGURE 16.22 *Lawsonia intracellularis*, proliferative enteritis, hemorrhagic form. Intestinal wall is diffusely thickened with luminal hemorrhage present. Courtesy of ISU Veterinary Diagnostic Laboratory.

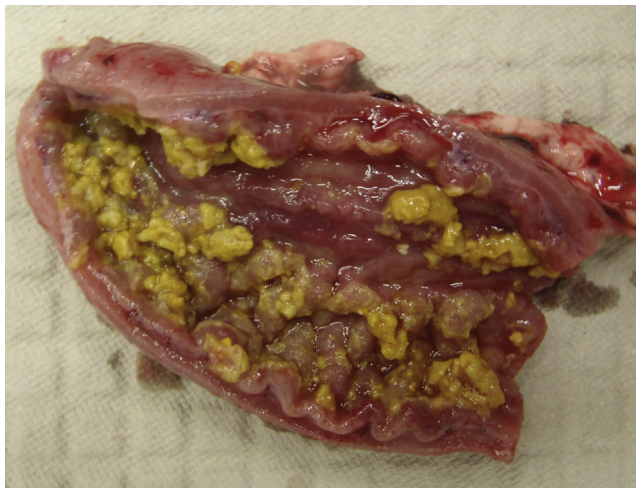


FIGURE 16.23 *Lawsonia intracellularis*, proliferative enteritis, fibrinonecrotic. The intestine is diffusely thickened and there is fibrinonecrotic debris adherent to the lumen. Courtesy of ISU Veterinary Diagnostic Laboratory.

blood clots; colonic contents may be black and tarry (Figs 16.22, 16.23) (McOrist and Gebhart, 2012; Love and Love, 1979). Histologic findings include extensive degeneration and necrosis of the ileal epithelium, crypt abscesses, and extensive accumulation of proteinaceous fluids in the lamina propria of the villi, resulting in distortion of the villi (Love and Love, 1979).

Granulomatous inflammation has also been associated with *Lawsonia* infection (Segales, 2012).

Research Complications The morbidity and mortality associated with PE make clinically affected pigs

unsuitable for experimental use. Although lesions typically resolve over time, the presence of clinical disease with lesions will impact research.

d. Colibacillosis

Enteric colibacillosis is the most important diarrheal disease of young swine (Fairbrother and Gyles, 2012). Diarrhea attributable to colibacillosis is commonly observed in neonates born to nonimmune sows or in piglets housed in heavily contaminated environments. Susceptible animals are those recently weaned and animals stressed by new housing, or dietary changes.

Etiology Colibacillosis is caused by pathogenic *E. coli*, a gram-negative facultative anaerobic rod. *E. coli* are responsible for many disease entities, the most important of which in pigs are postweaning diarrhea (PWD) and edema disease (ED). The species *E. coli* includes members that are normal gut flora as well as enteric pathogens that are further classified by antigenic serotype: somatic (O), capsular (K), flagellar (H), and fimbrial adhesins (F). Pathogenic *E. coli* also possess one or more virulence factors encoded on either the bacterial genome or plasmids. Various classifications associated with different modes of pathogenesis include enterotoxigenic strains of *E. coli* (ETEC), which produce heat-stable (ST) or heat-labile (LT) enterotoxins. Necrotoxic *E. coli* (NTEC) produce cytotoxic necrotic factors (CTF) which lead to diarrhea (De Rycke *et al.*, 1999; Toth *et al.*, 2000). Enteropathogenic *E. coli* (EPEC), also referred to as attaching and effacing strains (AEEC), attach to the enteric epithelium using fimbrial adhesins, and efface the microvilli and invade the epithelial cells. Strains of *E. coli* that cause hemorrhagic gastroenteritis are referred to as enterohemorrhagic *E. coli* (EHEC) (Tzipori *et al.*, 1989). ETEC is the most important of the *E. coli* in pigs. EPEC may also cause PWD. Shiga-toxin producing *E. coli* or ED associated *E. coli* (STEC/EDEC) are responsible for ED. This chapter will focus on causes of PWD and ED. Other conditions are beyond the scope of this publication but have been recently reviewed elsewhere (Kaper *et al.*, 2004; Croxen and Finlay, 2010).

Epizootiology and Transmission Clinical disease results from interaction between the causative bacteria, adverse environmental conditions, and select host factors. Infections with *E. coli* are widespread and up to 25 different strains may be identified in the gastrointestinal tract of any one individual (Fairbrother and Gyles, 2012). Newborn pigs encountering large numbers of *E. coli* carrying the appropriate virulence factors will develop colibacillosis if colostrum is not available or if the sow is not immune to *E. coli*.

Pathogenesis Some pigs are inherently resistant to colibacillosis because they lack receptors on their epithelial cell brush borders to which the fimbriae bind (Baker *et al.*, 1997).

The K1 polysaccharide enhances bacterial resistance to complement-mediated killing by inhibiting the alternative pathway to complement activation. The long O-chain polysaccharide chains in the cell wall bind the membrane attack complex resulting from complement activation distant from the cell membrane so that it cannot lyse the cell (Gyles, 1993). Specialized fimbriae, K88(F4), K99(F5), F6, and F41 permit the adherence and colonization of the enterocytes.

ETEC organisms produce toxins (STa, STb, LTI, LTII, and EAST-1) after attachment to the apical surface of enterocytes. These enterotoxins change the water-electrolyte flux in the small intestine which leads to diarrhea if the fluid is not resorbed in the large intestine. STa binds receptor leading to fluid/electrolyte secretion (Giannella and Mann, 2003). STb binds a receptor and increases cellular uptake of calcium inducing secretion of water and electrolytes (Harville and Dreyfus, 1995). LT is endocytosed and permanently activates adenyl cyclase, which increases water and electrolyte secretion (Dorsey *et al.*, 2006; Fairbrother and Gyles, 2012). EAST-1 acts similarly to STa (Fairbrother and Gyles, 2012).

ETEC have F4(K88) or F18 fimbrial adhesins. The fimbria produced determines where in the gastrointestinal tract the organism colonizes. When EPEC is involved in PWD, it causes attaching and effacing lesions via a complex secretion system. STEC/EDEC produce shiga toxins (also known as verotoxins). STEC/EDEC that secrete STx2e are most pathogenic of the STEC/EDEC and cause ED. STx2e damages blood vessel walls resulting in increased permeability and edema. STEC/EDEC often have F18 fimbrial adhesins.

Clinical Signs/Diagnosis Colibacillosis presents as diarrhea that varies in severity based on the virulence factors present and the age and immune status of the piglets. Severe dehydration, metabolic acidosis, and weight loss may accompany the diarrhea, or peracute death without diarrhea may be seen. Neonatal colibacillosis can develop within hours of birth and is characterized by either clear, watery diarrhea or loose stools that vary in color from white to brown. Litters born to gilts are more frequently affected versus litters born to sows. Severe outbreaks are associated with high morbidity and mortality in neonates; older pigs have less severe disease. Hemorrhagic gastroenteritis from colibacillosis can occur peracutely (sudden death) or acutely (rapid decline with severe diarrhea) in previously healthy, unweaned, or recently weaned pigs. The differential diagnoses for yellow to white, watery diarrhea in piglets that are newborn to several weeks of age should include salmonellosis, coronavirus, rotavirus, nematodiasis, and coccidiosis.

ED is characterized by swelling of the eyelids and forehead, and there is usually no diarrhea.

Treatment Administering broad-spectrum antibiotics should be started after confirming culture and

sensitivity because sensitivity varies significantly amongst *E. coli* isolates (Fairbrother and Gyles, 2012). Most isolates are sensitive to aminoglycosides, potentiated sulfa drugs, and cephalosporins. Administration of phages against experimentally infected weaned piglets with O149:H10:F4 (ETEC) demonstrated that phages have a potential for prophylactic use against diarrhea and shedding of ETEC (Jamalludeen *et al.*, 2009). Oral fluid therapy consisting of electrolyte replacement solutions containing glucose should be instituted to correct dehydration, energy depletion, and ongoing fluid and electrolyte losses.

Prevention/Control Farrowing management should be 'all in, all out' to provide for adequate sanitation between litters. In problem herds, gilts and sows should be immunized with a commercial vaccine or an autologous bacterin during gestation.

To minimize environmental stress, piglets should be kept warm, clean, and draft free. Nursing pigs will derive protection from colostrum feeding from immune sows.

Necropsy Lesions from animals with PWD are non-specific, but include dehydration, distended stomach with fundic hyperemia, and edema in the small intestine.

Gross lesions of ED may include marked edema of the mesenteric lymph nodes, mesocolon, mesentery, the wall of the stomach, large intestine, subcutaneous lymph nodes, eyelids, subcutaneous tissues, lungs, liver, and gallbladder. Degenerative angiopathy is present in above tissues as well as the brain (Fairbrother and Gyles, 2012).

Research Complications Morbidity and mortality from colibacillosis in neonatal pigs interfere with their experimental use. Once recovered, animals should be clinically normal.

Pigs can shed zoonotic EHEC and proper PPE should be worn when working with potentially or experimentally infected swine (Fairbrother and Gyles, 2012).

e. Clostridial Enteritis

Clostridial infection of the intestinal tract of young swine commonly results in necrotic enteritis with high mortality.

Etiology *C. perfringens* is an encapsulated, gram-positive bacillus that produces a variety of enterotoxins that are responsible for clinical signs and lesions (Buogo *et al.*, 1995). *C. perfringens* type A is a normal inhabitant of the swine intestine but some strains cause enteric disease. In contrast, fatal necrotic enteritis is caused by *C. perfringens* type C. *C. difficile* is an emerging cause of porcine neonatal diarrhea.

Epizootiology and Transmission The bacillus is transferred from sow to pigs and between pigs by fecal-oral contact. *C. perfringens* exists in the environment as a vegetative form or as spores that persist for at least a year.

C. perfringens type C is usually introduced by a carrier sow in which the organism is a minor component, but when piglets ingest organism, they act as an amplifying vessel and are overwhelmed by toxins secreted from overgrowth of organisms.

Although disease is most common in pigs aged 12 h to 7 days and peaks in incidence at 3 days of age, disease has also been observed in older pigs aged 2–4 weeks and in postweaning pigs. Disease is explosive, with 100% mortality in pigs born to nonimmune sows. Subsequent litters are protected by maternal immunity.

Pathogenesis Disease due to *C. perfringens* type A occurs when large numbers of organisms build up in the jejunum and ileum and produce a toxin (CPA) and may also produce CPB2 toxin. These organisms do not invade the enterocytes.

C. perfringens C attaches to the enteric epithelium at the apex of the villi leading to desquamation and proliferation of organisms along the basement membrane.

C. perfringens type C organisms produce a trypsin sensitive β -toxin that is responsible for much of the necrotizing lesions. The key factor is CPB toxin, although CPB2 toxin may also play a role. These organisms attach to enterocytes and result in initial loss of microvilli on the enterocytes at the tips of the villi and damage to terminal capillaries, with increased capillary permeability. This is followed by a rapid, progressive necrosis of the remaining villus enterocytes, the crypt cells, and mesenchymal structures in the lamina propria and muscularis mucosa (Niilo, 1993). Some organisms may penetrate to the muscle layers and produce emphysema of the gut wall and thrombosis of vessels (Frana, 2012).

C. difficile produces *C. dif* toxin A and *C. dif* toxin B, a cytotoxin and enterotoxin, respectively (Keel and Songer, 2006, 2011).

Clinical Signs/Diagnosis Clinical manifestations of infection with *C. perfringens* will depend on the immune status of the swine herd and the age of naive exposed piglets. Disease caused by *C. perfringens* Type A can develop within 48 h of birth. Piglets have rough pelage, perineal staining, and creamy or pasty diarrhea which may become pink and mucoid and last up to 5 days (Songer, 2012). The majority of affected piglets recover but tend to develop slower. Clinical signs of *C. perfringens* type C include hemorrhagic diarrhea, weakness, and lethargy although the only sign may be peracute with death of piglets aged 12–36 h. Acute disease is characterized by 2 days of reddish-brown diarrhea containing gray, necrotic debris, with death by 3 days of age. Subacute disease develops as persistent nonhemorrhagic diarrhea that is yellow initially and then changes to clear liquid with flecks of necrotic debris. Chronic enteritis may involve intermittent or persistent diarrhea for several weeks, with mucoid yellow–gray feces (Songer, 2012).

Diagnosis is difficult because *C. perfringens* A is normal flora. For *C. perfringens* C, ELISAs that detect the toxin in fecal matter, culture, examination of fecal smears, or histology may aid in diagnosis. Differentials for hemorrhagic diarrhea in newborn piglets to those several weeks of age should include *C. perfringens*, *B. hyodysenteriae*, *Salmonella*, *L. intracellularis*, and *T. suis*.

Treatment Once clinical signs develop, disease is extensive and often unresponsive to therapy. Oral antimicrobials such as ampicillin given soon after birth and repeated daily for the first 3 days of life may prevent clinical disease. Another prophylactic therapy is a combination of ceftiofur and bacitracin methylene disalicylate which may be given to sows before and after farrowing (Songer, 2012). Pigs with severe diarrhea should receive supplemental fluids containing glucose and electrolytes.

Prevention/Control Routine vaccination of sows will prevent disease (Kelneric *et al.*, 1996). Sows can be vaccinated with a toxoid at the time of breeding or midgestation and then again 2 weeks prior to farrowing. Piglets from immune sows will be protected by colostrum.

Clinically ill pigs should be isolated and treated and the premises sanitized. Individual piglets and pregnant swine that are at risk from recent exposure should be vaccinated with recombinant toxoids α and β (Salvarani *et al.*, 2013). Medicated feed has been shown to control clinical signs (Kyriakis *et al.*, 1996).

Necropsy *C. perfringens* A lesions consist of flaccid, thin-walled, intestine that is gas filled with watery contents, with necrosis of the superficial villus tip and fibrin.

White pasty fecal matter may be found in distended large intestines with no gross lesions. A large number of organisms may be found in the lumen and in lesions in the jejunum and ileum. *C. perfringens* C lesions are a segmental transmural necrosis with emphysema in the small intestine and sometimes in the cecum and proximal colon. The affected segments of gut vary from multifocal involvement to nearly diffuse involvement of the small intestine. The affected gut wall is dark red to black, and there may be gas bubbles. Enteric lymph nodes are red. The mucosa is dark red, and the intestinal contents in affected segments contain hemorrhagic and necrotic debris. The hallmark signs noted at necropsy are severe hemorrhage in the small intestines and blood-tinged peritoneal fluid (Songer, 2012). Microscopic lesions consist of severe necrosis of villi and crypts, and severe and extensive hemorrhages throughout the lamina propria and mucosa. There may be a necrotic membrane composed of bacteria, sloughed epithelium, fibrin, and inflammatory cells lying over the submucosa (Songer, 2012).

Research Complications Clostridial enteritis causes acute death and severe morbidity among survivors. Overgrowth of *C. perfringens* from perioperative use of

antibiotics may cause acute losses and interrupt surgical studies.

f. *Salmonella* Enterocolitis

See *Polysystemic Diseases* (Section III, A, 1).

g. Transmissible Gastroenteritis

Transmissible gastroenteritis (TGE) is a highly contagious viral enteritis associated with vomiting, severe diarrhea, and high mortality in piglets less than 2 weeks old.

Etiology TGE is caused by a member of the species *Alphacoronavirus 1*, which are pleomorphic enveloped viruses containing a positive-sense, single-stranded RNA genome in the *Alphacoronavirus* genus, Coronavirinae subfamily of the Coronaviridae family (Viruses, 2013; Carstens, 2010). Alphacoronavirus-1 is historically known as transmissible gastroenteritis virus (TGEV). This is one of four members that naturally infect pigs: TGEV, hemagglutinating encephalomyelitis virus, porcine respiratory coronavirus (PRCV), and the emerging disease, porcine epidemic diarrhea virus (PEDV).

Epizootiology and Transmission Epizootic TGE can develop within days when the majority of animals are susceptible. A pattern of enzootic TGE will follow if viral challenge exceeds protection afforded by maternal immunity or as passive immunity wanes in the post-weaning period. In herds with enzootic TGE, older animals will be asymptomatic, but diarrhea will develop in 1- to 2-week-old pigs. Usually morbidity and mortality are lower, making diagnosis more difficult and requiring discrimination between other common causes of neonatal diarrhea, such as rotavirus and colibacillosis. PEDV has only recently been reported in the US, thus expanding its distribution (Service, 2013).

Pathogenesis TGEV uses the aminopeptidase-N receptor on porcine enterocytes to gain access to the cell. These receptors are only found on enterocytes with microvilli and only cells mid-villus to the tip and not in crypts (Perlman and Netland, 2009; Weingartl and Derbyshire, 1994). Enterocytes are replaced in the neonatal period when cell type changes from fetal to adult (Smith and Peacock, 1980). This accounts for neonates being primarily susceptible. The virus multiplies in mid-villus enterocytes, which are then sloughed leading to villar blunting and fusion of non-epithelialized basement membranes, thus decreasing digestive surface and enzymatic activity resulting in maldigestive/malabsorptive diarrhea.

Clinical Signs/Diagnosis Anorexia, vomiting, and/or diarrhea develop in 18–72h in susceptible animals of all ages, particularly in the winter (Saif et al., 2012). Nursing pigs develop transient vomiting and profuse watery yellowish diarrhea, with dehydration and rapid weight loss. Malodorous diarrhea will contain

milk curds. Piglets less than 2 weeks old experience high mortality secondary to dehydration from enteritis. Piglets over 3 weeks of age typically survive but their growth may be stunted (Saif et al., 2012). Differential diagnoses for yellow to white watery diarrhea in piglets that are newborn to several weeks of age should include colibacillosis, rotavirus, coccidiosis, and nematodiasis.

Treatment There is no specific treatment for piglets infected with TGEV. Supportive care with fluids containing glucose and electrolytes is indicated. In piglets 2–5 weeks old, antibiotics are effective if there are concurrent primary or opportunistic bacterial pathogens.

Prevention/Control Swine intended for research should be purchased from a serologically negative herd. Naive swine should not be introduced into potentially contaminated environments or into established herds known to harbor enzootic TGEV. Vaccination of boars, gilts, and sows will moderately reduce clinical signs.

A moratorium on purchase of new animals and vaccination of reproductive stock will eventually contain an outbreak as the herd develops immunity. Stress exacerbates disease and should be minimized.

Necropsy Gross lesions are confined to the gastrointestinal tract and consist of a stomach distended with milk, gastric petechiation, and a distended, thin-walled small intestine, which is filled with watery material and curds of undigested milk. The piglets are usually severely dehydrated, and there is no chyle in the lymphatic channels in the mesentery (Hooper and Haelterman, 1966, 1969). The most striking microscopic lesion is severe villus atrophy in the jejunum and ileum (Fig. 16.24). The villus-to-crypt ratio of affected animals is 1:1, compared to a normal of about 7:1 (Hooper and Haelterman, 1966, 1969). The enterocytes are vacuolated and low-cuboidal or flattened, there is lymphoid depletion of Peyer's patches, and minimal inflammatory response in the lamina propria (Hooper and Haelterman, 1969). Virus particles can be found in the cytoplasm of villus enterocytes,

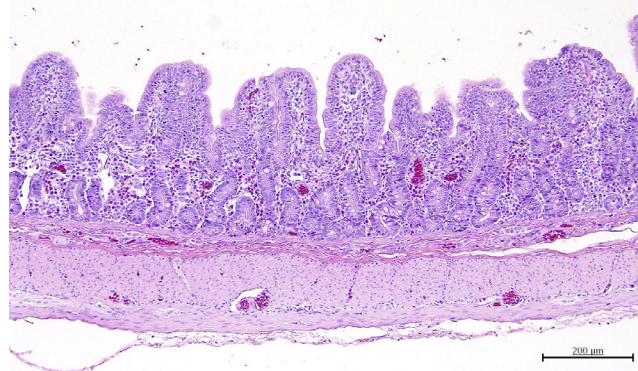


FIGURE 16.24 Porcine Coronavirus. Transmissible gastroenteritis. Villi of the small intestine are markedly shortened. Courtesy of J. Haruna.

M cells, lymphocytes, and macrophages within Peyer's patches (Saif *et al.*, 2012).

Research Complications Clinical signs of TGEV are severe enough to make animals unsuitable for experimental use unless sufficient time is available for clinical recovery.

h. Porcine Epidemic Diarrhea Virus

Porcine epidemic diarrhea virus (PEDV) is an alphacoronavirus related to TGEV. Clinically, PEDV is very similar to TGEV, and laboratory tests are required to differentiate the viruses. This is not a new virus, but has recently (2013) been found in a small number of herds in the US and has quickly spread to 30 states as of April 5, 2014 (Practitioners, 2014). There are many variants of the virus, but this newly circulating virus in the US is particularly virulent with 90–95% mortality in suckling pigs and vomiting and diarrhea from all ages of pigs (Stevenson *et al.*, 2013). Mice and cats can act as vectors of the virus (Truong *et al.*, 2013). Vaccines are available in Asia, but not in the US or EU. Biosecurity is currently the best way to prevent the virus in facilities. In April 2014 it was declared a reportable disease by the USDA (Agriculture, 2014).

i. Porcine Rotavirus

Porcine rotavirus is a major cause of morbidity and mortality from acute diarrhea in very young pigs, particularly if piglets are colostrum-deprived or raised under gnotobiotic conditions in which the herd is free of natural infection (Bridger *et al.*, 1998).

Etiology Rotaviruses are members of the family Reoviridae which are nonenveloped and contain a double-stranded RNA genome. Four (A, B, C, E) of seven serogroups (A–G) of rotavirus have been described in swine, with group A being the most commonly detected. Within these serogroups, rotaviruses fall into two major serotypes based on expression of two surface antigens, VP4 and VP7.

Epizootiology and Transmission Rotaviral infection is enzootic in most swine herds, and clinical disease is apparent only if viral challenge exceeds the capacity of passive maternal immunity. Piglets born to gilts are at greater risk than those farrowed by older sows, which are more likely to have naturally high virus neutralizing titers that protect the nursing piglets. Rotaviruses are stable in the environment and are relatively resistant to effects of temperature, pH, and disinfectants. Subclinical infection may persist in adult animals, with periodic shedding.

PATHOGENESIS Rotaviruses replicate in the cytoplasm of enterocytes and M cells overlying Peyer's patches (Buller and Moxley, 1988). Group A and C rotaviruses are responsible for diarrhea due to destruction of enterocytes on the tips of the villi and severe villous

atrophy compared to groups B and E (Saif, 1999; Chang *et al.*, 2012). An osmotic diarrhea ensues due to decreased resorption of sodium, water, and disaccharides in the jejunum and ileum, which causes intestinal contents to be hyperosmolar (Graham *et al.*, 1984).

Clinical Signs/Diagnosis Disease is most severe in naive pigs first exposed at 1–5 days of age. Typical signs follow an 18- to 96-h incubation period and include anorexia, lethargy, vomiting, fever, and profuse watery diarrhea that is white to yellow in color and contains flocculent material. In pigs that will recover, consistency of feces slowly returns to normal after 3–5 days of diarrhea. Clinical signs and losses are less severe if exposure occurs after piglets are 7 days of age, and infection is commonly subclinical if it occurs after they are 21–28 days of age. Disease is usually mild and self-limiting if other enteric pathogens are absent. If rotaviral infection is detected in clinically ill pigs of postweaning age, mixed infection with other agents such as TGEV should be suspected. Severe diarrhea and 50–100% mortality is seen in 1- to 5-day-old gnotobiotic or colostrum-deprived pigs experimentally exposed to rotavirus. Differential diagnoses for yellow to white, watery diarrhea in piglets that are newborn to several weeks of age should include rotavirus, colibacillosis, TGE, coccidiosis, and nematodiasis.

Treatment No specific treatment is available. Supportive therapy should include replacement fluids containing glucose and electrolytes, antibiotics to treat or prevent secondary bacterial infections, and warm, clean housing.

Prevention/Control Because porcine rotavirus is enzootic in most herds, exclusion is difficult. Management should concentrate on minimizing the viral challenge for susceptible pigs through good sanitation and boosting passive immunity by exposing replacement gilts to feces from the herd prior to their first parturition. Modified live- and inactivated-virus vaccines are commercially available for immunization of sows and nursing pigs. However, immunity is serotype-specific, with unknown duration.

Necropsy Gross lesions are confined to the small bowel. The wall of the distal half of the small intestine is typically thin and dilated and contains watery material, while the mesenteric lymph nodes are tan and small (Chang *et al.*, 2012). The cecum and colon are dilated, with watery contents similar to those in the small intestine. Gross lesions in pigs over 21 days of age are variable or absent. Microscopic lesions include degeneration and loss of enterocytes on the tips of the villi, which develop as early as 16h post inoculation, increased thickness of the lamina propria due to large numbers of neutrophils and mononuclear cells, reduction in villus height from the duodenum to the ileocecal juncture, and fusion of villi due to exposed lamina propria in villus cores (Pearson and McNulty, 1977).

Research Complications Morbidity and mortality of porcine rotaviral infection will impact studies using very young piglets and will probably be subclinical in postweaning animals.

j. Balantidiasis

Etiology Balantidiasis is caused by trophozoites of *Balantidium coli*, a ciliated protozoan that colonizes the cecum and anterior colon of swine, usually as a commensal. Trophozoites are large (25 × 150 μm), ciliated ovoid structures containing a macronucleus and micronucleus in addition to contractile and food vacuoles. Trophozoites of *B. coli* isolated from pigs affected by acute disease and from pigs with subclinical balantidiasis, as well as trophozoites cultured *in vitro*, have been shown to differ in nucleic acid content, suggesting that clinical disease may be associated with different strains of *B. coli* (Skotarczak and Zielinski, 1997).

Epizootiology and Transmission Infection with *B. coli* is contracted by ingestion of trophozoites or cysts that are shed in feces. Most infections are subclinical. If clinical enteritis is associated with *B. coli*, other infectious agents or management problems that may be cofactors in disease development should be investigated.

Pathogenesis Secondary invasion occurs when the integrity of the colonic mucosa is compromised.

Clinical Signs/Diagnosis Infection with *B. coli* may present as an acute typhilitis or colitis or more commonly, no apparent effect. Infection can cause severe ulcerative enterocolitis, which can be fatal. Clinical signs include weight loss, anorexia, weakness, lethargy, watery diarrhea, tenesmus, and rectal prolapse.

Treatment Balantidiasis can be successfully treated with antibiotics and oxytetracycline can eliminate *B. coli* (Stewart, 2007).

Prevention/Control Herd-health management that minimizes the risk of enteritis from any cause will help prevent clinical balantidiasis. Clinically ill pigs should be isolated and treated or necropsied to rule out other predisposing causes of enteritis.

Necropsy *B. coli* is not considered a primary pathogen in pigs, but has been shown to invade lesions caused by *Oesophagostomum* and *T. suis* (Bowman and Georgi, 2009; Beer and Lean, 1973).

Research Complications Although *B. coli* is usually nonpathogenic, severe ulcerative enterocolitis can develop. Because of zoonotic potential, it may be advisable to euthanize piglets shedding *B. coli* in high numbers.

k. Coccidiosis

While disease is commonly absent or subclinical, significant morbidity and mortality can result from severe diarrhea in neonatal piglets.

Etiology *Eimeria* spp., *Cryptosporidium parvum*, and *Isospora suis* are three genera of coccidia that infect

swine and other mammals. There are eight species of *Eimeria* that infect up to 95% of the swine housed on dirt lots in the US. *Eimeria* spp. are considered to be nonpathogenic in swine. *C. parvum* typically causes subclinical infection in swine that are 6–12 weeks of age. Clinical neonatal coccidiosis is caused by the intracellular parasite, *I. suis*, and is the most important protozoal disease of nursing piglets that are 1–2 weeks of age (Lindsay *et al.*, 1997).

Epizootiology and Transmission The most common coccidia affecting swine are transmitted by fecal-oral contact. Warm temperatures and high humidity associated with indoor farrowing favor rapid sporulation of oocysts. Contaminated environments pose the greatest risk to naive piglets.

Pathogenesis Ingestion of sporulated oocysts by the pig permits development to sporozoites in the intestinal lumen. These invade enterocytes and form trophozoites, which then form merozoites, resulting in rupture of the cell membranes when they are released into the intestinal lumen.

Clinical Signs/Diagnosis *I. suis* causes clinical disease in nursing piglets that are 1–2 weeks old. Yellow to gray diarrhea that varies in consistency from watery to pasty develops and piglets will continue to nurse. Weight loss and dehydration secondary to coccidiosis can be exacerbated by concurrent infections with other parasites, bacteria, or viruses. The differential diagnoses should include colibacillosis, *C. perfringens*, TGE, rotavirus, and *Strongyloides ransomi*.

Treatment Piglets should be individually dosed orally with amprolium or furazolidone. Sulfonamides and trimethoprim-sulfa are also effective (Lindsay *et al.*, 1997). Drug therapy may only delay the onset of clinical signs. Electrolyte and water-balance disturbances should be treated with either oral or parenteral fluids.

Prevention/Control Piglets should be purchased from vendors with an established herd-health profile that is free of coccidiosis. Newly received piglets should be routinely quarantined and tested for coccidia by fecal flotation.

Coccidiosis can be controlled by ‘all in, all out’ husbandry and thorough cleaning of housing areas, including removal of organic debris, chemical disinfection, and steam cleaning.

Necropsy The gross lesions are confined to the jejunum and ileum and consist of necrotic enteritis involving the entire thickness of the mucosa. A yellow fibrinonecrotic pseudomembrane may be present over foci of mucosal ulceration. Microscopic lesions consist of moderate to severe segmental villous atrophy and necrotic enteritis. The variable reduction in villous heights ranges from slight to severe, and the villous enterocytes are flattened and irregularly shaped. There may be crypt epithelial hyperplasia, and the lamina

propria is condensed and infiltrated with large numbers of mononuclear cells. The least involved sections of the mucosa contain varying stages of coccidia in vacuoles in the enterocytes of the distal two-thirds of the villi (Eustis and Nelson, 1981).

Research Complications Morbidity is high, but mortality is usually low to moderate in piglets affected by neonatal coccidiosis. Growth may be stunted.

l. Giardiasis

Etiology *Giardia* trophozoites commonly found in domestic swine are typically *Giardia duodenalis* although *G. lamblia* and *G. intestinalis* are also seen (Lindsay et al., 2012; Olson et al., 1997). Trophozoites colonize the surface of intestinal crypts of the small intestine from the duodenum to the ileum, with maximum numbers in the cranial part of the upper jejunum (Koudela et al., 1991).

Epizootiology and Transmission *Giardia* exists as a commensal in the vast majority of domestic swine (Olson et al., 1997). *Giardia* cysts are intermittently shed in feces and transmitted to other pigs by fecal–oral contact. Transmission is via the fecal–oral route.

Clinical Signs/Diagnosis Clinical signs include anorexia, depression, and formless feces. *Giardia* may be the primary cause of enteritis or may be found coincidental to other causes of enteritis (see Table 16.3). Fecal flotation using zinc sulfate is the most effective method of diagnosis.

Treatment Metronidazole is commonly used for 5 days to control giardiasis. Diagnostic steps to rule out other causes of enteritis are indicated.

Prevention/Control Sanitation protocols should include removing feces daily or housing pigs on slatted floors to minimize fecal contact. Clinical enteritis can be controlled by quarantine and treatment.

Necropsy No pathologic lesions were found in the small intestines of groups of pigs experimentally infected with *G. intestinalis* (Koudela et al., 1991). Detection of organisms can be accomplished using Giemsa-stained fecal smears or histologic sections.

Research Complications Giardiasis can cause debilitation from diarrhea and dehydration but usually responds to both supportive and medical treatment. Giardiasis is a zoonotic disease.

m. Nematodiasis

Young swine can be infected with the nematodes *Hyostrongylus rubidus*, *Globocephalus urosubulatus*, *Macracanthorhynchus hirudinaceus*, *Oesophagostomum* spp., *Ascaris suum*, *T. suis*, and *Strongyloides ransomi* (Zimmerman et al., 2012b). Only *T. suis* and *S. ransomi* will be discussed here because the other parasites are either discussed elsewhere (*Ascaris*), require intermediate hosts (*Macracanthorhynchus*), or infection by the parasite is associated with pasture maintenance (*Hyostrongylus*,

Globocephalus, *Oesophagostomum* spp.), which is unlikely to be an issue in laboratory animal research facilities.

i. TRICHURIS SUIS

Etiology The swine whipworm, *T. suis*, colonizes the small intestine and cecum, causing morbidity and possibly mortality in young, postweaning swine.

Epizootiology and Transmission Bipolar, thick-shelled eggs are intermittently shed in feces. After 3–4 weeks in the environment eggs are infective, and remain so, for as long as 6 years. Ingested eggs hatch in the small intestine and cecum, with newly released larvae penetrating cells lining the crypts. Larvae gradually migrate from the lamina propria into the submucosa over several weeks. After a series of molts, adult worms can be found with their anterior end buried in the mucosa and the posterior end free in the intestinal lumen. Prepatency is 6–7 weeks, and the life span of the adult worm is 4–5 months. Damage caused to the mucosa permits colonization by pathogenic bacteria and *B. coli*.

Clinical Signs/Diagnosis *T. suis* may cause anorexia, mucoid to hemorrhagic diarrhea, growth retardation, dehydration, and in severe infections, death (Batte et al., 1977; Beer and Lean, 1973). Differential diagnoses for hemorrhagic diarrhea in piglets that are newborn to several weeks of age include colibacillosis, *C. perfringens*, and *B. hyodysenteriae*. In older pigs, *Salmonella* and *L. intracellularis* should be considered.

Treatment Effective anthelmintics for trichuriasis include fenbendazole, dichlorvos, and levamisole hydrochloride. Although ivermectin is considered to be efficacious for elimination of *Ascaris*, *Oesophagostomum*, and *Metastrongylus*, it is less effective for *Trichuris*.

Prevention/Control *T. suis* eggs passed in feces require 3–4 additional weeks to develop to an infectious stage; hence, indoor housing with good sanitation that includes regular removal of feces and organic debris should prevent environmental contamination and reinfection. Newly received swine should be tested for *Trichuris* by fecal flotation and treated with anthelmintics during the quarantine period. Housing areas and equipment should be steam-cleaned to destroy eggs and infective larvae.

Necropsy Gross lesions are found primarily in the cecum and colon. The wall of the large intestine is thickened, the mesentery may be thickened and appear as bands between coils of gut, and there may be foci of hemorrhages on the serosal surface (Beer and Lean, 1973). The mesenteric lymph nodes are enlarged and congested. The lumen of the gut is filled with bloody fluid, and there is a hemorrhagic catarrhal colitis and typhlitis, with portions of the mucosa being replaced by a yellow crumb-like, fibrinonecrotic membrane (Batte et al., 1977; Beer and Lean, 1973). Microscopic examination reveals parasites embedded in the mucosa between

villi and in crypts, which may be cystic, or they may penetrate to the muscularis mucosa and the lamina propria is infiltrated by large numbers of mononuclear cells (Batte and Moncol, 1972). Foci of hemorrhage may be found in the mucosa, as well as ulcers, which are covered by thick fibrinonecrotic material (Beer and Lean, 1973).

Research Complications Severe infection with *Trichuris* will cause bloody scours in young pigs, with associated morbidity and some mortality. *T. suis* is a potential human health hazard (Beer, 1976).

ii. STRONGYLOIDES RANSOMI

Etiology *S. ransomi* is the small intestinal threadworm of swine. It is most prevalent in warm climates and causes morbidity in suckling pigs (Greve, 2012).

Epizootiology and Transmission Larvae of *S. ransomi* can infect pigs *in utero* as well as by the oral, percutaneous, and transcolostral routes. Eggs shed in feces hatch within hours to release larvae that are directly infective within 24 h or develop into males and females that then reproduce, resulting in more larvae within 72 h.

Pathogenesis Larvae enter the bloodstream and are transported to the lungs where they are coughed up and swallowed.

Clinical Signs/Diagnosis Large numbers of *Strongyloides* can result in poor body condition, decreased weight gain, diarrhea, with secondary dehydration and death within the first 2 weeks of life. The differential diagnosis for nonhemorrhagic diarrhea in piglets aged upward of 14 days should include colibacillosis, salmonellosis, rotavirus, TGE, giardiasis, coccidiosis, and nematodiasis.

Treatment Young swine can be treated with paste formulations of thiabendazole. Other effective drugs are ivermectin and levamisole.

Prevention/Control Breeding animals should receive anthelmintics several weeks before farrowing to control the shedding of *S. ransomi* eggs and transmission through colostrum. Removing feces daily or housing on slatted floors should minimize exposure of neonates to infective larvae.

Necropsy Pigs may be dehydrated or may be stunted and unthrifty. Adult forms of the parasite are found in the small intestine, and ova are present in the feces.

Research complications *S. ransomi* is an important cause of parasitic debilitation in nursing pigs in the southeastern US. Routine diagnostic screening and timely use of anthelmintics should minimize any impact on research.

4. Circulatory Disease

a. *Mycoplasma Suis*

Etiology *M. suis* has been reclassified from *Eperythrozoon suis* based on 16S RNA and is the etiologic

agent for this host-specific disease in swine (Neimark *et al.*, 2002). These are epicellular and membrane-bound intracellular, round to oval organisms that are found within or attached to the outer surface of erythrocytes and free within the plasma (Groebel *et al.*, 2009). They change size and shape as they mature, which gives the microscopic appearance of infection by two separate organisms. They stain well with Giemsa but not with Gram stain.

Epizootiology and Transmission The reservoir for *M. suis* is domestic swine, and serologic studies have not detected it in wild swine (Thacker and Minion, 2012). However, current serologic tests will not detect every latent carrier and some infected pigs never show disease. Transmission is mechanical by blood-sucking arthropods, primarily lice, or reuse of blood-contaminated needles, snares, and surgical or tattoo instruments. It can be directly transmitted orally when swine lick fresh wounds or any fluids containing blood. The organism can also be transmitted *in utero* (Henderson *et al.*, 1997).

Pathogenesis Acute disease is characterized by anemia which can be fatal, due to massive parasitism of host erythrocytes. Infected erythrocytes have altered membranes with increased fragility and are rapidly removed by the spleen. Endothelial cells are invaded and activated by the organism as well which further explains the range of clinical signs observed (Sokoli *et al.*, 2013).

Clinical Signs/Diagnosis Acute disease is usually seen in suckling or newly weaned piglets or other pigs that have been stressed, and consists of fever of 40–42°C, anemia, jaundice, pale mucous membranes, cyanosis of the ears, weakness, and poor weight gain. All ages of swine can be clinically affected, however, the very young are most likely to be. Acutely affected sows will become anorexic and febrile, and will have decreased milk production and poor maternal behavior. Vulvar and mammary gland edema may also be seen in sows.

The chronic form affects older pigs and is usually subclinical, but animals may show unthriftiness, pallor, and urticaria, or it may adversely affect reproductive parameters in sows (Messick, 2004; Groebel *et al.*, 2009). Reproductive problems include anestrus, low conception rates, abortions, weak piglets, and small litters. Mortality due to *M. suis* is extremely low.

PCR assays and ELISAs have been developed to detect and diagnose *M. suis* (Messick *et al.*, 1999). In acute cases, a fresh blood smear can be stained with Giemsa to visualize the organisms. Differentials include iron deficiency anemia and other causes of anemia in piglets and toxicity producing icterus or anemia.

Treatment Oxytetracycline either parenterally or in food or water will control the clinical signs but does not eliminate the organism. Iron dextran should be given to each clinically affected pig. In severely anemic animals,

administration of whole blood may be beneficial. Additionally, any form of environmental, experimental, or physical stress should be eliminated.

Prevention/Control Control measures include eliminating ectoparasites, never reusing needles, and sterilizing surgical instruments thoroughly. The most satisfactory prevention is to allow only known *M. suis*-free swine into a facility.

Necropsy Gross findings include icterus, distended gallbladder filled with gelatinous bile, splenomegaly, pale mucous membranes, watery blood, swollen edematous lymph nodes, ascites, hydrothorax, and a swollen and yellow–brown liver (Splitter, 1950; Thacker and Minion, 2012).

One or more of the organisms can be found within RBCs in a smear of peripheral blood, where they appear as 0.8- to 1- μ m diameter rings with a pale center (Thomson, 1988). Microscopic lesions in other organs include hemosiderosis in hepatocytes and Kupffer cells, fatty degeneration and centrilobular necrosis of hepatocytes, and hyperplastic bone marrow (Splitter, 1950; Thacker and Minion, 2012).

Research Complications *M. suis* causes an autoimmune hemolytic anemia, which will be precipitated or exacerbated by the stress of experimental protocols. This also predisposes affected animals to respiratory and gastrointestinal disease, which will further confound research protocols.

5. Skin Diseases

a. Exudative Epidermitis: Greasy Pig Disease

Etiology *Staphylococcus hyicus* is a gram-positive coccus considered to be normal flora on the skin of pigs.

Epizootiology and Transmission *S. hyicus* is present worldwide and in many herds does not cause disease. Outbreaks are seen upon introduction of naive animals. Newborn piglets are likely infected during parturition, and cross-contamination can occur when weanlings from different litters are group-housed. This bacterium is very persistent in the environment. Damage to the skin by abrasions from pen surfaces, fighting, mange mites, and concurrent vesicular disease facilitates entry of *S. hyicus*. Spread by other species is of little concern. Morbidity can reach 20%, with up to 80% mortality in affected piglets (Cowart, 1995). EE has also been associated with PCV2 (Kim and Chae, 2004).

Pathogenesis At least six antigenically distinct exfoliative toxins (ExhA, ExhB, ExhC, ExhD, ShetA, ShetB) have been identified and are thought to correlate with clinical disease (Andresen, 1998; Sato *et al.*, 1999; Tanabe *et al.*, 1996). These toxins target the stratum granulosum in the epidermis and are similar to *S. aureus* toxins (Frana, 2012).

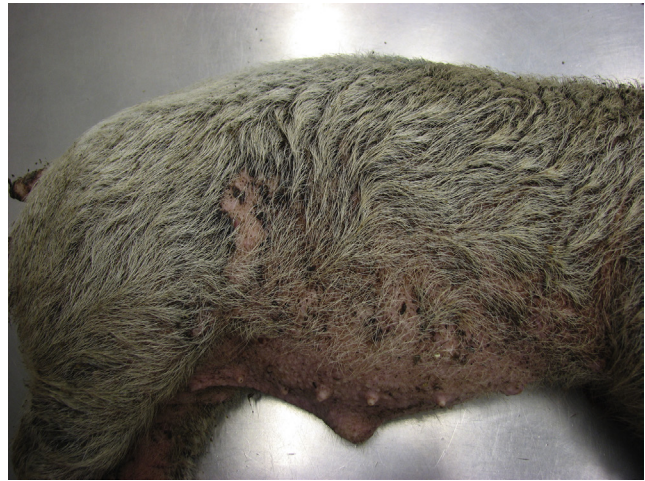

FIGURE 16.25 *Staphylococcus hyicus*, greasy pig disease. There is diffuse exudative dermatitis covering the torso and legs primarily in haired areas. Courtesy of ISU Veterinary Diagnostic Laboratory.

Clinical Signs/Diagnosis The early clinical signs of EE are lethargy, depression, anorexia, and erythematous skin in a variable number of piglets in a litter. Pigs aged 5 days to 2 months are susceptible, and older pigs are more resistant. Lesions progress to an exudative dermatitis characterized by exfoliation and crusting, which begins in the groin, axillae, behind the ears, and on areas of damaged skin (Fig. 16.25). Within 24–48 h lesions on the head expand, coalesce, and extend posteriorly. Haired areas are typically affected but lesions can also be seen on the tongue and oral mucosa. EE is generally self-limiting, lasting 2–3 months in most animals, but can last 12–18 months. Erosions at the coronary band of hooves and vesicles or ulcers in the mouth and on the tongue and snout are common findings. The dermatitis may progress to cover the majority of the body in 3–5 days and becomes exfoliative and crusty but non-pruritic. Severely affected members of the litter may die in 24 h to 10 days, and others may or may not be affected or be chronically affected with small, localized patches of EE. Adult animals may be mildly affected with small areas of EE on their backs and sides (Frana, 2012; Cowart, 1995). *S. hyicus* has also been reported to be an etiologic agent for arthritis in piglets less than 12 weeks old (Hill *et al.*, 1996). Differential diagnoses should include swine pox, mange, ringworm, and pityriasis rosea.

Treatment Treatment with antibiotics is challenging due to resistance to beta lactams, erythromycin, streptomycin, tetracycline, and sulfonamide. The choice, therefore, should be based on sensitivity testing. Topical treatment of the affected skin with antibiotics and antiseptic shampoos or dips in conjunction with the antibiotics is beneficial. Treatment is most effective when started early in the course of the disease, and severely

affected young piglets may be slow to recover (Coward, 1995; Frana, 2012).

Prevention/Control Autogenous bacterins made from strains cultured from a particular herd and given to nonimmune sows are useful to protect the litters of newly introduced sows. The exfoliative toxin and the bacterial cells should be included as antigens when the vaccine is made. An indirect ELISA or phage typing can be utilized to select a toxigenic strain for vaccine production (Andresen, 1999). The sows can be washed with appropriate antibacterials (chlorhexidine or povidone-iodine shampoos) prior to parturition and checked for ectoparasites. Sharp or abrasive surfaces should be removed from the pens.

Necropsy The skin in the area of the erosive lesions may be reddened, edematous or thickened, and covered with an exudate composed of sebum, serum, and sweat (Jones, 1956). These lesions are most commonly found on the ears, around the eyes, on the ventral thorax, and on the abdomen. Microscopic findings are the presence of both a superficial and deep pyoderma that may extend to involve the subcutis, with multiple coalescing foci of necrosis of the stratum corneum, the presence of a brownish exudate, and the formation of rete pegs by the hyperplastic stratum germinativum (Jones, 1956; McGavin and Zachary, 2007; Frana, 2012).

Research Complications Exudative epidermitis will complicate most studies involving young piglets due to the potentially significant morbidity and mortality.

b. Swine Pox

Etiology Swine pox virus is the only member of the genus *Suipoxvirus*, family Poxviridae.

Epizootiology and Transmission The pig is the only known host of this virus, and although worldwide in distribution, it exists primarily in herds where poor sanitation is practiced. The reservoir is infected swine, as the virus is host-restricted. The virus may persist in an active form in dry skin scabs for up to 1 year. Although horizontal transmission may occur via nasal and oral secretions coming in contact with abraded skin, the primary method of transmission is mechanical via the pig louse. Flies and mosquitoes can also carry the viral particles. Once the virus is established within a herd, it usually persists. Outbreaks can result in high morbidity if young animals are present, although mortality is very low.

Pathogenesis The virus replicates in the cells of the stratum spinosum and is suspected to spread from initial site to secondary sites via an as yet undetected viremia (Delhon *et al.*, 2012). Viremia is also believed to be responsible for transplacental infection and disease in neonates.

Clinical Signs/Diagnosis The lesions associated with this virus mimic other pox diseases. Initially, macules

form (reddening), followed by 1- to 6-mm-diameter papules (reddening with edema); transient vesicles (fluid within the lesion), then pustules (umbilicated, ischemic), and finally, crusts (brown to black in color). The progression of the lesions occurs over a 3- to 4-week period. Younger animals (less than 4 months old) are affected more severely than adults and may have lesions covering the entire body surface. Older animals tend to have lesions in more focal locations. If vector transmission has occurred, the location of the lesions follows the vector preferences, that is, the pig louse attacks the lower parts of the body, while flies feed predominantly over the top of the body. Adults have lesions primarily on their belly, udder, ears, snout, and vulva.

The diagnosis is primarily made by identifying the typical lesions in the typical locations. Differential diagnoses include any of the vesicular diseases, pityriasis rosea, allergic skin reactions, sunburn, or staphylococcal or streptococcal epidermitis. The presence of intracytoplasmic inclusion bodies along with central nuclear clearing in affected epithelial cells is a hallmark sign of this disease.

Treatment Supportive care should be given to prevent secondary bacterial skin infections.

Prevention/Control Affected animals should be isolated, and sanitation and pest control should be improved.

Necropsy Gross lesions are most commonly found on abdomen, chest, and legs, and only in severe cases involve the oral cavity and main airways. Early lesions consist of erythematous macules and papules, and later lesions progress to pustules and scabbing. Microscopic findings are related to viral replication in the stratum spinosum, causing hydropic degeneration, necrosis of epithelial cells, and formation of pustules that involves the full thickness of the epidermis with one to three eosinophilic intracytoplasmic poxvirus inclusion bodies in epithelial cells (Teppema and De Boer, 1975).

c. Mange (Scabies)

Etiology *Sarcoptes scabiei* var. *suis* from the family Sarcoptidae is the cause of sarcoptic mange in swine. This is probably the most significant ectoparasite of swine. This mite is 0.5 mm in length, has four pairs of legs, and completes its entire life cycle within the layers of the epidermis. The time necessary for an egg to hatch and develop into a mature egg-laying female is 10–25 days. This is one of the more common swine diseases, but it is frequently overlooked, probably because the clinical signs may be perceived as normal and losses are not readily apparent. Demodectic mange caused by *Demodex phylloides* can also occur in swine; however, it is a rarity.

Epizootiology and Transmission Mange infestations are fairly common in small conventional swine herds in the US. Nursing piglets obtain the mites from an infected sow through direct contact. Breeding sows

with hyperkeratotic encrustations in their ears are the primary reservoirs of mites. Group housing of pigs, especially from various sources, will facilitate spread of mites although spread via environmental contamination is still possible, as mites can survive off the host for several days. Herd-to-herd transmission is by introduction of a carrier pig; other species are not known to harbor this mite.

Pathogenesis Young pigs or newly exposed older animals become pruritic due to a hypersensitivity response to the mites burrowing into the dermis and laying eggs (Davis and Moon, 1990). This generally occurs several weeks post infection. The first 3 weeks postinfection, the females burrow into the skin and a covering of keratinized encrustations develops which falls off after 7 weeks, after which the mites leave the burrows (Morsy *et al.*, 1989).

Clinical Signs/Diagnosis There are two clinical forms of sarcoptic mange in swine. The acute pruritic or allergic hypersensitive form affects younger, growing pigs. This is characterized by an intensely pruritic, erythematous papular dermatitis on the ventral abdomen, flank, and rump that develops 2–11 weeks after infection. Pigs with this form will rub the affected areas, often causing hair loss, abrasions, and thickened, keratinized skin. A reduced growth rate will be seen if the dermatitis is severe (Davies, 1995). It is difficult with this form to find the mites on skin scrapings.

The chronic or hyperkeratotic form is typically found in mature sows and boars. Thick, crusty scabs begin on the pinnae and spread to the neck and head, and contain numerous mites that are relatively easy to find on skin scrapings. Mortality is unlikely unless concurrent disease is severe.

An ELISA for serum antibody levels to *S. scabiei* can be used to diagnose along with periodic skin scrapings, and monitoring for prevalence of scratching and papular dermatitis lesions (Zimmermann and Kircher, 1998; Jacobson *et al.*, 1999; Wallgren and Bornstein, 1997; Bornstein and Wallgren, 1997; Hollanders *et al.*, 1997; Davies *et al.*, 1996). Differentials include causes of dermatitis in swine, such as exudative epidermitis, dermatomycosis, swine pox, parakeratosis, niacin and biotin deficiencies, sunburn, photosensitization, and insect bites (Greve and Davies, 2012).

Treatment Ivermectin is effective orally or subcutaneously and should be repeated in 14 days (Greve and Davies, 2012; Hollanders *et al.*, 1995). Doramectin intramuscularly has also been reported to be effective and has a greater persistent efficacy than ivermectin (Cargill *et al.*, 1996; Logan *et al.*, 1996; Saeki *et al.*, 1997; Yazwinski *et al.*, 1997; Arends *et al.*, 1999). Other acaricides, including amitraz, phosmet, and diazinon, are also effective. Two or more treatments at 1- to 2-week intervals are usually necessary to eliminate these mites.

Swine with unusually severe chronic hyperkeratosis should be culled from the group if possible. This should be followed by thorough cleaning of the environment.

Prevention/Control Allowing only mange-free SPF animals into the facility is the most effective and satisfactory method of prevention. Treatment of sows with a single dose of ivermectin 8 days prior to farrowing prevents transmission to piglets (Mercier *et al.*, 2002). It is feasible to maintain a herd free of *S. scabiei* if a good biosecurity and surveillance program is developed (Cargill *et al.*, 1997).

Necropsy Papular dermatitis is seen in growing swine with or without positive skin scrapings for the sarcoptic mites. The papules are manifestations of the hypersensitivity reaction, contain eosinophils, mast cells, and lymphocytes, and have an associated eosinophilic perivascularitis (Hollanders and Vercruyse, 1990; Greve and Davies, 2012). Histologic sections show mites in the deep stratum corneum and stratum malpighii, producing hyperkeratosis and acanthosis (Jones and Hunt, 1983).

Research Complications Sarcoptic mange should not result in direct loss of animals in a study since this disease is rarely associated with mortality unless there is concurrent disease. The intense rubbing is a potential threat to surgical incisions and implants in these models.

d. Lice (Pediculosis)

Etiology *Haematopinus suis* females are 4–6 mm in length and males, 3.5–4.75 mm. These are sucking lice and are the only species of louse that affects swine (Lapage, 1968).

Epizootiology and Transmission Transmission is by direct pig-to-pig contact, as this louse is host-specific and will not survive very long (less than 2–3 days) off the host. The life cycle is 23–32 days and is entirely in and on the skin of pigs. It is considered a vector for swine pox and *M. suis*.

Pathogenesis The three instars of the nymph stage and egg-laying females suck blood, causing irritation, pruritus, and anemia.

Clinical Signs/Diagnosis Young pigs may show pruritus, poor growth, and anemia. Lice can be found almost anywhere on the body but have a predilection for the skin on the flank area, neck, axilla, groin, and the inner ears. Their eggs, or nits, are 1–2 mm in length and attach to the hair shafts.

Treatment The same treatments that are effective for mites also work well for lice, including sprays, dips, dusts, and oral and injectable ectoparasiticides. Most are efficacious when given as two treatments 2 weeks apart. The avermectins (primarily doramectin) and ivermectin are available as oral or injectable treatments and are also effective for ascarids and lungworms (Logan *et al.*, 1996).

Prevention/Control The most reasonable and effective means of lice prevention is to allow only swine

known to be lice-free into the research facility. Feral populations of *Sus scrofa* have been found to be reservoirs for *H. suis* (Gipson *et al.*, 1999), and certainly contact with domestic populations should be prevented.

Necropsy Adults can be visualized without special techniques. Allergic dermatitis and mechanically induced skin lesions with hemorrhage may be found on some affected pigs (Nickel and Danner, 1979).

Research Complications Severe infestations may cause anemia in young swine, and the rubbing may damage surgical incisions. Furthermore, the use of potentially toxic treatments to remove the lice may interfere with some research studies.

6. Reproductive Diseases

a. Brucellosis

Etiology *Brucella suis*, particularly biovars 1, 2, and 3, is the only species of *Brucella* that causes systemic infection and clinical disease, including infertility, in swine. Biovar 3 is currently the most common cause of this disease in swine. Morphologically, this genus is a nonmotile, non-spore-forming, small gram-negative, aerobic bacillus or coccobacillus.

Epizootiology and Transmission Domestic swine populations are the primary sources for *B. suis*. The European hare (*Lepus capinensis*) is a carrier for biovar 2 and has been linked to brucellosis in European swine facilities. Feral pigs are also reservoirs in areas where contact with domestic swine can occur (Heinritzi *et al.*, 1999). In the US, *B. suis* biovars 1 and 3 have been eradicated (Olsen *et al.*, 2012).

Transmission is most frequently via contaminated discharges or tissues from infected swine being ingested by a susceptible animal or via contaminated food or water. Contaminated tissues include aborted fetuses and fetal membranes. Additionally, nursing piglets frequently become infected while suckling infected sows. *B. suis* is present in semen of infected boars and can be spread by natural breeding or artificial insemination.

Pathogenesis After mucosal exposure to organisms, they enter through follicle-associated epithelial cells (M cells) or by phagocytosis, travel to the local lymph nodes, gain entrance to macrophages and neutrophils, and multiply. This is followed by a bacteremia with seeding of organisms in other lymph nodes, the genital tract, placenta, joint fluids, and bone marrow (Olsen *et al.*, 2012).

Clinical Signs/Diagnosis The clinical signs of *B. suis* infection vary with the herd and range from no obvious disease to the classical signs, which include abortion, infertility, metritis, orchitis, lameness, spondylitis, and posterior paralysis. Clinical disease in piglets of weaning age usually consists of spondylitis and posterior paralysis (Olsen *et al.*, 2012). Differentials include other causes of infertility and abortion in swine, such as PPV and leptospirosis.

Treatment Infected swine should be euthanized. Antimicrobials are unlikely to eliminate the bacteria from swine.

Prevention/Control The best prevention is to allow only brucellosis-free swine from validated herds into a facility. To date, available live bacteria vaccines are not effective in eradicating brucellosis but can create antibodies which could interfere with a serologic surveillance programs. Currently, the most effective control paradigm is to combine vaccination with test-and-removal procedures and sanitation measures. If a closed herd is maintained with a good biosecurity program, it is feasible to keep it brucellosis-free.

Necropsy Gross lesions are variable but generally consist of one or more abscesses, and there may be erosions of mucous membranes and seminal vesiculitis (Olsen *et al.*, 2012; Deyoe, 1967). Aborted fetuses may appear normal, or there may be edema or evidence of a suppurative placentitis. Microscopic lesions consist of granulomatous inflammation in the endometrium, uterine glands, and placenta. In the fetus, suppurative seminal vesiculitis; pyogranulomatous foci in the liver; caseous necrotic foci adjacent to growth plate cartilages in the vertebrae; and abscesses in the kidneys, spleen, ovaries, lungs, brain, and other tissues may be seen (Olsen *et al.*, 2012; Deyoe, 1967).

Research Complications Research protocols involving any aspect of swine reproduction are at highest risk for brucellosis. *B. suis* is one of the most common species implicated in cases of human brucellosis. Investigators and veterinarians performing necropsies on infected animals are at risk for becoming infected and BSL-3 containment is recommended for safely working with pathogenic strains of *B. suis* (Olsen *et al.*, 2012). Brucellosis is a zoonotic and reportable disease in the US (Olsen *et al.*, 2012). Since the US is considered *Brucella* free, health certificates from USDA-accredited veterinarians are needed for travel.

b. Leptospirosis

Etiology The etiologic agent for this disease in swine consists of several serovars of *Leptospira interrogans* and *L. borgpetersenii* (Ellis, 2012). All are gram-negative, motile aerobic spirochetes. The serovar *Pomona* is the most common cause of clinical leptospirosis in swine, and serovars *Bratislava* and *Muenchen* are commonly found in serologic surveys and are sometimes associated with clinical disease. There are several other serovars, which are typically maintained in other mammalian hosts but are occasionally found to infect swine. These include *Icterohaemorrhagiae*, *Sejroe*, *Hardjo*, *Canicola*, *Grippotyphosa*, and *Tarassovi* (Ellis, 2012; Cowart, 1995).

Epizootiology and Transmission Transmission from animal to animal is by direct or indirect contact with a carrier animal, which harbors the leptospire in

the renal tubules or genital tract. Leptospire are shed from carrier animals in urine and genital fluids into the environment. Feral swine are potential sources of serovars *Pomona* and *Bratislava* for outdoor facilities where contact can occur (Saliki *et al.*, 1998; Mason *et al.*, 1998). Venereal transmission is thought to be the mode of spread for serovar *Bratislava* because sows and boars harbor it in the reproductive tract and urinary excretion is relatively low. Survival of the bacteria out of the host is favored by warm, moist conditions. The route of infection is believed to be via the mucous membranes of the mouth, nasal passages, eye, and vagina, although transmission via milk has not been shown experimentally (Ellis, 2012).

Swine are typically maintenance hosts for serovars of the serogroups *Pomona*, *Australis* (serovars *Bratislava* and *Muenchen*), and *Tarassovi*. Infection with other serovars is considered incidental. Typically, only a limited number of serovars will be endemic in a given area and host species (Ellis, 2012).

Pathogenesis A bacteremia develops that results in seeding of *Leptospira* organisms in most organs, including the liver, the pregnant uterus, and the proximal renal tubules, where they persist, multiply, and are voided for varying periods in the urine.

Clinical Signs/Diagnosis The acute form is characterized by a mild transient anorexia, listlessness, diarrhea, and pyrexia that resolves within a week and usually goes unrecognized. Rarely, piglets <12 weeks of age are infected with strains from the serogroup *Icterohaemorrhagiae*, and have hemoglobinuria, and jaundice. The chronic form is characterized by late-term abortions, stillbirths, and weak newborn piglets. This is particularly true of serovar *Pomona* infection. Infertility of the sow is seen following infections due to serovar *Bratislava*; however, reproductive performance following abortions due to *Pomona* is not affected (Ellis, 2012). The microscopic agglutination test is commonly utilized for serologic monitoring of herds. Diagnosis may also be via serological tests for antibodies to leptospire or via demonstration of leptospire within pig tissues. Differential diagnoses include parvovirus, brucellosis, and PRV.

Treatment Medicating feed for periods of 4 weeks or more with oxytetracycline or chlortetracycline will help control clinical signs until a vaccination program can be established. Individual dosing of pigs with dihydrostreptomycin-penicillin G, oxytetracycline, erythromycin, or tylosin may help eliminate serovar *Pomona* from the renal tubules (Ellis, 2012; Alt and Bolin, 1996).

Prevention/Control A biosecurity program that prevents potential vectors, such as rodents and feral swine, from making direct or indirect contact with the swine in the facility is essential to prevent introduction and minimize spread. Artificial insemination can be

used to advantage to prevent spread or introduction of serovar *Bratislava*. Vaccination with bacterins will reduce the incidence of infection but not eliminate the disease from the herd. Immunity is short-lived, which necessitates revaccination at least every 6 months (Ellis, 2012; Cowart, 1995).

Necropsy In acute leptospirosis, few changes are present, but may include petechial or ecchymotic hemorrhages in the lungs and kidneys. In chronic disease, lesions are confined to the kidneys and consist of small gray lesions on the renal cortex. Glomeruli may be swollen or atrophic and cellular casts may be found in the lumen of renal tubules lined by atrophic epithelial cells (Ellis, 2012). The primary lesion is damage to endothelial cell membranes.

Research Complications Leptospirosis will interfere with studies involving swine reproduction or fetal surgery, due to the increased rate of late-term abortions associated with the chronic form of the infection.

c. Porcine Parvovirus

PPV is a disease of swine characterized by embryonic and fetal infection which is manifest as stillbirths, mummification, embryonic death, and infertility (SMEDI) when susceptible sows and gilts are exposed to the virus between 6 and 70 days of gestation. The infection typically causes no observable clinical signs in the infected female, and its major impact on animal health relates to the agent's ability to interfere with live births. Porcine parvovirus is one of the major infectious causes of embryonic and fetal death (Mengeling *et al.*, 1991).

Etiology The disease is caused by PPV-1, a single-stranded DNA virus classified in the genus *Parvovirus*, family *Parvoviridae*. Novel porcine parvoviruses recently identified include PPV2, hokovirus, PPV4, and PPV5, but the role of these viruses in pigs remains unclear (Xiao *et al.*, 2013).

Epizootiology and Transmission PV is ubiquitous among swine worldwide. In general, infection is enzootic in most herds, and with rare exception, sows are immune. Also, gilts usually contract PPV before conception and develop an active immunity that persists through life. Disease occurs when gilts do not have circulating antibody to the virus. Gilts are most commonly infected oronasally and prenatal pigs are infected transplacentally, although the exact mechanism remains unclear.

Nursing pigs absorb protective PPV antibody from colostrum. These titers diminish to levels that are not protective when the piglets are 3–6 months of age. The significance of the passively acquired antibody is that it interferes with the development of active immunity until the 3- to 6-month mark (Paul *et al.*, 1980).

The major reservoir for PPV is environmental. The virus is thermostable and resistant to many disinfectants. It has been shown that pigs transmit PPV in feces

for about 2 weeks after exposure, but the pens they were housed in remained infectious for up to 4 months through which the virus may be transmitted to pigs via fomites (Truyen and Streck, 2012; Mengeling and Paul, 1986).

It is also possible that immunotolerant carriers of PPV, resulting from early *in utero* infection but not death, are carriers (Johnson, 1973). Boars may also play a role in dissemination of the disease. During acute infection with the agent, the virus can be shed in semen. Virus can also be isolated from scrotal lymph nodes up to 35 days post exposure.

Pathogenesis The virus replicates initially in tonsils after which it reaches the lymphatic system leading to cell-free viremia. Placental cells do not support porcine parvoviral infection nor can the virus cross the epitheliochorial placenta (Joo *et al.*, 1976). Current research points to the virus infecting fetal lymphocytes within the circulatory system of pregnant sows (Mengeling *et al.*, 2000; Rudek and Kwiatkowska, 1983). The virus requires the host DNA polymerase to replicate and thus can only produce viral particles in S-phase. The virus has a propensity to invade rapidly dividing cells.

Clinical Signs/Diagnosis Acute infection of both postnatal and pregnant dams is subclinical; however, the pigs will have a transient, mild leukopenia within 10 days after the initial exposure. Maternal reproductive failure is the major sign of infection and is the only clinical sequela to exposure. There is no evidence that PPV impacts either fertility or libido of boars (Thacker *et al.*, 1987).

Dams can cycle back into estrus, farrow fewer pigs per litter, or farrow a large proportion of mummified fetuses. Typically, an epizootic of PPV starts as a subclinical infection and culminates with the delivery of mummified fetuses, usually at or near term. Most of the infected fetuses have a crown-rump length of 17 cm or less because those infected after day 70 are able to respond to the viral assault and survive (Mengeling *et al.*, 1993). Infertility, abortion, stillbirth, neonatal death, prolonged gestations, and reduced neonatal viability have also been attributed to PPV. PPV is one of the primary diagnostic considerations when swine exhibit embryonic or fetal death. Gilts are the population primarily at risk. The lack of maternal illness, abortions, or fetal developmental anomalies differentiates this disease from other causes of reproductive failure. In addition, identifying mummified fetuses that have a crown-rump length of ≤ 17 cm is a strong indicator that PPV is the infectious agent at play.

The definitive diagnosis can be made by identifying viral antigen by immunofluorescent (IF) microscopy from sections of fetal tissues. Serologic testing for antibodies (i.e., ELISA) is recommended only when tissues from mummified fetuses are not available. Results from

serum are of value if antibody is not detected or if samples are collected at intervals that document seroconversion for PPV. Since PPV is ubiquitous, the presence of antibody in a single sample is meaningless. Detection of antibody in sera of fetuses/stillborn before they nurse is evidence of *in utero* infection, as the maternal antibody does not cross the placenta (Chaniago *et al.*, 1978). Differential diagnoses should include PRRSV, brucellosis, leptospirosis, PRV, toxoplasmosis, and nonspecific uterine infection.

Prevention and Treatment There is no treatment for the reproductive failure associated with PPV. Prevention involves either naturally infecting gilts with PPV or vaccinating them with a modified live vaccine prior to pregnancy. Through herd-management practices, natural infections can be promoted. Seronegative gilts can be housed with seropositive sows. Vaccines are used extensively in the US. They are administered several weeks before conception but after the disappearance of passively acquired colostrum antibody. In essence, the window for vaccination is small in herds keyed for production. Vaccination for boars is also recommended.

Necropsy Gross lesions are confined to the placenta, which may be edematous and have white, mineralized deposits and stunted fetuses with prominent blood vessels on their surfaces, petechial hemorrhages, edema, enlarged dark liver and kidneys, serosanguinous fluid in body cavities, and mummification (Joo *et al.*, 1977; Hogg *et al.*, 1977). Microscopic findings in the fetuses include vasculitis with hypertrophy of endothelial cells, and perivascular accumulations of mononuclear cells around vessels in the gray and white matter of the cerebrum, brainstem, and meninges, in the interstitial area around glomeruli, portal areas of the liver, and the placenta (Joo *et al.*, 1977; Hogg *et al.*, 1977).

d. Porcine Reproductive and Respiratory Syndrome

This disease was first identified in the US in the late 1980s. Hallmark signs include reproductive disorders, high piglet mortality, and respiratory disease seen in a wide age range of animals. The disease is known officially as PRRS (porcine reproductive and respiratory syndrome) but had been referred to in the literature as SIRS (swine infertility and respiratory syndrome). The disease is now endemic in many countries and has escalated into one of the major causes of reproductive losses and respiratory disease in swine.

Etiology The causative agent is a single-stranded RNA virus classified in the order *Nidovirales*, family *Arteriviridae*, and genus *Arterivirus*. This agent shares structural and functional organization with others in the genus, including lactate dehydrogenase-elevating virus, equine arteritis virus, and simian hemorrhagic fever virus. These viruses in general are known to have high rates of mutation. There are two distinct genotypes, Type

1 (Lelystad) found primarily in the EU and Type 2 (VR-2332), found primarily in the US, which have genomic and serologic differences. The US isolates differ genomically but cross-react serologically. Infections in vaccinated herds lend suspicion that immunization does not provide protection across all isolates and recent studies continue to show lack of vaccine protection from heterologous viruses (Geldhof *et al.*, 2012). Likewise, if there is great enough antigen variation between strains, a new strain may cause disease in an enzootically infected herd (Tian *et al.*, 2007; Li *et al.*, 2007).

Epizootiology and Transmission This virus is spread predominantly through direct contact between infected and naive pigs, although the route of fetal PRRSV infection has not been identified. Once infected, pigs become persistently infected (Zimmerman *et al.*, 2012a). The virus establishes a foothold by infecting macrophages located within mucosal surfaces. The virus is believed to be limited to domestic swine. The disease does persist in infected swine in a transmissible, viable state, often without stimulating antibody production, thereby making serologic screening for the disease inaccurate. Pigs subclinically infected with PRRSV are thought to be the key factor in disease transmission within herds, and shedding level varies depending on virus variant (Cho and Dee, 2006; Rossow, 1998). The virus has been found in serum, oropharyngeal fluids, semen, feces, and urine, and animals are susceptible via intranasal, intramuscular, oral, intrauterine and vaginal exposure (Rossow, 1998). Animals are extremely susceptible to infection via skin breaks, including tail docking and tattooing (Zimmerman *et al.*, 2012a). Virus is inactivated by heat and drying, but remains infective in cool temperatures and high humidity. Transmission by aerosolization is possible, though routinely occurs only over short distances.

Pathogenesis The virus has been shown to enter via the nasal epithelium, bronchial epithelium, and tonsillar and pulmonary macrophages, followed by replication in alveolar macrophages, with a subsequent viremia and spread to lymphoid organs and lungs (Gomez-Laguna *et al.*, 2010; Rossow *et al.*, 1996a). PRRSV replicates in CD163(+)/sialoadhesin (+) macrophages, which include pulmonary alveolar macrophages, pulmonary intravascular macrophages, and lymphoid tissue macrophages (Zimmerman *et al.*, 2012a). Migration of infected macrophages across the placenta may be one of the mechanisms for transplacental infection of fetuses. PRRSV induces increases in IL-10 which results in downregulation of cytokines involved in virus clearing (IFN- α , IFN- γ , TNF- α and IL-12p40) (Gomez-Laguna *et al.*, 2010). Cytokines released in PRRS are thought to originate from septal macrophages, not the infected macrophages (Gomez-Laguna *et al.*, 2010).

Clinical Signs/Diagnosis The clinical presentation of PRRSV infection depends on the age of the pig and

the gestation status when infected. In addition, the clinical presentation can vary depending on complicating infections with viruses or bacteria. Late gestational abortions typically occur when animals are infected during the third trimester and can occur sporadically or sweep throughout the population of animals. Other reproductive manifestations that have been documented include delayed parturition and premature farrowing resulting in mummified or stillborn fetuses. Clinical signs in infected females vary from none to anorexia, fever, pneumonia, agalactia, red/blue discoloration of ears and vulva, subcutaneous edema, and a delayed return to estrus.

Clinical signs in PRRSV-infected newborn pigs also vary in frequency and severity. Dyspnea and tachypnea are the most characteristic clinical signs, with other signs including periorbital and eyelid edema, conjunctivitis, blue discoloration of the ears, diarrhea, and CNS signs. Mortality can reach 100%. As the pigs reach postweaning age, the clinical signs shift to include fever, pneumonia, failure to thrive, and significant mortality caused by otherwise non-life-threatening concurrent bacterial infections. PRRSV should be suspected in litters delivered prematurely but after 100 days of gestation.

The susceptibility and resulting impact of secondary bacterial infections in pigs infected with PRRSV depends on the PRRSV isolate, the swine genetic composition, management practices, and environmental factors. Subclinical infections occur commonly as the pig continues to mature, with the only indication of infection being seroconversion to the virus. Occasionally, a transient fever and inappetence or loss of libido can be observed.

Hematologic parameters congruent with infection include a decrease in lymphocytes, neutrophils, and monocytes at 4 days post infection, with a concurrent increase in band neutrophils. Four-week-old pigs had decreased RBC counts, hemoglobin levels, and hematocrits (Rossow *et al.*, 1994).

The viral infection is most accurately diagnosed through the demonstration of PRRSV by virus isolation, fluorescent antibody examination, immunohistochemistry, or PCR in concert with clinical signs and characteristic histologic lesions. Exposure to the virus can be documented through the use of serology testing for anti-PRRSV antibodies; however, if pigs are vaccinated with the modified live-PRRSV vaccine, the current serologic tests cannot differentiate between vaccine virus and field PRRSV isolates. It is also important to note that pigs vaccinated with the modified live vaccine can transmit vaccine virus to naive pigs, resulting in infection and seroconversion of the naive animal (Rossow, 1998).

The virus can most easily be located in lung tissue, lymphoid tissue, heart, brain, and nasal turbinates. Again, it is important to note that modified live-PRRSV

vaccine virus can also be identified from these tissues, and pathogenic PRRSV isolates must be differentiated from the vaccine virus. Differential diagnoses include PPV, PRV, CSF, CMV, PCV2, SIV, and leptospirosis.

Treatment Once pigs show signs of disease, supportive therapy should be implemented. This can include antibiotics to control concurrent bacterial infections and vitamin and food supplements until animals regain their appetite.

Prevention/Control Vaccination of pigs with a modified live-PRRSV vaccine has protected pigs from clinical disease when the pigs were challenged with heterologous PRRSV isolates; yet, other reports have shown that the vaccine is not universally protective against all isolates of PRRSV. Efforts should be made to obtain pigs from sources that are free of PRRSV. Pigs coming from different sources should be isolated from each other.

Necropsy PRRSV-infected litters contain normal pigs, small weak piglets, fresh stillborn, autolyzed stillborn, and mummified fetuses. Gross lesions in young piglets include mottled lungs with tan foci of consolidation; lymphadenopathy of the mesenteric and middle iliac nodes, which are tan and may contain cysts, moderately enlarged and rounded hearts, and clear fluid in the pericardial space and abdominal cavity.

Microscopic lesions consist of a multifocal lymphohistiocytic myocarditis; an interstitial pneumonia with mononuclear cell infiltrates, resulting in septal thickening; peribronchial and peribronchiolar lymphohistiocytic cuffing; hypertrophy and hyperplasia of type II pneumocytes; and filling of alveolar spaces with necrotic and normal macrophages. There is also follicular hypertrophy, hyperplasia, and necrosis in lymphoid tissues, and a mild lymphohistiocytic choroiditis with cuffing of vessels in the meninges, choroid plexus, and brain (Halbur *et al.*, 1995). Lesions in fetuses consist of myocarditis with fibrosis, arteritis, and encephalitis (Rossow *et al.*, 1996b).

7. Vesicular Diseases

Vesicular diseases are important in swine and are presented here briefly.

a. Foot-and-Mouth Disease

Etiology Foot-and-mouth disease virus (FMDV) is in the family Picornaviridae, genus *Aphthovirus*.

Epizootiology/Transmission FMDV is enzootic in large parts of Africa, Asia, and the Middle East, and South America. FMDV affects members of the order Arteriodactyla. The virus is typically spread via contact of mucus membranes, abrasions or cuts in the skin, or ingestion of contaminated foodstuffs, but can also be transmitted over long distances via aerosol. All secretions and excretions from infected animals contain infectious virus. FMDV can remain infectious within the environment for extended periods.

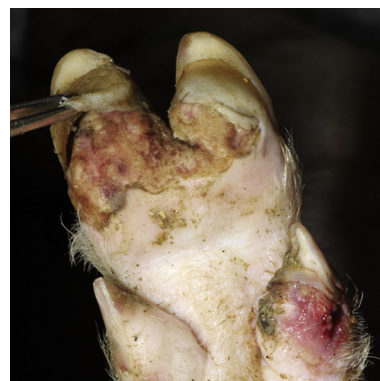

FIGURE 16.26 Foot-and-mouth disease virus. There is separation of the hoof keratin from underlying tissues. Courtesy of ISU Veterinary Diagnostic Laboratory.

Pathogenesis Typically, the pharynx is the primary site of infection, unless the virus enters the skin through a wound. The virus needs access to live cells on the surface and does not enter through cornified tissue (Alexandersen *et al.*, 2012). After initial replication, the virus enters the circulation and disseminates to the areas of amplification such as the skin, tongue, and mouth.

Clinical Signs/Diagnosis Pigs display fever and formation of vesicles in and around the mouth and feet (Fig. 16.26). Lesions on the feet are often interdigital, with the coronary band being especially predisposed due to the vascularity. Lesions on the feet result in the animal being lame and often 'dog-sitting'. Animals also show signs of depression and anorexia. If pregnant sows are infected with FMDV, they may abort.

Real-time RT-PCR is now used diagnostically to replace the combined ELISA/virus isolation system (Alexandersen *et al.*, 2012).

Treatment There is no treatment for foot-and-mouth disease in pigs. Euthanasia of all affected and susceptible animals at the infected site is recommended.

Prevalence/Control Increased biosecurity is paramount to preventing spread of this virus. Vaccines will not prevent infection, but may decrease clinical signs in those infected.

Necropsy Vesicles are often in and around the mouth and on the feet, but may also be present on the snout, teats, mammary gland, prepuce, vulva, and other sites. Oral lesions most commonly affect the tongue, and foot lesions are most often interdigital, at the heel bulb, and coronary bands. Lesions around coronary bands may lead to sloughing of claws. Histologically, there is ballooning degeneration in stratum spinosum of cornified stratified squamous epithelium. This is followed by intercellular edema, necrosis, and infiltration by mononuclear cells and granulocytes.

Research Complications The need to euthanize the animals results in loss of the colony. FMD is a reportable disease.

b. Swine Vesicular Disease

Etiology Swine vesicular disease virus is an *Enterovirus* in the family Picornaviridae.

Epizootiology/Transmission Transmission to new farms and animals is primarily through movement of animals, fomites, or feeding of contaminated waste food (Hedger and Mann, 1989). The virus can remain infectious for months. One major difference between SVDV and FMDV is that SVDV has not been shown to be transmitted via aerosol.

Pathogenesis The virus enters the pig via mucous membranes or abrasions of the skin.

Clinical Signs/Diagnosis Clinically, pigs have mild fever with rare lameness. Virus isolation and RT-PCR are used to diagnose the disease.

Treatment Treatment is not recommended as lesions are similar to FMD. Euthanasia is recommended.

Prevalence/Control SVD has only been isolated in Asia and Europe (Alexandersen *et al.*, 2012). It is on the OIE list because lesions caused by swine vesicular disease virus are indistinguishable from those caused by FMDV. Italy is one of only a few countries that actively screen for SVD antibodies, and recent outbreaks were detected via this screening (Alexandersen *et al.*, 2012). It is suspected that the virus is present in more countries than in which it has been reported.

Necropsy Vesicles are present at the coronary bands, snout, tongue, and lips. Lesions are indistinguishable from FMDV.

Research Complications Research is impacted by the loss of cohort or colony due to euthanasia. SVDV is a reportable disease.

c. Vesicular Exanthema of Swine

Vesicular exanthema of swine (VES) is caused by the vesicular exanthema of swine virus, genus *Vesivirus* in the Caliciviridae family (Knowles and Reuter, 2012). A disease indistinguishable from VES is present in wild sea lions in California, and occasionally in wildlife. After a fever, vesicles appear at snout, lips, tongue, oral mucosa, as well as sole, interdigital space and coronary band (McGavin and Zachary, 2007). This is a reportable disease.

d. Vesicular Stomatitis

Vesicular stomatitis (VS) infection in pigs is indistinguishable from FMD, and therefore is classified a notifiable disease (Health, 2013a). Vesicular stomatitis virus is in the genus *Vesiculovirus* and family Rhabdoviridae. Transmission is via aerosol or contact with experimental transmission via flies (Health, 2013a). Infection is localized to the site of inoculation. If the area is un-haired (oral

mucosa, snout, coronary bands), vesicles develop within 1–3 days, whereas if the area is haired, seroconversion with subclinical disease is seen (Swenson *et al.*, 2012). Clinical signs include excessive salivation, foot lesions with possible separation of the claw, and lameness. Virus detection is via tissue tags, vesicular fluid, or biopsy of affected area. Treatment is by supportive care and disinfection is crucial to prevent spread. VS is a zoonotic disease.

e. Classical Swine Fever

Etiology Classical swine fever (CSF) virus is in the family Flavivirus, genus *Pestivirus*. It is also known as hog cholera in the literature.

Epizootiology/Transmission Pigs are the only natural reservoirs of the virus, and it is included here for completeness, as it should be eradicated from all commercial breeding herds. The virus continues to circulate in China, Africa, Central America, and parts of South America (Kirkland *et al.*, 2012a). Transmission is oronasal, or by ingestion of infected material, although airborne transmission has been shown experimentally along with seminal transmission (Elbers *et al.*, 2001; Kirkland *et al.*, 2012a; De Smit *et al.*, 1999). The virus can survive in certain conditions for prolonged periods (Kirkland *et al.*, 2012a).

Pathogenesis Primary viral replication is in the tonsils followed by spread to lymph nodes, peripheral blood, and bone marrow. Not fully understood are the effects on immune system, endothelium, and epithelial cells, as well as thrombocytopenia and consumption coagulopathy followed by disseminated intravascular coagulation (Maxie and Jubb, 2007). Experimental infection of animals has shown platelet activation followed by macrophage activation and subsequent phagocytosis of platelets, which may explain the thrombocytopenia (Bautista *et al.*, 2002). Bone marrow megakaryocytic dysmegakaryocytopoiesis has also been described (Gomez-Villamandos *et al.*, 2003). Primary cytokines involved in this disease are TNF- α , IL-6, and IL-1 α (Sanchez-Cordon *et al.*, 2005).

Clinical Signs/Diagnosis Animals with CSF have pyrexia, anorexia, lethargy, conjunctivitis, respiratory signs, and constipation followed by diarrhea (Kirkland *et al.*, 2012a). Signs are the same in acute and chronic forms; only the time course is different.

Virus isolation, RT-PCR, virus neutralization, and ELISA are all used to diagnose CSF. Differentials include African swine fever, BVDV, PRRSV, PCV2, salmonellosis, erysipelas, streptococcosis, leptospirosis, and coumarin poisoning.

Prevention and Control Some CSF-free areas try to maintain a 'no vaccination' policy and eradicate infected herds, while those in endemic areas vaccinate to prevent disease (Kirkland *et al.*, 2012a).

Confounding Factors Bovine viral diarrhea virus (BVDV) is usually only pathogenic for fetal pigs, but it

can also infect pigs naturally, and pathological lesions can be indistinct from those of CSF (Maxie and Jubb, 2007; Kirkland *et al.*, 2012a). The primary problem with infection of pigs by BVDV is that it confounds accurate detection of CSF. Infection is typically cross-species, and BVDV lesions may be mistaken for CSF, thus complicating CSF detection and control.

Necropsy The presence of lesions is variable, but most commonly hemorrhage of the peripheral lymph nodes and renal petechiae and ecchymoses are present, while splenic infarction is nearly pathognomonic for the disease (Maxie and Jubb, 2007). Lesions consistent with DIC may also be seen.

8. Newly Reported or Emerging Infectious Diseases/Agents

a. Nipah Virus

Etiology Nipah virus is a single-stranded negative sense RNA virus in the family Paramyxovirus, genus *Henipavirus*. There are strain differences between isolates from different geographic regions.

Epizootiology/Transmission Initially identified in Malaysia in 1999, the virus has since emerged in Bangladesh and India. Pigs are an amplifying host; however, bats are the reservoir host and secrete virus in urine where pigs may ingest items containing infectious viral particles and become infected (Williamson and Torres-Velez, 2010). Close contact is required for transmission (Fogarty *et al.*, 2008).

Pathogenesis Vascular, nervous, and lymphoreticular systems are targets for the virus. The virus is able to circumvent the host interferon response (Williamson and Torres-Velez, 2010).

Clinical Signs Pigs are asymptomatic or have acute febrile disease with respiratory/CNS signs (Kirkland *et al.*, 2012b).

Treatment Euthanasia is the treatment of choice.

Prevention/Control Recombinant vaccines have been used in pigs.

Necropsy Enlarged lymph nodes, congestion and edema in meninges, pulmonary consolidation, and distended interlobular septa are associated with Nipah infection (Kirkland *et al.*, 2012b). Syncytial cells located in areas of interstitial pneumonia contain intracytoplasmic inclusion bodies (Torres-Velez, 2008).

Research Complications Nipah is a BSL-4 agent and is zoonotic.

b. Porcine Lymphotropic Herpesviruses

Porcine lymphotropic herpesvirus (PLHV) has been associated with a porcine lymphotropic disease with high mortality, similar to that of human post-transplantation lymphoproliferative disease, in pigs immunosuppressed for transplantation studies

(Mettenleiter *et al.*, 2012; Huang *et al.*, 2001; Chmielewicz *et al.*, 2003; Ehlers *et al.*, 1999). There is also concern that pig-human xenotransplantation may result in human disease from this virus (Ehlers *et al.*, 1999; Goltz *et al.*, 2002).

Etiology PLHV is in the Herpesviridae family, subfamily Gammaherpesvirinae, genus *Macavirus*, species *suid herpes-3,-4,-5*. *Suid herpesvirus-3,-4,-5* correspond to PLHV-1, -2, -3, respectively (Davison *et al.*, 2009).

Epizootiology/Transmission PLHV appear to be present in pigs worldwide with no outward disease in healthy individuals (Goltz *et al.*, 2002).

Pathogenesis PLHV predominantly infects B cells (Mettenleiter *et al.*, 2012).

Clinical Signs/Diagnosis There is no known disease unless animals are immunosuppressed. In immunosuppressed minipigs, there was profound B-cell proliferation and the majority of animals died (Huang *et al.*, 2001). Clinical signs included lethargy, fever, anorexia, and enlarged lymph nodes (Huang *et al.*, 2001). Diagnosis is typically via PCR specific for each of the lymphotropic viruses (PLHV-1, -2,-3).

Prevention/Control Caesarian derivation may reduce the prevalence of PLHVs (Tucker *et al.*, 2003).

Necropsy Macroscopic findings included enlarged lymphoreticular organs, airway obstruction, and respiratory failure (Huang *et al.*, 2001). Disease is only manifest in immunocompromised individuals.

Research Complications There is concern in xenotransplantation studies that lymphoproliferative disease due to PLHV will occur after immunosuppression of the host.

c. Ovine Herpesvirus-2

A naturally occurring disease similar to malignant catarrhal fever (MCF) has been reported in pigs, although rare and poorly documented (Alcaraz *et al.*, 2009; Loken *et al.*, 1998).

Etiology The disease in pigs is caused by ovine herpesvirus 2 in the family Herpesviridae, subfamily Gammaherpesvirinae, genus *Macavirus* (Davison *et al.*, 2009). Porcine disease has not been associated with other viruses that cause MCF in cattle (Alcelaphine herpesvirus 1).

Epizootiology/Transmission The mode of transmission is uncertain, but is suspected to be via nasal secretions. There have been reports of pigs becoming ill after having contact with sheep.

Clinical Signs/ Diagnosis Pigs with MCF display high persistent fever, anorexia, depression, recumbency, foul-smelling nasal discharge, ocular discharge, bilateral corneal edema, keratoconjunctivitis, ataxia, tremors, and possible convulsions (Alcaraz *et al.*, 2009). Diagnosis is dependent on clinical signs, histology, and presence of virus-specific antibodies (Mettenleiter *et al.*, 2012). This

disease can be mistaken for PRV, CSF, ASFV, porcine enterovirus, PCV2, and rabies.

Prevention/Control There is currently no vaccine in pigs. Decreasing any interactions pigs may have with sheep will help prevent cross-species transmission.

Necropsy There are multifocal cyanotic areas or petechiae on the skin, crusts on the skin, enlarged hyperemic lymph nodes, and mucopurulent exudate in airways. The spleen and liver are engorged (Alcaraz *et al.*, 2009). The most consistent and histological lesion is acute vasculitis in the CNS and other organs characterized by adventitial and transmural mononuclear cells with fibrinoid necrosis of vessel walls in many tissues. The myocardium, spleen, CNS, skin, and kidneys are commonly affected (panarteritis) (Mettenleiter *et al.*, 2012).

d. Hepatitis E

Hepatitis E is in the genus *Hepevirus* and there are four known genotypes of hepatitis E, of which genotypes 3 and 4 infect pigs (Temmam *et al.*, 2013). Infection in pigs is primarily without clinical signs. Genotype 3 infection of pigs leads to multifocal lymphoplasmacytic hepatitis and focal necrosis, but no elevation of liver enzymes has been noted (Vasickova *et al.*, 2007; Krawczynski *et al.*, 2011). Transmission is typically fecal-oral (Vasickova *et al.*, 2007). Exposure of humans to infected swine can lead to transmission of the virus to humans (Temmam *et al.*, 2013). Swine veterinarians have been shown to have detectable antibody titers to the virus (Meng *et al.*, 2002).

e. Ebola Virus

Ebola viruses are in the family Filoviridae, genus *Ebolavirus*, species *Reston ebolavirus* (REBOV). Pigs showed signs consistent with severe form of PRRSV and were found to be infected with PRRSV, REBOV, and in some cases PCV2 (Barrette *et al.*, 2009). The primary differential is PRRSV (Rowland *et al.*, 2012). Pigs have also been experimentally infected with Zaire ebolavirus in which transmission to NHP has been demonstrated (Weingartl *et al.*, 2012).

REBOV is a subclinical disease in pigs, and only causes lesions if infection occurs via a systemic route (Marsh *et al.*, 2011). Current knowledge indicates that REBOV is involved in outward disease only if another agent is present.

f. Japanese Encephalitis

Japanese encephalitis virus (JEV) is a member of the family Flaviviridae, genus *Flavivirus*. While mosquitos transmit the agent, the pig is a natural reservoir of JEV (Grand, 2012). Clinical signs in pigs include testicular degeneration, infertility, mummified fetuses, and piglets with birth defects, reproductive failure, and still

births (Grand, 2012). Reproductive failure is only seen when sows are infected before 60–70 days of gestation (Williams *et al.*, 2012). Experimental infection of 3-week-old piglets resulted in non-suppurative encephalitis of frontal and temporal lobes. The spinal cord was also affected (Yamada *et al.*, 2004). Differentials include PPV, PRV, PRRSV, toxoplasmosis, and leptospirosis. Virus isolation is required to diagnose the disease. Humans can also be infected by the virus, but only via a mosquito (Mackenzie *et al.*, 2004).

B. Metabolic/Nutritional Diseases

1. Porcine Stress Syndrome

Etiology Porcine stress syndrome (PSS) refers to a cascade of physiologic events and clinical signs that occur in pigs that have a mutation in the calcium-release channel protein (ryanodine receptor [RYR]). This mutation results in a hypersensitive triggering mechanism of the calcium-release channel in skeletal muscle sarcoplasmic reticulum in response to various stressors, such as gas anesthetics or stressful environmental conditions. The lack of proper calcium control within the membranous portions of the sarcoplasmic reticulum and mitochondria is thought to initiate the cascade of events that results in the syndrome (O'Brien *et al.*, 1991; Fujii *et al.*, 1991). Stress-susceptible pigs are also known to over-respond to stressful stimuli, with excessive β -adrenergic receptor stimulation, lower rates of lactate, alanine, and aspartate conversion to carbon dioxide by the liver, abnormal phosphorus metabolism, and a much higher cortisol and thyroxine turnover rate.

Animals carrying the genetic defect in RYR had been found throughout the world. Genotypic analyses have indicated that the mutation arose from a single founder animal. The mutation is found in five major breeds of swine: Landrace, Yorkshire, Duroc, Pietrain, and Poland China and other breeds, including miniature potbellied pigs (Claxton-Gill *et al.*, 1993). The mode of inheritance is autosomal recessive with variable penetrance. With the advent of genetic testing, the disease due to the RYR mutation has largely been bred out of existence in research and production animals, but does remain in the show pig population (Woods and Tynes, 2012). However, a newly identified mutation (R1958W) in the dystrophin gene has recently been shown to be responsible for loss of animals due to transport stress (Nonneman *et al.*, 2012). This syndrome has also been reported in humans, dogs, cats, and horses.

Clinical Signs In a laboratory setting, development of PSS has most commonly been associated with exposure to halothane and succinylcholine; however, methoxyflurane, enflurane, and isoflurane have all been shown to be capable of eliciting a reaction in susceptible

swine. The course of the disease is variable, ranging from abatement of clinical signs when anesthesia is terminated to fatality.

Initial signs include tachycardia, tachypnea, muscle rigidity, and hyperthermia. Clinicopathologic changes include metabolic acidosis, myoglobinemia, hyperkalemia, and hyperglycemia. These metabolic derangements frequently lead to cardiovascular collapse and death. In addition to the typical manifestation, nonrigid and normothermic forms have been described. Signs of this disease are less pronounced in young pigs and those that are heterozygous for the trait. In non-anesthetized pigs, stressful situations will lead to the early signs of the disease, which include muscle and tail tremors. Progression of the syndrome leads to dyspnea, blanched and reddened areas on the skin, increased body temperature, and cyanosis. Muscle rigidity and cardiovascular collapse follow. This syndrome is also known as malignant hyperthermia.

Treatment Early recognition of the disease is the key to treatment. Anesthetic delivery should be discontinued immediately and 100% oxygen delivered. Additional treatment includes sodium bicarbonate to combat the metabolic acidosis and hyperkalemia. Active cooling of the animal may be done by ice packing and IV administration of cooled fluids, or by gastric and/or rectal lavage with iced saline. Dantrolene, an agent that prevents PSS by decreasing release of calcium from the sarcoplasmic reticulum while allowing calcium uptake to continue, is highly effective in stopping the progression of the syndrome when administered at the onset of signs. After the crisis is alleviated, the animal must be monitored closely for 48h; redevelopment of the syndrome in response to minor stressors can occur. Dantrolene (3.5–5mg/kg) can also be given as preventive therapy in animals known to be susceptible and to treat (Flewellen and Nelson, 1980; Ehler *et al.*, 1985).

Prevention/Control The disease is best controlled by identifying those animals that carry the genetic mutation and eliminating them from the breeding stock. A readily available, inexpensive DNA-based test can be used to screen for the mutation (O'Brien *et al.*, 1993). The RYR mutation has largely been bred out of swine herds.

Necropsy Pigs exhibiting this syndrome present with a very rapid development of rigor mortis. In addition, many of the animals will have muscles that appear very pale and are very soft, almost watery in texture, due to the high lactic acid content in muscles that occurs *post-mortem*. *Ante mortem* histologic changes have not been identified in these animals. Lesions in animals with the dystrophin mutations consist of cardiomyofiber degeneration (Nonneman *et al.*, 2012).

2. Salt Poisoning

Etiology Salt poisoning, also known as sodium ion toxicosis, is a condition that can easily occur in swine. It

can be caused directly by the animal consuming excessive amounts of sodium. This happens infrequently, as animals are rarely presented with feed that has excessively high sodium content. However, feeding milk by-products such as whey, which has high sodium content, has been shown to cause the disease. By far the most common initiator for the condition is water deprivation. Usually, signs are initiated after a minimum of 24h of deprivation, but the condition can also occur after just a few hours of deprivation.

Pathogenesis Salt poisoning is caused by hyperosmolarity of the CNS. When the animal rehydrates, the osmotic pressure causes water to be drawn into the CNS, resulting in swelling and edema.

Clinical Signs/Diagnosis Initially, the animal presents as being very thirsty and constipated. CNS involvement, which may be delayed for several days after the insult, follows. The pigs will appear tense and apprehensive, with ears pricked and staring ahead with the head slightly elevated. The nose will then twitch, the eyes will close, and a rhythmic chomping of the jaws follows. Animals may also appear blind and deaf. Pigs near death may paddle continuously. If the condition occurs because of excessive salt consumption rather than water deprivation, vomiting and diarrhea may be part of the presentation.

The diagnosis can easily be made if the clinical signs are matched with known water deprivation. Supporting findings include gastritis, constipation, or enteritis. A laminar subcortical necrosis may occur if pigs are subacutely affected. The animal may present with hypernatremia; however, if the animal has had a chance to rehydrate, this finding will not be present. Differential diagnoses include PRV, hog cholera, and edema disease. Other causes of toxicosis, such as food poisoning, should also be considered.

Treatment Unfortunately, treatment is generally ineffective, and in fact, the condition is likely to be exacerbated by rehydration.

Pathology Histologic evaluation reveals eosinophilic cuffing of the meningeal and cerebral vessels.

3. Gastric Ulcers

Etiology Gastric ulceration in pigs refers to a condition in which ulceration of a specific region of the pig's stomach, the pars oesophagea, occurs. This condition has been diagnosed with increasing frequency since the 1950s, with the distribution being worldwide and varied in occurrence.

Pathogenesis To date, the pathogenesis of the disease remains speculative. However, a study has shown a relationship between the presence of *Helicobacter pylori*-like organisms, a high-carbohydrate diet, and gastric ulcers (Krakowka and Ellis, 2006).

Epizootiology Although this condition has been identified for decades, the definitive pathogenesis is still

unknown. Fasted pigs exposed to stressful environmental conditions had a higher incidence of ulcers compared to controls. An increased incidence of ulceration was produced when pigs were fed finely ground diets. Many species of bacteria and fungi have been isolated from ulcer lesions, but none have been shown to be causative. One study investigated the prevalence of *Gastrospirillum suis* in pigs with gastric ulcer but found no correlation between its presence and the occurrence of ulceration (Barbosa *et al.*, 1995). Further investigations are needed to better define the etiology of this condition.

Clinical Signs/Diagnosis The clinical signs vary depending on duration of the ulceration. In the peracute form, apparently healthy animals are simply found dead. In the acute form, pigs will become pale and weak, with an increased respiratory rate. Vomiting of blood and passage of bloody, tarry feces are seen. In the subacute or chronic form, the animal will be anemic and anorexic, with passage of dark feces that may be intermittent or persistent. Occasionally, the only sign observed may be the passage of dark, hard feces. Pigs of either sex or any breed may be affected. Usually, single pigs are affected, and body temperature is normal or slightly subnormal. Anemia can be detected hematologically if the chronic/subacute form is present. Differential diagnoses include swine dysentery, *S. enterica* ser. Choleraesuis, TGE, and intestinal hemorrhagic syndrome. These diseases can be differentiated relatively easily, as they impact on groups of animals and, with the exception of the intestinal hemorrhagic syndrome, result in high body temperatures.

Treatment Early stages of ulceration are not typically identified, so treatment is often not initiated until the condition has progressed to a point where treatment is ineffective. Options include administering nonabsorbable antacids, and vitamin E and selenium, as well as H-2 blockers (cimetidine, Zantac, etc.).

Prevention Providing pigs with appropriate feed is a prudent measure to take toward disease prevention. The diet should be more coarsely ground (not less than 700 μ m in size), not contain excessive unsaturated fatty acids, and have the right balance of vitamin E and selenium. Stressful conditions such as overcrowding, fasting, and unstable social groupings should be avoided.

Necropsy The pars oesophagea contains no glands and is covered by stratified squamous epithelium continuous with the esophagus. In a healthy animal, this surface appears white and smooth. Lesions can first be detected as a roughened, irregular surface. Ulceration follows, with a disruption in the epithelium that may be small, discrete, and single to multiple, large, and irregular. Blood or blood clots can be seen at the ulceration site, as well as in the stomach or in the gastrointestinal tract. If the subacute/chronic form of the condition is present, chronic ulceration usually ensues. This is characterized by the presence of fibrous tissue and the contraction of the area of ulceration.

In the early stages of the ulcer formation, parakeratosis of the epithelium occurs. Occasionally, infiltration of some polymorphonuclear cells occurs, but usually inflammatory cells are absent. The epithelium is weakened, and erosion of the tissue eventually occurs as a result of the parakeratosis. Once the underlying tissues are exposed to the gastric juices, diffuse necrosis and bleeding characteristic of any ulcer occur. Chronic ulcers develop as fibrous connective tissue forms in the underlying lamina propria. The muscularis mucosae may hypertrophy or may degenerate and be replaced by collagenized fibrous tissue. Occasionally, the ulcer may penetrate the serosa.

4. Melamine–Cyanuric Acid Toxicity

Melamine and cyanuric acids, when fed together, cause toxicity in animals. In 2007, there was a report in pigs in which they showed weight loss, pallor, rough coats, and increased mortality. Their kidneys were swollen with yellow discoloration. Histological examination revealed lesions in the proximal and distal tubules and collecting ducts with epithelial degeneration, necrosis, and crystals. The crystals were round, yellow to brown, and had radiating striations (Nilubol *et al.*, 2009).

C. Iatrogenic Diseases

1. Catheter Infections

Etiology A wide variety of either venous or arterial vascular-access lines are commonly used in swine and maintained for variable periods. Bacteria can be easily introduced into these lines if strict adherence to sterile technique is not observed during flushing. Improper maintenance of the catheter can also result in seeding of thrombi.

Pathogenesis Bacteremia with seeding of multiple organs can result in septic emboli in the lungs, kidney, spleen, and other sites. Thrombi dislodged from catheters during flushing can result in infarcts in multiple tissues, including the kidney.

Clinical Signs Swine with a catheter infection will be febrile, have decreased appetite, and have a discharge from around the vascular access port catheter exit site.

Differential Diagnosis The differential diagnosis should include foreign body reactions to the biomaterials.

Treatment Blood cultures or cultures taken from around the implant may identify the infectious agent responsible, and a sensitivity test should provide information needed to select appropriate antibiotics.

Prevention/Control Prevention and control consist of adequate flushing of lines, strict adherence to sterile technique in flushing, and use of flushes that have concentrations of anticoagulants adequate to prevent thrombus formation.

Necropsy A suppurative exudate may be present around the external access port or around subcutaneous implants. The entire catheter tract should be dissected to observe for any gross evidence of infection. Cultures should be taken of any suspicious sites. There may be a suppurative pneumonia with consolidation, suppurative emboli in multiple organs, renal infarcts, or infarcts in other organs. Microscopic lesions may include a cellulitis, myositis, suppurative pneumonia, suppurative emboli in one or more organs, or infarcts in the kidneys or other organs.

Research Complications Catheter infections are themselves research complications that may result in the animal being terminated from a study or euthanized due to persistent febrile state or compromised function of one or more organs.

D. Neoplastic Diseases

It has been touted that neoplasms occur with less frequency in pigs than in other domestic animals; however, this commonly held belief may be influenced by the fact that the majority of the pig population is slaughtered before reaching an age when cancer would normally appear with any significant incidence. The tumors that historically have been reported are those seen in young pigs, with the most common tumors being lymphosarcoma, embryonal nephroma, and melanoma. However, with the recent surge in popularity of potbellied pigs in the pet trade, more tumors are being found. A word of caution however, as these reports are from a single breed (Vietnamese potbellied) which may or may not be representative of the pig population at large.

A recent study of uteri from spayed miniature pigs (age 4 months to 14 years) found that 14/32 had smooth muscle tumors of the uterus or broad ligament (leiomyoma or leiomyosarcoma). One-third had adenoma or adenomyosarcoma (Ilha *et al.*, 2010). Another retrospective study found uterine leiomyomas in over 80% of samples and suggested similarities to human fibroids, proposing potbellied pigs as a model for this disease (Mozzachio *et al.*, 2004). Uterine adenocarcinoma has also been reported in mixed-breed research pigs (Cannon *et al.*, 2009).

Lymphosarcomas affect primarily younger animals but can affect mature animals of either sex. Most cases are classified as multicentric; thymic is the next most frequent classification. Infiltration of the liver, spleen, and kidney predominates. Histologically, pigs typically exhibit lymphocytic lymphosarcomas; however, lymphoblastic, histiocytic, and mixed types do occur. T-cell lymphosarcomas have also been found in aged potbellied pigs (Corapi *et al.*, 2011).

Embryonal nephromas affect pigs under 1 year of age, with predominance in females. The tumor arises in

the kidney parenchyma, is typically unilateral, and may spread to the lungs and liver. Histologically, the classifications that occur most commonly are nephroblastic and epithelial.

Melanomas occur as congenital lesions with exceptionally high frequency in Sinclair miniature swine (85% incidence at 1 year of age) and in Duroc, Iberian, and Hormel breeds. The disease is occasionally seen in other breeds as well. The tumors can be single or multiple and may affect the skin only or may involve metastasis to multiple internal organs. Initially, the skin tumor appears as a flat black spot that becomes a raised nodule. The tumor initiates as a focus of melanocytic hyperplasia within the basal layer. Spontaneous regression, thought to be caused by the cytotoxic effects of infiltrated tumor-specific T lymphocytes, occurs in the vast majority of cases.

Investigators are also beginning to target specific genes in pigs to generate 'oncopigs' which are prone to specific tumors (Flisikowska *et al.*, 2013).

E. Miscellaneous

1. Thrombocytopenic purpura

Thrombocytopenic purpura has been reported in Gottingen pigs in both the US and EU. There is no sex predilection (Carrasco *et al.*, 2003; Dincer and Skydsgaard, 2012). Grossly, animals have extensive multifocal subcutaneous hemorrhage. They have thrombocytopenia and anemia, leading to subcapsular hemorrhage of lymph nodes and hemorrhages of the urinary bladder urothelium (Carrasco *et al.*, 2003). Other lesions include ulceration of the torus pyloricæ and hemorrhages in numerous tissues (Carrasco *et al.*, 2003). Vascular lesions are consistently present in renal pelvis and coronary arteries, primarily within small to medium muscular arteries which display neointimal proliferation, thrombosis, and medial deposits of myxoid matrix (Maratea *et al.*, 2006). Renal glomeruli consistently have membranoproliferative lesions that label for immunoglobulins and C1q (Carrasco *et al.*, 2003). There are increased numbers of immature and apoptotic megakaryocytes within the bone marrow (Carrasco *et al.*, 2003). This is believed to be a Type III hypersensitivity reaction.

ACRONYMS USED IN CHAPTER

AHXR	Acute humoral xenograft rejection
APE	Acute pulmonary edema
APP	Actinobacillus pleuropneumoniae
AR	Atrophic rhinitis
ASFV	African swine fever virus
BM	Bone marrow

BVDV	Bovine viral diarrhea virus
CMV	Cytomegalovirus
CNS	Central nervous system
CSF	Classical swine fever
DNT	Dermonecrotic toxin – from <i>B. bronchiseptica</i>
ED	Edema disease
EE	Exudative epidermitis, greasy pig disease
ELISA	Enzyme-linked immunosorbent assay
EMCV	Encephalomyocarditis virus
EDEC	Edema disease associated <i>E. coli</i>
EHEC	Enterohemorrhagic <i>E. coli</i>
EPEC	Enteropathogenic <i>E. coli</i>
ETEC	Enterotoxigenic <i>E. coli</i>
EU	European Union
HAR	Hyperacute rejection
IBR	Inclusion body rhinitis (CMV)
IFA	Immunofluorescence assay
IFN	Interferon
Ig	Immunoglobulin
IHC	Immunohistochemistry
IL	Interleukin
MCF	Malignant catarrhal fever
MHC	Major histocompatibility complex
MPS	Mycoplasmal pneumonia of swine
NHP	Nonhuman primate
NPAR	Nonprogressive atrophic rhinitis (<i>B. bronchiseptica</i> alone)
PAN	PCV-2-associated neuropathy
PAR	Progressive atrophic rhinitis (<i>P. multocida</i> alone or in combination with <i>B. bronchiseptica</i>)
PCR	Polymerase chain reaction
PCV; PCV2	Porcine circovirus; porcine circovirus-2
PCVAD	PCV-associated disease
PDNS	Porcine dermatitis and nephropathy syndrome
PE	Proliferative enteropathy
PEDV	Porcine epidemic diarrhea virus
PHLV	Porcine lymphotropic herpesvirus
PMT	<i>P. multocida</i> toxin – from <i>P. multocida</i>
PMWS	Postweaning multisystemic wasting disease
PPV	Porcine parvovirus
PRDC	Porcine respiratory disease complex
PRRSV	Porcine reproductive and respiratory syndrome virus
PRV	Pseudorabies virus
PTV	Porcine teschovirus
PWD	Postweaning diarrhea
RT-PCR	Reverse transcriptase-polymerase chain reaction
RYR	Ryanodine receptor
SD	Swine dysentery

SE	Swine erysipelas
SIV	Swine influenza virus
SLA	Swine leukocyte antigen
SMEDI	Stillbirths, mummification, embryonic death, and infertility
SPF	Specific pathogen free
STEC	Shiga-toxin producing <i>E. coli</i>
TGE/TGEV	Transmissible gastroenteritis (coronavirus)/transmissible gastroenteritis virus
TNF	Tumor necrosis factor
TTV	Torque teno virus
US	United states

Acknowledgments

The authors acknowledge the input of the authors of the chapter in previous edition of this book: Drs. Kathy E. Laber, Mark T. Whary, Sarah A. Bingel, James A. Goodrich, and Alison C. Smith. Much of the current chapter is based on this influential work.

References

- Aarestrup, F.M., Jorsal, S.E., Jensen, N.E., 1998a. Serological characterization and antimicrobial susceptibility of *Streptococcus suis* isolates from diagnostic samples in Denmark during 1995 and 1996. *Vet. Microbiol.* 60, 59–66.
- Aarestrup, F.M., Rasmussen, S.R., Artursson, K., Jensen, N.E., 1998b. Trends in the resistance to antimicrobial agents of *Streptococcus suis* isolates from Denmark and Sweden. *Vet. Microbiol.* 63, 71–80.
- Ackermann, M.R., Debey, M.C., Debey, B.M., 1991. Bronchiolar metaplasia and *Ulex europaeus* agglutinin I (UEA-I) affinity in *Mycoplasma hyopneumoniae*-infected lungs of six pigs. *Vet. Pathol.* 28, 533–535.
- Ackermann, M.R., Register, K.B., Stabel, J.R., Gwaltney, S.M., Howe, T.S., Rimler, R.B., 1996. Effect of *Pasteurella multocida* toxin on physeal growth in young pigs. *Am. J. Vet. Res.* 57, 848–852.
- Agriculture, U.S.D.O., 2008. Pseudorabies (Aujeszky's disease) and its eradication: a review of the U.S. experience. USDA.
- Agriculture, U.S.D.O., 2014. Agriculture secretary Tom Vilsack announces additional USDA actions to combat spread of diseases among U.S. pork producers. Release No. 0066.14.
- Alcaraz, A., Warren, A., Jackson, C., Gold, J., McCoy, M., Cheong, S.H., et al., 2009. Naturally occurring sheep-associated malignant catarrhal fever in North American pigs. *J. Vet. Diagn. Invest.* 21, 250–253.
- Alexandersen, S., Knowles, N.J., Dekker, A., Belsham, G.J., Zhang, Z., Koenen, F., 2012. Picornaviruses. In: Zimmerman, J.J., Karriker, L.A., Ramirez, A., Schwartz, K.J., Stevenson, G.W. (Eds.), *Diseases of Swine*, tenth ed. Wiley-Blackwell, Chichester, West Sussex.
- Allan, G.M., Mc Neilly, F., Meehan, B.M., Kennedy, S., Mackie, D.P., Ellis, J.A., et al., 1999. Isolation and characterisation of circoviruses from pigs with wasting syndromes in Spain, Denmark and Northern Ireland. *Vet. Microbiol.* 66, 115–123.
- Alt, D.P., Bolin, C.A., 1996. Preliminary evaluation of antimicrobial agents for treatment of *Leptospira interrogans* serovar pomona infection in hamsters and swine. *Am. J. Vet. Res.* 57, 59–62.
- Amass, S.F., Scholz, D.A., 1998. Acute nonfatal erysipelas in sows in a commercial farrow-to-finish operation. *J. Am. Vet. Med. Assoc.* 212, 708–709.

- Amass, S.F., Wu, C.C., Clark, L.K., 1996. Evaluation of antibiotics for the elimination of the tonsillar carrier state of *Streptococcus suis* in pigs. *J. Vet. Diagn. Invest.* 8, 64–67.
- Andresen, L.O., 1998. Differentiation and distribution of three types of exfoliative toxin produced by *Staphylococcus hyicus* from pigs with exudative epidermitis. *FEMS Immunol. Med. Microbiol.* 20, 301–310.
- Andresen, L.O., 1999. Development and evaluation of an indirect ELISA for detection of exfoliative toxin ExhA, ExhB or ExhC produced by *Staphylococcus hyicus*. *Vet. Microbiol.* 68, 285–292.
- Anderson, M., 2006. Xenotransplantation: a bioethical evaluation. *J. Med. Ethics* 32, 205–208.
- Aragon, V., Segales, J., Oliveira, S., 2012. Glasser's disease. In: Zimmerman, J.J., Karriker, L.A., Ramirez, A., Schwartz, K.J., Stevenson, G.W. (Eds.), *Diseases of Swine*, tenth ed. Wiley-Blackwell, Chichester, West Sussex.
- Arends, J.J., Skogerboe, T.L., Ritzhaupt, L.K., 1999. Persistent efficacy of doramectin and ivermectin against experimental infestations of *Sarcoptes scabiei* var. *suis* in swine. *Vet. Parasitol.* 82, 71–79.
- Argenzio, R.A., Whipp, S.C., Glock, R.D., 1980. Pathophysiology of swine dysentery: colonic transport and permeability studies. *J. Infect. Dis.* 142, 676–684.
- Atyeo, R.F., Oxberry, S.L., Combs, B.G., Hampson, D.J., 1998. Development and evaluation of polymerase chain reaction tests as an aid to diagnosis of swine dysentery and intestinal spirochaetosis. *Lett. Appl. Microbiol.* 26, 126–130.
- Bahls, M., Bidwell, C.A., Hu, J., Krueger, C.G., Reed, J.D., Tellez, A., et al., 2011. Gene expression differences in healthy brachial and femoral arteries of Rapacz familial hypercholesterolemic swine. *Physiol. Genomics* 43, 781–788.
- Bahls, M., Bidwell, C.A., Hu, J., Tellez, A., Kaluza, G.L., Granada, J.F., et al., 2013. Gene expression differences during the heterogeneous progression of peripheral atherosclerosis in familial hypercholesterolemic swine. *BMC Genomics* 14, 443.
- Baker, D.R., Billey, L.O., Francis, D.H., 1997. Distribution of K88 *Escherichia coli*-adhesive and nonadhesive phenotypes among pigs of four breeds. *Vet. Microbiol.* 54, 123–132.
- Barbe, F., Atanasova, K., Van Reeth, K., 2011. Cytokines and acute phase proteins associated with acute swine influenza infection in pigs. *Vet. J.* 187, 48–53.
- Barbosa, A.J., Silva, J.C., Nogueira, A.M., Paulino Junior, E., Miranda, C.R., 1995. Higher incidence of *Gastrospirillum* sp. in swine with gastric ulcer of the pars oesophagea. *Vet. Pathol.* 32, 134–139.
- Barrette, R.W., Metwally, S.A., Rowland, J.M., Xu, L., Zaki, S.R., Nichol, S.T., et al., 2009. Discovery of swine as a host for the Reston ebolavirus. *Science* 325, 204–206.
- Batte, E.G., Moncol, D.J., 1972. Whipworms and dysentery in feeder pigs. *J. Am. Vet. Med. Assoc.* 161, 1226–1228.
- Batte, E.G., Mclamb, R.D., Muse, K.E., Tally, S.D., Vestal, T.J., 1977. Pathophysiology of swine trichuriasis. *Am. J. Vet. Res.* 38, 1075–1079.
- Baumeister, A.K., Runge, M., Ganter, M., Feenstra, A.A., Delbeck, F., Kirchoff, H., 1998. Detection of *Mycoplasma hyopneumoniae* in bronchoalveolar lavage fluids of pigs by PCR. *J. Clin. Microbiol.* 36, 1984–1988.
- Baums, C.G., Verkuhlen, G.J., Rehm, T., Silva, L.M., Beyerbach, M., Pohlmeier, K., et al., 2007. Prevalence of *Streptococcus suis* genotypes in wild boars of Northwestern Germany. *Appl. Environ. Microbiol.* 73, 711–717.
- Bautista, M.J., Ruiz-Villamor, E., Salguero, F.J., Sanchez-Cordon, P.J., Carrasco, L., Gomez-Villamandos, J.C., 2002. Early platelet aggregation as a cause of thrombocytopenia in classical swine fever. *Vet. Pathol.* 39, 84–91.
- Beach, N.M., Meng, X.J., 2012. Efficacy and future prospects of commercially available and experimental vaccines against porcine circovirus type 2 (PCV2). *Virus Res.* 164, 33–42.
- Beer, R.J., 1976. The relationship between *Trichuris trichiura* (Linnaeus 1758) of man and *Trichuris suis* (Schrank 1788) of the pig. *Res. Vet. Sci.* 20, 47–54.
- Beer, R.J., Lean, I.J., 1973. Clinical trichuriasis produced experimentally in growing pigs. I. Pathology of infection. *Vet. Rec.* 93, 189–195.
- Beier, D., Gross, R., 2008. The BvgS/BvgA phosphorelay system of pathogenic *Bordetella*: structure, function and evolution. *Adv. Exp. Med. Biol.* 631, 149–160.
- Berthelot-Herault, F., Gottschalk, M., Labbe, A., Cariolet, R., Kobisch, M., 2001. Experimental airborne transmission of *Streptococcus suis* capsular type 2 in pigs. *Vet. Microbiol.* 82, 69–80.
- Bertram, T.A., 1985. Quantitative morphology of peracute pulmonary lesions in swine induced by *Haemophilus pleuropneumoniae*. *Vet. Pathol.* 22, 598–609.
- Bielański, A., Raeside, J.L., 1977. Plasma concentrations of steroid hormones in sows infected experimentally with *Leptospira pomona* or porcine enterovirus strain T1 in late gestation. *Res. Vet. Sci.* 22, 28–34.
- Bobbie, D.L., Swindle, M.M., 1986. Pulse monitoring, intravascular and intramuscular injection sites in pigs. In: Tumbleson, M.E. (Ed.), *Swine in Biomedical Research*. Plenum Press, New York.
- Bollen, P.J.A., Hansen, A.K., Alstrup, A.K.O., 2010. *The Laboratory Swine*. CRC Press/Taylor & Francis, Boca Raton, FL.
- Bornstein, S., Wallgren, P., 1997. Serodiagnosis of sarcoptic mange in pigs. *Vet. Rec.* 141, 8–12.
- Bosse, J.T., Janson, H., Sheehan, B.J., Beddek, A.J., Rycroft, A.N., Kroll, J.S., et al., 2002. *Actinobacillus pleuropneumoniae*: pathobiology and pathogenesis of infection. *Microbes Infect.* 4, 225–235.
- Bouchet, B., Vanier, G., Jacques, M., Auger, E., Gottschalk, M., 2009. Studies on the interactions of *Haemophilus parasuis* with porcine epithelial tracheal cells: limited role of LOS in apoptosis and pro-inflammatory cytokine release. *Microb. Pathog.* 46, 108–113.
- Bousquet, E., Morvan, H., Aitken, I., Morgan, J.H., 1997. Comparative in vitro activity of doxycycline and oxytetracycline against porcine respiratory pathogens. *Vet. Rec.* 141, 37–40.
- Bousquet, E., Pommier, P., Wessel-Robert, S., Morvan, H., Benoit-Valiergue, H., Laval, A., 1998. Efficacy of doxycycline in feed for the control of pneumonia caused by *Pasteurella multocida* and *Mycoplasma hyopneumoniae* in fattening pigs. *Vet. Rec.* 143, 269–272.
- Bowman, D.D., Georgi, J.R., 2009. *Georgis' Parasitology for Veterinarians*. Saunders/Elsevier, St. Louis, MO.
- Boye, M., Jensen, T.K., Moller, K., Leser, T.D., Jorsal, S.E., 1998. Specific detection of *Lawsonia intracellularis* in porcine proliferative enteropathy inferred from fluorescent rRNA in situ hybridization. *Vet. Pathol.* 35, 153–156.
- Brady, P.S., Ku, P.K., Ullrey, D.E., Miller, E.R., 1978. Evaluation of an amino acid-iron chelate hematinic for the baby pig. *J. Anim. Sci.* 47, 1135–1140.
- Braun, W., 1993. Reproduction in miniature pet pigs. In: Reeves, D.E., Becker, H.N., American Association of Swine Practitioners, Care and Management of Miniature Pet Pigs: Guidelines for the Veterinary Practitioner, first ed. Veterinary Practice Pub. Co, Santa Barbara, CA.
- Brenner, P., Reichenspurner, H., Schmoedel, M., Wimmer, C., Rucker, A., Eder, V., et al., 2000. IG-therasorb immunoapheresis in orthotopic xenotransplantation of baboons with landrace pig hearts. *Transplantation* 69, 208–214.
- Bridger, J.C., Tauscher, G.I., Desselberger, U., 1998. Viral determinants of rotavirus pathogenicity in pigs: evidence that the fourth gene of a porcine rotavirus confers diarrhea in the homologous host. *J. Virol.* 72, 6929–6931.
- Brockmeier, S.L., Register, K.B., 2000. Effect of temperature modulation and bvg mutation of *Bordetella bronchiseptica* on adhesion, intracellular survival and cytotoxicity for swine alveolar macrophages. *Vet. Microbiol.* 73, 1–12.

- Brockmeier, S.L., Register, K.B., Nicholson, T.L., Loving, C.L., 2012. Bordetellosis. In: Zimmerman, J.J., Karriker, L.A., Ramirez, A., Schwartz, K.J., Stevenson, G.W. (Eds.), *Diseases of Swine*, tenth ed. Wiley-Blackwell, Chichester, West Sussex.
- Brooke, C.J., Riley, T.V., 1999. Erysipelothrix rhusiopathiae: bacteriology, epidemiology and clinical manifestations of an occupational pathogen. *J. Med. Microbiol.* 48, 789–799.
- Brouard, S., Gagne, K., Blancho, G., Soullillou, J.P., 1999. T cell response in xenorecognition and xenografts: a review. *Hum. Immunol.* 60, 455–468.
- Buettner, F.F., Konze, S.A., Maas, A., Gerlach, G.F., 2011. Proteomic and immunoproteomic characterization of a DIVA subunit vaccine against *Actinobacillus pleuropneumoniae*. *Proteome. Sci.* 9, 23.
- Buller, C.R., Moxley, R.A., 1988. Natural infection of porcine ileal dome M cells with rotavirus and enteric adenovirus. *Vet. Pathol.* 25, 516–517.
- Buogo, C., Capaul, S., Hani, H., Frey, J., Nicolet, J., 1995. Diagnosis of *Clostridium perfringens* type C enteritis in pigs using a DNA amplification technique (PCR). *Zentralbl. Veterinarmed. B* 42, 51–58.
- Burton, P.J., Thornsberry, C., Cheung Yee, Y., Watts, J.L., Yancey Jr., R.J., 1996. Interpretive criteria for antimicrobial susceptibility testing of ceftiofur against bacteria associated with swine respiratory disease. *J. Vet. Diagn. Invest.* 8, 464–468.
- Busque, P., Higgins, R., Caya, F., Quessy, S., 1997. Immunization of pigs against *Streptococcus suis* serotype 2 infection using a live avirulent strain. *Can. J. Vet. Res.* 61, 275–279.
- Calsamiglia, M., Pijoan, C., Solano, G., Rapp-Gabrielson, V., 1999. Development of an oligonucleotide-specific capture plate hybridization assay for detection of *Haemophilus parasuis*. *J. Vet. Diagn. Invest.* 11, 140–145.
- Cannon, C.Z., Godfrey, V.L., King-Herbert, A., Nielsen, J.N., 2009. Metastatic uterine adenocarcinoma in an 8-year-old gilt. *J. Am. Assoc. Lab. Anim. Sci.* 48, 795–800.
- Cargill, C., Davies, P., Carmichael, I., Hooke, F., Moore, M., 1996. Treatment of sarcoptic mite infestation and mite hypersensitivity in pigs with injectable doramectin. *Vet. Rec.* 138, 468–471.
- Cargill, C.F., Pointon, A.M., Davies, P.R., Garcia, R., 1997. Using slaughter inspections to evaluate sarcoptic mange infestation of finishing swine. *Vet. Parasitol.* 70, 191–200.
- Carlson, S.A., Barnhill, A.E., Griffith, R.W., 2012. Salmonellosis. In: Zimmerman, J.J. (Ed.), *Diseases of Swine*, tenth ed. Wiley-Blackwell, Chichester, West Sussex.
- Carrasco, L., Madsen, L.W., Salguero, F.J., Nunez, A., Sanchez-Cordon, P., Bollen, P., 2003. Immune complex-associated thrombocytopenic purpura syndrome in sexually mature Gottingen minipigs. *J. Comp. Pathol.* 128, 25–32.
- Carstens, E.B., 2010. Ratification vote on taxonomic proposals to the International Committee on Taxonomy of Viruses (2009). *Arch. Virol.* 155, 133–146.
- Chae, C., 2004. Postweaning multisystemic wasting syndrome: a review of aetiology, diagnosis and pathology. *Vet. J.* 168, 41–49.
- Chae, C., 2005. A review of porcine circovirus 2-associated syndromes and diseases. *Vet. J.* 169, 326–336.
- Chae, S.J., Kramer, A.D., Zhao, Y., Arn, S., Cooper, D.K., Sachs, D.H., 1999. Lack of variation in alphaGal expression on lymphocytes in miniature swine of different genotypes. *Xenotransplantation* 6, 43–51.
- Chang, K.-O., Saif, L.J., Kim, Y., 2012. Reoviruses (rotaviruses and reoviruses). In: Zimmerman, J.J., Karriker, L.A., Ramirez, A., Schwartz, K.J., Stevenson, G.W. (Eds.), *Diseases of Swine*, tenth ed. Wiley-Blackwell, Chichester, West Sussex.
- Chaniago, T.D., Watson, D.L., Owen, R.A., Johnson, R.H., 1978. Immunoglobulins in blood serum of foetal pigs. *Aust. Vet. J.* 54, 30–33.
- Chiers, K., Haesebrouck, F., Van Overbeke, I., Charlier, G., Ducatelle, R., 1999. Early in vivo interactions of *Actinobacillus pleuropneumoniae* with tonsils of pigs. *Vet. Microbiol.* 68, 301–306.
- Chirico, J., Eriksson, H., Fossum, O., Jansson, D., 2003. The poultry red mite, *Dermanyssus gallinae*, a potential vector of *Erysipelothrix rhusiopathiae* causing erysipelas in hens. *Med. Vet. Entomol.* 17, 232–234.
- Chmielewicz, B., Goltz, M., Franz, T., Bauer, C., Brema, S., Ellerbrok, H., et al., 2003. A novel porcine gammaherpesvirus. *Virology* 308, 317–329.
- Cho, J.G., Dee, S.A., 2006. Porcine reproductive and respiratory syndrome virus. *Theriogenology* 66, 655–662.
- Cho, W.S., Jung, K., Kim, J., Ha, Y., Chae, C., 2005. Expression of mRNA encoding interleukin (IL)-10, IL-12p35 and IL-12p40 in lungs from pigs experimentally infected with *Actinobacillus pleuropneumoniae*. *Vet. Res. Commun.* 29, 111–122.
- Choi, C., Chae, C., 2001. Colocalization of porcine reproductive and respiratory syndrome virus and porcine circovirus 2 in porcine dermatitis and nephrology syndrome by double-labeling technique. *Vet. Pathol.* 38, 436–441.
- Cino-Ozuna, A.G., Henry, S., Hesse, R., Nietfeld, J.C., Bai, J., Scott, H.M., et al., 2011. Characterization of a new disease syndrome associated with porcine circovirus type 2 in previously vaccinated herds. *J. Clin. Microbiol.* 49, 2012–2016.
- Claxton-Gill, M.S., Cornick-Seahorn, J.L., Gamboa, J.C., Boatright, B.S., 1993. Suspected malignant hyperthermia syndrome in a miniature pot-bellied pig anesthetized with isoflurane. *J. Am. Vet. Med. Assoc.* 203, 1434–1436.
- Collins, A., Love, R.J., Pozo, J., Smith, S.H., McOrist, S., 2000. Studies on the ex vivo survival of *Lawsonia intracellularis*. *Swine Health Prod.* 8, 211–215.
- Cooper, D.M., Gebhart, C.J., 1998. Comparative aspects of proliferative enteritis. *J. Am. Vet. Med. Assoc.* 212, 1446–1451.
- Corapi, W.V., Rodrigues, A., Lawhorn, D.B., 2011. Mucinous adenocarcinoma and T-cell lymphoma in the small intestine of 2 Vietnamese potbellied pigs (*Sus scrofa*). *Vet. Pathol.* 48, 1004–1007.
- Cornell Veterinary Medicine, 2012. Dr. John M. King's necropsy show and tell [Online]. Available: <<https://secure.vet.cornell.edu/nst/nst.asp>> (accessed 13.09.13).
- Cowart, R.P., 1995. *An Outline of Swine Diseases: a Handbook*. Iowa State University Press, Ames, IA.
- Critser, J.K., Laughlin, M.H., Prather, R.S., Riley, L.K., 2009. Proceedings of the conference on swine in biomedical research. *ILAR J.* 50, 89–94.
- Croxen, M.A., Finlay, B.B., 2010. Molecular mechanisms of *Escherichia coli* pathogenicity. *Nat. Rev. Microbiol.* 8, 26–38.
- Czechowicz, J., Huaman, J.L., Forshey, B.M., Morrison, A.C., Castillo, R., Huaman, A., et al., 2011. Prevalence and risk factors for encephalomyocarditis virus infection in Peru. *Vector Borne Zoonotic Dis.* 11, 367–374.
- Darwich, L., Mateu, E., 2012. Immunology of porcine circovirus type 2 (PCV2). *Virus Res.* 164, 61–67.
- Darwich, L., Pie, S., Rovira, A., Segales, J., Domingo, M., Oswald, I.P., et al., 2003. Cytokine mRNA expression profiles in lymphoid tissues of pigs naturally affected by postweaning multisystemic wasting syndrome. *J. Gen. Virol.* 84, 2117–2125.
- Davies, K.A., Chapman, P.T., Norsworthy, P.J., Jamar, F., Athanassiou, P., Keelan, E.T., et al., 1995. Clearance pathways of soluble immune complexes in the pig. Insights into the adaptive nature of antigen clearance in humans. *J. Immunol.* 155, 5760–5768.
- Davies, P.R., 1995. Sarcoptic mange and production performance of swine: a review of the literature and studies of associations between mite infestation, growth rate and measures of mange severity in growing pigs. *Vet. Parasitol.* 60, 249–264.
- Davies, P.R., Bahnson, P.B., Grass, J.J., Marsh, W.E., Garcia, R., Melancon, J., et al., 1996. Evaluation of the monitoring of papular dermatitis lesions in slaughtered swine to assess sarcoptic mite infestation. *Vet. Parasitol.* 62, 143–153.
- Davis, D.P., Moon, R.D., 1990. Density of itch mite, *Sarcoptes scabiei* (Acari: Sarcopitidae) and temporal development of cutaneous hypersensitivity in swine mange. *Vet. Parasitol.* 36, 285–293.

- Davis, W.C., Zuckermann, F.A., Hamilton, M.J., Barbosa, J.I., Saalmuller, A., Binns, R.M., et al., 1998. Analysis of monoclonal antibodies that recognize gamma delta T/null cells. *Vet. Immunol. Immunopathol.* 60, 305–316.
- Davison, A.J., Eberle, R., Ehlers, B., Hayward, G.S., McGeoch, D.J., Minson, A.C., et al., 2009. The order herpesvirales. *Arch. Virol.* 154, 171–177.
- Day, B.N., 1980. Parturition. In: Morrow, D.A. (Ed.), *Current Therapy in Theriogenology: Diagnosis, Treatment, and Prevention of Reproductive Diseases in Animals*. Saunders, Philadelphia, PA.
- Delhon, G., Tulman, E.R., Afonso, C.L., Rock, D.L., 2012. Swinepox virus. In: Zimmerman, J.J., Karriker, L.A., Ramirez, A., Schwartz, K.J., Stevenson, G.W. (Eds.), *Diseases of Swine*, tenth ed. Wiley-Blackwell, Chichester, West Sussex.
- Derbyshire, J.B., Arkell, S., 1971. The activity of some chemical disinfectants against Talfan virus and porcine adenovirus type 2. *Br. Vet. J.* 127, 137–142.
- De Rycke, J., Milon, A., Oswald, E., 1999. Necrotic Escherichia coli (NTEC): two emerging categories of human and animal pathogens. *Vet. Res.* 30, 221–233.
- De Smit, A.J., Bouma, A., Terpstra, C., Van Oirschot, J.T., 1999. Transmission of classical swine fever virus by artificial insemination. *Vet. Microbiol.* 67, 239–249.
- De Vleeschauwer, A., Atanasova, K., Van Borm, S., Van Den Berg, T., Rasmussen, T.B., Uttenthal, A., et al., 2009. Comparative pathogenesis of an avian H5N2 and a swine H1N1 influenza virus in pigs. *PLoS One* 4, e6662.
- Devriese, L.A., Haesebrouck, F., De Herdt, P., Dom, P., Ducatelle, R., Desmidt, M., et al., 1994. Streptococcus suis infections in birds. *Avian Pathol.* 23, 721–724.
- DeYoe, B.L., 1967. Pathogenesis of three strains of Brucella suis in swine. *Am. J. Vet. Res.* 28, 951–957.
- Didier, P.J., Perino, L., Urbance, J., 1984. Porcine Haemophilus pleuropneumonia: microbiological and pathologic findings. *J. Am. Vet. Med. Assoc.* 184, 716–719.
- Dincer, Z., Skydsgaard, M., 2012. Spontaneous/background pathology of Gottingen minipig. In: McNulty, P., Dayan, A.D., Ganderup, N.-C., Hastings, K. (Eds.), *The Minipig in Biomedical Research*. CRC Press, Boca Raton, FL.
- Dominick, M.A., Rimler, R.B., 1988. Turbinate osteoporosis in pigs following intranasal inoculation of purified Pasteurella toxin: histomorphometric and ultrastructural studies. *Vet. Pathol.* 25, 17–27.
- Dorsey, F.C., Fischer, J.F., Fleckenstein, J.M., 2006. Directed delivery of heat-labile enterotoxin by enterotoxigenic Escherichia coli. *Cell. Microbiol.* 8, 1516–1527.
- Dritz, S.S., Chengappa, M.M., Nelssen, J.L., Tokach, M.D., Goodband, R.D., Nietfeld, J.C., et al., 1996. Growth and microbial flora of nonmedicated, segregated, early weaned pigs from a commercial swine operation. *J. Am. Vet. Med. Assoc.* 208, 711–715.
- Duhamel, G.E., Kinyon, J.M., Mathiesen, M.R., Murphy, D.P., Walter, D., 1998. In vitro activity of four antimicrobial agents against North American isolates of porcine Serpulina pilosicoli. *J. Vet. Diagn. Invest.* 10, 350–356.
- Duncan, J.R., Ramsey, R.K., Switzer, W.P., 1966a. Pathology of experimental Bordetella bronchiseptica infection in swine: pneumonia. *Am. J. Vet. Res.* 27, 467–472.
- Duncan, J.R., Ross, R.F., Switzer, W.P., Ramsey, F.K., 1966b. Pathology of experimental Bordetella bronchiseptica infection in swine: atrophic rhinitis. *Am. J. Vet. Res.* 27, 457–466.
- Dwyer, K.M., Cowan, P.J., D'apice, A.J., 2002. Xenotransplantation: past achievements and future promise. *Heart Lung Circ.* 11, 32–41.
- Edington, N., Smith, I.M., Plowright, W., Watt, R.G., 1976. Relationship of porcine cytomegalovirus and B bronchiseptica to atrophic rhinitis in gnotobiotic piglets. *Vet. Rec.* 98, 42–45.
- Edington, N., Watt, R.G., Plowright, W., 1977. Experimental transplacental transmission of porcine cytomegalovirus. *J. Hyg. (Lond)* 78, 243–251.
- Ehler, W.J., Mack Jr., J.W., Brown, D.L., Davis, R.F., 1985. Avoidance of malignant hyperthermia in a porcine model for experimental open heart surgery. *Lab. Anim. Sci.* 35, 172–175.
- Ehlers, B., Ulrich, S., Goltz, M., 1999. Detection of two novel porcine herpesviruses with high similarity to gammaherpesviruses. *J. Gen. Virol.* 80 (Pt 4), 971–978.
- Einarsson, S., 1980. Artificial insemination. In: Morrow, D.A. (Ed.), *Current Therapy in Theriogenology: Diagnosis, Treatment, and Prevention of Reproductive Diseases in Animals*. Saunders, Philadelphia, PA.
- Elbers, A.R., Stegeman, J.A., De Jong, M.C., 2001. Factors associated with the introduction of classical swine fever virus into pig herds in the central area of the 1997/98 epidemic in the Netherlands. *Vet. Rec.* 149, 377–382.
- Ellis, E.A., 2012. Leptospirosis. In: Zimmerman, J.J., Karriker, L.A., Ramirez, A., Schwartz, K.J., Stevenson, G.W. (Eds.), *Diseases of Swine*, tenth ed. Wiley-Blackwell, Chichester, West Sussex.
- Ellis, J., Hassard, L., Clark, E., Harding, J., Allan, G., Willson, P., et al., 1998. Isolation of circovirus from lesions of pigs with postweaning multisystemic wasting syndrome. *Can. Vet. J.* 39, 44–51.
- Emery, D.W., Holley, K., Sachs, D.H., 1999. Enhancement of swine progenitor chimerism in mixed swine/human bone marrow cultures with swine cytokines. *Exp. Hematol.* 27, 1330–1337.
- Enright, M.R., Alexander, T.J., Clifton-Hadley, F.A., 1987. Role of houseflies (Musca domestica) in the epidemiology of Streptococcus suis type 2. *Vet. Rec.* 121, 132–133.
- Erickson, E.D., 1987. Streptococcosis. *J. Am. Vet. Med. Assoc.* 191, 1391–1393.
- Eustis, S.L., Nelson, D.T., 1981. Lesions associated with coccidiosis in nursing piglets. *Vet. Pathol.* 18, 21–28.
- Fairbrother, J.M., Gyles, C.L., 2012. Colibacillosis. In: Zimmerman, J.J., Karriker, L.A., Ramirez, A., Schwartz, K.J., Stevenson, G.W. (Eds.), *Diseases of Swine*, tenth ed. Wiley-Blackwell, Chichester, West Sussex.
- Fedoraka-Cray, P.J., Kelley, L.C., Stabel, T.J., Gray, J.T., Laufer, J.A., 1995. Alternate routes of invasion may affect pathogenesis of Salmonella typhimurium in swine. *Infect. Immun.* 63, 2658–2664.
- Fisher, T.F., 1993. Miniature swine in biomedical research: applications and husbandry considerations. *Lab. Anim.* 22, 47–50.
- Flewelling, E.H., Nelson, T.E., 1980. Dantrolene dose response in malignant hyperthermia-susceptible (MHS) swine: method to obtain prophylaxis and therapeutics. *Anesthesiology* 52, 303–308.
- Flisikowska, T., Kind, A., Schnieke, A., 2013. The new pig on the block: modelling cancer in pigs. *Transgenic. Res.* 22, 673–680.
- Fogarty, R., Halpin, K., Hyatt, A.D., Daszak, P., Mungall, B.A., 2008. Henipavirus susceptibility to environmental variables. *Virus Res.* 132, 140–144.
- Forum, M.R., 2013. Minipig Research Forum [Online]. Available: <<http://minipigresearchforum.org/index.php?id=19>> (accessed 13.09.13).
- Fox, J.G., 2002. *Laboratory Animal Medicine*. Academic Press, Amsterdam, The Netherlands; New York.
- Frana, T.S., 2012. Staphylococcosis. In: Zimmerman, J.J., Karriker, L.A., Ramirez, A., Schwartz, K.J., Stevenson, G.W. (Eds.), *Diseases of Swine*, tenth ed. Wiley-Blackwell, Chichester, West Sussex.
- Friedman, T., Shimizu, A., Smith, R.N., Colvin, R.B., Seebach, J.D., Sachs, D.H., et al., 1999. Human CD4+ T cells mediate rejection of porcine xenografts. *J. Immunol.* 162, 5256–5262.
- Fujii, J., Otsu, K., Zorzato, F., De Leon, S., Khanna, V.K., Weiler, J.E., et al., 1991. Identification of a mutation in porcine ryanodine receptor associated with malignant hyperthermia. *Science* 253, 448–451.
- Galdiero, M., D'isanto, M., Vitiello, M., Finamore, E., Peluso, L., Galdiero, M., 2003. Monocytic activation of protein tyrosine kinase, protein kinase A and protein kinase C induced by porins isolated from Salmonella enterica serovar Typhimurium. *J. Infect.* 46, 111–119.
- Gatlin, C.L., Jordan, W.H., Shryock, T.R., Smith, W.C., 1996. The quantitation of turbinate atrophy in pigs to measure the severity of induced atrophic rhinitis. *Can. J. Vet. Res.* 60, 121–126.

- Geldhof, M.F., Vanhee, M., Van Breedam, W., Van Doorselaere, J., Karniychuk, U.U., Nauwynck, H.J., 2012. Comparison of the efficacy of autogenous inactivated Porcine Reproductive and Respiratory Syndrome Virus (PRRSV) vaccines with that of commercial vaccines against homologous and heterologous challenges. *BMC Vet. Res.* 8, 182.
- Giannella, R.A., Mann, E.A., 2003. E. coli heat-stable enterotoxin and guanylyl cyclase C: new functions and unsuspected actions. *Trans. Am. Clin. Climatol. Assoc.* 114, 67–85. discussion 85–6.
- Gillespie, J., Opriessnig, T., Meng, X.J., Pelzer, K., Buechner-Maxwell, V., 2009. Porcine circovirus type 2 and porcine circovirus-associated disease. *J. Vet. Intern. Med.* 23, 1151–1163.
- Gipson, P.S., Veatch, J.K., Matlack, R.S., Jones, D.P., 1999. Health status of a recently discovered population of feral swine in Kansas. *J. Wildl. Dis.* 35, 624–627.
- Goltz, M., Ericsson, T., Patience, C., Huang, C.A., Noack, S., Sachs, D.H., et al., 2002. Sequence analysis of the genome of porcine lymphotropic herpesvirus 1 and gene expression during posttransplant lymphoproliferative disease of pigs. *Virology* 294, 383–393.
- Gomez-Laguna, J., Salguero, F.J., Barranco, I., Pallares, F.J., Rodriguez-Gomez, I.M., Bernabe, A., et al., 2010. Cytokine expression by macrophages in the lung of pigs infected with the porcine reproductive and respiratory syndrome virus. *J. Comp. Pathol.* 142, 51–60.
- Gomez-Villamandos, J.C., Salguero, F.J., Ruiz-Villamor, E., Sanchez-Cordon, P.J., Bautista, M.J., Sierra, M.A., 2003. Classical swine fever: pathology of bone marrow. *Vet. Pathol.* 40, 157–163.
- Gottschalk, M., 2012a. Actinobacillosis. In: Zimmerman, J.J. (Ed.), *Diseases of Swine*, tenth ed. Wiley-Blackwell, Chichester, West Sussex.
- Gottschalk, M., 2012b. Streptococcosis. In: Zimmerman, J.J., Karriker, L.A., Ramirez, A., Schwartz, K.J., Stevenson, G.W. (Eds.), *Diseases of Swine*, tenth ed. Wiley-Blackwell, Chichester, West Sussex.
- Gottschalk, M., Segura, M., 2000. The pathogenesis of the meningitis caused by *Streptococcus suis*: the unresolved questions. *Vet. Microbiol.* 76, 259–272.
- Gourlay, W.A., Chambers, W.H., Monaco, A.P., Maki, T., 1998. Importance of natural killer cells in the rejection of hamster skin xenografts. *Transplantation* 65, 727–734.
- Graham, D.Y., Sackman, J.W., Estes, M.K., 1984. Pathogenesis of rotavirus-induced diarrhea. Preliminary studies in miniature swine piglet. *Dig. Dis. Sci.* 29, 1028–1035.
- Gram, T., Ahrens, P., Nielsen, J.P., 1996. Evaluation of a PCR for detection of *Actinobacillus pleuropneumoniae* in mixed bacterial cultures from tonsils. *Vet. Microbiol.* 51, 95–104.
- Grand, N., 2012. Diseases of minipigs. In: McNulty, P.A., Dayan, A.D., Ganderup, N.-C., Hastings, K.L. (Eds.), *The Minipig in Biomedical Research*. CRC Press/Taylor & Francis, Boca Raton, FL.
- Gray, J.T., Fedorka-Cray, P.J., Stabel, T.J., Kramer, T.T., 1996. Natural transmission of *Salmonella choleraesuis* in swine. *Appl. Environ. Microbiol.* 62, 141–146.
- Greve, J.H., 2012. Internal parasites: Helminths. In: Zimmerman, J.J., Karriker, L.A., Ramirez, A., Schwartz, K.J., Stevenson, G.W. (Eds.), *Diseases of Swine*, tenth ed. Wiley-Blackwell, Chichester, West Sussex.
- Greve, J.H., Davies, P., 2012. External parasites. In: Zimmerman, J.J., Karriker, L.A., Ramirez, A., Schwartz, K.J., Stevenson, G.W. (Eds.), *Diseases of Swine*, tenth ed. Wiley-Blackwell, Chichester, West Sussex.
- Griesemer, A.D., Lamattina, J.C., Okumi, M., Etter, J.D., Shimizu, A., Sachs, D.H., et al., 2008. Linked suppression across an MHC-mismatched barrier in a miniature swine kidney transplantation model. *J. Immunol.* 181, 4027–4036.
- Groebel, K., Hoelzle, K., Wittenbrink, M.M., Ziegler, U., Hoelzle, L.E., 2009. *Mycoplasma suis* invades porcine erythrocytes. *Infect. Immun.* 77, 576–584.
- Gwaltney, S.M., Galvin, R.J., Register, K.B., Rimler, R.B., Ackermann, M.R., 1997. Effects of *Pasteurella multocida* toxin on porcine bone marrow cell differentiation into osteoclasts and osteoblasts. *Vet. Pathol.* 34, 421–430.
- Gyles, C.L., 1993. *Escherichia coli*. In: Gyles, C.L., Thoen, C.O. (Eds.), *Pathogenesis of Bacterial Infections in Animals*, second ed. Iowa State University, Ames, IA.
- Halbur, P.G., Paul, P.S., Frey, M.L., Landgraf, J., Eernisse, K., Meng, X.J., et al., 1995. Comparison of the pathogenicity of two US porcine reproductive and respiratory syndrome virus isolates with that of the Lelystad virus. *Vet. Pathol.* 32, 648–660.
- Hamilton, T.D., Roe, J.M., Hayes, C.M., Webster, A.J., 1998. Effects of ammonia inhalation and acetic acid pretreatment on colonization kinetics of toxigenic *Pasteurella multocida* within upper respiratory tracts of swine. *J. Clin. Microbiol.* 36, 1260–1265.
- Hamilton, T.D., Roe, J.M., Hayes, C.M., Jones, P., Pearson, G.R., Webster, A.J., 1999. Contributory and exacerbating roles of gaseous ammonia and organic dust in the etiology of atrophic rhinitis. *Clin. Diagn. Lab. Immunol.* 6, 199–203.
- Hampson, D.J., 2012. Brachyspiral colitis. In: Zimmerman, J.J., Karriker, L.A., Ramirez, A., Schwartz, K.J., Stevenson, G.W. (Eds.), *Diseases of Swine*, tenth ed. Wiley-Blackwell, Chichester, West Sussex.
- Hansen, M.S., Pors, S.E., Jensen, H.E., Bille-Hansen, V., Bisgaard, M., Flachs, E.M., et al., 2010. An investigation of the pathology and pathogens associated with porcine respiratory disease complex in Denmark. *J. Comp. Pathol.* 143, 120–131.
- Hansen, M.S., Segales, J., Fernandes, L.T., Grau-Roma, L., Bille-Hansen, V., Larsen, L.E., et al., 2013. Detection of porcine circovirus type 2 and viral replication by in situ hybridization in primary lymphoid organs from naturally and experimentally infected pigs. *Vet. Pathol.*
- Harris, I.T., Fedorka-Cray, P.J., Gray, J.T., Thomas, L.A., Ferris, K., 1997. Prevalence of *Salmonella* organisms in swine feed. *J. Am. Vet. Med. Assoc.* 210, 382–385.
- Harville, B.A., Dreyfus, L.A., 1995. Involvement of 5-hydroxytryptamine and prostaglandin E2 in the intestinal secretory action of *Escherichia coli* heat-stable enterotoxin B. *Infect. Immun.* 63, 745–750.
- Health, W.O.F.A., 2013a. Manual of Diagnostic Tests and Vaccines for Terrestrial Animals 2013 [Online]. OIE Organization Mondiale de la Sante Animale. Available: <<http://www.oie.int/international-standard-setting/terrestrial-manual/access-online/>> (accessed 12.02.14).
- Health, W.O.F.A., 2013b. OIE-Listed Diseases, Infections and Infestations in Force in 2013 [Online]. OIE Organization Mondiale de la Sante Animale, Paris, France. Available: <<http://www.oie.int/animal-health-in-the-world/oie-listed-diseases-2013/>> (accessed 2.09.13).
- Hedger, R.S., Mann, J.A., 1989. Swine vesicular disease virus. In: Pesaert, M.B. (Ed.), *Virus Infection of Pigs*, second ed. Elsevier Science Publishers BV, Amsterdam, The Netherlands.
- Heinritz, K., Aigner, K., Erber, M., Kersjes, C., Von Wangenheim, B., 1999. Brucellosis and Aujeszky's disease in a wild boar enclosure. Case report. *Tierarztl. Prax. Ausg. G. Grosstiere Nutztiere* 27, 41–46.
- Helke, K.L., Swindle, M.M., 2013. Animal models of toxicology testing: the role of pigs. *Exp. Opin. Drug Metab. Toxicol.* 9, 127–139.
- Henderson, J.P., O'hagan, J., Hawe, S.M., Pratt, M.C., 1997. Anaemia and low viability in piglets infected with *Eperythrozoon suis*. *Vet. Rec.* 140, 144–146.
- Henne, E., Nickel, S., Hiepe, T., 1978. Parasites in the GDR.1. Studies on helminths occurrence in European wild pigs (*Sus scrofa*). *Angew. Parasitol.* 19, 52–57.
- Hensel, A., Stockhofe-Zurwieden, N., Petzoldt, K., Lubitz, W., 1995. Oral immunization of pigs with viable or inactivated *Actinobacillus pleuropneumoniae* serotype 9 induces pulmonary and systemic antibodies and protects against homologous aerosol challenge. *Infect. Immun.* 63, 3048–3053.

- Hill, B.D., Corney, B.G., Wagner, T.M., 1996. Importance of *Staphylococcus hyicus* ssp *hyicus* as a cause of arthritis in pigs up to 12 weeks of age. *Aust. Vet. J.* 73, 179–181.
- Hodgins, D.C., Shewen, P.E., Dewey, C.E., 2004. Influence of age and maternal antibodies on antibody responses of neonatal piglets vaccinated against *Mycoplasma hyopneumoniae*. *J. Swine Health Prod.* 12, 10–16.
- Hogg, G.G., Lenghaus, C., Forman, A.J., 1977. Experimental porcine parvovirus infection of foetal pigs resulting in abortion, histological lesions and antibody formation. *J. Comp. Pathol.* 87, 539–549.
- Hollanders, W., Vercruyse, J., 1990. Sarcoptic mite hypersensitivity: a cause of dermatitis in fattening pigs at slaughter. *Vet. Rec.* 126, 308–310.
- Hollanders, W., Harbers, A.H., Huige, J.C., Monster, P., Rambags, P.G., Hendriks, W.M., 1995. Control of *Sarcoptes scabiei* var. *suis* with ivermectin: influence on scratching behaviour of fattening pigs and occurrence of dermatitis at slaughter. *Vet. Parasitol.* 58, 117–127.
- Hollanders, W., Vercruyse, J., Raes, S., Bornstein, S., 1997. Evaluation of an enzyme-linked immunosorbent assay (ELISA) for the serological diagnosis of sarcoptic mange in swine. *Vet. Parasitol.* 69, 117–123.
- Holman, J.E., Koestner, A., Kasza, L., 1966. Histopathogenesis of porcine polioencephalomyelitis in the germ free pig. *Pathol. Vet.* 3, 633–651.
- Hooper, B.E., Haelterman, E.O., 1966. Growth of transmissible gastroenteritis virus in young pigs. *Am. J. Vet. Res.* 27, 286–291.
- Hooper, B.E., Haelterman, E.O., 1969. Lesions of the gastrointestinal tract of pigs infected with transmissible gastroenteritis. *Can. J. Comp. Med.* 33, 29–36.
- Horiguchi, Y., Okada, T., Sugimoto, N., Morikawa, Y., Katahira, J., Matsuda, M., 1995. Effects of *Bordetella bronchiseptica* dermonecrotizing toxin on bone formation in calvaria of neonatal rats. *FEMS Immunol. Med. Microbiol.* 12, 29–32.
- Hormansdorfer, S., Bauer, J., 1998. Resistance of bovine and porcine *Pasteurella* to florfenicol and other antibiotics. *Berl. Munch. Tierarztl. Wochenschr.* 111, 422–426.
- Horner, B.M., Randolph, M.A., Huang, C.A., Butler, P.E., 2008. Skin tolerance: in search of the Holy Grail. *Transpl. Int.* 21, 101–112.
- Huang, C.A., Lorf, T., Arn, J.S., Koo, G.C., Blake, T., Sachs, D.H., 1999. Characterization of a monoclonal anti-porcine CD3 antibody. *Xenotransplantation* 6, 201–212.
- Huang, C.A., Fuchimoto, Y., Gleit, Z.L., Ericsson, T., Griesemer, A., Scheier-Dolberg, R., et al., 2001. Posttransplantation lymphoproliferative disease in miniature swine after allogeneic hematopoietic cell transplantation: similarity to human PTL and association with a porcine gammaherpesvirus. *Blood* 97, 1467–1473.
- Huang, Y.Y., Walther, I., Martinson, S.A., Lopez, A., Yason, C., Godson, D.L., et al., 2008. Porcine circovirus 2 inclusion bodies in pulmonary and renal epithelial cells. *Vet. Pathol.* 45, 640–644.
- Hughes, R., Olander, H.J., Kanitz, D.L., Qureshi, S., 1977. A study of swine dysentery by immunofluorescence and histology. *Vet. Pathol.* 14, 490–507.
- Ierino, F.L., Gojo, S., Banerjee, P.T., Giovino, M., Xu, Y., Gere, J., et al., 1999. Transfer of swine major histocompatibility complex class II genes into autologous bone marrow cells of baboons for the induction of tolerance across xenogeneic barriers. *Transplantation* 67, 1119–1128.
- Ilha, M.R., Newman, S.J., Van Amstel, S., Fecteau, K.A., Rohrbach, B.W., 2010. Uterine lesions in 32 female miniature pet pigs. *Vet. Pathol.* 47, 1071–1075.
- Imada, Y., Goji, N., Ishikawa, H., Kishima, M., Sekizaki, T., 1999. Truncated surface protective antigen (SpaA) of *Erysipelothrix rhusiopathiae* serotype 1a elicits protection against challenge with serotypes 1a and 2b in pigs. *Infect. Immun.* 67, 4376–4382.
- Institute of Laboratory Animal Resources (U.S.). Committee on Care and Use of Laboratory Animals, 2011. Guide for the Care and Use of Laboratory Animals. NIH Publication, Bethesda, MD, The National Academies Press.
- Iowa State University: The Center for Food Security and Public Health, 2014. Swine Diseases and Resources [Online]. Iowa State University: The Center for Food Security and Public Health. Available: <<http://www.cfsph.iastate.edu/Species/swine.php>> (accessed 10.04.14).
- Jackson, P.G.G., Cockcroft, P.D., 2007. Haematology and blood biochemistry in the pig. In: Jackson, P.G.G., Cockcroft, P.D. (Eds.), *Handbook of Pig Medicine*. Saunders Elsevier, Amsterdam, The Netherlands.
- Jacobs, A.A., Van Den Berg, A.J., Loeffen, P.L., 1996. Protection of experimentally infected pigs by suliyisin, the thiol-activated haemolysin of *Streptococcus suis*. *Vet. Rec.* 139, 225–228.
- Jacobson, M., Bornstein, S., Wallgren, P., 1999. The efficacy of simplified eradication strategies against sarcoptic mange mite infections in swine herds monitored by an ELISA. *Vet. Parasitol.* 81, 249–258.
- Jamalludeen, N., Johnson, R.P., Shewen, P.E., Gyles, C.L., 2009. Evaluation of bacteriophages for prevention and treatment of diarrhea due to experimental enterotoxigenic *Escherichia coli* O149 infection of pigs. *Vet. Microbiol.* 136, 135–141.
- Jasni, S., McOrist, S., Lawson, G.H., 1994. Reproduction of proliferative enteritis in hamsters with a pure culture of porcine ileal symbiont intracellularis. *Vet. Microbiol.* 41, 1–9.
- Jensen, T.K., Boye, M., Hagedorn-Olsen, T., Riising, H.J., Angen, O., 1999. *Actinobacillus pleuropneumoniae* osteomyelitis in pigs demonstrated by fluorescent in situ hybridization. *Vet. Pathol.* 36, 258–261.
- Jensen, T.K., Moller, K., Boye, M., Leser, T.D., Jorsal, S.E., 2000. Scanning electron microscopy and fluorescent in situ hybridization of experimental *Brachyspira* (*Serpulina*) *pilosicoli* infection in growing pigs. *Vet. Pathol.* 37, 22–32.
- Jensen, T.K., Vigre, H., Svensmark, B., Bille-Hansen, V., 2006. Distinction between porcine circovirus type 2 enteritis and porcine proliferative enteropathy caused by *Lawsonia intracellularis*. *J. Comp. Pathol.* 135, 176–182.
- Johnson, R.H., 1973. Isolation of swine papovirus in Queensland. *Aust. Vet. J.* 49, 157–159.
- Jones, L.D., 1956. Exudative epidermitis of pigs. *Am. J. Vet. Res.* 17, 179–193.
- Jones, T.C., Hunt, R.D., 1983. Diseases caused by parasitic helminths and arthropods. In: Jones, T.C., Hunt, R.D., Smith, H.A. (Eds.), *Veterinary Pathology*, fifth ed. Lea & Febiger, Philadelphia, PA.
- Joo, H.S., Donaldson-Wood, C.R., Johnson, R.H., 1976. Observations on the pathogenesis of porcine parvovirus infection. *Arch. Virol.* 51, 123–129.
- Joo, H.S., Donaldson-Wood, C.R., Johnson, R.H., Campbell, R.S., 1977. Pathogenesis of porcine parvovirus infection: pathology and immunofluorescence in the foetus. *J. Comp. Pathol.* 87, 383–391.
- Jung, T., Choi, C., Chae, C., 2002. Localization of swine influenza virus in naturally infected pigs. *Vet. Pathol.* 39, 10–16.
- Kamp, E.M., Bokken, G.C., Vermeulen, T.M., De Jong, M.F., Buys, H.E., Reek, F.H., et al., 1996. A specific and sensitive PCR assay suitable for large-scale detection of toxigenic *Pasteurella multocida* in nasal and tonsillar swabs specimens of pigs. *J. Vet. Diagn. Invest.* 8, 304–309.
- Kamp, E.M., Stockhofe-Zurwieden, N., Van Leengoed, L.A., Smits, M.A., 1997. Endobronchial inoculation with Apx toxins of *Actinobacillus pleuropneumoniae* leads to pleuropneumonia in pigs. *Infect. Immun.* 65, 4350–4354.
- Kaper, J.B., Nataro, J.P., Mobley, H.L., 2004. Pathogenic *Escherichia coli*. *Nat. Rev. Microbiol.* 2, 123–140.
- Kataoka, Y., Yamashita, T., Sunaga, S., Imada, Y., Ishikawa, H., Kishima, M., et al., 1996. An enzyme-linked immunosorbent assay (ELISA) for the detection of antibody against *Streptococcus suis* type 2 in infected pigs. *J. Vet. Med. Sci.* 58, 369–372.

- Kawashima, K., Yamada, S., Kobayashi, H., Narita, M., 1996. Detection of porcine reproductive and respiratory syndrome virus and *Mycoplasma hyorhinis* antigens in pulmonary lesions of pigs suffering from respiratory distress. *J. Comp. Pathol.* 114, 315–323.
- Keel, M.K., Songer, J.G., 2006. The comparative pathology of *Clostridium difficile*-associated disease. *Vet. Pathol.* 43, 225–240.
- Keel, M.K., Songer, J.G., 2011. The attachment, internalization, and time-dependent, intracellular distribution of *Clostridium difficile* toxin A in porcine intestinal explants. *Vet. Pathol.* 48, 369–380.
- Kelneric, Z., Naglic, T., Udovicic, I., 1996. Prevention of necrotic enteritis in piglets by vaccination of pregnant gilts with a *Clostridium perfringens* type C and D bacterin-toxoid. *Vet. Med. (Praha)* 41, 335–338.
- Kelsey, D.K., Olsen, G.A., Overall Jr, J.C., Glasgow, L.A., 1977. Alteration of host defense mechanisms by murine cytomegalovirus infection. *Infect. Immun.* 18, 754–760.
- Kim, B., Ahn, K.K., Ha, Y., Lee, Y.H., Kim, D., Lim, J.H., et al., 2009a. Association of tumor necrosis factor- α with fever and pulmonary lesion score in pigs experimentally infected with swine influenza virus subtype H1N2. *J. Vet. Med. Sci.* 71, 611–616.
- Kim, H.B., Lyoo, K.S., Joo, H.S., 2009b. Efficacy of different disinfectants in vitro against porcine circovirus type 2. *Vet. Rec.* 164, 599–600.
- Kim, J., Chae, C., 2004. A comparison of virus isolation, polymerase chain reaction, immunohistochemistry, and in situ hybridization for the detection of porcine circovirus 2 and porcine parvovirus in experimentally and naturally coinfecting pigs. *J. Vet. Diagn. Invest.* 16, 45–50.
- Kirkland, P.D., Le Potier, M.-F., Vannier, P., Finlaison, D., 2012a. Pestiviruses. In: Zimmerman, J.J. (Ed.), *Diseases of Swine*, tenth ed. Wiley-Blackwell, Chichester, West Sussex.
- Kirkland, P.D., Stephano, A., Weingartl, H.M., 2012b. Paramyxoviruses. In: Zimmerman, J.J. (Ed.), *Diseases of Swine*, tenth ed. Wiley-Blackwell, Chichester, West Sussex.
- Kirkwood, R.N., Althouse, G.C., Yaeger, M.J., Carr, J., Almond, G.W., 2012. Diseases of the reproductive system. In: Zimmerman, J.J., Karriker, L.A., Ramirez, A., Schwartz, K.J., Stevenson, G.W. (Eds.), *Diseases of Swine*, tenth ed. Wiley-Blackwell, Chichester, West Sussex.
- Knowles, N.J., Reuter, G., 2012. Porcine caliciviruses. In: Zimmerman, J.J., Karriker, L.A., Ramirez, A., Schwartz, K.J., Stevenson, G.W. (Eds.), *Diseases of Swine*, tenth ed. Wiley-Blackwell, Chichester, West Sussex.
- Kobayashi, E., Hishikawa, S., Teratani, T., Lefor, A.T., 2012. The pig as a model for translational research: overview of porcine animal models at Jichi Medical University. *Transplant. Res.* 1, 8.
- Koenen, F., Vanderhallen, H., Castryck, F., Miry, C., 1999. Epidemiologic, pathogenic and molecular analysis of recent encephalomyocarditis outbreaks in Belgium. *Zentralbl. Veterinarmed. B* 46, 217–231.
- Koestner, A., Kasza, L., Holman, J.E., 1966. Electron microscopic evaluation of the pathogenesis of porcine polioencephalomyelitis. *Am. J. Pathol.* 49, 325–337.
- Kolber-Simonds, D., Lai, L., Watt, S.R., Denaro, M., Arn, S., Augenstein, M.L., et al., 2004. Production of alpha-1,3-galactosyltransferase null pigs by means of nuclear transfer with fibroblasts bearing loss of heterozygosity mutations. *Proc. Natl. Acad. Sci. USA* 101, 7335–7340.
- Koudela, B., Nohynkova, E., Vitovec, J., Pakandl, M., Kulda, J., 1991. *Giardia* infection in pigs: detection and in vitro isolation of trophozoites of the *Giardia intestinalis* group. *Parasitology* 102 (Pt 2), 163–166.
- Kozlowski, T., Ierino, F.L., Lambrigts, D., Foley, A., Andrews, D., Awwad, M., et al., 1998. Depletion of anti-Gal(alpha)1-3Gal antibody in baboons by specific alpha-Gal immunoaffinity columns. *Xenotransplantation* 5, 122–131.
- Krakovka, S., Ellis, J., 2006. Reproduction of severe gastroesophageal ulcers (GEU) in gnotobiotic swine infected with porcine *Helicobacter pylori*-like bacteria. *Vet. Pathol.* 43, 956–962.
- Krakovka, S., Ellis, J.A., Mcneilly, F., Ringler, S., Rings, D.M., Allan, G., 2001. Activation of the immune system is the pivotal event in the production of wasting disease in pigs infected with porcine circovirus-2 (PCV-2). *Vet. Pathol.* 38, 31–42.
- Krakovka, S., Hartunian, C., Hamberg, A., Shoup, D., Rings, M., Zhang, Y., et al., 2008. Evaluation of induction of porcine dermatitis and nephropathy syndrome in gnotobiotic pigs with negative results for porcine circovirus type 2. *Am. J. Vet. Res.* 69, 1615–1622.
- Krakovka, S., Allan, G., Ellis, J., Hamberg, A., Charreyre, C., Kaufmann, E., et al., 2012. A nine-base nucleotide sequence in the porcine circovirus type 2 (PCV2) nucleocapsid gene determines viral replication and virulence. *Virus Res.* 164, 90–99.
- Krawczynski, K., Meng, X.J., Rybczynska, J., 2011. Pathogenetic elements of hepatitis E and animal models of HEV infection. *Virus Res.* 161, 78–83.
- Kritas, S.K., Pensaert, M.B., Nauwynck, H.J., Kyriakis, S.C., 1999. Neural invasion of two virulent suid herpesvirus 1 strains in neonatal pigs with or without maternal immunity. *Vet. Microbiol.* 69, 143–156.
- Kroll, J.J., Roof, M.B., McOrist, S., 2004. Evaluation of protective immunity in pigs following oral administration of an avirulent live vaccine of *Lawsonia intracellularis*. *Am. J. Vet. Res.* 65, 559–565.
- Kulick, D.M., Salerno, C.T., Dalmasso, A.P., Park, S.J., Paz, M.G., Fodor, W.L., et al., 2000. Transgenic swine lungs expressing human CD59 are protected from injury in a pig-to-human model of xenotransplantation. *J. Thorac. Cardiovasc. Surg.* 119, 690–699.
- Kyriakis, S.C., Sarris, K., Kritas, S.K., Tsinas, A.C., Giannakopoulos, C., 1996. Effect of salinomycin in the control of *Clostridium perfringens* type C infections in sucklings pigs. *Vet. Rec.* 138, 281–283.
- Langohr, I.M., Stevenson, G.W., Nelson, E.A., Lenz, S.D., Wei, H., Pogradichny, R.M., 2012. Experimental co-infection of pigs with Bovine viral diarrhoea virus 1 and Porcine circovirus-2. *J. Vet. Diagn. Invest.* 24, 51–64.
- Lapage, G., 1968. Order Phthiraptera. In: Lapage, G. (Ed.), *Veterinary Parasitology*, second rev. ed. Thomas, Springfield, IL.
- Lawson, G.H., McOrist, S., Jasni, S., Mackie, R.A., 1993. Intracellular bacteria of porcine proliferative enteropathy: cultivation and maintenance in vitro. *J. Clin. Microbiol.* 31, 1136–1142.
- Lee, C.A., Silva, M., Siber, A.M., Kelly, A.J., Galyov, E., McCormick, B.A., 2000. A secreted Salmonella protein induces a proinflammatory response in epithelial cells, which promotes neutrophil migration. *Proc. Natl. Acad. Sci. USA* 97, 12283–12288.
- Lee, J.I., Hampson, D.J., Lymbery, A.J., Harders, S.J., 1993. The porcine intestinal spirochaetes: identification of new genetic groups. *Vet. Microbiol.* 34, 273–285.
- Leiner, G., Franz, B., Strutzberg, K., Gerlach, G.F., 1999. A novel enzyme-linked immunosorbent assay using the recombinant *Actinobacillus pleuropneumoniae* ApxII antigen for diagnosis of pleuropneumonia in pig herds. *Clin. Diagn. Lab. Immunol.* 6, 630–632.
- Levonen, K., Frandsen, P.L., Seppanen, J., Veijalainen, P., 1996. Detection of toxigenic *Pasteurella multocida* infections in swine herds by assaying antibodies in sow colostrum. *J. Vet. Diagn. Invest.* 8, 455–459.
- Levy, M.F., Crippin, J., Sutton, S., Netto, G., McCormack, J., Curiel, T., et al., 2000. Liver allotransplantation after extracorporeal hepatic support with transgenic (hCD55/hCD59) porcine livers: clinical results and lack of pig-to-human transmission of the porcine endogenous retrovirus. *Transplantation* 69, 272–280.
- Lewis, A.J., Southern, L.L., 2001. *Swine Nutrition*. CRC Press, Boca Raton, FL.
- Li, H.W., Sykes, M., 2012. Emerging concepts in haematopoietic cell transplantation. *Nat. Rev. Immunol.* 12, 403–416.
- Li, Y., Wang, X., Bo, K., Wang, X., Tang, B., Yang, B., et al., 2007. Emergence of a highly pathogenic porcine reproductive and respiratory syndrome virus in the Mid-Eastern region of China. *Vet. J.* 174, 577–584.

- Lichtensteiger, C.A., Steenbergen, S.M., Lee, R.M., Polson, D.D., Vimr, E.R., 1996. Direct PCR analysis for toxigenic *Pasteurella multocida*. *J. Clin. Microbiol.* 34, 3035–3039.
- Lichtensteiger, C.A., Dipietro, J.A., Paul, A.J., Neumann, E.J., Thompson, L., 1999. Persistent activity of doramectin and ivermectin against *Ascaris suum* in experimentally infected pigs. *Vet. Parasitol.* 82, 235–241.
- Lindecrona, R.H., Jensen, T.K., Moller, K., 2004. Influence of diet on the experimental infection of pigs with *Brachyspira pilosicoli*. *Vet. Rec.* 154, 264–267.
- Lindsay, D.S., Dubey, J.P., Blagburn, B.L., 1997. Biology of *Isospora* spp. from humans, nonhuman primates, and domestic animals. *Clin. Microbiol. Rev.* 10, 19–34.
- Lindsay, D.S., Dubey, J.P., Santin-Duran, M., Fayer, R., 2012. Coccidia and other protozoa. In: Zimmerman, J.J., Karriker, L.A., Ramirez, A., Schwartz, K.J., Stevenson, G.W. (Eds.), *Diseases of Swine*, tenth ed. Wiley-Blackwell, Chichester, West Sussex.
- Little, T.W., Harding, J.D., 1971. The comparative pathogenicity of two porcine haemophilus species. *Vet. Rec.* 88, 540–545.
- Logan, N.B., Weatherley, A.J., Jones, R.M., 1996. Activity of doramectin against nematode and arthropod parasites of swine. *Vet. Parasitol.* 66, 87–94.
- Loken, T., Aleksandersen, M., Reid, H., Pow, I., 1998. Malignant catarrhal fever caused by ovine herpesvirus-2 in pigs in Norway. *Vet. Rec.* 143, 464–467.
- Love, D.N., Love, R.J., 1979. Pathology of proliferative haemorrhagic enteropathy in pigs. *Vet. Pathol.* 16, 41–48.
- Macinnes, J.I., Desrosiers, R., 1999. Agents of the ‘suis-ide diseases’ of swine: *Actinobacillus suis*, *Haemophilus parasuis*, and *Streptococcus suis*. *Can. J. Vet. Res.* 63, 83–89.
- Macintyre, N., Smith, D.G., Shaw, D.J., Thomson, J.R., Rhind, S.M., 2003. Immunopathogenesis of experimentally induced proliferative enteropathy in pigs. *Vet. Pathol.* 40, 421–432.
- Mackenzie, J.S., Gubler, D.J., Petersen, L.R., 2004. Emerging flaviviruses: the spread and resurgence of Japanese encephalitis, West Nile and dengue viruses. *Nat. Med.* 10, S98–109.
- Madsen, L.W., Svensmark, B., Elvestad, K., Jensen, H.E., 2001. Otitis interna is a frequent sequela to *Streptococcus suis* meningitis in pigs. *Vet. Pathol.* 38, 190–195.
- Madsen, L.W., Svensmark, B., Elvestad, K., Aalbaek, B., Jensen, H.E., 2002. *Streptococcus suis* serotype 2 infection in pigs: new diagnostic and pathogenetic aspects. *J. Comp. Pathol.* 126, 57–65.
- Makino, S., Yamamoto, K., Murakami, S., Shirahata, T., Uemura, K., Sawada, T., et al., 1998. Properties of repeat domain found in a novel protective antigen, SpaA, of *Erysipelothrix rhusiopathiae*. *Microb. Pathog.* 25, 101–109.
- Mankertz, A., 2012. Molecular interactions of porcine circoviruses type 1 and type 2 with its host. *Virus Res.* 164, 54–60.
- Maratea, K.A., Snyder, P.W., Stevenson, G.W., 2006. Vascular lesions in nine Gottingen minipigs with thrombocytopenic purpura syndrome. *Vet. Pathol.* 43, 447–454.
- Marchant-Forde, R.M., Marchant-Forde, J.N., 2004. Pregnancy-related changes in behavior and cardiac activity in primiparous pigs. *Physiol. Behav.* 82, 815–825.
- Marie, J., Morvan, H., Berthelot-Herault, F., Sanders, P., Kempf, I., Gautier-Bouchardon, A.V., et al., 2002. Antimicrobial susceptibility of *Streptococcus suis* isolated from swine in France and from humans in different countries between 1996 and 2000. *J. Antimicrob. Chemother.* 50, 201–209.
- Marsh, G.A., Haining, J., Robinson, R., Foord, A., Yamada, M., Barr, J.A., et al., 2011. Ebola Reston virus infection of pigs: clinical significance and transmission potential. *J. Infect. Dis.* 204 (Suppl. 3), S804–S809.
- Mason, R.J., Fleming, P.J., Smythe, L.D., Dohnt, M.F., Norris, M.A., Symonds, M.L., 1998. *Leptospira interrogans* antibodies in feral pigs from New South Wales. *J. Wildl. Dis.* 34, 738–743.
- Mateusen, B., Maes, D.G., Van Soom, A., Lefebvre, D., Nauwynck, H.J., 2007. Effect of a porcine circovirus type 2 infection on embryos during early pregnancy. *Theriogenology* 68, 896–901.
- Matsunari, H., Nagashima, H., 2009. Application of genetically modified and cloned pigs in translational research. *J. Reprod. Dev.* 55, 225–230.
- Maurice, H., Nielen, M., Vyt, P., Frankena, K., Koenen, F., 2007. Factors related to the incidence of clinical encephalomyocarditis virus (EMCV) infection on Belgian pig farms. *Prev. Vet. Med.* 78, 24–34.
- Maxie, M.G., Jubb, K.V.F., 2007. Cardiovascular system. In: Maxie, M.G., Robinson, W.F. (Eds.), *Pathology of Domestic Animals*, fifth ed. Elsevier Saunders, Edinburgh; New York.
- McAnulty, P.A., 2012. *The Minipig in Biomedical Research*. CRC Press/Taylor & Francis, Boca Raton, FL.
- McGavin, M.D., Zachary, J.F., 2007. *Pathologic Basis of Veterinary Disease*. Elsevier Mosby, St. Louis, MO.
- McGregor, C.G., Davies, W.R., Oi, K., Teotia, S.S., Schirmer, J.M., Risdahl, J.M., et al., 2005. Cardiac xenotransplantation: recent preclinical progress with 3-month median survival. *J. Thorac. Cardiovasc. Surg.* 130, 844–851.
- McOrist, S., Gebhart, C.J., 2012. Proliferative enteropathy. In: Zimmerman, J.J., Karriker, L.A., Ramirez, A., Schwartz, K.J., Stevenson, G.W. (Eds.), *Diseases of Swine*, tenth ed. Wiley-Blackwell, Chichester, West Sussex.
- McOrist, S., Gebhart, C.J., Boid, R., Barns, S.M., 1995a. Characterization of *Lawsonia intracellularis* gen. nov., sp. nov., the obligately intracellular bacterium of porcine proliferative enteropathy. *Int. J. Syst. Bacteriol.* 45, 820–825.
- McOrist, S., Mackie, R.A., Lawson, G.H., 1995b. Antimicrobial susceptibility of ileal symbiont *intracellularis* isolated from pigs with proliferative enteropathy. *J. Clin. Microbiol.* 33, 1314–1317.
- McOrist, S., Morgan, J., Veenhuizen, M.F., Lawrence, K., Kroger, H.W., 1997. Oral administration of tylosin phosphate for treatment and prevention of proliferative enteropathy in pigs. *Am. J. Vet. Res.* 58, 136–139.
- McOrist, S., Smith, S.H., Shearn, M.F., Carr, M.M., Miller, D.J., 1996. Treatment and prevention of porcine proliferative enteropathy with oral tiamulin. *Vet. Rec.* 139, 615–618.
- Meerts, P., Van Gucht, S., Cox, E., Vandebosch, A., Nauwynck, H.J., 2005. Correlation between type of adaptive immune response against porcine circovirus type 2 and level of virus replication. *Viral. Immunol.* 18, 333–341.
- Meng, X.J., Wiseman, B., Elvinger, F., Guenette, D.K., Toth, T.E., Engle, R.E., et al., 2002. Prevalence of antibodies to hepatitis E virus in veterinarians working with swine and in normal blood donors in the United States and other countries. *J. Clin. Microbiol.* 40, 117–122.
- Mengeling, W.L., Paul, P.S., 1986. Interepizootic survival of porcine parvovirus. *J. Am. Vet. Med. Assoc.* 188, 1293–1295.
- Mengeling, W.L., Lager, K.M., Zimmerman, J.K., Samarikermani, N., Beran, G.W., 1991. A current assessment of the role of porcine parvovirus as a cause of fetal porcine death. *J. Vet. Diagn. Invest.* 3, 33–35.
- Mengeling, W.L., Paul, P.S., Lager, K.M., 1993. Virus-induced maternal reproductive failure of swine. *J. Am. Vet. Med. Assoc.* 203, 1268–1272.
- Mengeling, W.L., Lager, K.M., Vorwald, A.C., 2000. The effect of porcine parvovirus and porcine reproductive and respiratory syndrome virus on porcine reproductive performance. *Anim. Reprod. Sci.* 60–61, 199–210.
- Mercier, P., Cargill, C.F., White, C.R., 2002. Preventing transmission of sarcoptic mange from sows to their offspring by injection of ivermectin. Effects on swine production. *Vet. Parasitol.* 110, 25–33.
- Messick, J.B., 2004. Hemotropic mycoplasmas (hemoplasmas): a review and new insights into pathogenic potential. *Vet. Clin. Pathol.* 33, 2–13.
- Messick, J.B., Cooper, S.K., Huntley, M., 1999. Development and evaluation of a polymerase chain reaction assay using the 16S rRNA

- gene for detection of Eperythrozoon suis infection. J. Vet. Diagn. Invest. 11, 229–236.
- Mettenleiter, T.C., 2000. Aujeszky's disease (pseudorabies) virus: the virus and molecular pathogenesis – state of the art, June 1999. Vet. Res. 31, 99–115.
- Mettenleiter, T.C., Ehlers, B., Muller, T., Yoon, K.-J., Teifke, J.P., 2012. Herpesviruses. In: Zimmerman, J.J., Karriker, L.A., Ramirez, A., Schwartz, K.J., Stevenson, G.W. (Eds.), Diseases of Swine, tenth ed. Wiley-Blackwell, Chichester, West Sussex.
- Meyerholz, D.K., Stabel, T.J., 2003. Comparison of early ileal invasion by Salmonella enterica serovars Choleraesuis and Typhimurium. Vet. Pathol. 40, 371–375.
- Meyerholz, D.K., Stabel, T.J., Ackermann, M.R., Carlson, S.A., Jones, B.D., Pohlenz, J., 2002. Early epithelial invasion by Salmonella enterica serovar Typhimurium DT104 in the swine ileum. Vet. Pathol. 39, 712–720.
- Mezrich, J.D., Haller, G.W., Arn, J.S., Houser, S.L., Madsen, J.C., Sachs, D.H., 2003. Histocompatible miniature swine: an inbred large-animal model. Transplantation 75, 904–907.
- Mielke, D., Hiepe, T., 1998. The effectiveness of different disinfectants based on p-chloro-m-cresol against Ascaris suum eggs under laboratory conditions. Berl. Munch. Tierarztl. Wochenschr. 111, 291–294.
- Mikami, O., Nakajima, H., Kawashima, K., Yoshii, M., Nakajima, Y., 2005. Nonsuppurative myocarditis caused by porcine circovirus type 2 in a weak-born piglet. J. Vet. Med. Sci. 67, 735–738.
- Minipigs, E.G., 2010. The Gottingen Minipig [Online]. Available: <<http://minipigs.dk/thegottingenminipig/>> (accessed 18.06.12).
- Misinzo, G., Delputte, P.L., Meerts, P., Lefebvre, D.J., Nauwynck, H.J., 2006. Porcine circovirus 2 uses heparan sulfate and chondroitin sulfate B glycosaminoglycans as receptors for its attachment to host cells. J. Virol. 80, 3487–3494.
- Moller, K., Jensen, T.K., Jorsal, S.E., Leser, T.D., Carstensen, B., 1998. Detection of Lawsonia intracellularis, Serpulina hyodysenteriae, weakly beta-haemolytic intestinal spirochaetes, Salmonella enterica, and haemolytic Escherichia coli from swine herds with and without diarrhoea among growing pigs. Vet. Microbiol. 62, 59–72.
- Morandi, F., Ostanello, F., Fusaro, L., Bacci, B., Nigrelli, A., Alborali, L., et al., 2010. Immunohistochemical detection of aetiological agents of proliferative and necrotizing pneumonia in Italian pigs. J. Comp. Pathol. 142, 74–78.
- Morita, T., Sasaki, A., Kaji, N., Shimada, A., Kazama, S., Yagihashi, T., et al., 1998. Induction of temporary otitis media in specific-pathogen-free pigs by intratympanic inoculation of Mycoplasma hyorhinis. Am. J. Vet. Res. 59, 869–873.
- Morita, T., Ohiwa, S., Shimada, A., Kazama, S., Yagihashi, T., Umamura, T., 1999. Intranasally inoculated Mycoplasma hyorhinis causes eustachitis in pigs. Vet. Pathol. 36, 174–178.
- Morsy, G.H., Turek, J.J., Gaafar, S.M., 1989. Scanning electron microscopy of sarcoptic mange lesions in swine. Vet. Parasitol. 31, 281–288.
- Mozzachio, K., Linder, K., Dixon, D., 2004. Uterine smooth muscle tumors in potbellied pigs (Sus scrofa) resemble human fibroids: a potential animal model. Toxicol. Pathol. 32, 402–407.
- Mueller, N.J., Livingston, C., Knosalla, C., Barth, R.N., Yamamoto, S., Gollackner, B., et al., 2004. Activation of porcine cytomegalovirus, but not porcine lymphotropic herpesvirus, in pig-to-baboon xenotransplantation. J. Infect. Dis. 189, 1628–1633.
- Mueller, Y.M., Davenport, C., Ildstad, S.T., 1999. Xenotransplantation: application of disease resistance. Clin. Exp. Pharmacol. Physiol. 26, 1009–1012.
- Mulder, W.A., Pol, J.M., Gruys, E., Jacobs, L., De Jong, M.C., Peeters, B.P., et al., 1997. Pseudorabies virus infections in pigs. Role of viral proteins in virulence, pathogenesis and transmission. Vet. Res. 28, 1–17.
- Muneta, Y., Minagawa, Y., Shimoji, Y., Nagata, R., Markham, P.F., Browning, G.F., et al., 2006. IL-18 expression in pigs following infection with Mycoplasma hyopneumoniae. J. Interferon Cytokine Res. 26, 637–644.
- Murakata, K., Sato, A., Yoshiya, M., Kim, S., Watarai, M., Omata, Y., et al., 2008. Infection of different strains of mice with Lawsonia intracellularis derived from rabbit or porcine proliferative enteropathy. J. Comp. Pathol. 139, 8–15.
- Murrell, K.D., Eriksen, L., Nansen, P., Slotved, H.C., Rasmussen, T., 1997. Ascaris suum: a revision of its early migratory path and implications for human ascariasis. J. Parasitol. 83, 255–260.
- Murtaugh, M.P., 1994. Porcine cytokines. Vet. Immunol. Immunopathol. 43, 37–44.
- National Research Council (U.S.). Committee on Nutrient Requirements of Swine, 2012. Nutrient Requirements of Swine. National Academies Press, Washington, DC.
- Nauwynck, H.J., Sanchez, R., Meerts, P., Lefebvre, D.J., Saha, D., Huang, L., et al., 2012. Cell tropism and entry of porcine circovirus 2. Virus Res. 164, 43–45.
- Neimark, H., Johansson, K.E., Rikihisa, Y., Tully, J.G., 2002. Revision of haemotrophic Mycoplasma species names. Int. J. Syst. Evol. Microbiol. 52, 683.
- Nickel, E.A., Danner, G., 1979. Experimental studies on the course and the effects of pediculosis in domestic swine. Arch. Exp. Veterinarmed. 33, 645–649.
- Nielsen, R., 1973. An outbreak of pleuropneumonia among a group of baconers. Pathological and bacteriological observations. Nord. Vet. Med. 25, 492–496.
- Niilo, C.L., 1993. Enterotoxemic Clostridium perfringens. In: Gyles, C.L., Thoen, C.O. (Eds.), Pathogenesis of Bacterial Infections in Animals, second ed. Iowa State University, Ames, IA.
- Nikolic, B., Gardner, J.P., Scadden, D.T., Arn, J.S., Sachs, D.H., Sykes, M., 1999. Normal development in porcine thymus grafts and specific tolerance of human T cells to porcine donor MHC. J. Immunol. 162, 3402–3407.
- Nilubol, D., Pattanaseth, T., Boonsri, K., Pirarat, N., Leepipatpiboon, N., 2009. Melamine- and cyanuric acid-associated renal failure in pigs in Thailand. Vet. Pathol. 46, 1156–1159.
- Nonneman, D.J., Brown-Brandl, T., Jones, S.A., Wiedmann, R.T., Rohrer, G.A., 2012. A defect in dystrophin causes a novel porcine stress syndrome. BMC Genomics 13, 233.
- Ober, B.T., Summerfield, A., Mattlinger, C., Wiesmuller, K.H., Jung, G., Pfaff, E., et al., 1998. Vaccine-induced, pseudorabies virus-specific, extrathymic CD4 + CD8+ memory T-helper cells in swine. J. Virol. 72, 4866–4873.
- O'Brien, P.J., Shen, H., Weiler, J., Ianuzzo, C.D., Wittnich, C., Moe, G.W., et al., 1991. Cardiac and muscle fatigue due to relative functional overload induced by excessive stimulation, hypersensitive excitation-contraction coupling, or diminished performance capacity correlates with sarcoplasmic reticulum failure. Can. J. Physiol. Pharmacol. 69 (262–8).
- O'Brien, P.J., Shen, H., Cory, C.R., Zhang, X., 1993. Use of a DNA-based test for the mutation associated with porcine stress syndrome (malignant hyperthermia) in 10,000 breeding swine. J. Am. Vet. Med. Assoc. 203, 842–851.
- O'Connor, B., Gauvreau, H., West, K., Bogdan, J., Ayroud, M., Clark, E.G., et al., 2001. Multiple porcine circovirus 2-associated abortions and reproductive failure in a multisite swine production unit. Can. Vet. J. 42, 551–553.
- Oishi, E., Kitajima, T., Koyama, Y., Ohgitani, T., Katayama, S., Okabe, T., 1995. Protective effect of the combined vaccine prepared from cell-free-antigen of Actinobacillus pleuropneumoniae serotypes 1, 2 and 5 in pigs. J. Vet. Med. Sci. 57, 1125–1128.
- Okada, M., Asai, T., Futo, S., Mori, Y., Mukai, T., Yazawa, S., et al., 2005. Serological diagnosis of enzootic pneumonia of swine by a double-sandwich enzyme-linked immunosorbent assay

- using a monoclonal antibody and recombinant antigen (P46) of *Mycoplasma hyopneumoniae*. *Vet. Microbiol.* 105, 251–259.
- Olsen, S.C., Garin-Bastuji, G., Blasco, J.M., Nicola, A.M., Samartino, L., 2012. Brucellosis. In: Zimmerman, J.J., Karriker, L.A., Ramirez, A., Schwartz, K.J., Stevenson, G.W. (Eds.), *Diseases of Swine*, tenth ed. Wiley-Blackwell, Chichester, West Sussex.
- Olson, L.B., Backstrom, L.R., 2000. The effect of tilmicosin in minimizing atrophic rhinitis, pneumonia, and pleuritis in swine. *Swine Health Prod.* 8, 263–268.
- Olson, M.E., Thorlakson, C.L., Deselliers, L., Morck, D.W., Mcallister, T.A., 1997. *Giardia* and *Cryptosporidium* in Canadian farm animals. *Vet. Parasitol.* 68, 375–381.
- Opriessnig, T., Halbur, P.G., 2012. Concurrent infections are important for expression of porcine circovirus associated disease. *Virus Res.* 164, 20–32.
- Opriessnig, T., Langohr, I., 2013. Current state of knowledge on porcine circovirus type 2-associated lesions. *Vet. Pathol.* 50, 23–38.
- Opriessnig, T., Wood, R.L., 2012. Erysipelas. In: Zimmerman, J.J., Karriker, L.A., Ramirez, A., Schwartz, K.J., Stevenson, G.W. (Eds.), *Diseases of Swine*, tenth ed. Wiley-Blackwell, Chichester, West Sussex.
- Opriessnig, T., Thacker, E.L., Yu, S., Fenaux, M., Meng, X.J., Halbur, P.G., 2004. Experimental reproduction of postweaning multisystemic wasting syndrome in pigs by dual infection with *Mycoplasma hyopneumoniae* and porcine circovirus type 2. *Vet. Pathol.* 41, 624–640.
- Opriessnig, T., Fenaux, M., Thomas, P., Hoogland, M.J., Rothschild, M.F., Meng, X.J., et al., 2006. Evidence of breed-dependent differences in susceptibility to porcine circovirus type-2-associated disease and lesions. *Vet. Pathol.* 43, 281–293.
- Pallares, F.J., Halbur, P.G., Opriessnig, T., Sorden, S.D., Villar, D., Janke, B.H., et al., 2002. Porcine circovirus type 2 (PCV-2) coinfections in US field cases of postweaning multisystemic wasting syndrome (PMWS). *J. Vet. Diagn. Invest.* 14, 515–519.
- Panepinto, L.M., 1986. Character and management of miniature swine. In: Stanton, H.C., Mersmann, H.J. (Eds.), *Swine in Cardiovascular Research*. CRC Press, Boca Raton, FL.
- Panepinto, L.M., Phillips, R.W., Norden, S., Pryor, P.C., Cox, R., 1983. A comfortable, minimum stress method of restraint for Yucatan miniature swine. *Lab. Anim. Sci.* 33, 95–97.
- Paul, P.S., Mengeling, W.L., Brown Jr., T.T., 1980. Effect of vaccinal and passive immunity on experimental infection of pigs with porcine parvovirus. *Am. J. Vet. Res.* 41, 1368–1371.
- Paulin, S.M., Jagannathan, A., Campbell, J., Wallis, T.S., Stevens, M.P., 2007. Net replication of *Salmonella enterica* serovars Typhimurium and Choleraesuis in porcine intestinal mucosa and nodes is associated with their differential virulence. *Infect. Immun.* 75, 3950–3960.
- Pearson, G.R., McNulty, M.S., 1977. Pathological changes in the small intestine of neonatal pigs infected with a pig reovirus-like agent (rotavirus). *J. Comp. Pathol.* 87, 363–375.
- Pennington, L.R., Sakamoto, K., Popitz-Bergez, F.A., Pescovitz, M.D., McDonough, M.A., Macvittie, T.J., et al., 1988. Bone marrow transplantation in miniature swine. I. Development of the model. *Transplantation* 45, 21–26.
- Perlman, S., Netland, J., 2009. Coronaviruses post-SARS: update on replication and pathogenesis. *Nat. Rev. Microbiol.* 7, 439–450.
- Pescovitz, M.D., 1998. Immunology of the pig. In: Pastoret, P.-P. (Ed.), *Handbook of Vertebrate Immunology*. Academic Press, San Diego, CA.
- Phaneuf, L.R., Ceccarelli, A., Laing, J.R., Moloo, B., Turner, P.V., 2007. Porcine dermatitis and nephropathy syndrome associated with porcine circovirus 2 infection in a Yorkshire pig. *J. Am. Assoc. Lab. Anim. Sci.* 46, 68–72.
- Piffer, I.A., Ross, R.F., 1984. Effect of age on susceptibility of pigs to *Mycoplasma hyopneumoniae* pneumonia. *Am. J. Vet. Res.* 45, 478–481.
- Pijoan, C., Fuentes, M., 1987. Severe pleuritis associated with certain strains of *Pasteurella multocida* in swine. *J. Am. Vet. Med. Assoc.* 191, 823–826.
- Plumb, D.C., 2011. *Plumb's Veterinary Drug Handbook*. PharmaVet; Distributed by Wiley, Stockholm, Wis. Ames, Iowa.
- Pluske, J.R., Siba, P.M., Pethick, D.W., Durmic, Z., Mullan, B.P., Hampson, D.J., 1996. The incidence of swine dysentery in pigs can be reduced by feeding diets that limit the amount of fermentable substrate entering the large intestine. *J. Nutr.* 126, 2920–2933.
- Potgieter, L.N., Ross, R.F., 1972. Demonstration of *Mycoplasma hyorhinis* and *Mycoplasma hyosynoviae* in lesions of experimentally infected swine by immunofluorescence. *Am. J. Vet. Res.* 33, 99–105.
- Potgieter, L.N., Frey, M.L., Ross, R.F., 1972. Chronological development of *Mycoplasma hyorhinis* and *Mycoplasma hyosynoviae* infections in cultures of a swine synovial cell strain. *Can. J. Comp. Med.* 36, 145–149.
- Practitioners, A.A.O.S., 2014. *Porcine Epidemic Diarrhea Virus (PEDV)*. American Association of Swine Veterinarians, Perry, IA.
- Prideaux, C.T., Lenghaus, C., Krywult, J., Hodgson, A.L., 1999. Vaccination and protection of pigs against pleuropneumonia with a vaccine strain of *Actinobacillus pleuropneumoniae* produced by site-specific mutagenesis of the ApxII operon. *Infect. Immun.* 67, 1962–1966.
- Ramjeet, M., Deslandes, V., Goure, J., Jacques, M., 2008. *Actinobacillus pleuropneumoniae* vaccines: from bacterins to new insights into vaccination strategies. *Anim. Health Res. Rev.* 9, 25–45.
- Rasmussen, S.R., Aarestrup, F.M., Jensen, N.E., Jorsal, S.E., 1999. Associations of *Streptococcus suis* serotype 2 ribotype profiles with clinical disease and antimicrobial resistance. *J. Clin. Microbiol.* 37, 404–408.
- Reeves, D.E., 1993. Neonatal care of miniature pet pigs. In: Reeves, D.E., Becker, H.N., American Association of Swine Practitioners (Eds.), *Care and Management of Miniature Pet Pigs: Guidelines for the Veterinary Practitioner*, first ed. Veterinary Practice Pub. Co, Santa Barbara, CA.
- Register, K.B., Brockmeier, S.L., De Jong, M.C., Pijoan, C., 2012. Pasteurellosis. In: Zimmerman, J.J., Karriker, L.A., Ramirez, A., Schwartz, K.J., Stevenson, G.W. (Eds.), *Diseases of Swine*, tenth ed. Wiley-Blackwell, Chichester, West Sussex.
- Rehm, T., Baums, C.G., Strommenger, B., Beyerbach, M., Valentin-Weigand, P., Goethe, R., 2007. Amplified fragment length polymorphism of *Streptococcus suis* strains correlates with their profile of virulence-associated genes and clinical background. *J. Med. Microbiol.* 56, 102–109.
- Reimer, D., Frey, J., Jansen, R., Veit, H.P., Inzana, T.J., 1995. Molecular investigation of the role of ApxI and ApxII in the virulence of *Actinobacillus pleuropneumoniae* serotype 5. *Microb. Pathog.* 18, 197–209.
- Roepstorff, A., 1998. Natural *Ascaris suum* infections in swine diagnosed by coprological and serological (ELISA) methods. *Parasitol. Res.* 84, 537–543.
- Roop 2ND, R.M., Veit, H.P., Sinsky, R.J., Veit, S.P., Hewlett, E.L., Kornegay, E.T., 1987. Virulence factors of *Bordetella bronchiseptica* associated with the production of infectious atrophic rhinitis and pneumonia in experimentally infected neonatal swine. *Infect. Immun.* 55, 217–222.
- Rose, N., Opriessnig, T., Grasland, B., Jestin, A., 2012. Epidemiology and transmission of porcine circovirus type 2 (PCV2). *Virus Res.* 164, 78–89.
- Rosell, C., Segales, J., Domingo, M., 2000. Hepatitis and staging of hepatic damage in pigs naturally infected with porcine circovirus type 2. *Vet. Pathol.* 37, 687–692.
- Ross, R.F., Switzer, W.P., Duncan, J.R., 1971. Experimental production of *Mycoplasma hyosynoviae* arthritis in swine. *Am. J. Vet. Res.* 32, 1743–1749.
- Rossow, K.D., 1998. Porcine reproductive and respiratory syndrome. *Vet. Pathol.* 35, 1–20.

- Rossow, K.D., Bautista, E.M., Goyal, S.M., Molitor, T.W., Murtaugh, M.P., Morrison, R.B., et al., 1994. Experimental porcine reproductive and respiratory syndrome virus infection in one-, four-, and 10-week-old pigs. *J. Vet. Diagn. Invest.* 6, 3–12.
- Rossow, K.D., Benfield, D.A., Goyal, S.M., Nelson, E.A., Christopher-Hennings, J., Collins, J.E., 1996a. Chronological immunohistochemical detection and localization of porcine reproductive and respiratory syndrome virus in gnotobiotic pigs. *Vet. Pathol.* 33, 551–556.
- Rossow, K.D., Laube, K.L., Goyal, S.M., Collins, J.E., 1996b. Fetal microscopic lesions in porcine reproductive and respiratory syndrome virus-induced abortion. *Vet. Pathol.* 33, 95–99.
- Rowland, J.M., Geisbert, T.W., Rowland, R.R., 2012. Filovirus. In: Zimmerman, J.J., Karriker, L.A., Ramirez, A., Schwartz, K.J., Stevenson, G.W. (Eds.), *Diseases of Swine*, tenth ed. Wiley-Blackwell, Chichester, West Sussex.
- Rudek, Z., Kwiatkowska, L., 1983. The possibility of detecting fetal lymphocytes in the maternal blood of the domestic pig, *Sus scrofa*. *Cytogenet. Cell. Genet.* 36, 580–583.
- Saadi, S., Platt, J.L., 1999. Role of complement in xenotransplantation. *Clin. Exp. Pharmacol. Physiol.* 26, 1016–1019.
- Sablinski, T., Emery, D.W., Monroy, R., Hawley, R.J., Xu, Y., Gianello, P., et al., 1999. Long-term discordant xenogeneic (porcine-to-primate) bone marrow engraftment in a monkey treated with porcine-specific growth factors. *Transplantation* 67, 972–977.
- Sachs, D.H., 2005. A knock-out punch? *Nat. Med.* 11, 1271.
- Saeki, H., Fujii, T., Fukumoto, S., Kagota, K., Taneichi, A., Takeda, S., et al., 1997. Efficacy of doramectin against intestinal nematodes and sarcoptic mange mites in naturally infected swine. *J. Vet. Med. Sci.* 59, 129–132.
- Safron, J., Gonder, J.C., 1997. The SPF Pig in Research. *ILAR J.* 38, 28–31.
- Saif, L.J., 1999. Comparative pathogenesis of enteric viral infections of swine. *Adv. Exp. Med. Biol.* 473, 47–59.
- Saif, L.J., Pensaert, M., Sestak, K., Yeo, S.-G., Jung, K., 2012. Coronaviruses. In: Zimmerman, J.J., Karriker, L.A., Ramirez, A., Schwartz, K.J., Stevenson, G.W. (Eds.), *Diseases of Swine*, tenth ed. Wiley-Blackwell, Chichester, West Sussex.
- Sakamoto, K., Pennington, L.R., Popitz-Bergez, F.A., Pescovitz, M.D., Gress, R.E., McDonough, M.A., et al., 1987. Swine GVDH model and the effect of T cell depletion of marrow by monoclonal antibodies. In: Gale, R.P., Champlin, R., Sandoz Inc. (Eds.), *Progress in Bone Marrow Transplantation: Proceedings of the Fourth International UCLA Symposium on Bone Marrow Transplantation*, held in Keystone, Colorado, April 13–18, 1986, Sponsored by Sandoz, Inc. UCLA Symposia on Molecular and Cellular Biology. Liss, New York.
- Sakano, T., Okada, M., Taneda, A., Mukai, T., Sato, S., 1997. Effect of Bordetella bronchiseptica and serotype D Pasteurella multocida bacterin-toxoid on the occurrence of atrophic rhinitis after experimental infection with B. bronchiseptica and toxigenic type AP. multocida. *J. Vet. Med. Sci.* 59, 55–57.
- Saliki, J.T., Rodgers, S.J., Eskew, G., 1998. Serosurvey of selected viral and bacterial diseases in wild swine from Oklahoma. *J. Wildl. Dis.* 34, 834–838.
- Salvarani, F.M., Conceicao, F.R., Cunha, C.E., Moreira, G.M., Pires, P.S., Silva, R.O., et al., 2013. Vaccination with recombinant Clostridium perfringens toxoids alpha and beta promotes elevated antepartum and passive humoral immunity in swine. *Vaccine* 31, 4152–4155.
- Sanchez-Cordon, P.J., Nunez, A., Salguero, F.J., Pedrera, M., Fernandez De Marco, M., Gomez-Villamandos, J.C., 2005. Lymphocyte apoptosis and thrombocytopenia in spleen during classical swine fever: role of macrophages and cytokines. *Vet. Pathol.* 42, 477–488.
- Sandfoss, M.R., Deperno, C.S., Betsill, C.W., Palamar, M.B., Erickson, G., Kennedy-Stoskopf, S., 2012. A serosurvey for Brucella suis, classical swine fever virus, porcine circovirus type 2, and pseudorabies virus in feral swine (*Sus scrofa*) of eastern North Carolina. *J. Wildl. Dis.* 48, 462–466.
- Sarli, G., Mandrioli, L., Panarese, S., Brunetti, B., Segales, J., Dominguez, J., et al., 2008. Characterization of interstitial nephritis in pigs with naturally occurring postweaning multisystemic wasting syndrome. *Vet. Pathol.* 45, 12–18.
- Sarradell, J., Andrada, M., Ramirez, A.S., Fernandez, A., Gomez-Villamandos, J.C., Jover, A., et al., 2003. A morphologic and immunohistochemical study of the bronchus-associated lymphoid tissue of pigs naturally infected with Mycoplasma hyopneumoniae. *Vet. Pathol.* 40, 395–404.
- Sato, H., Watanabe, T., Murata, Y., Ohtake, A., Nakamura, M., Aizawa, C., et al., 1999. New exfoliative toxin produced by a plasmid-carrying strain of Staphylococcus hyicus. *Infect. Immun.* 67, 4014–4018.
- Sawatsky, J., 1993. Behavior of miniature pet pigs. In: Reeves, D.E., Becker, H.N., American Association of Swine Practitioners (Eds.), *Care and Management of Miniature Pet Pigs: Guidelines for the Veterinary Practitioner*, first ed. Veterinary Practice Pub. Co, Santa Barbara, CA.
- Schmall, L.M., Argenzio, R.A., Whipp, S.C., 1983. Pathophysiologic features of swine dysentery: cyclic nucleotide-independent production of diarrhea. *Am. J. Vet. Res.* 44, 1309–1316.
- Schoenbaum, M.A., Zimmerman, J.J., Beran, G.W., Murphy, D.P., 1990. Survival of pseudorabies virus in aerosol. *Am. J. Vet. Res.* 51, 331–333.
- Schuurman, H.J., Graham, M.L., Spizzo, T., Patience, C., 2012. Xenotransplantation. In: McAnulty, P.A. (Ed.), *The Minipig in Biomedical Research*. CRC Press/Taylor & Francis, Boca Raton, FL.
- Schwartz, K.J., 1991. Diagnosing and controlling Salmonella choleraesuis in swine. *Vet. Med. (Praha)* 86, 1041–1048.
- Seeliger, F.A., Bruggmann, M.L., Kruger, L., Greiser-Wilke, I., Verspohl, J., Segales, J., et al., 2007. Porcine circovirus type 2-associated cerebellar vasculitis in postweaning multisystemic wasting syndrome (PMWS)-affected pigs. *Vet. Pathol.* 44, 621–634.
- Segales, J., 2012. Porcine circovirus type 2 (PCV2) infections: clinical signs, pathology and laboratory diagnosis. *Virus Res.* 164, 10–19.
- Service, A.A.P.H.I., 2013. Technical Note: Porcine Epidemic Diarrhea (PED) [Online]. United States Department of Agriculture. Available: <http://www.aphis.usda.gov/animal_health/animal_dis_spec/swine/downloads/ped_tech_note.pdf> (accessed 23.09.13).
- Sharing, U.N.F.O., 2013. United Network for Organ Sharing [Online]. Available: <<http://www.unos.org/>>.
- Sheerar, M.G., Easterday, B.C., Hinshaw, V.S., 1989. Antigenic conservation of H1N1 swine influenza viruses. *J. Gen. Virol.* 70 (Pt 12), 3297–3303.
- Shimizu, I., Smith, N.R., Zhao, G., Medof, E., Sykes, M., 2006. Decay-accelerating factor prevents acute humoral rejection induced by low levels of anti-alphaGal natural antibodies. *Transplantation* 81, 95–100.
- Shimoji, Y., Mori, Y., Fischetti, V.A., 1999. Immunological characterization of a protective antigen of Erysipelothrix rhusiopathiae: identification of the region responsible for protective immunity. *Infect. Immun.* 67, 1646–1651.
- Shryock, T.R., Losonsky, J.M., Smith, W.C., Gatlin, C.L., Francisco, C.J., Kuriashkin, I.V., et al., 1998. Computed axial tomography of the porcine nasal cavity and a morphometric comparison of the nasal turbinates with other visualization techniques. *Can. J. Vet. Res.* 62, 287–292.
- Skjolaas, K.A., Burkey, T.E., Dritz, S.S., Minton, J.E., 2006. Effects of Salmonella enterica serovars Typhimurium (ST) and Choleraesuis (SC) on chemokine and cytokine expression in swine ileum and jejunal epithelial cells. *Vet. Immunol. Immunopathol.* 111, 199–209.

- Skotarczak, B., Zielinski, R., 1997. A comparison of nucleic acid content in *Balantidium coli* trophozoites from different isolates. *Folia Biol. (Krakow)* 45, 121–124.
- Smith, A.C., Swindle, M.M., 2006. Preparation of swine for the laboratory. *ILAR J.* 47, 358–363.
- Smith, M.E., Gopee, N.V., Ferguson, S.A., 2009. Preferences of minipigs for environmental enrichment objects. *J. Am. Assoc. Lab. Anim. Sci.* 48, 391–394.
- Smith, M.W., Peacock, M.A., 1980. Anomalous replacement of foetal enterocytes in the neonatal pig. *Proc. R Soc. Lond. B Biol. Sci.* 206, 411–420.
- Sokoli, A., Groebel, K., Hoelzle, K., Amselgruber, W.M., Mateos, J.M., Schneider, M.K., et al., 2013. *Mycoplasma suis* infection results endothelial cell damage and activation: new insight into the cell tropism and pathogenicity of hemotropic mycoplasma. *Vet. Res.* 44, 6.
- Songer, J.G., 2012. Clostridiosis. In: Zimmerman, J.J., Karriker, L.A., Ramirez, A., Schwartz, K.J., Stevenson, G.W. (Eds.), *Diseases of Swine*, tenth ed. Wiley-Blackwell, Chichester, West Sussex.
- Splitter, E.J., 1950. *Eperythrozoon suis*, the etiologic agent of icteronemia or an anaplasmosis-like disease in swine. *Am. J. Vet. Res.* 11, 324–330.
- Staats, J.J., Feder, I., Okwumabua, O., Chengappa, M.M., 1997. *Streptococcus suis*: past and present. *Vet. Res. Commun.* 21, 381–407.
- Stanton, H.C., Mersmann, H.J., 1986. *Swine in Cardiovascular Research*. CRC Press, Boca Raton, FL.
- Stanton, T.B., 2006. The genus *Brachyspira*. In: Dworkin, M., Falkow, S. (Eds.), *The Prokaryotes: a Handbook on the Biology of Bacteria*, third ed. Springer, New York; London.
- Stege, H., Jensen, T.K., Moller, K., Baekbo, P., Jorsal, S.E., 2001. Risk factors for intestinal pathogens in Danish finishing pig herds. *Prev. Vet. Med.* 50, 153–164.
- Stemke, G.W., 1997. Gene amplification (PCR) to detect and differentiate mycoplasmas in porcine mycoplasmal pneumonia. *Lett. Appl. Microbiol.* 25, 327–330.
- Stevenson, G.W., Hoang, H., Schwartz, K.J., Burrough, E.R., Sun, D., Madson, D., et al., 2013. Emergence of Porcine epidemic diarrhea virus in the United States: clinical signs, lesions, and viral genomic sequences. *J. Vet. Diagn. Invest.* 25, 649–654.
- Stewart, T.B., 2007. Parasites of swine. In: Baker, D.G. (Ed.), *Flynn's Parasites of Laboratory Animals*. Blackwell publishing, Ames, IA.
- Stewart, T.B., Fox, M.C., Wiles, S.E., 1996. Doramectin efficacy against gastrointestinal nematodes in pigs. *Vet. Parasitol.* 66, 101–108.
- Studdert, V.P., Gay, C.C., Blood, D.C., 2012. *Saunders Comprehensive Veterinary Dictionary*. New York, Saunders Elsevier, Edinburgh.
- Swenson, S.L., Mead, D.G., Bunn, T.O., 2012. Rhabdoviruses. In: Zimmerman, J.J., Karriker, L.A., Ramirez, A., Schwartz, K.J., Stevenson, G.W. (Eds.), *Diseases of Swine*, tenth ed. Wiley-Blackwell, Chichester, West Sussex.
- Swindle, M.M., 1986. Surgery and anesthesia. In: Tumbleson, M.E. (Ed.), *Swine in Biomedical Research*. Plenum Press, New York.
- Swindle, M.M., 1998. Defining appropriate health status and management programs for specific-pathogen-free swine for xenotransplantation. *Ann. NY Acad. Sci.* 862, 111–120.
- Swindle, M.M., 2007. *Swine in the Laboratory: Surgery, Anesthesia, Imaging, and Experimental Techniques*. CRC Press, Boca Raton, FL.
- Swindle, M.M., Swindle, M.M., 2007. *Swine in the Laboratory: Surgery, Anesthesia, Imaging, and Experimental Techniques*. CRC Press, Boca Raton, FL.
- Swindle, M.M., Thompson, R.P., Carabello, B.A., Smith, A.C., Hepburn, B.J., Bodison, D.R., et al., 1990. Heritable ventricular septal defect in Yucatan miniature swine. *Lab. Anim. Sci.* 40, 155–161.
- Swindle, M.M., Moody, D.C., Phillips, L.D., 1992. Swine as Models in Biomedical Research. Iowa State University Press, Ames, IA.
- Swindle, M.M., Smith, A.C., Laber-Laird, K., Dungan, L., 1994. Swine in biomedical research: management and models. *ILAR J.* 36, 1–5.
- Swindle, M.M., Makin, A., Herron, A.J., Clubb Jr., F.J., Frazier, K.S., 2012. Swine as models in biomedical research and toxicology testing. *Vet. Pathol.* 49, 344–356.
- Szeredi, L., Dan, A., Solymosi, N., Csagola, A., Tuboly, T., 2012. Association of porcine circovirus type 2 with vascular lesions in porcine pneumonia. *Vet. Pathol.* 49, 264–270.
- Tanabe, T., Sato, H., Sato, H., Watanabe, K., Hirano, M., Hirose, K., et al., 1996. Correlation between occurrence of exudative epidermitis and exfoliative toxin-producing ability of *Staphylococcus hyicus*. *Vet. Microbiol.* 48, 9–17.
- Temmam, S., Besnard, L., Andriamandimby, S.F., Foray, C., Rasamoelina-Andriamanivo, H., Heraud, J.M., et al., 2013. High prevalence of hepatitis E in humans and pigs and evidence of genotype-3 virus in swine, Madagascar. *Am. J. Trop. Med. Hyg.* 88, 329–338.
- Teppema, J.S., DE Boer, G.F., 1975. Ultrastructural aspects of experimental swinepox with special reference to inclusion bodies. *Arch. Virol.* 49, 151–163.
- Thacker, B.J., Joo, H.S., Winkelman, N.L., Leman, A.D., Barnes, D.M., 1987. Clinical, virologic, and histopathologic observations of induced porcine parvovirus infection in boars. *Am. J. Vet. Res.* 48, 763–767.
- Thacker, E.L., Minion, F.C., 2012. Mycoplasmosis. In: Zimmerman, J.J., Karriker, L.A., Ramirez, A., Schwartz, K.J., Stevenson, G.W. (Eds.), *Diseases of Swine*, tenth ed. Wiley-Blackwell, Chichester, West Sussex.
- Thacker, E.L., Halbur, P.G., Ross, R.F., Thanawongnuwech, R., Thacker, B.J., 1999. *Mycoplasma hyopneumoniae* potentiation of porcine reproductive and respiratory syndrome virus-induced pneumonia. *J. Clin. Microbiol.* 37, 620–627.
- Thacker, E.L., Thacker, B.J., Young, T.F., Halbur, P.G., 2000. Effect of vaccination on the potentiation of porcine reproductive and respiratory syndrome virus (PRRSV)-induced pneumonia by *Mycoplasma hyopneumoniae*. *Vaccine* 18, 1244–1252.
- Thacker, E.L., Thacker, B.J., Janke, B.H., 2001. Interaction between *Mycoplasma hyopneumoniae* and swine influenza virus. *J. Clin. Microbiol.* 39, 2525–2530.
- Thanawongnuwech, R., Young, T.F., Thacker, B.J., Thacker, E.L., 2001. Differential production of proinflammatory cytokines: in vitro PRRSV and *Mycoplasma hyopneumoniae* co-infection model. *Vet. Immunol. Immunopathol.* 79, 115–127.
- Thome, M., Hirt, W., Pfaff, E., Reddehase, M.J., Saalmuller, A., 1994. Porcine T-cell receptors: molecular and biochemical characterization. *Vet. Immunol. Immunopathol.* 43, 13–18.
- Thomsen, L.E., Knudsen, K.E., Jensen, T.K., Christensen, A.S., Moller, K., Roepstorff, A., 2007. The effect of fermentable carbohydrates on experimental swine dysentery and whip worm infections in pigs. *Vet. Microbiol.* 119, 152–163.
- Thomson, R.G., 1988. *Special Veterinary Pathology*. B.C. Decker; C.V. Mosby Co. distributor, Toronto; Philadelphia Saint Louis, Missouri.
- Tian, K., Yu, X., Zhao, T., Feng, Y., Cao, Z., Wang, C., et al., 2007. Emergence of fatal PRRSV variants: unparalleled outbreaks of atypical PRRS in China and molecular dissection of the unique hallmark. *PLoS One* 2, e526.
- Tischer, I., Miels, W., Wolff, D., Vagt, M., Griem, W., 1986. Studies on epidemiology and pathogenicity of porcine circovirus. *Arch. Virol.* 91, 271–276.
- Tomanova, K., Bartak, P., Smola, J., 2002. Detection of *Lawsonia intracellularis* in wild pigs in the Czech Republic. *Vet. Rec.* 151, 765–767.
- Torremorell, M., Calsamiglia, M., Pijoan, C., 1998. Colonization of suckling pigs by *Streptococcus suis* with particular reference to pathogenic serotype 2 strains. *Can. J. Vet. Res.* 62, 21–26.
- Torres-Velez, F.J., 2008. Nipah virus. In: United States Animal Health Association. Committee on Foreign Animal Diseases, Foreign Animal Diseases, seventh ed. United States Animal Health Association, St. Joseph, MO.

- Toth, I., Oswald, E., Mainil, J.G., Awad-Masalmeh, M., Nagy, B., 2000. Characterization of intestinal cnf1+ *Escherichia coli* from weaned pigs. *Int. J. Med. Microbiol.* 290, 539–542.
- Trible, B.R., Rowland, R.R., 2012. Genetic variation of porcine circovirus type 2 (PCV2) and its relevance to vaccination, pathogenesis and diagnosis. *Virus Res.* 164, 68–77.
- Trott, D.J., Huxtable, C.R., Hampson, D.J., 1996. Experimental infection of newly weaned pigs with human and porcine strains of *Serpulina pilosicoli*. *Infect. Immun.* 64, 4648–4654.
- Truong, Q.L., Seo, T.W., Yoon, B.I., Kim, H.C., Han, J.H., Hahn, T.W., 2013. Prevalence of swine viral and bacterial pathogens in rodents and stray cats captured around pig farms in Korea. *J. Vet. Med. Sci.* 75, 1647–1650.
- Truyen, U., Streck, A.F., 2012. Porcine parvovirus. In: Zimmerman, J.J., Karriker, L.A., Ramirez, A., Schwartz, K.J., Stevenson, G.W. (Eds.), *Diseases of Swine*, tenth ed. Wiley-Blackwell, Chichester, West Sussex.
- Tucker, A.W., Mcneilly, F., Meehan, B., Galbraith, D., Mcardle, P.D., Allan, G., et al., 2003. Methods for the exclusion of circoviruses and gammaherpesviruses from pigs. *Xenotransplantation* 10, 343–348.
- Tumbleson, M.E., 1986. *Swine in Biomedical Research*. Plenum Press, New York.
- Turk, J.R., Fales, W.H., Maddox, C., Miller, M., Pace, L., Fischer, J., et al., 1992. Pneumonia associated with *Salmonella choleraesuis* infection in swine: 99 cases (1987–1990). *J. Am. Vet. Med. Assoc.* 201, 1615–1616.
- Tzipori, S., Gibson, R., Montanaro, J., 1989. Nature and distribution of mucosal lesions associated with enteropathogenic and enterohemorrhagic *Escherichia coli* in piglets and the role of plasmid-mediated factors. *Infect. Immun.* 57, 1142–1150.
- Uthe, J.J., Royae, A., Lunney, J.K., Stabel, T.J., Zhao, S.H., Tuggle, C.K., et al., 2007. Porcine differential gene expression in response to *Salmonella enterica* serovars *Choleraesuis* and *Typhimurium*. *Mol. Immunol.* 44, 2900–2914.
- Vahle, J.L., Haynes, J.S., Andrews, J.J., 1995. Experimental reproduction of *Haemophilus parasuis* infection in swine: clinical, bacteriological, and morphologic findings. *J. Vet. Diagn. Invest.* 7, 476–480.
- Van Reeth, K., Nauwynck, H., Pensaert, M., 1998. Bronchoalveolar interferon-alpha, tumor necrosis factor-alpha, interleukin-1, and inflammation during acute influenza in pigs: a possible model for humans? *J. Infect. Dis.* 177, 1076–1079.
- Van Reeth, K., Van Gucht, S., Pensaert, M., 2002. Correlations between lung proinflammatory cytokine levels, virus replication, and disease after swine influenza virus challenge of vaccination-immune pigs. *Viral. Immunol.* 15, 583–594.
- Van Reeth, K., Brown, I.H., Olsen, C.W., 2012. Influenza virus. In: Zimmerman, J.J., Karriker, L.A., Ramirez, A., Schwartz, K.J., Stevenson, G.W. (Eds.), *Diseases of Swine*, tenth ed. Wiley-Blackwell, Chichester, West Sussex.
- Vasickova, P., Psikal, I., Kralik, P., Widen, F., Hubalek, Z., Pavlik, I., 2007. Hepatitis E virus: a review. *Veterinarni Medicina* 52, 365–384.
- Vazquez-Torres, A., Jones-Carson, J., Baumler, A.J., Falkow, S., Valdivia, R., Brown, W., et al., 1999. Extraintestinal dissemination of *Salmonella* by CD18-expressing phagocytes. *Nature* 401, 804–808.
- Veterinarians, A.A.O.S., 2013. American Association of Swine Veterinarians: Increasing the Knowledge of Swine Veterinarians [Online]. Perry, IA. Available: <<https://www.aasv.org/>> (accessed 7.01.14).
- Viruses, I.C.O.T.O., 2013. ICTV Taxonomy History for Alphacoronavirus-1 [Online]. Available: <http://www.ictvonline.org/taxonomyHistory.asp?taxnode_id=20123515&taxa_name=Alphacoronavirus%201> (accessed 30.09.13).
- Vitiello, M., D'isanto, M., Finamore, E., Ciarcia, R., Campanaraki, A., Galdiero, M., 2008. Role of mitogen-activated protein kinases in the iNOS production and cytokine secretion by *Salmonella enterica* serovar *Typhimurium* porins. *Cytokine* 41, 279–285.
- Wagner, B., Polley, L., 1997. *Ascaris suum* prevalence and intensity: an abattoir survey of market hogs in Saskatchewan. *Vet. Parasitol.* 73, 309–313.
- Wallgren, P., Bornstein, S., 1997. The spread of porcine sarcoptic mange during the fattening period revealed by development of antibodies to *Sarcoptes scabiei*. *Vet. Parasitol.* 73, 315–324.
- Wang, F., Guo, X., Ge, X., Wang, Z., Chen, Y., Cha, Z., et al., 2009. Genetic variation analysis of Chinese strains of porcine circovirus type 2. *Virus Res.* 145, 151–156.
- Wang, H., Verhalen, J., Madariaga, M.L., Xiang, S., Wang, S., Lan, P., et al., 2007. Attenuation of phagocytosis of xenogeneic cells by manipulating CD47. *Blood* 109, 836–842.
- Wang, Q., Chang, B.J., Riley, T.V., 2010. *Erysipelothrix rhusiopathiae*. *Vet. Microbiol.* 140, 405–417.
- Warrens, A.N., Simon, A.R., Theodore, P.R., Sachs, D.H., Sykes, M., 1998. Function of porcine adhesion molecules in a human marrow microenvironment. *Transplantation* 66, 252–259.
- Weingartl, H.M., Derbyshire, J.B., 1994. Evidence for a putative second receptor for porcine transmissible gastroenteritis virus on the villous enterocytes of newborn pigs. *J. Virol.* 68, 7253–7259.
- Weingartl, H.M., Embury-Hyatt, C., Nfon, C., Leung, A., Smith, G., Kobinger, G., 2012. Transmission of Ebola virus from pigs to non-human primates. *Sci. Rep.* 2, 811.
- Wellenberg, G.J., Stockhofe-Zurwieden, N., De Jong, M.F., Boersma, W.J., Elbers, A.R., 2004. Excessive porcine circovirus type 2 antibody titres may trigger the development of porcine dermatitis and nephropathy syndrome: a case-control study. *Vet. Microbiol.* 99, 203–214.
- Whary, M.T., Zarkower, A., Confer, F.L., Ferguson, F.G., 1995. Age-related differences in subset composition and activation responses of intestinal intraepithelial and mesenteric lymph node lymphocytes from neonatal swine. *Cell Immunol.* 163, 215–221.
- Wiegand, M., Kielstein, P., Pohle, D., Rassbach, A., 1997. Examination of primary SPF swine after experimental infection with *Haemophilus parasuis*. Clinical symptoms, changes in hematological parameters and in the parameters of the cerebrospinal fluid. *Tierarztl Prax.* 25, 226–232.
- Williams, D.T., Mackenzie, J.S., Daniels, P.W., 2012. Flaviviruses. In: Zimmerman, J.J., Karriker, L.A., Ramirez, A., Schwartz, K.J., Stevenson, G.W. (Eds.), *Diseases of Swine*, tenth ed. Wiley-Blackwell, Chichester, West Sussex.
- Williamson, M.M., Torres-Velez, F.J., 2010. Henipavirus: a review of laboratory animal pathology. *Vet. Pathol.* 47, 871–880.
- Wisselink, H.J., Reek, F.H., Vecht, U., Stockhofe-Zurwieden, N., Smits, M.A., Smith, H.E., 1999. Detection of virulent strains of *Streptococcus suis* type 2 and highly virulent strains of *Streptococcus suis* type 1 in tonsillar specimens of pigs by PCR. *Vet. Microbiol.* 67, 143–157.
- Wood, R.L., 1984. Swine erysipelas – a review of prevalence and research. *J. Am. Vet. Med. Assoc.* 184, 944–949.
- Woods, A.L., Tynes, V.V., 2012. Special considerations for show and pet pigs. In: Zimmerman, J.J., Karriker, L.A., Ramirez, A., Schwartz, K.J., Stevenson, G.W. (Eds.), *Diseases of Swine*, tenth ed. Wiley-Blackwell, Chichester, West Sussex.
- Xiao, C.T., Halbur, P.G., Opriessnig, T., 2012. Complete genome sequence of a novel porcine circovirus type 2b variant present in cases of vaccine failures in the United States. *J. Virol.* 86, 12469.
- Xiao, C.T., Gimenez-Lirola, L.G., Jiang, Y.H., Halbur, P.G., Opriessnig, T., 2013. Characterization of a novel porcine parvovirus tentatively designated PPV5. *PLoS One* 8, e65312.

- Yaeger, M.J., 1995. Actinobacillus suis septicemia: an emerging disease in high health herds. *Swine Health Prod.* 3, 209–210.
- Yamada, K., Yazawa, K., Shimizu, A., Iwanaga, T., Hisashi, Y., Nuhn, M., et al., 2005. Marked prolongation of porcine renal xenograft survival in baboons through the use of alpha1,3-galactosyltransferase gene-knockout donors and the cotransplantation of vascularized thymic tissue. *Nat. Med.* 11, 32–34.
- Yamada, M., Nakamura, K., Yoshii, M., Kaku, Y., 2004. Nonsuppurative encephalitis in piglets after experimental inoculation of Japanese encephalitis flavivirus isolated from pigs. *Vet. Pathol.* 41, 62–67.
- Yamamoto, K., Kijima, M., Yoshimura, H., Takahashi, T., 2001. Antimicrobial susceptibilities of *Erysipelothrix rhusiopathiae* isolated from pigs with swine erysipelas in Japan, 1988–1998. *J. Vet. Med. B Infect. Dis. Vet. Public Health* 48, 115–126.
- Yamazaki, Y., Sato, H., Sakakura, H., Shigeto, K., Nakano, K., Saito, H., et al., 1999. Protective activity of the purified protein antigen of *Erysipelothrix rhusiopathiae* in pigs. *Zentralbl. Veterinarmed. B* 46, 47–55.
- Yang, Y.G., Sykes, M., 2007. Xenotransplantation: current status and a perspective on the future. *Nat. Rev. Immunol.* 7, 519–531.
- Yazwinski, T.A., Tucker, C., Featherston, H., Johnson, Z., Wood-Huels, N., 1997. Endectocidal efficacies of doramectin in naturally parasitized pigs. *Vet. Parasitol.* 70, 123–128.
- Ye, Y., Niekrasz, M., Kosanke, S., Welsh, R., Jordan, H.E., Fox, J.C., et al., 1994. The pig as a potential organ donor for man. A study of potentially transferable disease from donor pig to recipient man. *Transplantation* 57, 694–703.
- Yeatman, M., Daggett, C.W., Lau, C.L., Byrne, G.W., Logan, J.S., Platt, J.L., et al., 1999. Human complement regulatory proteins protect swine lungs from xenogeneic injury. *Ann. Thorac. Surg.* 67, 769–775.
- Zheng, P., Zhao, Y.X., Zhang, A.D., Kang, C., Chen, H.C., Jin, M.L., 2009. Pathologic analysis of the brain from *Streptococcus suis* type 2 experimentally infected pigs. *Vet. Pathol.* 46, 531–535.
- Zimmerman, J.J., Berry, W.J., Beran, G.W., Murphy, D.P., 1989. Influence of temperature and age on the recovery of pseudorabies virus from houseflies (*Musca domestica*). *Am. J. Vet. Res.* 50, 1471–1474.
- Zimmerman, J.J., Benfield, D.A., Dee, S.A., Murtaugh, M.P., Stadejek, T., Stevenson, G.W., et al., 2012a. Porcine reproductive and respiratory syndrome virus (porcine Aterivirus). In: Zimmerman, J.J., Karriker, L.A., Ramirez, A., Schwartz, K.J., Stevenson, G.W. (Eds.), *Diseases of Swine*, tenth ed. Wiley-Blackwell, Chichester, West Sussex.
- Zimmerman, J.J., Karriker, L.A., Ramirez, A., Schwartz, K.J., Stevenson, G.W., 2012b. *Diseases of Swine*. Wiley-Blackwell, Chichester, West Sussex.
- Zimmermann, W., Kircher, P., 1998. Continuous serologic study and sanitation inspection of *Sarcoptes scabiei* var. *suis* infection: preliminary results. *Schweiz Arch. Tierheilkd* 140, 513–517.