



Since January 2020 Elsevier has created a COVID-19 resource centre with free information in English and Mandarin on the novel coronavirus COVID-19. The COVID-19 resource centre is hosted on Elsevier Connect, the company's public news and information website.

Elsevier hereby grants permission to make all its COVID-19-related research that is available on the COVID-19 resource centre - including this research content - immediately available in PubMed Central and other publicly funded repositories, such as the WHO COVID database with rights for unrestricted research re-use and analyses in any form or by any means with acknowledgement of the original source. These permissions are granted for free by Elsevier for as long as the COVID-19 resource centre remains active.

# 11

## Liver and Bile Duct Infections

RICARD MASIA, JOSEPH MISDRAJI

### Viral Infections of the Liver and Bile Duct

- Hepatitis A
- Hepatitis B
- Hepatitis C
- Hepatitis D
- Hepatitis E
- George Barker Virus Type C (Hepatitis G)
- Epstein-Barr Virus
- Cytomegalovirus
- Herpes Simplex Virus
- Varicella Zoster Virus
- Adenovirus
- Parvovirus B19
- Rubella (German Measles)
- Rubeola (Measles)
- Severe Acute Respiratory Syndrome Coronavirus
- Human Immunodeficiency Virus
- Yellow Fever
- Dengue
- Rift Valley Fever
- Lassa Fever
- Ebola Virus
- Marburg Virus

### Mycobacterial Infections of the Liver and Bile Duct

- Tuberculosis
- Mycobacterium avium-intracellulare* Complex
- Leprosy
- Bacillus Calmette-Guérin

### Other Bacterial Infections of the Liver and Bile Duct

- Pyogenic Liver Abscess
- Acute Cholangitis
- Recurrent Pyogenic Cholangitis (Oriental Cholangiohepatitis)
- Brucellosis
- Bartonella* Infection (Cat-Scratch Disease)
- Enteric Fever (Typhoid and Paratyphoid Fever)

- Tularemia
- Melioidosis
- Listeriosis
- Spirochetes
- Rickettsia

### Fungal Infections of the Liver and Bile Duct

- Histoplasma
- Candida
- Pneumocystis jiroveci*
- Aspergillus*
- Mucormycetes/Zygomycetes
- Penicilliosis
- Cryptococcosis
- Coccidioidomycosis
- Blastomycosis
- Paracoccidioidomycosis (South American Blastomycosis)
- Microsporidiosis

### Helminth Infections of the Liver and Bile Duct

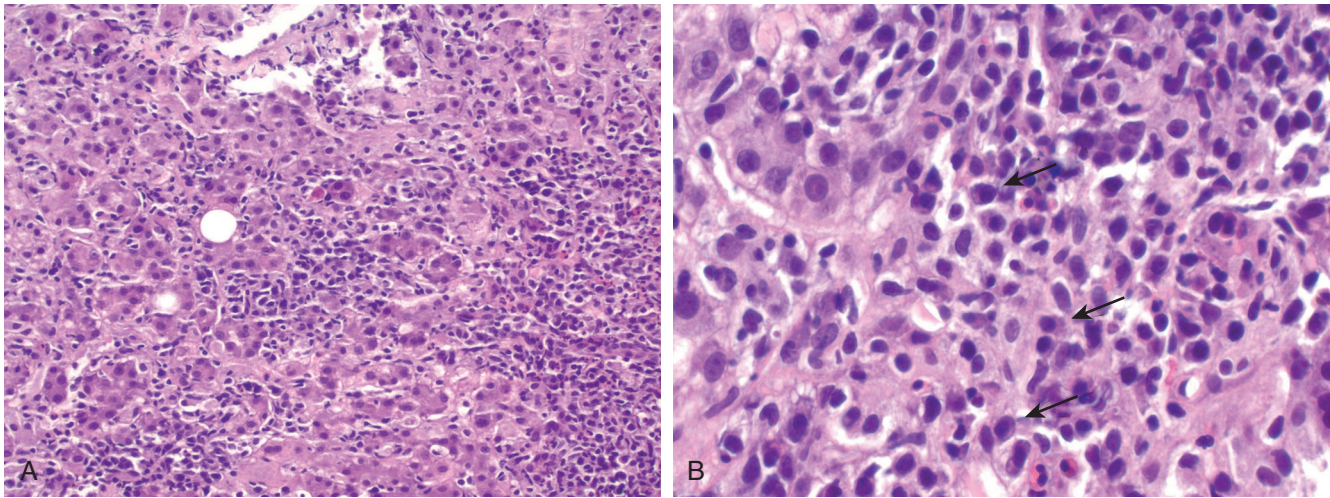
- Schistosomiasis
- Strongyloides
- Enterobiasis (Pinworm)
- Echinococcosis
- Toxocara
- Capillariasis
- Fascioliasis
- Clonorchiasis
- Ascariasis

### Protozoal Infections of the Liver and Bile Duct

- Amebiasis
- Malaria
- Leishmania*
- Toxoplasmosis
- Cryptosporidiosis

The liver is the target of many infectious agents, most notably hepatotropic viruses such as hepatitis B virus (HBV) and hepatitis C virus (HCV). In addition, many infectious organisms can involve the liver in the setting of disseminated infection, in immunosuppressed patients, or as a medical curiosity. The major challenge facing the pathologist in diagnosing these conditions is that many of these diseases have

overlapping histopathologic characteristics. Hepatitis, necrosis, or granulomas are characteristic of many liver infections, and distinguishing the exact cause often requires a meticulous search for organisms, attention to subtle morphologic clues, or, not uncommonly, clinical, epidemiologic, or serologic data. Although some organisms can be readily detected in tissue, many are not, even with the use of ancillary techniques. Furthermore, many of the



• **Figure 11.1** Liver biopsy in hepatitis A. **A**, Panlobular inflammation and lobular disarray. **B**, High power shows many plasma cells within the infiltrate (arrows).

ancillary techniques used to detect organisms in tissue are not widely available. Therefore, although the pattern of injury can provide a differential diagnosis, in some cases the final diagnosis relies on culture or serologic studies.

## Viral Infections of the Liver and Bile Duct

### Hepatitis A

Hepatitis A virus (HAV) is an RNA virus in the Picornaviridae family. Although the incidence of HAV infection has fallen dramatically since the introduction of vaccines, it still causes approximately 60,000 infections per year and occasionally causes dramatic outbreaks with fulminant hepatitis and death.<sup>1</sup> Fecal-oral transmission is facilitated by extensive viral shedding in feces during the 3- to 6-week incubation period, which reaches a maximum just before the onset of hepatocellular injury.<sup>1</sup> An increasing incidence has been noted among urban homosexual men. An effective vaccine has been developed.

The signs and symptoms of hepatitis A are related to patient age. In children younger than 3 years, more than 80% of infections are clinically silent, whereas in adolescents and adults, more than 75% of cases are symptomatic.<sup>2</sup> Symptoms include fever, malaise, abdominal pain, and jaundice. Marked transaminase elevations are characteristic. Approximately 100 cases of HAV-related fulminant liver failure are reported each year, predominantly in adults.<sup>2</sup> Chronic infection does not occur. However, HAV infection can precipitate autoimmune hepatitis, which can progress to chronic hepatitis with fibrosis or cirrhosis.<sup>3-6</sup>

Liver injury in HAV infection is the result of an immunopathologic response to infected hepatocytes rather than a direct cytopathic effect of the virus.<sup>1</sup> The adaptive immune response is highly effective in eliminating the virus. The earliest antibody response is largely that of immunoglobulin M (IgM), with IgG production beginning shortly thereafter; therefore the diagnosis is established by the detection of anti-HAV IgM (with or without IgG). Anti-HAV IgG persists for life and confers protection against reinfection.<sup>1</sup>

Acute HAV infection may be indistinguishable from other acute viral hepatitis (see discussion of hepatitis B). However, portal plasma cell infiltrates and periportal necrosis may be

prominent, causing confusion with autoimmune hepatitis (Fig. 11.1).<sup>7</sup> In rare cases, perivenular cholestasis with relatively little inflammation mimics cholestatic drug reactions. Fibrin ring granulomas have been reported.<sup>8,9</sup>

### Hepatitis B

Chronic hepatitis B affects an estimated 400 million persons worldwide, of whom 1 million die annually.<sup>10,11</sup> Three-quarters of patients with chronic hepatitis B in the world are Chinese, and sub-Saharan Africa also has high prevalence.<sup>11</sup> In the United States the incidence of newly acquired HBV infection has been declining due to screening of pregnant women, vaccination, and safer injection practices.<sup>10</sup>

#### Virology of Hepatitis B Virus

HBV is a DNA-containing virus with four overlapping open reading frames.<sup>12</sup> Its four genes are core, surface, X, and polymerase genes. The core gene encodes the core nucleocapsid protein, which is important in viral packaging, and hepatitis B e antigen (HBeAg). The surface gene encodes pre-S1, pre-S2, and S protein, which are large, middle, and small surface proteins, respectively. The X gene encodes the X protein, which may be important in carcinogenesis. The polymerase gene encodes a large protein that has a role in packaging and DNA replication.<sup>12</sup>

There are eight major HBV genotypes: A is pandemic, B and C are found in Asia, D in southern Europe, E in Africa, F in the United States and South America, G in the United States and France, and H in South America.<sup>11</sup> To some extent, genotype influences the severity of hepatitis and its outcome. The severity of chronic hepatitis is greater with genotype C than with B, and there is a higher frequency of cirrhosis and hepatocellular carcinoma (HCC) in patients infected with HBV genotype C. A higher rate of virologic response is achieved among patients infected with genotype B, compared with genotype C.<sup>13</sup>

#### Pathophysiology of Hepatitis B Virus

Hepatitis B is not directly cytotoxic to hepatocytes. Instead, the pathogenesis of HBV infection is related to the host immune response to viral infection. More vigorous immune responses cause more severe liver injury. Patients with a vigorous immune

response may suffer fulminant infection with severe liver injury followed by rapid viral clearance, whereas hosts with less vigorous immune responses may become asymptomatic carriers.<sup>10</sup>

### Natural History of Hepatitis B Virus

Transmission of HBV is parenteral. In developed countries, sexual contact, intravenous drug use, acupuncture, and transfusion constitute the most common modes of transmission. In developing countries, vertical transmission is more significant.

Acute hepatitis B manifests as an icteric illness after an incubation period of 6 weeks to 6 months in up to 50% of infected persons.<sup>10</sup> A subset of patients experience a prodromal phase characterized by arthralgias and urticarial skin rash.<sup>14</sup> Acute infection is diagnosed by the detection of hepatitis B surface antigen (HBsAg), IgM antibodies to hepatitis B core antigen (anti-HBcAg), and HBeAg. The outcome of acute hepatitis depends on the immune status and age of the host. Chronic HBV infection develops in as many as 90% of neonates and infants but in only 1% to 5% of immunocompetent adults.<sup>10,11</sup> Patients with chronic HBV infection rarely have extrahepatic manifestations, such as polyarteritis nodosa or glomerulonephritis.<sup>14</sup> Many remain asymptomatic until they present with cirrhosis, HCC, or both.

The presence of HBsAg in serum for 6 months or longer is indicative of chronic HBV infection. Chronic HBV infection manifests in one of several well-defined stages. The immune tolerance phase is seen largely in patients who acquire infection at birth or in early childhood. These patients have high levels of HBV replication but little to no liver inflammation and normal serum aminotransferase levels. Serum HBeAg is detectable, and HBV DNA is markedly elevated.<sup>10,11,15,16</sup> As the host immune system matures, the patient enters the immune clearance phase, which is characterized by immune-mediated liver injury. Patients who acquire infection as children come to clinical attention in this stage, and those who acquire infection as adolescents or adults have a very short or no immune tolerance phase and rapidly move into this second phase of the infection. Viral levels decrease, but HBV DNA is still elevated, and HBeAg is detectable. Serum aminotransferases increase, and liver histology shows active chronic hepatitis with evolving fibrosis.<sup>10</sup> Although most patients remain asymptomatic, some present with flares that mimic acute hepatitis, and this may precede the development of antibodies to HBeAg and remission of hepatitis activity.<sup>10</sup> Spontaneous seroconversion to anti-HBeAg antibody (HBeAb)-positive status occurs in up to 90% of white adults with chronic hepatitis B within 10 years of follow-up, and it is more likely in those with high transaminase levels, which indicate a vigorous immune response to HBV.<sup>10,16</sup>

Seroconversion is followed by the low or nonreplicative HBsAg carrier stage, characterized by normalization of aminotransferases and low or undetectable HBV DNA levels.<sup>10,16</sup> Histologically, minimal to mild hepatitis with variable fibrosis is seen.<sup>10</sup> Most patients remain in this stage, particularly if they acquired the infection as adults; viral clearance may occur, but in patients with established cirrhosis, monitoring for HCC must continue.<sup>10,17</sup> Up to 20% of patients serorevert to HBeAg-positive status, with a flare of activity.<sup>10,15,17</sup> In approximately 20% of patients, chronic hepatitis recurs without seroreversion; this is known as HBeAg-negative chronic hepatitis, due to mutations in the precore or core-promoter regions of the HBV genome.<sup>10,15,17</sup> In this phase, despite the presence of HBeAb and the absence of HBeAg, HBV DNA is detectable, serum aminotransferases rise, and histologic

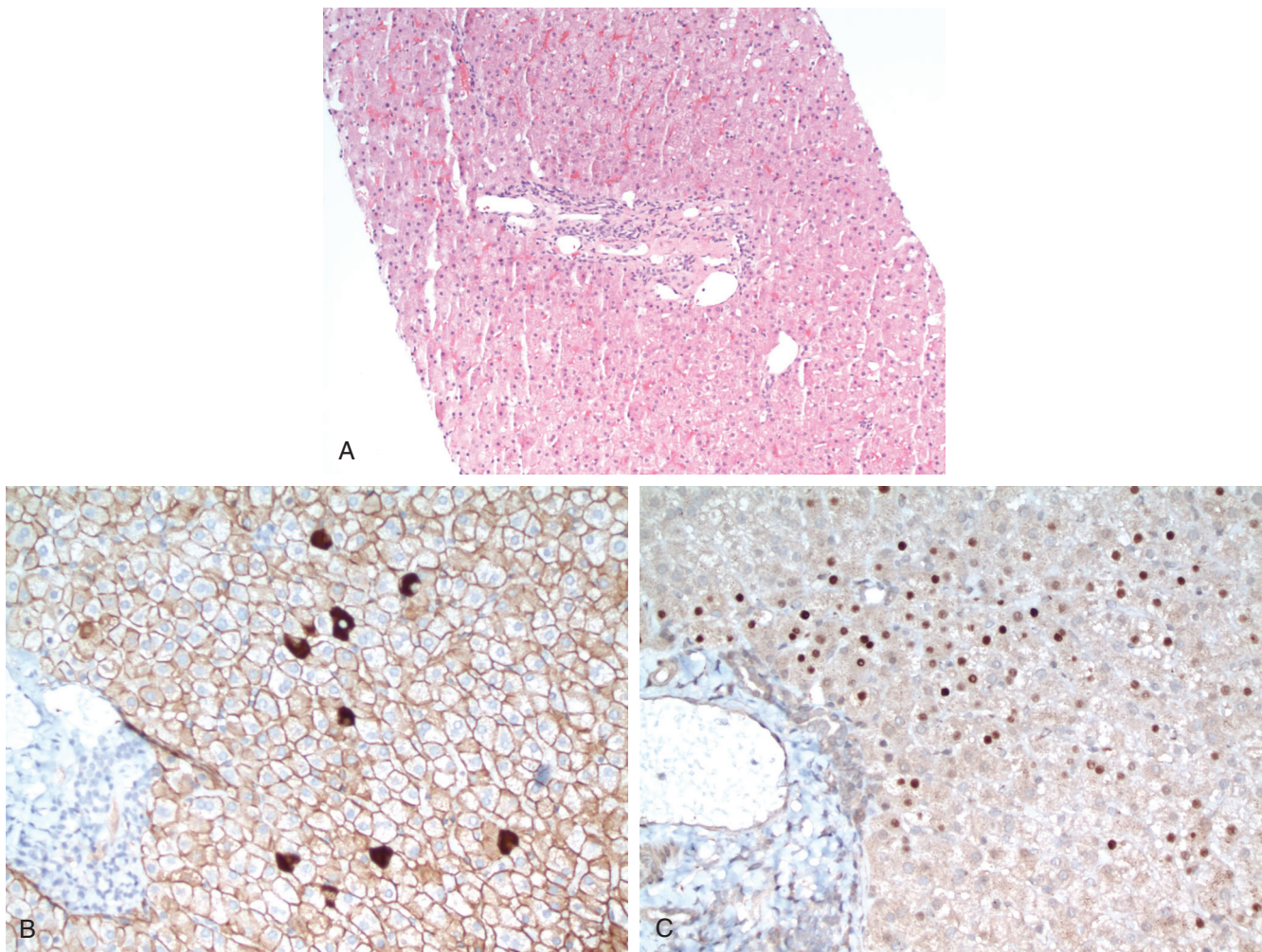
examination of the liver shows chronic hepatitis.<sup>10</sup> However, patients with HBeAg-negative chronic hepatitis tend to have lower HBV DNA levels than patients with HBeAg-positive chronic hepatitis and to have a more fluctuating course.<sup>15</sup> In addition, they are generally older and have more advanced liver fibrosis.<sup>10</sup> Resolved chronic hepatitis B is defined by the loss of HBsAg and acquisition of antibody to HBsAg. Approximately 0.5% of persons with inactive chronic hepatitis clear HBsAg yearly, and most of these will develop antibodies to HBsAg.<sup>15</sup> However, covalently closed circular DNA remains in the nucleus of hepatocytes, even in patients with serologic evidence of resolved infection, and poses a lifelong risk for reactivation of infection.<sup>15</sup>

Cirrhosis develops at an annual incidence of 8% to 10% in patients with HBeAg-negative chronic hepatitis and 2% to 5% in patients with HBeAg-positive chronic hepatitis.<sup>10</sup> Cirrhosis is the major risk factor for the development of HCC; the annual incidence of HCC is 1% for HBV carriers without cirrhosis and 2% to 3% for those with cirrhosis.<sup>10</sup> The risk factors for cirrhosis and HCC are similar and include high HBV DNA levels, HBeAg positivity, older age, and male gender.<sup>10,16</sup> Additional risk factors for HCC include abnormal alanine aminotransferase (ALT) levels, long duration of infection, coinfection with HCV or hepatitis D virus (HDV), a family history of HCC, excessive alcohol intake, cigarette smoking, HBV genotype C, and core-promoter mutations.<sup>10</sup>

### Histopathology of Hepatitis B Virus

Acute HBV infection is indistinguishable from other forms of acute viral hepatitis. Portal tracts exhibit a moderate to marked lymphocytic infiltrate. Lobular mononuclear inflammation is associated with widespread lobular injury in the form of hepatocyte ballooning, although in the early stages the injury may be confined to centrilobular regions. Numerous acidophil bodies, canalicular cholestasis, and Kupffer cell hyperplasia may be seen. In more severe cases, bridging necrosis may span between portal tracts and central veins. Panacinar necrosis or multiacinar necrosis may also be a feature. Fulminant cases are characterized by submassive or massive necrosis with marked ductular reaction. Numerous macrophages laden with lipofuscin and hemosiderin may be seen in necrotic areas. Hepatic lobular regeneration may also be evident, with mitotic figures and lobular disarray. The latter can be highlighted by reticulin stains, which serve to delineate the loss of normal hepatic plate architecture.

The histology of chronic hepatitis B varies according to the phase of the disease and host immunity. The immune tolerance phase may show no or minimal portal and lobular inflammation and no fibrosis, despite rapid viral replication (Fig. 11.2). In the immune clearance phase, chronic hepatitis B shows portal mononuclear infiltrates with interface hepatitis and variable fibrosis (Fig. 11.3). Varying degrees of lobular necroinflammatory activity are present, but typically not to the extent seen in acute viral hepatitis. Hepatocyte anisonucleosis may be conspicuous. A characteristic feature of chronic HBV is the presence of ground-glass hepatocytes (Fig. 11.4), which contain HBsAg. These hepatocytes show a finely granular cytoplasmic inclusion that displaces the nucleus and is surrounded by a pale halo. Ground-glass hepatocytes can be demonstrated by various histochemical stains, such as Victoria blue, orcein, or aldehyde fuchsin,<sup>18</sup> and by immunohistochemical stains for HBsAg. In some cases the hepatocyte nuclei have a "sanded" appearance due to the accumulation of HBcAg, although these are difficult to recognize and also are seen in delta hepatitis.<sup>18</sup>



• **Figure 11.2** Liver biopsy in the immune tolerance phase of hepatitis B. **A**, Portal tract without inflammation or fibrosis. **B**, Immunohistochemical staining for hepatitis B surface antigen shows strong membranous staining of hepatocytes, as well as individual hepatocytes with strong cytoplasmic staining, consistent with high viremia. **C**, Immunohistochemical stain for the hepatitis B core antigen shows nuclear staining of many hepatocytes, consistent with high viral replication.

### Immunohistochemistry of Hepatitis B Virus

Immunohistochemistry for HBV antigens can be used to evaluate the pattern of antigen expression, which correlates with viral replication and disease activity (Table 11.1). Membranous expression of HBsAg in hepatocytes with strong cytoplasmic expression in individual hepatocytes indicates high viremia and is seen in the immune tolerance phase.<sup>19,20</sup> In contrast, cytoplasmic expression of HBsAg in clusters of hepatocytes is more often seen in patients with low or absent viremia and without active viral replication; these cells contain integrated HBV DNA, and clonal expansion of such cells may explain their clustering.<sup>19,20</sup>

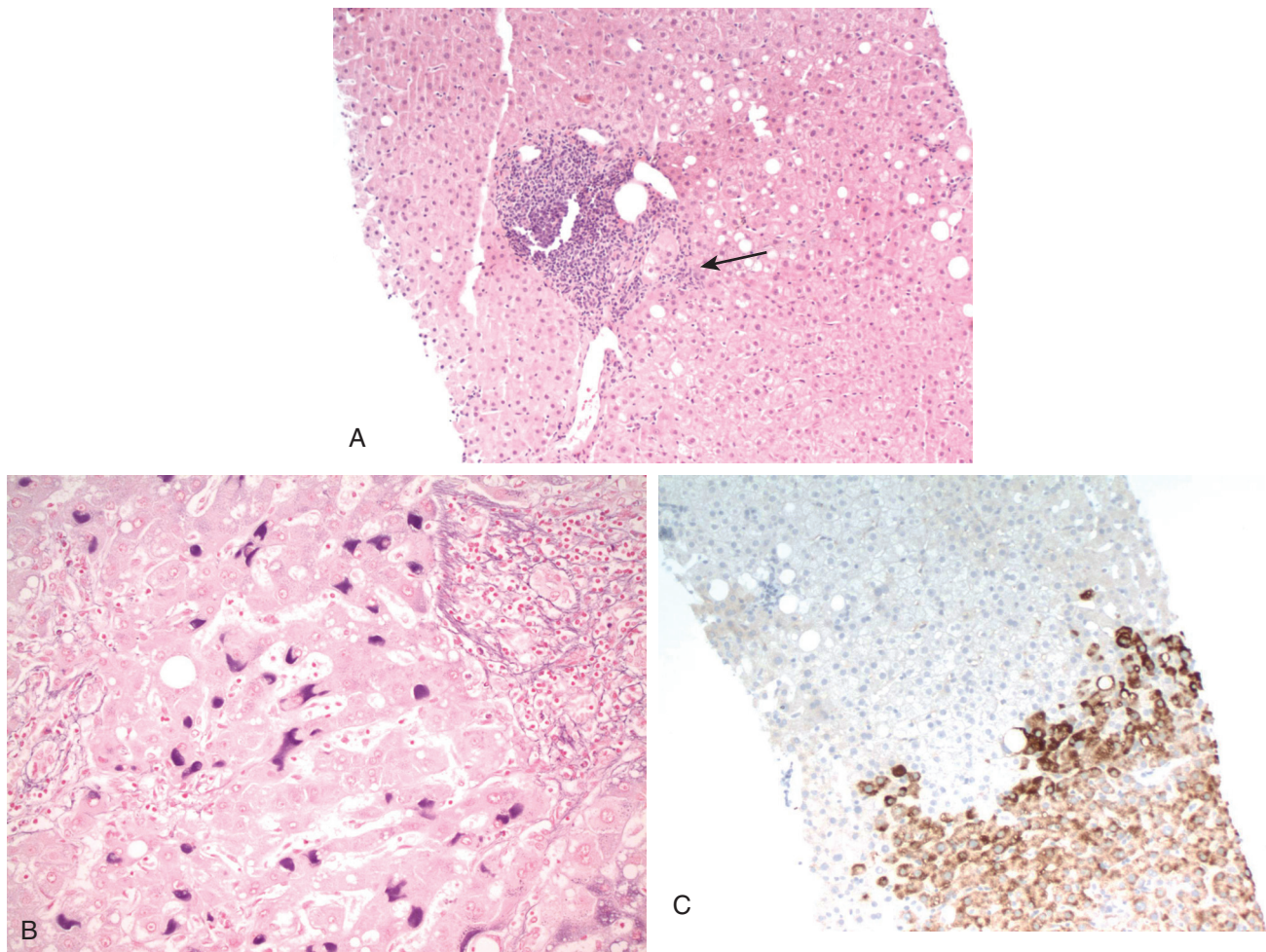
Expression of HBcAg can be cytoplasmic, nuclear, or a mixed pattern. Nuclear expression correlates with the degree of viral replication and the level of HBV DNA<sup>21</sup>; biopsy specimens from patients in the immune tolerance phase or from immunosuppressed patients often show widespread nuclear staining, whereas those from patients with chronic hepatitis and low-replicative states have rare positive nuclei. Cytoplasmic HBcAg expression is associated with active liver damage and higher ALT level,<sup>22</sup> suggesting that HBcAg is the likely target for immune-mediated

cytolysis.<sup>19</sup> Coinfection with delta virus can suppress HBcAg production and is one possible cause of a negative HBcAg stain in the setting of active hepatitis.

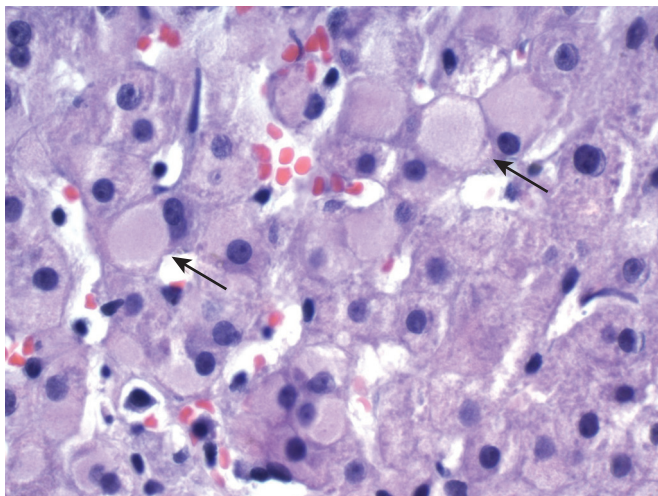
In general, immunohistochemistry findings for HBV antigens are negative in acute or fulminant hepatitis. Presumably, the inability to detect HBV antigen expression is a result of the short time interval of infection and insufficient accumulation of the proteins in hepatocytes to permit detection by immunohistochemistry.

### Management of Hepatitis B Virus

The management of chronic HBV infection has improved significantly in the past decade with the introduction of nucleoside and nucleotide analogues. These agents are orally administered, well tolerated, and very effective at suppressing HBV DNA replication.<sup>23</sup> However, HBsAg clearance is rarely observed, and lifelong therapy is often required. Because lifelong treatment exposes patients to adverse reactions and high costs and may induce viral resistance,<sup>23</sup> the question of when to begin treatment remains an important one in the management of these patients. In general, patients with active disease benefit most from therapy. Although



• **Figure 11.3** Liver biopsy in the immune clearance phase of hepatitis B. **A**, Low-power view of a portal tract with a dense mononuclear infiltrate and focal interface hepatitis (*arrow*). **B**, Aldehyde fuchsin stain confirms the accumulation of hepatitis B surface antigen within hepatocytes. **C**, Immunohistochemical stain for HBsAg shows cytoplasmic staining of clusters of hepatocytes, indicative of low viremia.



• **Figure 11.4** Ground-glass hepatocytes in chronic hepatitis B (*arrows*). Ground-glass hepatocytes show finely granular cytoplasmic inclusions that displace the nucleus to the edge of the cell and are surrounded by a clear halo.

ALT can be an indicator of active disease, it has been shown that approximately 20% of patients with normal ALT levels have significant inflammation and/or fibrosis on biopsy, particularly among patients who are older than 35 years of age, who are HBeAg negative, or who have fluctuating ALT levels.<sup>24</sup> Therefore a liver biopsy is frequently used in questionable cases to determine whether there is sufficient necroinflammatory activity to warrant therapy.

Current American Association for the Study of Liver Diseases (AASLD) guidelines recommend antiviral therapy for adults with immune-active chronic hepatitis B, whether HBeAg negative or positive.<sup>15</sup> Immune-active disease is defined as elevation of ALT greater than 2 times the upper limit of normal or evidence of significant histologic disease plus elevated HBV DNA above 2000 IU/mL (HBeAg negative) or above 20,000 IU/mL (HBeAg positive).<sup>15</sup> Additional factors, including gender, age, family history of HCC, and presence of extrahepatic manifestations, may be taken into consideration for patients whose ALT or HBV DNA levels do not meet these criteria. The AASLD recommends against treating adults with immune-tolerant hepatitis B, but ALT levels should be tested periodically to monitor for the transition to immune-active stage.<sup>15</sup> Moderate to severe necroinflammatory

**TABLE 11.1** Immunohistochemistry for Hepatitis B

	HBsAg		HBcAg	
	Membranous	Cytoplasmic	Nuclear	Cytoplasmic
Immune tolerance phase	++	++ (individual cells)	++	–
Immune clearance phase	–/+	+ (individual cells)	+ (few cells)	+/–
Low-replication states (chronic carriers)	–	++ (clustered cells)	–/+ (rare cells)	–
HDV/HCV coinfection	+	+/–	–	–
HBV in immunodeficiency states	++	+/–	++	+

–, Absent; +, present; *HBcAg*, hepatitis B core antigen; *HBsAg*, hepatitis B surface antigen; *HBV*, hepatitis B virus; *HCV*, hepatitis C virus; *HDV*, hepatitis D virus.

activity or fibrosis on liver biopsy warrants consideration to initiate antiviral therapy.<sup>15</sup>

All guidelines recommend continuing therapy in HBeAg-positive individuals at least until they achieve HBeAg seroconversion and have undetectable HBV DNA levels followed by 12 months of consolidation therapy. However, many experts feel that HBeAg seroconversion is not an acceptable endpoint and recommend therapy until HBsAg is lost, particularly in patients with advanced fibrosis or cirrhosis. Because HBsAg clearance is rare, most patients will be treated for life.<sup>23</sup>

### Viral Mutants of Hepatitis B Virus

**Precore and Core Gene Mutations.** Precore and core gene mutations are associated with decreased production of HBeAg despite continued production of infectious virions. The most common mutation results in a stop codon that prematurely terminates the synthesis of HBeAg.<sup>16</sup> Other mutations in the basic core promoter downregulate HBeAg synthesis at the transcriptional level.<sup>16</sup> Patients infected with these mutants exhibit absent HBeAg but positive HBsAg, elevated serum HBV DNA, and elevated transaminases.

**Surface Gene Mutations.** Surface gene mutations are responsible for vaccine escape. Although patients infected with these mutants are infectious, HBsAg is not detectable.<sup>12</sup>

**Polymerase Gene Mutations.** Mutations in the YMDD catalytic site of the polymerase significantly reduce the effectiveness of lamivudine and famciclovir.<sup>12,25</sup> Despite developing this mutation, patients continue to receive some benefit from lamivudine therapy because the YMDD variant HBV exhibits reduced replication competence and reduced virulence.<sup>12</sup> Discontinuation of lamivudine may cause mutant virus to revert to wild-type, with renewed efficacy of lamivudine.<sup>25</sup>

### Posttransplantation Hepatitis B

HBV frequently infects liver allografts after transplantation for HBV and may lead to deterioration of graft function, although some patients enjoy excellent graft function for many years despite active viral replication.<sup>26</sup> The risk of reinfection is greater after transplantation for chronic HBV infection with cirrhosis, compared with acute HBV.<sup>27</sup> The pattern of hepatitis in this setting ranges from purely immunohistochemical evidence of viral antigen expression without histologic features of HBV infection, to acute hepatitis, and to chronic hepatitis with cirrhosis.<sup>26</sup> Acute HBV hepatitis after transplantation may show marked ballooning and degenerative changes in the hepatocytes, scattered acidophil

bodies, and extensive immunohistochemical evidence of viral antigen expression but with remarkably scant inflammation.<sup>26,27</sup>

A distinctive pattern of hepatitis in the transplantation population is known as fibrosing cholestatic hepatitis, initially described by Davies et al. in 1991.<sup>26-29</sup> This pattern is characterized by canalicular and cellular cholestasis, ballooning of hepatocytes, and scattered acidophil bodies with relatively scant parenchymal inflammation. Portal tracts are mildly to moderately inflamed and show periportal fibrosis, with immature fibrous tissue extending as thin perisinusoidal strands into the acinus. At the interface, a proliferation of ductal-type cells lends a hypercellularity to the portal areas. Immunohistochemical stains show extensive cytoplasmic and membranous expression with HBsAg and extensive nuclear and cytoplasmic HBcAg.<sup>26,28,29</sup> The combination of high HBV antigen expression, marked hepatocyte injury, and relatively little inflammation suggests that the virus itself may be cytopathic in this setting.<sup>26,27,29</sup> Fibrosing cholestatic hepatitis is associated with a high rate of viral replication, with high serum HBV DNA, high serum HBsAg titers, and rapid deterioration.<sup>27-29</sup> It has also been described in HBV infection in other settings involving immunosuppression, including human immunodeficiency virus (HIV) infection<sup>30</sup> and bone marrow transplantation.<sup>31</sup>

### Coinfection With Hepatitis B Virus and Human Immunodeficiency Virus

Approximately 90% of HIV-infected persons show evidence of prior HBV infection, and 5% to 15% have chronic HBV infection.<sup>32</sup> In patients coinfecting with HIV and HBV, the rate of clearance of HBsAg and HBeAg is reduced, compared with non-HIV-infected individuals.<sup>33</sup> This reduced clearance rate is most likely due to a weakened immune system. However, the reduced immune reaction is potentially responsible for the relatively reduced inflammation in these patients despite their higher HBV viral replication rates.<sup>33</sup> Even though there is reduced inflammation, HBV infection is more progressive in HIV-positive patients, including development of cirrhosis and its complications.<sup>33</sup> A pattern of hepatitis similar to fibrosing cholestatic hepatitis has been described in HIV patients with concurrent HBV infection.<sup>30</sup> The HBV-related mortality in HIV patients has increased since the introduction of highly active antiretroviral therapy (HAART), possibly because of increased immunologic injury to the liver with immune reconstitution, toxicity of the antiviral drugs, or longer life spans in HIV patients.<sup>33</sup> Conversely, the use of antiretroviral agents that also have activity against HBV may slow the progression of chronic HBV and even result in

seroconversion, whereas their discontinuation can cause significant liver disease due to reemergence of HBV replication.<sup>32</sup>

## Hepatitis C

Hepatitis C affects between more than 170 million people worldwide.<sup>34</sup>

### Virology of Hepatitis C Virus

HCV is an RNA flavivirus that was characterized in the late 1980s.<sup>35</sup> Its genome is a positive, single-stranded RNA with a large open reading frame that encodes a 3011- to 3030-amino-acid polyprotein.<sup>36</sup> This polyprotein is processed into an array of structural and nonstructural proteins. The structural proteins include the core protein and two envelope proteins, E1 and E2.<sup>36</sup> The nonstructural proteins are p7, NS2, NS3, NS4A, NS4B, NS5A, and NS5B (RNA polymerase).<sup>34,36</sup>

There are six major genotypes and more than 50 subtypes. However, the genome of HCV is highly mutagenic, and a given host carries a mixture of viral particles with closely related sequences known as quasispecies.<sup>36,37</sup> The high mutation rate may allow the virus to escape the immune system; patients with chronic infection harbor highly diverse quasispecies, whereas those who clear the infection have low virus diversity and patients with fulminant hepatitis have the lowest level of viral diversity.<sup>37</sup> Genotypes 1, 2, and 3 have worldwide distribution, but their relative prevalence varies geographically.<sup>38</sup> Genotype 1a is the predominant genotype in North America (70%).<sup>39</sup> In Japan, subtype 1b is responsible for up to 73% of infections. Subtypes 2a and 2b are common in North America, Europe, and Japan, whereas subtype 2c is common in northern Italy. Genotype 3 is endemic in Southeast Asia, and it is also prevalent among intravenous drug users in Europe and the United States.<sup>39</sup> Genotype 4 is prevalent in North Africa and the Middle East; genotype 5 is largely confined to South Africa; and genotype 6 is found in Hong Kong, Macao, and Vietnam.<sup>38,39</sup>

The genotype affects the rate of evolution to chronic hepatitis, the severity of liver disease, and the response to interferon (IFN) therapy.<sup>38</sup> For example, genotype 1 is associated with a poor response to IFN therapy, whereas genotypes 2 and 3 respond more favorably.<sup>39</sup> An association between genotype 1b and an increased risk of developing severe liver disease and HCC has been reported.<sup>39,40</sup>

### Natural History of Hepatitis C Virus

HCV is primarily transmitted parenterally, such as by recreational drug use, injection with contaminated syringes or needles, or blood transfusion.<sup>35,41</sup> Although sexual and vertical transmission occur, they are less important with HCV than with HBV. The incidence of HCV in the United States has fallen since the introduction of widespread blood donor screening and needle exchange programs.<sup>37</sup> However, since 2000, there has been an increase in the number of cases of acute HCV occurring in HIV-positive men who have sex with men (MSM).<sup>34</sup>

Acute infection can be diagnosed in a variety of ways, including documentation of anti-HCV seroconversion and detection of HCV RNA in the absence of HCV antibodies.<sup>42-44</sup> The mean incubation time for HCV is 6 to 8 weeks.<sup>35</sup> Although the majority (60% to 75%) of affected patients do not experience symptoms when acutely infected,<sup>35</sup> acute HCV still accounts for approximately 20% of cases of acute hepatitis.<sup>41,45</sup> The symptoms of acute HCV are malaise, fatigue, lethargy, anorexia, abdominal pain,

jaundice, mild hepatosplenomegaly, maculopapular rash, and arthralgia.<sup>35</sup> Fulminant hepatitis is rare.

A minority of patients (approximately 15% to 50%) clear the infection, but most develop chronic viral hepatitis. Symptomatic onset of disease and female gender are associated with a higher chance of viral clearance after acute infection.<sup>45</sup> The serologic diagnosis of chronic HCV infection is made by detection of HCV antibodies, usually by enzyme immunoassay.<sup>35</sup> These assays have a 95% to 99% sensitivity and can detect antibodies 6 to 8 weeks after exposure. Polymerase chain reaction (PCR)-based methods can detect HCV RNA 1 to 3 weeks after exposure.<sup>35</sup> Patients with chronic HCV infection may present with normal transaminases. These patients are often identified during blood donation or screening. The rate of progression to fibrosis or cirrhosis is very low in this group.<sup>41</sup> Patients with elevated transaminases may suffer from fatigue or from nonspecific symptoms.<sup>41</sup>

Extrahepatic manifestations may include mixed essential cryoglobulinemia, membranous or membranoproliferative glomerulonephritis, non-Hodgkin lymphoma, Sjögren syndrome, lichen planus, autoimmune thyroid disease, and porphyria cutanea tarda.<sup>35,41,46</sup> A subset of patients with HCV demonstrate autoantibodies similar to those seen in autoimmune hepatitis, namely antinuclear antibodies (ANAs), smooth muscle antibody (SMA), perinuclear antineutrophilic cytoplasmic antibody (p-ANCA), and anti-asialoglycoprotein receptor, although often at lower titer than is typically seen in autoimmune hepatitis.<sup>46</sup> Less often, liver-kidney microsomal (LKM1) autoantibodies are detected, although the epitopes recognized by these antibodies in HCV differ from those in autoimmune hepatitis type 2.<sup>46</sup> Patients with autoantibodies tend to be females and to have higher transaminase levels.<sup>47</sup> Some of these patients experience exacerbation during IFN- $\alpha$  therapy that may respond to steroid therapy, suggesting either preexisting autoimmune hepatitis or induction of autoimmune hepatitis in these patients.

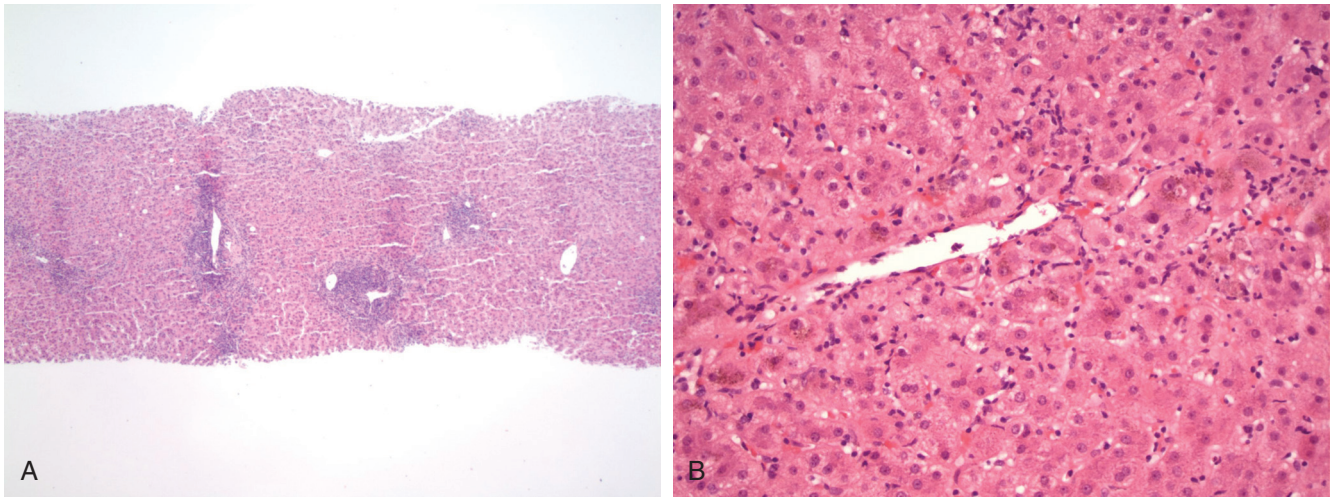
The rate at which chronic hepatitis C progresses to cirrhosis depends on several factors. Factors that increase the rate of progression include male gender, older age at infection acquisition, longer duration of infection, immune suppression (e.g., HIV coinfection), HBV coinfection, alcohol use, and obesity.<sup>35</sup> The risk of developing cirrhosis is approximately 20% to 30% after 10 to 20 years of infection.<sup>41</sup> After cirrhosis has developed, the risk of liver disease-related mortality is 2% to 5% per year and the risk of developing HCC is 3% to 5% each year.<sup>41</sup>

### Histopathology of Hepatitis C Virus

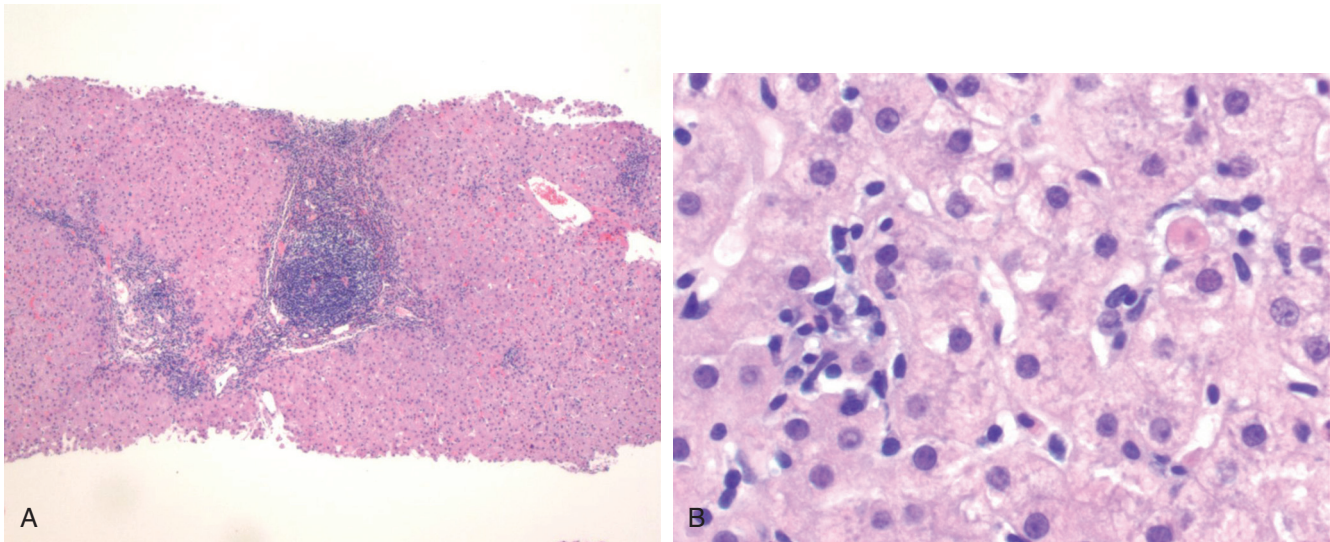
Acute hepatitis C is characterized by panlobular inflammation, numerous acidophil bodies, and lobular disarray similar to that seen in other acute hepatitis. A sinusoidal pattern of inflammation can mimic Epstein-Barr virus (EBV) hepatitis. More severe patterns of acute hepatitis, such as bridging necrosis or panacinar necrosis, are typically absent. Portal tracts harbor dense mononuclear infiltrates, resembling chronic HCV infection (Fig. 11.5). Bile duct injury may be present. Cholestatic forms of acute HCV infection occur rarely, predominantly in the immunosuppressed population.

Chronic HCV infection is characterized by dense mononuclear cell aggregates or follicles in portal tracts, with mild to moderate interface hepatitis.<sup>48</sup> Bile duct injury may be prominent, although typically it is mild. The lobules show scattered acidophil bodies (Councilman bodies) or foci of lytic necrosis marked by a small cluster of mononuclear cells (Fig. 11.6).<sup>48</sup> Kupffer cell prominence and lymphocytic infiltration of sinusoids may be seen.<sup>18,48</sup> Variable





• **Figure 11.5** Liver biopsy in acute hepatitis C. **A**, Low-power view shows mononuclear cell infiltrates within portal tracts, similar in appearance to chronic hepatitis C virus infection. **B**, High-power view of the centrilobular region shows sinusoidal lymphocytic infiltrates surrounding a central vein.



• **Figure 11.6** Liver biopsy in chronic hepatitis C. **A**, Low-power view shows a dense lymphoid aggregate within a portal tract. Bridging fibrosis is also evident, with mononuclear infiltrates in the septum. **B**, Lobular inflammation shows lytic necrosis on the left with a cluster of mononuclear cells indicating a focus of hepatocyte necrosis and a Councilman body (apoptotic hepatocyte) on the right; the latter is characteristic of hepatitis C virus infection.

fibrosis is present, and its extent often drives the decision of whether to treat the infection. Demonstration of virus by immunohistochemistry<sup>49</sup> or in situ hybridization<sup>50</sup> has been described but does not play a significant role in the routine evaluation of liver biopsies in hepatitis C.

Mild to moderate steatosis is characteristic of chronic HCV infection.<sup>48</sup> Steatosis may be related to direct viral cytopathic effects in patients with genotype 3 but to underlying metabolic status in patients with other genotypes.<sup>51,52</sup> HCV core protein expression produces steatosis in mice through mitochondrial toxicity and production of reactive oxygen species.<sup>51</sup> The severity of steatosis correlates with fibrosis.

Sarcoid-like granulomas are occasionally seen in liver biopsy specimens from patients with HCV. In one series, 9.5% of hepatic granulomas were attributed to HCV.<sup>53</sup> In another series, 5 (10%)

of 52 liver explants for HCV-related cirrhosis had granulomas for which no other cause could be identified.<sup>54</sup> In a biopsy series, 14 of 155 biopsies for HCV had granulomas, but half of them could be ascribed to another cause (sarcoidosis, schistosomiasis, primary biliary cirrhosis [PBC], or mycobacterial infection).<sup>55</sup> In a large series of 542 biopsies for HCV, only 2% had granulomas. In that series, the presence of granulomas predicted a better response to IFN- $\alpha$  therapy.<sup>56</sup> Others have described granulomas in HCV after treatment with IFN- $\alpha$  in patients who did not respond well to IFN- $\alpha$ .<sup>57-59</sup> In short, when a granulomatous process is encountered in a patient with HCV, other causes of granulomas in the liver must be rigorously excluded before they can be attributed to HCV. A history of IFN- $\alpha$  therapy should be sought.

The granulomas in HCV may occur in portal tracts or in the lobules. It is well known that HCV can be associated with mild bile

duct injury. If the granulomas are in the portal area, their presence in conjunction with injured bile ducts may mimic PBC. Other clinical information (e.g., antimitochondrial antibody [AMA], alkaline phosphatase level) may be needed to distinguish the two.

After successful treatment of hepatitis C, most patients experience either stable or reduced fibrosis and have a reduced risk for hepatic decompensation and HCC. However, curiously, a small percentage of patients who appear to have been successfully treated for HCV actually continue to progress and may still have inflammation in liver biopsies.<sup>60,61</sup> One factor that might explain this variable response is that patients with early cirrhosis are more likely to regress than those with advanced cirrhosis. In advanced cirrhosis, the extensive deposition of elastin and increased cross-linking of the extracellular matrix may prove more resistant to degradation.<sup>61</sup> Another theory that has been proposed as a possible explanation for this phenomenon is the concept of “occult HCV” in which very sensitive assays are able to detect the presence of virus in plasma, lymphocytes, and macrophages in patients with a confirmed sustained viral response (SVR).<sup>61</sup> Finally, genetic variants may be responsible because the rate of fibrosis regression differs among different ethnic groups.<sup>61</sup> Patients who did not enjoy a good response to therapy tend to progress similarly to those who were not treated.<sup>60</sup>

### Management of Hepatitis C Virus

The management of HCV has changed dramatically in the past several years. From the mid-1980s until 2014, the mainstay of treatment for chronic HCV included IFN. Standard IFN therapy was administered 3 times weekly and resulted in a fluctuating HCV RNA level.<sup>62</sup> By attaching a polyethylene glycol moiety to IFN (pegylated interferon [peg-IFN]), a single weekly injection became possible. The addition of ribavirin (RBV) to peg-IFN improved SVR rates and became the mainstay of therapy.<sup>62</sup> This combination achieved an SVR in approximately 40% to 50% of patients with genotype 1 and in approximately 80% of patients with genotypes 2, 3, 5, and 6.<sup>63</sup> An important discovery during this era was that polymorphisms of the *interleukin-28B* (*IL-28B*) gene predicted response to therapy in patients with genotype 1.<sup>62</sup> Among persons with genotype 1, the non-C/C genotype (CT or TT) was associated with reduced rates of SVR.

After the HCV genome had been mapped out, it became possible to target structural components of the virus itself. Direct-acting antivirals (DAAs) target several steps in the life cycle of HCV, including NS3-NS4A, NS5A, and NS5B RNA-dependent RNA polymerase.<sup>63</sup> In 2011 the first DAAs, boceprevir and telaprevir, protease inhibitors (PIs) of NS3-NS4, were approved for the treatment of chronic HCV, in combination with peg-IFN and RBV.<sup>63</sup> However, the initial enthusiasm for these agents was dampened by their significant toxicity. Second-generation PIs, such as simeprevir, have fewer drug-drug interactions and less severe side effects, with increased efficacy against genotype 1.<sup>63</sup>

NS5B inhibitors include nucleotide/nucleoside polymerase inhibitors (NPIs) and nonnucleotide/nucleoside polymerase inhibitors (NNPIs). NPIs are incorporated into the nascent RNA chain and cause chain termination, whereas NNPIs act as allosteric inhibitors of the polymerase.<sup>63</sup> Sofosbuvir is the first NS5B NPI available in the United States and has become the backbone of HCV therapy given its high barrier to resistance, pangentotypic activity, and favorable pharmacologic profile. In 2014 IFN-free combinations became available that proved to have extremely high efficacy in achieving SVR in patients with chronic HCV, including patients considered difficult to treat, such as cirrhotics and

those with genotype 1. Still, genotype may continue to be useful information in the decision of which combination to use because some, not all, DAAs have consistent activity across all genotypes and some genotypes are more likely to harbor resistance mutations. Despite the excitement IFN-free treatment of HCV has produced, the high cost of these drugs and other barriers to access remain as challenges to the eradication of HCV.

### Posttransplantation Hepatitis C

Historically, after transplantation for chronic HCV, reinfection of the graft was almost universal, although with the advent of highly successful therapy, patients will increasingly be treated before transplantation to prevent reinfection of the allograft. Although most patients do well in the long term, recurrent HCV can be progressive and can lead to graft dysfunction. The histologic features of recurrent HCV hepatitis progress from acute lobular hepatitis with scattered acidophil bodies and sinusoidal lymphocytic infiltration in the early stage to portal-based hepatitis with portal lymphoid aggregates typical of HCV infection in the chronic phase.<sup>64,65</sup> Progressive fibrosis and cirrhosis of the graft may result. A rapidly progressive cholestatic form of HCV infection has been described in the transplantation population, similar to the fibrosing cholestatic hepatitis described with HBV.<sup>66</sup> Fibrosing cholestatic hepatitis secondary to HCV has also been described in other immunosuppressed patient populations, such as in HIV patients<sup>67</sup> and after heart or kidney transplantation.<sup>68-70</sup>

### Coinfection With Hepatitis C Virus and Human Immunodeficiency Virus

In the United States and Europe 33% of HIV-infected persons are coinfecting with HCV.<sup>32</sup> The clearance rate of HCV after acute infection is reduced in HIV-infected patients.<sup>32</sup> In chronic infection, HCV RNA levels are higher in HIV-coinfecting patients, the efficacy of anti-HCV therapy is reduced, and the incidence of cirrhosis and HCC is higher.<sup>25,32,33</sup> In hemophiliac patients infected with HCV, coinfection with HIV has been associated with increased severity of hepatitis and increased risk of developing cirrhosis and liver failure.<sup>71,72</sup> Fibrosing cholestatic hepatitis related to HCV has been described in patients with HIV coinfection.<sup>67</sup> With the introduction of HAART, HCV-related liver disease has become an important factor in hospitalizations and mortality of HIV patients.<sup>33</sup> Patients with HCV are more likely to suffer from hepatotoxicity related to HAART and to have impaired immune reconstitution.<sup>32</sup>

### Hepatitis D

HDV (delta virus) is a defective, single-stranded, circular RNA virus that requires the lipoprotein coat of HBV for its replication; therefore infection from HDV alone does not occur. Eight genotypes are known; genotype 1 is the most common worldwide. There are two modes of infection: coinfection with HBV and superinfection of prior HBV infection. The severity of hepatitis in coinfection depends on the virulence of the concomitant HBV infection and ranges from mild hepatitis to severe acute hepatitis with high mortality.<sup>73</sup> The usual outcome is complete recovery, and only 2% of patients develop chronic disease; resolution produces immunity to both viruses. Superinfection presents as exacerbation in a patient with preexisting chronic hepatitis or as a new hepatitis in a previously asymptomatic HBV carrier. In superinfection, chronic infection develops in more than 90% of cases.<sup>73</sup> HDV infection inhibits HBV replication, resulting in

little to no evidence of HBV replication, with antibodies to HBeAg and low HBV DNA.<sup>73</sup> Treatment with IFN- $\alpha$  inhibits HDV replication, but relapse is common.

HDV infection may be associated with autoimmune manifestations in a subset of patients. Anti-liver kidney microsomal 3 (LKM3) autoantibodies are detected in 13% of patients with HDV.<sup>46</sup> However, one study found liver-specific autoantibodies (anti-asialoglycoprotein receptor) and non-organ-specific autoantibodies (e.g., ANA, anti-SMA) in 60.3% and 22.1% of HBV patients, respectively, regardless of whether HDV was present.<sup>74</sup> The pathology of HBV and delta virus is indistinguishable from that of HBV alone,<sup>75</sup> except that the degree of inflammation and hepatocyte necrosis is often more prominent than with HBV alone. Liver specimens from an outbreak among Venezuelan Indians showed a range of histologic severity from diffuse small-droplet steatosis with focal necrosis in the earliest stages to confluent necrosis and, in the late stage, postnecrotic cirrhosis with massive collapse.<sup>76</sup> Immunohistochemistry in cases of hepatitis D demonstrates delta antigen in nuclei of hepatocytes, reduced or absent expression of HBcAg, but continued expression of HBsAg.<sup>75-77</sup>

## Hepatitis E

Hepatitis E virus (HEV) is a nonenveloped, positive-sense, single-stranded RNA virus of the Hepeviridae family. There are four genotypes: genotypes 1 and 2 cause human disease in endemic areas, predominantly in developing countries, whereas genotypes 3 and 4 infect animals and cause zoonotic infections in humans in nonendemic areas. The virus is spread through fecally contaminated water or food, and epidemics have occurred in central and Southeast Asia, the Middle East, and North Africa.<sup>78,79</sup> In contrast, genotype 3 has been detected in domesticated pigs, wild boars, deer, and rodents and can be transmitted by porcine meat.

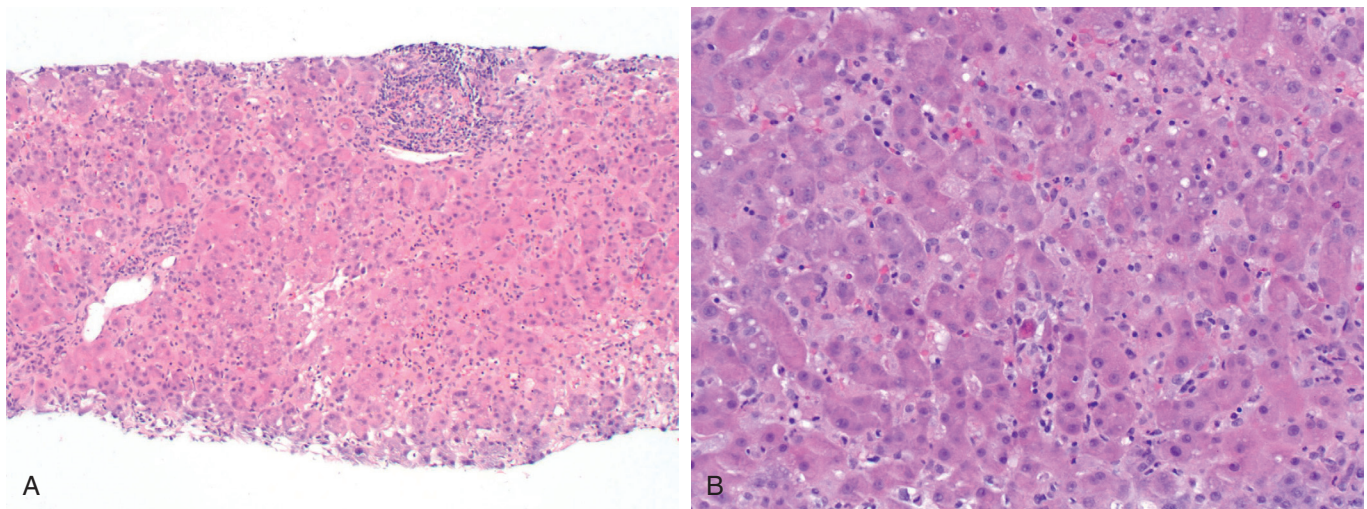
Most often, hepatitis E presents as acute hepatitis that is clinically indistinguishable from hepatitis A, ranging from asymptomatic infection to fulminant hepatitis. Mortality rate is 1% to 4% overall, but it is approximately 20% among pregnant women.<sup>78,79</sup> In immunocompetent individuals, there is no progression to chronic hepatitis. Although hepatitis E has been regarded as a

disease largely restricted to underdeveloped countries with warm climates, it is being increasingly recognized in industrialized countries; indeed, a small percentage of presumed cases of drug hepatitis may be acute hepatitis E.<sup>80</sup> Among 400 patients with acute hepatitis in Montenegro, 6% were demonstrated to have HEV by the presence of IgM anti-HEV.<sup>81</sup>

In immunosuppressed patients, chronic HEV infection with prolonged viremia has been described. Chronic HEV infection occurs largely in the solid organ transplant population,<sup>82,83</sup> but rare cases in HIV-positive individuals are described.<sup>84</sup> Chronic HEV might explain some cases of otherwise unexplained chronic hepatitis in liver allografts that, in some patients, leads to cirrhosis, sometimes requiring retransplantation.<sup>85</sup> Factors that predispose to chronic HEV include liver transplantation (relative to kidney transplantation) and tacrolimus immunosuppression rather than cyclosporin A.<sup>82</sup> Most patients eventually clear the virus, usually because of reduced immunosuppression, although treatment with RBV and peg-IFN may be beneficial in some patients.

Serologic diagnosis of HEV infection is hampered by the high prevalence of anti-HEV in the general population and a high false negative rate in immunocompromised individuals. The prevalence of anti-HEV ranges from 6% to 53% of the population, depending on the region surveyed. For example, in a nationwide survey of blood donors in France, 22.4% of the population had IgG to HEV and 1% of the population had IgM to HEV.<sup>86</sup> Areas of highest prevalence of IgG corresponded to areas of higher consumption of pork meat, raw pork liver sausage, game meat, offal, and oysters. In the United States the seroprevalence rate between 1988 and 1994 was 21%, with the likelihood of exposure increasing with age.<sup>87</sup> The presence of anti-HEV IgM is required to make the diagnosis of acute infection, but specific testing may not be available in all geographic locations. A rising IgG anti-HEV titer can provide evidence of infection, and PCR for HEV RNA provides additional supportive evidence.

The histopathology of acute HEV is similar to HAV in that it usually produces classic acute hepatitis (Fig. 11.7). Cases from endemic regions have been described as having ballooning degeneration of hepatocytes, apoptotic bodies, pseudorosette formation of hepatocytes, steatosis, and portal plasma cells.<sup>88</sup> Cases of



• **Figure 11.7** Liver biopsy in acute hepatitis E. **A**, Medium-power view showing lymphohistiocytic infiltrate in sinusoids, mild lobular disarray, and mononuclear cells in portal tracts. **B**, High-power view shows occasional acidophil bodies (*center*), mild lobular disarray, small droplet fat in some hepatocytes, and lymphohistiocytic inflammation.

autochthonous HEV hepatitis due to genotype 3 show acinar and portal inflammation with lymphocytes, plasma cells, and polymorphs, with equal numbers of eosinophils and neutrophils. Neutrophilic or lymphocytic cholangitis, cholestasis, lobular disarray with ballooning degeneration, hepatocyte rosettes, perivascular edema, confluent necrosis, anisonucleosis, and Kupffer cell aggregates are also described.<sup>89,90</sup> In transplant patients, biopsies may show mild portal and lobular hepatitis with acidophil bodies, progression to portal-based chronic hepatitis, and variable fibrosis including cirrhosis.<sup>83,85</sup>

### George Barker Virus Type C (Hepatitis G)

During the investigation for the cause of non-A, non-B hepatitis, a virus was discovered that was initially classified as hepatitis G but is now considered nonpathogenic. In 1966 a surgeon, George Barker (GB), became ill with acute hepatitis, and his blood was used to infect marmosets, which developed hepatitis. Serum from these animals was used to infect other primates. Eventually, two viruses were discovered in this primate group and called GB virus A (GBV-A) and GB virus B (GBV-B), after the surgeon.<sup>91,92</sup> Attempts to isolate these viruses from humans failed, but a related virus, GB virus C (GBV-C), was isolated from patient material.<sup>91</sup> Meanwhile, independent investigators discovered a novel virus that they classified as hepatitis G, and soon it was discovered that GBV-C and hepatitis G were genetically identical.<sup>91</sup> Like HCV, GBV is classified as members of the family Flaviviridae.<sup>92</sup>

Most immunocompetent people clear the virus in approximately 2 years, although some patients have persistent viremia. Clearance of the virus is associated with the production of antibodies to the envelope glycoprotein E2. Infection with GBV-C is worldwide and common. One percent to 4% of blood donors are viremic at the time of donation, and another 13% have antibodies.<sup>93</sup> Among HIV-positive homosexual men, approximately 85% are viremic or have antibodies indicating prior infection,<sup>93</sup> evidence of sexual transmission. Prostitutes also have high prevalence. Other methods of transmission are transfusion and maternal transmission.<sup>91</sup>

Because GBV-C was found in patients with hepatitis and at risk of developing parenteral hepatitis, it was initially believed to be a hepatotropic virus responsible for some cases of transfusion-related hepatitis, acute hepatitis, or chronic hepatitis. However, the virus is actually lymphotropic, not hepatotropic, and no convincing association between the virus and human disease has been identified.<sup>92</sup> Therefore the virus is currently believed to be nonpathogenic.

### Epstein-Barr Virus

The liver is involved in more than 90% of cases of infectious mononucleosis, which is caused by EBV infection; hepatomegaly is present in 10% to 15% of cases, splenomegaly in 50%, and jaundice in only 5%. Most often, the hepatic manifestations of EBV infection consist of self-limited elevations of hepatic transaminases. Rarely, EBV hepatitis has more serious consequences, such as the induction of autoimmune hepatitis,<sup>94</sup> severe hepatitis with jaundice,<sup>95,96</sup> or liver failure.<sup>97-99</sup>

Liver biopsy shows portal and periportal infiltrates of small and large lymphocytes, with occasional larger immunoblastic cells resembling the Reed-Sternberg cells of Hodgkin disease. A characteristic feature is sinusoidal infiltration by these same lymphocytes, which creates a beaded appearance (Fig. 11.8).<sup>100</sup> Bile duct

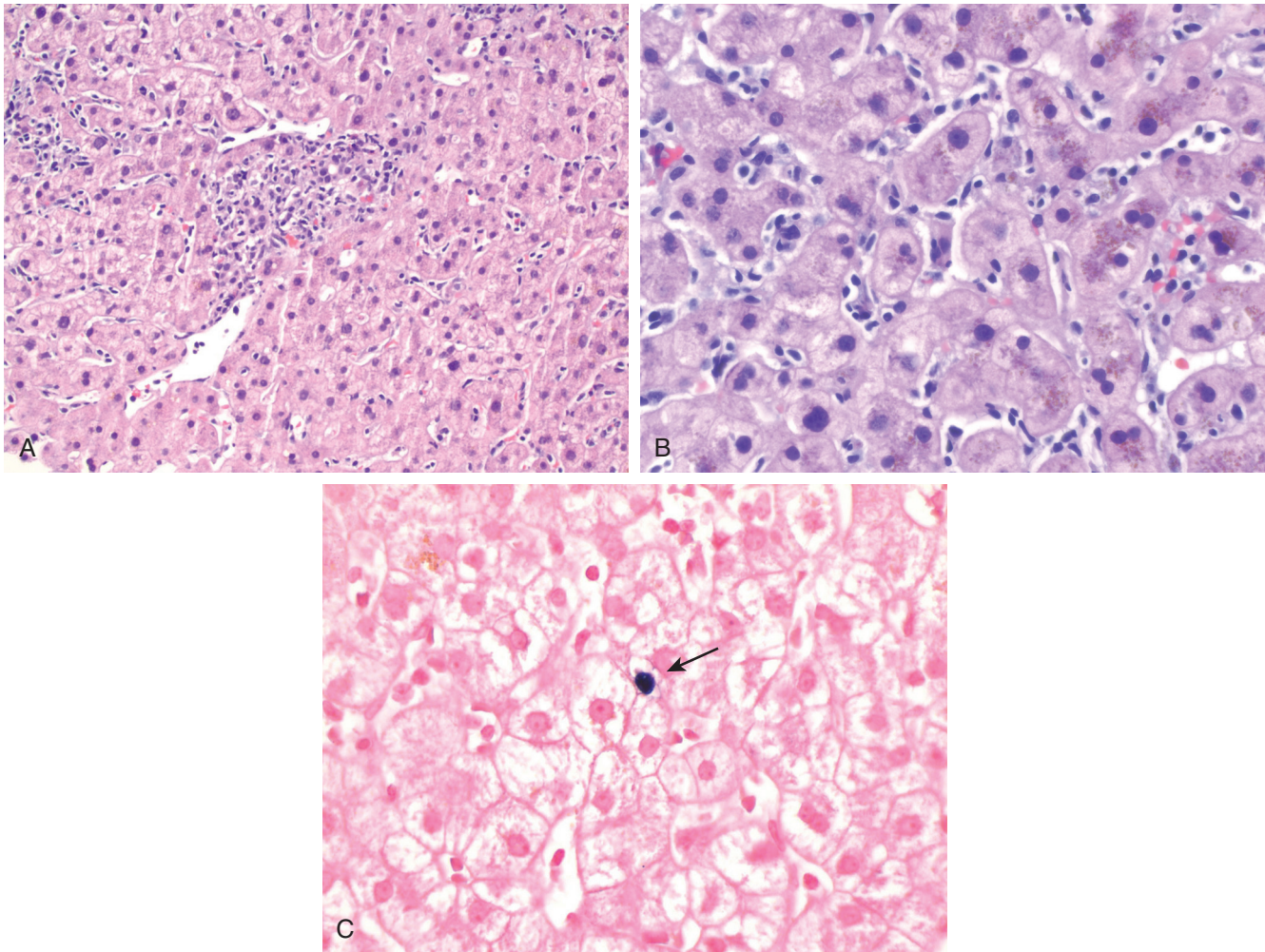
injury may be subtle.<sup>95</sup> Liver cell ballooning is not prominent, although hepatocyte regeneration, canalicular cholestasis, and Kupffer cell hyperplasia are variably seen. Areas of necrosis may be infiltrated by collections of mononuclear cells, creating a granulomatous appearance. Although these histiocytes usually do not form true epithelioid granulomas, well-developed nonnecrotizing granulomas<sup>101</sup> and fibrin ring granulomas have been reported in patients with EBV hepatitis.<sup>102</sup> In fatal cases, submassive lobular necrosis has been seen.<sup>97</sup>

Detection of EBV is done by in situ hybridization for EBV-encoded RNA (EBER) or by PCR for EBV DNA.<sup>103</sup> Immunohistochemistry for EBV latent membrane protein has not proved to be a reliable method for detecting EBV in EBV hepatitis.

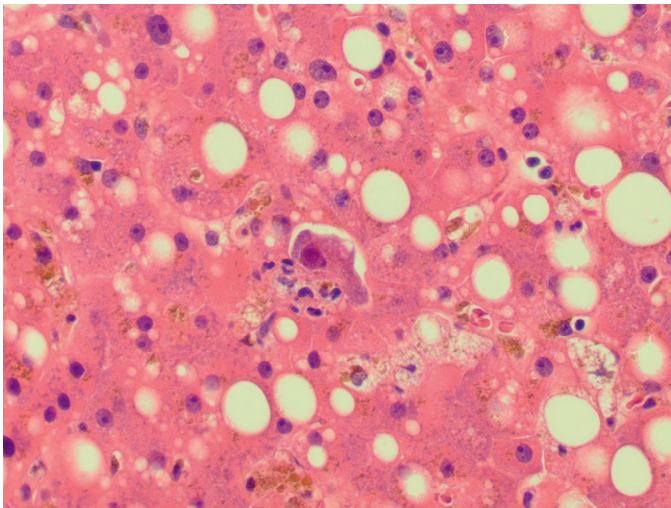
### Cytomegalovirus

In neonates, cytomegalovirus (CMV) infection has been associated with neonatal hepatitis or neonatal cholestasis, although establishing a serologic diagnosis in these cases is challenging due to maternal transfer of antibodies and poor IgM production in neonates.<sup>104</sup> Several studies have found CMV DNA in the serum or liver tissue of neonates with liver dysfunction or cholestasis.<sup>104,105</sup> The histology in these cases may resemble extrahepatic biliary atresia, with portal expansion, bile ductular proliferation, and bile stasis. Fatal cases may show widespread hepatocyte necrosis, lobular disarray with pseudorosettes, giant cell transformation of hepatocytes, and ductular metaplasia of hepatocytes.<sup>106</sup> Cytomegalic inclusion bodies have been described in hepatocytes, endothelial cells, and bile duct epithelium.<sup>106</sup> However, inclusions may be absent by routine histologic assessment, and immunohistochemistry or in situ hybridization may be useful, although their utility in this population has not been formally studied.<sup>105</sup> CMV has also been implicated in extrahepatic biliary atresia, based on studies demonstrating CMV DNA in liver tissue, serologic evidence of CMV infection, or positive urine cultures in a subset of infants with biliary atresia.<sup>107-109</sup> Inclusions have not been described by histologic assessment.<sup>108</sup> Although intriguing, the possible association between biliary atresia and CMV may lead to delay in diagnosis of biliary atresia when a child presenting with cholestasis is found to have clinical evidence of CMV infection.<sup>107,108</sup> Clinical evidence of CMV infection should not preclude evaluation for other causes of cholestasis, particularly biliary atresia, which requires early surgical intervention.

In adults, CMV infection is clinically mild and self-limited; CMV accounts for 8% of cases of infectious mononucleosis-like syndrome with hepatic involvement. Rare cases of massive hepatic necrosis have been reported, usually in immunocompromised hosts. In immunocompetent hosts, CMV infection can result in a histologic picture virtually identical to that of EBV hepatitis, with sinusoidal beading, atypical lymphocytes within sinusoids, lymphocytic infiltrates in portal tracts, and areas of necrosis with aggregates of Kupffer cells resulting in a granulomatous appearance.<sup>110,111</sup> CMV infection is rarely associated with well-formed nonnecrotizing granulomas<sup>112</sup> or fibrin ring granulomas.<sup>113</sup> In immunocompromised patients, viral inclusions may be found in hepatocytes, endothelial cells, Kupffer cells, and duct epithelium (Fig. 11.9). Virally infected cells show a large amphophilic nuclear inclusion surrounded by a halo, known as an "owl's-eye" nuclear inclusion, and coarsely granular cytoplasmic inclusions. The inclusions may be isolated, or they may elicit an inflammatory reaction that can be granulomatous or neutrophilic, the latter being especially common in transplantation patients.<sup>110</sup> In fact, a



• **Figure 11.8** Liver biopsy in Epstein-Barr virus infection. **A**, A portal tract shows a mild mononuclear infiltrate, and the lobules show infiltration of sinusoids by mononuclear cells. **B**, High magnification shows prominent sinusoidal lymphocytic infiltration without hepatocyte necrosis. **C**, In situ hybridization for Epstein-Barr virus–encoded RNA shows nuclear staining of a single infected lymphocyte (*arrow*).

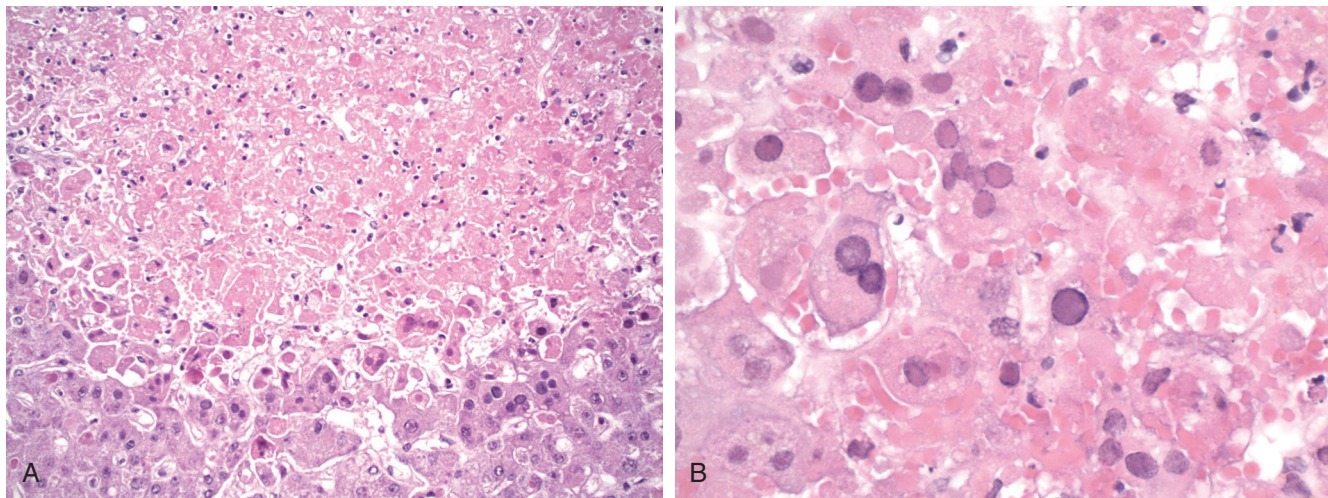


• **Figure 11.9** Cytomegalovirus (CMV) hepatitis, demonstrating a CMV inclusion in a hepatocyte associated with a few mononuclear inflammatory cells.

pattern of “disseminated focal hepatitis” with small inflammatory foci in the lobules composed of either neutrophils or mononuclear cells should prompt exclusion of CMV in transplant patients by searching for inclusions or immunohistochemistry.<sup>114</sup> In HIV-positive patients, bile duct involvement may result in sclerosing cholangitis (HIV-associated cholangiopathy). Immunohistochemical stains for CMV can highlight cells with inclusions, including atypical inclusions, and may stain infected hepatocytes that are not recognizable as infected cells on routine stains, increasing sensitivity for the diagnosis of CMV hepatitis.

### Herpes Simplex Virus

Herpes simplex virus (HSV) viremia can result in visceral involvement, affecting mainly the esophagus, lungs, and liver. Liver involvement occurs primarily in neonates, pregnant patients, and immunocompromised patients, although immunocompetent adults are rarely affected as well.<sup>115,116</sup> Dissemination usually occurs in primary infection (particularly if the patient is immunocompetent) but has also been described in reactivation.<sup>117</sup> In children, severe protein-calorie malnutrition and the postmeasles



• **Figure 11.10** Herpes simplex virus infection. **A**, The liver shows necrotic regions without an inflammatory response. **B**, Hepatocytes at the edge of the necrotic regions show glassy nuclear inclusions and multinucleation, consistent with herpes simplex virus infection.

state predispose to disseminated HSV infection.<sup>117</sup> Oral ulcers and skin lesions may or may not be present. HSV hepatitis is rapidly lethal and requires early recognition and institution of antiviral therapy to improve outcome.

HSV hepatitis is characterized by patchy, nonzonal coagulative necrosis with minimal to absent inflammatory response (Fig. 11.10). Mild to severe fatty change may be present.<sup>117</sup> Intranuclear inclusions of two types can be found in hepatocytes at the edge of the necrotic foci, and virally infected cells are often multinucleated.<sup>115,116</sup> Cowdry type A inclusions are large, eosinophilic intranuclear inclusions surrounded by a halo, whereas type B inclusions replace the entire nucleus with a basophilic ground-glass appearance. Immunohistochemistry for herpes type I and type II antigens highlights the nuclear inclusions, and overlap between the two antibodies is frequent.<sup>115,116</sup>

Treatment with antiviral drugs before the biopsy is obtained may result in a biopsy specimen with extensive necrosis but without diagnostic inclusions.<sup>116</sup> The main differential is varicella zoster virus (VZV) infection and adenovirus infection, both of which have a similar histologic appearance; immunohistochemical staining or PCR may be necessary to distinguish these infections. HSV serologic studies are not helpful in establishing the diagnosis but virologic cultures may be positive.

### Varicella Zoster Virus

Rarely, the rash of VZV can be accompanied by potentially life-threatening noncutaneous manifestations, including encephalitis, pneumonitis, myocarditis, and hepatitis, especially in immunocompromised patients, neonates, and adults. Dissemination is virtually always seen in primary infection, although dissemination in reactivation can occur in the immunocompromised patient.<sup>117</sup> Primary infection in immunocompetent adults can cause severe acute hepatitis and, rarely, fulminant hepatic failure. Transplantation patients and immunocompromised patients are at higher risk for a fatal fulminant hepatitis. In children, the convalescent phase can be associated with Reye syndrome (microvesicular steatosis, hyperammonemia, coagulopathy, and cerebral edema), particularly if aspirin has been administered.

Serology is of little use, especially in the immunocompromised patient. The appearance on liver biopsy resembles HSV. Immunohistochemistry can confirm the presence of a herpes virus, but, depending on the antibody, may not distinguish which one. PCR may be necessary to distinguish HSV from VZV infection.

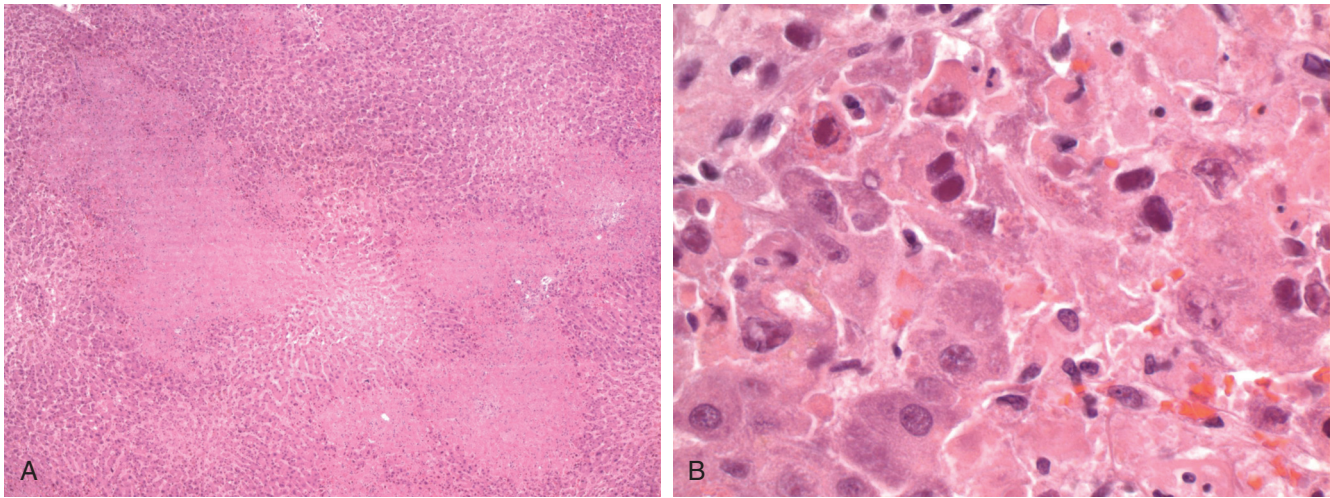
### Adenovirus

Although infection by adenoviruses is generally restricted to the upper respiratory tract and conjunctivae in the normal host, disseminated infection can occur in immunodeficient patients, particularly liver transplant recipients, bone marrow transplant recipients, and patients receiving chemotherapy.<sup>118</sup> Sixty-four percent of cases in the literature occurred in patients younger than 18 years of age.<sup>118</sup> Liver biopsies or postmortem livers in patients with adenovirus hepatitis have shown widespread necrosis with little inflammation, mild steatosis, and viral inclusions with a deep blue-purple smudged appearance (Fig. 11.11).<sup>118-120</sup> Immunohistochemistry, in situ hybridization, electron microscopy, PCR, or viral culture can be helpful in confirming the diagnosis.<sup>118,120</sup>

### Parvovirus B19

Parvovirus B19 produces several clinical manifestations, including erythema infectiosum (fifth disease) in children; hydrops fetalis; arthritis associated with acute infection in adults; various hematologic disorders (e.g., leukopenia, thrombocytopenia, transient aplastic crisis); and, rarely, involvement of other organs, including neurologic, cardiac, hepatic, and vascular disease.

The role of parvovirus B19 infection in acute or fulminant hepatitis is controversial. Several reports raise the possibility that parvovirus B19 may cause acute hepatitis, fulminant hepatitis, or fulminant hepatic failure. These cases describe several lines of evidence that implicate parvovirus B19, including the presence of parvovirus B19 DNA in the liver of patients with fulminant hepatic failure, the presence of parvovirus B19 DNA in liver tissue or serum of patients with acute or fulminant hepatitis, and the presence of IgM to parvovirus B19 in serum in patients with acute hepatitis.<sup>121-126</sup> In patients with fulminant hepatic failure,<sup>123</sup>



• **Figure 11.11** Adenovirus hepatitis. **A**, Low-power view shows several regions of necrosis without an inflammatory reaction. **B**, High-power view shows hepatocytes with smudgy nuclear inclusions similar to the Cowdry type A inclusions of herpes simplex virus.

parvovirus B19 DNA was found in liver tissue in four of six patients with associated aplastic anemia and in two of four patients without aplastic anemia but not in six patients with known causes of acute liver failure. Histology studies in these and other<sup>125</sup> cases showed a range of injury, from mild lobular hepatitis to massive or submassive hepatic necrosis and collapse with either no inflammatory infiltrates or small aggregates of lymphocytes. Viral inclusions are not seen on routinely stained slides, but parvovirus VP1 antigen (a structural protein produced by the virus) was detected by immunohistochemistry in one case report.<sup>125</sup> In contrast, other investigators found no parvovirus B19 DNA by PCR in 33 cases of cryptogenic acute liver failure but detected parvovirus B19 DNA in several patients with known causes of acute liver failure.<sup>127</sup> In that study, several patients had low-titer IgM positivity without confirmatory PCR positivity. In another study, parvovirus B19 DNA was found with similar frequency in patients with fulminant hepatitis and with hepatitis B or C.<sup>128</sup> Furthermore, RNA transcripts could not be detected in any of the liver tissue samples, arguing against active viral replication.<sup>120</sup> These studies suggest that low levels of PCR positivity may reflect remote infection, and they raise questions about the role of parvovirus B19 in acute hepatitis and acute liver failure.

The role for parvovirus B19 in chronic hepatitis is equally controversial. Although there are reported cases of chronic hepatitis secondary to parvovirus B19,<sup>129</sup> studies have shown that parvovirus B19 DNA can persist in liver tissue for prolonged periods.<sup>130,131</sup> Whether coinfection with parvovirus B19 worsens the prognosis of patients with hepatitis B or hepatitis C is uncertain. Some studies found that coinfecting patients have more severe disease, but most studies do not corroborate that finding.<sup>131-133</sup>

### Rubella (German Measles)

Acute hepatitis has been reported in adults who acquire rubella. The morphology shows ballooning degeneration of hepatocytes, focal hepatocyte necrosis, and infiltrating mononuclear cells, similar to classic acute hepatitis.<sup>134,135</sup> In addition, a case of fatal fulminant hepatic failure with giant cell transformation of hepatocytes in a child has been reported.<sup>136</sup>

### Rubeola (Measles)

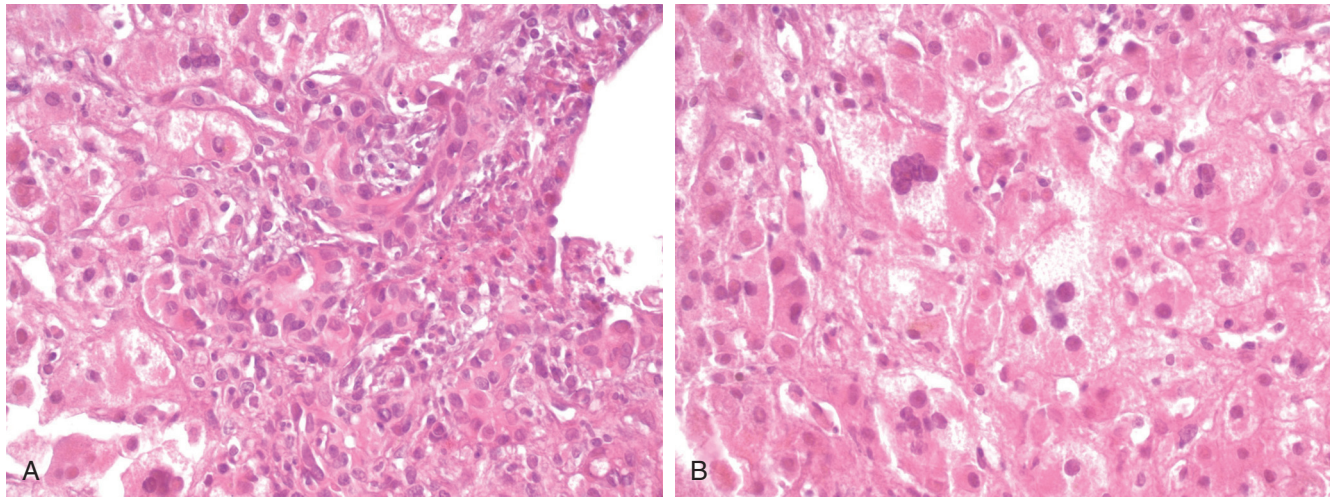
Measles is a contagious, acute, febrile illness that predominantly affects children and causes a maculopapular rash, Koplik spots, cough, conjunctivitis, fever, and lymphadenopathy. The virus enters the body through the lungs or conjunctivae, replicates at these sites, and then is transported to the reticuloendothelial system, where further replication and lymphoid proliferation occur. Transient transaminase elevation is not uncommon in measles.<sup>137</sup> In one reported case, liver biopsy demonstrated acute cholangitis, periportal inflammation with lymphocytes, eosinophils and neutrophils, periportal hepatocyte necrosis, ballooning degeneration and cholestasis, and multinucleated giant cells (Fig. 11.12). At autopsy, viral inclusions were noted in hepatocytes.<sup>138</sup>

### Severe Acute Respiratory Syndrome Coronavirus

In 2003 a novel coronavirus was found to be the causative agent of severe acute respiratory syndrome (SARS), an atypical pneumonia that can progress rapidly to acute respiratory distress syndrome. Hepatic impairment is common in these patients, with elevated transaminases seen in approximately 60% of cases. Liver histology shows lobular hepatitis with occasional acidophil bodies, prominent Kupffer cells, increased numbers of hepatocyte mitoses, focal mild ballooning degeneration, and mild portal tract inflammation.<sup>139</sup>

### Human Immunodeficiency Virus

HIV is associated with liver disease in several ways. During seroconversion, a small proportion of patients may experience hepatitis with transaminase elevations, although the histology of this hepatitis has not been described.<sup>140,141</sup> Opportunistic infections such as CMV, *Histoplasma capsulatum*, *Mycobacterium avium-intracellulare* complex (MAC), and *Pneumocystis jirovecii* can infect the liver. HIV can also increase the risk of progression of nonopportunistic pathogens, such as *Mycobacterium tuberculosis*, HBV, or HCV (see earlier discussions). Patients with acquired



• **Figure 11.12** Liver biopsy in a patient with measles hepatitis. **A**, Portal tracts show inflammation, cholangitis with bile duct injury, periportal hepatocyte loss, and ballooning degeneration. **B**, The lobules show widespread hepatocyte ballooning degeneration, cholestasis, and multinucleated hepatocytes.

immune deficiency syndrome (AIDS) may develop unusual reactions to certain pathogens, such as bacillary epithelioid angiomatosis secondary to *Bartonella henselae* or *Bartonella quintana* infection (discussed later).<sup>142,143</sup>

Granulomas are a common finding in liver biopsy of patients with HIV infection. The more common causes are *M. tuberculosis*, MAC, *Histoplasma*, *Candida*, CMV, and *Cryptococcus*.<sup>144</sup> In some of these patients the granulomatous response is poorly developed and composed of loose aggregates of histiocytes, but silver or acid-fast stains show numerous organisms. Therefore acid-fast and silver stains should be done routinely on biopsy specimens from patients with HIV/AIDS.

AIDS-related cholangiopathy is a syndrome that manifests with right upper quadrant abdominal pain, fever, and marked elevations of serum alkaline phosphatase. On cholangiography, the bile duct shows strictures and irregularities indistinguishable from those of primary sclerosing cholangitis (PSC). Several opportunistic pathogens have been implicated in this disorder, including *Cryptosporidium*, CMV, and microsporidia (*Enterocytozoon bieneusi*).<sup>145-150</sup> In a significant minority of cases, there is no identifiable pathogen; it is unclear whether these cases are due to unknown pathogens, occult infection, altered immunity, direct infiltration of the bile duct mucosa by HIV, or PSC coincidentally occurring in patients with AIDS.<sup>149,150</sup>

The liver can be involved by HIV-associated neoplasms, such as lymphoma or Kaposi sarcoma.<sup>151</sup> The latter is caused by another virus, Kaposi sarcoma-associated herpes virus (KSHV), also known as *human herpesvirus 8* (HHV-8). Finally, immune reconstitution with HAART can precipitate autoimmune hepatitis.<sup>152</sup>

## Yellow Fever

Yellow fever is a viral hemorrhagic fever that can vary from subclinical to rapidly fatal. It is transmitted by the *Aedes* mosquito. Classic symptoms include sudden onset of fever, rigors, and headache. Jaundice and hemorrhagic manifestations portend a poor prognosis. The pattern of injury is frequently described as midzonal and sometimes centrilobular.<sup>153-156</sup> Others describe panlobular injury with only a collar (one or two cells thick) of preserved hepatocytes around central veins and portal tracts.<sup>157</sup>

The key findings are necrosis with numerous apoptotic hepatocytes (Councilman bodies), microvesicular steatosis, and absence of inflammation (Fig. 11.13).<sup>153-156</sup> Eosinophilic intranuclear inclusions, Torres bodies, are rarely seen in humans.<sup>157</sup> Immunoperoxidase assays are not widely available, but the diagnosis can be confirmed serologically. The differential diagnosis includes other viral hemorrhagic fevers, such as dengue and Rift Valley fever.

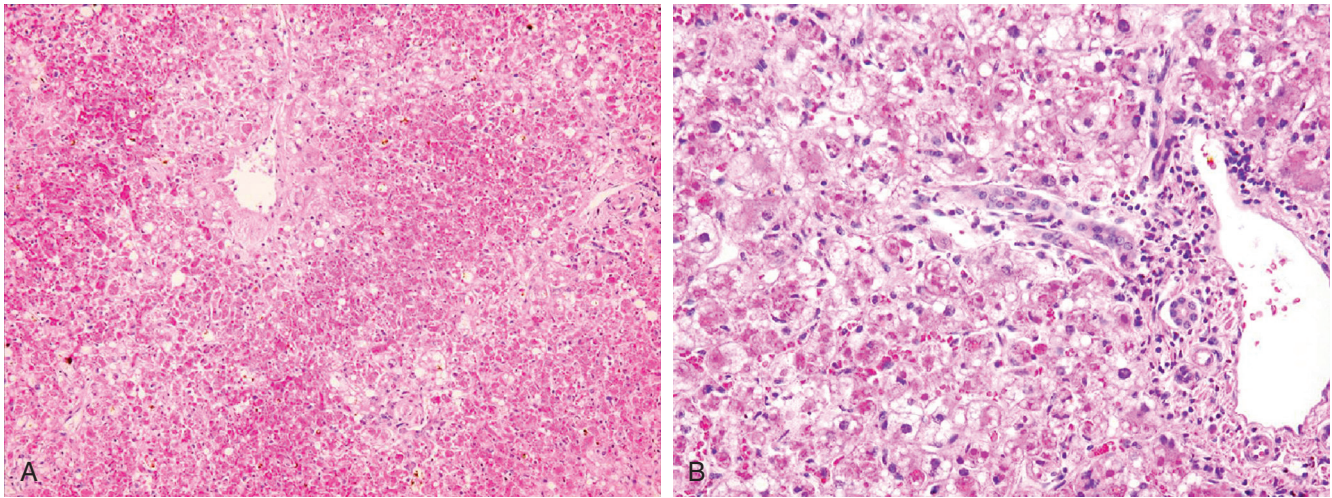
## Dengue

The dengue virus, a member of the Flaviviridae family, is also transmitted by the *Aedes* mosquito. Dengue virus infection is one of the most important mosquito-borne diseases in the world, and the resurgence of this disease in the last few decades may be related to human population growth, inadequate wastewater management, lack of effective mosquito eradication programs, and emergence of more virulent strains.<sup>158</sup> There are four serotypes of dengue virus, and infection with one serotype confers future protective immunity against that serotype only. Infection with a second serotype may result in antibody-dependent enhancement of the illness with immune complex formation.<sup>158</sup>

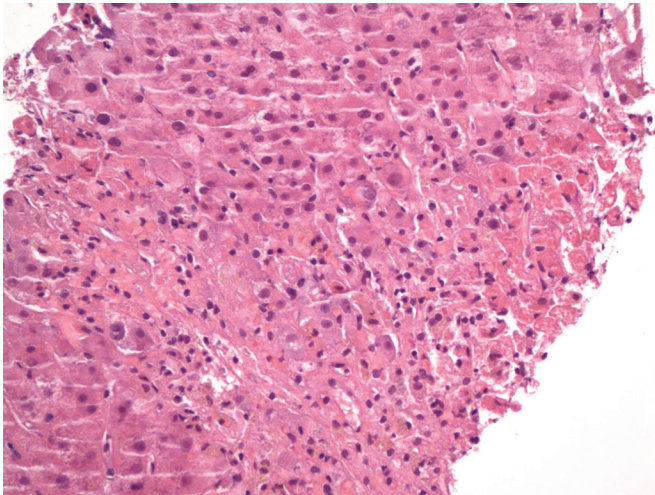
The clinical manifestations range from asymptomatic infection to severe infections known as dengue fever, dengue hemorrhagic fever, or dengue shock syndrome. Dengue fever manifests as high fever, severe headache, arthralgias, myalgias, and sometimes a rash. Patients with dengue hemorrhagic fever suffer from bleeding phenomena and circulatory failure. Dengue shock is caused by severe plasma leakage and manifests as cyanosis, hypotension, and encephalopathy.<sup>158</sup> The severity of hepatic involvement parallels the severity of the dengue infection. Serotypes 3 and 4 are associated with more severe liver disease.<sup>158</sup> Acute liver failure may develop at a median of 7.5 days after the onset of fever.<sup>159</sup> The prognosis varies; children may have higher mortality than adults.<sup>159-161</sup>

The histology is characterized by necrosis, with Councilman bodies involving the centrilobular region or, as in yellow fever, zone 2, although in most cases the degree of necrosis is not as severe as in yellow fever (Fig. 11.14).<sup>156,157</sup> Other features include hemorrhage, edema, macrophages in sinusoids, and platelets in





• **Figure 11.13** Yellow fever. **A**, Low-power view shows panlobular necrosis with numerous necrotic hepatocytes primarily in zones 2 and 3. **B**, High-power view shows relative preservation of periportal hepatocytes with steatosis, ballooning degeneration, and scattered necrotic hepatocytes. (Courtesy Dr. Shu-Yuan Xiao.)



• **Figure 11.14** Liver biopsy specimen from a patient who died of dengue shock demonstrates centrilobular necrosis with numerous acidophil bodies (*right*) and no inflammatory reaction.

the sinusoids with loss of endothelium.<sup>162</sup> Microvesicular steatosis is frequent, although relatively mild, and often localizes to the periportal space.<sup>162</sup> As with other arboviruses, little inflammation is present.<sup>163,164</sup> The distinction from yellow fever may require geographic data, clinical features, and virologic studies. The contributions of virus, the immune response, or shock to the pathologic changes remain uncertain.<sup>157,165,166</sup> However, immunohistochemical demonstration of the virus within hepatocytes has been described.<sup>162-164</sup> Viruslike particles have also been detected in hepatocytes using transmission electron microscopy, and in the same case, dengue virus polypeptides were found by electron immunomicroscopy.<sup>167</sup>

### Rift Valley Fever

Rift Valley fever primarily affects sheep and cattle in Africa, although humans who have direct contact with animals or

carcasses may become infected. Fever, severe headache, and myalgia may be followed by facial inflammation, encephalitis, and macular degeneration.<sup>153</sup> Hemorrhage and jaundice are poor prognostic features. Autopsies of cases with hemorrhage show hepatic necrosis, either widespread or predominantly in the periportal and midzonal areas, without prominent inflammatory infiltrates; numerous acidophil bodies; and hemorrhage.<sup>153,157,168</sup>

### Lassa Fever

Lassa virus is associated with severe febrile illness among missionaries and travelers returning from West Africa. Symptoms include chills, malaise, headache, and myalgia. Petechiae, ulcerative tonsillitis, and lymphadenopathy are common.<sup>153</sup> The liver shows haphazardly distributed areas of hepatocyte necrosis, both as foci of contiguous cells and as individual cells, either acidophilic or coagulative in type.<sup>157,169</sup> There is little inflammatory reaction apart from histiocytes phagocytosing necrotic debris.<sup>169</sup> The nonzonal distribution of the necrosis distinguishes this disease from yellow fever.<sup>153,169</sup>

### Ebola Virus

Ebola virus causes a severe and frequently fatal viral hemorrhagic fever. Outbreaks occur intermittently in Sub-Saharan Africa; the largest outbreak to date occurred in 2014-2016 and primarily affected Guinea, Liberia, and Sierra Leone. The disease is similar to Marburg virus infection, with disseminated intravascular coagulopathy and bleeding occurring in the majority of patients.<sup>153</sup> The histology is characterized by foci of hepatocellular necrosis randomly distributed throughout the parenchyma and eosinophilic inclusions within hepatocytes.<sup>153,157</sup> Mild to moderate steatosis, mild mononuclear infiltrates in the periportal area, and Kupffer cell activation are additional findings.<sup>157</sup>

### Marburg Virus

Marburg virus has been associated with African green monkeys. Fever, malaise, headache, and myalgia may be accompanied by a

maculopapular rash and conjunctivitis.<sup>153</sup> The histology is similar to that of Ebola virus infection. On electron microscopy, many hepatocytes contain inclusions composed of uniformly packed filaments arranged in parallel arrays.<sup>153</sup>

## Mycobacterial Infections of the Liver and Bile Duct

### Tuberculosis

Worldwide, *M. tuberculosis* is one of the most common causes of hepatic granulomas. The organisms may reach the liver hematogenously from the lungs (or less commonly an extrapulmonary site), through the portal circulation in the setting of gastrointestinal tuberculosis (TB), or via lymphatics.<sup>170</sup> The prevalence of hepatic involvement in patients with active TB has been estimated at approximately 1%.<sup>171</sup> TB can affect the liver in several forms. Most often (approximately 80% of cases of hepatic TB), the liver is affected in the setting of generalized miliary TB.<sup>172,173</sup> Less often (approximately 20%), hepatic TB manifests as a localized mass lesion that mimics a neoplasm, causes obstructive jaundice from extrinsic compression of the hepatic duct, or causes portal hypertension from compression of the portal vein.<sup>170,174</sup> Localized hepatic involvement can occur in primary infection, in which case there is no evidence of antecedent infection, or as reactivation TB.<sup>175</sup> Tuberculous cholangitis, in which the bacillus primarily infects the biliary tree, is extremely rare.<sup>176</sup> Hepatic TB is common among HIV-positive individuals: it was identified in 26% of untreated HIV-positive patients undergoing liver biopsy in one series from Brazil<sup>177</sup> and may be found in the liver at autopsy in approximately a third of HIV-positive patients.<sup>171</sup> HIV-positive patients tend to have more severe manifestations of hepatic TB.

The most common presenting symptoms of hepatic TB are hepatomegaly, fever, respiratory symptoms, abdominal pain, and weight loss; splenomegaly, ascites, and jaundice may also be seen but are less common.<sup>171</sup> Diffuse abdominal pain is more common in localized hepatic TB, whereas respiratory symptoms (such as cough with or without sputum production) are more common in miliary hepatic TB. The relatively nonspecific presentation makes the diagnosis difficult in the absence of a high index of suspicion. Alkaline phosphatase elevations and hyponatremia usually are prominent features.<sup>175,178,179</sup> An inverted albumin to globulin ratio (*A/G*), in which serum globulin is 1.25 to 1.86 times higher than serum albumin, is common.<sup>171</sup> In 65% to 78% of patients with hepatic TB, respiratory symptoms or chest radiographs suggest pulmonary TB as well.<sup>170,175,178,179</sup> Abdominal computed tomography imaging shows multiple hypodense micronodules throughout the liver or hepatomegaly without nodules, whereas in localized TB it shows one large solitary nodule or 2 to 3 hypodense nodules.<sup>171</sup> Liver calcifications are seen in approximately half of patients.<sup>170,173,180,181</sup> Presentation with acute liver failure is rare but has been reported.<sup>182</sup>

Liver biopsy with mycobacterial culture is considered the most specific diagnostic test for hepatic TB. Caseating granulomas are a hallmark of hepatic TB (seen in 51% to 83% of cases), particularly miliary TB in the setting of primary infection; in reactivation TB, noncaseating granulomas may be present instead (Fig. 11.15).<sup>171</sup> The granulomas may reside in the lobules or in portal tracts; the former location may be more common in miliary TB, whereas the latter may be more common in localized TB.<sup>171</sup> In TB-endemic countries, such as Iran, India, and Saudi Arabia, TB

is the most common cause of hepatic granulomas (accounting for approximately 50%), as opposed to non-TB-endemic countries where histoplasmosis, sarcoidosis, or PBC are more common etiologies.<sup>171</sup> Sinusoidal congestion and peliosis hepatis may also be seen.<sup>183</sup> Acid-fast bacilli (AFB) smears are positive in 0% to 59% of cases (median 25%), and organisms are more likely to be found with caseating necrosis, but smears may be positive due to infection from nontuberculous mycobacteria.<sup>171,175,176,178</sup> Cultures provide the strongest evidence of hepatic TB, but the sensitivity may be less than 10%. Histologic evidence of caseating granulomas has a median sensitivity of 68% (range: 14% to 100%) and is generally sufficient to establish the diagnosis in TB-endemic areas.<sup>171</sup> PCR for *M. tuberculosis* DNA has a 53% to 88% sensitivity and a 96% to 100% specificity for detecting hepatic TB.<sup>170,184,185</sup> Immunocompromised patients may present with a wasting syndrome in which multiple organs, including the liver, contain necrotic miliary nodules surrounded by histiocytes that do not aggregate into well-formed granulomas. AFB stain shows numerous organisms in these lesions.<sup>186</sup> Prompt initiation of four-drug anti-TB therapy should lead to clinical improvement in most patients with hepatic TB.

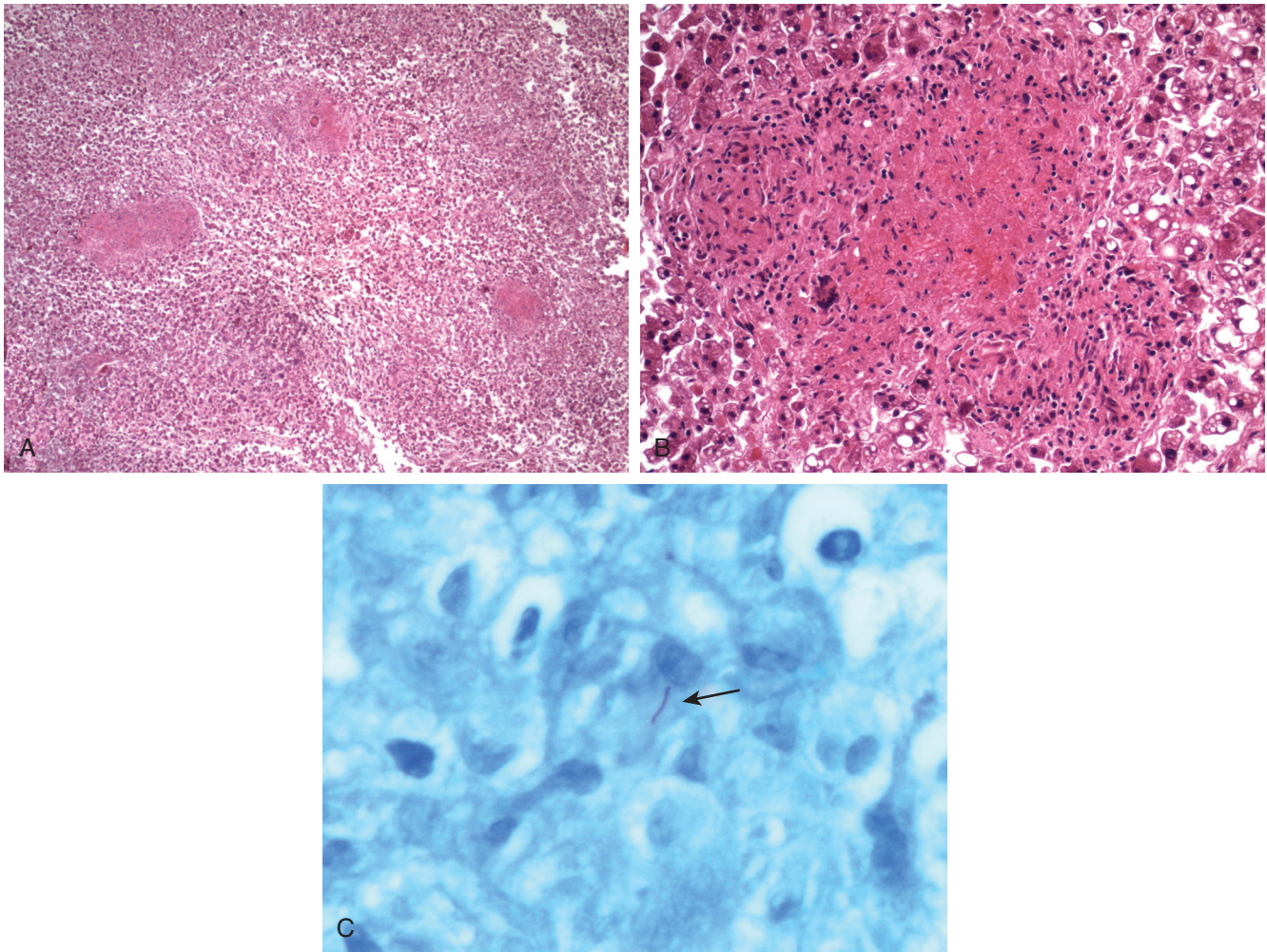
Localized hepatic TB includes tuberculoma and tuberculous abscess. Radiologically, it mimics tumors except that calcification may be prominent and may assume a bull's-eye configuration.<sup>174,187-189</sup> The diagnosis in these cases is more elusive because liver biopsy, unlike in the setting of diffuse hepatic involvement, often shows nonspecific findings. Combined with the clinical and radiologic suspicion of malignancy, this may lead to surgical resection of localized hepatic TB.<sup>190,191</sup> Grossly, localized hepatic TB appears as cheesy or chalky white, irregular nodules. Histologically, tuberculomas are composed of confluent granulomas, contain few organisms, and are encountered in immunocompetent patients, whereas tuberculous abscesses are centrally suppurative, contain numerous organisms, and are encountered mainly in immunodeficient patients.

Biliary involvement manifests as obstructive jaundice, which might have as its cause compression of the bile duct by a hepatic tuberculoma, small duct involvement by granulomas, or isolated biliary tree involvement.<sup>173</sup> The latter may result in bile duct strictures that can be mistaken for cholangiocarcinoma or PSC.<sup>173,180,192</sup> Biliary involvement mimicking cholangiocarcinoma has also been reported with the atypical *Mycobacterium abscessus*.<sup>193</sup>

In HIV patients initiating HAART, coinfection with TB may precipitate an inflammatory reaction to TB antigens known as the immune reconstitution inflammatory syndrome (IRIS). IRIS is characterized clinically by hepatomegaly, abdominal pain, elevated liver enzymes, jaundice, and constitutional symptoms, such as fever. The syndrome, which generally occurs within 8 weeks of initiation of HAART, may be difficult to distinguish from drug-induced liver injury. Liver biopsy shows necrotizing and non-necrotizing granulomas, but the granulomas may exhibit a more "inflamed" or "activated" appearance than is typical in TB (with numerous admixed neutrophils, lymphocytes, and plasma cells).<sup>194</sup>

### *Mycobacterium avium-intracellulare* Complex

Of the atypical mycobacteria, *M. avium* and *M. intracellulare* are significant hepatic pathogens. MAC is commonly encountered in immunocompromised patients, particularly those with AIDS. These organisms cause disseminated infection that commonly affects lung, liver, spleen, lymph nodes, and bone marrow. Patients with hepatic involvement present with fever, elevated alkaline



• **Figure 11.15** Miliary tuberculosis involving the liver. **A**, Low-power view shows several necrotizing granulomas. **B**, High-power view of a necrotizing granuloma. Note the central region of necrosis surrounded by histiocytes and a giant cell. **C**, An acid-fast stain highlights a single bacillus (*arrow*) within the granuloma.

phosphatase, and hepatomegaly.<sup>195</sup> The histopathologic findings range from numerous well-formed, nonnecrotizing granulomas with rare acid-fast organisms on Ziehl-Neelsen stain to less well-formed granulomas with large numbers of acid-fast organisms spilling out of the loose granulomas into nearby Kupffer cells (Fig. 11.16).<sup>186,196</sup> Although the latter pattern differs from the usual case of hepatic TB, the degree of immune compromise, rather than the species of mycobacteria, may be the more important factor in determining the number of organisms and type of granulomas seen, because T-cell function is required for the formation of well-formed granulomas, and hepatic TB in patients with AIDS also may show large numbers of organisms and few well-formed granulomas.<sup>186,195</sup> Granulomas in hepatic MAC may exhibit a portal or periportal distribution.<sup>197</sup> IRIS in HIV patients has been described with hepatic MAC.<sup>198</sup>

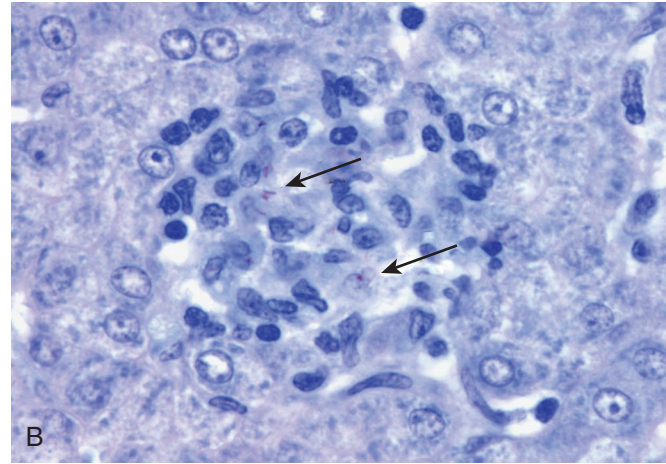
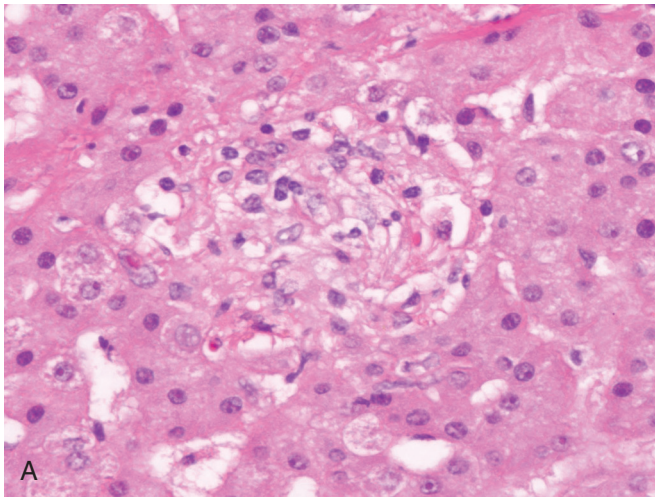
### Leprosy

Infection by *Mycobacterium leprae* commonly involves the liver, although clinical manifestations are often mild or absent. Hepatic granulomas are found in 90% of patients with lepromatous leprosy but in fewer than 20% of patients with tuberculoid

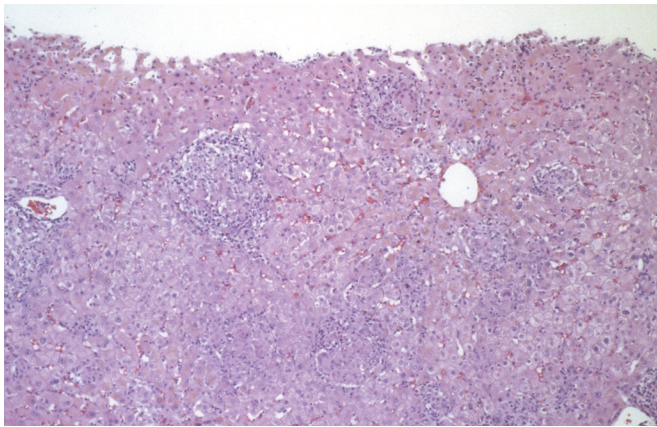
leprosy.<sup>199</sup> The appearance of the granulomas depends on the type of leprosy. In lepromatous leprosy, collections of foam cells within the lobules or portal tracts contain numerous AFB.<sup>199,200</sup> In tuberculoid leprosy, epithelioid granulomas with rare or no acid-fast organisms are seen (Fig. 11.17).<sup>199</sup> An individual patient may have both lepromatous and tuberculoid granulomas.

### Bacillus Calmette-Guérin

Bacillus Calmette-Guérin (BCG) is an attenuated form of *Mycobacterium bovis*, immunologically related to *M. tuberculosis*, that has been used as a vaccine against TB, as intralesional treatment of dermal malignancies, and as intravesical therapy for superficial bladder cancer. Hepatic granulomas have been described in patients after intradermal injections of BCG.<sup>201,202</sup> Pneumonitis or granulomatous hepatitis, or both, affect 0.7% of patients who receive multiple intravesical instillations of BCG and are more likely after traumatic catheterization, extensive tumor resection, or bladder perforation.<sup>203</sup> Rarely, acute hepatic failure with encephalopathy may develop.<sup>204</sup> The liver shows noncaseating epithelioid granulomas, epithelioid giant cells, mild steatosis, hepatocyte necrosis, and portal inflammation.<sup>205-207</sup> Often, AFB



• **Figure 11.16** *Mycobacterium avium-intracellulare* complex infection in an immunocompromised patient. **A**, The liver shows loose collections of histiocytes, suggestive of poorly formed granulomas. **B**, On acid-fast staining, several bacilli are present (arrows).



• **Figure 11.17** Liver biopsy sample from a patient with leprosy. Several noncaseating granulomas are present.

are not identified, and cultures are negative. This has led to the suggestion that the granulomatous hepatitis represents a hypersensitivity reaction to antigens present in the BCG preparation,<sup>201</sup> particularly because some cases show additional features of extra-hepatic granulomas, leukocytoclastic vasculitis, or bile duct injury and eosinophils (Fig. 11.18).<sup>208,209</sup> However, in some reported cases, AFB have been identified in the granulomas, blood cultures have been positive for *M. bovis*, or PCR for mycobacterial DNA has been positive, indicating disseminated BCG infection.<sup>209-212</sup> Some have suggested that two types of adverse reactions may occur, one a disseminated infection that responds to anti-TB therapy and the other a sterile hypersensitivity reaction that is delayed in appearance and responds to steroids.<sup>209</sup>

## Other Bacterial Infections of the Liver and Bile Duct

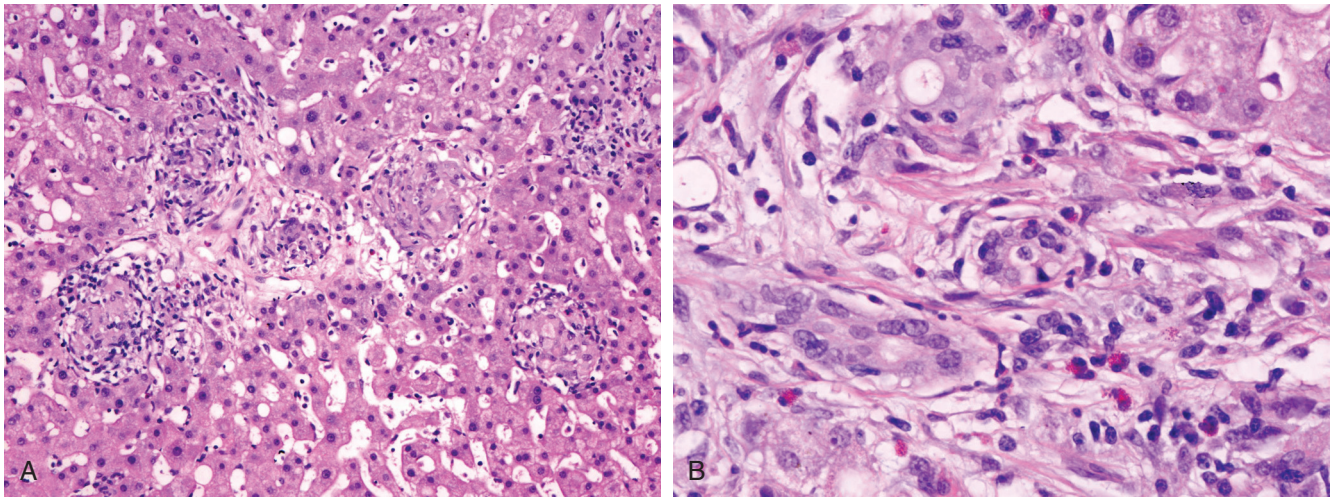
Bacterial infections of the liver can produce a wide range of pathology, including hepatitis, parenchymal necrosis, microabscesses, pyogenic liver abscess, and granulomatous hepatitis. Mixed patterns are frequent, and many organisms can produce

### • BOX 11.1 Infections Associated With Granulomatous Inflammation in the Liver

<i>Viral</i>	<i>Spirochetal</i>
HCV	Syphilis
CMV	Lyme disease
EBV	<i>Fungal</i>
<i>Mycobacterial</i>	Aspergillosis
TB	Blastomycosis
Leprosy	Candidiasis
Atypical tuberculosis	Coccidioidomycosis
<i>Bacterial</i>	Cryptococcosis
Brucellosis	Histoplasmosis
Cat-scratch disease	Mucormycosis
Enteric fever; typhoid fever	Paracoccidioidomycosis
Listeriosis	<i>Pneumocystis</i>
Melioidosis	<i>Helminthic</i>
Tularemia	Ascariasis
Whipple disease <sup>213</sup>	Capillariasis
<i>Pasteurella multocida</i> <sup>214</sup>	Fascioliasis
<i>Yersinia enterocolitica</i> <sup>215</sup>	Opisthorchiasis
Actinomycosis	Schistosomiasis
Nocardiosis	Strongyloidiasis
<i>Rickettsial</i>	Visceral larva migrans
Q fever	<i>Protozoal</i>
<i>Chlamydial</i>	Leishmaniasis
<i>Lymphogranuloma venereum</i>	Toxoplasmosis
Psittacosis	

CMV, Cytomegalovirus; EBV, Epstein-Barr virus; HCV, hepatitis C virus; TB, tuberculosis.

several patterns. Microabscesses or pyogenic liver abscesses can be caused by a multitude of aerobic and anaerobic organisms, fungi, and parasites. Granulomatous hepatitis with or without a necrotizing component can be seen in a number of infections (Box 11.1).<sup>213-215</sup> However, in some entities the granulomas are not true epithelioid granulomas but rather aggregates of histiocytes in foci of parenchymal necrosis. Because these “microgranulomas” do not generate the same differential diagnosis as true epithelioid



• **Figure 11.18** Liver biopsy in a patient with bacillus Calmette-Guérin infection. **A**, Several small granulomas are present in this view. **B**, In some portal tracts, bile duct injury and scattered eosinophils are present, suggesting a hypersensitivity reaction.

granulomas, the diagnosis of “granulomatous hepatitis” in these cases is best avoided. Biliary involvement can produce acute cholangitis or cholecystitis.

### Pyogenic Liver Abscess

Historically, pyogenic liver abscess was associated with acute appendicitis or intra-abdominal infection, and in those settings it was seen more often in children.<sup>216</sup> More recently, biliary disease has emerged as a common etiology, and with that shift, the age of the patients has also increased, to 55 to 60 years of age.<sup>217-219</sup> Diabetes mellitus is a strong risk factor for the development of pyogenic liver abscess.<sup>219,220</sup> Other frequent comorbidities are malignancy, alcohol abuse, cirrhosis, hypertension, recent surgery, and immunosuppression.<sup>217,218,221</sup> A significant minority of cases remain cryptogenic. Although the disease carries a high mortality, improved diagnosis, abscess drainage, and antibiotic therapy have reduced the mortality rate to 5% to 31%.<sup>217,221</sup> Patients typically present with fever, chills, right upper quadrant pain, and elevated alkaline phosphatase.<sup>217,218</sup> Men are affected more often than women in most series.<sup>217-219</sup> Most abscesses are solitary; multiple abscesses occur in 25% to 45% of cases.<sup>217-219,221</sup> Most abscesses are right sided (55% to 70%), with left-sided and bilateral disease occurring less often.<sup>216,217,219</sup> Liver abscesses are rare in neonates but may be seen in the setting of sepsis, particularly if there is a history of umbilical catheterization.<sup>222</sup>

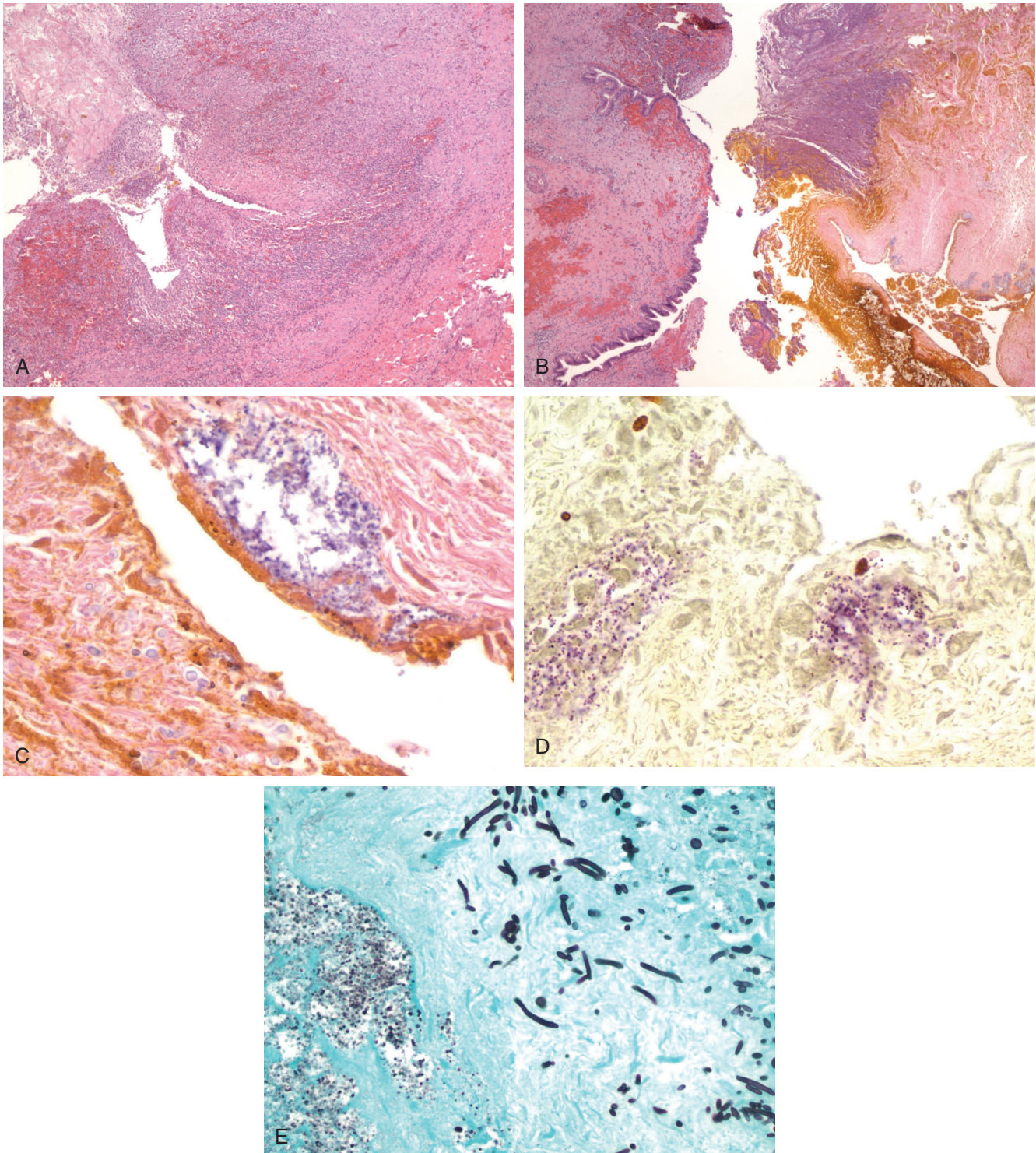
Culture of aspirated purulent material from the abscess or of blood may yield the offending organisms, although both of these are occasionally negative. Sometimes blood culture results do not correlate with pus culture results; therefore blood culture alone is not sufficient to determine the etiology.<sup>217</sup> Depending on the organism, serology may be useful. The most commonly isolated organisms are *Escherichia coli*, *Klebsiella pneumoniae*, *Enterococcus*, *Streptococcus*, and *Pseudomonas* spp.<sup>217,219,221</sup> A third of infections are polymicrobial (Fig. 11.19). Organisms that produce formic hydrogenylase, such as *Klebsiella* spp. and *E. coli*, can convert acids that accumulate within the abscess to carbon dioxide and hydrogen gas; infection with these organisms can result in gas-forming pyogenic abscess, which carries a higher risk of septic shock, bacteremia, and mortality.<sup>223</sup> The incidence of *K. pneumoniae*

abscesses has increased in recent years, and this organism is now the leading cause of pyogenic liver abscesses in Asia. *K. pneumoniae* abscess may be suspected on the basis of the following features on abdominal CT: a thin abscess wall, presence of necrotic debris within the abscess cavity, presence of metastatic infection, and absence of underlying biliary disease.<sup>224</sup> Abscesses secondary to *Yersinia enterocolitica* or *Yersinia pseudotuberculosis* are often associated with underlying hemochromatosis.<sup>225-228</sup> Anaerobes are isolated in up to 25% of cases, sometimes together with aerobes.<sup>218,229,230</sup> Microaerophilic streptococci, *Bacteroides fragilis*, *Fusobacterium necrophorum*, and *Clostridium* spp. are the most commonly implicated anaerobes. *Actinomyces* spp. are infrequently found by either anaerobic culture of aspirated pus or identification of filamentous bacteria and sulfur granules on histologic examination of resection material (Fig. 11.20); these organisms may be associated with the formation of sinus tracts.<sup>231-234</sup> Rarely, *Francisella tularensis*,<sup>235</sup> *Burkholderia pseudomallei* (the agent of melioidosis),<sup>236,237</sup> or *Listeria monocytogenes*<sup>238</sup> causes liver abscesses. Fungi, such as *Candida* and *Aspergillus*, are found in approximately 15% of cases.<sup>229,239</sup>

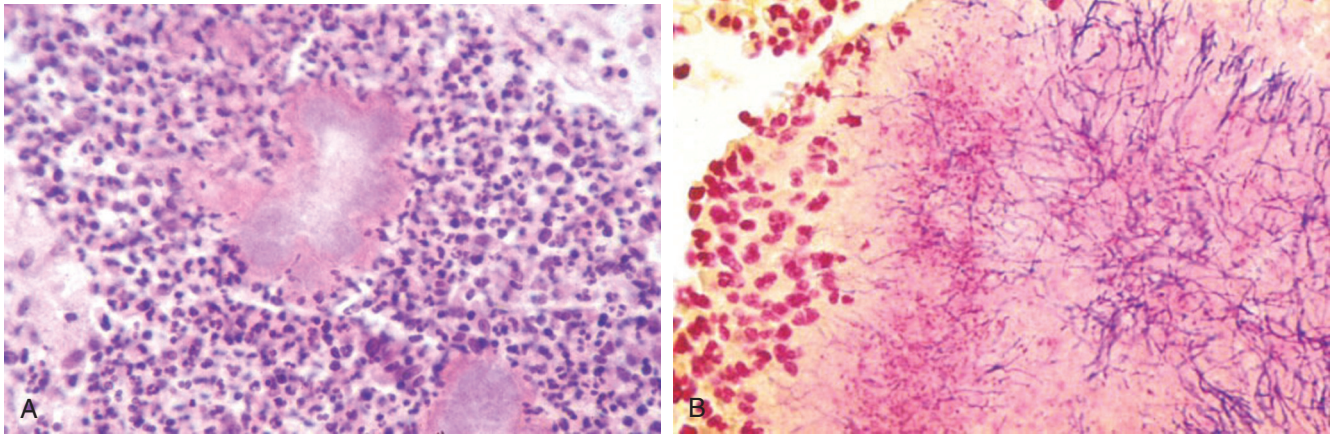
Complications of pyogenic liver abscess include metastatic infections, such as endophthalmitis, meningitis, osteomyelitis, pyelonephritis, and pneumonia. The two main risk factors for metastatic infection are infection with *K. pneumoniae* and underlying diabetes mellitus.<sup>221,240,241</sup> Although surgical management was once the mainstay of therapy, percutaneous drainage and antibiotics have become the first line approach.<sup>217</sup>

### Acute Cholangitis

The term *acute cholangitis* refers to an infection of the bile ducts characterized by jaundice, abdominal pain, and sepsis, in combination with biliary obstruction. Bacterial colonization of the biliary tree in the absence of obstruction produces no symptoms; conversely, sterile obstruction of the bile duct produces a picture of aseptic obstructive jaundice.<sup>242</sup> The route by which bacteria colonize the bile ducts is uncertain. Possible sources include reflux of intestinal contents through the choledochal sphincter; passage from an infected gallbladder; and lymphatic, hepatic arterial, or portal venous bacteremia.<sup>242</sup> Obstruction is most often due to



• **Figure 11.19** Hepatic abscesses arising from polymicrobial cholangitis with *Enterococcus* and *Candida* in a liver transplant recipient. **A**, The abscess contains a center of necrotic debris, fibrin, and neutrophils surrounded by granulation tissue and inflammation, with a fibrotic rim. **B**, In some areas, residual bile duct epithelium at the abscess edge betrays origin from cholangitis. **C**, Yeast forms (*lower left*) are present adjacent to bacterial cocci (*upper right*) in the bile duct lumen. **D**, Gram-positive cocci are revealed by Brown-Hopps stain. **E**, Yeast forms and pseudohyphae consistent with *Candida* (*upper right*) and bacterial cocci (*lower left*) are present (Gomori methenamine silver stain).



• **Figure 11.20** *Actinomyces*. **A**, Sulfur granule with aggregate of filamentous bacteria and neutrophils. **B**, Brown-Hopps stain shows gram-positive filamentous bacteria in the sulfur granule. (Courtesy Dr. Laura Lamps.)

gallstones. Other causes include strictures, malignancy, and congenital anomalies of the ampulla of Vater. How bactibilia and obstruction leads to biliary septicemia is uncertain. Cholangiovenous reflux with increased intrabiliary pressure can be demonstrated using contrast, and higher biliary pressures are associated with an increased incidence of purulent bile, sepsis, and bacteremia.<sup>242</sup>

Manifestations of acute cholangitis range from mild, recurrent illness to overwhelming sepsis. Most patients are middle aged, and men and women are affected equally. Fever and jaundice are the most common symptoms. In 1877 Charcot proposed a clinical triad: right upper quadrant abdominal pain, fever, and jaundice.<sup>243</sup> Approximately 70% of patients present with the full triad. Reynolds arrived at a pentad in 1959 by adding hypotension and delirium.<sup>244</sup> Although rare, the pentad describes patients with high mortality risk.<sup>245</sup> Alkaline phosphatase and bilirubin are elevated in most patients, but blood cultures are positive in fewer than half of patients.

The bacteria that infect the biliary tree usually derive from the gut. The bacteria most commonly isolated from bile are *E. coli*, *Enterococcus*, *Klebsiella*, *Proteus*, *Pseudomonas*, and *Enterobacter*.<sup>242,246</sup> Improved culture techniques have shown a significant incidence of infection by anaerobes, such as *B. fragilis* and clostridial species, frequently in association with previous biliary-intestinal anastomosis, an older adult patient, and more severe illness.<sup>242,247</sup> Overall, 56% of cases are polymicrobial. Mycotic infection of the bile duct, principally by *Candida albicans*, is rare and affects older patients, patients with malignancy, immunosuppressed patients, and diabetics.<sup>242</sup>

The histology of acute cholangitis is similar to that of large duct obstruction, with portal edema, neutrophilic portal and periductal inflammation, and neutrophils within duct epithelium.<sup>248,249</sup> Ductular reaction and canalicular and ductular cholestasis may also be seen.<sup>250</sup> In some cases, neutrophils accumulate within the duct lumina; although this is suggestive of infection, the association is not sufficiently reliable to be predictive.<sup>248,249</sup> Microabscesses and macroscopic abscesses may be seen. Thrombophlebitis may result in portal vein thrombi.<sup>249</sup> Patients suffering from shock may show necrosis of the liver.<sup>249</sup> Chronic changes include strictures, dilatations, portal fibrosis, and potentially ductopenia. Histologic findings frequently do not correlate with clinical status, in that most cases of acute cholangitis show

relatively minor histologic changes, and patients with mild symptoms can have frank abscesses.<sup>249</sup> Histology is also not predictive of survival.<sup>245</sup> Therefore clinical and microbiologic correlation is frequently required to make the diagnosis of acute bacterial cholangitis.

Most patients respond well to antibiotics. The efficacy of a specific antibiotic depends on its biliary secretion, which is affected by the size of the compound. The inflammatory process also can cause impairment of secretion. Treatment of the obstruction is necessary to prevent recurrence. Some patients require emergent biliary drainage in addition to antibiotics, and there may be a survival advantage to surgical management of the obstruction.<sup>245</sup> Complications of acute cholangitis include renal failure and the development of hepatic abscesses.<sup>242</sup>

### Recurrent Pyogenic Cholangitis (Oriental Cholangiohepatitis)

Recurrent pyogenic cholangitis is a disease that historically was seen largely in the Far East but is reported in increasing numbers in the West, largely among Asian immigrants. The disease is characterized by abdominal pain, fever, chills, and jaundice, resulting from recurrent attacks of suppurative cholangitis associated with intrahepatic biliary stones.<sup>251</sup> The cause is not fully known, but bacterial infection of the biliary tree is perhaps the inciting event. Enteric organisms, particularly *E. coli*, are cultured from bile in most cases.<sup>251</sup> Bacteria deconjugate bilirubin glucuronide, which then precipitates with calcium in the bile as soft, brown, friable calcium bilirubinate stones.<sup>251,252</sup> Exactly what predisposes patients to biliary tract infection is unknown, but the geographic distribution of this disease mirrors that of *Clonorchis sinensis* and *Ascaris lumbricoides*, and biliary parasites are detected in a significant minority of patients.<sup>251</sup> Dead flukes and ova within the bile ducts, accompanied by bile stasis, may lead to bacterial infection. However, large numbers of people in endemic areas are infested with liver flukes without recurrent pyogenic cholangitis. In any case, the recurrent cholangitis results in intense periductal inflammation and fibrosis, strictures, and dilated ducts filled with sludge, predominantly affecting the left lobe.<sup>252</sup>

Morphologically, large ducts show chronic and acute cholangitis, fibrosis, and peribiliary gland hyperplasia (“chronic proliferative cholangitis”). Pigmented stones and pus are seen in ducts;

liver abscesses may be present.<sup>251</sup> During acute infection, there is acute cholangitis with portal edema, erosion/ulceration of large ducts, and thrombophlebitis of portal vein branches.<sup>253</sup> Bile ductular proliferation with cholangiolitis and periductal fibrosis develops in small interlobular portal tracts. Small portal vein branches are reduced in number and may show fibrous obliteration.<sup>253</sup> Atrophy of liver parenchyma may also be seen. Biliary dysplasia and cholangiocarcinoma are complications and were seen in 13% and 23% of patients undergoing hepatic resection in one study, respectively.<sup>254</sup>

The changes in small interlobular tracts may lead to consideration of PSC, particularly in the West; however, ductopenia in recurrent pyogenic cholangitis is not as significant as PSC, and ductular reaction is only rarely observed.<sup>253</sup> In addition, chronic cholestatic changes (such as copper deposition in periportal hepatocytes) are typically not seen, and progression to biliary cirrhosis is rare. These differences, as well as the different clinical presentations and epidemiologic associations, should allow distinction of recurrent pyogenic cholangitis from PSC and other biliary diseases in which secondary stone formation may occur.<sup>253</sup>

## Brucellosis

Brucellosis is the most common zoonotic disease in the world, with 500,000 cases per year, and is particularly common in the Mediterranean basin, the Middle East, India, and Central and South America. It largely affects handlers of livestock, particularly those in the meatpacking industry, due to direct contact with animals and animal parts. It may also be acquired by ingestion of unpasteurized dairy products or infected meat, or by occupational exposure in veterinarians and clinical laboratory workers. The organism escapes destruction by replicating intracellularly within phagocytic cells, and thus involvement of the liver is common given its large population of reticuloendothelial cells. Although mildly elevated transaminases or hepatomegaly are seen in almost all patients, a true hepatitis (defined as a five-fold or greater increase in transaminases) is seen in approximately 25% of cases.<sup>255</sup> A cholestatic presentation may also be seen. *Brucella melitensis* accounts for most cases of hepatic involvement, whereas *Brucella abortus* and *Brucella suis* are seen in a minority of cases. Most (approximately 90%) patients present with an acute illness (0 to 2 months in duration) characterized by malaise, fever, chills, sweats, arthralgia, weight loss, and headache, but some patients become symptomatic after many years of dormancy or are episodically symptomatic.<sup>255-257</sup> Fever in brucellosis patients can be intermittent and has been described as “undulant fever.” Subacute and chronic presentations are less common but do occur.

The characteristic histopathologic pattern of hepatic brucellosis is a granulomatous hepatitis.<sup>258-260</sup> In a series of 14 patients with brucellosis, all had hepatic granulomas in both portal tracts and lobules<sup>261</sup>; in another, 28 of 40 patients (70%) had granulomas.<sup>258</sup> However, in a prospective study in which patients presenting with acute brucellosis underwent liver biopsy, the most common finding (15 of 20 cases, 75%) was a nonspecific hepatitis characterized by portal and/or lobular mononuclear inflammation. Of these cases, only four (20%) also showed granulomas.<sup>262</sup> The remainder of the cases showed mixed inflammation (one case, 5%) or no significant inflammation (four cases, 20%). Thus granulomas may correlate with more severe liver disease because in other studies liver biopsies were usually done because of biochemical evidence of liver dysfunction. Granulomas in brucellosis may be indistinguishable from TB or sarcoidosis, and brucellosis

should be considered in any patient with hepatic granulomas.<sup>260</sup> Some authors consider granulomas in brucellosis to be smaller and less clearly defined than in TB, sarcoidosis, or histoplasmosis<sup>258</sup>; the term “microgranuloma” has also been used to describe them.<sup>262</sup> The presence of granulomas does not reliably distinguish among the various species of *Brucella*,<sup>263-266</sup> despite a report that *B. melitensis* is not associated with granulomas.<sup>267</sup> Other findings may include nonspecific acute hepatitis with hepatocyte necrosis, portal inflammation, and Kupffer cell hyperplasia.<sup>256-258,261,266</sup> Liver involvement by brucellosis generally follows a benign course, and a full recovery in greater than 95% patients is expected after treatment with doxycycline in combination with an aminoglycoside and/or rifampin.<sup>256</sup> Relapse of chronic brucellosis may be precipitated by viral illness or trauma.<sup>257</sup>

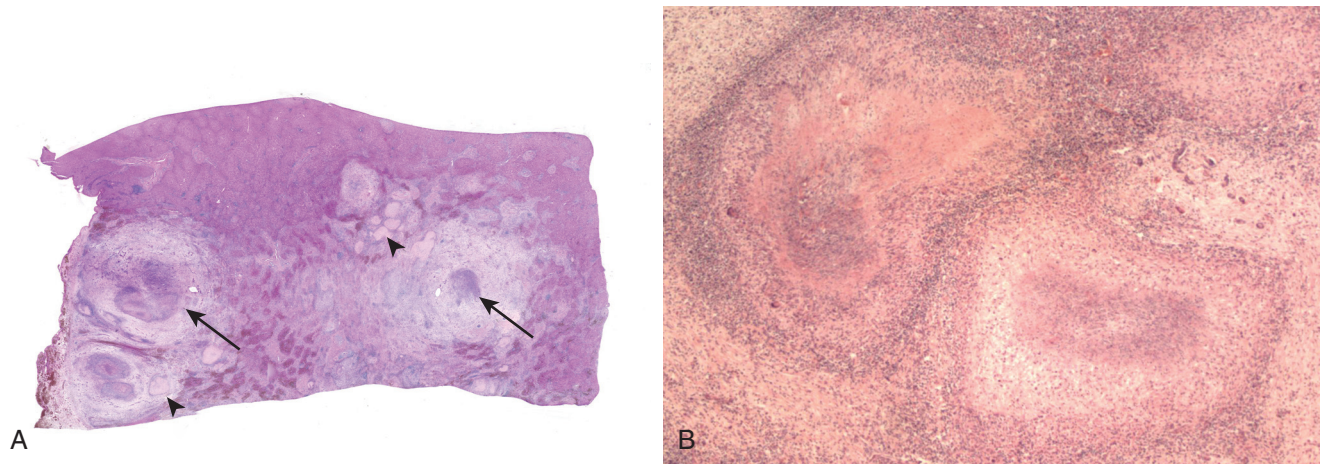
The diagnosis is established by rose bengal test or *Brucella* agglutination titer (Wright serum agglutination test or standard tube agglutination [STA]), which are positive in greater than 90% of cases.<sup>255,256</sup> Indirect Coombs test is almost invariably positive and may be used to make the diagnosis in patients with negative STA tests. Culturing the organism from blood, body fluids, or tissue is difficult; cultures are positive in only approximately 40% of patients, although the yield has increased in recent years due to improvements in technique. PCR testing for *Brucella* spp. DNA may also be performed.

Rarely, patients present with hepatosplenic abscesses or mass-like lesions (brucelloma) mimicking a tumor.<sup>257,268,269</sup> In one series of 15 patients with brucelloma in the liver or spleen, half had suffered from brucellosis many years before, suggesting reactivation of latent disease.<sup>270</sup> Radiologically, brucellomas have central calcification with peripheral necrotic areas.<sup>257,268-272</sup> Two general presentations of hepatosplenic *Brucella* abscesses are seen. The most common is a solitary liver abscess, often large and located in the right lobe, with a central calcification, which occurs only in adults and should immediately prompt suspicion of brucellosis in an endemic setting. A less common presentation is multiple small abscesses in the liver and spleen, known as “miliary” pattern, which occurs in children and adults and mimics disseminated TB.<sup>268</sup> Histologically, a brucelloma shows necrotic areas surrounded by a palisaded granulomatous reaction.<sup>269,270</sup> Some cases may show only fibrosis with dense chronic inflammation.<sup>272</sup> Organisms are isolated from cultures of abscess material in only 18% of cases. When an organism is identified in patients with liver abscesses (combining cultures of blood and abscess material), the majority (80%) are due to *B. melitensis*, and the remainder are due to *B. abortus* (12%) and *B. suis* (8%).<sup>268</sup> In addition to antibiotics, management of brucellomas requires surgery in approximately half of cases, and resolution of the lesions is expected in the overwhelming majority of cases.

## Bartonella Infection (Cat-Scratch Disease)

Cat-scratch disease is a self-limited infection caused by infection with *Bartonella* spp. after inoculation by a cat, which usually manifests as a local skin reaction and lymphadenopathy. Most cases are attributed to *B. henselae*, but *B. quintana* has been implicated in some.<sup>273</sup> Approximately 1% to 2% of patients with *Bartonella* infection develop severe systemic disease with involvement of the liver, spleen, bone, central nervous system, or lung.<sup>274</sup> Most patients with hepatosplenic presentation are children 5 to 10 years of age.<sup>273,275,276</sup> Patients often have nonspecific symptoms, including fever, abdominal pain, chills, headache, malaise, and weight loss. Approximately 25% of patients have





• **Figure 11.21** Cat-scratch disease involving the liver. **A**, Low-power view of a section of liver shows multiple stellate abscesses (arrows) and several older, hyalinized scars (arrowheads). **B**, Medium-power view of stellate abscesses shows central necrosis surrounded by palisaded histiocytes, chronic inflammation, and fibrotic tissue.

lymphadenopathy, but often the classic skin papule of cat-scratch disease is absent.<sup>273-275</sup> Hepatic lesions are typically multiple and associated with abdominal lymphadenopathy and, in some cases, splenic lesions; many patients come to biopsy to exclude neoplasia.<sup>274,276,277</sup> On laparotomy, the liver may be found to be studded with hard nodules of varying sizes.<sup>277</sup>

The hallmark lesion in hepatic cat-scratch disease is an irregular, stellate microabscess surrounded by a layer of palisading histiocytes, lymphocytes, and a rim of fibrous tissue (Fig. 11.21).<sup>274,277,278</sup> Younger lesions may show more necrosis with less organization of the inflammatory granulomatous response, whereas older lesions may show confluent granulomas with scarring and scant residual necrosis.<sup>274</sup> These hepatic lesions are similar to the ones seen in lymph nodes in patients with cat-scratch disease, but they have also been noted in infections with *Y. enterocolitica*, *E. tularensis*, lymphogranuloma venereum, mycobacterial species, *Candida*, and *Actinomyces*.<sup>274</sup> Other lesions may appear as small, rounded granulomas with giant cells and small foci of central necrosis, similar to caseating granulomas in mycobacterial or fungal infections. The background liver parenchyma shows sinusoidal dilatation, portal mixed but predominantly lymphocytic inflammatory infiltrates, portal fibrosis, periductal concentric fibrosis, and focal bile ductular proliferation.<sup>274</sup> These changes are attributed to mass effect and are also seen in other infections that result in space-occupying lesions, such as pyogenic abscesses.<sup>274</sup>

Warthin-Starry stains identify bacilli in some cases, and the organisms often cluster around vessels or along collagen fibers; the stain is not specific for the organism.<sup>275</sup> Culture is difficult. The diagnosis can be confirmed by PCR and Southern blot for *Bartonella* DNA on tissue, skin testing, or serology.<sup>273,274,278,279</sup> The disease is self-limited without long-term hepatic dysfunction. The infection responds dramatically to rifampin, erythromycin, or doxycycline, but antibiotics are unnecessary in most cases.

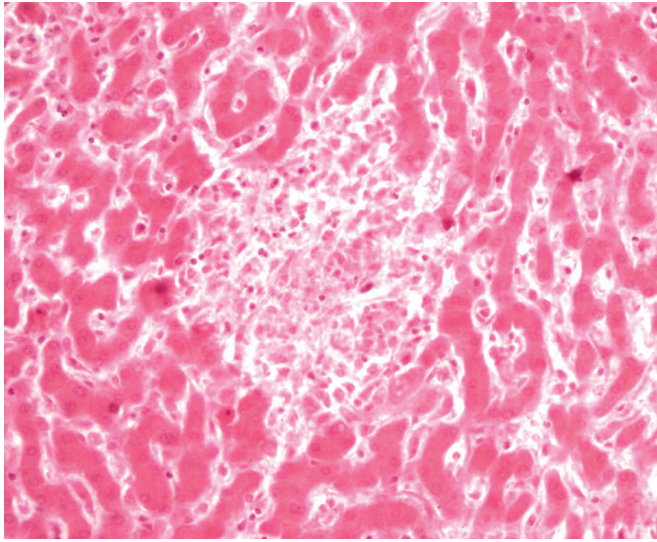
*Bartonella* also may cause vascular proliferative lesions in the liver. Bacillary epithelioid angiomatosis is a vasoproliferative tissue reaction to *B. henselae* or *B. quintana* that usually occurs in immunocompromised hosts. Hepatic involvement shows sharply demarcated periportal areas in which the normal parenchyma is replaced by vascular tissue with extravasated erythrocytes, delicate spindle cells, neutrophils, and karyorrhexic debris, mimicking

Kaposi sarcoma.<sup>142</sup> Similar lesions have been designated as bacillary peliosis hepatitis; these are characterized by the presence of multiple blood-filled cystic spaces, foci of necrosis, fibromyxoid stroma, and clumps of granular purple material that correspond to organisms on Warthin-Starry stain and electron microscopy.<sup>142</sup> The latter lesions can be mistaken for nonbacillary peliosis hepatitis. Although these infections can be progressive and fatal, they respond to antibiotics.

### Enteric Fever (Typhoid and Paratyphoid Fever)

Enteric fever (the inclusive term for typhoid and paratyphoid fever) is caused by infection with *Salmonella enterica* serotype Typhi (*Salmonella typhi*) or serotype Paratyphi (*Salmonella paratyphi*). The disease is transmitted via the fecal-oral route from food or water contaminated by an acutely ill person or a chronic carrier.<sup>280</sup> Human beings are the only known reservoir. Most infections nowadays occur in countries where sanitary conditions are poor; the Indian subcontinent has a particularly high incidence.<sup>280</sup> Travelers to these areas can also be affected. Although *S. typhi* causes 80% of infections, *S. paratyphi* may be more important among travelers, possibly due to a vaccine effect that protects only against *S. typhi*.<sup>280</sup> In indigenous populations, enteric fever is a disease of young children and adolescents, whereas among travelers, the age of the patients reflects the age of travelers.<sup>280</sup>

Ingestion of the organism is followed by an asymptomatic period of approximately 7 days, during which the organism multiplies within mononuclear phagocytic cells in Peyer patches, mesenteric lymph nodes, liver, and spleen.<sup>281</sup> This is followed by a bacteremic phase, with fever, chills, headache, and rose spots. During this phase, invasion of the gallbladder occurs, either directly or from infected bile. Chronic biliary carriage occurs in 2% to 5% of cases, even after treatment, particularly among women, older adults, and patients with cholelithiasis.<sup>280,281</sup> In these cases, shedding of virus continues for more than a year and is a public health risk. The majority of patients experience minor degrees of hepatomegaly and elevated transaminases. However, the presentation can resemble acute viral hepatitis, with jaundice and very high transaminases or even fulminant hepatic failure, although coinfection with HAV or HEV may be responsible for



• **Figure 11.22** Typhoid nodule in typhoid fever. An aggregate of mononuclear cells, including histiocytes and lymphocytes, is present in the lobule. The surrounding liver shows prominent Kupffer cells in the sinusoids.

some of these cases.<sup>280</sup> Intestinal perforation, hemorrhage, and encephalopathy are the most important complications. The diagnosis is made by blood culture or Widal serology assay.

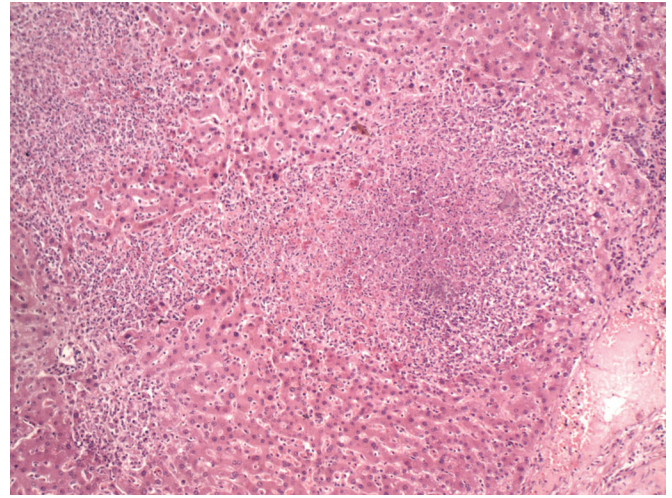
In the liver, hyperplasia of the reticuloendothelial system results in prominence of mononuclear cells in the sinusoids and typhoid nodules (Fig. 11.22).<sup>282,283</sup> Typhoid nodules are lobular collections of macrophages that ingest bacteria, erythrocytes, and degenerated lymphocytes.<sup>283</sup> These nodules may resemble granulomas but are not true epithelioid granulomas, although granulomatous hepatitis has also been described.<sup>284,285</sup> Abscesses are rare.<sup>286</sup>

## Tularemia

Tularemia is caused by the coccobacillus *F. tularensis*. The disease is most often transmitted to humans by ticks or by animal contact, especially with rabbits. Inhalation outbreaks have been associated with lawn mowing and brush cutting in contaminated areas.<sup>235</sup> Most patients have pulmonary involvement. Other features include fever, cutaneous ulcers, lymphadenopathy, headache, and malaise. Hepatic involvement occurs in up to 75% of patients and includes hepatosplenomegaly and mild to moderate elevations of transaminases.<sup>287</sup> Severe cases may show jaundice. Liver histology shows suppurative microabscesses and areas of necrosis (Fig. 11.23). As the lesions age, they become more granulomatous.<sup>288</sup> The diagnosis is often established serologically because the organism is difficult to culture and is rarely seen on tissue Gram stain. PCR assays for *F. tularensis* in fresh tissue and on formalin-fixed tissue have been described.<sup>235</sup>

## Melioidosis

Melioidosis is a glanderslike disease caused by *B. pseudomallei*, a gram-negative aerobic bacillus that survives within phagocytic cells. The organism is a soil saprophyte that prefers wet soils and is an important community-acquired pathogen in Southeast Asia and northern Australia, particularly during rainy seasons.<sup>237</sup>

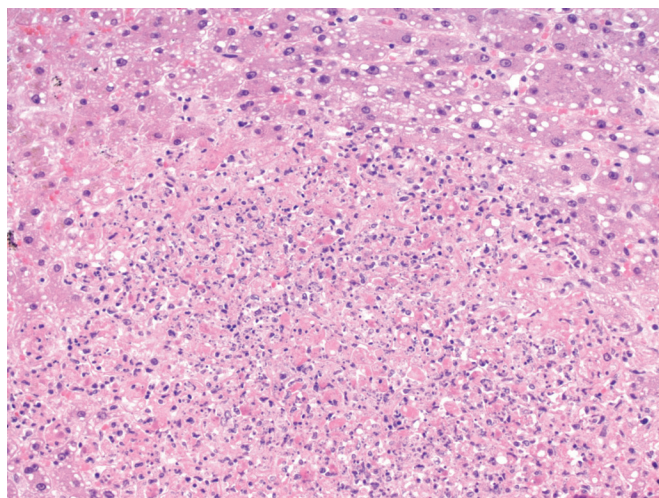


• **Figure 11.23** Tularemia involving the liver. Several small abscesses are present throughout the lobules.

Percutaneous inoculation and inhalation are modes of transmission. Travelers can be exposed when they come in contact with wet soil, such as during adventure tours.<sup>289</sup> Occasionally, patients have chronic disease or reactivation of a latent focus years after leaving an endemic area, a possibility that caused concern for veterans returning from Vietnam.<sup>289</sup> Predisposing factors include diabetes mellitus, renal disease, alcoholism, cirrhosis, and immunosuppression.<sup>236,237</sup> The acute form of the disease is characterized by abscess formation, predominantly in the lung, but seeding and abscess formation also occur in the liver, spleen, skeletal muscle, and lymph nodes; often, multiple sites are involved.<sup>236,237,290</sup> Large abscesses tend to be multiseptate and multiloculated, resulting in a “honeycomb” appearance on radiology.<sup>235</sup> Chronic melioidosis shows granulomatous inflammation with central irregular abscesses, indistinguishable from the stellate abscesses of cat-scratch disease, tularemia, or lymphogranuloma venereum.<sup>290</sup> The granulomas may show caseous-type necrosis, mimicking TB.<sup>290</sup> The lesions in chronic melioidosis are usually confined to a single organ. Serology is not completely reliable, but *B. pseudomallei* can be readily cultured from abscess material.<sup>236</sup> The organism can also be detected in Gram stains as a gram-negative bacillus with a characteristic “safety pin” appearance.

## Listeriosis

*L. monocytogenes* is a gram-positive, facultative intracellular bacillus that is an occasional contaminant of food, even despite proper refrigeration. Infection is associated with pregnancy, extremes of age, diabetes mellitus, and immunosuppression. Transplacental transmission causes granulomatosis infantisepticum, which is characterized by abscesses and granulomas in various fetal organs.<sup>291</sup> After ingestion, the organisms invade the Peyer patches and are transported to the liver, where they are cleared from the bloodstream by Kupffer cells. Some organisms escape from Kupffer cells and invade hepatocytes, where, protected from the host immune response, they replicate. Neutrophils are recruited to the area, forming abscesses, and after a few days, granulomas form in an attempt to impede further spread. After the organisms escape the granulomas and are released into the blood, they have a predilection for the central nervous system and placenta.<sup>291</sup>



• **Figure 11.24** Liver from a patient who died of systemic listeriosis, showing microabscess and steatosis in the surrounding hepatocytes.

Hepatic involvement can manifest as solitary liver abscess, multiple liver abscesses, or diffuse hepatitis (Fig. 11.24).<sup>238,291-293</sup> Solitary liver abscess is associated with diabetes mellitus, absence of bacteremia or extrahepatic manifestations, and a relatively good prognosis.<sup>238,291</sup> Multiple liver abscesses are more often associated with bacteremia, extrahepatic sites of involvement, and meningitis and carry a worse prognosis.<sup>238,291</sup> Diffuse hepatitis is associated with underlying conditions, such as viral hepatitis, pregnancy, or alcohol abuse,<sup>291,294</sup> although it may also occur in healthy individuals.<sup>295</sup> Bacteremia is highly likely in cases with diffuse hepatitis. The histology is that of an active hepatitis with extensive necro-inflammatory activity, or sometimes a granulomatous hepatitis.<sup>291,294</sup> Cholestasis and sinusoidal infiltration by mononuclear inflammatory cells may also be seen.<sup>296</sup> Diffuse hepatitis due to *Listeria* often mimics acute viral hepatitis clinically and pathologically (fever, jaundice, substantially elevated transaminases, active hepatitis on biopsy) and may lead to misdiagnosis and delayed treatment.<sup>293-297</sup> The diagnosis is made by culture of the organism from blood or abscess material.

## Spirochetes

### Syphilis

*Treponema pallidum* infection can affect the liver in secondary syphilis, in tertiary syphilis, or congenitally. Involvement by the liver in secondary syphilis has been reported in men and women. It is common in HIV-positive individuals. Among HIV-positive patients with syphilis, the rate of liver involvement (based on abnormal liver function tests [LFTs]) is between 19% and 38%.<sup>298-301</sup> However, others have argued that the true rate of syphilitic hepatitis in this patient population is substantially lower, given that many other etiologies may cause liver dysfunction in HIV-positive patients, including viral hepatitis, drug hepatotoxicity, and fatty liver disease.<sup>302</sup> Liver involvement by syphilis is also common among MSM,<sup>303-309</sup> possibly from portal transport of the organism after anal intercourse,<sup>309</sup> although this may be confounded by high rates of MSM among HIV-positive patients.<sup>299-304</sup> A characteristic clinical picture is cholestatic jaundice, hepatomegaly, and a disproportionately elevated alkaline phosphatase level.<sup>305,307,308,310-313</sup> The trademark palmar rash of syphilis may be the key to diagnosis.<sup>298,311,312</sup>

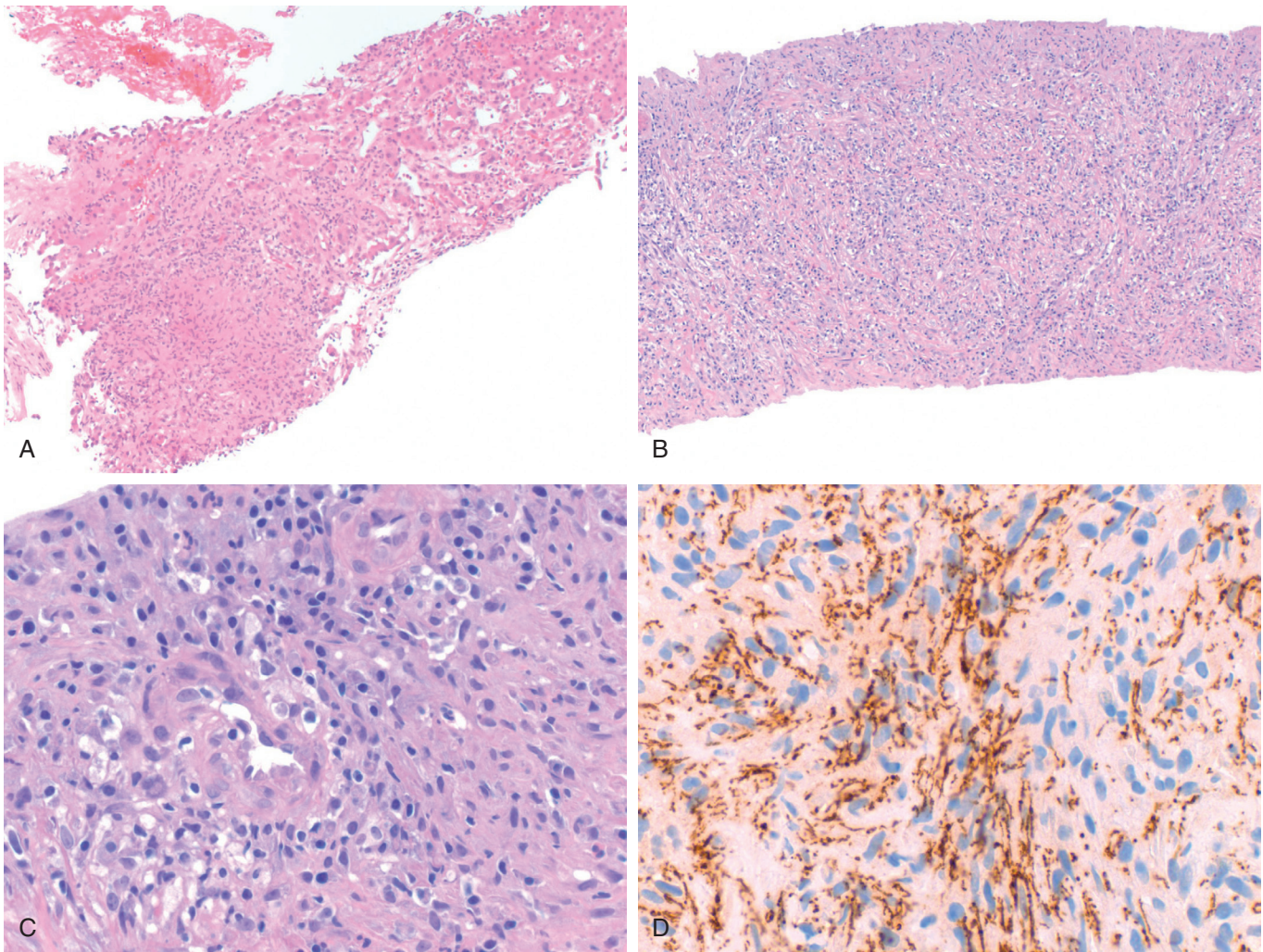
Histologic examination of liver may show a variety of pathologic patterns. In most cases, portal inflammation with mononuclear cells or neutrophils surrounding damaged bile ducts (pericholangitis) is the main finding.<sup>306,307,313-316</sup> Scattered foci of necrosis may be present in the lobules, sometimes accompanied by inflammation around the central veins and Glisson capsule.<sup>304,307,309,316,317</sup> Granulomatous hepatitis is described in some cases (Fig. 11.25).<sup>310,317,318</sup> Rarely, other patterns can be seen, such as diffuse sinusoidal histiocytic infiltration or postinfantile giant cell hepatitis.<sup>319</sup> Spirochetes are only rarely identified in histologic sections with silver stains, such as Warthin-Starry or Steiner.<sup>305,311,316</sup> Organisms can be demonstrated with immunohistochemical stains.<sup>303,320-322</sup>

In tertiary syphilis, multiple gummas in the liver may mimic metastatic carcinoma.<sup>323,324</sup> Histologically, gummas resemble TB, in that they are composed of masses of granulomas with caseating necrosis, surrounding fibrosis, chronic inflammation, and histiocytic inflammation.<sup>324</sup> Organizing abscesses with abundant eosinophils have also been reported.<sup>325</sup> Healed gummas may be replaced by fibrous scars (Fig. 11.26). Retraction of these scars can distort the liver by producing pseudolobules or so-called hepar lobatum.<sup>324</sup> Scars near the hilum may result in portal hypertension. Less commonly, secondary syphilis may also present as mass-forming lesions in the liver, leading to a radiologic diagnosis of malignancy.<sup>303,321,322,325</sup> Lesions are typically multiple in number, ranging from two to innumerable, and may be up to 5.7 cm in size. Histologically the lesions consist of a variably cellular storiform spindle cell proliferation with mixed inflammation, sometimes with abscesses.<sup>303,323,325</sup> The lesions contain numerous spirochetes, particularly within the walls of small blood vessels.<sup>303,321,322</sup> The background liver may show mixed inflammation with portal edema, pericholangitis/cholangitis with duct injury, and granulomas. Although pathologically the lesions mimic a spindle cell neoplasm, awareness of the clinical scenario, as well as the background inflamed liver, should enable the pathologist to suspect syphilis. Treatment with intramuscular benzathine penicillin or, less commonly, oral ceftriaxone or doxycycline, should result in resolution of mass lesions and LFT abnormalities.

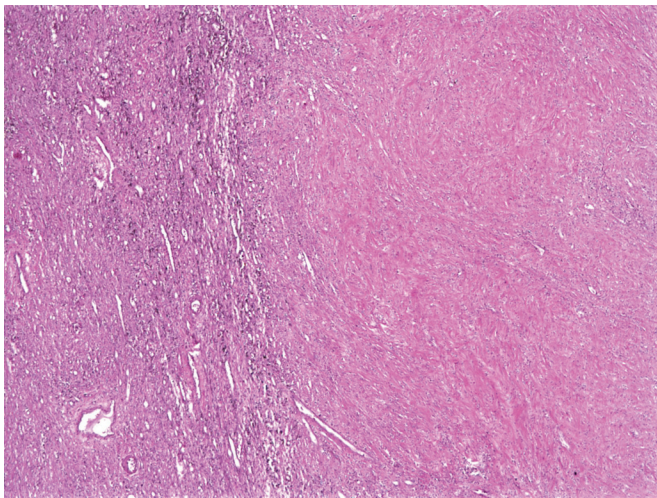
Congenital syphilis is frequently fatal, but surviving infants may have hepatomegaly and jaundice, with diffuse fibrosis. Spirochetes can be seen within connective tissue septa, parenchymal cells, and the walls of small vessels.<sup>326</sup>

### Leptospirosis

Leptospirosis is an acute febrile illness caused by *Leptospira interrogans* that affects humans and animals in all parts of the world.<sup>327</sup> The disease is biphasic, with a septicemic phase followed by an immune phase with antibody production and urinary excretion of the organism.<sup>327</sup> Most patients experience a mild anicteric illness, with fever, headaches, and myalgias. Severe cases, characterized by hepatic, renal, and pulmonary involvement, are known as Weil syndrome.<sup>327</sup> Liver pathology is predominantly a cholestatic hepatitis with reactive hepatocellular changes and Kupffer cell hyperplasia.<sup>283,327-329</sup> Scattered Councilman bodies, bile within canaliculi, and mild portal inflammation may be seen.<sup>283,330</sup> Very rarely, spirochetes can be demonstrated on silver stain. Immunohistochemical staining for *Leptospira* is also available from the Centers for Disease Control and Prevention,<sup>328</sup> and PCR assays can be performed from formalin-fixed, paraffin-embedded tissue.<sup>331</sup> However, the diagnosis is usually based on serologic assays.



• **Figure 11.25** Syphilis in the liver. **A**, Granulomatous inflammation is seen adjacent to inflamed hepatic parenchyma. **B**, Medium-power view of an inflammatory tumor in syphilis composed of spindle cells with a storiform appearance and mixed inflammation. **C**, High-power view shows a mononuclear infiltrate with plasma cells surrounding small vessels. **D**, Immunohistochemical stain for *T. pallidum* showing numerous organisms in the inflammatory mass.



• **Figure 11.26** Old gumma in the liver, showing a hyalinized nodule with mild chronic inflammation at the periphery. (Courtesy Dr. Laura Lamps.)

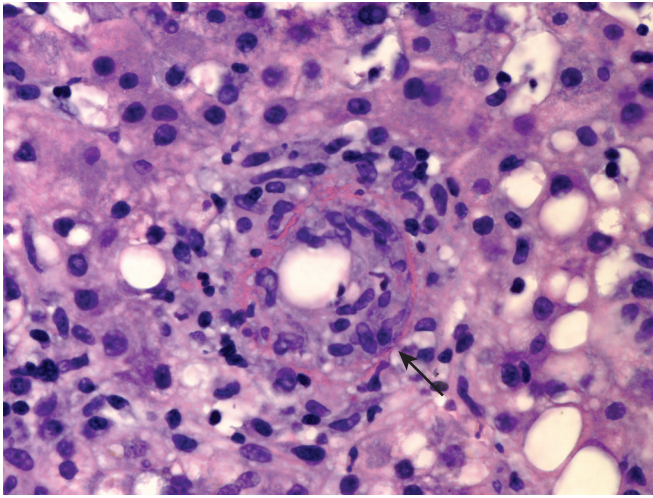
### Lyme Disease

Lyme disease is caused by *Borrelia burgdorferi* and is transmitted by *Ixodid* ticks, usually during the months of May through October. Hepatomegaly and symptoms of hepatitis are uncommon. Elevated transaminases indicate mild hepatocellular injury, although a nonhepatic source is possible in the case of Lyme disease–associated myositis.<sup>287</sup> In the liver, mononuclear cells, plasma cells, and granulocytes are seen in sinusoids. Kupffer cell hyperplasia, steatosis, and hepatocyte ballooning are also described.<sup>287,332</sup> Granulomatous hepatitis is uncommon; necrotizing granulomas have been reported.<sup>333</sup> Organisms are only rarely seen in hepatic sinusoids and parenchyma with silver stain, such as Dieterle.<sup>332</sup>

### Rickettsia

#### Q Fever (*Coxiella burnetii*)

Q fever is a zoonotic rickettsial disease that is caused by the aerosol spread of *Coxiella burnetii* from infected sheep and cattle. The disease is endemic in the southwestern United States and in



• **Figure 11.27** Fibrin ring granuloma. A collection of histiocytes contains a central fat droplet surrounded by a rim of histiocytes, a ring of fibrin (arrow), and another rim of histiocytes.

southwestern Ontario. Most patients suffer an acute, self-limited infection that typically manifests as pneumonitis, although chronic infection with endocarditis is well known. Unlike other rickettsial diseases, Q fever does not produce a rash.<sup>334</sup> Hepatic involvement is common, and the disease may even manifest as hepatic disease without pulmonary symptoms.<sup>335</sup> Hepatic abscess formation detected radiologically has been reported.<sup>336</sup> Some cases may be associated with the hemophagocytic syndrome.<sup>337</sup> The diagnosis is established by complement-fixing antibodies to phase II *C. burnetii* antigen in serum.

The classic lesion of Q fever is the fibrin ring granuloma, which can be found in liver or bone marrow (Fig. 11.27).<sup>334,335,337-344</sup> Also known as doughnut or ring granulomas, these lesions contain a central fat vacuole that can lead to their being mistaken for lipogranulomas, but on closer inspection a ring of fibrin surrounds the fat vacuole. The fibrin ring is highlighted on trichrome stain. Q fever is the most commonly reported etiology, but fibrin ring granulomas have also been reported in other infections and in noninfectious conditions, including hepatitis A,<sup>8,9</sup> *Staphylococcus epidermidis* infection,<sup>345</sup> allopurinol hypersensitivity,<sup>346-349</sup> visceral leishmaniasis,<sup>348,349</sup> giant cell arteritis,<sup>350</sup> CMV,<sup>113</sup> EBV,<sup>102,351</sup> Hodgkin disease,<sup>349,352</sup> toxoplasmosis,<sup>348</sup> and boutonneuse fever.<sup>348</sup>

In addition to fibrin ring granulomas, epithelioid granulomas with or without central necrosis may be seen and can be mistaken for TB.<sup>334,340,343,348,353,354</sup> Other findings in Q fever hepatitis include moderate steatosis, focal liver cell necrosis, Kupffer cell hyperplasia, hemosiderin deposits, acute cholangitis, and, rarely, microabscesses.<sup>340,343</sup>

### Ehrlichiosis

Ehrlichiosis is caused by gram-negative obligate intracellular organisms that are transmitted by a tick vector, predominantly in the southeastern United States. Human monocytic ehrlichiosis is caused by *Ehrlichia chaffeensis* and *Ehrlichia canis*, whereas human granulocytic ehrlichiosis is caused by *Ehrlichia phagocytophila* and *Ehrlichia equi*.<sup>287</sup> Symptoms include fever, headache, anorexia, and myalgia. The relatively low incidence of rash (20%) contrasts with the frequent presence of a rash in Lyme disease and Rocky Mountain spotted fever.<sup>355,356</sup> Transaminases are often mildly

elevated, although they may be in the range of viral hepatitis. Alkaline phosphatase and bilirubin are less likely to be elevated but may be so with severe cholestasis.<sup>355,356</sup> Liver biopsy may show lobular lymphohistiocytic aggregates and sinusoidal infiltration by lymphohistiocytic cells associated with erythroleukophagocytosis.<sup>357</sup> In cholestatic cases, bile stasis, duct epithelial injury, and neutrophilic infiltration of medium-sized ducts may suggest extrahepatic obstruction.<sup>355,357</sup> Other reported findings include focal hepatic necrosis, steatosis, granulomas, and foamy Kupffer cells with scattered apoptotic bodies.<sup>356,357</sup>

### Rocky Mountain Spotted Fever

*Rickettsia rickettsii* is transmitted by the wood tick, *Dermacentor andersoni*, in the Rocky Mountain region and by the dog tick, *Dermacentor variabilis*, in the eastern United States. Mild to moderate transaminase elevations and occasionally jaundice may be seen. The main pathologic lesion is vasculitis, and rickettsiae are capable of infecting the endothelial lining cells of portal blood vessels, especially arteries and arterioles, and sinusoidal lining cells.<sup>287,358</sup> Reports of autopsy livers describe portal inflammation, portal vasculitis with subendothelial and intramural mononuclear leukocytes, portal vascular thrombi, portal tract hemorrhage, sinusoidal leukocytosis, and erythrophagocytosis by Kupffer cells.<sup>358,359</sup> Immunofluorescence techniques can be used to identify the organisms in tissue.

### Boutonneuse Fever/Mediterranean Spotted Fever

Boutonneuse fever, also known as Mediterranean spotted fever, is caused by *Rickettsia conorii* and is transmitted by the dog tick *Rhipicephalus sanguineus*. The disease is found in Mediterranean countries between the months of June and September and classically presents with fever, maculopapular rash, and a black eschar at the bite site (known as “tache noire,” or black spot in French).<sup>360</sup> As is the case with Q fever, boutonneuse fever may be associated with the hemophagocytic syndrome.<sup>337</sup> Hepatic involvement shows Kupffer cell swelling and increased sinusoidal cellularity. Small foci of hepatocyte necrosis are seen, associated with collections of histiocytes, a few neutrophils, and lymphocytes.<sup>361,362</sup> The mononuclear cell aggregates in the areas of necrosis may resemble poorly formed granulomas, but they are not true epithelioid granulomas. The diagnosis is typically made by serology.

## Fungal Infections of the Liver and Bile Duct

### Histoplasma

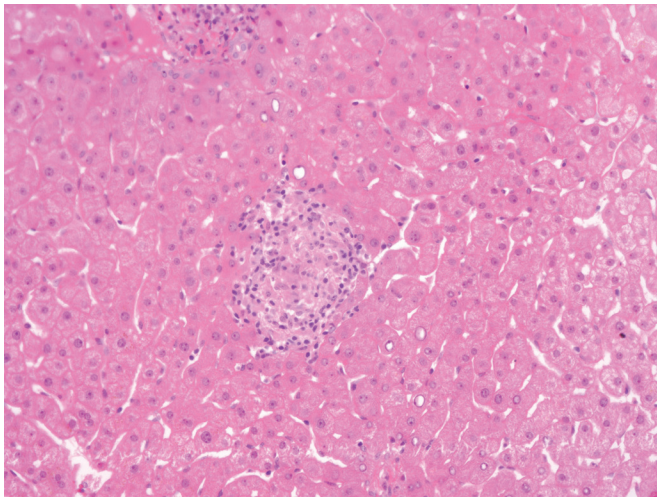
*Histoplasma* is considered to be the most common fungal cause of hepatic granulomas, and it is a common cause of granulomatous hepatitis in areas where *H. capsulatum* is endemic, such as in the Ohio River valley.<sup>363</sup> In one series from that region, 15 (65%) of 23 children with hepatic granulomas had histoplasmosis demonstrated by PCR.<sup>364</sup> In another series, 50% of liver biopsy specimens with granulomas cultured positively for *Histoplasma*. Although histoplasmosis is usually self-limited in infants or immunocompromised patients, it can manifest with progressive disseminated disease requiring treatment.<sup>364</sup> Progressive disseminated histoplasmosis often involves the liver, with hepatomegaly in 62% of patients and abnormal liver function studies in 84%.<sup>365</sup>

Histologically the appearance is identical to sarcoidosis, with numerous well-formed epithelioid granulomas (Fig. 11.28).<sup>176,366</sup> In immunocompromised hosts, loose collections of histiocytes

with numerous intracellular organisms can mimic leishmaniasis (Fig. 11.29). The absence of a kinetoplast on Giemsa stain helps to distinguish *Histoplasma* from *Leishmania*.<sup>367</sup> The diagnosis can be established with methenamine silver staining of involved tissue, fungal culture, or complement fixation tests.<sup>365</sup>

## Candida

Candidiasis is especially problematic in immunocompromised patients, particularly those with leukemia or cytotoxic chemotherapy-related neutropenia.<sup>368</sup> *Candida* accounts for 62% to 91% of fungal infections in the liver transplantation population, affecting 5% to 42% of all liver transplant recipients.<sup>110</sup> Patients present with fever, abdominal pain, and elevated alkaline phosphatase; blood cultures are negative in at least half of the cases.<sup>369</sup> Usually, patients are in the recovery phase from the neutropenic episode, suggesting a role for the host inflammatory response in defining the lesions.<sup>368</sup> The diagnosis is often not made



• **Figure 11.28** Liver biopsy sample in an immunocompetent patient with hepatic and splenic histoplasmosis. A solitary, well-formed granuloma is present in the liver.

until postmortem examination. *Candida* is an uncommon but important cause of hepatic abscesses in preterm neonates.<sup>370-372</sup>

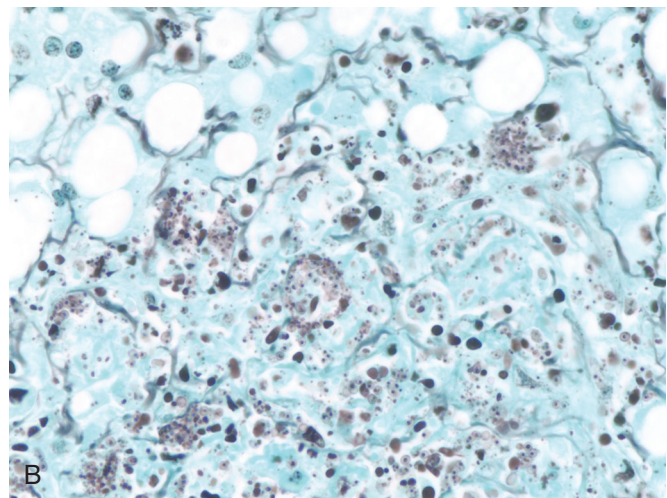
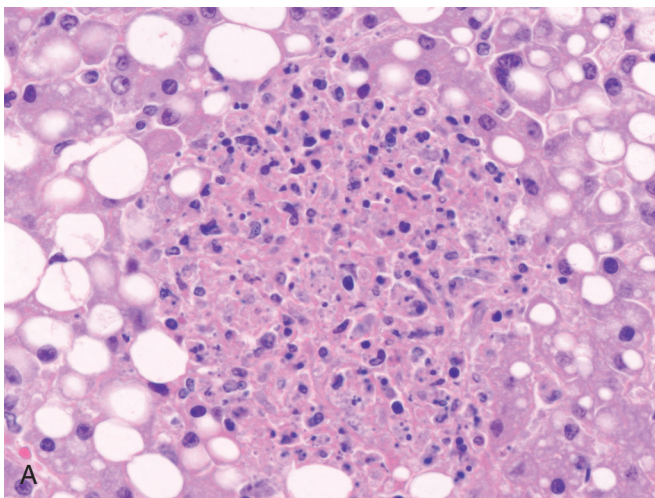
Radiologically the lesions appear targetoid and, in the case of older lesions, calcified.<sup>368,369</sup> Grossly the liver and spleen are studded with white to yellow nodules. In the early stages, the nodule consists of a necrotic center and surrounding neutrophilic infiltrate. Periodic acid–Schiff (PAS) or Gomori methenamine silver (GMS) stains demonstrate yeast or pseudohyphae in the center of the abscess. As the lesion matures, a palisaded histiocytic reaction may develop at the periphery of the lesion, surrounded by a fibrous wall (Fig. 11.30).<sup>369</sup> Eventually, well-defined granulomas with giant cells may be seen.<sup>368</sup> As the lesions progress with increasing fibrosis, organisms become more difficult to detect, so their absence does not exclude the diagnosis. The adjacent liver parenchyma frequently shows sinusoidal dilatation, portal edema, neutrophilic infiltrate, and ductular reaction, presumably due to mass effect.<sup>369</sup> Candidal infection of the biliary tree and gallbladder occurs in disseminated candidiasis, with bacterial cholangitis, or as isolated candidal cholangitis or cholecystitis.<sup>373,374</sup> *Candida* species can be identified from liver biopsies using PCR techniques, which may be useful in cases in which patients are on antifungal treatment and organisms are not identified by pathologic examination.<sup>375</sup>

## *Pneumocystis jiroveci*

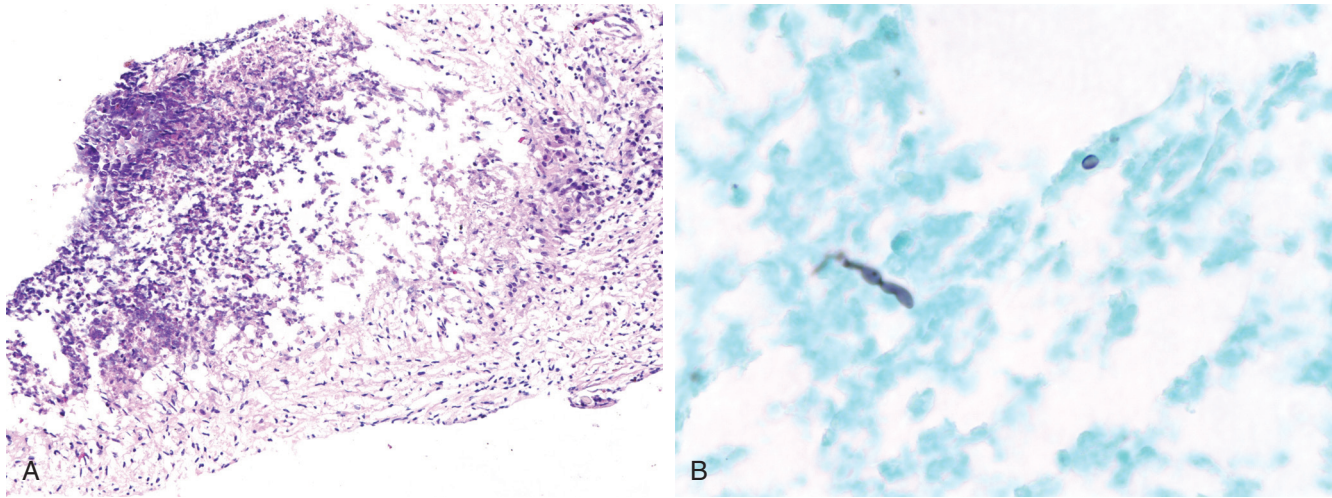
*P. jiroveci* (formerly *Pneumocystis carinii*) is a fungal organism that typically causes lung infections in immunocompromised patients. Extrapulmonary infection is rare but has been associated with the use of prophylactic aerosolized pentamidine, which suppresses pulmonary disease but might allow for dissemination of the organism.<sup>376,377</sup> Grossly the liver is studded with yellow-white nodules. The pathology ranges from caseating granulomas to massive infiltration of sinusoids and vessels by the organism with little inflammatory reaction (Fig. 11.31).<sup>376,377</sup> The organism appears as indented, helmet-shaped “cysts” on silver stains.

## *Aspergillus*

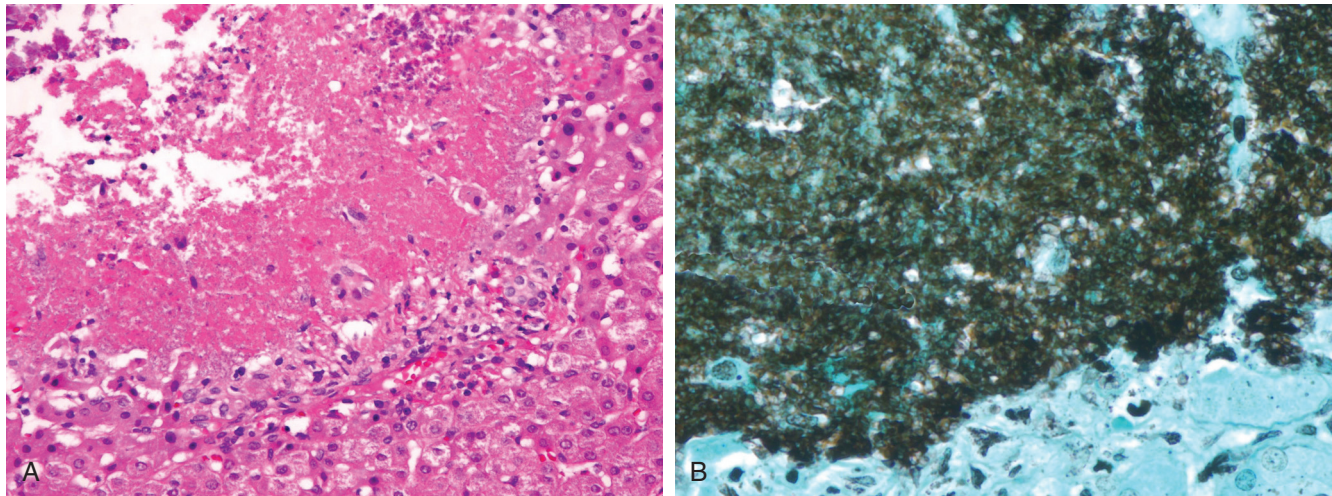
*Aspergillus* spp. (*Aspergillus fumigatus* or *Aspergillus flavus*) involving the liver is seen in cases of disseminated aspergillosis and



• **Figure 11.29** Histoplasmosis in an acquired immune deficiency syndrome patient. **A**, Necrotic lesions are composed of histiocytes and debris. **B**, Gomori methenamine silver stain shows yeast in macrophages in the necrotic lesion.



• **Figure 11.30** Candidal abscess in a patient with leukemia. **A**, Abscess with necrosis and neutrophils (upper left) surrounded by a palisaded histiocytic reaction. **B**, Rare yeast and pseudohyphae on Gomori methenamine silver staining.



• **Figure 11.31** *Pneumocystis jirovecii* in the liver. **A**, Necrotic lesion composed of granular eosinophilic material with mild histiocytic reaction at the periphery. **B**, Gomori methenamine silver stain demonstrates that the granular material is composed of masses of *Pneumocystis* organisms.

in immunosuppressed patients, particularly organ transplant recipients. Liver abscess and cholangitis secondary to *Aspergillus* infection have been described.<sup>239,378-381</sup> The organism is easily demonstrated on methenamine silver or PAS stains and shows characteristic septate hyphae with acute-angle branching. Speciation can be accomplished by culture (with examination of fruiting bodies) or PCR-based techniques.

### Mucormycetes/Zygomycetes

Fungi of the class *Mucormycetes* (formerly *Zygomycetes*) are ubiquitous in nature, occurring in decaying material and soil. The members of this class most often implicated in human disease are *Rhizopus*, *Rhizomucor*, *Mucor*, and *Absidia*.<sup>382</sup> Hepatic zygomycosis has been reported in immunocompromised patients, in patients receiving chemotherapy, in stem cell transplant recipients, and in solid organ transplant recipients.<sup>382-386</sup> Involvement of liver

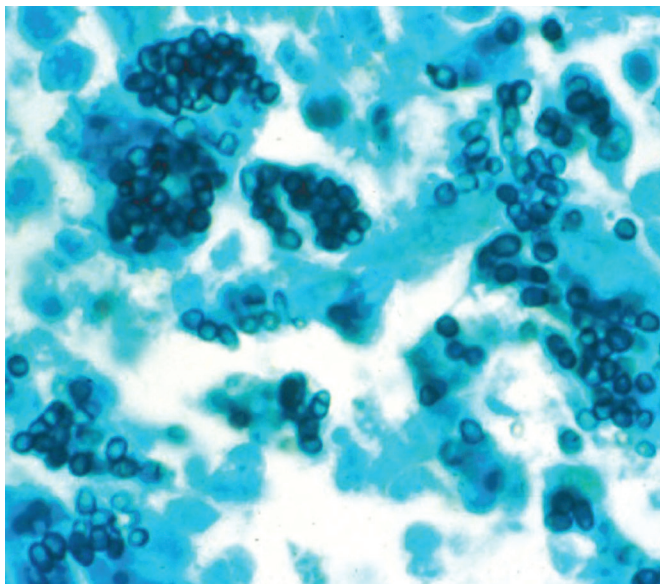
allografts leading to retransplantation has been described.<sup>387,388</sup> Less commonly, it may affect immunocompetent patients.<sup>389</sup> Hepatic infection in the absence of pulmonary disease may be caused by spread from a gastrointestinal source, and thus many patients have concurrent involvement of a site in the tubular gastrointestinal tract.<sup>382,390,391</sup> Patients may present with single or multiple hypodense lesions on abdominal CT.<sup>392,393</sup> Mass effect may lead to stenosis and dilatation of the extrahepatic bile ducts, mimicking cholangiocarcinoma.<sup>389</sup> Peripheral eosinophilia may be present.

Pathologic specimens commonly show organizing abscesses with necrosis, with or without granulomatous inflammation. Some cases contain abundant eosinophilic infiltration and may be described as eosinophilic granulomas; this is common in zygomycosis due to *Basidiobolus ranarum*.<sup>390,394-396</sup> These fungi have broad (10 to 20  $\mu\text{m}$ ), aseptate or hyposeptate, ribbonlike hyphae with right-angle branching, and they have a propensity

to invade blood vessels, leading to extensive necrosis, infarctions, and dissemination.<sup>382-385,393,397</sup> When eosinophilic inflammation is prominent, degenerated fungal organisms may be associated with dense, hyalinized, eosinophilic material (Splendore-Hoeppli phenomenon). Diagnosis requires identification of the fungus in tissue or culture. However, tissue culture sensitivity is poor, possibly because the grinding of tissue in preparation for plating destroys the delicate hyphae, and this technique is no longer recommended.<sup>382</sup> PCR-based techniques for diagnosis are also available. Blood cultures are always negative. In tissue identification, erroneous classification as *Aspergillus* may occur if the hyphae are hyposeptate.<sup>382</sup> Some evidence suggests that iron is required for growth of zygomycetes, and thus there is interest in using iron chelators in combination with antifungal agents to treat zygomycosis; however, it is not established whether this approach is more effective.

### Penicilliosis

Penicilliosis is an infection caused by the dimorphic fungus, *Penicillium marneffei*, which is endemic in Southeast Asia.<sup>398</sup> This pathogen has emerged as the third most common opportunistic infection among AIDS patients in Southeast Asia and southern China, although it affects people with apparently normal immunity as well.<sup>399</sup> Disseminated infection commonly presents with fever and skin lesions, and hepatic abscess formation may occur.<sup>400</sup> Pathologic findings include a granulomatous hepatitis with relatively few organisms, diffuse sinusoidal infiltration by foamy macrophages containing numerous organisms, and suppurative abscesses or necrotic lesions consisting of histiocytes filled with organisms, the latter being typical in immunocompromised patients.<sup>398,399,401</sup> The organisms appear as small spherules, 2 to 4  $\mu\text{m}$  in diameter, along with some elongated and septate forms; they are highlighted with methenamine silver stain or by PAS stain with diastase digestion (Fig. 11.32).<sup>398,399,401</sup> Isolated



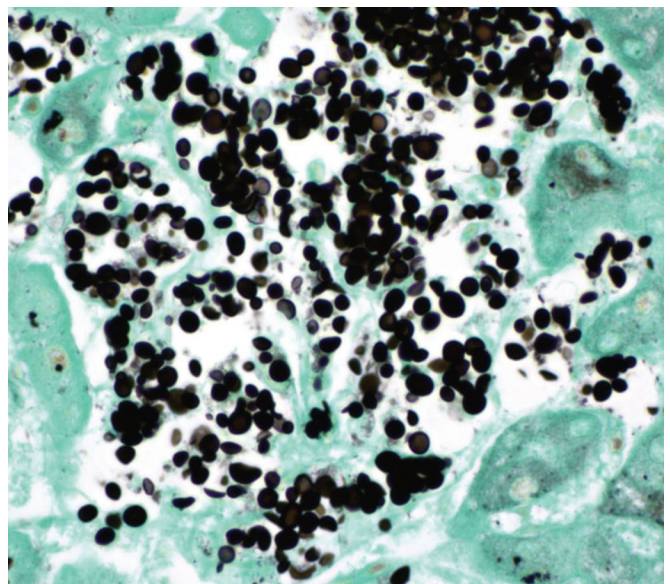
• **Figure 11.32** Penicilliosis. A Gomori methenamine silver stain shows numerous yeast forms in macrophages. The organisms are round to oval, with a few slightly elongate and septate forms. (Courtesy Drs. David Walker and Laura Lamps.)

organisms grow as mold at 25°C on Sabouraud glucose agar and produce a characteristic soluble red pigment that diffuses into the agar.<sup>399,400</sup> The main differential diagnosis is *H. capsulatum*.

### Cryptococcosis

Cryptococcosis is caused by the encapsulated yeast, *Cryptococcus neoformans*. Lung and central nervous system are the two most commonly affected organs, but hepatic infection has been reported in both immunocompromised and immunocompetent patients.<sup>402,403</sup> In immunocompromised patients, hepatic involvement commonly occurs in the setting of disseminated infection or multiorgan involvement.<sup>404-406</sup> In contrast, immunocompetent patients tend to present with an isolated biliary infection that clinically and radiologically mimics sclerosing cholangitis or cholangiocarcinoma.<sup>407-412</sup> These patients exhibit obstructive jaundice, and radiologic studies may show dilatation of intrahepatic bile duct dilatation, stricturing and wall thickening of extrahepatic bile ducts, and masslike lesions in the hilum. Most reported immunocompetent patients with biliary cryptococcosis are children or young adults.<sup>407-409,412</sup>

Histopathologically, immunocompetent cases are characterized by granulomas, whereas in AIDS patients, an inflammatory reaction is poorly developed or absent. Autopsies in cases of disseminated infection have shown areas of necrosis with innumerable yeast cells, yeast cells diffusely within tissue admixed with cellular debris and inflammation, or yeast cells within Kupffer cells (Fig. 11.33).<sup>406,411</sup> The organism can be demonstrated on special stains (silver impregnation, PAS), and mucicarmine stain can be used to highlight the capsule.<sup>404-406,409,410</sup> The capsule is a virulence factor and is helpful in the diagnosis, but in rare instances, capsule-deficient strains can cause infection, particularly in immunocompromised patients (see Fig. 11.33). Capsule-deficient forms can be confused with other yeasts. The diagnosis can be made by serology but may be elusive in cases with atypical presentations



• **Figure 11.33** Capsule-deficient *Cryptococcus*. A Gomori methenamine silver stain shows yeast cells of varying sizes within a collection of histiocytes in the liver. (Courtesy Dr. Laura Lamps.)



(e.g., without prominent pulmonary symptoms), leading to delayed treatment and poor outcomes.

### Coccidioidomycosis

*Coccidioides immitis* is endemic to the southwestern United States and northern Mexico. Disseminated infection can show granulomatous hepatitis or microabscesses containing the thick-walled spherules of *C. immitis*, which can be highlighted with PAS and methenamine silver stains.<sup>413-415</sup> The spherules may or may not contain endospores; immature spherules without endospores can be mistaken for *Blastomyces dermatitidis* or *C. neoformans*.<sup>415</sup> Serology and culture results can be used to establish the diagnosis.

### Blastomycosis

*B. dermatitidis* is a dimorphic fungus that usually involves skin and lungs. The fungus is endemic to the southeastern and south central United States, the areas bordering the Great Lakes, and the Ohio and Mississippi River basins. Hepatic granulomas and cholangitis have been described.<sup>416</sup> Thick-walled yeast forms with broad-based budding are seen on PAS or silver stains (Fig. 11.34).

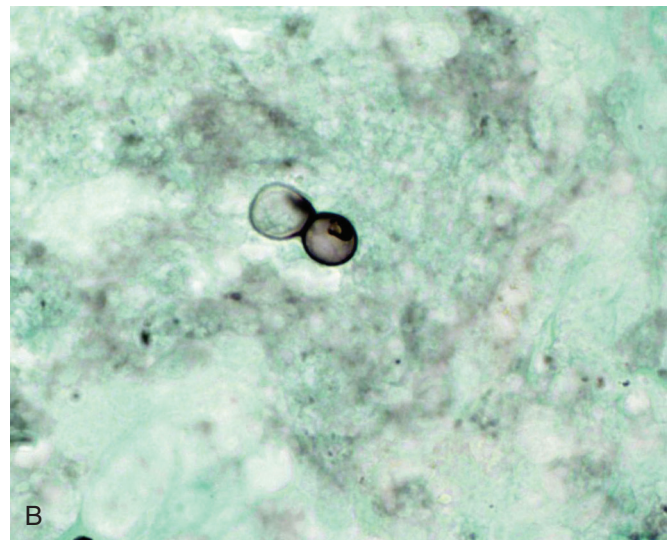
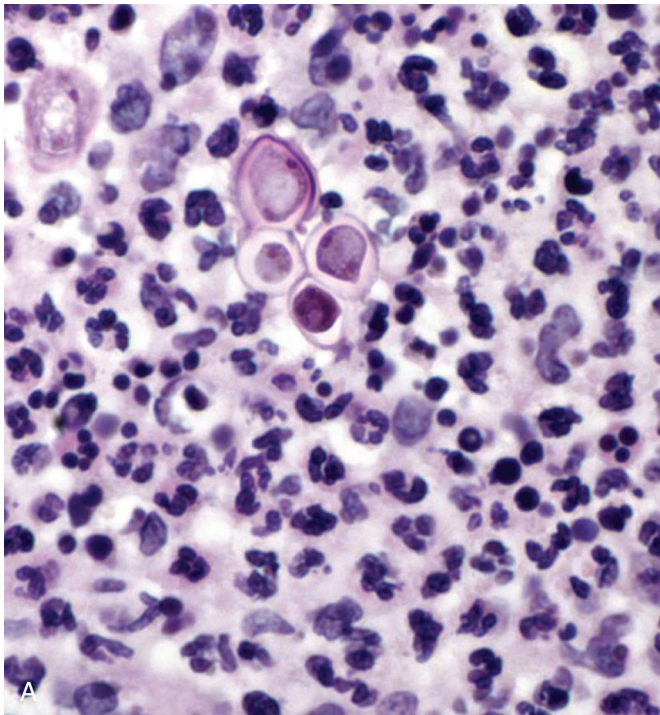
### Paracoccidioidomycosis (South American Blastomycosis)

*Paracoccidioides brasiliensis* causes a chronic granulomatous disease known as South American blastomycosis. The disease is endemic in rural South America and affects males more often than females. Although pulmonary lesions are typical, extrapulmonary disease can occur. In the liver the fungus usually causes a granulomatous reaction. Less often, it causes focal necrosis with neutrophilic

exudates containing numerous organisms.<sup>417</sup> The inflammatory reaction may involve the portal tracts and be associated with bile duct injury, ductular reaction, and portal fibrosis, which may progress to bridging.<sup>418</sup> Yeast forms can be demonstrated by silver impregnation stains. Intrahepatic ductal dilatation may result from biliary involvement and may mimic cholangiocarcinoma radiologically.<sup>419</sup>

### Microsporidiosis

Microsporidia are obligate intracellular organisms that were originally believed to be primitive eukaryotes but have been reclassified as fungi, based on DNA sequence data. Infection of bile duct epithelium has been described as a cause of AIDS-related cholangitis.<sup>146,148</sup> Several species have been implicated in AIDS-related cholangitis: *E. bienewisi* (the most common), *Encephalitozoon cuniculi*, and *Septata intestinalis* (previously *Encephalitozoon intestinalis*).<sup>420</sup> The presentation is similar to AIDS cholangitis due to other organisms, including elevation of alkaline phosphatase and PSC-like changes on endoscopic retrograde cholangiopancreatography (ERCP). *S. intestinalis* may also cause radiologically detected hypodense parenchymal lesions, which on biopsy show necrotizing cholangitis consisting of periportal mixed inflammation coalescing into granulomatous microabscesses with foamy macrophages that contain organisms.<sup>421</sup> *S. intestinalis*, unlike *E. bienewisi*, may infect macrophages, fibroblasts, and endothelial cells, in addition to epithelial cells; thus the presence of foamy macrophages suggests *S. intestinalis* infection.<sup>422</sup> The organisms may be seen on Brown-Hopps or Giemsa stains and appear as ovoid spores measuring 2.2 to 2.4  $\mu\text{m}$  in greatest dimension, with characteristic cross-banding and polar vacuoles.<sup>421</sup> A case of hepatitis has also been reported, with



• **Figure 11.34** Blastomycosis. **A**, Broad-based, budding yeast forms are present in an area of suppurative inflammation. **B**, Gomori methenamine silver stain shows broad-based, thick-walled yeast cells. (Courtesy Dr. Laura Lamps.)

sinusoidal congestion and microgranulomas on light microscopy.<sup>145</sup> Electron microscopy is necessary to identify the organisms in most cases, but often the organism has already been identified in intestinal biopsy specimens by the time cholangitis develops. Treatment with albendazole may eradicate the organism, but microsporidial cholangitis in HIV patients has a poor prognosis (as does AIDS cholangitis in general) and often follows a progressive course.

## Helminth Infections of the Liver and Bile Duct

### Schistosomiasis

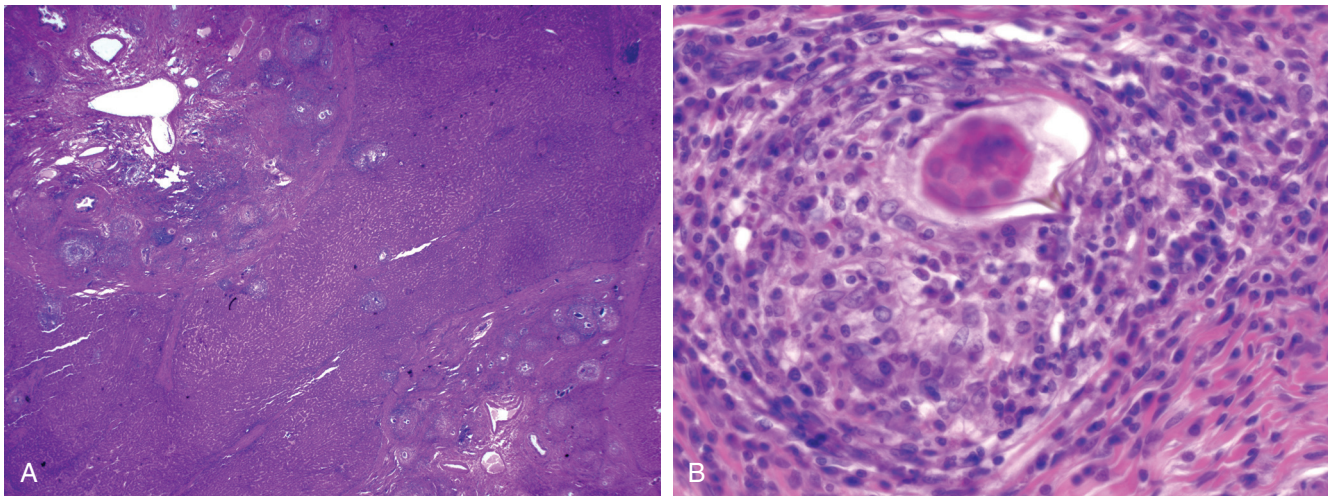
Schistosomiasis is the second most common parasitic infection of humans after malaria. Several species of schistosomes affect humans. *Schistosoma japonicum* and *Schistosoma mansoni* are the two major species associated with hepatic and intestinal schistosomiasis and account for the disease burden in endemic areas.<sup>423</sup> Uncommonly, hepatic involvement has also been documented with *Schistosoma hematobium*, *Schistosoma intercalatum*, and *Schistosoma mekongi*. The intermediate host is a population of snails that is not found in North America or Europe.<sup>424</sup> Infection occurs when the cercariae exit the snail and penetrate the skin of a vertebrate host. In the human host the cercariae migrate to the lungs, where they mature, reach the left side of the heart, and then are carried to the portal hepatic circulation. In the mesenteric venous plexus, the male occupies the gynecophoric canal of the female, and the worms remain in a state of continuous copulation for their life span of 3 to 5 years.<sup>424</sup> Eggs released in the mesenteric venous plexus can migrate to the intestine (intestinal form) or into the liver (hepatosplenic form), where they lodge in the small portal vein tributaries and release antigens that elicit a granulomatous immunologic reaction. Granuloma formation around the eggs leads to pyelophlebitis and periportal fibrosis. *S. mansoni* eggs are ovoid, measure  $140 \times 60 \mu\text{m}$ , and have a prominent lateral spine, whereas *S. japonicum* eggs are smaller and more rounded ( $100 \times 60 \mu\text{m}$ ) and have a smaller lateral spine

that is often obscured.<sup>423</sup> Degenerated eggs may become calcified, which is more commonly seen with *S. japonicum* than with *S. mansoni*.

Histology shows portal fibrosis with partial or complete destruction of the main branches of the portal vein but sparing of arteries and ducts.<sup>424</sup> Adult worms metabolize large amounts of hemoglobin and regurgitate hemozoin pigment, which is engulfed by macrophages in the sinusoids and portal tracts and can be accentuated by Prussian blue stain. Despite the scarring, lobular architecture is maintained, so the fibrosis does not represent true cirrhosis, and there is evidence that it may undergo regression with clearance of the organisms.<sup>425</sup> This pattern of fibrosis is known as Symmers pipestem fibrosis because of the clay pipestem appearance on gross pathology (Fig. 11.35).<sup>424</sup> The dense periportal fibrosis can also be seen on radiology as characteristic low-attenuation bands or rings around large portal vein branches, which may be associated with calcified eggs.<sup>426</sup>

Eventually, portal hypertension supervenes with splenomegaly and esophagogastric varices. However, compensatory increase in hepatic arterial blood flow maintains hepatic perfusion and hepatic function.<sup>424</sup> Often, patients lack other stigmata of chronic liver disease. The diagnosis is based on the demonstration of ova in stool specimens. Serology to detect anti-schistosomal antibodies does not distinguish active from resolved infection. Enzyme-linked immunosorbent assays (ELISAs) have been developed that detect schistosomal antigens in the serum and urine of actively infected patients. Antigen levels correlate with worm burden.<sup>424</sup> Coinfection with HBV or HCV is associated with a more aggressive course of hepatitis B or C and accelerated progression of fibrosis.<sup>423</sup>

In endemic areas, recently infected patients may present with an acute form of the disease (sometimes referred to as Katayama fever) caused by a systemic hypersensitivity reaction to migrating cercariae and eggs.<sup>423</sup> Clinical symptoms include fever, headache, myalgias, pneumonia, diarrhea, hepatosplenomegaly, and peripheral eosinophilia. Pathologic examination shows granulomas with extensive central necrosis and dense eosinophilic infiltrates surrounding eggs in the liver, intestines, and other organs.<sup>427</sup>



• **Figure 11.35** Schistosomiasis. **A**, The liver shows marked expansion of two portal areas with fibrosis and numerous granulomas, consistent with Symmers pipestem fibrosis. Note the absence of cirrhosis in the background liver. **B**, A high-power view of a granuloma surrounding a schistosome ovum with the characteristic lateral spine.

## Strongyloides

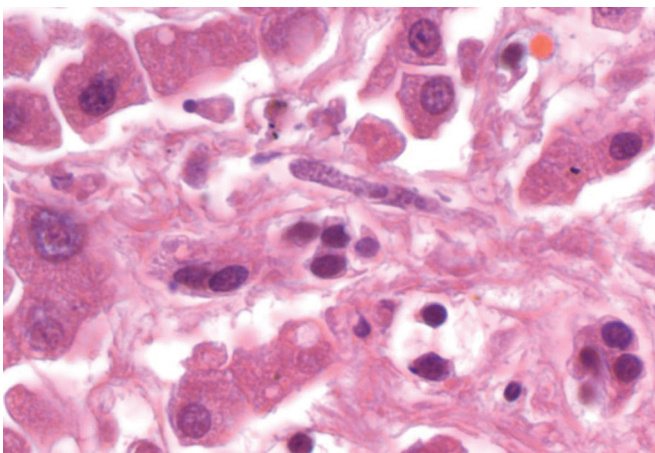
*Strongyloides stercoralis* exist as rhabditiform larvae in soil and as filariform larvae in humans. The organisms reside in the intestine, where they produce eggs that develop into rhabditiform larvae, which are shed in feces. In certain settings, rhabditiform larvae may develop into the infectious filariform larvae within the intestine; this form is capable of invading the intestinal mucosa and traveling throughout the body, typically the central nervous system, liver, and lungs. This unique cycle of autoinfection is accelerated in immunosuppressed patients, particularly those receiving corticosteroids, and is referred to as hyperinfection syndrome or disseminated strongyloidiasis; untreated, its mortality rate approaches 100%.<sup>428</sup> The diagnosis is based on detection of larvae in stool in conjunction with serologic testing. In the liver the larvae can cause granulomatous hepatitis with or without larval remnants. The larvae measure between 6 and 13  $\mu\text{m}$ , and they may be seen in sinusoids, portal tract lymphatics, or branches of the portal vein (Fig. 11.36).<sup>429</sup> The larvae occasionally do not provoke an inflammatory reaction.<sup>429</sup> Steatosis and cholestasis are additional features.

## Enterobiasis (Pinworm)

Rarely, *Enterobius vermicularis* travels from the anus to unusual locations, such as the urethra or vagina. Rupture of the appendix or other intestinal disease may also provide the nematode with a mode of reaching the liver.<sup>430</sup> Subcapsular nodules in the liver may be found at the time of surgery or may be radiologically detected during staging of patients with carcinoma, leading to misdiagnosis as metastases.<sup>431,432</sup> Histologic examination shows large necrotic nodules with surrounding histiocytic reaction and fibrosis, hyalinizing granulomas, or calcifying granulomas; the lesions contain remnants of pinworms with characteristic lateral alae and multiple ova.<sup>430-433</sup>

## Echinococcosis

Echinococcosis or hydatid cyst disease is caused by species of the tapeworm, *Echinococcus*. *Echinococcus granulosus* is endemic in Mediterranean countries, Iran, India, China, Chile, and Argentina



• **Figure 11.36** *Strongyloides* in an AIDS patient with disseminated *Strongyloides* infestation. A larval form is present in a small portal lymphatic channel.

and causes cystic disease, whereas *Echinococcus multilocularis* is endemic in central Europe, the Near East, Russia, China, northern Japan, and Alaska and causes alveolar disease.<sup>434,435</sup> The adult tapeworms live in the jejunum of dogs and other carnivores, the final hosts; the larvae infect herbivores, the intermediate hosts, when they ingest the eggs released in the feces of the carnivore host. Humans are incidental intermediate hosts because further development of the cestode requires ingestion of the larvae by a carnivore.<sup>436</sup>

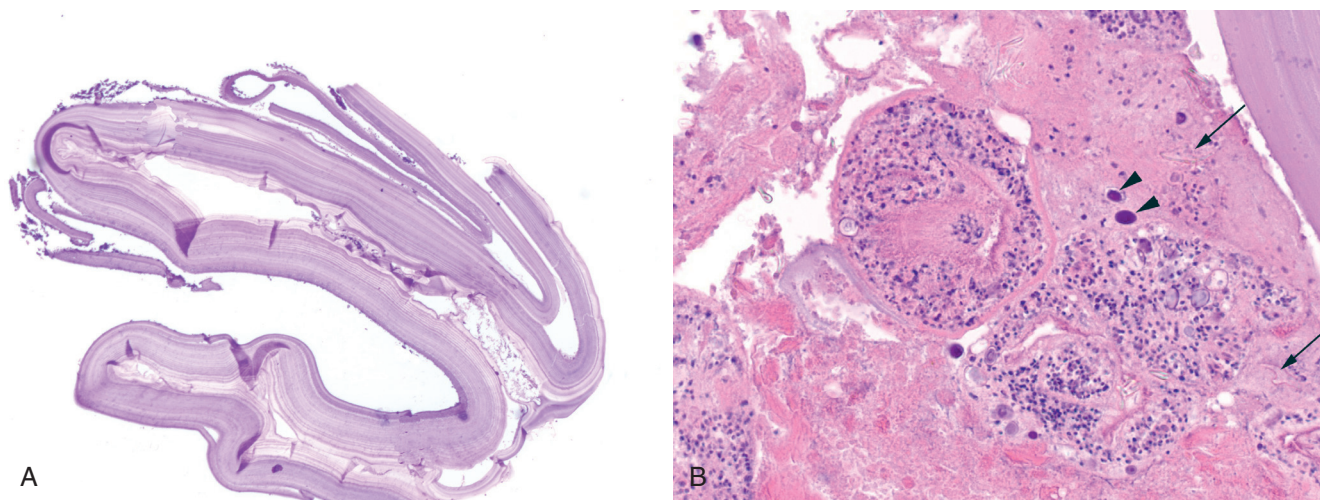
After being ingested, the egg develops into a larval oncosphere, which penetrates the intestinal mucosa, enters the portal circulation or lymphatics, and, on reaching the target organ (usually the liver, in 70% of cases, or the lung, in 20%), forms a rounded, multinucleated mass that becomes cystic and progressively enlarges.<sup>435</sup> The hydatid cyst or metacestode consists of an external, acellular, laminated cuticle and an inner germinal membrane that gives rise to brood capsules containing new larvae called protoscolices (Fig. 11.37).<sup>435,437</sup> The fully developed protoscolex stage contains suckers, hooks, a cup-shaped foramen, and calcareous corpuscles, which are irregularly spherical or ovoid in shape and have a diameter of 2 to 16  $\mu\text{m}$ .<sup>438</sup> The central region of the calcareous corpuscles is composed of an electron-lucent matrix containing granular deposits of inorganic salts (chiefly calcium and magnesium carbonate) and paired membrane lamellae.<sup>439</sup>

Hydatid cysts are initially uniloculated but develop internal septations as they form daughter cysts, either from the germinal membrane or from the protoscolices or brood capsules. Cysts cause a granulomatous host reaction that leads to development of a fibrous tissue layer or pericyst.<sup>436</sup> In the case of *E. granulosus* the cysts are slowly enlarging masses that remain asymptomatic for a long period. They may eventually cause dull abdominal pain and a palpable mass.<sup>374</sup> Abdominal ultrasound is key for the diagnosis of cystic echinococcosis and further classifies the cysts as active, transitional, or inactive based on a classification scheme developed by the World Health Organization (WHO) which helps to guide management.<sup>440</sup> Serologic testing is available but has low sensitivity and is used primarily as a confirmatory test. Approximately 40% of cases are associated with complications, including erosion into bile ducts, through the hepatic capsule into the peritoneal cavity, into adherent organs, or through the diaphragm.<sup>374</sup> Therapeutic options include medical therapy, percutaneous aspiration injection and reaspiration (PAIR), and surgical resection.<sup>441</sup> In alveolar hydatid disease due to *E. multilocularis*, the hepatic parenchyma is invaded and replaced by fibrous tissue with numerous embedded vesicles (each with a germinal layer and laminated cuticle) that mimics carcinoma.<sup>434</sup> Dense granulomatous inflammation, microcalcifications, and necrotic cavitation may be present.<sup>437</sup>

Alveolar hydatid disease carries a high mortality without surgery, due to liver failure, invasion of contiguous structures, or, less often, metastases to the lung and brain.<sup>434,437</sup> Transplantation has been attempted, but there is a high risk of recurrence in the donor liver.<sup>437</sup> As with cystic echinococcosis, the diagnosis can be made radiologically and confirmed serologically, although some patients do not develop an immune response.<sup>434,437</sup>

## Toxocara

Toxocarosis refers to infection by larvae of the dog ascarid, *Toxocara canis*, or, less commonly, the cat ascarid, *Toxocara cati*. In humans, these larvae do not develop into adult worms but travel throughout host tissue, primarily liver and lungs; therefore the



• **Figure 11.37** Echinococcal cyst. **A**, Collapsed cyst wall is composed of an acellular laminated cuticle. **B**, Closer inspection of the cyst debris shows protoscolices, calcareous corpuscles (arrowheads), and refractile hooklets (arrows).

disease is known as visceral larva migrans.<sup>442</sup> Humans acquire the infection by ingesting the eggs from contaminated soil or by eating undercooked meat or other animal tissues (e.g., cow liver) that are infected by the encapsulated larvae. The larvae are released in the intestines, burrow through the intestinal wall, and reach the liver via the portal vein. From there, they travel to various other organs, causing eosinophilic inflammation, granulomas, and abscesses.<sup>442</sup> Most patients are asymptomatic but demonstrate peripheral eosinophilia and hypergammaglobulinemia. Vague abdominal pain, fever, cough, and dyspnea are occasional complaints.<sup>442</sup> In the United States, visceral toxocariasis affects primarily children between 2 and 7 years old.<sup>443</sup> Radiologic studies show multiple, ill-defined, oval or angular hypoechoic lesions that improve or resolve spontaneously, similar to *Fasciola hepatica* and *Capillaria hepatica*. The nonspecific radiologic appearance may lead to consideration of other etiologies, such as microabscesses, sarcoidosis, and malignancies.<sup>444</sup> Serologic testing for IgG to *Toxocara* antigens has high sensitivity and specificity and is used to make the diagnosis.

In liver biopsy specimens, multiple granulomas and confluent granulomas may be the main finding.<sup>445,446</sup> Grossly the liver may show 0.3- to 1-cm, white-gray lesions, primarily in the subcapsular region of the right lobe.<sup>447,448</sup> These granulomatous lesions show central necrosis surrounded by a mixed inflammatory infiltrate that includes numerous eosinophils and palisading epithelioid histiocytes and may be referred to as eosinophilic granulomas.<sup>444</sup> The central necrotic zone shows granular debris or eosinophilic material. Charcot-Leyden crystals may be seen in the areas of necrosis. Remnants of parasites are found in a minority of cases and measure 15 to 21  $\mu\text{m}$  in diameter.<sup>447</sup> The differential diagnosis includes other causes of visceral larva migrans, including *C. hepatica* and *Ascaris*.

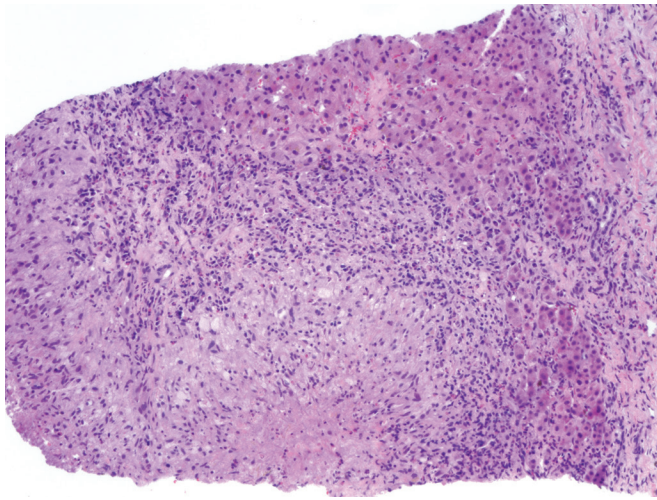
### Capillariasis

*C. hepatica* is a nematode that mainly affects rodents but is also found in carnivores. The organism requires only a single host, with the liver containing both the adult parasite and its ova.<sup>449</sup> Eggs are deposited in soil, where, under favorable conditions,

they embryonate. Ingestion of the unembryonated eggs does not result in hepatic disease but only in abdominal discomfort; in these spurious cases, eggs are passed in the stool. Ingestion of embryonated eggs results in hepatic disease; the larvae bore through the intestinal wall and reach the liver via the portal circulation where they mature into adults. Eggs are not passed into stool.<sup>449</sup> Infection of humans is rare; children are more commonly affected, probably because of frequent soil-to-mouth contact.<sup>449</sup> Patients present with chronic fever, hepatomegaly, and peripheral eosinophilia.<sup>450</sup> Imaging may show portal lymphadenopathy and multiple ill-defined, subcentimeter hypodense nodules throughout the liver.<sup>451</sup> Liver biopsy specimens may show granulomas and eosinophils. Granulomatous lesions with central eosinophilic necrosis rimmed by palisaded histiocytes and numerous eosinophils similar to toxocariasis may be seen.<sup>447,451-454</sup> Fibrosis may develop over time. Remnants of the parasite and its eggs may be identified.<sup>449</sup> The parasite measures 50  $\mu\text{m}$  or larger in diameter<sup>447</sup> and can be identified by the presence of its internal organs (bacillary bands, esophagus, and associated stichosome).<sup>450</sup> The eggs are elliptical, measure 54 to 64  $\mu\text{m}$  by 29 to 33  $\mu\text{m}$ , and have a double-layered envelope with an outer striated wall and bipolar plugs (“biopercolated eggs”).<sup>449,450,453-455</sup> Serology for *Capillaria* is not available. Thus, unlike other helminthic diseases in which the diagnosis is made primarily by serology, a definitive diagnosis of hepatic capillariasis requires pathologic identification of the adult or eggs in biopsy material. Serology should still be performed to exclude other infections in the differential diagnosis, particularly toxocariasis.

### Fascioliasis

*F. hepatica* and *Fasciola gigantica* are trematode bile duct flukes found primarily in sheep and cattle, with a broad geographic distribution.<sup>434,456</sup> The leaf-shaped worms reach a size of approximately 2 cm and may remain viable in the bile ducts for more than a decade. The eggs pass in feces, hatch in water, and infect lymnaeid snails.<sup>434</sup> Snails release a cercarial stage of the parasite that contaminates aquatic plants that are ingested by sheep, cattle, or humans. Watercress is often associated with human



• **Figure 11.38** Fascioliasis. Necrotic tract is surrounded by a palisaded histiocytic reaction in a patient with *Fasciola* infestation.

infection.<sup>457</sup> After being ingested, metacercariae penetrate the intestine, traverse the peritoneal cavity, and penetrate the liver capsule.<sup>458</sup> They burrow through the liver parenchyma for 1 to 3 months, while maturing, and finally enter the bile ducts to complete the life cycle.

Acute (invasive) fascioliasis manifests with fever, right upper quadrant discomfort, hepatomegaly, and eosinophilia.<sup>456</sup> Infrequently, patients experience respiratory, cardiac, or neurologic symptoms that are believed to be immunoallergic in origin because the organism only rarely appears at these sites.<sup>456</sup> As the flukes course through the liver, they create tracks of necrosis infiltrated by eosinophils, sometimes surrounded by a reaction of palisaded histiocytes (Fig. 11.38).<sup>457,458</sup> These tracks appear as yellow-white subcapsular nodules or cords at laparoscopy.<sup>457,458</sup> Common findings on CT or magnetic resonance imaging (MRI) include the classic picture of multiple lesions which change in position, attenuation, and shape over time; tracklike subcapsular hypodense lesions; and subcapsular hematomas.<sup>459</sup> As the lesions age, they become cavities bound by granulation tissue, fibrous tissue, and calcifications.<sup>458</sup> Immature flukes that fail to reach the liver may produce ectopic abscesses, most often in the skin.<sup>456</sup>

After the flukes penetrate ducts, egg production initiates chronic (obstructive) fascioliasis, characterized by local inflammation, fibrous thickening of the duct wall, ascending cholangitis, episodic biliary pain, and obstructive jaundice.<sup>456</sup> Peripheral eosinophilia is mild or absent in this stage. The flukes attach to the bile duct epithelium using suckers and cause ductal epithelial proliferation, possibly due to their production of proline.<sup>458</sup> Large necrotic granulomas can develop around entrapped eggs, and tissue eosinophilia is typical in these lesions. Adult flukes can be found in the bile ducts or gallbladder, along with stones, hypertrophied muscle coat, and mucosal hyperplasia. Cholangiocarcinoma is not associated with fascioliasis, but development of cirrhosis has been described. Radiologic findings in the chronic phase are nonspecific and may include hepatosplenomegaly, periportal fibrosis, cystic lesions, and calcifications, as well as dilated common bile duct and thickened gallbladder.<sup>459</sup> Diagnosis is made with serologic and antigen-identification tests or stool examination for ova, although the latter is useful only in chronic disease and may be negative if ova production is intermittent.<sup>456</sup>

## Clonorchiasis

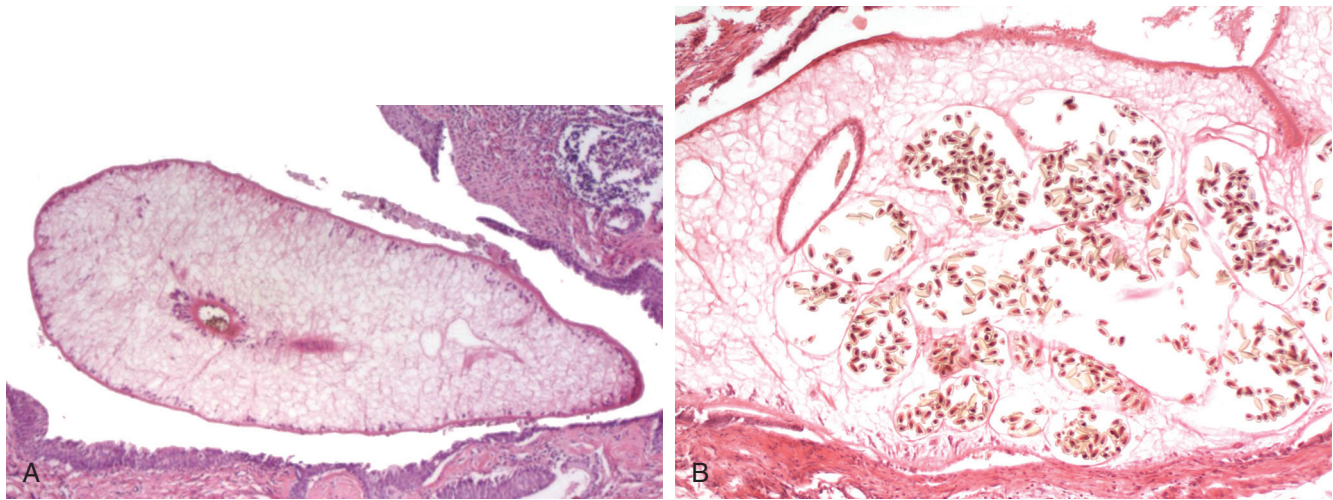
The trematode liver flukes *C. sinensis*, *Opisthorchis viverrini*, and *Opisthorchis felineus* are similar and are usually considered together. *C. sinensis* infects persons in China and east Asia and is common among immigrants to New York City. *O. viverrini* is limited to Thailand, Laos, Vietnam, and Cambodia, and *O. felineus* infects cats and humans in parts of Russia and eastern Europe.<sup>459,460</sup> These bile duct flukes are acquired through ingestion of raw fish containing the metacercariae.<sup>459,460</sup>

In contradistinction to *Fasciola*, the flukes migrate into the ducts via the ampulla of Vater, where they mature in approximately 25 days.<sup>459,460</sup> The adults reside in medium-sized and small intrahepatic ducts and occasionally in the extrahepatic ducts, gallbladder, or pancreatic duct, where they can live for a decade or longer.<sup>459</sup> Human hosts excrete eggs that hatch in water, pass through snails and fish, and infect other humans or animals. Patients are usually asymptomatic but may present with abdominal pain, hepatomegaly, and eosinophilia or with the syndrome of recurrent pyogenic cholangitis.

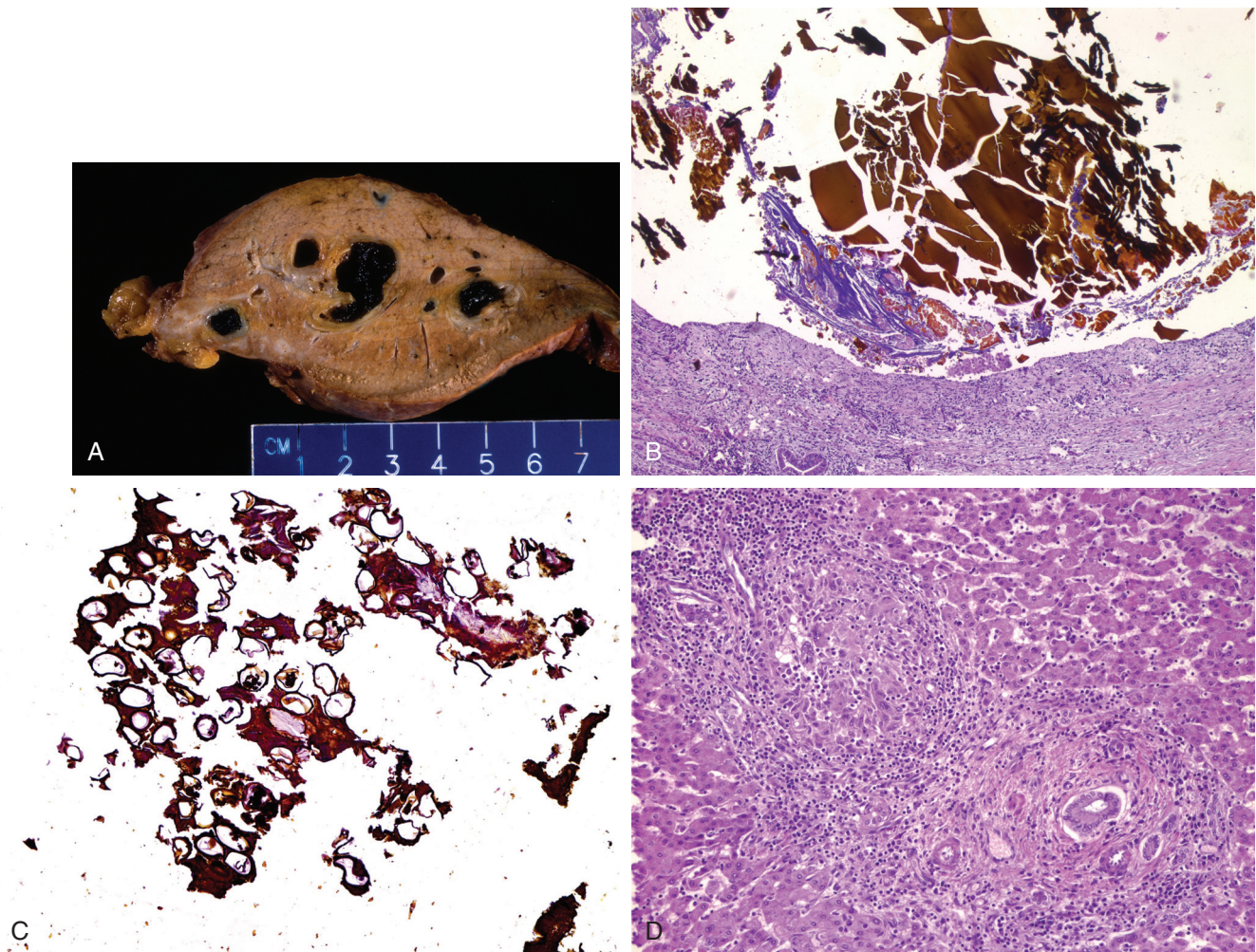
Grossly, focal dilatation of segments of smaller ducts may be seen, with thickened walls and possibly worms in the lumen. The left lobe is affected more often because the left intrahepatic bile duct is straighter and wider, allowing easier access for the worms. Bile ducts that harbor these flukes show dilatation, irregular thickening, adenomatous epithelial hyperplasia, and variable eosinophilia (Fig. 11.39).<sup>459</sup> *Opisthorchis* flukes contain an egg-filled branched uterus flanked by paired ceca.<sup>461</sup> Eggs are not usually seen in tissues. Ascending cholangitis, usually from *E. coli*, can lead to purulent exudates in dilated ducts. Bile duct obstruction can result from the worms, strictures, or calculus formation.<sup>459</sup> Stones often have dead worms as their nidus. Imaging may show intrahepatic duct dilatation, increased periductal echogenicity, and gallbladder sludge. Diagnosis is made by identifying the ova in stool or by ultrasonography. Infection with *O. viverrini* or *C. sinensis* is strongly associated with development of cholangiocarcinoma, which is often intrahepatic, multicentric, and mucin secreting. In fact, *O. viverrini* is considered a group 1 carcinogen. The mechanisms of carcinogenesis in clonorchiasis are not well understood but may be multifactorial. Serology does not distinguish between present and past infection. Therefore the diagnosis of active infection may require the detection of ova in stool.<sup>459</sup>

## Ascariasis

*A. lumbricoides* rarely causes biliary ascariasis when the roundworms, which usually reside in the lumen of the small intestine, ascend the bile duct; this occurs usually in patients who live in endemic areas, have biliary abnormalities, or have undergone sphincterotomy. Although children are infected with *Ascaris* commonly, biliary involvement is rare in children, probably because of the narrow ampulla of Vater and bile duct lumen.<sup>462</sup> Bile duct infestation manifests as biliary colic, obstructive jaundice, or pancreatitis. Dying worms, in conjunction with *E. coli* and other bacteria that they transport into the liver, can cause suppurative cholangitis, liver abscesses, or the syndrome of recurrent pyogenic cholangitis (Fig. 11.40).<sup>248,463,464</sup> Hepatolithiasis in association with ascariasis has also been described.<sup>465</sup> The worms can also penetrate liver tissue (visceral larva migrans), perforate the Glisson capsule, and exit into the subdiaphragmatic space.<sup>248</sup> Adult worms or ova may be present in tissue sections. The ova can cause granulomas and pseudotumors.<sup>466</sup> Bile ducts may show



• **Figure 11.39** *Clonorchis* infestation. **A**, A fluke is present within a large duct that shows squamous metaplasia and periductal chronic inflammation. **B**, Higher magnification shows cross-sections of the uterus filled with ova.



• **Figure 11.40** *Ascaris* infection in a patient with the clinical diagnosis of recurrent pyogenic cholangitis. **A**, Gross photograph of a section of liver shows dilated bile ducts inspissated with darkly stained sludge. **B**, On microscopic examination, the inspissated sludge is found to contain laminated, bile-stained structures suggestive of dead *Ascaris*. **C**, Focally, a collection of *Ascaris* ova is present in the sludge. **D**, Elsewhere in the liver, granulomatous inflammation was seen in the lobules adjacent to portal tracts.

mucosal ulceration and a mixed inflammatory infiltrate associated with embedded ova.<sup>467</sup> Fine-needle aspiration cytology from a liver abscess may reveal numerous fertilized, decorticated *Ascaris* eggs in a background of necrosis, inflammation, and Charcot-Leyden crystals.<sup>468</sup> Ultrasonography can identify worms within the gallbladder or extrahepatic ducts or the presence of a dilated common bile duct.<sup>462</sup> Ova or adult worms can be found in stool in 91% of patients.<sup>462</sup> In some patients the worms exit the ducts spontaneously; in others, antihelminthic therapy or surgery is required, particularly if abscess formation has occurred.<sup>462-464</sup>

## Protozoal Infections of the Liver and Bile Duct

### Amebiasis

Liver abscess is the most common extraintestinal manifestation of amebiasis, which is endemic in several tropical regions of India, Southeast Asia, Central America, and Africa. Amebic liver abscesses most likely arise from hematogenous spread of the trophozoites, probably via the portal circulation.<sup>469</sup> The classic presentation is fever, right upper quadrant pain, and hepatic tenderness.<sup>470</sup> Often, patients with liver abscess have no bowel symptoms, and stool microscopy is negative for *Entamoeba histolytica* trophozoites and cysts.<sup>469</sup> Amebic abscesses are approximately 10 times more common in men; proposed explanations for this disparity include inhibition of amebic growth by iron deficiency anemia (which is common in women in affected areas), hormonal factors, and higher rates of alcohol consumption in men. In North America, patients may present years after travel to an endemic area.<sup>471</sup> Compared with pyogenic liver abscesses, amebic abscesses are more likely to be solitary, are more common in men, and tend to occur in younger patients without underlying liver disease or other comorbidities.<sup>471,472</sup> In the United States the disease commonly affects young Hispanic men from southwestern states.

The histopathologic findings in hepatic amebiasis consist of well-circumscribed regions of dead hepatocytes, liquefied cells, and cellular debris. A rim of connective tissue with few inflammatory cells and amebic trophozoites surrounds the necrotic lesion (Fig. 11.41). The adjacent hepatic parenchyma is often completely unaffected.<sup>469</sup> The number of trophozoites may be

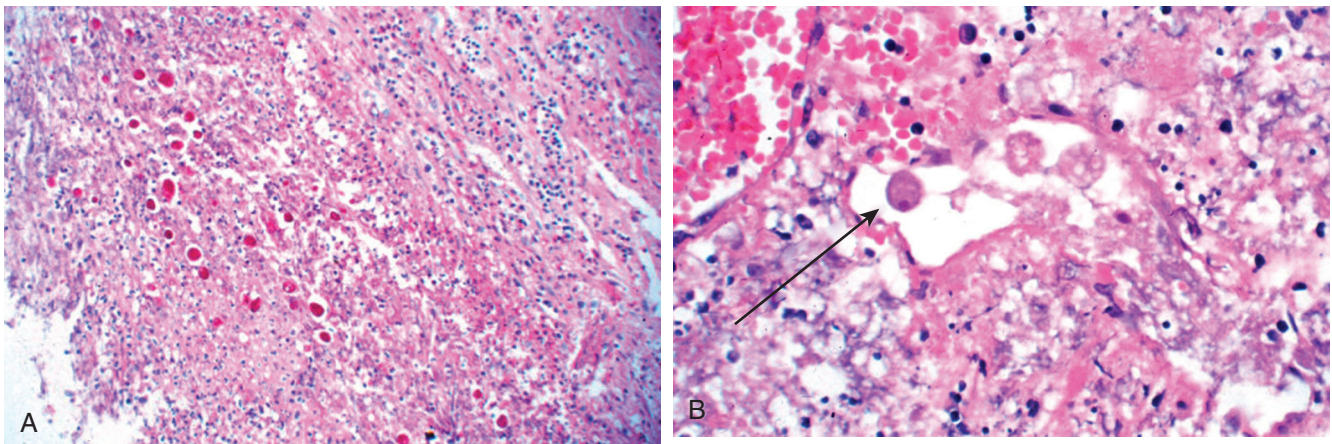
surprisingly small relative to the size of the abscess. The diagnosis is often made by identification of a lesion in the liver in the setting of positive amebic serology.

### Malaria

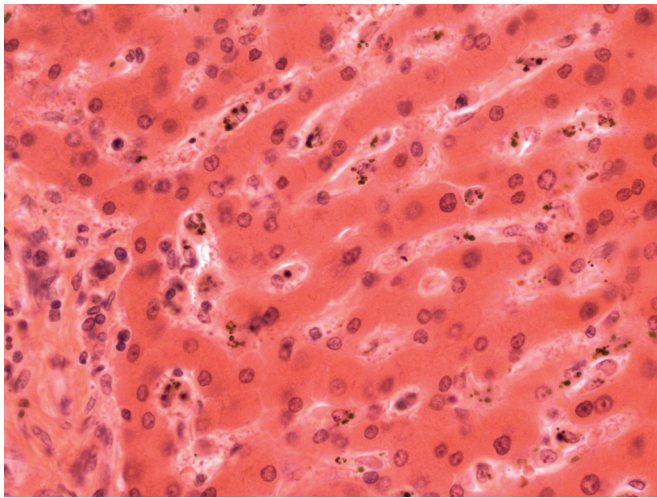
The *Plasmodium* parasite has a life cycle that involves both mosquitoes and humans. When the parasite is first transmitted to a human host, it is incapable of infecting red blood cells and must first pass through the liver. The parasite grows rapidly within hepatocytes, producing merozoites that can infect red blood cells. Through unknown mechanisms, the parasites render hepatocytes resistant to apoptotic signals.<sup>473</sup>

Hepatic dysfunction is well described in malaria, particularly with infection by *Plasmodium falciparum* or mixed infection with both *P. falciparum* and *Plasmodium vivax*, and usually involves mild abnormalities of liver function studies or jaundice, although in some instances there may be a more severe acute hepatitis.<sup>474-476</sup> Hepatic dysfunction has also been reported with *Plasmodium malariae* and *Plasmodium knowlesi*.<sup>477,478</sup> Hepatomegaly and abdominal pain may be seen. The combination of fever and jaundice may lead to a misdiagnosis of acute viral hepatitis. Hepatic encephalopathy is rare but does occur.<sup>479</sup> Hepatic dysfunction and jaundice may be multifactorial in etiology, including hemolysis, sequestration of infected red blood cells in sinusoids, or coexistent viral hepatitis.<sup>476</sup>

The histologic hallmarks of malarial hepatitis are Kupffer cell hyperplasia and deposition of malarial pigment or hemozoin in Kupffer cells and macrophages (Fig. 11.42).<sup>480-483</sup> Hemozoin pigment is coarse and birefringent when examined with polarized light. Pigment is seen throughout the lobule in parasitemic cases but is concentrated in portal areas in nonparasitemic cases, suggesting movement towards portal areas with resolution of infection.<sup>481</sup> The degree of inflammation and hepatocyte injury is generally mild. Sinusoidal congestion and centrilobular necrosis may be caused by adherence of red blood cells in sinusoids, resulting in ischemia. Kupffer cell activation, fatty change, and cholestasis are other common findings.<sup>476,482</sup> Exoerythrocytic forms of the parasite in liver biopsy material can be demonstrated by immunofluorescence.<sup>484</sup> In cases of fatal malaria, examination of the liver at autopsy may also show submassive coagulative-type



• **Figure 11.41** Amebic abscess in the liver. **A**, Low-power view shows the edge of an abscess cavity with inflammation and debris. **B**, High-power view of an amebic trophozoite (arrow) within the necrotic debris. (Courtesy Drs. David Walker and Laura Lamps.)



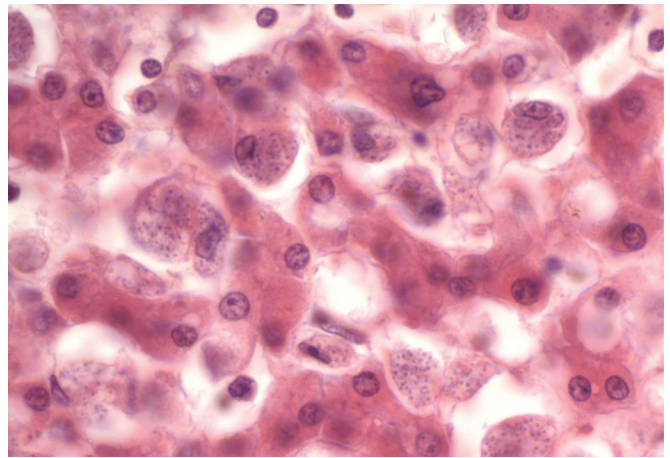
• **Figure 11.42** Malarial pigment within Kupffer Cells.

necrosis, likely as a result of shock and hypoperfusion in the setting of multiorgan system failure.<sup>482</sup>

### Leishmania

Visceral leishmaniasis, or kala-azar, is caused by an obligate intracellular protozoan, *Leishmania donovani*, that is transmitted to humans by the sandfly, *Phlebotomus argentipes*. Worldwide, India has the highest incidence of kala-azar. Children comprise the majority of patients. In southwest Europe, visceral leishmaniasis affects adults, many of whom are coinfecting with HIV.<sup>485</sup> In this population, the majority of patients are intravenous drug users, and the organism is transmitted by the sharing of syringes.<sup>485</sup> In addition, reactivation of latent disease may occur in immunocompromised patients years after travel to endemic areas, making the infection difficult to suspect.<sup>486</sup> The organisms exist as flagellated promastigotes in the gut of female sandflies and as amastigotes in animal or human hosts. In visceral leishmaniasis, an incubation period of 10 days to 1 year is followed by low-grade recurrent fevers, malaise, wasting, anemia, and hepatosplenomegaly.<sup>487</sup> Death follows in 2 to 3 years, commonly from secondary infections.

The accumulation of mononuclear phagocytic cells in infected tissues leads to reticuloendothelial hyperplasia affecting the liver, spleen, intestinal mucosa, bone marrow, and lymph nodes.<sup>487</sup> In the liver, the typical pattern consists of marked hyperplasia of Kupffer cells, many of them parasitized by numerous amastigotes (Fig. 11.43).<sup>488</sup> Well-formed granulomas may be seen alongside Kupffer cells with intracellular amastigotes.<sup>487,489</sup> Other patterns include a nodular pattern, with collections of macrophages, lymphocytes, and plasma cells within the lobules and portal tracts harboring few parasites, and a fibrogenic pattern, with perisinusoidal fibrosis that isolates small groups of liver cells with regenerative changes.<sup>488,490</sup> The differential diagnosis includes *H. capsulatum*, *P. marneffei*, and *Toxoplasma gondii*.<sup>486</sup> Fibrin ring granulomas have been reported.<sup>349,491</sup> The diagnosis depends on demonstration of the organism in tissue, typically bone marrow smears or spleen aspirates.<sup>487</sup> In liver tissue, demonstration of the parasites is best done with Giemsa staining, preferably of touch preparations on glass slides.<sup>484</sup> The presence of an eccentrically located rodlike kinetoplast on Giemsa stain is characteristic of *Leishmania* and distinguishes this parasite from *Histoplasma* and



• **Figure 11.43** Visceral leishmaniasis (kala-azar) in the liver. In the sinusoids, Kupffer cells are filled with amastigotes.

trophozoites of *T. gondii*.<sup>484</sup> In addition, *Leishmania*, unlike *Histoplasma*, lacks a cell wall and is negative on PAS and silver impregnation stains. Immunohistochemical stains and serologic assays are available.

### Toxoplasmosis

*T. gondii* is an obligate intracellular parasite usually acquired from ingestion of undercooked pork or lamb, or transplacentally. Cats are a major reservoir. Disseminated infection occurs in bone marrow and solid organ transplant recipients and in AIDS patients. Hepatitis has been reported in apparently healthy persons during acute infection; these patients present with jaundice, rash, and elevated levels of transaminases and alkaline phosphatase.<sup>492-495</sup>

Histologically, *Toxoplasma* hepatitis is characterized as a diffuse hepatitis with infiltration of portal tracts and sinusoids by mononuclear cells associated with focal hepatic necrosis, similar to EBV or CMV hepatitis.<sup>492-494</sup> Granulomatous hepatitis has also been described.<sup>495</sup> In some cases, bradyzoite-containing *Toxoplasma* cysts have been identified in histiocytes and granulomas or within the hepatic parenchyma.<sup>493-496</sup> Free tachyzoites have been described within degenerating or necrotic hepatocytes, although they can be difficult to distinguish from detritus.<sup>492,495</sup> Giemsa stain, PAS, immunohistochemical stains, or immunofluorescent stains may assist in the detection of organisms in tissue. Serologic assay for IgM antibodies to *T. gondii* can be used to establish the diagnosis.

### Cryptosporidiosis

*Cryptosporidium* is a protozoan that causes an opportunistic infection of the gastrointestinal tract, resulting in diarrhea. In patients with AIDS or other immunocompromised states, including primary immunodeficiency syndromes and solid organ transplantation, the organism has been known to infect the biliary tree, producing a syndrome similar to PSC.<sup>147,497-501</sup> The incidence of *Cryptosporidium* biliary infection is particularly high in patients with X-linked hyper-IgM syndrome; these patients lack the CD40 receptor CD40L, which suggests an essential role of the CD40-CD40L interaction in the immune response to *Cryptosporidium*.<sup>500-503</sup> Signs and symptoms include right upper quadrant abdominal pain, nausea, vomiting, fever, and



biochemical evidence of anicteric cholestasis.<sup>147</sup> Dilatation of the common bile duct is often seen on ultrasonography or CT scanning, and cholangiography reveals attenuation and pruning of duct branches, stricturing and beading of the proximal intrahepatic bile ducts, and dilatation or stricturing of the extrahepatic duct.<sup>147,503,504</sup> The histologic picture reflects the intense periductal inflammatory response elicited by the organism, with portal edema, inflammation, and hyperplastic periductal glands. The biliary epithelium may be reactive or frankly necrotic. Some cases may show prominent periductal “onion-skinning” fibrosis with minimal inflammation, indistinguishable from PSC.<sup>499</sup> Portal fibrosis and ductular reaction may develop, and progression to biliary-type cirrhosis has been reported.<sup>497,502</sup> Organisms can be detected on the luminal surface of the epithelial lining of small biliary radicles, peribiliary glands, the pancreatic duct, and the gallbladder.<sup>147,498,501</sup> Concomitant CMV infection may be found. *Cryptosporidium*-associated sclerosing cholangitis may lead to biliary dysplasia and cholangiocarcinoma in patients with X-linked hyper-IgM syndrome.<sup>500,502,504</sup> Although the organism may be cleared in non-AIDS patients, leading to resolution of liver disease, the infection appears difficult or impossible to cure in AIDS patients.

## References

- Martin A, Lemon SM. Hepatitis A virus: from discovery to vaccines. *Hepatology*. 2006;43:S164-S172.
- Leach CT. Hepatitis A in the United States. *Pediatr Infect Dis J*. 2004;23:551-552.
- Skoog SM, Rivard RE, Batts KP, Smith CI. Autoimmune hepatitis preceded by acute hepatitis A infection. *Am J Gastroenterol*. 2002;97(6):1568-1569.
- Huppertz HI, Treichel U, Gassel AM, Jeschke R, Meyer zum Büschenfelde KH. Autoimmune hepatitis following hepatitis A virus infection. *J Hepatol*. 1995;23:204-208.
- Hilzenrat N, Zilberman D, Klein T, Zur B, Sikuler E. Autoimmune hepatitis in a genetically susceptible patient: is it triggered by acute viral hepatitis A? *Dig Dis Sci*. 1999;44:1950-1952.
- Vento S, Garofano T, Di Perri G, Dolci L, Concia E, Bassetti D. Identification of hepatitis A virus as a trigger for autoimmune chronic hepatitis type 1 in susceptible individuals. *Lancet*. 1991;337:1183-1187.
- Goldin RD. Viral hepatitis. *Curr Diagn Pathol*. 1994;1:70-76.
- Ruel M, Sevestre H, Henry-Biabaud E, Courouce AM, Capron JP, Erlinger S. Fibrin ring granulomas in hepatitis A. *Dig Dis Sci*. 1992;37:1915-1917.
- Ponz E, Garcia-Pagan JC, Bruguera M, Bruix J, Rodés J. Hepatic fibrin-ring granulomas in a patient with hepatitis A. *Gastroenterology*. 1991;100:268-270.
- Pungpapong S, Kim WR, Poterucha JJ. Natural history of hepatitis B virus infection: an update for clinicians. *Mayo Clin Proc*. 2007;82:967-975.
- Lai CL, Ratziu V, Yuen MF, Poynard T. Viral hepatitis B. *Lancet*. 2003;362:2089-2094.
- Hunt CM, McGill JM, Allen MI, Condrey LD. Clinical relevance of hepatitis B viral mutations. *Hepatology*. 2000;31:1037-1044.
- Akuta N, Kumada H. Influence of hepatitis B virus genotypes on the response to antiviral therapies. *J Antimicrob Chemother*. 2005;55:139-142.
- Trepo C, Guillemin L. Polyarteritis nodosa and extrahepatic manifestations of HBV infection: the case against autoimmune intervention in pathogenesis. *J Autoimmun*. 2001;16:269-274.
- Terrault NA, Bzowej NH, Chang KM, et al. AASLD guidelines for treatment of chronic hepatitis B. *Hepatology*. 2016;63:261-283.
- Fattovich G, Bortolotti F, Donato F. Natural history of chronic hepatitis B: special emphasis on disease progression and prognostic factors. *J Hepatol*. 2008;48:335-352.
- Hsu YS, Chien RN, Yeh CT, et al. Long-term outcome after spontaneous HBeAg seroconversion in patients with chronic hepatitis B. *Hepatology*. 2002;35:1522-1527.
- Ishak KG. Chronic hepatitis: morphology and nomenclature. *Mod Pathol*. 1994;7:690-713.
- Naoumov NV, Portmann BC, Tedder RS, et al. Detection of hepatitis B virus antigens in liver tissue: a relation to viral replication and histology in chronic hepatitis B infection. *Gastroenterology*. 1990;99:1248-1253.
- Hsu HC, Lai MY, Su IJ, et al. Correlation of hepatocyte HBsAg expression with virus replication and liver pathology. *Hepatology*. 1988;8:749-754.
- Chu CM, Yeh CT, Chien RN, Sheen IS, Liaw YF. The degrees of hepatocyte nuclear but not cytoplasmic expression of hepatitis B core antigen reflect the level of viral replication in chronic hepatitis B virus infection. *J Clin Microbiol*. 1997;35:102-105.
- Huang YH, Hung HH, Chan CC, et al. Core antigen expression is associated with hepatic necroinflammation in e antigen-negative chronic hepatitis B patients with low DNA loads. *Clin Vaccine Immunol*. 2010;17:1048-1053.
- Locarnini S, Hatzakis A, Chen DS, Lok A. Strategies to control hepatitis B: public policy, epidemiology, vaccine and drugs. *J Hepatol*. 2015;62:S76-S86.
- Nguyen MH, Garcia RT, Trinh HN, et al. Histological disease in Asian-Americans with chronic hepatitis B, high hepatitis B virus DNA, and normal alanine aminotransferase levels. *Am J Gastroenterol*. 2009;104:2206-2213.
- Thomson EC, Main J. Advances in hepatitis B and C. *Curr Opin Infect Dis*. 2004;17:449-459.
- Walker N, Apel R, Kerlin P, et al. Hepatitis B virus infection in liver allografts. *Am J Surg Pathol*. 1993;17:666-677.
- Harrison RF, Davies MH, Goldin RD, Hubscher SG. Recurrent hepatitis B in liver allografts: a distinctive form of rapidly developing cirrhosis. *Histopathology*. 1993;23:21-28.
- Davies SE, Portmann BC, O'Grady JG, et al. Hepatic histological findings after transplantation for chronic hepatitis B virus infection, including a unique pattern of fibrosing cholestatic hepatitis. *Hepatology*. 1991;13:150-157.
- Benner KG, Lee RG, Keeffe EB, Lopez RR, Sasaki AW, Pinson CW. Fibrosing cytolytic liver failure secondary to recurrent hepatitis B after liver transplantation. *Gastroenterology*. 1992;103:1307-1312.
- Fang JW, Wright TL, Lau JY. Fibrosing cholestatic hepatitis in patient with HIV and hepatitis B. *Lancet*. 1993;342:1175.
- McIvor C, Morton J, Bryant A, Cooksley WG, Durrant S, Walker N. Fatal reactivation of precore mutant hepatitis B virus associated with fibrosing cholestatic hepatitis after bone marrow transplantation. *Ann Intern Med*. 1994;121:274-275.
- Sulkowski MS. Viral hepatitis and HIV coinfection. *J Hepatol*. 2008;48:353-367.
- Thimme R, Spangenberg HC, Blum HE. Hepatitis B or hepatitis C and human immunodeficiency virus infection. *J Hepatol*. 2005;42(suppl 1):S37-S44.
- Webster DP, Klenerman P, Dusheiko GM. Hepatitis C. *Lancet*. 2015;385:1124-1135.
- Wong T, Lee SS. Hepatitis C: a review for primary care physicians. *Can Med Assoc J*. 2006;174:649-659.
- Giannini C, Brechot C. Hepatitis C virus biology. *Cell Death Differ*. 2003;10(suppl 1):S27-S38.
- Orland JR, Wright TL, Cooper S. Acute hepatitis C. *Hepatology*. 2001;33:321-327.
- Zein NN. Clinical significance of hepatitis C virus genotypes. *Clin Microbiol Rev*. 2000;13:223-235.
- Mondelli MU, Silini E. Clinical significance of hepatitis C virus genotypes. *J Hepatol*. 1999;31(suppl 1):65-70.

40. Hatzakis A, Katsoulidou A, Kaklamani E, et al. Hepatitis C virus 1b is the dominant genotype in HCV-related carcinogenesis: a case-control study. *Int J Cancer*. 1996;68:51-53.
41. Marcellin P. Hepatitis C: the clinical spectrum of the disease. *J Hepatol*. 1999;31(suppl 1):9-16.
42. Mondelli MU, Cerino A, Cividini A. Acute hepatitis C: diagnosis and management. *J Hepatol*. 2005;42(suppl 1):S108-S114.
43. Chung RT. Acute hepatitis C virus infection. *Clin Infect Dis*. 2005;41(suppl 1):S14-S17.
44. Caruntu FA, Benea L. Acute hepatitis C virus infection: diagnosis, pathogenesis, treatment. *J Gastrointest Liver Dis*. 2006;15:249-256.
45. Gerlach JT, Diepolder HM, Zachoval R, et al. Acute hepatitis C: high rate of both spontaneous and treatment-induced viral clearance. *Gastroenterology*. 2003;125:80-88.
46. Obermayer-Straub P, Manns MP. Hepatitis C and D, retroviruses and autoimmune manifestations. *J Autoimmun*. 2001;16:275-285.
47. Cassani F, Cataleta M, Valentini P, et al. Serum autoantibodies in chronic hepatitis C: comparison with autoimmune hepatitis and impact on the disease profile. *Hepatology*. 1997;26:561-566.
48. Scheuer PJ, Ashrafzadeh P, Sherlock S, Brown D, Dusheiko GM. The pathology of hepatitis C. *Hepatology*. 1992;15:567-571.
49. Syed SI, Sadiq S. Immunohistochemical detection of hepatitis C virus (HCV) in liver biopsies of hepatitis C patients. *J Pak Med Assoc*. 2011;61:1198-1201.
50. Li G, Li K, Lea AS, et al. In situ hybridization for the detection of hepatitis C virus RNA in human liver tissue. *J Viral Hepat*. 2013;20:183-192.
51. Negro F. Hepatitis C virus and liver steatosis: when fat is not beautiful. *J Hepatol*. 2004;40:533-535.
52. Castera L, Chouteau P, Hezode C, Zafrani ES, Dhumeaux D, Pawlotsky JM. Hepatitis C virus-induced hepatocellular steatosis. *Am J Gastroenterol*. 2005;100:711-715.
53. Gaya DR, Thorburn D, Oien KA, Morris AJ, Stanley AJ. Hepatic granulomas: a 10 year single centre experience. *J Clin Pathol*. 2003;56:850-853.
54. Emile JF, Sebah M, Feray C, David F, Reynès M. The presence of epithelioid granulomas in hepatitis C virus-related cirrhosis. *Hum Pathol*. 1993;24:1095-1097.
55. Goldin RD, Levine TS, Foster GR, Thomas HC. Granulomas and hepatitis C. *Histopathology*. 1996;28:265-267.
56. Harada K, Minato H, Hiramatsu K, Nakanuma Y. Epithelioid cell granulomas in chronic hepatitis C: immunohistochemical character and histological marker of favourable response to interferon-alpha therapy. *Histopathology*. 1998;33:216-221.
57. Veerabagu MP, Finkelstein SD, Rabinovitz M. Granulomatous hepatitis in a patient with chronic hepatitis C treated with interferon-alpha. *Dig Dis Sci*. 1997;42:1445-1448.
58. Propst A, Propst T, Dietze O, Kathrein H, Judmeier G, Vogel W. Development of granulomatous hepatitis during treatment with interferon-alpha 2b. *Dig Dis Sci*. 1995;40:2117-2118.
59. Mert A, Tabak F, Ozaras R, Tahan V, Senturk H, Ozbay G. Hepatic granulomas in chronic hepatitis C. *J Clin Gastroenterol*. 2001;33:342-343.
60. Shiffman ML, Sterling RK, Contos M, et al. Long term changes in liver histology following treatment of chronic hepatitis C virus. *Ann Hepatol*. 2014;13:340-349.
61. Lee YA, Friedman SL. Reversal, maintenance or progression: what happens to the liver after a virologic cure of hepatitis C? *Antiviral Res*. 2014;107:23-30.
62. Pawlotsky JM, Feld JJ, Zeuzem S, Hoofnagle JH. From non-A, non-B hepatitis to hepatitis C virus cure. *J Hepatol*. 2015;62:S87-S99.
63. Bertino G, Ardiri A, Proiti M, et al. Chronic hepatitis C: this and the new era of treatment. *World J Hepatol*. 2016;8:92-106.
64. Vasuri F, Malvi D, Gruppioni E, et al. Histopathological evaluation of recurrent hepatitis C after liver transplantation: a review. *World J Gastroenterol*. 2014;20:2811-2824.
65. Greenson JK, Svoboda-Newman SM, Merion RM, Frank TS. Histologic progression of recurrent hepatitis C in liver transplant allografts. *Am J Surg Pathol*. 1996;20:731-738.
66. Schluger LK, Sheiner PA, Thung SN, et al. Severe recurrent cholestatic hepatitis C following orthotopic liver transplantation. *Hepatology*. 1996;23:971-976.
67. Rosenberg PM, Farrell JJ, Abraczinskas DR, Graeme-Cook FM, Dienstag JL, Chung RT. Rapidly progressive fibrosing cholestatic hepatitis: hepatitis C virus in HIV coinfection. *Am J Gastroenterol*. 2002;97:478-483.
68. Lim HL, Lau GK, Davis GL, Dolson DJ, Lau JY. Cholestatic hepatitis leading to hepatic failure in a patient with organ-transmitted hepatitis C virus infection. *Gastroenterology*. 1994;106:248-251.
69. Zylberberg H, Carnot F, Mamzer MF, Blanche G, Legendre C, Pol S. Hepatitis C virus-related fibrosing cholestatic hepatitis after renal transplantation. *Transplantation*. 1997;63:158-160.
70. Toth CM, Pascual M, Chung RT, et al. Hepatitis C virus-associated fibrosing cholestatic hepatitis after renal transplantation: response to interferon-alpha therapy. *Transplantation*. 1998;66:1254-1258.
71. Makris M, Preston FE, Rosendaal FR, Underwood JC, Rice KM, Triger DR. The natural history of chronic hepatitis C in haemophiliacs. *Br J Haematol*. 1996;94:746-752.
72. Hanley JP, Jarvis LM, Andrews J, et al. Investigation of chronic hepatitis C infection in individuals with haemophilia: assessment of invasive and non-invasive methods. *Br J Haematol*. 1996;94:159-165.
73. Farci P, Niro GA. Clinical features of hepatitis D. *Semin Liver Dis*. 2012;32:228-236.
74. McFarlane BM, Bridger CB, Smith HM, et al. Autoimmune mechanisms in chronic hepatitis B and delta virus infections. *Eur J Gastroenterol Hepatol*. 1995;7:615-621.
75. Verme G, Amoroso P, Lettieri G, et al. A histological study of hepatitis delta virus liver disease. *Hepatology*. 1986;6:1303-1307.
76. Popper H, Thung SN, Gerber MA, et al. Histologic studies of severe delta agent infection in Venezuelan Indians. *Hepatology*. 1983;3:906-912.
77. Kabacam G, Wedemeyer H, Savas B, et al. Role of immunohistochemistry for hepatitis D and hepatitis B virus in hepatitis delta. *Liver Int*. 2014;34:1207-1215.
78. Emerson SU, Purcell RH. Hepatitis E. *Pediatr Infect Dis J*. 2007;26:1147-1148.
79. Wang L, Zhuang H. Hepatitis E: an overview and recent advances in vaccine research. *World J Gastroenterol*. 2004;10:2157-2162.
80. Davern TJ, Chalasani N, Fontana RJ, et al. Acute hepatitis E infection accounts for some cases of suspected drug-induced liver injury. *Gastroenterology*. 2011;141:1665-72.e1-1665-72.e9.
81. Terzic D, Dupanovic B, Mugosa B, Draskovic N, Svrtlih N. Acute hepatitis E in Montenegro: epidemiology, clinical and laboratory features. *Ann Hepatol*. 2009;8:203-206.
82. Kamar N, Garrouste C, Haagsma EB, et al. Factors associated with chronic hepatitis in patients with hepatitis E virus infection who have received solid organ transplants. *Gastroenterology*. 2011;140:1481-1489.
83. Protzer U, Bohm F, Longereich T, et al. Molecular detection of hepatitis E virus (HEV) in liver biopsies after liver transplantation. *Mod Pathol*. 2015;28:523-532.
84. Kuniholm MH, Ong E, Hogema BM, et al. Acute and chronic hepatitis E virus infection in human immunodeficiency virus-infected U.S. women. *Hepatology*. 2016;63:712-720.
85. Haagsma EB, van den Berg AP, Porte RJ, et al. Chronic hepatitis E virus infection in liver transplant recipients. *Liver Transpl*. 2008;14:547-553.
86. Mansuy JM, Gallian P, Dimeglio C, et al. A nationwide survey of hepatitis E viral infection in French blood donors. *Hepatology*. 2016;63:1145-1154.
87. Kuniholm MH, Purcell RH, McQuillan GM, Engle RE, Wasley A, Nelson KE. Epidemiology of hepatitis E virus in the United

- States: results from the Third National Health and Nutrition Examination Survey, 1988–1994. *J Infect Dis.* 2009;200:48–56.
88. Agrawal V, Goel A, Rawat A, Naik S, Aggarwal R. Histological and immunohistochemical features in fatal acute fulminant hepatitis E. *Indian J Pathol Microbiol.* 2012;55:22–27.
  89. Malcolm P, Dalton H, Hussaini HS, Mathew J. The histology of acute autochthonous hepatitis E virus infection. *Histopathology.* 2007;51:190–194.
  90. Peron JM, Danjoux M, Kamar N, et al. Liver histology in patients with sporadic acute hepatitis E: a study of 11 patients from South-West France. *Virchows Arch.* 2007;450:405–410.
  91. Reshetnyak VI, Karlovich TI, Ilchenko LU. Hepatitis G virus. *World J Gastroenterol.* 2008;14:4725–4734.
  92. Mohr EL, Stapleton JT. GB virus type C interactions with HIV: the role of envelope glycoproteins. *J Viral Hepat.* 2009;16:757–768.
  93. Stapleton JT, Fong S, Muerhoff AS, Bukh J, Simmonds P. The GB viruses: a review and proposed classification of GBV-A, GBV-C (HGV), and GBV-D in genus Pegivirus within the family *Flaviviridae*. *J Gen Virol.* 2011;92:233–246.
  94. Vento S, Guella L, Mirandola F, et al. Epstein-Barr virus as a trigger for autoimmune hepatitis in susceptible individuals. *Lancet.* 1995;346:608–609.
  95. Cauldwell K, Williams R. Unusual presentation of Epstein-Barr virus hepatitis treated successfully with valganciclovir. *J Med Virol.* 2014;86:484–486.
  96. Kimura H, Nagasaka T, Hoshino Y, et al. Severe hepatitis caused by Epstein-Barr virus without infection of hepatocytes. *Hum Pathol.* 2001;32:757–762.
  97. Sanchez F, Gimeno-Bayon JL, Esgueva R, Alvarez F, Munné MA, Serrano S. Fatal liver failure: molecular evidence for chronic active Epstein-Barr virus infection. *Ann Diagn Pathol.* 2008;12:368–371.
  98. White NJ, Juel-Jensen BE. Infectious mononucleosis hepatitis. *Semin Liver Dis.* 1984;4:301–306.
  99. Feranchak AP, Tyson RW, Narkewicz MR, Karrer FM, Sokol RJ. Fulminant Epstein-Barr viral hepatitis: orthotopic liver transplantation and review of the literature. *Liver Transpl Surg.* 1998;4:469–476.
  100. Alshak NS, Jimenez AM, Gedebo M, et al. Epstein-Barr virus infection in liver transplantation patients: correlation of histopathology and semiquantitative Epstein-Barr virus-DNA recovery using polymerase chain reaction. *Hum Pathol.* 1993;24:1306–1312.
  101. Biest S, Schubert TT. Chronic Epstein-Barr virus infection: a cause of granulomatous hepatitis? *J Clin Gastroenterol.* 1989;11:343–346.
  102. Nenert M, Mavier P, Dubuc N, Deforges L, Zafrani ES. Epstein-Barr virus infection and hepatic fibrin-ring granulomas. *Hum Pathol.* 1988;19:608–610.
  103. Suh N, Liapis H, Misdraji J, Brunt EM, Wang HL. Epstein-Barr virus hepatitis: diagnostic value of in situ hybridization, polymerase chain reaction, and immunohistochemistry on liver biopsy from immunocompetent patients. *Am J Surg Pathol.* 2007;31:1403–1409.
  104. Shibata Y, Kitajima N, Kawada J, et al. Association of *cytomegalovirus* with infantile hepatitis. *Microbiol Immunol.* 2005;49:771–777.
  105. Bellomo-Brandao MA, Andrade PD, Costa SC, et al. *Cytomegalovirus* frequency in neonatal intrahepatic cholestasis determined by serology, histology, immunohistochemistry and PCR. *World J Gastroenterol.* 2009;15:3411–3416.
  106. Lurie M, Elmalach I, Schuger L, et al. Liver findings in infantile *cytomegalovirus* infection: similarity to extrahepatic biliary obstruction. *Histopathology.* 1987;11:1171–1180.
  107. Tarr PI, Haas JE, Christie DL. Biliary atresia, *cytomegalovirus*, and age at referral. *Pediatrics.* 1996;97:828–831.
  108. De Tommaso AM, Andrade PD, Costa SC, Escanhoela CA, Hessel G. High frequency of human *cytomegalovirus* DNA in the liver of infants with extrahepatic neonatal cholestasis. *BMC Infect Dis.* 2005;5:108.
  109. Fischler B, Ehrnst A, Forsgren M, Orvell C, Nemeth A. The viral association of neonatal cholestasis in Sweden: a possible link between *cytomegalovirus* infection and extrahepatic biliary atresia. *J Pediatr Gastroenterol Nutr.* 1998;27:57–64.
  110. Washington K. Update on post-liver transplantation infections, malignancies, and surgical complications. *Adv Anat Pathol.* 2005;12:221–226.
  111. Bonkowsky HL, Lee RV, Klatskin G. Acute granulomatous hepatitis: occurrence in *cytomegalovirus* mononucleosis. *J Am Med Assoc.* 1975;233:1284–1288.
  112. Clarke J, Craig RM, Saffro R, Murphy P, Yokoo H. *Cytomegalovirus* granulomatous hepatitis. *Am J Med.* 1979;66:264–269.
  113. Lobdell DH. “Ring” granulomas in *cytomegalovirus* hepatitis. *Arch Pathol Lab Med.* 1987;111:881–882.
  114. Colina F, Juca NT, Moreno E, et al. Histological diagnosis of *cytomegalovirus* hepatitis in liver allografts. *J Clin Pathol.* 1995;48:351–357.
  115. Toomey DP, Dhadda AS, Sanni LA, et al. Fatal herpes simplex virus hepatitis following neoadjuvant chemoradiotherapy and anterior resection for rectal cancer. *Ann R Coll Surg Engl.* 2014;96:e12–e14.
  116. Goodman ZD, Ishak KG, Sesterhenn IA. Herpes simplex hepatitis in apparently immunocompetent adults. *Am J Clin Pathol.* 1986;85:694–699.
  117. Fingerth JD. Herpesvirus infection of the liver. *Infect Dis Clin North Am.* 2000;14:689–719.
  118. Ronan BA, Agrwal N, Carey EJ, et al. Fulminant hepatitis due to human adenovirus. *Infection.* 2014;42:105–111.
  119. Krilov LR, Rubin LG, Frogel M, et al. Disseminated adenovirus infection with hepatic necrosis in patients with human immunodeficiency virus infection and other immunodeficiency states. *Rev Infect Dis.* 1990;12:303–307.
  120. Janner D, Petru AM, Belchis D, Azimi PH. Fatal adenovirus infection in a child with acquired immunodeficiency syndrome. *Pediatr Infect Dis J.* 1990;9:434–436.
  121. Hatakka A, Klein J, He R, Piper J, Tam E, Walkty A. Acute hepatitis as a manifestation of parvovirus B19 infection. *J Clin Microbiol.* 2011;49:3422–3424.
  122. Sokal EM, Melchior M, Cornu C, et al. Acute parvovirus B19 infection associated with fulminant hepatitis of favourable prognosis in young children. *Lancet.* 1998;352:1739–1741.
  123. Langnas AN, Markin RS, Cattral MS, Naides SJ. Parvovirus B19 as a possible causative agent of fulminant liver failure and associated aplastic anemia. *Hepatology.* 1995;22:1661–1665.
  124. Yoto Y, Kudoh T, Haseyama K, Suzuki N, Chiba S. Human parvovirus B19 infection associated with acute hepatitis. *Lancet.* 1996;347:868–869.
  125. Pinho JR, Alves VA, Vieira AF, et al. Detection of human parvovirus B19 in a patient with hepatitis. *Braz J Med Biol Res.* 2001;34:1131–1138.
  126. Abe K, Kiuchi T, Tanaka K, Edamoto Y, Aiba N, Sata T. Characterization of erythrovirus B19 genomes isolated in liver tissues from patients with fulminant hepatitis and biliary atresia who underwent liver transplantation. *Int J Med Sci.* 2007;4:105–109.
  127. Lee WM, Brown KE, Young NS, et al. Brief report: no evidence for parvovirus B19 or hepatitis E virus as a cause of acute liver failure. *Dig Dis Sci.* 2006;51:1712–1715.
  128. Wong S, Young NS, Brown KE. Prevalence of parvovirus B19 in liver tissue: no association with fulminant hepatitis or hepatitis-associated aplastic anemia. *J Infect Dis.* 2003;187:1581–1586.
  129. Mogensen TH, Jensen JM, Hamilton-Dutoit S, Larsen CS. Chronic hepatitis caused by persistent parvovirus B19 infection. *BMC Infect Dis.* 2010;10:246.
  130. Eis-Hubinger AM, Reber U, Abdul-Nour T, Glatzel U, Lauschke H, Pütz U. Evidence for persistence of parvovirus B19 DNA in livers of adults. *J Med Virol.* 2001;65:395–401.
  131. Wang C, Heim A, Schlaphoff V, et al. Intrahepatic long-term persistence of parvovirus B19 and its role in chronic viral hepatitis. *J Med Virol.* 2009;81:2079–2088.

132. Toan NL, Song le H, Kreamsner PG, et al. Co-infection of human parvovirus B19 in Vietnamese patients with hepatitis B virus infection. *J Hepatol*. 2006;45:361-369.
133. Hsu TC, Chen TY, Lin MC, Tzang BS, Tsay GJ. Human parvovirus B19 infection in patients with chronic hepatitis B or hepatitis C infection. *J Gastroenterol Hepatol*. 2005;20:733-738.
134. Tameda Y, Kosaka Y, Shiraki K, et al. Hepatitis in an adult with rubella. *Intern Med*. 1993;32:580-583.
135. Onji M, Kumon I, Kanaoka M, Miyaoka H, Ohta Y. Intrahepatic lymphocyte subpopulations in acute hepatitis in an adult with rubella. *Am J Gastroenterol*. 1988;83:320-322.
136. Figueiredo CA, de Oliveira MI, Tarandachi PR, de Carvalho WB, Kanamura CT, Scatena Rdos S. Fatal acute liver failure in a child due to acquired rubella infection. *J Clin Virol*. 2014;61:1-2.
137. McLellan RK, Gleiner JA. Acute hepatitis in an adult with rubeola. *J Am Med Assoc*. 1982;247:2000-2001.
138. Cheeseman SH, Cleveland RH, Mark EJ. Case records of the Massachusetts General Hospital: weekly clinicopathological exercises. Case 34-1988: progressive pulmonary consolidations in a 11-year-old boy with Evans' syndrome. *N Engl J Med*. 1988;319:495-509.
139. Chau TN, Lee KC, Yao H, et al. SARS-associated viral hepatitis caused by a novel coronavirus: report of three cases. *Hepatology*. 2004;39:302-310.
140. Boag FC, Dean R, Hawkins DA, Lawrence AG, Gazzard BG. Abnormalities of liver function during HIV seroconversion illness. *Int J STD AIDS*. 1992;3:46-48.
141. Molina JM, Welker Y, Ferchal F, Decazes JM, Shenmetzler C, Modai J. Hepatitis associated with primary HIV infection. *Gastroenterology*. 1992;102:739.
142. Steeper TA, Rosenstein H, Weiser J, Inampudi S, Snover DC. Bacillary epithelioid angiomatosis involving the liver, spleen, and skin in an AIDS patient with concurrent Kaposi's sarcoma. *Am J Clin Pathol*. 1992;97:713-718.
143. Perkocha LA, Geaghan SM, Yen TS, et al. Clinical and pathological features of bacillary peliosis hepatitis in association with human immunodeficiency virus infection. *N Engl J Med*. 1990;323:1581-1586.
144. Jagadha V, Andavolu RH, Huang CT. Granulomatous inflammation in the acquired immune deficiency syndrome. *Am J Clin Pathol*. 1985;84:598-602.
145. Terada S, Reddy KR, Jeffers LJ, Cali A, Schiff ER. Microsporidian hepatitis in the acquired immunodeficiency syndrome. *Ann Intern Med*. 1987;107:61-62.
146. Beaugerie L, Teilhac MF, Deluol AM, et al. Cholangiopathy associated with Microsporidia infection of the common bile duct mucosa in a patient with HIV infection. *Ann Intern Med*. 1992;117:401-402.
147. Teixidor HS, Godwin TA, Ramirez EA. Cryptosporidiosis of the biliary tract in AIDS. *Radiology*. 1991;180:51-56.
148. Pol S, Romana CA, Richard S, et al. Microsporidia infection in patients with the human immunodeficiency virus and unexplained cholangitis. *N Engl J Med*. 1993;328:95-99.
149. Cello JP. Acquired immunodeficiency syndrome cholangiopathy: spectrum of disease. *Am J Med*. 1989;86:539-546.
150. Forbes A, Blanshard C, Gazzard B. Natural history of AIDS related sclerosing cholangitis: a study of 20 cases. *Gut*. 1993;34:116-121.
151. Hasan FA, Jeffers LJ, Welsh SW, Reddy KR, Schiff ER. Hepatic involvement as the primary manifestation of Kaposi's sarcoma in the acquired immune deficiency syndrome. *Am J Gastroenterol*. 1989;84:1449-1451.
152. O'Leary JG, Zachary K, Misdraji J, Chung RT. De novo autoimmune hepatitis during immune reconstitution in an HIV-infected patient receiving highly active antiretroviral therapy. *Clin Infect Dis*. 2008;46:e12-e14.
153. Howard CR, Ellis DS, Simpson DI. Exotic viruses and the liver. *Semin Liver Dis*. 1984;4:361-374.
154. Quaresma JA, Duarte MI, Vasconcelos PF. Midzonal lesions in yellow fever: a specific pattern of liver injury caused by direct virus action and in situ inflammatory response. *Med Hypotheses*. 2006;67:618-621.
155. Francis TI, Moore DL, Edington GM, Smith JA. A clinicopathological study of human yellow fever. *Bull World Health Organ*. 1972;46:659-667.
156. Monath TP, Barrett AD. Pathogenesis and pathophysiology of yellow fever. *Adv Virus Res*. 2003;60:343-395.
157. Ishak KG, Walker DH, Coetzer JA, Gardner JJ, Gorelkin L. Viral hemorrhagic fevers with hepatic involvement: pathologic aspects with clinical correlations. *Prog Liver Dis*. 1982;7:495-515.
158. Malavige GN, Fernando S, Fernando DJ, Seneviratne SL. Dengue viral infections. *Postgrad Med J*. 2004;80:588-601.
159. Tan SS, Bujang MA. The clinical features and outcomes of acute liver failure associated with dengue infection in adults: a case series. *Braz J Infect Dis*. 2013;17:164-169.
160. Shah I. Dengue and liver disease. *Scand J Infect Dis*. 2008;40:993-994.
161. Chongsrisawat V, Hutagalung Y, Poovorawan Y. Liver function test results and outcomes in children with acute liver failure due to dengue infection. *Southeast Asian J Trop Med Public Health*. 2009;40:47-53.
162. Povaia TF, Alves AM, Oliveira CA, Nuovo GJ, Chagas VL, Paes MV. The pathology of severe dengue in multiple organs of human fatal cases: histopathology, ultrastructure and virus replication. *PLoS ONE*. 2014;9:e83386.
163. de Macedo FC, Nicol AE, Cooper LD, Yearsley M, Pires AR, Nuovo GJ. Histologic, viral, and molecular correlates of dengue fever infection of the liver using highly sensitive immunohistochemistry. *Diagn Mol Pathol*. 2006;15:223-228.
164. Huerre MR, Lan NT, Marianneau P, et al. Liver histopathology and biological correlates in five cases of fatal dengue fever in Vietnamese children. *Virchows Arch*. 2001;438:107-115.
165. Pagliari C, Quaresma JA, Fernandes ER, et al. Immunopathogenesis of dengue hemorrhagic fever: contribution to the study of human liver lesions. *J Med Virol*. 2014;86:1193-1197.
166. Sung JM, Lee CK, Wu-Hsieh BA. Intrahepatic infiltrating NK and CD8 T cells cause liver cell death in different phases of dengue virus infection. *PLoS ONE*. 2012;7:e46292.
167. Limonta D, Falcon V, Torres G, et al. Dengue virus identification by transmission electron microscopy and molecular methods in fatal dengue hemorrhagic fever. *Infection*. 2012;40:689-694.
168. Shieh WJ, Paddock CD, Lederman E, et al. Pathologic studies on suspect animal and human cases of Rift Valley fever from an outbreak in Eastern Africa, 2006-2007. *Am J Trop Med Hyg*. 2010;83:38-42.
169. Walker DH, McCormick JB, Johnson KM, et al. Pathologic and virologic study of fatal Lassa fever in man. *Am J Pathol*. 1982;107:349-356.
170. Alvarez SZ. Hepatobiliary tuberculosis. *J Gastroenterol Hepatol*. 1998;13:833-839.
171. Hickey AJ, Gounder L, Moosa MY, Drain PK. A systematic review of hepatic tuberculosis with considerations in human immunodeficiency virus co-infection. *BMC Infect Dis*. 2015;15:209.
172. Freudenreich O, Basgoz N, Fernandez-Robles C, Larvie M, Misdraji J. Case records of the Massachusetts General Hospital. Case 5-2012. A 39-year-old man with a recent diagnosis of HIV infection and acute psychosis. *N Engl J Med*. 2012;366:648-657.
173. Chong VH. Hepatobiliary tuberculosis: a review of presentations and outcomes. *South Med J*. 2008;101:356-361.
174. Huang WT, Wang CC, Chen WJ, Cheng YF, Eng HL. The nodular form of hepatic tuberculosis: a review with five additional new cases. *J Clin Pathol*. 2003;56:835-839.
175. Essop AR, Posen JA, Hodkinson JH, Segal I. Tuberculosis hepatitis: a clinical review of 96 cases. *Q J Med*. 1984;53:465-477.

176. Harrington PT, Gutierrez JJ, Ramirez-Ronda CH, Quiñones-Soto R, Bermúdez RH, Chaffey J. Granulomatous hepatitis. *Rev Infect Dis.* 1982;4:638-655.
177. Pereira GH, Yamagutti DC, Mendonca JS. Evaluation of the histopathological hepatic lesions and opportunistic agents in Brazilian HIV patients. *Rev Soc Bras Med Trop.* 2010;43:1-3.
178. Maharaj B, Leary WP, Pudifin DJ. A prospective study of hepatic tuberculosis in 41 black patients. *Q J Med.* 1987;63:517-522.
179. Wang JY, Hsueh PR, Wang SK, et al. Disseminated tuberculosis: a 11-year experience in a medical center. *Medicine (Baltimore).* 2007;86:39-46.
180. Chong VH, Lim KS. Hepatobiliary tuberculosis. *Singapore Med J.* 2010;51:744-751.
181. Maglante DD, Alvarez SZ, Ng AC, Lapeña JL. Patterns of calcifications and cholangiographic findings in hepatobiliary tuberculosis. *Gastrointest Radiol.* 1988;13:331-335.
182. Hussain W, Mutimer D, Harrison R, Hubscher S, Neuberger J. Fulminant hepatic failure caused by tuberculosis. *Gut.* 1995;36:792-794.
183. Sanz-Canalejas L, Gómez-Mampaso E, Cantón-Moreno R, Varona-Crespo C, Fortún J, Drona F. Peliosis hepatis due to disseminated tuberculosis in a patient with AIDS. *Infection.* 2014;42(1):185-189.
184. Alcantara-Payawal DE, Matsumura M, Shiratori Y, et al. Direct detection of *Mycobacterium tuberculosis* using polymerase chain reaction assay among patients with hepatic granuloma. *J Hepatol.* 1997;27:620-627.
185. Diaz ML, Herrera T, Lopez-Vidal Y, et al. Polymerase chain reaction for the detection of *Mycobacterium tuberculosis* DNA in tissue and assessment of its utility in the diagnosis of hepatic granulomas. *J Lab Clin Med.* 1996;127:359-363.
186. Orenstein MS, Tavitian A, Yonk B, et al. Granulomatous involvement of the liver in patients with AIDS. *Gut.* 1985;26:1220-1225.
187. Zhang L, Yang NB, Ni SL, Zhang SN, Shen CB, Lu MQ. A case of multiple macronodular hepatic tuberculosis difficult to differentiate from hepatocellular carcinoma with intrahepatic metastasis: CT-guided fine needle aspiration biopsy confirmed the diagnosis. *Int J Clin Exp Pathol.* 2014;7:8240-8244.
188. Hassani KI, Ousadden A, Ankouza A, Mazaz K, Taleb KA. Isolated liver tuberculosis abscess in a patient without immunodeficiency: a case report. *World J Hepatol.* 2010;2:354-357.
189. Chan HS, Pang J. Isolated giant tuberculomata of the liver detected by computed tomography. *Gastrointest Radiol.* 1989;14:305-307.
190. Oliva A, Duarte B, Jonasson O, Nadimpalli V. The nodular form of local hepatic tuberculosis. A review. *J Clin Gastroenterol.* 1990;12:166-173.
191. Park JI. Primary hepatic tuberculosis mimicking intrahepatic cholangiocarcinoma: report of two cases. *Ann Surg Treat Res.* 2015;89:98-101.
192. Hickey N, McNulty JG, Osborne H, Finucane J. Acute hepatobiliary tuberculosis: a report of two cases and a review of the literature. *Eur Radiol.* 1999;9:886-889.
193. Kanhere HA, Trochsler MI, Pierides J, Maddern GJ. Atypical mycobacterial infection mimicking metastatic cholangiocarcinoma. *J Surg Case Rep.* 2013;2013:rjt038.
194. Barr DA, Ramdial PK. Clinicopathological correlates in HIV seropositive tuberculosis cases presenting with jaundice after initiating antiretroviral therapy with a structured review of the literature. *BMC Infect Dis.* 2012;12:257.
195. Kahn SA, Saltzman BR, Klein RS, Mahadevia PS, Friedland GH, Brandt LJ. Hepatic disorders in the acquired immune deficiency syndrome: a clinical and pathological study. *Am J Gastroenterol.* 1986;81:1145-1148.
196. Farhi DC, Mason UG 3rd, Horsburgh CR Jr. Pathologic findings in disseminated *Mycobacterium avium-intracellulare* infection: a report of 11 cases. *Am J Clin Pathol.* 1986;85:67-72.
197. Toyoda M, Yokomori H, Kaneko F, et al. Hepatic granulomas as primary presentation of *Mycobacterium avium* infection in an HIV-negative, nonimmunosuppressed patient. *Clin J Gastroenterol.* 2009;2:431-437.
198. Mogamberg JC, Motala A, Padayachee K, Jozi C, Dawood H. Nontuberculous mycobacteria immune reconstitution syndrome. *Case Rep Med.* 2014;2014:964612.
199. Chen TS, Drutz DJ, Whelan GE. Hepatic granulomas in leprosy: their relation to bacteremia. *Arch Pathol Lab Med.* 1976;100:182-185.
200. Ferrari TC, Araujo MG, Ribeiro MM. Hepatic involvement in lepromatous leprosy. *Lepr Rev.* 2002;73:72-75.
201. Bodurtha A, Kim YH, Laucius JF, Donato RA, Mastrangelo MJ. Hepatic granulomas and other hepatic lesions associated with BCG immunotherapy for cancer. *Am J Clin Pathol.* 1974;61:747-752.
202. Hunt JS, Silverstein MJ, Sparks FC, Haskell CM, Pilch YH, Morton DL. Granulomatous hepatitis: a complication of B.C.G. immunotherapy. *Lancet.* 1973;2:820-821.
203. Lamm DL, van der Meijden PM, Morales A, et al. Incidence and treatment of complications of bacillus Calmette-Guerin intravesical therapy in superficial bladder cancer. *J Urol.* 1992;147:596-600.
204. Kaklamanos M, Hardavella G, Trigidou R, et al. Multi-organ failure with atypical liver granulomas following intravesical Bacillus Calmette-Guerin instillation. *World J Hepatol.* 2011;3:79-82.
205. Ozbakkaloglu B, Tunger O, Surucuoglu S, Lekili M, Kandiloglu AR. Granulomatous hepatitis following intravesical bacillus Calmette-Guerin therapy. *Int Urol Nephrol.* 1999;31:49-53.
206. Soylu A, Ince AT, Polat H, et al. Peritoneal tuberculosis and granulomatous hepatitis secondary to treatment of bladder cancer with Bacillus Calmette-Guerin. *Ann Clin Microbiol Antimicrob.* 2009;8:12.
207. Delimpoura V, Samitas K, Vamvakaris I, Zervas E, Gaga M. Concurrent granulomatous hepatitis, pneumonitis and sepsis as a complication of intravesical BCG immunotherapy. *BMJ Case Rep.* 2013;2013:bcr2013200624.
208. Barza MJ, Blum JH, Graeme-Cook FM. Case records of the Massachusetts General Hospital: weekly clinicopathological exercises. Case 29-1998: a 57-year-old man with fever and jaundice after intravesical instillation of bacille Calmette-Guerin for bladder cancer. *N Engl J Med.* 1998;339:831-837.
209. Schattner A, Gilad A, Cohen J. Systemic granulomatosis and hypercalcaemia following intravesical bacillus Calmette-Guerin immunotherapy. *J Intern Med.* 2002;251:272-277.
210. Shoaran M, Najafi M, Jalilian R, Rezaei N. Granulomatous hepatitis as a rare complication of Bacillus Calmette-Guerin vaccination. *Ann Saudi Med.* 2013;33:627-629.
211. Proctor DD, Chopra S, Rubenstein SC, Jokela JA, Uhl L. Mycobacteremia and granulomatous hepatitis following initial intravesical bacillus Calmette-Guerin instillation for bladder carcinoma. *Am J Gastroenterol.* 1993;88:1112-1115.
212. Leebeek FW, Ouwendijk RJ, Kolk AH, et al. Granulomatous hepatitis caused by bacillus Calmette-Guerin (BCG) infection after BCG bladder instillation. *Gut.* 1996;38:616-618.
213. Saint-Marc Girardin MF, Zafrani ES, Chaumette MT, Delchier JC, Mètreau JM, Dhumeaux D. Hepatic granulomas in Whipple's disease. *Gastroenterology.* 1984;86:753-756.
214. Chateil JF, Brun M, Perel Y, Sananes JC, Castell JF, Diard F. Granulomatous hepatitis in *Pasteurella multocida* infection. *Eur Radiol.* 1998;8:588-591.
215. Stjernberg U, Silseth C, Ritland S. Granulomatous hepatitis in *Yersinia enterocolitica* infection. *Hepatogastroenterology.* 1987;34:56-57.
216. Muorah M, Hinds R, Verma A, et al. Liver abscesses in children: a single center experience in the developed world. *J Pediatr Gastroenterol Nutr.* 2006;42:201-206.
217. Rahimian J, Wilson T, Oram V, Holzman RS. Pyogenic liver abscess: recent trends in etiology and mortality. *Clin Infect Dis.* 2004;39:1654-1659.
218. Ruiz-Hernandez JJ, Leon-Mazorra M, Conde-Martel A, Marchena-Gómez J, Hemmersbach-Miller M, Betancor-León P. Pyogenic

- liver abscesses: mortality-related factors. *Eur J Gastroenterol Hepatol*. 2007;19:853-858.
219. Chan KS, Yu WL, Tsai CL, et al. Pyogenic liver abscess caused by *Klebsiella pneumoniae*: analysis of the clinical characteristics and outcomes of 84 patients. *Chin Med J*. 2007;120:136-139.
  220. Thomsen RW, Jepsen P, Sorensen HT. Diabetes mellitus and pyogenic liver abscess: risk and prognosis. *Clin Infect Dis*. 2007;44:1194-1201.
  221. Chen W, Chen CH, Chiu KL, et al. Clinical outcome and prognostic factors of patients with pyogenic liver abscess requiring intensive care. *Crit Care Med*. 2008;36:1184-1188.
  222. Simeunovic E, Arnold M, Sidler D, Moore SW. Liver abscess in neonates. *Pediatr Surg Int*. 2009;25:153-156.
  223. Chong VH, Yong AM, Wahab AY. Gas-forming pyogenic liver abscess. *Singapore Med J*. 2008;49:e123-e125.
  224. Lee NK, Kim S, Lee JW, et al. CT differentiation of pyogenic liver abscesses caused by *Klebsiella pneumoniae* vs non-*Klebsiella pneumoniae*. *Br J Radiol*. 2011;84:518-525.
  225. Vadillo M, Corbella X, Pac V, Fernandez-Viladrich P, Pujol R. Multiple liver abscesses due to *Yersinia enterocolitica* discloses primary hemochromatosis: three cases reports and review. *Clin Infect Dis*. 1994;18:938-941.
  226. Farrer W, Kloser P, Ketyer S. *Yersinia pseudotuberculosis* sepsis presenting as multiple liver abscesses. *Am J Med Sci*. 1988;295:129-132.
  227. Santoro MJ, Chen YK, Seid NS, Abdulian JD, Collen MJ. *Yersinia enterocolitica* liver abscesses unmasking idiopathic hemochromatosis. *J Clin Gastroenterol*. 1994;18:253-254.
  228. Bergmann TK, Vinding K, Hey H. Multiple hepatic abscesses due to *Yersinia enterocolitica* infection secondary to primary hemochromatosis. *Scand J Gastroenterol*. 2001;36:891-895.
  229. Sabbaj J. Anaerobes in liver abscess. *Rev Infect Dis*. 1984;6(suppl 1):S152-S156.
  230. Brook I, Fraizer EH. Role of anaerobic bacteria in liver abscesses in children. *Pediatr Infect Dis J*. 1993;12:743-747.
  231. Kazmi KA, Rab SM. Primary hepatic actinomycosis: a diagnostic problem. *Am J Trop Med Hyg*. 1980;40:310-311.
  232. Christodoulou N, Papadakis I, Velegakis M. Actinomycotic liver abscess: case report and review of the literature. *Chir Ital*. 2004;56:141-146.
  233. Hilfiker ML. Disseminated actinomycosis presenting as a renal tumor with metastases. *J Pediatr Surg*. 2001;36:1577-1578.
  234. Sharma M, Briski LE, Khatib R. Hepatic actinomycosis: an overview of salient features and outcome of therapy. *Scand J Infect Dis*. 2002;34:386-391.
  235. Lamps LW, Havens JM, Sjostedt A, Page DL, Scott MA. Histologic and molecular diagnosis of tularemia: a potential bioterrorism agent endemic to North America. *Mod Pathol*. 2004;17:489-495.
  236. Apisarnthanarak A, Apisarnthanarak P, Mundy LM. Computed tomography characteristics of *Burkholderia pseudomallei* liver abscess. *Clin Infect Dis*. 2006;42:989-993.
  237. White NJ. Melioidosis. *Lancet*. 2003;361:1715-1722.
  238. Braun TI, Travis D, Dee RR, Nieman RE. Liver abscess due to *Listeria monocytogenes*: case report and review. *Clin Infect Dis*. 1993;17:267-269.
  239. Rieder J, Lechner M, Lass-Floerl C, et al. Successful management of *Aspergillus* liver abscess in a patient with necrotizing fasciitis. *Dig Dis Sci*. 2007;52:1548-1553.
  240. Fang CT, Lai SY, Yi WC, Hsueh PR, Liu KL, Chang SC. *Klebsiella pneumoniae* genotype K1: an emerging pathogen that causes septic ocular or central nervous system complications from pyogenic liver abscess. *Clin Infect Dis*. 2007;45:284-293.
  241. Tan YM, Chee SP, Soo KC, Chow P. Ocular manifestations and complications of pyogenic liver abscess. *World J Surg*. 2004;28:38-42.
  242. Sinanan MN. Acute cholangitis. *Infect Dis Clin North Am*. 1992;6:571-599.
  243. Charcot JM. *Leçons Sur Les Maladies du Foi des Voies Fliares et des Rins*. Paris: Faculté de Médecine de Paris; 1877.
  244. Reynolds BM, Dargan EL. Acute obstructive cholangitis: a distinct clinical syndrome. *Ann Surg*. 1959;150:299-303.
  245. O'Connor MJ, Schwartz ML, McQuarrie DG, Sumer HW. Acute bacterial cholangitis: an analysis of clinical manifestation. *Arch Surg*. 1982;117:437-441.
  246. Mukaiya M, Hirata K, Katsuramaki T, et al. Isolated bacteria and susceptibilities to antimicrobial agents in biliary infections. *Hepato-gastroenterology*. 2005;52:686-690.
  247. Qureshi WA. Approach to the patient who has suspected acute bacterial cholangitis. *Gastroenterol Clin North Am*. 2006;35:409-423.
  248. Carpenter HA. Bacterial and parasitic cholangitis. *Mayo Clin Proc*. 1998;73:473-478.
  249. Shimada H, Nihmoto S, Matsuba A, Nakagawara G. Acute cholangitis: a histopathologic study. *J Clin Gastroenterol*. 1988;10:197-200.
  250. Bilezikci B, Demirhan B, Kocbiyik A, Arat Z, Haberal M. Relevant histopathologic findings that distinguish acute cellular rejection from cholangitis in hepatic allograft biopsy specimens. *Transplant Proc*. 2008;40:248-250.
  251. Lim JH. Oriental cholangiohepatitis: pathologic, clinical, and radiologic features. *AJR Am J Roentgenol*. 1991;157:1-8.
  252. Chung RT, Varghese JC, Sheffer EC. Case records of the Massachusetts General Hospital: weekly clinicopathological exercises. Case 28-2001: a 44-year-old woman with chills, fever, jaundice, and hepatic abscesses. *N Engl J Med*. 2001;345:817-823.
  253. Tsui WM, Chan YK, Wong CT, Lo YF, Yeung YW, Lee YW. Hepatolithiasis and the syndrome of recurrent pyogenic cholangitis: clinical, radiologic, and pathologic features. *Semin Liver Dis*. 2011;31:33-48.
  254. Tabrizian P, Jibara G, Shrager B, Schwartz ME, Roayaie S. Hepatic resection for primary hepatolithiasis: a single-center Western experience. *J Am Coll Surg*. 2012;215:622-626.
  255. Buzgan T, Karahocagil MK, Irmak H, et al. Clinical manifestations and complications in 1028 cases of brucellosis: a retrospective evaluation and review of the literature. *Int J Infect Dis*. 2010;14:e469-e478.
  256. Ozturk-Engin D, Erdem H, Gencer S, et al. Liver involvement in patients with brucellosis: results of the Marmara study. *Eur J Clin Microbiol Infect Dis*. 2014;33:1253-1262.
  257. Williams RK, Crossley K. Acute and chronic hepatic involvement of brucellosis. *Gastroenterology*. 1982;83:455-458.
  258. Cervantes F, Bruguera M, Carbonell J, Force L, Webb S. Liver disease in brucellosis. A clinical and pathological study of 40 cases. *Postgrad Med J*. 1982;58:346-350.
  259. Hunt AC, Bothwell PW. Histological findings in human brucellosis. *J Clin Pathol*. 1967;20:267-272.
  260. Spink WW, Hoffbauer FW. Histopathology of the liver in human brucellosis. *J Lab Clin Med*. 1949;34:40-58.
  261. Akritidis N, Tzivras M, Delladetsima I, Stefanaki S, Moutsopoulos HM, Pappas G. The liver in brucellosis. *Clin Gastroenterol Hepatol*. 2007;5:1109-1112.
  262. Young EJ, Hasanjanani Roushan MR, Shafae S, Genta RM, Taylor SL. Liver histology of acute brucellosis caused by *Brucella melitensis*. *Hum Pathol*. 2014;45:2023-2028.
  263. Jordans HG, DeBruin KD. Granulomas in *Brucella melitensis* infection. *Ann Intern Med*. 1980;92:264-265.
  264. Ledro D, Llamas R, Herrerias JM, Domecq G, Justo E, Garrido M. The presence of granulomas due to *Brucella melitensis* in hepatitis. *J Infect Dis*. 1983;147:606-607.
  265. Bruguera M, Cervantes F. Hepatic granulomas in brucellosis. *Ann Intern Med*. 1980;92:571-572.
  266. Fernandez Guerrero ML, Diaz Curiel M, Cortes Cansino JM. Hepatic granulomas in brucellosis. *Ann Intern Med*. 1980;92:572.
  267. Young EJ. *Brucella melitensis* hepatitis: the absence of granulomas. *Ann Intern Med*. 1979;91:414-415.

268. Heller T, Belard S, Wallrauch C, et al. Patterns of hepatosplenic *Brucella* abscesses on cross-sectional imaging: a review of clinical and imaging features. *Am J Trop Med Hyg.* 2015;93:761-766.
269. Villar JM, Garrote D, Villegas MT, et al. Hepatic brucellosis. *J Am Coll Surg.* 2002;194:86.
270. Ariza J, Pigrau C, Canas C, et al. Current understanding and management of chronic hepatosplenic suppurative brucellosis. *Clin Infect Dis.* 2001;32:1024-1033.
271. Chourmouzi D, Boulogianni G, Kalomenopoulou M, Kanellos I, Drevelgas A. *Brucella* liver abscess; imaging approach, differential diagnosis, and therapeutic management: a case report. *Cases J.* 2009;2:7143.
272. Barutta L, Ferrigno D, Melchio R, et al. Hepatic brucellosis. *Lancet Infect Dis.* 2013;13:987-993.
273. Arisoy ES, Correa AG, Wagner ML, Kaplan SL. Hepatosplenic cat-scratch disease in children: selected clinical features and treatment. *Clin Infect Dis.* 1999;28:778-784.
274. Lamps LW, Gray GF, Scott MA. The histologic spectrum of hepatic cat scratch disease: a series of six cases with confirmed *Bartonella henselae* infection. *Am J Surg Pathol.* 1996;20:1253-1259.
275. Lenoir AA, Storch GA, DeSchryver-Kecsckemeti K, et al. Granulomatous hepatitis associated with cat scratch disease. *Lancet.* 1988;1:1132-1136.
276. Ventura A, Massei F, Not T, Massimetti M, Bussani R, Maggiore G. Systemic *Bartonella henselae* infection with hepatosplenic involvement. *J Pediatr Gastroenterol Nutr.* 1999;29:52-56.
277. Malatack JJ, Jaffe R. Granulomatous hepatitis in three children due to cat-scratch disease without peripheral adenopathy: an unrecognized cause of fever of unknown origin. *Am J Dis Child.* 1993;147:949-953.
278. VanderHeyden TR, Yong SL, Breitschwerdt EB, et al. Granulomatous hepatitis due to *Bartonella henselae* infection in an immunocompetent patient. *BMC Infect Dis.* 2012;12:17.
279. Liston TE, Koehler JE. Granulomatous hepatitis and necrotizing splenitis due to *Bartonella henselae* in a patient with cancer: case report and review of hepatosplenic manifestations of bartonella infection. *Clin Infect Dis.* 1996;22:951-957.
280. Connor BA, Schwartz E. Typhoid and paratyphoid fever in travelers. *Lancet Infect Dis.* 2005;5:623-628.
281. Parry CM, Hien TT, Dougan G, White NJ, Farrar JJ. Typhoid fever. *N Engl J Med.* 2002;347:1770-1782.
282. Rubin EJ, Graeme-Cook FM. Case records of the Massachusetts General Hospital: weekly clinicopathological exercises. Case 22-2001: a 25-year-old woman with fever and abnormal liver function. *N Engl J Med.* 2001;345:201-205.
283. Sorabjee JS. The liver in enteric fever and leptospirosis. *Indian J Gastroenterol.* 2001;20(suppl 1):C44-C46.
284. Narechania S, Duran M, Karivedu V, Gopalakrishna KV. A case of typhoid fever with hepatic granulomas and enteritis. *Case Rep Pathol.* 2015;2015:745461.
285. Pais P. A hepatitis like picture in typhoid fever. *Br Med J (Clin Res Ed).* 1984;289:225-226.
286. Soni PN, Hoosen AA, Pillay DG. Hepatic abscess caused by *Salmonella typhi*. A case report and review of the literature. *Dig Dis Sci.* 1994;39:1694-1696.
287. Zaidi SA, Singer C. Gastrointestinal and hepatic manifestations of tickborne diseases in the United States. *Clin Infect Dis.* 2002;34:1206-1212.
288. Lamps LW. Hepatic granulomas, with an emphasis on infectious causes. *Adv Anat Pathol.* 2008;15:309-318.
289. Currie BJ. Melioidosis: an important cause of pneumonia in residents of and travellers returned from endemic regions. *Eur Respir J.* 2003;22:542-550.
290. Piggott JA, Hochholzer L. Human melioidosis: a histopathologic study of acute and chronic melioidosis. *Arch Pathol Lab Med.* 1970;90:101-111.
291. Scholing M, Schneeberger PM, van den Dries P, Drenth JP. Clinical features of liver involvement in adult patients with listeriosis: review of the literature. *Infection.* 2007;35:212-218.
292. Jenkins D, Richards JE, Rees Y, Wicks AC. Multiple listerial liver abscesses. *Gut.* 1987;28:1661-1662.
293. Yu VL, Miller WP, Wing EJ, Romano JM, Ruiz CA, Bruns FJ. Disseminated listeriosis presenting as acute hepatitis. Case reports and review of hepatic involvement in listeriosis. *Am J Med.* 1982;73:773-777.
294. De Vega T, Echevarria S, Crespo J, Artiñano E, San Miguel G, Pons Romero F. Acute hepatitis by *Listeria monocytogenes* in an HIV patient with chronic HBV hepatitis. *J Clin Gastroenterol.* 1992;15:251-255.
295. Hardie R, Roberts W. Adult listeriosis presenting as acute hepatitis. *J Infect.* 1984;8:256-258.
296. Bourgeois N, Jacobs F, Tavares ML, et al. *Listeria monocytogenes* hepatitis in a liver transplant recipient: a case report and review of the literature. *J Hepatol.* 1993;18:284-289.
297. Vargas V, Aleman C, de Torres I, et al. *Listeria monocytogenes*-associated acute hepatitis in a liver transplant recipient. *Liver.* 1998;18:213-215.
298. Crum-Cianflone N, Weekes J, Bavaro M. Syphilitic hepatitis among HIV-infected patients. *Int J STD AIDS.* 2009;20:278-284.
299. Manavi K, Dhasmana D, Cramb R. Prevalence of hepatitis in early syphilis among an HIV cohort. *Int J STD AIDS.* 2012;23:e4-e6.
300. Jung N, Kummerle T, Brengelmann SD, et al. Liver involvement in HIV-infected patients diagnosed with syphilis. *Infection.* 2012;40:543-547.
301. Palacios R, Navarro F, Narankiewicz D, et al. Liver involvement in HIV-infected patients with early syphilis. *Int J STD AIDS.* 2013;24:31-33.
302. Adachi E, Koibuchi T, Okame M, et al. Liver dysfunction in patients with early syphilis: a retrospective study. *J Infect Chemother.* 2013;19:180-182.
303. Hagen CE, Kamionek M, McKinsey DS, Misdraji J. Syphilis presenting as inflammatory tumors of the liver in HIV-positive homosexual men. *Am J Surg Pathol.* 2014;38:1636-1643.
304. Noto P, Del Nonno F, Licci S, Chinello P, Petrosillo N. Early syphilitic hepatitis in an immunocompetent patient: really so uncommon? *Int J STD AIDS.* 2008;19:65-66.
305. Keisler DS Jr, Starke W, Looney DJ, Mark WW Jr. Early syphilis with liver involvement. *J Am Med Assoc.* 1982;247:1999-2000.
306. Campisi D, Whitcomb C. Liver disease in early syphilis. *Arch Intern Med.* 1979;139:365-366.
307. Baker AL, Kaplan MM, Wolfe HJ, McGowan JA. Liver disease associated with early syphilis. *N Engl J Med.* 1971;284:1422-1423.
308. Ridruejo E, Mordoh A, Herrera F, Avagnina A, Mando OO. Severe cholestatic hepatitis as the first symptom of secondary syphilis. *Dig Dis Sci.* 2004;49:1401-1404.
309. Ozaki T, Takemoto K, Hosono H, Miyagawa K, Akimoto S, Nishimura N. Secondary syphilitic hepatitis in a fourteen-year-old male youth. *Pediatr Infect Dis J.* 2002;21:439-441.
310. Yoshikawa K, Aida Y, Seki N, et al. Early syphilitic hepatitis concomitant with nephrotic syndrome followed by acute kidney injury. *Clin J Gastroenterol.* 2014;7:349-354.
311. Mullick CJ, Liappis AP, Benator DA, Roberts AD, Parenti DM, Simon GL. Syphilitic hepatitis in HIV-infected patients: a report of 7 cases and review of the literature. *Clin Infect Dis.* 2004;39:e100-e105.
312. Greenstone CL, Saint S, Moseley RH. Clinical problem solving: a hand-carried diagnosis. *N Engl J Med.* 2007;356:2407-2411.
313. Pareek SS. Liver involvement in secondary syphilis. *Dig Dis Sci.* 1979;24:41-43.
314. Miura H, Nakano M, Ryu T, Kitamura S, Suzuki A. A case of syphilis presenting with initial syphilitic hepatitis and serological recurrence with cerebrospinal abnormality. *Intern Med.* 2010;49:1377-1381.

315. Bork JT, Macharia T, Choi J, Gilliam BL, Buchwald UK. Syphilitic hepatitis treated with doxycycline in an HIV-infected patient and review of the literature. *Sex Transm Dis.* 2014;41:507-510.
316. Sobel HJ, Wolf EH. Liver involvement in early syphilis. *Arch Pathol Lab Med.* 1972;93:565-568.
317. Longstreth P, Hoke AW, Elroy C. Hepatitis and bone destruction as uncommon manifestations of early syphilis: report of a case. *Arch Dermatol.* 1976;112:1451-1454.
318. Koff RS, Gang DL. Case records of the Massachusetts General Hospital: weekly clinicopathological exercises. Case 27-1983: a 25 year old man with liver disease. *N Engl J Med.* 1983;309:1127-1128.
319. Mulder CJ, Cho RS, Harrison SA, Cebe K, Francis JM. Syphilitic hepatitis uncommon presentation of an old scourge. *Mil Med.* 2015;180:e611-e613.
320. Khambaty M, Singal AG, Gopal P. Spirochetes as an almost forgotten cause of hepatitis. *Clin Gastroenterol Hepatol.* 2015;13:A21-A22.
321. Solari PR, Jones C, Wallace MR. Hepatic lesions with secondary syphilis in an HIV-infected patient. *Case Rep Med.* 2014;2014:604794.
322. Gaslightwala I, Khara HS, Diehl DL. Syphilitic gummas mistaken for liver metastases. *Clin Gastroenterol Hepatol.* 2014;12:e109-e110.
323. Shim HJ. Tertiary syphilis mimicking hepatic metastases of underlying primary peritoneal serous carcinoma. *World J Hepatol.* 2010;2:362-366.
324. Maincent G, Labadie H, Fabre M, et al. Tertiary hepatic syphilis: a treatable cause of multinodular liver. *Dig Dis Sci.* 1997;42:447-450.
325. Mahto M, Mohammed F, Wilkins E, Mason J, Haboubi NY, Khan AN. Pseudohepatic tumour associated with secondary syphilis in an HIV-positive male. *Int J STD AIDS.* 2006;17:139-141.
326. Vainrub B. Bacterial infections of the liver and biliary tract: laboratory studies to determine etiology. *Lab Res Methods Biol Med.* 1983;7:119-128.
327. de Brito T, Menezes LF, Lima DM, Lourenço S, Silva AM, Alves VA. Immunohistochemical and in situ hybridization studies of the liver and kidney in human leptospirosis. *Virchows Arch.* 2006;448:576-583.
328. Wysocki J, Liu Y, Shores N. Leptospirosis with acute liver injury. *Proc (Bayl Univ Med Cent).* 2014;27:257-258.
329. de Brito T, Penna DO, Hoshino S, Pereira VG, Caldas AC, Rothstein W. Cholestasis in human leptospirosis: a clinical, histochemical, biochemical and electron microscopy study based on liver biopsies. *Beitr Pathol Anat.* 1970;140:345-361.
330. de Brito T, Machado MM, Montans SD, Hoshino S, Freymüller E. Liver biopsy in human leptospirosis: a light and electron microscopy study. *Virchows Arch Pathol Anat Physiol Klin Med.* 1967;342:61-69.
331. D'Andrea A, Martinez YZ, Alduina R, Monteverde V, Molina CF, Vitale M. Comparison of two PCR methods for detection of *Leptospira interrogans* in formalin-fixed and paraffin-embedded tissues. *Mem Inst Oswaldo Cruz.* 2012;107:85-88.
332. Goellner MH, Agger WA, Burgess JH, Duray PH. Hepatitis due to recurrent Lyme disease. *Ann Intern Med.* 1988;108:707-708.
333. Zanchi AC, Gingold AR, Theise ND, Min AD. Necrotizing granulomatous hepatitis as an unusual manifestation of Lyme disease. *Dig Dis Sci.* 2007;52:2629-2632.
334. Srigley JR, Vellend H, Palmer N, et al. Q-fever: the liver and bone marrow pathology. *Am J Surg Pathol.* 1985;9:752-758.
335. Hofmann CE, Heaton JW Jr. Q fever hepatitis: clinical manifestations and pathological findings. *Gastroenterology.* 1982;83:474-479.
336. Gomes MM, Chaves A, Gouveia A, Santos L. Two rare manifestations of Q fever: splenic and hepatic abscesses and cerebral venous thrombosis, with literature review ma non troppo. *BMJ Case Rep.* 2014;2014.
337. Lecronier M, Prendki V, Gerin M, et al. Q fever and Mediterranean spotted fever associated with hemophagocytic syndrome: case study and literature review. *Int J Infect Dis.* 2013;17:e629-e633.
338. Aguilar-Olivos N, del Carmen Manzano-Robleda M, Gutierrez-Grobo Y, Chablé-Montero F, Albores-Saavedra J, López-Méndez E. Granulomatous hepatitis caused by Q fever: a differential diagnosis of fever of unknown origin. *Ann Hepatol.* 2013;12:138-141.
339. Dugdale C, Chow B, Yakirevich E, Kojic E, Knoll B. Prolonged pyrexia and hepatitis: Q fever. *Am J Med.* 2014;127:928-930.
340. Lee M, Jang JJ, Kim YS, et al. Clinicopathologic features of Q fever patients with acute hepatitis. *Korean J Pathol.* 2012;46:11-14.
341. Modol JM, Llamazares JF, Mate JL, Troya J, Sabria M. Acute abdominal pain and Q fever. *Eur J Clin Microbiol Infect Dis.* 1999;18:158-160.
342. Travis LB, Travis WD, Li CY, Pierre RV. Q fever: a clinicopathologic study of five cases. *Arch Pathol Lab Med.* 1986;110:1017-1020.
343. Qizilbash AH. The pathology of Q fever as seen on liver biopsy. *Arch Pathol Lab Med.* 1983;107:364-367.
344. Silver SS, McLeish WA. "Doughnut" granulomas in Q fever. *Can Med Assoc J.* 1984;130:102-104.
345. Font J, Bruguera M, Perez-Villa F, Ingelmo M. Hepatic fibrin-ring granulomas caused by *Staphylococcus epidermidis* generalized infection. *Gastroenterology.* 1987;93:1449-1451.
346. Stricker BH, Blok AP, Babany G, Benhamou JP. Fibrin ring granulomas and allopurinol. *Gastroenterology.* 1989;96:1199-1203.
347. Vanderstigel M, Zafrani ES, Lejonn JL, Schaeffer A, Portos JL. Allopurinol hypersensitivity syndrome as a cause of hepatic fibrin-ring granulomas. *Gastroenterology.* 1986;90:188-190.
348. Marazuela M, Moreno A, Yebra M, Cerezo E, Gómez-Gesto C, Vargas JA. Hepatic fibrin-ring granulomas: a clinicopathologic study of 23 patients. *Hum Pathol.* 1991;22:607-613.
349. Moreno A, Marazuela M, Yebra M, et al. Hepatic fibrin-ring granulomas in visceral leishmaniasis. *Gastroenterology.* 1988;95:1123-1126.
350. de Baysier L, Roblot P, Ramassamy A, Silvain C, Levillain P, Becq-Giraudon B. Hepatic fibrin-ring granulomas in giant cell arteritis. *Gastroenterology.* 1993;105:272-273.
351. Voigt JJ, Delsol G, Fabre J. Liver and bone marrow granulomas in Q fever. *Gastroenterology.* 1983;84:887-888.
352. Delsol G, Pellegrin M, Voigt JJ, Fabre J. Diagnostic value of granuloma with fibrinoid ring. *Am J Clin Pathol.* 1980;73:289.
353. Lin PH, Lo YC, Chiang FT, et al. Acute Q fever presenting as fever of unknown origin with rapidly progressive hepatic failure in a patient with alcoholism. *J Formos Med Assoc.* 2008;107:896-901.
354. Pellegrin M, Delsol G, Auvergnat JC, et al. Granulomatous hepatitis in Q fever. *Hum Pathol.* 1980;11:51-57.
355. Moskovitz M, Fadden R, Min T. Human ehrlichiosis: a rickettsial disease associated with severe cholestasis and multisystemic disease. *J Clin Gastroenterol.* 1991;13:86-90.
356. Nutt AK, Raufman J. Gastrointestinal and hepatic manifestations of human ehrlichiosis: 8 cases and a review of the literature. *Dig Dis.* 1999;17:37-43.
357. Sehdev AE, Dumler JS. Hepatic pathology in human monocytic ehrlichiosis: *Ehrlichia chaffeensis* infection. *Am J Clin Pathol.* 2003;119:859-865.
358. Jackson MD, Kirkman C, Bradford WD, Walker DH. Rocky mountain spotted fever: hepatic lesions in childhood cases. *Pediatr Pathol.* 1986;5:379-388.
359. Adams JS, Walker DH. The liver in Rocky Mountain spotted fever. *Am J Clin Pathol.* 1981;75:156-161.
360. Pishmisheva M, Stoycheva M, Vatev N, Semerdjieva M. Mediterranean spotted fever in children in the Pazardjik region, South Bulgaria. *Pediatr Infect Dis J.* 2014;33:542-544.
361. Walker DH, Staiti A, Mansueto S, Tringali G. Frequent occurrence of hepatic lesions in boutonuse fever. *Acta Trop.* 1986;43:175-181.



362. Guardia J, Martinez-Vazquez JM, Moragas A, et al. The liver in boutonneuse fever. *Gut*. 1974;15:549-551.
363. Mir-Madjlessi SH, Farmer RG, Hawk WA. Granulomatous hepatitis: a review of 50 cases. *Am J Gastroenterol*. 1973;60:122-134.
364. Collins MH, Jiang B, Croffie JM, Chong SK, Lee CH. Hepatic granulomas in children: a clinicopathologic analysis of 23 cases including polymerase chain reaction for *Histoplasma*. *Am J Surg Pathol*. 1996;20:332-338.
365. Smith JW, Utz JP. Progressive disseminated histoplasmosis: a prospective study of 26 patients. *Ann Intern Med*. 1972;76:557-565.
366. Rihana NA, Kandula M, Velez A, Dahal K, O'Neill EB. Histoplasmosis presenting as granulomatous hepatitis: case report and review of the literature. *Case Rep Med*. 2014;2014:879535.
367. Maekelt GA. Diagnostic procedures in the evaluation of hepatic diseases: studies to determine mycotic etiology. *Lab Res Methods Biol Med*. 1983;7:141-144.
368. Thaler M, Pastakia B, Shawker TH, O'Leary T, Pizzo PA. Hepatic candidiasis in cancer patients: the evolving picture of the syndrome. *Ann Intern Med*. 1988;108:88-100.
369. Johnson TL, Barnett JL, Appelman HD, Nostrant T. *Candida* hepatitis: histopathologic diagnosis. *Am J Surg Pathol*. 1988;12:716-720.
370. Cascio A, Pantaleo D, Corona G, et al. Neonatal liver abscesses associated with candidemia: three cases and review of literature. *J Matern Fetal Neonatal Med*. 2014;27:743-749.
371. Sharma D, Choudhary M, Shastri S, Sharma PK. Neonatal liver abscesses due to *Candida* infection in a preterm infant, secondary to malpositioned umbilical lines—a rare entity. *Pathog Glob Health*. 2015;109:84-87.
372. Picone S, Manzoni P, Bedetta M, Mostert M, Benjamin DK Jr, Paolillo P. Pharmacological resolution of a multiloculated *Candida* spp. liver abscess in a preterm neonate. *Early Hum Dev*. 2013;89(suppl 1):S47-S50.
373. Diebel LN, Raafat AM, Dulchavsky SA, Brown WJ. Gallbladder and biliary tract candidiasis. *Surgery*. 1996;120:760-764, [discussion 4-5].
374. Uflacker R, Wholey MH, Amaral NM, Lima S. Parasitic and mycotic causes of biliary obstruction. *Gastrointest Radiol*. 1982;7:173-179.
375. Fleischhacker M, Schulz S, Johrens K, et al. Diagnosis of chronic disseminated candidosis from liver biopsies by a novel PCR in patients with haematological malignancies. *Clin Microbiol Infect*. 2012;18:1011-1016.
376. Kates DM, Sparling TG, Jetha N, Burdge DR. Alteration of the natural history of *Pneumocystis carinii* infection in patients with acquired immunodeficiency syndrome receiving aerosolized pentamidine. *West J Med*. 1991;154:721-723.
377. Boldorini R, Guzzetti S, Meroni L, Quirino T, Cristina S, Monga G. Acute hepatic and renal failure caused by *Pneumocystis carinii* in patients with AIDS. *J Clin Pathol*. 1995;48:975-978.
378. Yuchong C, Dingheng Z, Zhizhong Y, Hongyu Y, Jing H, Jianghan C. Aspergillosis of biliary tract after liver transplantation: a case report. *Mycopathologia*. 2010;170:117-121.
379. Yamada R, Horikawa K, Ishihara S, et al. Successful treatment of *Aspergillus* liver abscesses in a patient with acute monoblastic leukemia using combination antifungal therapy including micafungin as a key drug. *Int J Hematol*. 2010;91:711-715.
380. Gupta KL, Rajaram KG, Joshi K, Sakhuja V. Progression of hepatic aspergillosis following second renal transplantation in a patient with recurrent glomerulonephritis. *Indian J Pathol Microbiol*. 2012;55:580-582.
381. Erdman SH, Barber BJ, Barton LL. *Aspergillus* cholangitis: a late complication after Kasai portoenterostomy. *J Pediatr Surg*. 2002;37:923-925.
382. Padmanabhan S, Battiwalla M, Hahn T, et al. Two cases of hepatic zygomycosis in allogeneic stem cell transplant recipients and review of literature. *Transpl Infect Dis*. 2007;9:148-152.
383. Marco del Pont J, De Cicco L, Gallo G, Llera J, De Santibanez E, D'agostino D. Hepatic arterial thrombosis due to *Mucor* species in a child following orthotopic liver transplantation. *Transpl Infect Dis*. 2000;2:33-35.
384. Mekeel KL, Hemming AW, Reed AI, et al. Hepatic mucormycosis in a renal transplant recipient. *Transplantation*. 2005;79:1636.
385. Suh IW, Park CS, Lee MS, et al. Hepatic and small bowel mucormycosis after chemotherapy in a patient with acute lymphocytic leukemia. *J Korean Med Sci*. 2000;15:351-354.
386. Oliver MR, Van Voorhis WC, Boeckh M, Mattson D, Bowden RA. Hepatic mucormycosis in a bone marrow transplant recipient who ingested naturopathic medicine. *Clin Infect Dis*. 1996;22:521-524.
387. Gurevich M, Levi I, Steinberg R, et al. Mucormycosis in a liver allograft: salvage re-transplantation and targeted immunosuppressive management. *Transpl Infect Dis*. 2012;14:E97-E101.
388. Sethi P, Balakrishnan D, Surendran S, Mohamed ZU. Fulminant zygomycosis of graft liver following liver transplantation. *BMJ Case Rep*. 2016;2016.
389. Li KW, Wen TF, Li GD. Hepatic mucormycosis mimicking hilar cholangiocarcinoma: a case report and literature review. *World J Gastroenterol*. 2010;16:1039-1042.
390. Vikram HR, Smilack JD, Leighton JA, Crowell MD, De Petris G. Emergence of gastrointestinal basidiobolomycosis in the United States, with a review of worldwide cases. *Clin Infect Dis*. 2012;54:1685-1691.
391. van den Berk GE, Noorduyt LA, van Ketel RJ, van Leeuwen J, Bemelman WA, Prins JM. A fatal pseudo-tumour: disseminated basidiobolomycosis. *BMC Infect Dis*. 2006;6:140.
392. Su H, Thompson GR 3rd, Cohen SH. Hepatic mucormycosis with abscess formation. *Diagn Microbiol Infect Dis*. 2012;73:192-194.
393. Lalwani S, Govindasamy M, Gupta M, et al. Gastrointestinal mucormycosis—four cases with different risk factors, involving different anatomical sites. *Indian J Gastroenterol*. 2012;31:139-143.
394. Geramizadeh B, Sanai Dashti A, Kadivar MR, Kord S. Isolated hepatic basidiobolomycosis in a 2-year-old girl: the first case report. *Hepat Mon*. 2015;15:e30117.
395. Hassan HA, Majid RA, Rashid NG, et al. Eosinophilic granulomatous gastrointestinal and hepatic abscesses attributable to basidiobolomycosis and fascioliasis: a simultaneous emergence in Iraqi Kurdistan. *BMC Infect Dis*. 2013;13:91.
396. Ejtehadi F, Anushiravani A, Bananzadeh A, Geramizadeh B. Gastrointestinal basidiobolomycosis accompanied by liver involvement: a case report. *Iran Red Crescent Med J*. 2014;16:e14109.
397. Busca A, Marmont F, Locatelli F, et al. Combined antifungal therapy, iron chelation and surgical resection as treatment of hepatic zygomycosis in a patient with haematological malignancy. *Mycoses*. 2010;53:275-278.
398. Tsui WM, Ma KF, Tsang DN. Disseminated *Penicillium marneffei* infection in HIV-infected subject. *Histopathology*. 1992;20:287-293.
399. Duong TA. Infection due to *Penicillium marneffei*, an emerging pathogen: review of 155 reported cases. *Clin Infect Dis*. 1996;23:125-130.
400. Liu X, Wu H, Huang X. Disseminated *Penicillium marneffei* infection with IRIS. *IDCases*. 2015;2:92-93.
401. Yousukh A, Jutavijittum P, Pisetpongsa P, et al. Clinicopathologic study of hepatic *Penicillium marneffei* in Northern Thailand. *Arch Pathol Lab Med*. 2004;128:191-194.
402. Bonacini M, Nussbaum J, Ahluwalia C. Gastrointestinal, hepatic, and pancreatic involvement with *Cryptococcus neoformans* in AIDS. *J Clin Gastroenterol*. 1990;12:295-297.
403. Das BC, Haynes I, Weaver RM, Acland PR. Primary hepatic cryptococcosis. *Br Med J (Clin Res Ed)*. 1983;287:464.
404. Utili R, Tripodi MF, Ragone E, et al. Hepatic cryptococcosis in a heart transplant recipient. *Transpl Infect Dis*. 2004;6:33-36.
405. Lu S, Furth EE, Blumberg EA, Bing Z. Hepatic involvement in a liver transplant recipient with disseminated cryptococcosis. *Transpl Infect Dis*. 2009;11:179-182.

406. Rohtagi A, Aggarwal A, Chabra MK, Dahale AS. Disseminated cryptococcosis with hepatic dysfunction as the initial manifestation in an immunocompetent adult. *Arch Iran Med.* 2013;16:303-305.
407. Cai X, Liu K, Liang Y, Yu H, Lv F, Liang X. Isolated biliary cryptococcosis manifesting as obstructive jaundice in an immunocompetent adult. *Int J Med Sci.* 2012;9:200-206.
408. Luo Y, Cui MY, Liao B, et al. Diagnostic and post-treatment CT appearance of biopsy proven mixed *Cryptococcus* and *Candida* cholangitis. *J Xray Sci Technol.* 2014;22:727-733.
409. Zhang C, Du L, Cai W, Wu Y, Lv F. Isolated hepatobiliary cryptococcosis manifesting as obstructive jaundice in an immunocompetent child: case report and review of the literature. *Eur J Pediatr.* 2014;173:1569-1572.
410. Nara S, Sano T, Ojima H, et al. Liver cryptococcosis manifesting as obstructive jaundice in a young immunocompetent man: report of a case. *Surg Today.* 2008;38:271-274.
411. Sabesin SM, Fallon HJ, Andriole VT. Hepatic failure as a manifestation of cryptococcosis. *Arch Intern Med.* 1963;111:661-669.
412. Bucuvalas JC, Bove KE, Kaufman RA, Gilchrist MJ, Oldham KT, Balistreri WF. Cholangitis associated with *Cryptococcus neoformans*. *Gastroenterology.* 1985;88:1055-1059.
413. Knapp WA, Seeley TT, Ruebner BH. Fatal coccidioidomycosis: report of two cases. *Calif Med.* 1972;116:86-90.
414. Zangerl B, Edel G, von Manitus J, Schmidt-Wilcke HA. Kokzidioidomykose als Ursache einer granulomatösen hepatitis. *Med Klin.* 1998;93:170-173.
415. Howard PF, Smith JW. Diagnosis of disseminated coccidioidomycosis by liver biopsy. *Arch Intern Med.* 1983;143:1335-1338.
416. Ryan ME, Kirchner JP, Sell T, Swanson M. Cholangitis due to *Blastomyces dermatitidis*. *Gastroenterology.* 1989;96:1346-1349.
417. Teixeira F, Gayotto LC, De Brito T. Morphological patterns of the liver in South American blastomycosis. *Histopathology.* 1978;2:231-237.
418. de Melo Braga G, Hessel G, Pereira RM, Escanhoela CA. Hepatic involvement in paediatric patients with paracoccidioidomycosis: a histological study. *Histopathology.* 2014;64:256-262.
419. Steinbruck K, Fernandes R, Campos CF, Bento G, Stoduto G, Auel T. Intrahepatic biliary paracoccidioidomycosis mimicking cholangiocarcinoma. *J Gastrointest Liver Dis.* 2014;23:239.
420. Sheikh RA, Prindiville TP, Yenamandra S, Munn RJ, Ruebner BH. Microsporidial AIDS cholangiopathy due to *Encephalitozoon intestinalis*: case report and review. *Am J Gastroenterol.* 2000;95:2364-2371.
421. Willson R, Harrington R, Stewart B, Fritsche T. Human immunodeficiency virus 1-associated necrotizing cholangitis caused by infection with *Septata intestinalis*. *Gastroenterology.* 1995;108:247-251.
422. Liberman E, Yen TS. Foamy macrophages in acquired immunodeficiency syndrome cholangiopathy with *Encephalitozoon intestinalis*. *Arch Pathol Lab Med.* 1997;121:985-988.
423. Ross AG, Bartley PB, Sleight AC, et al. Schistosomiasis. *N Engl J Med.* 2002;346:1212-1220.
424. Bica I, Hamer DH, Stadecker MJ. Hepatic schistosomiasis. *Infect Dis Clin North Am.* 2000;14:583-604.
425. Elbaz T, Esmat G. Hepatic and intestinal schistosomiasis: review. *J Adv Res.* 2013;4:445-452.
426. Manzella A, Ohtomo K, Monzawa S, Lim JH. Schistosomiasis of the liver. *Abdom Imaging.* 2008;33:144-150.
427. Lambertucci JR. Acute schistosomiasis mansoni: revisited and reconsidered. *Mem Inst Oswaldo Cruz.* 2010;105:422-435.
428. Ramanathan R, Nutman T. *Strongyloides stercoralis* infection in the immunocompromised host. *Curr Infect Dis Rep.* 2008;10:105-110.
429. Poltera AA, Katsimbura N. Granulomatous hepatitis due to *Strongyloides stercoralis*. *J Pathol.* 1974;113:241-246.
430. Mondou EN, Gnepp DR. Hepatic granuloma resulting from *Enterobius vermicularis*. *Am J Clin Pathol.* 1989;91:97-100.
431. Roberts KJ, Hubscher S, Mangat K, Sutcliffe R, Marudanayagam R. Pinworm infection masquerading as colorectal liver metastasis. *Ann R Coll Surg Engl.* 2012;94:e195-e197.
432. Furnee EJ, Spoto C, de Graaf MJ, Smakman N. *Enterobius vermicularis* infection of the liver in a patient with colorectal carcinoma with suspected liver metastasis. *BMJ Case Rep.* 2015;2015.
433. Daly JJ, Baker GF. Pinworm granuloma of the liver. *Am J Trop Med Hyg.* 1984;33:62-64.
434. Garcia HH, Moro PL, Schantz PM. Zoonotic helminth infections of humans: echinococcosis, cysticercosis and fascioliasis. *Curr Opin Infect Dis.* 2007;20:489-494.
435. Filippou D, Tselepis D, Filippou G, Papadopoulos V. Advances in liver echinococcosis: diagnosis and treatment. *Clin Gastroenterol Hepatol.* 2007;5:152-159.
436. Nunnari G, Pinzone MR, Gruttadauria S, et al. Hepatic echinococcosis: clinical and therapeutic aspects. *World J Gastroenterol.* 2012;18:1448-1458.
437. Craig P. *Echinococcus multilocularis*. *Curr Opin Infect Dis.* 2003;16:437-444.
438. Martinez C, Paredes R, Stock RP, et al. Cellular organization and appearance of differentiated structures in developing stages of the parasitic platyhelminth *Echinococcus granulosus*. *J Cell Biochem.* 2005;94:327-335.
439. Smith SA, Richards KS. Ultrastructure and microanalyses of the calcareous corpuscles of the protoscoleces of *Echinococcus granulosus*. *Parasitol Res.* 1993;79:245-250.
440. Rinaldi F, Brunetti E, Neumayr A, Maestri M, Goblirsch S, Tamarruzzi F. Cystic echinococcosis of the liver: a primer for hepatologists. *World J Hepatol.* 2014;6:293-305.
441. Pakala T, Molina M, Wu GY. Hepatic echinococcal cysts: a review. *J Clin Transl Hepatol.* 2016;4:39-46.
442. Lim JH. Toxocariasis of the liver: visceral larva migrans. *Abdom Imaging.* 2008;33:151-156.
443. Woodhall DM, Fiore AE. Toxocariasis: a review for pediatricians. *J Pediatric Infect Dis Soc.* 2014;3:154-159.
444. Hossack J, Ricketts P, Te HS, Hart J. A case of adult hepatic toxocariasis. Nature clinical practice. *Gastroenterol Hepatol.* 2008;5:344-348.
445. Hartleb M, Januszewski K. Severe hepatic involvement in visceral larva migrans. *Eur J Gastroenterol Hepatol.* 2001;13:1245-1249.
446. Kaushik SP, Hurwitz M, McDonald C, Pavli P. *Toxocara canis* infection and granulomatous hepatitis. *Am J Gastroenterol.* 1997;92:1223-1225.
447. Kaplan KJ, Goodman ZD, Ishak KG. Eosinophilic granuloma of the liver: a characteristic lesion with relationship to visceral larva migrans. *Am J Surg Pathol.* 2001;25:1316-1321.
448. Inan M, Sakru N, Vatansever U, Bilgi S. Visceral larva migrans presenting as acute abdomen in a child. *J Pediatr Surg.* 2006;41:e7-e9.
449. Berger T, Degremont A, Gebbers JO, Tönz O. Hepatic capillariasis in a 1-year-old child. *Eur J Pediatr.* 1990;149:333-336.
450. Choe G, Lee HS, Seo JK, et al. Hepatic capillariasis: first case report in the Republic of Korea. *Am J Trop Med Hyg.* 1993;48:611-625.
451. Sharma R, Dey AK, Mittal K, Kumar P, Hira P. *Capillaria hepatica* infection: a rare differential for peripheral eosinophilia and an imaging dilemma for abdominal lymphadenopathy. *Ann Parasitol.* 2015;61:61-64.
452. Klenzak J, Mattia A, Valenti A, Goldberg J. Hepatic capillariasis in Maine presenting as a hepatic mass. *Am J Trop Med Hyg.* 2005;72:651-653.
453. Sawamura R, Fernandes MI, Peres LC, et al. Hepatic capillariasis in children: report of 3 cases in Brazil. *Am J Trop Med Hyg.* 1999;61:642-647.
454. Terrier P, Hack I, Hatz C, Theintz G, Roulet M. Hepatic capillariasis in a 2-year-old boy. *J Pediatr Gastroenterol Nutr.* 1999;28:338-340.

455. Nabi F, Palaha HK, Sekhsaria D, Chiatla A. *Capillaria hepatica* infestation. *Indian Pediatr.* 2007;44:781-782.
456. Arjona R, Riancho JA, Aguado JM, Salesa R, González-Macías J. Fascioliasis in developed countries: a review of classic and aberrant forms of the disease. *Medicine (Baltimore).* 1995;74:13-23.
457. MacLean JD, Graeme-Cook FM. Case records of the Massachusetts General Hospital: weekly clinicopathological exercises. Case 12-2002: a 50-year-old man with eosinophilia and fluctuating hepatic lesions. *N Engl J Med.* 2002;346:1232-1239.
458. Acosta-Ferreira W, Vercelli-Retta J, Falconi LM. *Fasciola hepatica* human infection: histopathological study of sixteen cases. *Virchows Arch A Pathol Anat Histol.* 1979;383:319-327.
459. Marcos LA, Terashima A, Gotuzzo E. Update on hepatobiliary flukes: fascioliasis, opisthorchiasis and clonorchiasis. *Curr Opin Infect Dis.* 2008;21:523-530.
460. Lim JH, Kim SY, Park CM. Parasitic diseases of the biliary tract. *AJR Am J Roentgenol.* 2007;188:1596-1603.
461. Tappe D, Triefenbach R. Histopathological diagnosis of opisthorchiasis in an immigrant. *Am J Trop Med Hyg.* 2010;83:734-735.
462. Al Absi M, Qais AM, Al Katta M, Gafour M, Al-Wadan AH. Biliary ascariasis: the value of ultrasound in the diagnosis and management. *Ann Saudi Med.* 2007;27:161-165.
463. Javid G, Wani NA, Gulzar GM, et al. *Ascaris*-induced liver abscess. *World J Surg.* 1999;23:1191-1194.
464. Bari S, Sheikh KA, Ashraf M, Hussain Z, Hamid A, Mufti GN. *Ascaris* liver abscess in children. *J Gastroenterol.* 2007;42:236-240.
465. Lee CF, Lee WC, Wu RC, Chen TC. Intrahepatic duct stones harboring *Ascaris* ova: a case report. *Medicine (Baltimore).* 2016;95:e3139.
466. Fogaca HS, Oliveira CS, Barbosa HT, Lanfredi RM, Chagas V. Liver pseudotumor: a rare manifestation of hepatic granulomata caused by *Ascaris lumbricoides* ova. *Am J Gastroenterol.* 2000;95:2099-2101.
467. Swain R, Behera C, Mridha AR, Gupta SK. Massive hepatobiliary ascariasis at autopsy. *BMJ Case Rep.* 2015;2015.
468. Chakrabarti I, Giri A, De A, Roy AC. Radio-pathological diagnosis of hepatobiliary ascariasis: a rare entity. *J Cytol.* 2011;28:114-116.
469. Stanley SL Jr. Amoebiasis. *Lancet.* 2003;361:1025-1034.
470. Alam F, Salam MA, Hassan P, Mahmood I, Kabir M, Haque R. Amebic liver abscess in northern region of Bangladesh: sociodemographic determinants and clinical outcomes. *BMC Res Notes.* 2014;7:625.
471. Wuerz T, Kane JB, Boggild AK, et al. A review of amoebic liver abscess for clinicians in a nonendemic setting. *Can J Gastroenterol.* 2012;26:729-733.
472. Congly SE, Shaheen AA, Meddings L, Kaplan GG, Myers RP. Amebic liver abscess in USA: a population-based study of incidence, temporal trends and mortality. *Liver Int.* 2011;31:1191-1198.
473. Mikolajczak SA, Kappe SH. A clash to conquer: the malaria parasite liver infection. *Mol Microbiol.* 2006;62:1499-1506.
474. Abro AH, Ustadi AM, Abro HA, Abdou AS, Younis NJ, Akaila SI. Jaundice with hepatic dysfunction in *P. falciparum* malaria. *J Coll Physicians Surg Pak.* 2009;19:363-366.
475. Shah S, Ali L, Sattar RA, Aziz T, Ansari T, Ara J. Malarial hepatopathy in *falciparum* malaria. *J Coll Physicians Surg Pak.* 2009;19:367-370.
476. Bhalla A, Suri V, Singh V. Malarial hepatopathy. *J Postgrad Med.* 2006;52:315-320.
477. Pongponratn E, Prommano O, Chaisri U, Viriyavejakul P, Wilairatana P. Plasmodium malariae-infected erythrocytes in the peripheral blood, liver, stomach and duodenum: an ultrastructural study. *Southeast Asian J Trop Med Public Health.* 2012;43:1080-1086.
478. Cox-Singh J, Hiu J, Lucas SB, et al. Severe malaria—a case of fatal Plasmodium knowlesi infection with post-mortem findings: a case report. *Malar J.* 2010;9:10.
479. Kochar DK, Agarwal P, Kochar SK, et al. Hepatocyte dysfunction and hepatic encephalopathy in *Plasmodium falciparum* malaria. *QJM.* 2003;96:505-512.
480. Anand AC, Ramji C, Narula AS, Singh W. Malarial hepatitis: a heterogeneous syndrome? *Natl Med J India.* 1992;5:59-62.
481. Whitten R, Milner DA Jr, Yeh MM, Kamiza S, Molyneux ME, Taylor TE. Liver pathology in Malawian children with fatal encephalopathy. *Hum Pathol.* 2011;42:1230-1239.
482. Rupani AB, Amarapurkar AD. Hepatic changes in fatal malaria: an emerging problem. *Ann Trop Med Parasitol.* 2009;103:119-127.
483. Viriyavejakul P, Khachonsakumet V, Punsawad C. Liver changes in severe *Plasmodium falciparum* malaria: histopathology, apoptosis and nuclear factor kappa B expression. *Malar J.* 2014;13:106.
484. Maekelt GA. Diagnostic procedures in the evaluation of hepatic diseases: studies to determine parasitologic etiology. *Lab Res Methods Biol Med.* 1983;7:129-139.
485. Cruz I, Nieto J, Moreno J, Cañavate C, Desjeux P, Alvar J. *Leishmania*/HIV co-infections in the second decade. *Indian J Med Res.* 2006;123:357-388.
486. Albrecht H, Sobottka I, Emminger C, et al. Visceral leishmaniasis emerging as an important opportunistic infection in HIV-infected persons living in areas nonendemic for *Leishmania donovani*. *Arch Pathol Lab Med.* 1996;120:189-198.
487. Malla N, Mahajan RC. Pathophysiology of visceral leishmaniasis: some recent concepts. *Indian J Med Res.* 2006;123:267-274.
488. Duarte MI, Corbett CE. Histopathological patterns of the liver involvement in visceral leishmaniasis. *Rev Inst Med Trop Sao Paulo.* 1987;29:131-136.
489. Koshy A, Al-Azmi WM, Narayanan S, et al. Leishmaniasis diagnosed by liver biopsy: management of two atypical cases. *J Clin Gastroenterol.* 2001;32:266-267.
490. Seixas Duarte MI, Tuon FF, Pagliari C, Kauffman MR, Brasil RA. Human visceral leishmaniasis expresses Th1 pattern in situ liver lesions. *J Infect.* 2008;57:332-337.
491. Khanlari B, Bodmer M, Terracciano L, Heim MH, Fluckiger U, Weisser M. Hepatitis with fibrin-ring granulomas. *Infection.* 2008;36:381-383.
492. Dogan N, Kabukcuoglu S, Vardareli E. Toxoplasmic hepatitis in an immunocompetent patient. *Turkiye Parazitolo Derg.* 2007;31:260-263.
493. Atilla A, Aydin S, Demirdoven AN, Kiliç SS. Severe toxoplasmic hepatitis in an immunocompetent patient. *Jpn J Infect Dis.* 2015;68:407-409.
494. Tiwari I, Rolland CF, Popple AW. Cholestatic jaundice due to toxoplasma hepatitis. *Postgrad Med J.* 1982;58:299-300.
495. Weitberg AB, Alper JC, Diamond I, Fligiel Z. Acute granulomatous hepatitis in the course of acquired toxoplasmosis. *N Engl J Med.* 1979;300:1093-1096.
496. Bonacini M, Kanel G, Alamy M. Duodenal and hepatic toxoplasmosis in a patient with HIV infection: review of the literature. *Am J Gastroenterol.* 1996;91:1838-1840.
497. Campos M, Jouzdani E, Sempoux C, et al. Sclerosing cholangitis associated to cryptosporidiosis in liver-transplanted children. *Eur J Pediatr.* 2000;159:113-115.
498. Chen XM, LaRusso NF. Cryptosporidiosis and the pathogenesis of AIDS-cholangiopathy. *Semin Liver Dis.* 2002;22:277-289.
499. Abdo A, Klassen J, Urbanski S, Raber E, Swain MG. Reversible sclerosing cholangitis secondary to cryptosporidiosis in a renal transplant patient. *J Hepatol.* 2003;38:688-691.
500. Rodrigues F, Davies EG, Harrison P, et al. Liver disease in children with primary immunodeficiencies. *J Pediatr.* 2004;145:333-339.
501. Denkinger CM, Harigopal P, Ruiz P, Dowdy LM. *Cryptosporidium parvum*-associated sclerosing cholangitis in a liver transplant patient. *Transpl Infect Dis.* 2008;10:133-136.

502. Hayward AR, Levy J, Facchetti F, et al. Cholangiopathy and tumors of the pancreas, liver, and biliary tree in boys with X-linked immunodeficiency with hyper-IgM. *J Immunol.* 1997;158:977-983.
503. Dimicoli S, Bensoussan D, Latger-Cannard V, et al. Complete recovery from *Cryptosporidium parvum* infection with gastroenteritis and sclerosing cholangitis after successful bone marrow transplantation in two brothers with X-linked hyper-IgM syndrome. *Bone Marrow Transpl.* 2003;32:733-737.
504. Rahman M, Chapel H, Chapman RW, Collier JD. Cholangiocarcinoma complicating secondary sclerosing cholangitis from cryptosporidiosis in an adult patient with CD40 ligand deficiency: case report and review of the literature. *Int Arch Allergy Immunol.* 2012;159:204-208.