

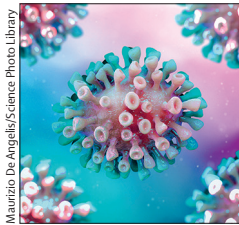


Since January 2020 Elsevier has created a COVID-19 resource centre with free information in English and Mandarin on the novel coronavirus COVID-19. The COVID-19 resource centre is hosted on Elsevier Connect, the company's public news and information website.

Elsevier hereby grants permission to make all its COVID-19-related research that is available on the COVID-19 resource centre - including this research content - immediately available in PubMed Central and other publicly funded repositories, such as the WHO COVID database with rights for unrestricted research re-use and analyses in any form or by any means with acknowledgement of the original source. These permissions are granted for free by Elsevier for as long as the COVID-19 resource centre remains active.



Coronavirus epidemic: preparing for extracorporeal organ support in intensive care



Maurizio De Angelis/Science Photo Library

Published Online

February 6, 2020

[https://doi.org/10.1016/S2213-2600\(20\)30060-6](https://doi.org/10.1016/S2213-2600(20)30060-6)

For more on **2019-nCoV global surveillance** see <https://www.who.int/health-topics/coronavirus>

For more on the **first cases of 2019-nCoV in Wuhan** see **Articles** *Lancet* 2020; **395**: 497–506

For more on the **first cases of 2019-nCoV confirmed in Europe** see <http://www.euro.who.int/en/health-topics/emergencies/pages/news/news/2020/01/2019-ncov-outbreak-first-cases-confirmed-in-europe>

For more on **extracorporeal membrane oxygenation centres** see *JAMA* 2011; **306**: 1659–68

For more on the **role of ECMO in pandemic management** see *J Extra Corpor Technol* 2010; **42**: 268–80

For more on **treatment limitations in the era of ECMO** see **Articles** *Lancet Respir Med* 2017; **5**: 769–70

For more on **acute myocarditis associated with novel MERS coronavirus** see *Ann Saudi Med* 2016; **36**: 78–80

Zoonotic viral infections are more frequently crossing species to infect human populations. In 2003, the severe acute respiratory syndrome (SARS) virus was transmitted to humans from exotic animals in wet markets in China, and in 2015, the Middle East respiratory syndrome (MERS) virus was transmitted from camels in Saudi Arabia. In both cases, and with the 2019 coronavirus outbreak in China, the original host of the virus is likely to be bats.

The 2019 coronavirus (2019-nCoV) was identified as such with the use of electron microscope analysis, to determine its shape, and genomic sequencing. The virus causes an aspecific respiratory syndrome and a generalised inflammatory response in humans. Patient zero was likely to have been infected by 2019-nCoV at a seafood market in Wuhan (Hubei province, China)—WHO has provided the case definition. Although the information surrounding the current situation is changing on a daily basis, transparency and consistent data through official channels for the international scientific community is highly recommended. Experts provide their opinion based on experience and current information, but the basic reproduction number (R_0)—ie, the number of cases generated by one case—is presently unclear, and data about mortality are inconsistent. Both in Europe and the USA, close attention is being paid to the problem despite the apparent low risk of an immediate epidemic diffusion.

What has been confirmed is that some infected individuals have developed acute respiratory distress syndrome (ARDS), which requires mechanical ventilation and, in the most severe cases, extracorporeal membrane oxygenation (ECMO).

Transmission of 2019-nCoV is likely to occur through large droplets, which could provide an explanation for the initial infection at the wet fish market in Wuhan, although contact by aerosols cannot be excluded. In recent reports, the median time from onset of symptoms to first hospital admission was 7.0 days (minimum to maximum 4.0–8.0), to shortness of breath was 8.0 days (5.0–13.0), to ARDS was 9.0 days (8.0–14.0), to mechanical ventilation was 10.5 days (7.0–14.0), and to intensive care unit (ICU) admission was 10.5 days. Beyond the classic prevention measures, strict adherence to suggested precautions should also be followed to prevent transmission. Despite specific sanitary measures at airports and frontiers, we must be able to respond appropriately to the international public health emergency declared by WHO. From our past experience of treating viral infections in critically ill patients, we know the level of severity of illness in patients infected by coronavirus depends on the presence of comorbidities and immune status of the host. On the one hand, anergic patients are likely to develop a severe clinical response; on the other hand, an excessive immune response might also add to severity through a generalised inflammatory status. In both cases, immune dysregulation can lead to a progressive cascade of pathophysiological events leading to critical illness with multiple organ dysfunction.

Because it is not possible to anticipate the extent of the epidemic and the consequent number of patients who require intensive care management, intensive care clinicians must be prepared to provide specific organ support treatments and to consider that this type of treatment might be necessary for a large number of patients. Extracorporeal therapies can be helpful to support different organs, such as the lungs, heart, kidneys, and liver, through the application of specific devices. Venovenous ECMO is a complex and sophisticated support for treatment of the most severe forms of acute hypoxaemic respiratory failure; it is performed in specialised, experienced referral centres that are commonly organised into networks, serving large regions or whole countries. The number of critically ill individuals who are infected with 2019-nCoV and who will require ECMO is unknown. In some regions, more than in others, a shortness of ECMO devices could occur and might impose choices that come with important ethical questions. Without predefined criteria to guide the decision on who will get the treatment and in what order, this will lead unavoidably to a first-come-first-serve approach. Clinical presentation, comorbidities, age, number of days of mechanical ventilation before indication for ECMO,



Edwin Remsburg/WVI Pics/Science Photo Library

and risk for complications are all factors influencing a potentially favourable outcome. 2019-nCoV might also cause severe myocarditis resulting in acute heart failure, which might indicate, in the most severe forms, the need for venous-arterial ECMO support.

Extracorporeal CO₂ removal (ECCO2R) is a technique that can be performed in more ICUs due to the much lower level of complexity than is required for ECMO, but ECCO2R is not really helpful for severely hypoxaemic patients who actually need full ECMO treatment. Acute kidney injury in these patients is not common, but it might result from a systemic inflammatory syndrome involving combined myocardial and kidney function. In these cases, continuous renal replacement therapies by haemofiltration and haemodiafiltration can contribute to resolution of organ failure. Liver dysfunction can also rarely occur in patients with severe viral infection and it might require extracorporeal blood purification techniques to support the patient until hepatocyte recovery occurs. Finally, a sepsis-like syndrome might occur frequently due to the virus itself or to a superimposed bacterial infection and in this case, since pharmacological approaches have shown poor results,

new extracorporeal organ support therapies including haemoadsorption and haemoperfusion, with new sorbent cartridges designed to remove cytokines and other circulating mediators, should be considered.

However the 2019-nCoV epidemic evolves, ICU personnel must be prepared and trained to apply early and optimal interventions. Extracorporeal organ support therapies might represent an important part of the response and clinicians and other health-care professionals need to be familiar with this sophisticated therapy. A call to action should be made to raise awareness of the different extracorporeal techniques, each with specific criteria and modalities of prescription, delivery, and monitoring.

We declare no competing interests.

**Claudio Ronco, Paolo Navalesi, Jean Louis Vincent*
ronco@goldnet.it

Department of Medicine, University of Padua, Padua, Italy (CR, PN); International Renal Research Institute, Vicenza, Italy (CR, PN); Division of Nephrology, Dialysis and Transplantation, San Bortolo Hospital, Vicenza, Italy (CR); Anesthesia and Intensive Care Unit, Padua University Hospital, Padua, Italy (PN); and Department of Intensive Care, Erasme University Hospital, Bruxelles, Belgium (JLV)

For more on ECCO2R see [Review](#) *Lancet Respir Med* 2018; **6**: 874–84

For more on ECCO2R removal see *Crit Care* 2014; **18**: 222

For more on **cardioresnal syndrome in sepsis** see *J Crit Care* 2018; **43**: 122–27

For more on **extracorporeal organ support in critical illness and acute kidney injury** see *Intensive Care Med* 2018; **44**: 1447–59

For more on **extracorporeal organ support in critically ill patients** see *Blood Purif* 2019; **48**: 99–105

For more on **cytosorb adsorption columns** see *Blood Purif* 2019; **48**: 196–202

For more on **sorbent devices** see *Blood Purif* 2019; **47**: 94–100

For more on **the call to action for research on use of extracorporeal life support** see *Chest* 2018; **153**: 788–91

Patient perspectives

Surviving sepsis and intensive care unit delirium: a remarkable recovery

Waking shivering in the night, Michelle Bryden assumed she had flu, and took the following day off work. But then her feet and hands started to turn purple. In fact, she had contracted bacterial meningitis caused by *Streptococcus pneumoniae* and was admitted to Howard County General (Columbia, MD), where she was eventually diagnosed with sepsis. At the time, in April 2019, Michelle was a healthy, active 48-year-old, with a passion for gardening, who worked at Johns Hopkins Applied Physics Laboratory (Laurel, MD, US) as an engineer.

Initially, antibiotics gave her some respite, but when her vision started to deteriorate, she was transferred to Johns Hopkins Hospital. The doctors treated her sight loss but when she experienced breathing difficulties, she was transferred to intensive care, intubated, and sedated. 2 days later she was extubated, but with further respiratory problems she was back in critical care after 2 days. With a total of 4 days on mechanical ventilation, and 10 days after her first admission, Michelle's life had become fragile and tenuous. "I can only describe it as being like a dream", she says, "only when I left the hospital, did I really fully appreciate how dangerous it had all been".

Delirium in the intensive care unit (ICU), is characterised by an acute onset of intense confusion and is extremely common in critical care, particularly for those patients on mechanical ventilation. Patients are in a dream-like state, which can lead on to hallucinations, delusions, and paranoia. Alarming, delirium can often go undiagnosed, despite its association with post-traumatic stress disorder, higher risk of long-term cognitive damage, and lower survival rates. In her delirium, Michelle was convinced she was the star of a medical drama TV show—she did not believe the doctors were doctors and was aggravated she was not being given her breaks from her acting role. She laughs when she retells the story, but delirium is very disorientating in an already alien environment. Even though she was screened for and diagnosed with ICU delirium, Michelle's memory loss ("I couldn't remember anything, even my birthday") and inability to pass basic cognitive tests led her husband to believe she was having a stroke.

Ken, Michelle's husband, describes her illness progression as a "roller coaster"—periods of stability and lucidity were followed by sudden emergency intubations: "my greatest fear was her health taking a serious turn for



Michelle Bryden

Published Online
January 30, 2020
[https://doi.org/10.1016/S2213-2600\(20\)30043-6](https://doi.org/10.1016/S2213-2600(20)30043-6)

For more on **Michelle's story** see https://www.hopkinsmedicine.org/pulmonary/research/outcomes_after_critical_illness_surgery/oacis_videos_news.html

For more on **ICU delirium** see *Ann Intensive Care* 2012; **2**: 49

For more on **PTSD in the ICU** see *Spotlight Lancet Respir Med* 2019; **7**: 843–44

For the **VICTUS trial protocol** see *Trials* 2019; **20**: 197