

Astrocytic Reaction Predominance in Chronic Encephalitis of Junin Virus-Infected Rats

Eduardo F. Lascano, María I. Berría, María M. Avila, and Mercedes C. Weissenbacher

Departamento de Microbiología, Facultad de Medicina, Universidad de Buenos Aires, Buenos Aires, Argentina

Junin virus antigen distribution and astrocytic reaction to prolonged infection were characterized in rat brain by the PAP technique. During the acute stage of neurologic disease following intracerebral inoculation, Junin antigen was detected in 100% of animals, strongly in most neurons but also to a much lesser degree in scattered astrocytes, dropping to 20% of rats at 540 days postinfection. Initially labeled in all brain areas, viral antigen gradually disappeared from hippocampus but persisted irregularly in cerebral cortex, basal ganglia, Purkinje cells, pons, and medulla oblongata. Such a pattern suggests that specific neuronal subpopulations, in spite of apparently unaltered cell morphology, may persistently harbor the virus, leading on occasion to a delayed neurologic syndrome. During both the acute and chronic stages of disease, a mild inflammatory exudate was observed, characterized by the presence of T and B lymphocytes, as well as macrophages and unidentified round cells. GFAP immunostaining showed increased astrocytic reaction as infection lapsed into chronicity. Corpus callosum, hippocampus, and cerebellum exhibited the sharpest reactive astrogliosis, followed by basal ganglia, pons, and medulla oblongata, whereas in cerebral cortex it was considerably less. Astrocyte activation, which failed to correlate with viral antigen presence in neurons, seems to result from a generalized condition, possibly including diffusible brain factors triggered by viral infection. Such widespread astroglial reaction may thus contribute to the outcome of the late neurologic syndrome.

KEY WORDS: Argentine hemorrhagic fever, neurological disease, viral antigen

INTRODUCTION

Junin virus, a member of the Arenaviridae family and etiologic agent of Argentine hemorrhagic fever, is known to induce neurologic disease in some animal

models. As previously reported [Weissenbacher et al., 1986], following intracerebral inoculation of newborn rats with XJ strain three different stages could be discerned: an early phase of acute disease, up to 30 days postinfection (pi), with 5% mortality; an intermediate one, extending to 280 days pi, without clinical signs but with evident viral persistence; and a final period of chronic illness, featuring a clinical neurologic syndrome.

However, a more expansive histopathologic study of samples corresponding to these sequential stages was lacking. Therefore, on the basis of brain tissue findings, the purpose of the present study was to characterize the topographical distribution of viral antigen and the degree of astrocytic reaction to prolonged infection. Since chronic neurologic disease in rats seems associated with virus persistence and long-lasting immunologic stimulation [Weissenbacher et al., 1986], factors involved in faulty clearance of brain virus could explain the mechanism through which the viral infection may ultimately damage the CNS.

Extrapolation of data from a useful model of Junin virus chronic neurologic disease, such as the rat has proved to be, may help to shed some light on the pathogenesis of the late neurologic syndrome observed at times in Argentine hemorrhagic fever patients [Maiztegui et al., 1979; Melcon and Herkovits, 1981].

MATERIALS AND METHODS

Virus

The XJ prototype strain of Junin virus was used.

Animals

Two-day-old Wistar rats were employed.

Experimental Design

Animals were intracerebrally inoculated with 10^4 LD₅₀ of virus. Ten rats each were harvested at 10, 18,

Accepted for publication July 28, 1989.

Address reprint requests to Dr. Eduardo F. Lascano, Departamento de Microbiología, Facultad de Medicina, UBA, Paraguay 2155, 1121 Buenos Aires, Argentina.

TABLE I. Distribution of Junin Virus Antigen in Intracerebrally Inoculated Rats*

	Days postinfection					
	30	82	160	280	450	540
No. positive animals/ No. inoculated animals	10/10	8/10	6/10	1/10	1/10	2/10
Cerebral cortex	++++	++	++	++	++	++
Hippocampus	++++	-	-	-	-	-
Basal ganglia	++++	++	++	++	+	+
Cerebellum	++++	++	++	++	+	+
Pons and medulla oblongata	++++	++	++	++	+	+

*-, No reaction; + to + + + +, least to greatest intensity of PAP labeling.

30, 82, 160, 280, 450, and 540 days postinoculation (pi). Coronal brain sections, including cerebral cortex, basal ganglia, cerebellum, pons, and medulla oblongata, were fixed by CNS perfusion with 8% paraformaldehyde in Tris buffer, pH 7.2, followed by immersion in the same fixative for several days. Samples were then dehydrated in 75%, 96%, and 100% ethanols, cleared in xylene, and embedded in paraffin. Uninoculated age-matched animals were used as controls at harvesting times.

Histological Study

Techniques employed to identify brain structures included hematoxylin-eosin (HE) for routine examination and special staining methods such as Luxol fast blue-Holmes silver nitrate for myelin and neurofibrils, the Nissl procedure for neurons, and an expressly developed silver impregnation method for neurons and glial cells. Solutions for the silver impregnation method comprised 1) 2% aqueous potassium bichromate; 2) 1% aqueous silver nitrate plus 0.4% aqueous potassium carbonate, and the resulting precipitate just dissolved by dropwise addition of ammonium hydroxide; and 3) 0.25% (w/v) gelatin dispersed in warm distilled water followed by addition of 10% paraformaldehyde. The steps for staining were as follows: 1) Samples were deparaffinized, hydrated, and sensitized with potassium bichromate solution for 2 min; 2) preparations were washed several times in distilled water; 3) one drop of pure pyridine was added for each milliliter of filtered silver solution and then used to impregnate samples at 60°C for 15 min; and 4) Formalin-gelatin mixture was employed to reduce silver, the reaction left to rest for 10 min. If the staining was weak, as usually occurs, steps 2-4 were repeated as required until intensity and sharpness were achieved.

Immunoperoxidase Procedures

The PAP method was employed to label Junin virus antigen and glial fibrillary acidic protein (GFAP) as described elsewhere [Lascano and Berria, 1983] and to stain T lymphocytes, B lymphocytes, and macrophages as previously reported [Lascano et al., 1986].

RESULTS

Rat brains harvested up to 30 days pi were considered representative of the acute stage of neurologic disease, while the remainder were regarded as depicting chronic infection.

Table I summarizes findings from virus antigen-PAP immunostaining, gradually dropping to 2/10 at 540 days pi. The number of positive cells peaked at 30 days pi, declining thereafter. From 82 days pi until the end of the observation period, viral antigen gradually disappeared from hippocampus, but persisted irregularly in cerebral cortex, basal ganglia, cerebellum, pons and medulla oblongata. During the acute period, the neuronal cytoplasm exhibited a slender yellowish-ochre deposit of viral antigen, as illustrated by cerebral cortex (Fig. 1a) and cerebellum (Fig. 1b), but from 82 days pi onward, staining became dark brown, apparently because of antigen concentration, particularly in cerebral cortex (Fig. 1c) and in Purkinje cells (Fig. 1d). As regards viral antigen in astrocytes, it was also observed in both the acute and chronic stages, but in every case to a much lesser extent than in neurons.

In contrast to the overt presence of viral antigen in neurons, the histological techniques that were used failed to disclose any degenerative, atrophic, or necrotic changes in brain cells. Resorting to the described variant of silver impregnation, the unaltered stratified arrangement of brain neurons, the apparent absence of nuclear changes, and the sharply stained perinuclear cytoplasm were readily distinguished, even in areas such as cerebral cortex (Fig. 2a) and basal ganglia (Fig. 2b), where viral presence was recorded up to 540 days pi. Likewise, by this silver procedure no modifications could be discerned in oligodendrocytes (Fig. 2c), while Nissl staining confirmed the lack of cytoplasmic changes in neurons. In support, the combined Luxol fast blue-Holmes technique showed no alterations in neurofibrils or in myelin sheaths throughout the brain (Fig. 3).

On the basis of HE staining, inflammatory exudate was mild except during the chronic stage, when on occasion [Weissenbacher et al., 1986], it was manifested by rather thick perivascular cuffings. PAP identification of immune cells disclosed that the inflammatory response mainly featured T lymphocytes and macro-

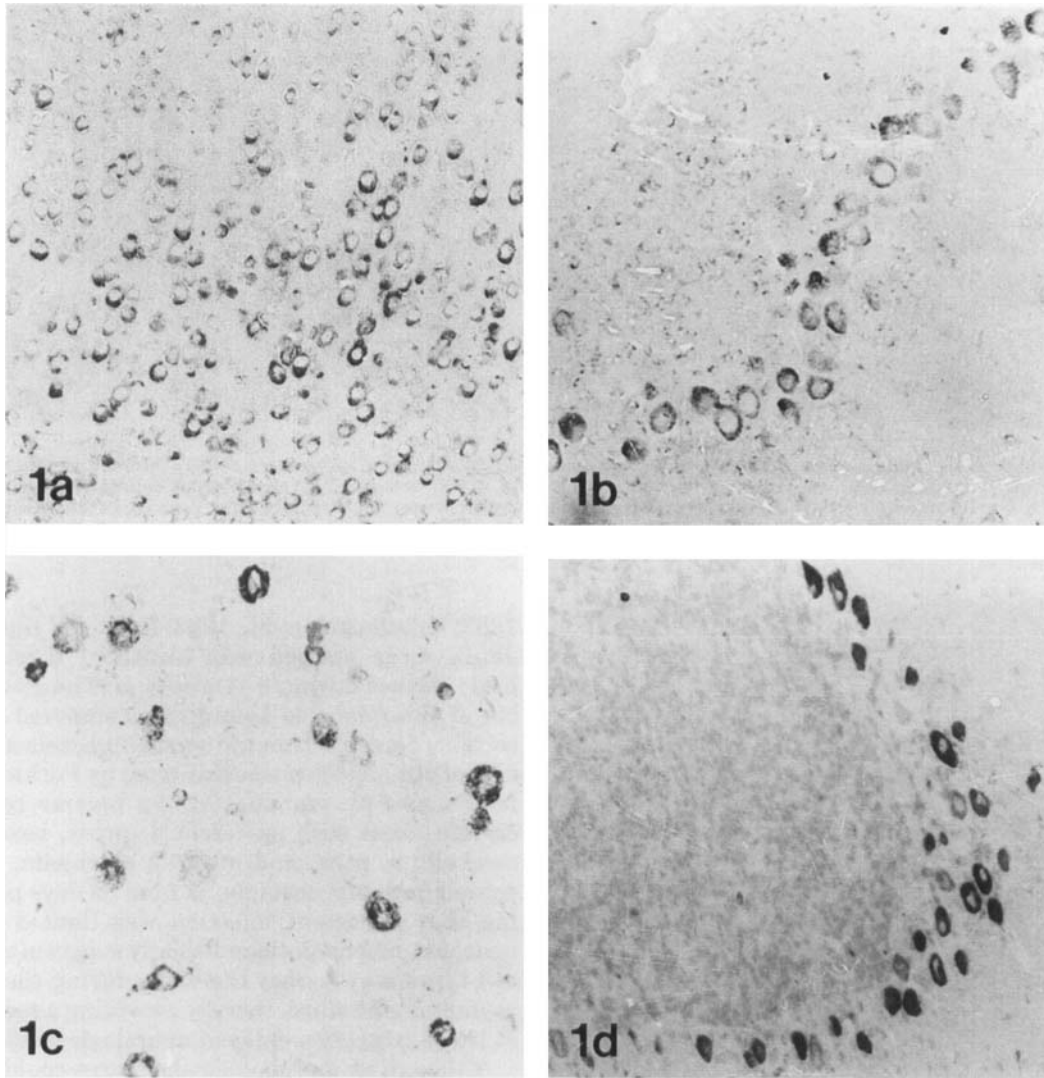


Fig. 1. Immunolabeling of Junin virus antigen. PAP technique. **a:** Numerous stained neurons are seen in cerebral cortex; 18 days pi. $\times 250$. **b:** Sharp labeling of Purkinje cells; weaker staining in granular cells; 18 days pi. $\times 250$. **c:** In cerebral cortex, scattered but strongly

labeled neurons, larger than those observed during acute stage; 82 days pi. $\times 250$. **d:** Remarkable concentration of viral antigen in Purkinje cells; 280 days pi. $\times 250$.

phages, together with a few B lymphocytes and a variable number of unidentified round cells. This immunoperoxidase profile persisted until the very end of the observation period.

Table II outlines the results of GFAP immunostaining and also staining by the PAP technique. Degrees of astrocytic reaction degree, which increased with the successive stages of the disease, are depicted. Specifically, the cell activation, representing faster morphologic and immunocytochemical maturation versus control animals, featured hyperplasia and hypertrophy of cell bodies and processes. As from the onset, cerebellum exhibited sharp GFAP staining of astrocytes and of Bergmann fibers (Fig. 4a). Although the glial reaction was less evident in basal ganglia, isolated cell areas of

strong labeling were observed (Fig. 4b). On occasion, foci of bizarre astrocytes were seen throughout the brain, including the thalamus (Fig. 4c). Toward the end of the observation period, Bergmann fibers gradually stained even more heavily for GFAP (Fig. 4d). Hyperplasia and hypertrophy were often depicted by an increase in number and size of vascular end-feet, making up a sharp continuous border. Furthermore, a few degenerative foci appeared as from 30 days pi, represented by amorphous GFAP-positive masses or granules scattered within brain tissues. Table II also shows that the corpus callosum, hippocampus, and cerebellum had the sharpest astrocytic activation, followed by basal ganglia, pons, and medulla oblongata, whereas in cerebral cortex glial reaction was considerably weaker.

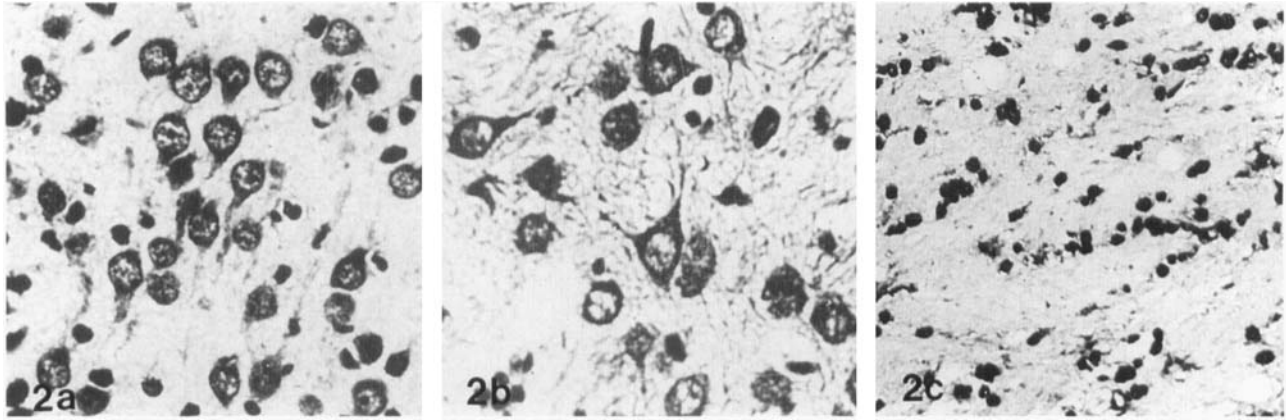


Fig. 2. Variant of silver impregnation method. **a:** In cerebral cortex, orderly arranged neurons show vesicular nuclei and sharply stained perinuclear cytoplasm; glial cells are densely stained; 160 days pi. $\times 500$. **b:** Normal appearance of large thalamic neurons;

slight staining of axons surrounding neurons and glial cells; 540 days pi. $\times 500$. **c:** Extending along corpus callosum fibers, rows of oligodendrocytes; staining allows a few processes to be visualized; 540 days pi. $\times 300$.

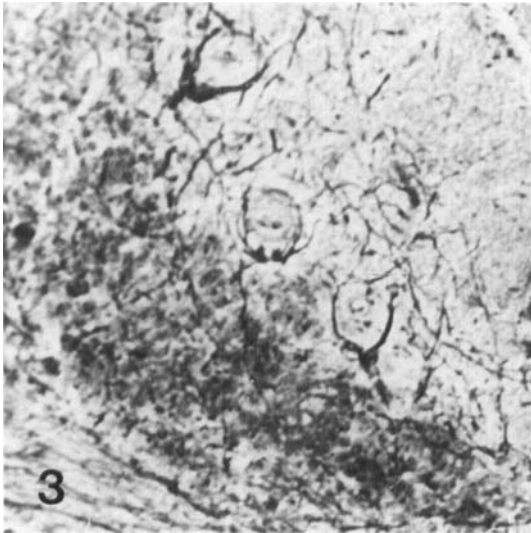


Fig. 3. Luxol fast blue-Holmes method. Single row of Purkinje cells between molecular and granular layers; at bottom left, axons with spared myelin sheaths; 540 days pi. $\times 400$.

DISCUSSION

As shown by general and specialized staining methods, the XJ strain of Junin virus induced mild histological changes in rat brain since the inflammatory reaction was moderate and, except astrocytic activation, no apparent neuronal, oligodendroglial, or myelin alterations were observed. The fact that during the chronic period infectious virus could only be rescued by coculture [Weissenbacher et al., 1986] indicates that Junin virus may persist in brain tissues, either causing a low-grade productive infection or remaining in an abortive state during which synthesis or assembly of viral components is incomplete.

In common with other CNS viral infections [Bernard et al., 1983; de la Monte et al., 1983; Fekadu et al.,

1982; Kristensson et al., 1983; Sethi and Lipton, 1985], Junin virus antigen was identified throughout the brain tissues during 3–4 weeks pi. The greatest number of Junin-labeled neurons was observed in cerebral cortex whereas within the cerebellum, selective expression of viral antigen was exhibited by Purkinje cells. At later times pi, immunostaining became restricted to certain areas such as cerebral cortex, basal ganglia, cerebellum, pons, and medulla oblongata, but disappeared from hippocampus as from 82 days pi. The finding that persistent infection was limited to specific neuronal subpopulations strongly suggests that certain cell types may harbor the virus during the prolonged asymptomatic stage, thereby providing a reservoir that at times triggers a delayed neurologic syndrome.

Although no morphological changes could be seen in infected neurons, it is quite possible that signs of disease may develop because of dysfunction in such highly specialized cells. The selective vulnerability of neuronal subpopulations to viral infections has been reported for many RNA viruses [Kristensson and Norrby, 1986], and, by comparing immunocytochemical findings to date, Purkinje cells stand out as a peculiar reservoir for persistent infection by virus such as JHM [Sorensen and Dales, 1985], human coronavirus [Pearson and Mims, 1983], and reovirus type 3 [Spriggs et al., 1983]. It should be emphasized that the long-lasting detection of Junin virus antigen observed in cerebral cortex neurons and in Purkinje cells has also been described for lymphocytic choriomeningitis virus [Rodriguez et al., 1983], prototype of the Arenaviridae family to which Junin virus belongs. In our rat model, viral antigen was located mainly in neurons and, to a lesser extent, in astrocytes, closely paralleling a feature previously described for the mouse [Lascano and Berria, 1983]. Actually, neurons and astrocytes are precisely the two CNS cell types in which budding of Junin virus particles has been demonstrated [Lascano

TABLE II. PAP Staining of GFAP in Junin Virus-Intracerebrally Inoculated Rats*

Brain areas	Days postinfection					
	30	82	160	280	450	540
Cerebral cortex	+	+	++	+++	+++	+++
Corpus callosum	++++	++++	++++	++++	++++	++++
Hippocampus	++++	++++	++++	++++	+++++	+++++
Basal ganglia	+++	+++	+++	+++	+++	+++
Cerebellum	+++	+++	+++	+++	+++	+++
Pons and medulla oblongata	++	+++	+++	+++	+++	+++

*+ to +++++, least to greatest degrees of astrocyte hyperplasia and hypertrophy.

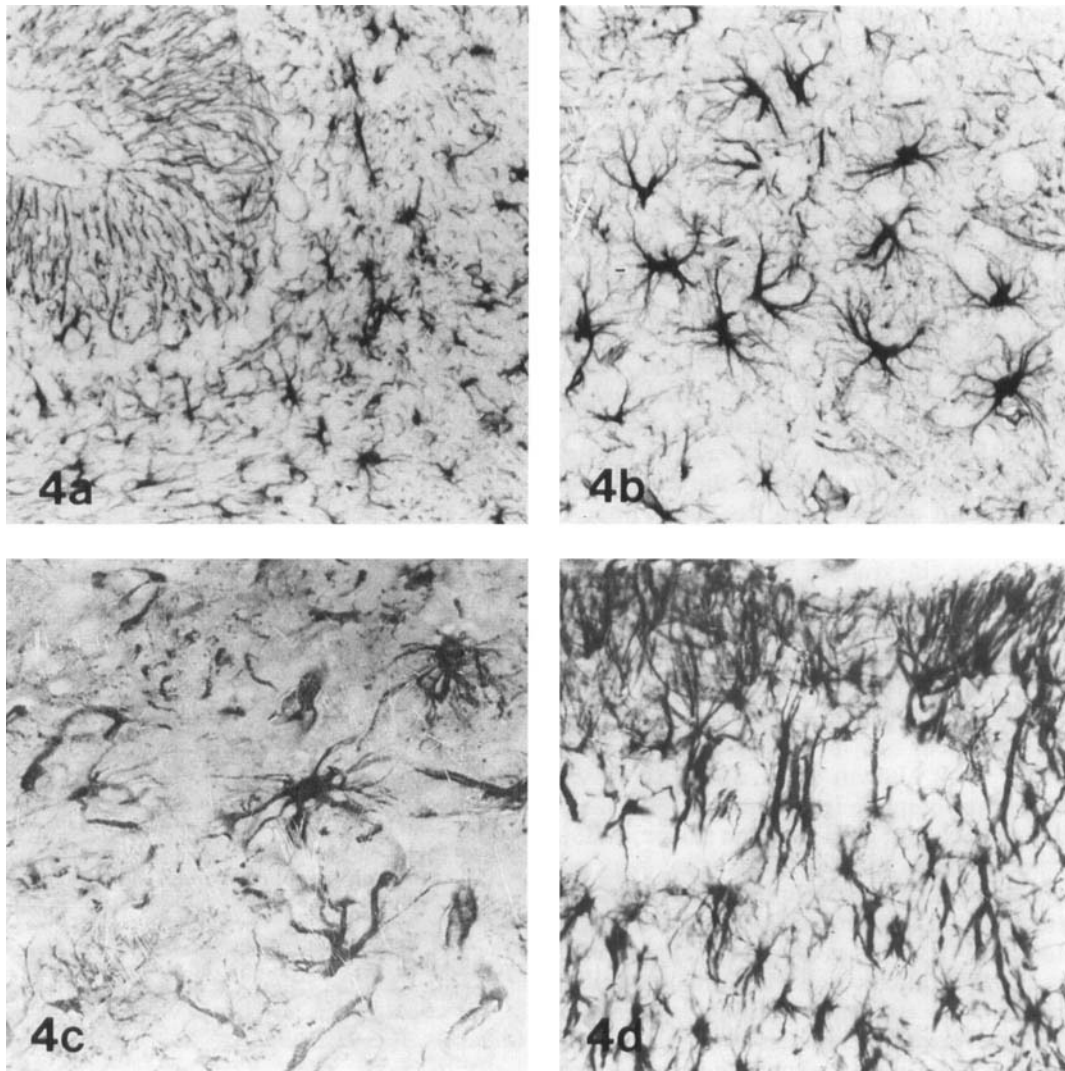


Fig. 4. Immunolabeling of GFAP, PAP technique. **a:** Distinct staining of both Bergmann fibers and cerebellar astrocytes; 18 days pi. $\times 250$. **b:** Astrocytic hyperplasia and hypertrophy are evident in striatum; 82 days pi. $\times 250$. **c:** Thalamic astrocytes of irregular size,

occasionally showing bizarre forms; 450 days pi. $\times 250$. **d:** Remarkable hyperplasia and hypertrophy of Bergmann fibers as well as of cerebellar astrocytes; 540 days pi. $\times 250$.

and Berría, 1974]. Another pattern common to both animal models is that Junin antigen, though distributed all over the cytoplasm, was mostly concentrated at the cell periphery, where viral particle budding invariably takes place.

Inflammatory infiltrate was mild throughout, in sharp contrast with the plentiful exudate observed in rat for the XJ-Cl₃ strain [Lascano et al., 1986]. As regards its immunocytochemical profile, it agreed with the unique CNS features delineated by Griffin et al.

[1987] in other experimental viral encephalitis diseases such as those induced by Sindbis and lymphocytic choriomeningitis viruses.

It is known that the astrocytic response to CNS injury is stereotyped, unidirectional, and characterized by proliferation [Latov et al., 1979], hypertrophy, and appearance of large quantities of GFAP [Amaducci et al., 1981; Bignami and Dahl, 1976]. As a general rule, the intensity of the glial reaction is directly related to the proximity of the injury site [Eng and DeArmond, 1982]. However, in the present case, a comparison of the data given in Tables I and II indicates that there is no topographical relationship between viral antigen location in neurons and astrocytic activation detected by GFAP labeling. In fact, the hippocampus was Junin antigen free from 82 days pi, but this was the very area where astrocytic hyperplasia and hypertrophy reached a considerable degree. Conversely, during persistent infection, viral antigen was frequently detected in cerebral cortex neurons, where astrocytic activation was manifested to a lesser extent. Furthermore, at 280 and 450 days pi, there was a single case out of 10 animals that exhibited viral antigen in brain, although all rats presented a similar degree of astrocytic reaction. Resorting to *in vitro* systems [Berría and Lascano, 1985], a direct Junin virus effect has been demonstrated on rat astroglial cell cultures, consisting of the induction of morphological and immunocytochemical differentiation. However, in the present model, the number of Junin antigen-labeled astrocytes in the whole animal was considerably lower than the number of activated astrocytes. Moreover, the gradual viral antigen restriction in neurons during the chronic stage was concomitant with widespread astrocytic reaction. Thus, the presence of viral antigen in both astrocytes and neurons seems unrelated to reactive astrocytosis.

Since control rats failed to show such changes, the recognized influence of age on GFAP labeling [Bignami and Dahl, 1974; Ludwin et al., 1976] had to be ruled out. Although complete information is still lacking about the triggering of glial reaction [Reier, 1986], several substances have been identified that may induce astrocyte proliferation or differentiation [Lindsay, 1986], such as glia maturation factors present in brain tissues [Kato et al., 1981; Nieto-Sampedro et al., 1985; Pettmann et al., 1980; Sobue and Pleasure, 1984] and possibly released from damaged neurons, as well as from demyelinated areas [Kristensson et al., 1986]. Glial reaction has also been attributed to lymphokines produced by viral antigen-stimulated perivascular lymphocytes [Oldstone et al., 1986] or to direct effects caused by the infective agent itself [Manuelidis et al., 1987].

Recent evidence has been presented that viral infection can impair neuronal activity even in the absence of histologic injury [Lipkin et al., 1988]. Although consistent morphologic changes were lacking in Junin antigen-labeled neurons, it is probable that cell infection can induce the release of mitogenic and morphogenic

factors. Understandably, since the astrocyte is the most abundant neuroectodermal cell of the brain, its reactivity seems the most obvious histologic expression of Junin virus persistent infection. It may therefore be concluded that the indiscriminate and detrimental astrocytic activation is a contributory factor to the pathogenesis of the delayed neurologic disease observed in the adult rat. The present findings encourage further studies that include the identification of the astrocyte subtypes [Miller and Raff, 1984; Takamiya et al., 1988] that are involved in such glial reaction. It seems reasonable to assume the existence of regional differences in the astrocytic response to persistent viral infection of the CNS.

ACKNOWLEDGMENTS

We thank Dr. Lawrence F. Eng, Pathology Research, Veterans Administration Medical Center, Palo Alto, CA, for the gift of anti-GFAP antiserum. This work was partially supported by grants from CONICET and SECYT, Argentina.

REFERENCES

- Amaducci A, Forno KI, Eng LF (1981): Glial fibrillary acidic protein in cryogenic lesions of the rat brain. *Neuroscience Letters* 21:27-32.
- Bernard A, Wild TF, Tripier MF (1983): Canine distemper infection in mice: Characterization of a neuro-adapted virus strain and its long-term evolution in the mouse. *Journal of General Virology* 64:1571-1579.
- Berría MI, Lascano EF (1985): Astrocyte differentiation induced by Junin virus in rat brain cell cultures. *Acta Neuropathologica* 66:233-238.
- Bignami A, Dahl D (1974): Astrocyte-protein and neuroglial differentiation. An immunofluorescent study with antibodies to the glial fibrillary acidic protein. *Journal of Comparative Neurology* 153:27-38.
- Bignami A, Dahl D (1976): The astroglial response to stabbing. Immunofluorescence studies with antibodies to astrocyte-specific protein (GFA) in mammalian and submammalian vertebrates. *Neuropathology and Applied Neurobiology* 2:99-110.
- de la Monte SM, Linhares AL, Travassos da Rosa APA, Pinheiro FP (1983): Immunoperoxidase detection of yellow fever after natural and experimental infections. *Tropical and Geographical Medicine* 35:235-241.
- Eng LF, DeArmond SJ (1982): Immunocytochemical studies of astrocytes in normal development and disease. In Fedoroff S, Hertz L (eds): "Advances in Cellular Neurobiology," Vol 3. New York: Academic Press, pp 145-171.
- Fekadu M, Chandler FW, Harrison AK (1982): Pathogenesis of rabies in dogs inoculated with an Ethiopian rabies virus strain. Immunofluorescence, histologic and ultrastructural studies of the central nervous system. *Archives of Virology* 71:109-126.
- Griffin DE, Hess JL, Moench TR (1987): Immune responses in the central nervous system. *Toxicologic Pathology* 15:294-302.
- Kato T, Fukui Y, Turriff DE, Nagakawa S, Lim R, Arnason BGW, Tanaka R (1981): Glia maturation factor in bovine brain: Partial purification and physicochemical characterization. *Brain Research* 212:393-402.
- Kristensson K, Holmes KV, Duchala CS, Zeller NK, Lazzarini RA, Dubois-Dalq M (1986): Increased levels of myelin basic protein transcript gene in virus-induced demyelination. *Nature* 322:544-547.
- Kristensson K, Norrby E (1986): Persistence of RNA viruses in the central nervous system. *Annual Review of Microbiology* 40:159-184.
- Kristensson K, Orvell C, Leetsma J, Norrby E (1983): Sandai virus infection in the brains of mice: Distribution of viral antigens stud-

- ied with monoclonal antibodies. *Journal of Infectious Diseases* 147:297–301.
- Lascano EF, Berría MI (1974): Ultrastructure of Junin virus in mouse whole brain and in mouse brain tissue cultures. *Journal of Virology* 14:965–974.
- Lascano EF, Berría MI (1983): Immunoperoxidase study of astrocytic reaction to Junin virus encephalomyelitis of mice. *Acta Neuro-pathologica* 59:183–190.
- Lascano EF, Blejer JL, Galassi NV, Nejamkis MR (1986): Brain inflammatory exudate in Junin virus-infected rats: Its characterization by the immunoperoxidase (PAP) technique. *Journal of Neuroimmunology* 11:105–116.
- Latov N, Nilaver G, Zimmerman EA, Johnson WG, Silverman A-J, Defendini R, Cote L (1979): Fibrillary astrocytes proliferate in response to brain injury. A study combining immunoperoxidase technique for glial fibrillary acidic protein and radioautography of tritiated thymidine. *Developmental Biology* 72:381–384.
- Lindsay RM (1986): Reactive gliosis. In Fedoroff S, Vernadakis A (eds): "Astrocytes. Cell Biology and Pathology of Astrocytes," Vol 3. Orlando: Academic Press, pp 231–262.
- Lipkin WI, Battenburg ELF, Bloom FE, Oldstone MBA (1988): Viral infection of neurons can depress neurotransmitter mRNA levels without histologic injury. *Brain Research* 451:333–339.
- Ludwin SK, Kosek JC, Eng LF (1976): The topographical distribution of S-100 and GFA proteins in the adult rat brain. An immunohistochemical study using horseradish peroxidase-labelled antibodies. *Journal of Comparative Neurology* 165:197–208.
- Maiztegui JI, Fernandez NJ, Damilano AJ de (1979): Efficacy of immune plasma in treatment of Argentine hemorrhagic fever and association between treatment and a late neurologic syndrome. *Lancet* 2:1216–1217.
- Manuelidis L, Tesin DM, Sklaviadis T, Manuelidis EE (1987): Astrocyte gene expression in Creutzfeldt-Jakob disease. *Proceedings of the National Academy of Sciences USA* 84:5937–5941.
- Melcon MO, Herskovitz E (1981): Complicaciones neurológicas tardías de la Fiebre Hemorrágica Argentina. *Medicina (Buenos Aires)* 41:137–145.
- Miller RH, Raff MC (1984): Fibrous and protoplasmic astrocytes are biochemically and developmentally distinct. *Journal of Neuroscience* 4:585–592.
- Nieto-Sampedro M, Saneto RP, de Vellis J, Cotman CW (1985): The control of glial populations in brain: Changes in astrocytic mitogenic and morphogenic factors in response to injury. *Brain Research* 343:320–328.
- Oldstone MBA, Blount P, Southern PJ, Lampert PW (1986): Cytoimmunotherapy for persistent virus infection reveals a unique clearance pattern from the central nervous system. *Nature* 321:239–243.
- Pearson J, Mims CA (1983): Selective vulnerability of neural cells and age-related susceptibility to Oc43 virus in mice. *Archives of Virology* 77:109–118.
- Pettmann B, Sensebrenner M, Labourdette G (1980): Isolation of a glial maturation factor from beef brain. *FEBS Letters* 118:195–199.
- Reier PJ (1986): Gliosis following CNS injury: The anatomy of astrocytic scars and their influences on axonal elongation. In Fedoroff S, Vernadakis A (eds): "Astrocytes. Cell Biology and Pathology of Astrocytes," Vol 3. Orlando: Academic Press, pp 263–324.
- Rodriguez M, Buchmeier MJ, Oldstone MBA, Lampert PW (1983): Ultrastructural localization of viral antigens in the CNS of mice persistently infected with lymphocytic choriomeningitis virus (LCM). *American Journal of Pathology* 110:95–100.
- Sethi P, Lipton HL (1983): Location and distribution of virus antigen in the central nervous system of mice persistently infected with Theiler's virus. *British Journal of Experimental Pathology* 64: 57–65.
- Sobue G, Pleasure D (1984): Astroglial proliferation and phenotype are modulated by neuronal plasma membrane. *Brain Research* 324:175–179.
- Sorensen O, Dales S (1985): In vivo and in vitro models of demyelinating disease: JHM virus in the rat central nervous system localized by in situ cDNA hybridization and immunofluorescent microscopy. *Journal of Virology* 56:434–438.
- Spriggs DR, Bronson RT, Fields BN (1983): Hemagglutinin variants of reovirus type 3 have altered central nervous system tropism. *Science* 226:505–507.
- Takamiya Y, Kohsaka S, Toya S, Otani M, Tsukada Y (1988): Immunohistochemical studies on the proliferation of reactive astrocytes and the expression of cytoskeletal proteins following brain injury in rats. *Developmental Brain Research* 38:201–210.
- Weissenbacher MC, Lascano EF, Avila MM, Berría MI (1986): Chronic neurologic disease in Junin virus-infected rats. *Journal of Medical Virology* 20:57–65.