

# Chronic liver disease: current concepts of disease mechanisms

**Optimal management of chronic liver disease requires an understanding of aetiological factors or conditions initiating and sustaining tissue damage. Injury may derive initially from toxin or xenobiotic exposure (direct, biotransformation adducts, hypersensitivity responses or immune-mediated mechanisms), infectious organisms, inborn errors of metabolism, or pathological accumulations of transition metals (iron or copper), endotoxins or membranocytolytic bile acids. Secondly, cells and mediators associated with inflammation, pathological expression of major histocompatibility foci on hepatocytes and biliary epithelia, aberrant initiation of apoptosis, modification of the extracellular matrix, and depletion of natural antioxidants can each play pivotal roles. Cholestatic liver injury derived from extrahepatic mechanical obstruction or intrahepatic cholestasis (many causes) can induce membrane damage subsequent to accumulation of membranocytolytic bile acids, copper retention, and membrane peroxidation. This paper reviews contemporary issues of chronic hepatocellular injury and hepatic fibrosis with the aim of broadening the clinical perspective of treatment strategies.**

S. A. CENTER

*Journal of Small Animal Practice* (1999)  
40, 106-114

Department of Internal Medicine,  
College of Veterinary Medicine,  
Cornell University, Ithaca,  
NY 14853, USA

## **Introduction**

Much progress has been made in the last decade in the understanding of the pathophysiological mechanisms underlying chronic hepatobiliary disease. Information has been derived from studies performed on laboratory animals with experimentally induced liver injury as well as humans and animals with spontaneous disease. Research endeavours have examined mechanisms from a fundamental molecular level to attain a better understanding of how complex biological processes culminate in cholestasis and/or hepatobiliary inflammation and fibrosis. It is hoped that this growth in knowledge will lend reason, objectivity and sound scientific logic to clinical management strategies.

## **Chronic liver disorders in the dog and cat**

There are many forms of chronic liver disease in the dog and cat that can progress

to fibrosis or cirrhosis (Table 1). These can be divided anatomically into areas of gross involvement (vascular, parenchymal, biliary structures) and on the basis of histological characteristics, including lobular distribution, the presence or absence of inflammation, type of inflammation (suppurative, non-suppurative or mixed infiltrate), and the presence, localisation and severity of fibrosis. Recognition and classification of chronic hepatitis therefore requires liver biopsy, with acquisition of enough tissue to make accurate diagnostic appraisals. The recent common use of needle biopsy sampling using ultrasonographic guidance has led to inadequate sample collection from some patients. A minimum of 15 portal triads should be observed to ascertain the presence or absence of a periportal/portal lesion.

## **Hepatic fibrosis**

The length of time required to develop substantial fibrosis can vary widely depending on the causative events or agents. The most common progression of chronic hepatitis in the dog and of chronic cholangiohepatitis in the cat occurs as fibrosis bridges between portal triads. In humans, and possibly the dog, bridging fibrosis between portal triads and hepatic venules appears to have a more rapid progression and grave prognosis.

Hepatic fibrosis represents a net increase in extracellular matrix (ECM) in the liver. In normal liver, the ECM constitutes approximately 0.5 per cent of organ wet weight. This tissue component is subdivided into a pericellular matrix interacting with cell membrane components, the classic interstitial matrix structure of the interstitial spaces and basement membranes comprised of minor amounts of several non-collagenous components. In normal liver ECM, type I and III collagens exist in approximately equal amounts. In hepatic fibrosis there is a quantitative increase in collagen (four- to seven-fold normal) and type I collagen predominates (Bissell and Maher 1996).

Since similar ECM changes can develop following all forms of injury, general or

**Table 1. Common chronic hepatobiliary disorders in the dog and cat associated with hepatic fibrosis/cirrhosis**

Dogs	Cats
<p><i>Inflammatory hepatopathies</i>                      Chronic 'persistent' hepatitis                      Chronic 'active' hepatitis, breed-related: eg,                      Dobermann                      Cocker spaniel                      Labrador retriever                      Copper storage hepatopathy:                      Bedlington terrier                      West Highland white terrier (?)                      Rarely, other breeds, mixed-breed dogs                      Chronic non-suppurative hepatitis                      Chronic portal triaditis                      Chronic 'drug induced' hepatitis                      'Toxic' hepatitis                      Chronic lobular hepatitis                      Lobular dissecting hepatitis                      Chronic cholangiohepatitis                      Chronic cholangitis                      Chronic major bile duct obstruction</p> <p><i>Non-inflammatory hepatopathies</i>                      Idiopathic hepatic fibrosis                      Hepatic fibrosis in young dogs:                      perivenular fibrosis                      hepatoportal fibrosis                      perisinusoidal fibrosis</p>	<p><i>Inflammatory hepatopathies</i>                      Chronic portal 'triaditis'                      Chronic suppurative cholangitis                      Chronic suppurative cholangiohepatitis                      Chronic non-suppurative cholangitis                      Chronic non-suppurative cholangiohepatitis                      Chronic major bile duct obstruction</p> <p><i>Non-inflammatory hepatopathies</i>                      Polycystic hepatic disease:                      Persians                      Himalayans                      Idiopathic hepatic fibrosis (rare)</p>

central aetiological factors appear to be involved. Recent studies suggest a key role for lipid-derived reactive oxygen intermediates in initiating tissue injury (Paradis and others 1997). Change in the composition and location of the ECM may be pivotally important as this constituent plays a major role in liver cell biology, influencing both hepatocytes and sinusoidal cell functions (Racine-Samson and others 1996).

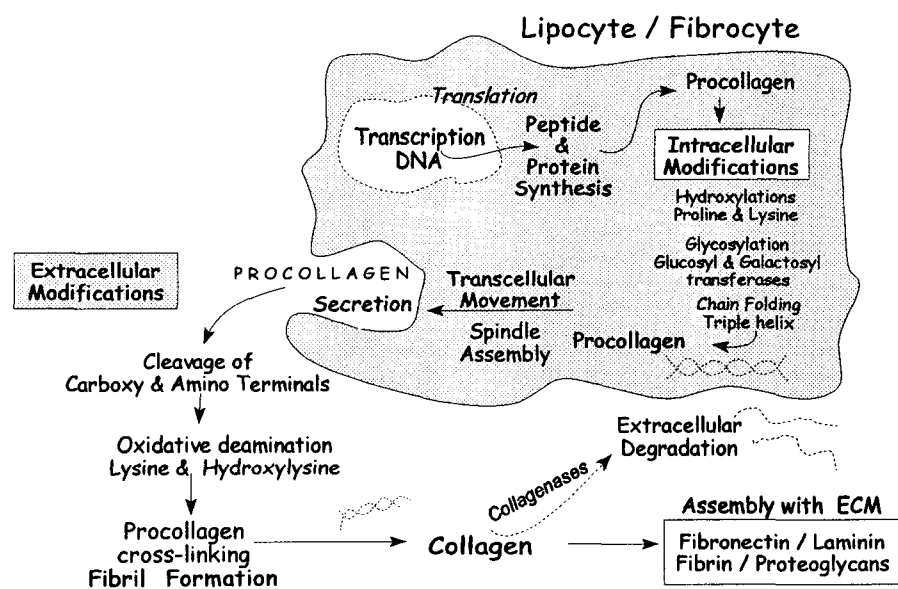
Change in ECM in early liver injury leads to deterioration in hepatocyte function and the appearance of clinicopathological markers consistent with chronic liver disease (eg, reduced synthesis of albumin and clotting factors). Change in matrix composition also directly activates collagen secretion. Formation and deposition of collagens in the ECM involves a complex series of events, as summarised in Fig 1. Collagen is initially secreted as a propeptide containing large amounts of proline and hydroxyproline. Increased tensile strength of secreted collagen is accomplished by fibril cross linking which occurs extracellularly. Understanding the mechanisms involved in collagen formation/ deposition has uncovered new methods for controlling fibrogenesis

under investigation (Hanauske-Abel 1996).

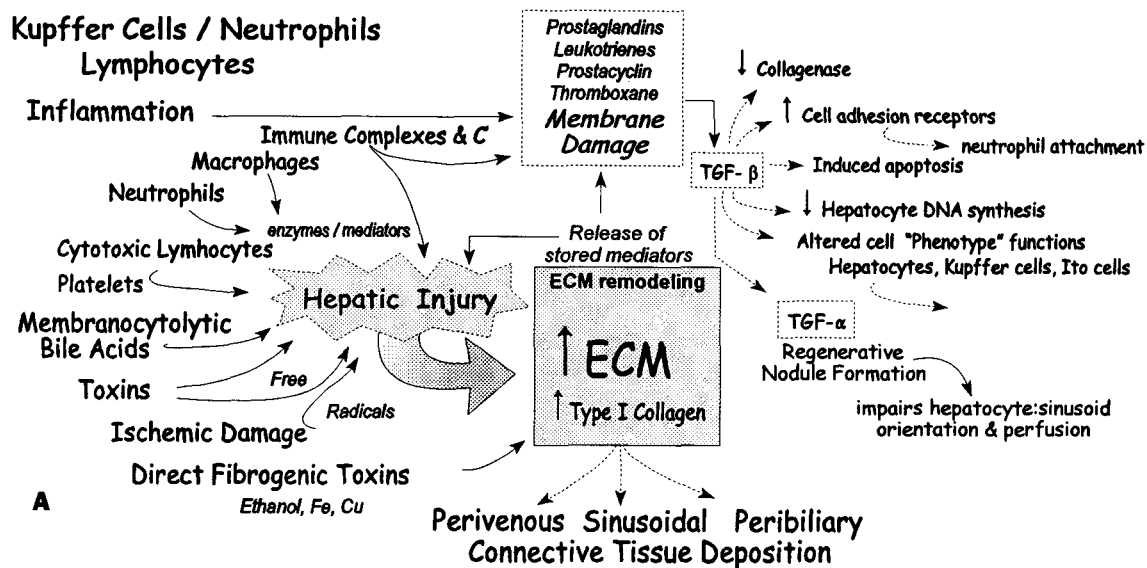
In the normal liver, the space of Disse is a 'virtual' space, defined by a non-fibrillar ECM, that readily permits the exchange of ultrafiltrate between sinusoidal blood and hepatocytes. All cell components defining this space participate in the synthesis of the ECM, although most of the type III and IV collagen and laminin is synthesised by Ito and sinusoidal endothelial cells. During active hepatic fibrogenesis, however, Ito cells become the major ECM-producing cell, and the predominant producer of collagen (type I). As cirrhosis develops, changes in blood vessels, sinusoidal continuity and phenotypic behaviour of

parenchymal and perisinusoidal cells develop simultaneously. Formation of regenerative nodules, encouraged by growth promoters (especially transforming growth factor- $\alpha$  [TGF- $\alpha$ ]), impairs the hepatocyte-to-sinusoid orientation and perfusion (Fig 2).

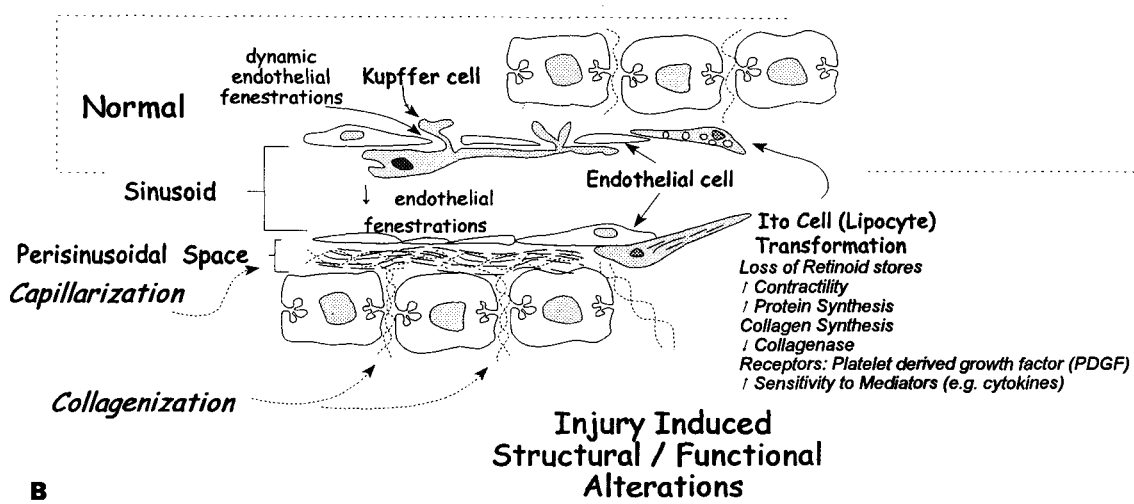
As fibrosis progresses, large bundles of collagen fibres accumulate, limiting the ability of sinusoids, portal and hepatic veins to distend, increasing intrahepatic resistance to blood flow and impairing sinusoidal perfusion. This process is referred to as collagenisation. Elastin increases in the walls of arteries creating a space occupying barrier. Altered selective permeability and loss of dynamic fenestrations of sinusoidal endothelial cells and increased collagen deposition in the space of Disse transforms sinusoids so that they resemble systemic capillaries. This capillarisation impairs oxygen and nutrient availability and impairs metabolite exchange between hepatocytes and sinusoidal blood (Villeneuve and Huet 1987, Sherman and others 1990). Oxygen consumption as well as delivery of oxygen to hepatocytes is therefore reduced in cirrhosis (Kamada and others 1986, Morgan and McLean 1991). This may be critical for some patients, as even a small reduction in hepatic oxygen delivery can impair elimination of substances biotransformed by enzyme systems that use oxygen directly. Recent studies suggest that this is a major underlying cause of altered drug metabolism in liver disease (Morgan and McLean 1995).



**FIG 1.** Simplified diagram of the complex series of mechanisms influencing the accumulation of collagen in the liver



A



B

### Influence of Fibrosis on Hepatic Sinusoids

FIG 2. (A) Mechanisms of hepatobiliary injury and response to membrane damage culminating in connective tissue deposition. (B) Structural and functional alterations in the liver involving transformation of the sinusoids by capillarisation and collagenisation

As hepatic fibrosis evolves, the ECM undergoes remodelling. In early fibrosis, both collagen synthesis and collagenase activity increase; degradation of ECM occurs through a family of enzymes called matrix metalloproteinases of which collagenases are only one component. The degradation/remodelling permits extension of inflammatory mediators through removal of entrapping matrix. As fibrosis progresses, the balance between collagen synthesis and its degradation favours the former and tissue collagenisation becomes established.

#### Mechanisms of hepatic fibrosis

Both direct and indirect factors stimulate hepatic fibrogenesis. Immune responses and tissue wound repair involve indirect mechanisms linked with inflammation and local release of cytokines. A self-perpetuating cycle of injury, repair and fibrogenesis can be initiated and sustained by a variety of agents and mechanisms (Fig 2). The biochemical cascades that drive fibro-

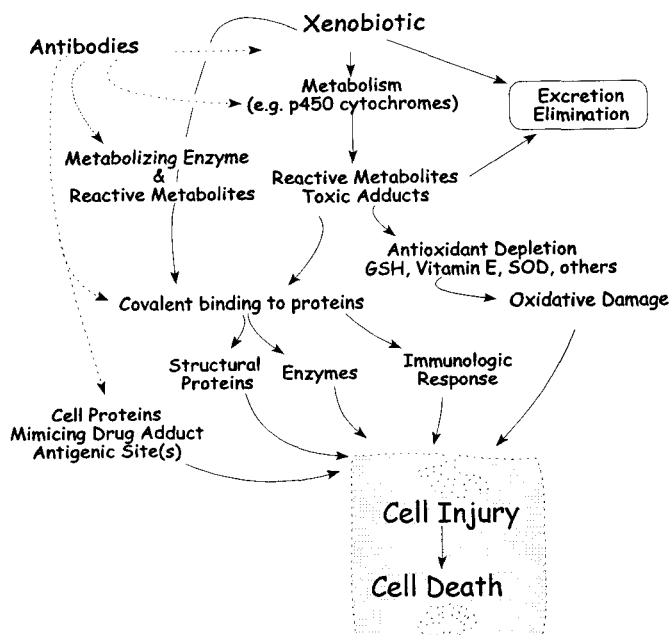
genesis are summarised in Fig 2A. In general, the role of direct fibrogenic influences (ethanol and excessive stores of iron and copper) is not understood and is thought to be minor relative to inflammation and the cascade of events described below.

Inflammatory infiltrates comprised of neutrophils and macrophages are associated with most forms of liver injury, irrespective of initiating circumstances. Immune complex deposition may precede tissue damage in some situations. The ECM can serve as a depot for inflammatory mediators and immune complexes and thus can sustain mediator release and inflammation long after the initiating event has resolved. Leucocytes migrating into an area of inflammation release lysosomal proteases and reactive radicals, disrupting normal ECM and cell structures. This liberates not only proinflammatory eicosanoids, but also peptides that function as chemoattractants for collagen-producing cells, neutrophils and macrophages.

Transforming growth factor-β (TGF-β), produced by many cells, including Kupffer cells, lymphocytes, macrophages and platelets, is the best known of a family of low molecular weight soluble factors that stimulate collagen deposition by Ito cells (Pinzani 1995, Losser and Payen 1996). This substance also impairs hepatocyte DNA synthesis, induces apoptosis and up-regulates cell adhesion receptors, favouring accumulation of inflammatory cells. These changes promote development of an architecturally deranged and fibrotic acinus. TGF-β also seems to retard collagen degradation which, along with its stimulatory influence on fibrogenesis, favours collagen accumulation.

#### Role of the Ito cell

Ito cells, perisinusoidal mesenchymal cells located in the space of Disse, are located along hepatic sinusoids at regular intervals, suggesting fixed site positioning (Pinzani 1995). Also called fat or vitamin A-storing cells, stellate cells and hepatic lipocytes,



**FIG 3.** Pathophysiological mechanisms causing hepatobiliary damage induced by chronic or repeated exposure to various xenobiotics

these are the main connective tissue producing cells in the fibrotic liver. In normal liver, Ito cells release cytokines, produce collagenases and their inhibitors, and play a role in vasoregulation. Resembling smooth muscle cell-like pericytes (cells lying adjacent to vascular pathways) in other organs, Ito cells have similar contractile capabilities that may have pathogenic significance in portal hypertension and in contraction of mature scar tissue in the fibrotic liver. Endothelin-1, a potent vasoconstrictor produced by Ito cells, may help maintain normal sinusoidal tone (Friedman 1997).

Projections extending from Ito cells normally contact hepatocytes (Fig 2B). These are thought to maintain normal epithelio-mesenchymal communication and may be operational in influencing activation of Ito cells into myofibroblast-like cells. Release of a potent mitogen from damaged hepatocytes may initiate Ito cell transformation into an 'activated' form. Ito cell activation is characterised by transformation of resting cells into proliferative, fibrogenic, contractile myofibroblasts with increased capacity for protein synthesis and receptors for platelet derived growth

factor (PDGF), release of normal retinoid (vitamin A) stores, and a heightened sensitivity to certain mediators (eg, endotoxin) (Fig 2B). Ito cells play a pivotal role in hepatic fibrogenesis as their transformation leads to a vicious cycle of enhanced fibrogenic and chemotactic mediator production as they amplify the inflammatory response (Pinzani 1995, Friedman 1997).

### Hepatocyte/biliary epithelial injury

Initial injury to the liver can be primary or occur secondary to disease in other organ systems. Primary injury may be caused by: exposure to certain drugs, xenobiotics or toxins, as well as to hepatotropic viral, microbial, protozoal or parasitic agents; mechanical cholestasis (biliary tree obstruction); inborn errors of metabolism (eg, copper storage disease,  $\alpha_1$ -antitrypsin deficiency); or immunological processes. Secondary hepatic injury occurs subsequent to systemic infections, disseminated neoplasia or pathological change in other organ systems (cardiovascular, gastrointestinal, pancreatic, urogenital and endocrine systems). The variety of injurious agents and conditions that can initiate hepatic inflammation are summarised in Table 2. These can lead to chronic disease or patient death if the hepatobiliary insult is protracted or recurrent. Unfortunately, in many cases, an underlying cause for chronic liver disease can never be ascertained.

### Drug or toxin exposure

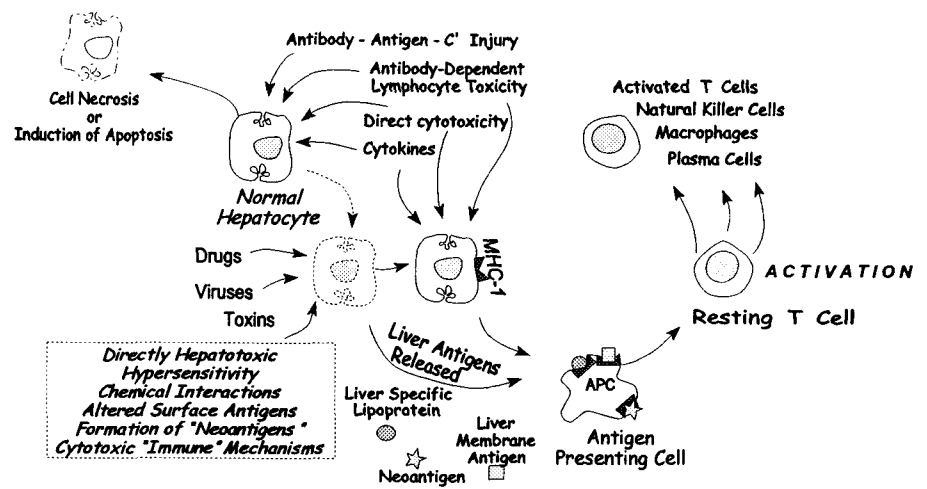
Insults derived from repeated drug or toxin administration have been well documented in humans, animal models and companion animals. In most cases, xenobiotics become toxic after metabolic activation, primarily via the superfamily cytochrome p450 enzyme system. Cell damage from reactive intermediates can occur by two major mechanisms (Fig 3) (Losser and Payen 1996, Pumford and others 1997). The first is direct toxicity, moderated by electrophiles that bind covalently to proteins or by free radicals that cause lipid peroxidation and protein thiol oxidation. These produce

**Table 2. Toxins, drugs, infectious organisms and conditions known or suspected to produce hepatic injury in humans, dogs and cats**

<i>Toxins (examples)</i>	<i>Endotoxin</i>
Aflatoxins	Gram - lipopolysaccharide
(other mycotoxins)	
Carbon tetrachloride	<i>Infectious agents</i>
Chloroform	<i>Bacteria:</i>
Copper	<i>Campylobacter</i> species
Dinitrosamine	Enteric organisms
Ferric ion	<i>Helicobacter</i> (?)
Galactosamine	Leptospirosis
Mushroom toxicity	<i>Mycobacterium</i> species
(amatoxins, phallotoxins)	<i>Nocardia</i> species
	<i>Fungi:</i>
<i>Drugs (examples)</i>	Systemic mycoses
Acetaminophen	<i>Parasites:</i>
Carprofen	Trematodes
Cimetidine	Schistosomes
Dantrolene	<i>Protozoa:</i>
Diazepam	Toxoplasma
Halothane	Cryptosporidia
Mebendazole	Microsporidia
Oxibendazole	<i>Viruses:</i>
Phenytoin	Canine adenovirus 1
Phenobarbital	Coronavirus (FIP strain)
Primidone	
Sulpha drugs $\pm$	<i>Antibodies against cell surface antigens</i>
trimethoprim	<i>or neoantigens (see Table 3)</i>
Thiacetamide	

*Major bile duct occlusion*  
5 to 6 weeks  $\rightarrow$  biliary cirrhosis

*$\alpha_1$ -antitrypsin deficiency*



**Immunoregulatory dysfunction perpetuates injurious reactions**  
**Loss of self tolerance of selected or altered epitopes**  
**Formation of "neoantigens"**  
**Aberrant expression of MHC- foci**  
**MHC - 1 (hepatocytes)**  
**MHC - 2 (biliary epithelium)**

**FIG 4.** Postulated immune-mediated mechanisms sustaining hepatobiliary injury in chronic acquired inflammatory hepatic disease

damage to a 'critical' protein or some 'critical' regulatory pathway. Direct damage to plasma membranes, disruption of cytoskeletal structure, mitochondrial dysfunction, imbalanced intracellular ion homeostasis, as well as activation of degradative enzymes, have all been demonstrated. The second method of damage involves aberrant immune reactivity, as can occur when modification of proteins by covalent binding creates a hapten or cell damage produces or releases a neoantigen capable of provoking an immune response (Fig 4). This may result in either a hypersensitivity reaction or an 'auto' immune phenomenon.

Recent work has shown that some drugs that are metabolically activated by cytochrome p450 enzymes result in adduct formation while associated with the enzyme and thus generate a novel domain directing antibody formation against the enzyme (eg, tienilic acid, dihydralazine, phenytoin) (Manns and Obermayer-Straub 1997, Pumford and others 1997). Hepatotoxicity caused by a drug via adduct formation or DNA injury manifests immediately and in a dose-dependent manner. In contrast, liver damage in immune-mediated drug-induced hepatitis occurs after a significant lag-period, is independent of dose, does not occur after first exposure and is characterised by autoantibodies. Methods have been developed to detect and identify xenobiotics covalently bound to proteins as well as neoantigens and autoantibodies. Investigations have clarified the toxic properties and mechanisms of acetaminophen, galactosamine, carbon tetrachloride (CCl<sub>4</sub>), halothane and certain other drugs. Deficiencies in normal detoxification pathways such as sulphate or glucuronide conjugation, availability of reduced glutathione (GSH) or other free radical scavengers, increased formation of toxic adducts due to enzyme induction (phenobarbital enzyme induction), or reduced rate of adduct elimination as a result of patient exposure to enzyme inhibitors (eg, cimetidine, quinidine, chloramphenicol), can enhance toxicity of some agents.

### Copper and iron

Accumulation of excess hepatocellular copper can develop due to inherited defects in copper transport or excretion, excessive copper intake, or secondary to cholestatic liver injury. Excessive iron can accumulate due to an inherited defect causing increased alimentary uptake in humans (haemochromatosis), excessive exogenous iron administration, haemolytic disease or chronic repeated blood transfusion. Increased Kupffer cell iron is commonly apparent histologically adjacent to areas of chronic inflammation. Copper and iron-induced hepatic damage is related to free radical-generated oxidant injury (Fig 5). Damage to membranes, including plasma, mitochondrial, lysosomal and microsomal, leads to cell energy deficits, abnormal microsomal enzyme function and deleterious changes in intracellular free calcium (Bacon and Tavill 1996, Zucker and Gollan 1996). Copper and iron are also believed to initiate Ito cell activation and collagen synthesis directly.

### Endotoxin

Bacterial cell products and toxins have been shown to act singly as well as in combination with other hepatotoxic events (Schrumph and others 1988). Of particular concern is endotoxin, the lipopolysaccharide derived from the cell wall of gram-negative bacteria. The deleterious effects of endotoxaemia are a result of their expansive influence on inflammation.

After exposure to endotoxin, hepatocytes develop dilated organelles associated

with metabolic changes, including the inhibition of adenylate cyclase, reduced gluconeogenesis, increased lipogenesis, decreased cytochrome p450 activity and altered cytoskeletal function, reducing bilirubin and transport of other organic anions. Metabolic changes precede development of multifocal necrosis which is associated with a neutrophilic infiltrate.

Endotoxin is a potent activator of platelets, macrophages and neutrophils, and can therefore promote release of tissue necrosis factor  $\alpha$  (TNF- $\alpha$ ), injurious enzymes and proinflammatory eicosanoids. Consequently, it can also encourage release of injurious free radicals, causing oxidative damage, and can enhance the toxicity of other hepatotoxins. There is a recognised association between the presence of Gram-negative bacterial organisms, endotoxin, periportal hepatitis and hepatic venular lesions (Vierling 1996). Normally, endotoxin is delivered continuously to the liver from the splanchnic circulation and removed routinely by the hepatic mononuclear-phagocyte surveillance system (Kupffer cell population).

### Role of Kupffer cells and neutrophils

The Kupffer cell population represents 90 per cent of the body's fixed macrophages. Where strategically located in the lumen of the hepatic sinusoid, these are normally well perfused, in order to remove particulate debris, bacteria and endotoxin delivered from the splanchnic circulation. However,

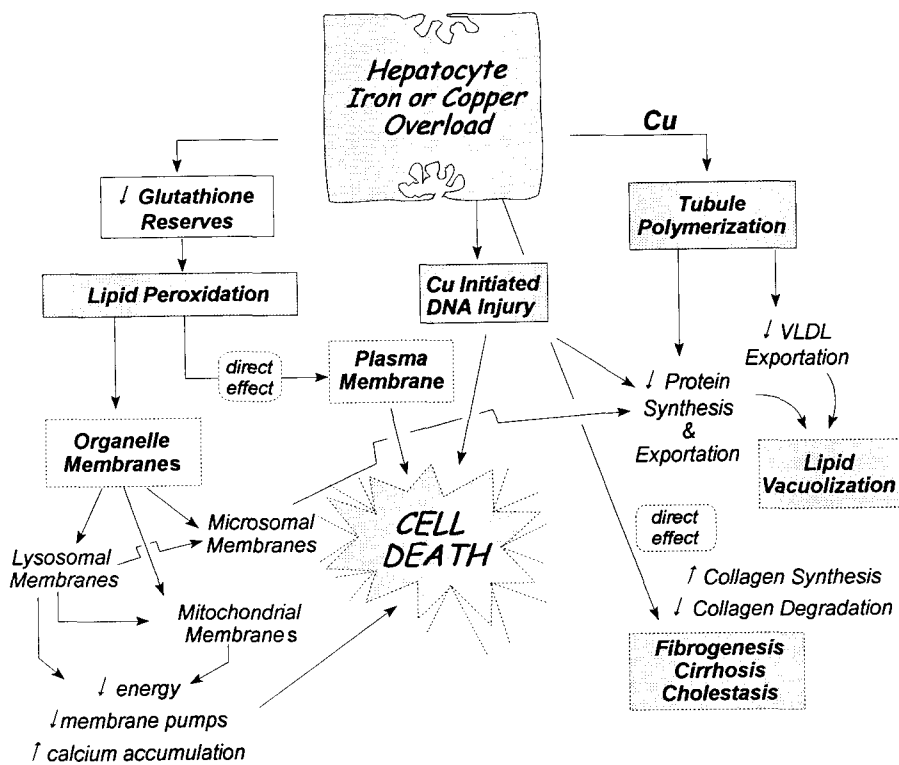


FIG 5. Pathological effects of excessive copper or iron stores in the liver culminating in chronic organ damage, sustained inflammation, fibrosis and hepatocellular necrosis

in the event of hepatic fibrosis, cirrhosis or portosystemic shunting, the function, perfusion and population of Kupffer cells is insufficient to maintain their normal detoxification function. Subsequently, such patients are at increased risk of endotoxin-induced effects. Since the digestive system and liver are particularly rich in substrates and enzymes capable of generating cytotoxic oxidants and the alimentary canal is a ready source of endotoxin, patients with inflammatory bowel disease, pancreatitis and hypotensive shock have a higher risk of endotoxin-mediated liver injury. Porto-caval shunting or other causes of impaired Kupffer cell function prevent normal immune tolerance to substances derived from the alimentary circulation as peripherally located immunocytes are newly challenged.

Both Kupffer cells and neutrophils play a major role in perpetuating liver injury. After stimulation by endotoxin, Kupffer cells release chemoattractants that recruit neutrophils. Activated neutrophils produce free radicals, damaging membranes and up-regulating surface adhesion molecule receptors so that they adhere to the sinusoidal endothelium (cell rolling) (Losser and Payen 1996). This promotes neutrophil migration into adjacent hepatic parenchyma. Kupffer cells produce toxic mediators as well as provoking platelet aggregation. Collectively, these effects promote circulatory stasis and microthrombosis in sinusoids narrowed functionally by vasoconstriction, as well as adherent neutrophils, aggregated platelets and swollen Kupffer cells.

### Major histocompatibility antigen

The major histocompatibility antigens (MHC) are cell-surface glycoproteins involved intimately with immune defence and cell injury. The MHC class I foci are found on the surfaces of almost all nucleated cells and present antigen derived from intracellular proteins to CD8<sup>+</sup> T lymphocytes. These foci are required for programming efficient lysis of target cells by cytotoxic T lymphocytes.

The MHC class II foci are highly polymorphic glycoprotein receptors that bind peptide fragments derived from endocytosed extracellular proteins. Bound peptides (foreign and self-derived) are presented to helper T lymphocytes (CD4<sup>+</sup> lymphocytes) that are both peptide-specific and MHC-restricted (recognising a particular peptide only when presented by a particular class II molecule). Immune responsiveness is influenced by this array of polymorphic class II foci. Normally, macrophages (including Kupffer cells) and monocytes phagocytise antigens and then degrade them enzymatically into small antigenic peptides that fit into their MHC class II groove. These antigens are presented to a specific CD4<sup>+</sup> T cell which subsequently undergoes 'activation'. The activated CD4<sup>+</sup> T cell initiates a response through elaboration of inflammatory and cytotoxic mediators, cooperation with B cells and/or cytotoxic lymphocytes and, in some cases, induction of apoptosis. In humans, chronic viral hepatitis and primary biliary cirrhosis involve CD8<sup>+</sup> T cells and 'auto' immune forms of hepati-

tis mostly involve CD4<sup>+</sup> T cells, B cells and plasma cells.

Hepatocytes normally have low immunogenicity, expressing few MHC class I and no MHC class II molecules (Franco and others 1988, Innes and others 1988, Lobo-Yeo and others 1990, Arvieux and others 1993). The expression of MHC class I foci in liver is restricted normally to sinusoidal and biliary cells, while MHC class II foci are restricted to sinusoidal and dendritic cells. However, in pathological situations, hepatocytes express high numbers of MHC class I molecules and, in some chronic cholestatic disorders, MHC class II molecules are expressed in biliary epithelium (Fig 4). These changes place hepatocytes and biliary epithelium in a position of antigen presentation/recognition in which they may become recipients of cytotoxic and immune-mediated injury. Such a scenario most likely occurs in many forms of chronic hepatitis.

In addition to MHC foci, certain accessory molecules are also expressed on cell surfaces in response to cytokines and eicosanoid products. These influence cell communication, ECM deposition and remodelling, and adherence of inflammatory cells.

### Apoptosis

Apoptosis, or programmed cell death, is a normal physiological process by which single senescent cells are eliminated. Histologically, apoptosis is marked by cell shrinkage, chromatin condensation and DNA fragmentation (Oberhammer and Roberts 1994). In health, this process predominates in zone 3 of the hepatic lobule and occurs in the absence of inflammation (Benedetti and others 1988). Pathologically, T lymphocyte and natural killer lymphocyte cytotoxicity is expressed by initiation of the apoptosis pathway. Some forms of liver injury are theorised to involve this mechanism through increased expression of the receptors involved on hepatocytes or expression ligands on T lymphocytes and stimulation/accumulation of TNF- $\alpha$  (Tiegs and Gantner 1996). Apoptotic bodies observed in acute or

chronic hepatitis have been referred to traditionally as acidophilic or Councilman bodies. In experimental models, hepatic apoptosis always precedes necrosis and fulminant liver disease and has been suggested to represent an early marker of T-cell-dependent liver injury. Microbial toxins as well as certain drugs and xenobiotics can also exert their toxic potential through immune mechanisms that can invoke TNF- $\alpha$  as a cytotoxic mediator of apoptosis (Tiegs and Gantner 1996). Pathological accumulation of iron (eg, haemolytic, excessive blood transfusion or excessive exogenous intake) can also result in initiation of the apoptosis pathway (Zhao and others 1997).

### **Cholestatic liver injury**

Cholestatic liver injury can be subdivided into intrahepatic and extrahepatic aetiologies. Whatever the cause, cholestasis leads to the accumulation of noxious bile acids, most notably the monohydroxy secondary bile acid lithocholic acid derived from chenodeoxycholic acid by enteric bacterial dehydroxylation. Lithocholic acid is a well recognised hepatotoxin known to induce a variety of metabolic and structural injuries. Because lithocholic acid is poorly water soluble, normally only small amounts are dispersed into the portal circulation and presented to the liver.

Following hepatocellular uptake in extrahepatic cholestasis, cytosolic peptides direct lithocholate to the canalicular membrane where it binds inducing a deleterious decrease in membrane fluidity (Yousef and others 1977). Membrane changes are associated with an altered cholesterol-to-phospholipid ratio which compromises membrane integrity and function. Similar subcellular injury has been shown in all species studied and includes dilation of bile canaliculi, loss of canalicular microvilli and lamellar transformation of canalicular membranes (Miyai and others 1977). Although lithocholate is not the only 'membranocytolytic' bile acid, it is the most noxious, with chronic exposure leading to cirrhosis. Accumulation of lithocholate, as

well as other noxious bile acids, is thought to contribute to ongoing liver injury in patients with cholestasis and many different forms of chronic liver disease.

Intrahepatic cholestasis can result from a multitude of factors, including drugs, toxins, endogenous products (eg, steroid hormones) and endotoxin. With some drugs, cholestasis is dose-dependent and reversible, while with others it involves cell injury and immune-mediated mechanisms.

### **Extrahepatic bile duct occlusion**

Disorders resulting in mechanical obstruction to bile flow produce tissue injury subsequent to increased pressure in the biliary tree, precipitation of intraluminal bile with calcium, and accumulation of membranocytolytic bile acids, lysolecithin and possibly copper. Subcellular injury precedes the development of overt histological changes. Biliary tree damage results from eicosanoid-mediated inflammation and oxidative injury, as well as from cytokines and mediators recruited into the area of inflammation. Biliary epithelial hyperplasia and bile ductule proliferation are early histological features. Classic histological changes of major duct occlusion include distension of the biliary structures, devitalisation of biliary epithelium, accumulation of necrotic debris and suppurative inflammation within the bile duct lumen, periportal accumulations of neutrophils, lymphocytes, plasma cells and oedema, and multifocal parenchymal necrosis. Periportal fibrosis is usually obvious within weeks and evolves into an 'onion skin' appearance around bile ducts. In chronic cases, irreparable distension of large bile ducts develops. If obstruction is alleviated within the first few weeks, the periductal fibrosis, oedema and bile duct distension may resolve completely. If obstruction persists beyond six weeks, biliary cirrhosis follows predictably.

### **Lipid peroxidation**

The normal liver maintains an elaborate antioxidant system for defence against oxidative damage; this system includes

glutathione stores, *s*-adenosylmethionine, vitamin E, superoxide dismutase (SOD) and coenzyme Q<sub>10</sub> (a ubiquinone). There is increasing evidence to suggest that lipid peroxidation is an important mechanism of injury in a variety of hepatobiliary disorders, including acute damage associated with toxins, extrahepatic bile duct occlusion, ongoing injury associated with chronic hepatitis of various aetiologies and copper and iron storage hepatopathies. In some of these disorders, lipid peroxidation is implicated as an early pathogenic feature (Tribble and others 1987, Paradis and others 1997). Lipid peroxidation, initiated by attack of hydroxyl radicals on the unsaturated bonds of membrane phospholipids, propagates as an autocatalytic chain reaction involving highly reactive polyunsaturated fatty acid (PUFA) radicals (Tribble and others 1987). Cytotoxic metabolites damage membranes leading to cell dysfunction and death. In the circumstance of ATP depletion or oxidative stress, ATP metabolism generates xanthine, which serves as a substrate for generation of O<sub>2</sub><sup>-</sup>. This is converted rapidly to H<sub>2</sub>O<sub>2</sub> by enzymatic dismutation (SOD), yielding the deleterious hydroxyl radical (Losser and Payen 1996). If normal antioxidant defences are diminished, hepatocellular and biliary tree damage occurs.

Both local and more distant cellular injury can occur as cytotoxic metabolites disperse from their site of origin. Formation of covalent bonds between oxidative metabolites and cellular components causes injury resembling that due to toxic drug adducts. Cell injury may involve impaired regulation of endogenous vasodilators (prostaglandins, nitric oxide), enzyme inactivation, altered DNA ultrastructure and impaired synthesis of RNA and proteins (Gonzalez-Correa and others 1997). In many conditions, oxygen radicals are generated initially by stimulated Kupffer cells and sequestered neutrophils. In metal-associated hepatopathies (copper- or iron-associated injury) free ions initiate lipid peroxidation.

**Table 3. Antibodies identified in experimental models of hepatobiliary disease in humans and companion animals\* with hepatobiliary disease**

Antinuclear antibodies (ANA)*	Anti-liver cytosol antibodies (ACA)
Anti-smooth muscle antibodies (ASMA)	Anti-soluble liver antigen antibodies (LSA)*
Anti-actin antibodies (AAA)	Anti-liver/pancreas antigen antibodies (ALPA)
Anti-sialoglycoprotein receptor antibody (ASGPR)	Anti-mitochondrial antibodies (AMA)
Anti-liver/kidney microsomal antibody (LKA)	Anti-neutrophil cytoplasmic antibodies (ANCA)
Anti-liver/kidney membrane antibody (LMA)*	Cross-reactive antigens in Gram-negative bacteria*
Liver-specific lipoprotein (LSP)	

ANA: Antibodies against nuclear antigens. Evaluation by immunofluorescence or by immunohistochemistry can produce a variety of patterns dependent upon the antigenic reactant (eg, speckled, homogeneous, nucleolar, peripheral or rim patterns)

ASMA & AAA: Antibodies against smooth muscle antigens are heterogeneous but in the liver are predominantly against F-actin, a constituent of the liver cell cytoskeleton associated with the plasma cell membrane

ASGPR: Antibody against a liver-specific glycoprotein receptor distributed on the basal lateral membrane of mammalian hepatocytes and a component of the complex antigen preparation called liver-specific protein (LSP). Up to approximately 88 per cent of humans with autoimmune chronic 'active' hepatitis have antibodies against this antigen, while patients with non-hepatic autoimmune disorders or non-hepatic disease rarely exhibit anti-ASGPR. Anti-ASGPR has been shown to bind most selectively to the periportal region in humans with hepatocellular necrosis due to chronic 'active' hepatitis

LKA: These antigens are components of the cytochrome p450 superfamily of enzymes and are derived from liver and kidney cell homogenates

LMA: These are detected by the binding of IgG to the surface of hepatocytes. A study of anti-liver membrane protein extract was carried out in 21 dogs with chronic hepatitis. Of these, 48 per cent had titres greater than 2 SD above the mean for control dogs (Weiss and others 1995). The dogs also had higher ALT and total bilirubin values and more severe liver lesions than anti-LMA negative dogs. The association between anti-liver antibodies was, however, greater than that found in a previous study (Andersson and Sevelius 1992). Methodological differences may underlie these differences; the former study used antigen derived from dog liver and reacted sera from patients using an ELISA test system, whereas the latter study used patient sera layered on to sections of rat liver tissue, and an immunofluorescent detection assay

LSP: A complex antigen fraction derived from liver membrane protein which contains organ-specific and non-organ-specific membrane-associated and cytoplasmic proteins containing species-specific and non-species-specific determinants (Thomas 1988). Monoclonal antibodies against a liver-specific membrane component of rabbit LSP cause hepatocellular damage in vivo and in vitro, and long-term immunisation in rabbits can induce chronic hepatitis. Antibody against LSP can inhibit mononuclear cell cytotoxicity in humans with chronic 'active' hepatitis and LSP is antigenically reactive with sera of humans with chronic hepatitis

ACA & LSA: Water-soluble components and vesicular membrane fragments ranging in molecular weight from 10 to 200 kD. Although most LSA antigenic proteins are not liver-specific, LSA does contain several antigens recognised by sera of human patients with autoimmune chronic hepatopathies. Current information suggests that this antibody is directed against specific cytochromes

ALPA: Antibodies reactive against antigens derived from liver and pancreatic tissue of patients with chronic hepatitis, where this is characterised as an unusual form of autoimmune hepatitis

AMA: Antibodies directed against mitochondria, highly associated with primary biliary cirrhosis in humans. Although 'crude' antibody titres are non-specific, as they can be isolated in other inflammatory/infectious non-hepatic disorders, detection of specific M2 autoantigen is specific for liver disease. Some AMA are cross-reactive with antigens present in bacteria (*E coli*). These represent antimitochondrial antibodies against the pyruvate dehydrogenase and the 2-oxoglutarate dehydrogenase complexes

ANCA: Antibodies reactive against neutrophil cytosolic components (granules containing proteases)

### Immune and cytokine-related injury

Although cytokines are an essential part of host defence, their excessive production can prove deleterious. The proinflammatory cytokines TNF- $\alpha$ , interleukin-1 (IL-1) and interleukin-6 (IL-6) produced by stimulated Kupffer cells are sufficient to induce inflammatory reactions, such as acute phase protein production, sinusoidal neutrophil adhesion and a multitude of other effects (Tran-Thi and others 1993). IL-6 is the strongest stimulant for acute phase protein synthesis, IL-8 for neutrophil chemoattraction and TNF- $\alpha$  and IL-1 are associated with necrosis (Losser and Payen 1996, Friedman 1997). Nitric oxide may also be generated, primarily by interferon- $\gamma$  (IFN- $\gamma$ ) and LPS, and can mediate inflammation and cytotoxicity (Losser and Payen 1996).

Complement activation may also be involved in the initiation and perpetuation of liver injury. Included among its hepatoinjurious effects are its ability to enhance phagocytosis of opsonised microbes and the consequent cellular responses, to initiate Kupffer cell and neutrophil activation, to enhance neutrophil chemoattraction and adhesion, and to initiate direct cell lysis by formation of the membrane attack complex. Hepatotoxicity mediated by complement activation may develop dur-

ing endotoxaemia, ischaemia reperfusion injury, oxidative damage and consequent to a variety of immune responses (Losser and Payen 1996).

Immunological reactions against liver-specific antigens are believed to be integral in the perpetuation of liver injury in chronic hepatitis. These reactions can result from exposure of antigens normally hidden within hepatocellular membranes, cytosol or organelles, by alteration of normal surface antigens forming neoantigens, formation of haptens as occurs with certain drug metabolites, alteration in MHC expression (as previously described), or as a consequence of an abnormal immune response. Antigenic moieties involved are controversial and just how autoantibodies are involved in the pathogenesis of inflammatory liver disease remains unclear. None of the autoantibodies yet recognised have been shown to be pathological and are likely to be by-products of hepatocyte destruction. However, in humans, certain antigens and antibodies have diagnostic importance in differentiating between chronic hepatobiliary disorders. A list of antigens and antibodies associated with various forms of spontaneous and experimentally induced hepatobiliary disorders in man, experimental animal models and companion animal patients is summarised

in Table 3 (Thomas 1988, Andersson and Sevelius 1992, Weiss and others 1995, Czaja 1996, Meyer zum Buschenfelde and Gerken 1996, Poutout and others 1997).

A confusing aspect of some of the antigenic agents studied is their molecular complexity and lack of specificity for hepatobiliary components. Furthermore, differing analytical methods have led to contradictory findings. Nevertheless, the pathogenetic mechanism of immunoinjury targeted to hepatobiliary antigens is well accepted as a basis for perpetuation of non-suppurative chronic hepatic inflammation. Some of these reactions may be involved with the hepatic injury while others could well represent an epiphenomenon.

### Alpha<sub>1</sub>-antitrypsin

Alpha<sub>1</sub>-antitrypsin is an  $\alpha_1$ -globulin serine protease inhibitor synthesised largely in the liver. This glycoprotein has a relatively short half-life (four to five days in humans) and provides the majority of serum inhibition of trypsin, chymotrypsin, pancreatic elastase, skin collagenase, renin, urokinase, Hageman factor-cofactor and neutral proteases of polymorphonuclear leucocytes (Ghishan 1996). Defective formation of  $\alpha_1$ -antitrypsin in humans is associated with emphysematous lung disease pathologically linked with unrestrained neutrophil elastase. Hepatic cirrhosis develops in a subset of patients deficient in  $\alpha_1$ -antitrypsin. In these, globules of an amorphous PAS-positive diastase resistant material accumulates in hepatocytes, especially in periportal areas. How this is related aetiologically to hepatocellular injury has not been clarified. It has been suspected that some dogs with liver disease, particularly cocker spaniels, may have a deficiency of  $\alpha_1$ -antitrypsin activity (Sevelius and others 1994).

### Sequelae of hepatobiliary injury

Severe acute, self-limiting hepatic necrosis or inflammation rarely leads to fibrosis, cirrhosis or permanent architectural derangement. Although differentiated hepatocytes and bile epithelial cells are quiescent mitotically in a healthy adult liver,



hepatic stem cells (oval cells) are capable of extended proliferation that can effectively support repair of either cell type. As long as the reticulin fibre scaffolding is retained and 'pluripotential' oval cells remain, regeneration can follow an orderly pattern resulting in almost complete tissue repair. Although the precise anatomical location of the hepatic stem cell compartment is not well defined, evidence indicates that these cells reside in bile ductules (Alpini and others 1994, Roberts and others 1997). Recently identified proteins that may regulate cholangiocyte growth and proliferation include hepatocyte growth factor, epidermal growth factor, TGF $\alpha$ , proline, cholecystokinin and insulin-like growth factors. The reparative response of oval cells is recognised by most pathologists as bile duct proliferation and is a common histological feature observed in many forms of liver disease.

Chronic or repetitive injury is necessary to induce the cascade of events that culminate in hepatobiliary fibrosis. The reasons are not clear but could reflect the presence of mediators unique to chronic injury or failure of compensatory mechanisms to maintain the balance between collagen deposition and remodelling. Complex interactions involve immunological responses against normal or altered cell components and establishment of a self-perpetuating cycle of cell injury, cytokine production, eicosanoid liberation and inflammatory cell accumulation.

## Acknowledgements

This paper was presented at the BSAVA Annual Congress, Birmingham, UK, April 1998.

## References

ALPINI, G., PHILLIPS, J. O. & LARUSSO, N. F. (1994) The biology of biliary epithelia. In: *The Liver: Biology and Pathobiology*, 3rd edn. Eds I. M. Arias, J. L. Boyer, N. Fausto, W. B. Jakoby, D. A. Schachter and D. A. Shafritz. Raven Press, New York. pp 623-653

ANDERSSON, M. & SEVELIUS, E. (1992) Circulating auto-antibodies in dogs with chronic liver disease. *Journal of Small Animal Practice* **33**, 389-394

ARVIEUX, C., CALMUS, Y., GANE, P., LEGENDRE, C., MARIANI, P., DELELO, R., POUPON, R. & NORDLINGER, B. (1993) Immunogenicity of rat hepatocytes in vivo: effect of cholestasis-induced changes in major histocompatibility complex expression. *Journal of Hepatology* **18**, 335-341

BACON, B. R. & TAVILL, A. S. (1996) Hemochromatosis and the iron overload syndromes. In: *Hepatology: A Textbook of Liver Disease*, 3rd edn. Eds D. Zakim and T. D. Boyer. W. B. Saunders, Philadelphia. pp 1439-1472

BENEDETTI, A., BRUNELLI, E., RISICATO, R., CILLUFFO, T., JEZEQUEL, A. M. & ORLANDI, F. (1988) Subcellular changes and apoptosis induced by ethanol in rat liver. *Journal of Hepatology* **6**, 137-143

BISSELL, M. D. & MAHER, J. J. (1996) Hepatic fibrosis and cirrhosis. In: *Hepatology: A Textbook of Liver Disease*, 3rd edn. Eds D. Zakim and T. D. Boyer. W. B. Saunders, Philadelphia. pp 506-525

CZAJA, A. J. (1996) Autoimmune liver disease. In: *Hepatology: A Textbook of Liver Disease*. Eds D. Zakim and T. D. Boyer. W. B. Saunders, Philadelphia. pp 1259-1292

FRANCO, A., BARNABA, V., NATALI, P., BALSANO, C., MUSCA, A. & BALSANO, F. (1988) Expression of class I and class II major histocompatibility complex antigens on human hepatocytes. *Hepatology* **8**, 449-454

FRIEDMAN, S. L. (1997) Molecular mechanisms of hepatic fibrosis and principles of therapy. *Journal of Gastroenterology* **32**, 424-430

GHISHAN, F. K. (1996) Alpha<sub>1</sub>-antitrypsin deficiency. In: *Hepatology: A Textbook of Liver Disease*, 3rd edn. Eds D. Zakim and T. D. Boyer. W. B. Saunders, Philadelphia. pp 1565-1574

GONZALEZ-CORREA, J. A., DE LA CRUZ, J. P., MARTIN-AURIOLES, E., LOPEZ-EGEA, M. A., ORTIZ, P. & SANCHEZ DE LA CUESTA, F. (1997) Effects of s-adenosyl-L-methionine on hepatic and renal oxidative stress in an experimental model of acute biliary obstruction in rats. *Hepatology* **26**, 121-127

HANAUSKE-ABEL, H. M. (1996) Fibrosis: representative molecular elements, a basic concept, and emerging targets for suppressive treatment. In: *Hepatology: A Textbook of Liver Disease*, 3rd edn. Eds D. Zakim and T. D. Boyer. W. B. Saunders, Philadelphia. pp 465-506

INNES, G. K., NAGAFUCHI, Y., FULLER, B. J. & HOBBS, K. E. (1988) Increased expression of major histocompatibility antigens in the liver as a result of cholestasis. *Transplantation* **45**, 749-752

KAMADA, T., HAYASHI, N., SATO, N., KASAHARA, A. & ABE, H. (1986) Estimated hepatic oxygen consumption in patients with chronic liver diseases as assessed by organ reflectance spectrophotometry. *Digestive Diseases and Sciences* **31**, 119-124

LOBO-YEO, A., SENALDI, G., PORTMANN, B., MOWAT, A. P., MIELI-VERGANI, G. & VEREGANI, D. (1990) Class I and class II major histocompatibility complex antigen expression on hepatocytes: a study in children with liver disease. *Hepatology* **12**, 224-232

LOSSER, M.-R. & PAYEN, D. (1996) Mechanisms of liver damage. *Seminars in Liver Diseases* **16**, 356-367

MANN, M. P. & OBERMAYER-STRAUB, P. (1997) Cytochromes p 450 and uridine triphosphate-glucuronosyltransferases; model autoantigens to study drug-induced, virus-induced, and autoimmune liver disease. *Hepatology* **26**, 1054-1066

MEYER ZUM BUSCHENFELDE, K.-H. & GERKEN, G. (1996) Immune mechanism in the production of liver disease. In: *Hepatology: A Textbook of Liver Disease*. Eds D. Zakim and T. D. Boyer. W. B. Saunders, Philadelphia. pp 1243-1258

MIYAI, K., RICHARDSON, A. L., MAYR, W. & JAVITT, N. B. (1977) Subcellular pathology of rat liver in cholestasis and cholesteris induced by bile salts. *Laboratory Investigation* **36**, 249-258

MORGAN, D. J. & McLEAN, A. J. (1991) Therapeutic implications of impaired hepatic oxygen diffusion in chronic liver disease. *Hepatology* **14**, 1280-1282

MORGAN, D. J. & McLEAN, A. J. (1995) Clinical pharmacokinetic and pharmacodynamic considerations in patients with liver disease. *Clinical Pharmacokinetics* **29**, 370-391

OBERHAMMER, F. A. & ROBERTS, R. A. (1994) Apoptosis:

a widespread process involved in liver adaptation and carcinogenesis. In: *The Liver: Biology and Pathobiology*, 3rd edn. Eds I. M. Arias, J. L. Boyer, N. Fausto, W. B. Jakoby, D. A. Schachter and D. A. Shafritz. Raven Press, New York. pp 1547-1556

PARADIS, V., KOLLINGER, M., FABRE, M., HOLSTEGE, A., POYNARD, T. & BEDOSSA, P. (1997) In situ detection of lipid peroxidation by-products in chronic liver diseases. *Hepatology* **26**, 135-142

PINZANI, M. (1995) Novel insights into the biology and physiology of the Ito cell. *Pharmacology and Therapeutics* **66**, 387-412

POITOUT, F., WEISS, D. J. & ARMSTRONG, P. J. (1997) Cell-mediated immune responses to liver membrane protein in canine chronic hepatitis. *Veterinary Immunology and Immunopathology* **57**, 169-178

PUMFORD, N. R., HALMES, N. C. & HINSON, J. A. (1997) Covalent binding of xenobiotics to specific proteins in the liver. *Drug Metabolism Reviews* **29**, 39-57

RACINE-SAMSON, L., SCOZEC, J.-Y., D'ERRICO, A., FIORENTINO, M., CHRISTA, L., MOREAU, A., RODA, C., GRIGIONI, W. F. & FELDMAN, G. (1996) The metabolic organization of the adult human liver: a comparative study of normal, fibrotic, and cirrhotic liver tissue. *Hepatology* **24**, 104-113

ROBERTS, S. K., LUDWIG, J. & LARUSSO, N. F. (1997) The pathobiology of biliary epithelia. *Gastroenterology* **112**, 269-279

SCHRUMPF, E., FAUSA, O., ELGJO, K. & KOLMANNKOG, F. (1988) Hepatobiliary complications of inflammatory bowel disease. *Seminars in Liver Diseases* **8**, 201-209

SEVELIUS, E., ANDERSSON, M. & JONSSON, L. (1994) Hepatic accumulation of alpha-1-antitrypsin in chronic liver disease in the dog. *Journal of Comparative Pathology* **111**, 401-412

SHERMAN, I. A., PAPPAS, S. C. & FISHER, M. (1990) Hepatic microvascular changes associated with development of liver fibrosis and cirrhosis. *American Journal of Physiology* **258**, H460-H465

THOMAS, H. C. (1988) Immunologic aspects of liver disease. In: *Diseases of the Liver*, 6th edn. Eds L. Schiff and E. R. Schiff. J. B. Lippincott, Philadelphia. pp 163-185

TIEGS, G. & GANTNER, F. (1996) Immunotoxicology of T-cell-dependent experimental liver injury. *Experimental Toxicology and Pathology* **48**, 471-476

TRAN-THI, T. A., WEINHOLD, L., WEINSTOCK, C., HOFFMANN, R., SCHULZE-SPECKING, A., NORTHOFF, H. & DECKER, K. (1993) Production of tumor necrosis factor- $\alpha$ , interleukin-1 and interleukin-6 in the perfused rat liver. *European Cytokine Network* **4**, 363-370

TRIBBLE, D. L., AW, T. K. & JONES, D. P. (1987) The pathophysiological significance of lipid peroxidation in oxidative cell injury. *Hepatology* **7**, 377-387

VIERLING, J. M. (1996) Hepatobiliary complications of ulcerative colitis and Crohn's disease. In: *Hepatology: A Textbook of Liver Disease*, 3rd edn. Eds D. Zakim and T. D. Boyer. W. B. Saunders, Philadelphia. pp 1366-1404

VILLENEUVE, J. P. & HUET, P. M. (1987) Microcirculatory abnormalities in liver disease. *Hepatology* **7**, 186-187

WEISS, D. J., ARMSTRONG, J. & MRUTHYUNJAYA, A. (1995) Anti-liver membrane protein antibodies in dogs with chronic hepatitis. *Journal of Veterinary Internal Medicine* **9**, 267-271

YOUSEF, I. M., BOUCHARD, G., TUCHWEBER, B. & PLAA, G. L. (1997) Monohydroxy bile acid induced cholestasis: role of biotransformation. *Drug Metabolism Reviews* **19**, 167-181

ZHAO, M., LAISSUE, J. A. & ZIMMERMANN, A. (1997) Hepatocyte apoptosis in hepatic iron overload diseases. *Histology and Histopathology* **12**, 367-374

ZUCKER, S. D. & GOLLAN, J. L. (1996) Wilson's disease and hepatic copper toxicosis. In: *Hepatology: A Textbook of Liver Disease*. Eds D. Zakim and T. D. Boyer. W. B. Saunders, Philadelphia. pp 1405-1439