

Retrospective Study

Optimal treatment strategies for hepatic portal venous gas: A retrospective assessment

Masanori Gonda, Tatsuya Osuga, Yoshihiro Ikura, Kazunori Hasegawa, Kentaro Kawasaki, Takatoshi Nakashima

ORCID number: Masanori Gonda (0000-0003-2692-5004); Tatsuya Osuga (0000-0001-7316-9833); Yoshihiro Ikura (0000-0001-8599-2245); Kazunori Hasegawa (0000-0003-3270-4689); Kentaro Kawasaki (0000-0002-1891-8886); Takatoshi Nakashima (0000-0003-2051-2057).

Author contributions: Gonda M, Osuga T and Hasegawa K contributed to study concept and design; Gonda M and Osuga T contributed to data collection; Gonda M, Osuga T and Ikura Y contributed to data verification; Osuga T and Ikura Y contributed to data management, interpretation and supervision; Osuga T and Ikura Y contributed to statistical analysis and drafted the manuscript; Kawasaki K and Nakashima T contributed to critical revision of the manuscript.

Institutional review board

statement: The institutional review boards in Takatsuki General Hospital (Approval No: 2018-1) approved this study including an opt-out method of informed consent.

Informed consent statement:

Patient's consent was obtained through the opt-out method instead of a written form.

Conflict-of-interest statement: All authors declare no conflicts of interest related to this article.

Data sharing statement: No additional data are available.

Masanori Gonda, Tatsuya Osuga, Kazunori Hasegawa, Takatoshi Nakashima, Department of Gastroenterology, Takatsuki General Hospital, Takatsuki 5691192, Japan

Yoshihiro Ikura, Department of Pathology, Takatsuki General Hospital, Takatsuki 5691192, Japan

Kentaro Kawasaki, Department of Surgery, Takatsuki General Hospital, Takatsuki 5691192, Japan

Corresponding author: Tatsuya Osuga, MD, PhD, Chief Physician, Doctor, Postdoc, Department of Gastroenterology, Takatsuki General Hospital, 1-3-13 Kosobe-cho, Takatsuki 5691192, Japan. tatsuya.osuga@ajk.takatsuki-hp.or.jp

Abstract**BACKGROUND**

Hepatic portal venous gas (HPVG) generally indicates poor prognoses in patients with serious intestinal damage. Although surgical removal of the damaged portion is effective, some patients can recover with conservative treatments.

AIM

To establish an optimal treatment strategy for HPVG, we attempted to generate computed tomography (CT)-based criteria for determining surgical indication, and explored reliable prognostic factors in non-surgical cases.

METHODS

Thirty-four cases of HPVG (patients aged 34-99 years) were included. Necessity for surgery had been determined mainly by CT findings (*i.e.* free-air, embolism, lack of contrast enhancement of the intestinal wall, and intestinal pneumatosis). The clinical data, including treatment outcomes, were analyzed separately for the surgical cases and non-surgical cases.

RESULTS

Laparotomy was performed in eight cases (surgical cases). Seven patients (87.5%) survived but one (12.5%) died. In each case, severe intestinal damage was confirmed during surgery, and the necrotic portion, if present, was removed. Non-occlusive mesenteric ischemia was the most common cause ($n = 4$). Twenty-six cases were treated conservatively (non-surgical cases). Surgical treatments had been required for twelve but were abandoned because of the patients' poor general conditions. Surprisingly, however, three (25%) of the twelve inoperable

Open-Access: This article is an open-access article that was selected by an in-house editor and fully peer-reviewed by external reviewers. It is distributed in accordance with the Creative Commons Attribution NonCommercial (CC BY-NC 4.0) license, which permits others to distribute, remix, adapt, build upon this work non-commercially, and license their derivative works on different terms, provided the original work is properly cited and the use is non-commercial. See: <http://creativecommons.org/licenses/by-nc/4.0/>

Manuscript source: Invited Conference Manuscripts

Received: December 26, 2019

Peer-review started: December 26, 2019

First decision: February 18, 2020

Revised: March 25, 2020

Accepted: April 1, 2020

Article in press: April 1, 2020

Published online: April 14, 2020

P-Reviewer: Tsoulfas G

S-Editor: Zhang L

L-Editor: A

E-Editor: Ma YJ



patients survived. The remaining 14 of the 26 cases were diagnosed originally as being sufficiently cured by conservative treatments, and only one patient (7%) died. Comparative analyses of the fatal ($n = 10$) and recovery ($n = 16$) cases revealed that ascites, peritoneal irritation signs, and shock were significantly more frequent in the fatal cases. The mortality was 90% if two or all of these three clinical findings were detected.

CONCLUSION

HPVG related to intestinal necrosis requires surgery, and our CT-based criteria are probably useful to determine the surgical indication. In non-surgical cases, ascites, peritoneal irritation signs and shock were closely associated with poor prognoses, and are applicable as predictors of patients' prognoses.

Key words: Hepatic portal venous gas; Surgical treatment; Conservative treatment; Computed tomography; Intestinal necrosis; Prognostic factor

©The Author(s) 2020. Published by Baishideng Publishing Group Inc. All rights reserved.

Core tip: Hepatic portal venous gas caused by intestinal necrosis is a life-threatening condition and requires surgery. Computed tomography findings of free-air, embolism, lack of contrast enhancement of the intestinal wall, and intestinal pneumatosis are useful criteria to determine the surgical indication. In non-surgical cases, ascites, peritoneal irritation signs and shock were closely associated with poor prognoses, and are valuable as predictors of patients' prognoses.

Citation: Gonda M, Osuga T, Ikura Y, Hasegawa K, Kawasaki K, Nakashima T. Optimal treatment strategies for hepatic portal venous gas: A retrospective assessment. *World J Gastroenterol* 2020; 26(14): 1628-1637

URL: <https://www.wjgnet.com/1007-9327/full/v26/i14/1628.htm>

DOI: <https://dx.doi.org/10.3748/wjg.v26.i14.1628>

INTRODUCTION

Hepatic portal venous gas (HPVG) was first presented by Wolfe and Evans^[1] in 1955 as a pediatric case, followed in 1960 by the report of Susman and Senturia^[2] of an adult case, and was recognized as a fatal condition in patients with serious intestinal damage, including severe intestinal ischemia, enterocolitis, *etc.*^[3,4]. Although surgical removal of the damaged portion has generally been considered the sole effective therapy, it has been shown by advanced imaging modalities, including computed tomography (CT), that some of the patients can recover with non-surgical, conservative treatments^[3,5-9]. HPVG in the patients who recovered was mostly not associated with intestinal necrosis, suggesting that not all HPVG patients require surgery^[9,10]. Conversely, unnecessary laparotomy might have been performed in such mild cases. A robust criterion of surgical indication is necessary to prevent unpredictable under- and/or over-treatments.

The challenging surgery conducted in emergency settings is not applicable to every patient with acute intestinal damage. Some pre-existing conditions, such as poor performance status (PS), severe frailty and extreme exhaustion, may rule out surgery as a therapeutic option. In those cases, to make the best management plan for each non-surgical patient and to explain anticipated outcomes clearly to their families, physicians require reliable prediction indices for estimating the curative potential of non-surgical, conservative treatments.

In this retrospective study, we attempt to determine novel CT-based criteria for deciding surgical indication, and to define prognostic factors in non-surgical conservative treatments of HPVG. A goal of the study is the establishment of optimal treatment strategies against HPVG especially in non-surgical cases.

MATERIALS AND METHODS

Patients

From April 2012 to February 2019, 34 patients (35 cases; one patient was treated twice conservatively) were diagnosed as HPVG and treated at Takatsuki General Hospital. One patient was excluded due to insufficient clinical data, and the remaining 33 patients (19 women and 14 men; aged 34-99 years) were included in this retrospective study. Their chief complaints were abdominal pain ($n = 28$), nausea/vomiting ($n = 12$), melena ($n = 9$) and abdominal fullness ($n = 28$). Their comorbidities were diabetes ($n = 8$), cerebral infarction ($n = 6$), ischemic heart disease ($n = 3$), pancreatic cancer ($n = 1$), cerebral palsy ($n = 1$) and chronic subdural hematoma ($n = 1$). All the patients presented with acute and serious illnesses, and ten of them were in shock (systolic blood pressure ≤ 90 mmHg) at the initial consultations. This study was reviewed and approved by the ethical committee of Takatsuki General Hospital (Approval No: 2018-1).

The necessity for surgical treatments of these patients was determined mainly based on presence of one or more of the following CT findings: (1) Abdominal free-air; (2) Mesenteric artery embolism; (3) Lack of contrast enhancement of the intestinal wall; and (4) Intestinal pneumatosis. However, for some of the patients who required surgery, laparotomy was abandoned because of poor physical status and socio-medical conditions (inoperable patients). Consequently, the patients were divided into a surgical treatment group and a non-surgical conservative treatment group (including inoperable patients and patients who did not require surgery). Three typical cases are presented below.

Representative cases

Case 1 (surgical case): A 72-year-old female patient, hospitalized for treatment of ischemic heart disease and cerebral infarction complained suddenly of abdominal pain, vomiting and melena. She fell into shock and an abdominal CT was performed immediately, providing a diagnosis of HPVG with intestinal ischemia (Figure 1A). Partial intestinal resection was carried out to save the patient and the pathologic specimen obtained revealed hemorrhagic necrosis associated with pneumatosis (Figure 1B and C), which was concordant with a clinical diagnosis of non-occlusive mesenteric ischemia (NOMI).

Case 2 (inoperable case with recovery): An 86-year-old female patient with dementia and a history of aortic dissection complained of vomiting and melena after her evening meal. She was transferred to our hospital by ambulance. An emergency abdominal CT revealed HPVG and intestinal pneumatosis (Figure 2A). Laparotomy was considered but not performed because of her poor general condition. However, HPVG was alleviated (Figure 2B) by conservative treatment (rehydration and antibiotics), and she survived and recovered.

Case 3 (inoperable fatal case): A 91-year-old female patient with dementia and extremely poor PS [Eastern Cooperative Oncology Group (ECOG) PS 4] complained of vomiting and melena. On admission, abdominal CT showed HPVG and intestinal pneumatosis (Figure 3). Surgical treatment was abandoned because of the expected poor postoperative prognosis. She died the day after admission.

Assessments

The patients' data including clinical backgrounds, physical examination findings, laboratory test results, CT images, and treatment outcomes were analyzed separately for the surgical patients and non-surgical patients. The primary purposes of the analyses were validation of the appropriateness of CT findings-based decision criteria for surgery and development of a prediction index to estimate the mortality of non-surgical patients. Fisher's exact test and Mann-Whitney *U*-test were used for statistical analysis, and $P < 0.05$ was considered to be significant.

RESULTS

As shown in Figure 4, 20 patients were considered to be suitable for surgical treatments, eight were treated with operations (surgical cases) but 12 were determined to be inoperable cases because of their poor general conditions, *e.g.* ECOG PS 4 ($n = 9$). Of the eight surgical cases, five patients were originally in shock status, which was resolved preoperatively by rapid rehydration. In 14 cases, CT findings on admission suggested that surgery was not necessary. Consequently, a total of 26 cases (25 patients) were managed conservatively as non-surgical cases, of which 16 cases (15 patients) survived/recovered and 10 died. The overall mortality was 32% (11 of 34

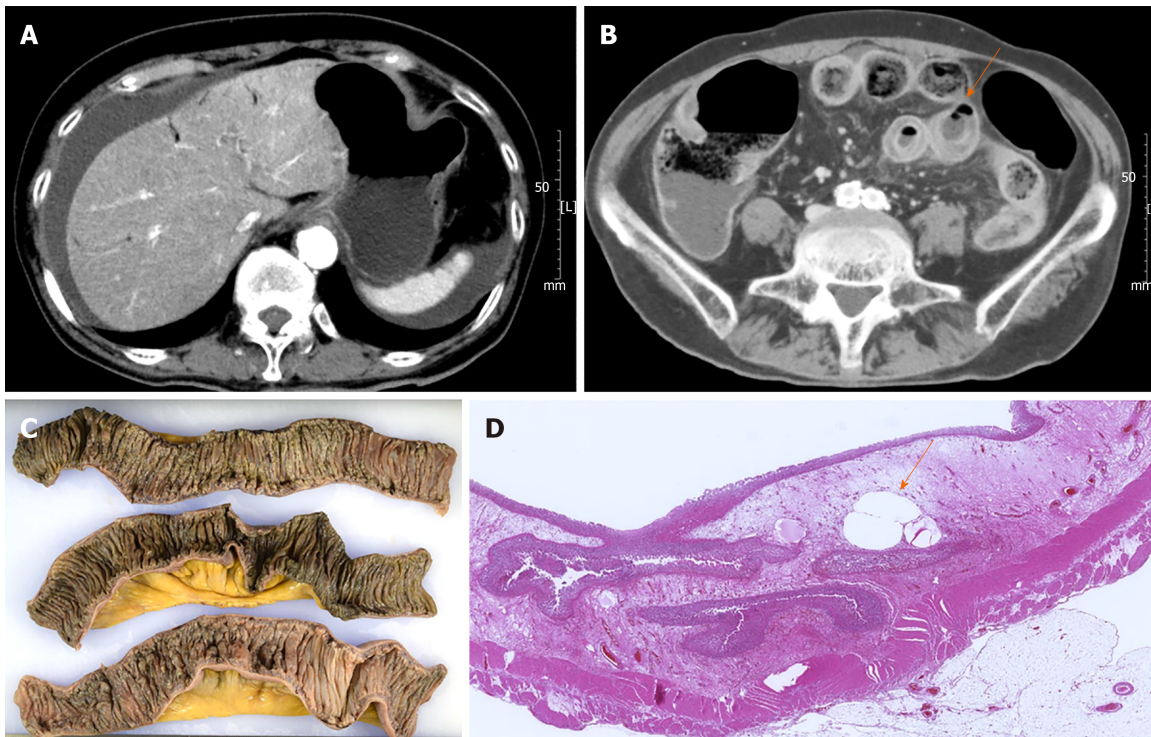


Figure 1 Computed tomography and pathologic findings of case 1. A: Abdominal computed tomography images on admission demonstrate hepatic portal venous gas, ascites; B: Intestinal pneumatosis (arrow); C: The resected small intestine shows hemorrhagic necrosis; D: Air-bubbles in the damaged intestinal wall (arrow).

cases).

Surgical cases

Clinical and pathological details of the eight surgically-treated patients are shown in [Table 1](#). Necrotic portions of the intestine were resected in seven patients, and one patient could be rescued only by separation of intestinal adhesions. Final diagnoses were NOMI ($n = 4$), clostridium difficile enteritis ($n = 1$), strangulation ileus ($n = 1$), superior mesenteric artery thrombosis ($n = 1$) and gastric perforation ($n = 1$, a fatal case).

Seven (87.5%) of the eight surgically treated patients survived, and one (12.5%) died (three days post-operation due to sepsis). In contrast, only three (25%) of 12 inoperable patients survived, and nine (75%) died. The difference in the survival rate was statistically significant ($P = 0.02$), indicating that the decision for operation/laparotomy was very appropriate. This was confirmed by the very low mortality rate ($n = 1$, 7%) of 14 cases not requiring surgery. In the fatal case, the HPVG had disappeared, and the general condition had also improved, but the patient died of recurrent illness.

Non-surgical cases

Of the 26 non-surgical cases, 16 (61.5%) were cured by conservative treatments (rehydration, antibiotics, ileus tube insertion, *etc.*), but 10 (38.5%) died. Nine of the 10 fatal cases had been defined as inoperable. Detailed clinical and laboratory data of the patients who died or recovered are shown in [Table 2](#).

To determine the critical prognostic factors in the non-surgical cases, comparative analyses were performed between the fatal and recovery cases ([Table 2](#)). Rates of ascites (80% *vs* 31%), peritoneal irritation sign (80% *vs* 12.5%) and shock (60% *vs* 0%) were significantly higher in the fatal cases. Of the laboratory test results, leukocyte counts were significantly higher in the fatal cases than the recovery cases (median 13400 *vs* 9050 / μ L; $P = 0.025$). Base excess (median -6.2 *vs* 1.8 mEq/L) tended to be lower, and plasma levels of CRP (median 12.84 *vs* 2.39 mg/dL) and lactic acid (median 36 *vs* 26 mg/dL) tended to be higher in the fatal cases, but the differences were not significant.

A predictive index was developed using the three statistically significant clinical/non-laboratory factors, *i.e.* ascites, peritoneal irritation sign and shock. Most of the fatal cases (90%) presented two or three of the factors, while none of the recovery cases presented two or three of the factors ([Table 3](#)). This indicates that prediction of mortality with detection of two or all of the three factors is a superior

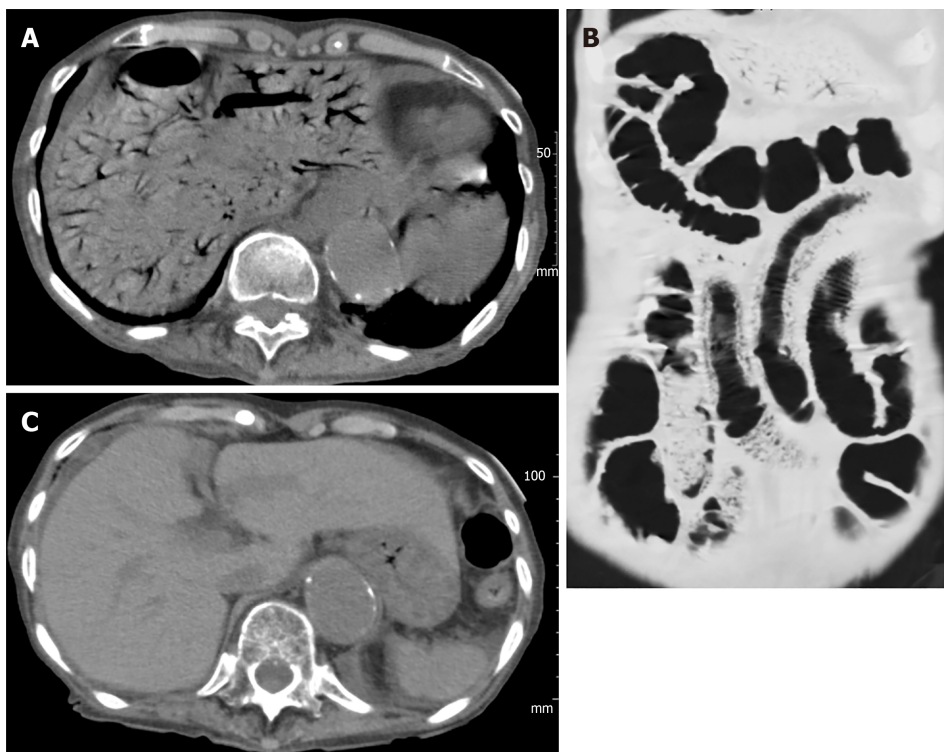

Figure 2 Abdominal computed tomography images of case 2. A: Extensive hepatic portal venous gas; B: Intestinal pneumatosis were found on the first hospital day; C: However, hepatic portal venous gas disappeared on the seventh hospital day.

index of sensitivity 90% and specificity 100%. Notably, the three inoperable patients who recovered, without exception, had none or only one of the three factors. The predictive accuracy was not improved by adding the leukocyte counts as a fourth factor (data not shown).

DISCUSSION

HPVG has been recognized as a serious condition that is associated with poor prognosis and requires urgent surgical treatment. Formerly its mortality was reported to be 75%-90%^[3,11] but this has improved recently to 29%-56%^[6,10,12] with an increase in the detection rate and advances in therapy. At the same time, non-surgical cases have become more common^[6-9] but reliable guidelines to select the optimal treatment for each patient have not yet been established.

The pathologic mechanisms of HPVG are summarized as (1) intramural gas-producing bacterial proliferation; (2) elevated intraluminal pressure because of bowel obstruction, endoscopic procedures, *etc.*; and (3) air-translocation through damaged/necrotic mucosa^[3,7]. Kinoshita *et al*^[10] reported that the etiologies /underlying conditions of HPVG were mesenteric ischemia (43%), digestive tract dilation (12%), intraperitoneal abscess (11%), ulcerative colitis (4%), gastric ulcer (4%), complications from endoscopic procedures (4%), intraperitoneal tumors (3%), and others (15%). HPVG of our patients were related to NOMI ($n = 12$, including eight suspicious cases), ischemic enterocolitis ($n = 5$), superior mesenteric arterial thrombosis ($n = 3$), ileus [strangulation ($n = 1$) or non-strangulation ($n = 4$)], constipation ($n = 4$), postoperative intestinal necrosis ($n = 1$), clostridium difficile enteritis ($n = 1$), acute pancreatitis ($n = 1$), gastric perforation ($n = 1$), and bladder cancer invading the rectum ($n = 1$). The proportion of these background conditions and the overall mortality in our cases (32%) were almost identical with those of other recent reports, indicating that our HPVG group was standard and not at all unusual.

Through the retrospective observation of this standard HPVG group, we validated the appropriateness of our original CT findings-based determination to select subjects for surgical treatment. The four CT findings, *i.e.* abdominal free-air, mesenteric artery embolism, lack of contrast enhancement of the intestinal wall, and intestinal pneumatosis, which are hallmarks of intestinal perforation and/or severe ischemia/necrosis^[13], seem to be appropriate as convenient decision criteria for laparotomy. A similar preoperative assessment was previously reported from a group

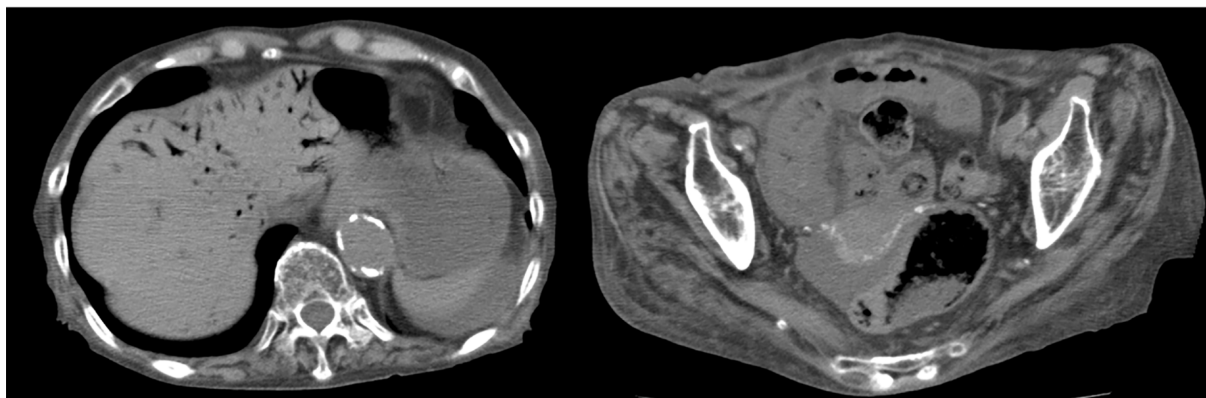


Figure 3 Abdominal computed tomography images of case 3 on admission. Left lobe hepatic portal venous gas and the moderate amount of ascites are seen.

of Japanese surgeons^[14]. Our CT-based simple method provides not only comparable accuracy but also superior convenience.

In addition, we found reliable clinical indices for predicting the mortality of non-surgical patients with HPVG, including inoperable cases. Non-surgical patients who have more than two of three clinically obtainable factors, ascites (by CT), peritoneal irritation (by physical examination), and shock (by checking vital signs), are thought to be in life-threatening conditions. Critical intestinal ischemia is associated frequently with perforation, sepsis and peritonitis, and hence, ascites, peritoneal irritation and shock are thought to be its typical manifestations. An analogous prediction system using Acute Physiology and Chronic Health Evaluation (APACHE) II was proposed by Yoo *et al*^[15]. However, because APACHE II requires several items of laboratory data^[16,17], this predictive algorithm may be difficult to disseminate as a general procedure. Very recently, similar emergency medicine scorings also have been suggested for use for the identical purpose^[18,19]. Same as APACHE II, they are not specific to abdominal illnesses, and seem not to be perfect as predictors of HPVG.

The importance of laboratory test results for determination of surgical indication and for prediction of non-surgical patients' prognoses was also examined, as had been done in previous analogous studies. Although some of these tended to show greater degrees of abnormal values in patients who died than in those who survived, the differences were not statistically significant. Only leukocyte counts were significantly higher in the fatal cases than in the recovery cases, but were not a contributory factor to the mortality prediction. As a result, we were able to develop a quite simple diagnostic algorithm composed of characteristic CT findings and physical examination findings, to provide the optimal treatment for each HPVG patient. With the progression of an aging society, the incidence of HPVG, especially of inoperable cases, is inevitably increasing. Our two-step decision and prediction process may be useful not only for selection of surgical cases but also for considering non-surgical but intensive treatments for such inoperable patients. In other words, a strategic non-surgical management may be recommended in the future to HPVG patients who have 0-1 of the high-mortality factors (ascites, peritoneal irritation sign and shock). Alternatively, a challenging surgery may be considered in patients who have 2-3 of the factors, regardless of their background conditions. A further validation study, such as a prospective study, may be required to generalize our novel treatment strategy for HPVG.

Table 1 Preoperative findings, outcomes and final diagnosis of the surgical cases (n = 8)

Case	Age	Gen-der	Final diagnosis	Outco-me	Chief complaints	Shock ¹	Perito-neal irritation signs	Asci-tes ²	Intes-tinal pneuma-tosis	LOCE in intesti-nal wall	Free air	WBC (μL)	CRP (mg/dL)	BE (mmol/L)	Lactate (mg/dL)
1 ³	72	F	NOMI	Recovery	Abdominal pain, nausea	+	+	2+	-	+	-	26000	1.57	-4.9	18
2	74	M	Clostridium enteritis	Recovery	Nausea, vomiting	-	+	2+	-	+	-	15400	16	5.3	7
3	65	F	NOMI	Recovery	Abdominal pain	-	-	-	-	+	+	31500	7.39	-7	13
4	86	M	Gastric perforation	Death	Abdominal pain, vomiting	+	+	3+	+	+	+	7800	0.17	-11.3	73
5	69	M	NOMI	Recovery	Abdominal pain	+	+	2+	+	-	-	13200	10.8	2.3	14
6	71	M	Mesenteric artery thrombosis	Recovery	Abdominal pain, vomiting	+	+	1+	+	+	+	22500	1.81	-6.3	46
7	84	M	NOMI	Recovery	Abdominal fullness	+	+	2+	+	NE	-	36700	15.54	-5.5	47
8	34	M	Strangulation ileus	Recovery	Abdominal fullness	-	NE	-	+	+	-	10000	4.67	-3.1	42

¹≤ Systolic blood pressure 90 mmHg.

²Semiquantitative evaluation as - (none).

³Shown as case 1 in the case presentation.

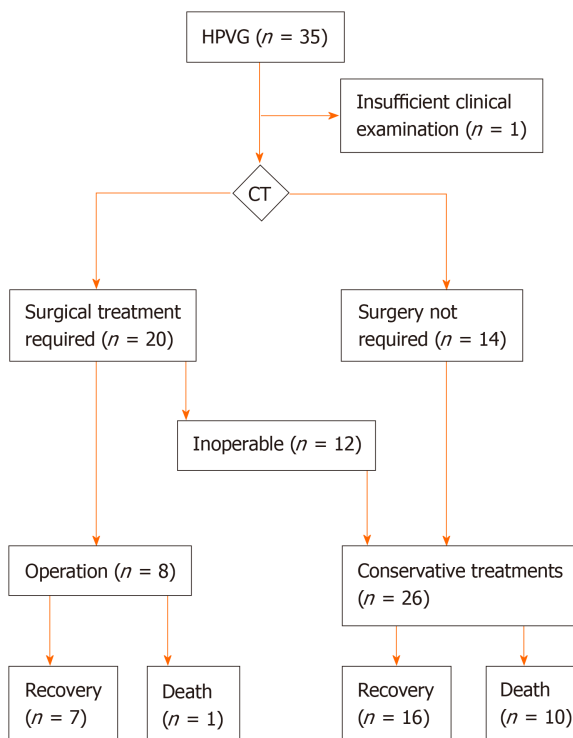
1+: Small amount; 2+: Moderate amount; 3+: Large amount. LOCE: Lack of contrast enhancement; BE: Base excess; NE: Not examined; NOMI: Non-occlusive mesenteric ischemia.

Table 2 Clinical data comparison between the non-surgical recovery and the non-surgical death cases

	Recovery (<i>n</i> = 16)	Death (<i>n</i> = 10)	<i>P</i> value
Age [median (range)]	86 (56-92)	84 (72-99)	<i>P</i> > 0.999 ¹
Gender (M:F)	4:12	4:6	<i>P</i> = 0.665 ²
Shock (≤ systolic BP 90 mmHg) (%)	0 (0%)	6 (60%)	<i>P</i> = 0.001 ²
Peritoneal irritation (%)	2 (13%)	8 (80%)	<i>P</i> = 0.001 ²
Ascites (%)	5 (31%)	8 (80%)	<i>P</i> = 0.041 ²
Intestinal pneumatosis (%)	8 (50%)	7 (70%)	<i>P</i> = 0.428 ²
WBC (/μL) [median (range)]	9050 (4200-31800)	13400 (9900-19000)	<i>P</i> = 0.025 ¹
CRP (mg/dL) [median (range)]	2.39 (0.11-28.41)	12.84 (0.1-33.26)	<i>P</i> = 0.355 ¹
BE (mmol/L) [median (range)]	1.8 (-8.4 - 14.6)	-6.2 (-18.2 - 6.8)	<i>P</i> = 0.071 ¹
Lactate (mg/dL) [median (range)]	26 (9-63)	36 (11-120)	<i>P</i> = 0.231 ¹

¹Mann-Whitney-*U* test.²Fisher's exact test. A significant *P* value is shown on underline. BE: Base excess.**Table 3** Mortality prediction in the 26 non-surgical cases by the three factors [Ascites, peritoneal irritation sign (muscular defense and/or rebound tenderness), and shock]

	Recovery	Death
0-1 Factor	16	1
2-3 Factors	0	9

**Figure 4** A treatment decision flowchart and outcomes. CT: Computed tomography; HPVG: Hepatic portal venous gas.

ARTICLE HIGHLIGHTS

Research background

Hepatic portal venous gas (HPVG) is generally recognized as a life-threatening sign in patients with serious intestinal damage. While most of such patients require surgical treatments, some

patients can recover without surgery.

Research motivation

We aimed to establish an optimal treatment strategy for HPVG, *i.e.*, how to select surgical or conservative treatments.

Research objectives

We tested accuracy of our original computed tomography (CT)-based selection criteria. Additionally, we found if there were reliable prognostic factors in non-surgical cases.

Research methods

Thirty-four cases of HPVG were included. Surgical indication had been decided by CT findings, including free-air, embolism, lack of contrast enhancement of the intestinal wall, and intestinal pneumatosis. Their clinical findings and treatment outcomes were analyzed separately in the surgical cases and non-surgical cases.

Research results

Of eight surgical cases, seven patients (87.5%) survived but one (12.5%) died. All the surgical patients had severe intestinal damage and the necrotic portions were resected. In addition to 14 cases without surgical indication, 12 inoperable cases were defined as non-surgical cases (total 26 cases). Three (25%) of the 12 inoperable patients survived. Only one patient (7%) died among the 14 patients diagnosed as being surgery unnecessary. Comparative analyses of the fatal ($n = 10$) and recovery ($n = 16$) cases revealed that ascites, peritoneal irritation signs, and shock were significantly more frequent in the fatal cases. The mortality was 90% if two or all of these three clinical findings were detected.

Research conclusions

Our CT-based criteria were useful to determine the surgical indication for HPVG patients. In non-surgical cases, ascites, peritoneal irritation signs and shock were closely associated with poor prognoses, and are applicable as predictors of patients' prognoses.

Research perspectives

Our two-step decision and prediction process may be applicable not only for selection of surgical cases but also for considering non-surgical but intensive treatments for such inoperable patients.

ACKNOWLEDGEMENTS

The authors thank Dr. Masashi Shimizu (Department of Radiology, Takatsuki General Hospital) who helped us by reviewing the CT findings of all the HPVG patients.

REFERENCES

- 1 **Wolfe JN**, Evans WA. Gas in the portal veins of the liver in infants; a roentgenographic demonstration with postmortem anatomical correlation. *Am J Roentgenol Radium Ther Nucl Med* 1955; **74**: 486-488 [PMID: [13249015](#)]
- 2 **Susman N**, Senturia HR. Gas embolization of the portal venous system. *Am J Roentgenol Radium Ther Nucl Med* 1960; **83**: 847-850 [PMID: [13835795](#)]
- 3 **Liebman PR**, Patten MT, Manny J, Benfield JR, Hechtman HB. Hepatic--portal venous gas in adults: etiology, pathophysiology and clinical significance. *Ann Surg* 1978; **187**: 281-287 [PMID: [637584](#) DOI: [10.1097/0000658-197803000-00012](#)]
- 4 **Hussain A**, Mahmood H, El-Hasani S. Portal vein gas in emergency surgery. *World J Emerg Surg* 2008; **3**: 21 [PMID: [18637169](#) DOI: [10.1186/1749-7922-3-21](#)]
- 5 **Chan SC**, Wan YL, Cheung YC, Ng SH, Wong AM, Ng KK. Computed tomography findings in fatal cases of enormous hepatic portal venous gas. *World J Gastroenterol* 2005; **11**: 2953-2955 [PMID: [15902735](#) DOI: [10.3748/wjg.v11.i19.2953](#)]
- 6 **Faberman RS**, Mayo-Smith WW. Outcome of 17 patients with portal venous gas detected by CT. *AJR Am J Roentgenol* 1997; **169**: 1535-1538 [PMID: [9393159](#) DOI: [10.2214/ajr.169.6.9393159](#)]
- 7 **Nelson AL**, Millington TM, Sahani D, Chung RT, Bauer C, Hertl M, Warshaw AL, Conrad C. Hepatic portal venous gas: the ABCs of management. *Arch Surg* 2009; **144**: 575-581; discussion 581 [PMID: [19528392](#) DOI: [10.1001/archsurg.2009.88](#)]
- 8 **Gorospe EC**. Benign hepatic portal venous gas in a critically ill patient. *ScientificWorldJournal* 2008; **8**: 951-952 [PMID: [18836664](#) DOI: [10.1100/tsw.2008.133](#)]
- 9 **Abboud B**, El Hachem J, Yazbeck T, Doumit C. Hepatic portal venous gas: physiopathology, etiology, prognosis and treatment. *World J Gastroenterol* 2009; **15**: 3585-3590 [PMID: [19653334](#) DOI: [10.3748/wjg.15.3585](#)]
- 10 **Kinoshita H**, Shinozaki M, Tanimura H, Umemoto Y, Sakaguchi S, Takifuji K, Kawasaki S, Hayashi H, Yamaue H. Clinical features and management of hepatic portal venous gas: four case reports and cumulative review of the literature. *Arch Surg* 2001; **136**: 1410-1414 [PMID: [11735870](#) DOI: [10.1001/archsurg.136.12.1410](#)]
- 11 **Fred HL**, Mayhall CG, Harle TS. Hepatic portal venous gas. A review and report on six new cases. *Am J Med* 1968; **44**: 557-565 [PMID: [5642715](#) DOI: [10.1016/0002-9343\(68\)90056-9](#)]
- 12 **Seak CJ**, Hsu KH, Wong YC, Ng CJ, Yen DH, Seak JC, Seak CK. The prognostic factors of adult patients with hepatic portal venous gas in the ED. *Am J Emerg Med* 2014; **32**: 972-975 [PMID: [25043627](#) DOI: [10.1016/j.ajem.2014.05.015](#)]

- 10.1016/j.ajem.2014.05.016]
- 13 **Knechtle SJ**, Davidoff AM, Rice RP. Pneumatosis intestinalis. Surgical management and clinical outcome. *Ann Surg* 1990; **212**: 160-165 [PMID: 2375647 DOI: 10.1097/00000658-199008000-00008]
 - 14 **Koami H**, Isa T, Ishimine T, Kameyama S, Matsumura T, Yamada KC, Sakamoto Y. Risk factors for bowel necrosis in patients with hepatic portal venous gas. *Surg Today* 2015; **45**: 156-161 [PMID: 24880671 DOI: 10.1007/s00595-014-0941-1]
 - 15 **Yoo SK**, Park JH, Kwon SH. Clinical outcomes in surgical and non-surgical management of hepatic portal venous gas. *Korean J Hepatobiliary Pancreat Surg* 2015; **19**: 181-187 [PMID: 26693238 DOI: 10.14701/kjhbpps.2015.19.4.181]
 - 16 **Wu JM**, Tsai MS, Lin MT, Tien YW, Lin TH. High APACHE II score and long length of bowel resection impair the outcomes in patients with necrotic bowel induced hepatic portal venous gas. *BMC Gastroenterol* 2011; **11**: 18 [PMID: 21385464 DOI: 10.1186/1471-230X-11-18]
 - 17 **Knaus WA**, Draper EA, Wagner DP, Zimmerman JE. APACHE II: a severity of disease classification system. *Crit Care Med* 1985; **13**: 818-829 [PMID: 3928249]
 - 18 **Seak CJ**, Yen DH, Ng CJ, Wong YC, Hsu KH, Seak JC, Chen HY, Seak CK. Rapid Emergency Medicine Score: A novel prognostic tool for predicting the outcomes of adult patients with hepatic portal venous gas in the emergency department. *PLoS One* 2017; **12**: e0184813 [PMID: 28915258 DOI: 10.1371/journal.pone.0184813]
 - 19 **Olsson T**, Terent A, Lind L. Rapid Emergency Medicine score: a new prognostic tool for in-hospital mortality in nonsurgical emergency department patients. *J Intern Med* 2004; **255**: 579-587 [PMID: 15078500 DOI: 10.1111/j.1365-2796.2004.01321.x]



Published By Baishideng Publishing Group Inc
7041 Koll Center Parkway, Suite 160, Pleasanton, CA 94566, USA
Telephone: +1-925-3991568
E-mail: bpgoffice@wjgnet.com
Help Desk: <http://www.f6publishing.com/helpdesk>
<http://www.wjgnet.com>

