

Herpesvirus Respiratory Infections in Immunocompromised Patients: Epidemiology, Management, and Outcomes

Gail E. Reid, MD¹ Joseph P. Lynch III, MD² Samuel Weigt, MD² David Sayah, MD²
John A. Belperio, MD² Shellee A. Grim, PharmD^{1,3} Nina M. Clark, MD¹

¹Division of Infectious Diseases, Department of Medicine, Loyola University, Maywood, Illinois

²Division of Pulmonary, Critical Care Medicine, Allergy, and Clinical Immunology, Department of Medicine, The David Geffen School of Medicine at University of California at Los Angeles, Los Angeles, California

³Department of Pharmacy Practice, University of Illinois at Chicago, Chicago, Illinois

Address for correspondence: Nina M. Clark, MD, Loyola University Medical Center, 2160 South First Avenue, Fahey Center, Room 112, Maywood, IL 60153 (e-mail: nmclark@lumc.edu).

Semin Respir Crit Care Med 2016;37:603–630.

Abstract

Among immunocompromised individuals, members of the human Herpesviridae family are frequently encountered pathogens. Cytomegalovirus, herpes simplex virus 1 and 2, varicella zoster virus, Epstein–Barr virus, and human herpesvirus-6, -7, and -8 all establish latency after infection and can reactivate during periods of immunosuppression, leading to both direct and indirect adverse effects on the host including severe organ dysfunction as well as allograft rejection and loss after transplantation. While not all herpesviruses are primary respiratory pathogens, many of their manifestations include involvement of the respiratory tract. This article discusses the individual viruses, their epidemiology, and clinical manifestations as well as recommended treatment and preventive strategies.

Keywords

- ▶ herpesviruses
- ▶ transplantation
- ▶ immunodeficiency
- ▶ viral infection

Respiratory infections remain a common and serious complication of transplantation and chronic immunosuppressive therapy. Manifestations are often more severe than in immunocompetent hosts and may be atypical. Human herpesviruses (HHVs) cause a major burden of disease in patients with impaired immunity and cause a wide spectrum of disease, including pulmonary infection. In addition, Epstein–Barr virus (EBV) and HHV-8 are oncogenic viruses, and in certain settings, infection with these pathogens may evolve into malignancy that can include respiratory tract involvement. This review will focus on the epidemiology, clinical manifestations, treatment, and preventive strategies for infection by HHVs in immunocompromised persons, including hematopoietic cell transplant (HCT) and solid organ transplant (SOT) recipients.

Cytomegalovirus

Epidemiology and Prevalence

Cytomegalovirus (CMV), also known as HHV-5, is a ubiquitous human DNA virus of the subfamily β -Herpesviridae. It typically infects individuals early in life, with rates of seropositivity varying from 40% in industrialized countries to 100% in some underdeveloped countries.^{1,2} Acute CMV infection in immunocompromised hosts such as SOT or HCT recipients and those with acquired immunodeficiency syndrome (AIDS) not only causes direct morbidity and mortality, it may have widespread indirect effects on the host.³ Despite progress in the management of CMV infection, it remains a leading complication of transplantation, and prevention and treatment of active CMV can positively impact transplant outcomes.⁴

Issue Theme Respiratory Viral Infections; Guest Editor: Sunit K. Singh, PhD

Copyright © 2016 by Thieme Medical Publishers, Inc., 333 Seventh Avenue, New York, NY 10001, USA.
Tel: +1(212) 584-4662.

DOI <http://dx.doi.org/10.1055/s-0036-1584793>.
ISSN 1069-3424.

Because of the frequency with which CMV is encountered after transplantation, its wide-ranging effects, and its impact on morbidity and mortality, it is one of the most significant infections that can occur in transplant recipients. After primary infection occurs, CMV establishes persistent latency in various cells including monocytes, dendritic cells, megakaryocytes, and progenitor myeloid cells in bone marrow, leading to the lifelong potential for reactivation.⁵ Primary infection in immunocompetent hosts typically occurs with no symptoms or a mononucleosis-type illness,⁶ but can be much more severe in immunocompromised persons.⁷

CMV-seronegative SOT recipients may develop primary CMV infection from the donor organ, from blood transfusions or via contact with infected body fluids including saliva, semen, and breast milk.⁸ Reactivation of latent infection may also occur after transplant, as can coinfection by a donor's CMV strain.⁹ Organ transplant recipients who are CMV-seropositive before transplantation often develop less severe manifestations of infection compared with those who develop primary infection after transplantation.¹⁰ CMV infection, characterized by the presence of viremia, should be viewed separately from "CMV disease"; the latter refers to CMV infection accompanied by signs and symptoms such as fever, leukopenia, or organ dysfunction.¹¹

If antiviral prophylaxis is not administered, CMV infection occurs within the first 3 months of transplant in SOT recipients who are seropositive or those who receive an organ from a seropositive donor,^{10,12-14} as this is generally the period of greatest immunosuppression. Infection may be asymptomatic or associated with the disease. However, because CMV prophylaxis is commonly used after solid organ transplantation if the donor or recipient is seropositive, late-onset infection may occur after prophylaxis is discontinued, and has been identified in 17 to 37% of CMV D + /R- recipients.¹⁵⁻¹⁸ Late-onset infection usually occurs in the first year after transplant,^{15,19-21} but can sometimes occur much later.²² The late-onset disease is associated with mortality and graft loss.^{19,23}

Clinical Manifestations

CMV infection after transplant can lead to asymptomatic infection or life-threatening disease. Some patients develop what is termed "CMV syndrome," a nonspecific presentation characterized by fever and myelosuppression in association with CMV viremia.¹¹ CMV also causes tissue-invasive disease, including the most common manifestation in SOT recipients, enteritis.^{14,24} This is characterized by symptoms, such as abdominal pain, nausea, and diarrhea with endoscopically identified gastrointestinal (GI) lesions and identification of CMV in a GI tissue specimen.¹¹ In addition, CMV pneumonitis can be a particularly severe disease with a high mortality, and it most commonly occurs in allogeneic HCT recipients and lung transplant recipients.²⁵ Pancreatitis, retinitis, nephritis, hepatitis, and encephalitis are additional manifestations of CMV infection that may occur in immunocompromised hosts.²⁶ The transplanted allograft may become infected,²⁷ possibly due to dysregulation of the immune response in the graft and/or the fact that the graft can be a reservoir for the virus.²⁷

CMV infection has been associated with increased mortality in transplant recipients,^{13,19,22,28-30} both due to direct tissue damage as well as immunomodulatory effects.⁸ CMV interacts with the host immune system in a complex manner. It can induce inflammatory cytokines and upregulate major histocompatibility complex antigens and proinflammatory adhesion molecules, and this may enhance immunogenicity of the organ.^{7,27,31} This is a potential mechanism for the acute and chronic rejection and long-term graft dysfunction associated with CMV infection.^{10,19,31-41} Bronchiolitis obliterans syndrome (BOS), a form of chronic rejection in lung transplant recipients, has been associated with CMV infection,⁷ and CMV viremia in the first 6 months after lung transplant has been linked to a significantly higher risk of BOS.⁴² The detection of CMV nucleic acids in bronchoalveolar lavage (BAL) fluid has also been identified as a risk for BOS by some,⁴³ but not all investigators.⁴⁴ CMV disease has also been associated with cardiac allograft vasculopathy in heart transplant recipients.⁴⁵ The virus can elicit inflammatory responses that damage cardiac allograft endothelial cells in animal models and result in thickening of the intima,⁴⁶ a process that can be prevented by the administration of ganciclovir.³¹ Furthermore, cytokines and growth factors triggered by episodes of acute rejection can activate the expression of CMV, potentially leading to amplification of both processes.^{31,32} Finally, the augmented immunosuppression used when treating rejection may lead to CMV reactivation and disease.^{14,47}

CMV also appears to impair immune responses of the host, as it is an independent risk factor for secondary bacterial and fungal infections and EBV-related posttransplant lymphoproliferative disorder (PTLD).^{14,48-51} CMV has also been associated with recurrent liver disease due to hepatitis C in liver transplant recipients,⁵² new-onset diabetes mellitus after transplantation⁵³ and hepatic artery thrombosis after liver transplantation.⁵⁴

Diagnosis

The most frequently used method for diagnosing CMV infection is quantitative nucleic acid testing (QNAT) via polymerase chain reaction (PCR) assays.^{55,56} QNAT can be used to rapidly detect infection, monitor response to antiviral therapy, assess severity of infection and the likelihood of tissue invasive disease, since higher viral loads correlate with risk of tissue-invasive disease.^{57,58} Due to differences in quantitative methods between laboratories, there are no established viremia thresholds above which it is agreed treatment should be initiated.^{8,59} However, a World Health Organization CMV international standard has been developed to calibrate assays for consistent viral load reporting.⁵⁹ Identifying a rapidly increasing viral load is more helpful in predicting disease than any single value,⁵⁸ and changes in viral loads of < 0.5 log₁₀ copies/mL are not considered significant variations.⁶⁰

PCR assays for CMV viremia may be less sensitive in patients with localized tissue-invasive disease such as enteritis; in one review of studies reporting transplant recipients with GI disease due to ganciclovir-susceptible CMV, viremia was detected in only 44 to 75% of the cases.⁶¹ Therefore, CMV

disease cannot be excluded by negative QNAT, and endoscopy and biopsy may be required to establish the diagnosis in patients with compatible clinical syndromes. In fact, the gold standard of diagnosis of tissue-invasive CMV disease is biopsy, with the appearance of “owl’s eye” viral inclusion bodies, viral antigen staining by immunohistochemical methods and/or the detection of viral nucleic acids in specimens confirming the diagnosis.²⁷ Tissue culture can be useful if positive, but is slower and less sensitive than molecular assays.⁶² Identifying CMV in BAL fluid in lung transplant recipients may be a sign of asymptomatic viral replication rather than indicative of tissue-invasive disease, but quantitative assays may be more specific for diagnosing disease.^{63–66}

The pp65 antigenemia test detects viral antigen in peripheral white blood cells. Higher levels of blood pp65 antigenemia have been correlated with disease.⁶⁷ However, the test is labor and time intensive, does not perform well in patients with neutropenia, and is less sensitive than QNAT at lower viral load ranges.^{8,57,58,68,69} Therefore, most centers use QNAT for diagnosis of CMV infection.⁷⁰ Testing for antibody responses to CMV is not recommended for diagnosing transplant-related CMV infection as it takes time for antibodies to develop after infection, and antibody responses may be impaired in immunocompromised individuals.^{26,27,71} Furthermore, CMV IgM assays are known to lack specificity, with frequent false-positive reactions.⁷²

Risk Factors

The most important predictor of developing CMV infection or disease in solid organ transplantation is the CMV serostatus of the donor–recipient pair; the highest risk of developing CMV disease occurs when a CMV-seronegative recipient receives an organ from a seropositive donor (CMV D + /R –).^{10,73,74} CMV IgG testing is performed routinely on organ donors and recipients before transplant to stratify the risk of the recipient and inform the prophylaxis strategy. Approximately 20% of solid organ transplantation procedures performed in the United States occur in high-risk serodiscordant pairs.⁷⁵ For HCT recipients, CMV-seropositive recipients of grafts from seronegative donors have been noted to be at higher risk from CMV disease and death compared with recipients of grafts from seropositive donors, presumably because the latter type of recipient receives CMV-specific donor CD4+ and CD8+ T cells which can help contain infection.^{76,77} However, the results of studies of CMV-related outcomes in CMV-mismatched donor–recipient HCT pairs are inconsistent.⁷⁸ Other risk factors for CMV infection in HCT recipients include umbilical cord blood transplantation, receipt of T cell-depleted stem cells, graft-versus-host disease (GVHD), total body irradiation, and fludarabine-containing chemotherapy regimens.⁷⁹ CMV-seronegative transplant recipients receiving allografts from seronegative donors are at the lowest risk for CMV disease after transplantation and they should receive leukoreduced and/or CMV-seronegative blood products.^{27,80}

The level of host immunosuppression is an important risk factor for CMV infection. Transplant recipients who receive antilymphocyte antibodies, such as thymoglobulin or alemtuzumab, or those receiving high-dose corticosteroids for

treatment of rejection are at an increased risk of CMV infection and disease.^{24,47,57,81} Comorbidities can also enhance risk as can the type of organ transplanted, with lung and small intestine allograft recipients at highest risk among SOT recipients, perhaps due to the amount of lymphoid tissue in the organs and the intensity of immunosuppression.²⁷

Finally, certain host genetic factors have also been shown to confer variable risks for CMV infection.^{82–84} Polymorphisms in genes of the innate immune system, including those for Toll-like receptors and mannose-binding lectin^{83,85,86} have been shown to affect the risk for CMV in organ transplant recipients. Deficiencies in CMV-specific T-lymphocyte responses⁸⁷ and hypogammaglobulinemia after transplantation⁸⁸ have also been identified as risk factors for CMV disease.

Prognosis and Therapy

The standard of care for treatment of CMV infection and disease is intravenous (IV) ganciclovir or its oral prodrug, valganciclovir.²⁷ The mechanism of action for ganciclovir and valganciclovir, like that of the other drugs approved for CMV treatment, foscarnet and cidofovir, is through inhibition of viral DNA polymerase activity.⁸⁹ Treatment dosing for IV ganciclovir is 5 mg/kg twice daily with a duration of 2 to 4 weeks, but longer therapy may be required, depending on the decline in viremia and resolution of symptoms.⁹⁰ Valganciclovir is dosed 900 mg orally twice daily and both ganciclovir and valganciclovir should be dose-adjusted for renal impairment. The equivalence of IV ganciclovir and oral valganciclovir for the treatment of mild-to-moderate CMV infection and disease in SOT recipients has been demonstrated in a multicenter, randomized trial comparing the two therapies in 321 SOT recipients.⁹⁰ Valganciclovir demonstrated a rate of viral clearance at 21 days similar to that of IV ganciclovir with comparable side effects. Also, there were no differences in long-term outcomes at 1 year of follow-up.⁹¹ Of note, patients were excluded if they had a life-threatening CMV disease and median initial viral loads were relatively low, < 20,000 copies/mL. In this study, most patients in each arm of the trial were viremic for longer than 21 days, demonstrating that treatment of CMV infection may need to be prolonged. Treatment should last at least 2 weeks and continue until viremia has resolved.^{27,80} Low pretreatment CMV viral loads have been correlated with more rapid disease resolution with antiviral treatment.⁵⁵ Intravenous ganciclovir is recommended over valganciclovir for patients with impaired GI absorption, those with questionable compliance, or those with life-threatening disease.^{27,80} Oral ganciclovir can prevent CMV disease, but neither it nor acyclovir is recommended for the treatment of CMV.^{27,80} Because of their toxicities, particularly nephrotoxicity, foscarnet and cidofovir are reserved for failure or intolerance of ganciclovir or valganciclovir. Reduction of immunosuppression should be considered in patients with moderate-to-severe CMV disease.^{27,80}

CMV recurs in 25 to 30% of SOT recipients after treatment, and relapse is associated with longer time to viral clearance.^{91–93} The best predictor of relapse of CMV is detectable

CMV viremia at the time antiviral therapy is discontinued,⁹¹ so treatment should be continued with weekly monitoring until viremia is resolved.^{27,80} The benefit of intravenous immune globulin (IVIG) or CMV immune globulin as adjuncts to antiviral therapy has not been established, but could be considered, particularly in cases of CMV pneumonitis or other severe disease due to CMV.^{27,80,94} A 1 to 3 month course of secondary prophylaxis is often administered to SOT recipients after therapy is complete, but close monitoring of symptoms and viral loads is an acceptable alternative.^{27,80,93}

Ganciclovir-resistant CMV is uncommon, but is more likely to occur among lung transplant recipients and CMV D + /R− transplant recipients with an incidence of 5 to 10%,^{95–98} and in those who have received prolonged low doses of antiviral prophylaxis.⁹⁶ Resistance typically occurs as a result of a mutation in the viral *UL97 kinase* gene, which is required to phosphorylate ganciclovir and make it active.⁹⁷ Resistance is less commonly due to mutation in the *UL54 CMV DNA polymerase* gene, which incorporates ganciclovir triphosphate into the DNA resulting in termination of viral replication.⁹⁷ Foscarnet remains active against UL97 mutants, and cidofovir may also be a viable treatment option as neither requires phosphorylation by UL97 for activity.^{8,27,97} Certain mutations in UL97 may not result in clinical resistance to ganciclovir, and low-level ganciclovir resistance can sometimes be overcome with increased doses of ganciclovir, up to 10 mg/kg twice daily.^{27,80} Mutations in UL54 are less common, but typically result in cross-resistance to foscarnet, cidofovir, and ganciclovir.^{8,27,97} Ganciclovir resistance should be suspected if there is not a significant decline in the level of CMV viremia after 2 weeks of appropriate treatment, particularly in patients who have received prolonged antiviral prophylaxis or treatment.^{27,80} Genotypic testing can confirm the presence of mutations that may confer clinical resistance.⁹⁷

Foscarnet, either alone or in combination with ganciclovir, can be effective in the treatment of ganciclovir-resistant CMV.^{15,99} Foscarnet is very active against CMV, but is considered a second-line agent due to its nephrotoxicity. Cidofovir is another treatment option but is also nephrotoxic. An important adjunctive maneuver in treating CMV is reducing the level of immunosuppression.^{27,80,100} Switching to a mammalian (or mechanistic) target of rapamycin [mTOR] inhibitor such as sirolimus (rapamycin) or everolimus may be helpful, as lower rates of CMV infection have been noted with these agents.¹⁰¹ CMV immunoglobulin or IVIG may also be considered as they could bolster host defenses.^{27,80}

Ganciclovir-resistant CMV infections have been associated with high rates of treatment toxicity, relapsed CMV infection, and mortality,⁹⁸ and there is a clear need for novel, nontoxic anti-CMV agents, particularly ones with activity against resistant strains. Medications currently being investigated for treatment of CMV include maribavir, leflunomide, cyclopropavir, synguanol, letermovir (AIC246), and artesunate.^{8,102–108} In addition, brincidofovir is a lipid conjugate derivative prodrug of cidofovir with broad activity against double-stranded DNA viruses, including CMV, and it has been used in small series to successfully treat refractory or resis-

tant CMV infections.^{109,110} It has enhanced potency compared with cidofovir and no nephrotoxicity or myelosuppressive effects.¹¹¹ Cytotoxic T-cells active against CMV can be engineered and have been employed to help overcome CMV infection in immunocompromised hosts, although this type of therapy remains under development and is not yet widely available.^{112,113}

Prevention

If CMV prophylaxis is not administered to SOT recipients at risk, CMV infection and disease may occur within the first 3 to 4 months after transplant.^{114,115} Antiviral therapy to prevent CMV is therefore recommended for CMV D + /R− and CMV R+ SOT recipients.^{28,80} Prophylaxis can prevent CMV disease^{10,12,20,28,116} and in some studies, protects against rejection, graft dysfunction, and graft loss.^{10,36,45,117} In addition, a study of over 61,000 adult recipients of deceased donor kidney allografts demonstrated that CMV prophylaxis of D + /R− renal transplant recipients was associated with a significant decrease in cardiovascular deaths, particularly in those recipients ≥ 40 years of age.¹¹⁸

The two strategies generally employed for CMV prevention are universal prophylaxis and preemptive treatment.¹¹⁴ The former involves administering antiviral medication to all persons at risk (e.g., CMV D + /R− and R+), whereas the latter involves CMV testing at regular intervals (e.g., weekly) and starting antiviral therapy only when CMV is detected. Universal prophylaxis has the advantage of protecting against other herpesviruses, and it has been associated with a decreased risk for opportunistic processes such as PTLD, infection by *Pneumocystis jiroveci*, aspergillosis, and bacterial infections in SOT recipients.^{10,49,119,120} Preemptive therapy avoids the use of potentially toxic and costly medications, and may also allow exposure to CMV so that immunity develops and limits the later development of CMV disease.^{27,80,114} However, preemptive therapy is logistically difficult and the monitoring expensive, and this approach may not detect CMV infection before the onset of disease, particularly in CMV D + /R− SOT recipients. Most SOT programs internationally and in the United States favor universal prophylaxis^{70,100} although studies vary in outcome differences between the two options. Two meta-analyses have shown reduced CMV disease and allograft rejection with both strategies,^{4,116} with universal prophylaxis associated with fewer opportunistic infections and lower mortality in one study⁴ but similar mortality in the other.¹¹⁶ A more recent meta-analysis of 20 studies involving 2,744 SOT recipients showed a similar risk of CMV syndrome with the two approaches, but a higher risk of late-onset CMV for prophylaxis compared with preemptive therapy and no difference in graft loss, acute rejection, other opportunistic infections, or mortality.¹²¹ The Swiss Transplant Cohort Study of over 1,200 SOT recipients demonstrated similar rates of CMV disease with prophylaxis and preemptive strategies but improved graft survival with prophylaxis.¹²² The available randomized trials that compare universal prophylaxis and preemptive therapy have also shown similar efficacy for CMV disease prevention,^{36,123–125} but improved allograft survival with universal prophylaxis in

some studies.^{36,124} Antiviral resistance has been encountered with each strategy.^{27,95,126-128} Current CMV guidelines for SOT recipients recommend universal prophylaxis for D + /R- SOT recipients and either prophylaxis or preemptive therapy for R+ recipients.^{27,80} CMV D - /R- SOT recipients do not require CMV prophylaxis.^{27,80} Among HCT recipients, valganciclovir was not proven superior in preventing CMV disease, other infectious complications or death when compared with preemptive therapy in a randomized, double-blind trial, and more patients receiving valganciclovir required hematopoietic growth factors.¹²⁹

Valganciclovir 900 mg/day, oral ganciclovir 3 g/day, or IV ganciclovir 5 mg/kg/day are recommended for CMV prophylaxis in solid organ transplantation^{27,80} based on randomized clinical trials.^{12,16,18} In addition, valgacyclovir 8 g/day may also be used for renal transplant recipients only.^{10,27,80} Valganciclovir is most commonly used, including in liver and lung transplant recipients,^{70,100} despite not being U.S. Food and Drug Administration -approved for prophylaxis in those populations. At some centers, IVIG is used in combination with antiviral therapy for thoracic transplant recipients, though data are sparse.^{27,80,130-132} Use of low-dose valganciclovir prophylaxis (450 mg daily) is not recommended as it has been associated with breakthrough CMV infection and may also be associated with ganciclovir-resistant CMV infection.¹³³ CMV can occur in up to 80% of CMV-seropositive HCT recipients after allogeneic HCT but most HCT centers use preemptive therapy after HCT due to the myelosuppressive effects of ganciclovir and valganciclovir.⁷⁹

Newer agents have been studied for use in CMV prophylaxis. Maribavir at a dose of 100 mg orally twice daily was ineffective compared with oral ganciclovir for CMV prophylaxis in liver transplant recipients.¹³⁴ Similarly, maribavir was no more effective than placebo in preventing CMV disease in allogeneic HCT recipients.¹³⁵ However, letermovir, which has a novel mechanism of action against CMV, reduced the incidence of CMV infection in allogeneic HCT recipients compared with placebo and was well-tolerated.¹³⁶ Brincidofovir, an agent with a prolonged half-life, also appears to be a promising agent for CMV prophylaxis. A randomized trial of brincidofovir versus placebo in allogeneic HCT recipients has shown efficacy of brincidofovir in preventing CMV viremia and disease when dosed only twice weekly.¹³⁷ The results of a recently completed multicenter phase 3 trial in HCT recipients examining the efficacy of brincidofovir for CMV prevention have yet to be published.^a

The duration of antiviral prophylaxis for SOT recipients varies by transplant center and by organ and generally ranges from 3 to 6 months.^{27,70,80,100} As noted above, a concern is the development of late-onset CMV after prophylaxis is discontinued.^{16,18,21} Extended prophylaxis of 200 versus 100 days of valganciclovir in 316 CMV D + /R- renal transplant recip-

ients showed a significantly lower incidence of CMV disease at 12 months among those receiving 200 days of prophylaxis (16.1 vs. 36.8%, $p < 0.0001$) and a higher risk of opportunistic infections with 100 days of prophylaxis (27 vs. 13%, $p = 0.001$)¹⁴ and is recommended for these patients.^{27,80} Twelve versus 3 months of valganciclovir in lung transplant recipients significantly reduced the rate of CMV disease from 32 to 4% ($p < 0.001$) and CMV infection from 64 to 10% ($p < 0.001$)¹⁸ and is recommended particularly for CMV D + /R- lung transplant recipients but may also be used in R+ lung transplant recipients.^{27,80} Some have suggested even longer courses of prophylaxis in CMV D + /R- lung transplant recipients.¹³⁸ However, the toxicities and costs of prolonged prophylaxis need to be considered. Although supportive data are limited, a hybrid approach to prophylaxis is an option, particularly for patients at high risk of late CMV disease or those on augmented immunosuppression.^{80,139} This approach involves a period of prophylactic antiviral therapy followed by a period of monitoring for CMV viremia. Unfortunately, the sensitivity of monitoring for CMV infection after prophylaxis discontinuation, and its specificity in predicting disease are low.^{140,141}

Assays to measure CMV-specific immunity are under study.^{73,142,143} The QuantiFERON-CMV assay, Cellestis, Valencia, CA) is an enzyme-linked immunosorbent assay-based measurement of interferon-gamma secretion in response to CMV peptides and is the only commercially available test for assessing CMV-specific immunity. Additional study is needed to determine its utility and the test sensitivity is low in patients with lymphopenia, but the assay has been able to predict disease and may help with stratifying patient risks for CMV and guiding prophylaxis or preemptive treatment.^{73,80,142,144} Finally, while none is available for clinical use, CMV vaccines are in development, with some in phase II clinical trials¹⁴⁵⁻¹⁴⁸ and an ongoing phase III DNA vaccine trial.¹⁴⁹

Epstein-Barr Virus

Epidemiology and Prevalence

EBV, also known as HHV-4, is a double-stranded DNA gamma herpesvirus that infects more than 90% of adults worldwide, usually causing asymptomatic infection in immunocompetent individuals.¹⁵⁰⁻¹⁵³ Primary EBV infection has been shown to occur with a bimodal distribution.^{151,152,154,155} The first peak is between 2 and 4 years of age with a higher incidence among children in day care settings.¹⁵¹ The second peak occurs in adolescence and may be associated with higher socioeconomic groups that may have avoided early infection.^{151,152,154,155} Regardless, the primary route of infection is close salivary contact, although the virus has been detected in male and female genital secretions suggesting that sexual transmission may occur.^{150,156} The manifestations of EBV infection in immunocompromised hosts such as SOT or HCT recipients are wide-ranging, from asymptomatic infection to infectious mononucleosis to malignancy.^{150,157,158} As discussed further below, EBV is also associated with certain malignancies occurring in immunocompetent individuals.^{150,159}

^a Marty FM, Winston DJ, Chemaly RF, et al. Brincidofovir for prevention of cytomegalovirus (CMV) after allogeneic hematopoietic cell transplantation in CMV-seropositive patients: a randomized, double-blind, placebo-controlled, parallel-group phase 3 trial. *Biol Blood Marrow Transplant* 2016;22(3):S23

Given EBV's widespread prevalence and potentially devastating consequences in immunocompromised hosts, it is an important consideration in transplant medicine. After primary infection occurs, EBV establishes lifelong latency primarily in B lymphocytes (memory B cells), and to a lesser extent in T lymphocytes, and natural killer (NK) cells.^{150,158} The virus is shed in the saliva, hence its spread through close oral contact. EBV may replicate in squamous epithelial cells but not in the absence of B lymphocytes.¹⁵⁰ EBV also has the ability to transform B lymphocytes, and is associated with lymphomas, including Burkitt, Hodgkin, and immunoblastic lymphomas, as well as nonlymphoid malignancies including nasopharyngeal and gastric carcinomas.^{150,159-162} Among SOT and HCT recipients, PTLD is the most concerning EBV manifestation as it may lead to high-grade monoclonal lymphoma.¹⁵⁸ EBV can exploit normal B lymphocyte biology through complex immunomodulatory effects of EBV proteins, leading to the malignant proliferation of cells. For example, Epstein-Barr nuclear antigen-1 protein binds to viral DNA, allowing the EBV genome to be maintained in the B cell, and additional EBV proteins can function as oncogenes, blocking differentiation and facilitating lymphocyte proliferation.^{150,159,163} The importance of viral and cellular micro-RNAs in promoting EBV oncogenesis has also been recently noted.^{159,164} The immune response to EBV infection is mediated by NK cells and cytotoxic CD4 and CD8 T lymphocytes.^{150,165} With anti-T cell immunosuppression after transplant, EBV-infected B lymphocytes can proliferate with impunity. The polyclonal proliferation may transform to monoclonal proliferation that develops into a lymphoma.^{150,159,166} In SOT recipients, the source of the EBV is usually reactivation from the recipient,¹⁶⁷⁻¹⁶⁹ although PTLD that occurs early posttransplant is more likely to be of donor origin.¹⁷⁰ In HCT, the source of EBV is usually from the donor.^{171,172} Among SOT recipients, the highest rate of PTLD is in the first year after transplant, although more recent data suggest that this rate may be decreasing and that the onset of PTLD is getting later post-SOT.^{158,173,174} Recent data among HCT recipients show a median time to development of PTLD ranging from 2 to 6 months post-HCT.^{171,174,175}

Clinical Manifestations

Initial infection in young children is usually asymptomatic, while acute infection in immunocompetent young adults more often presents as a mononucleosis syndrome, with fever, generalized malaise, lymphadenopathy, sore throat, myalgia, and GI symptoms.¹⁷⁶ In immunocompromised individuals, EBV infection may be asymptomatic or the disease spectrum can range from a mononucleosis syndrome to lymphoid interstitial pneumonitis to PTLD.¹⁵⁸ PTLD is a heterogeneous spectrum of lymphocyte proliferation disorders comprising more than 20% of malignancies after transplant.^{158,177} Although EBV can cause a polymorphic lymphoid hyperplasia, an aggressive monomorphic lymphoma with gene rearrangements may occur.¹⁷⁸ Most PTLD lesions are of B cell origin and are EBV-positive; EBV-negative PTLD more often occurs years after transplant.¹⁷⁹ While potentially any organ can be affected by PTLD, pulmonary or intrathoracic

PTLD is common, particularly among lung transplant recipients who develop PTLD early after transplant.¹⁸⁰

Nonmalignant pulmonary manifestations of EBV primary infection or reactivation are uncommon, but may occur in immunocompromised patients, and asymptomatic pneumonia is seen in 5 to 10% of patients with mononucleosis.¹⁸¹ Rapidly progressive pneumonia and BOS have been described after SOT in association with EBV infection.¹⁸² In addition, some have reported EBV reactivation in pleural fluid and suggested a role for EBV in the development of idiopathic pleural effusions, particularly in immunosuppressed patients.^{183,184} An additional respiratory tract condition associated with EBV infection in SOT recipients is laryngeal smooth muscle tumors.^{185,186}

Diagnosis

In immunocompetent patients, EBV infection is typically diagnosed by detection of anti-EBV antibodies but, as with CMV diagnosis, antibody tests are unreliable for diagnosis of primary EBV infection or PTLD in immunocompromised individuals due to impairment in humoral responses to infection.¹⁵⁸ However, EBV serologic testing is useful in

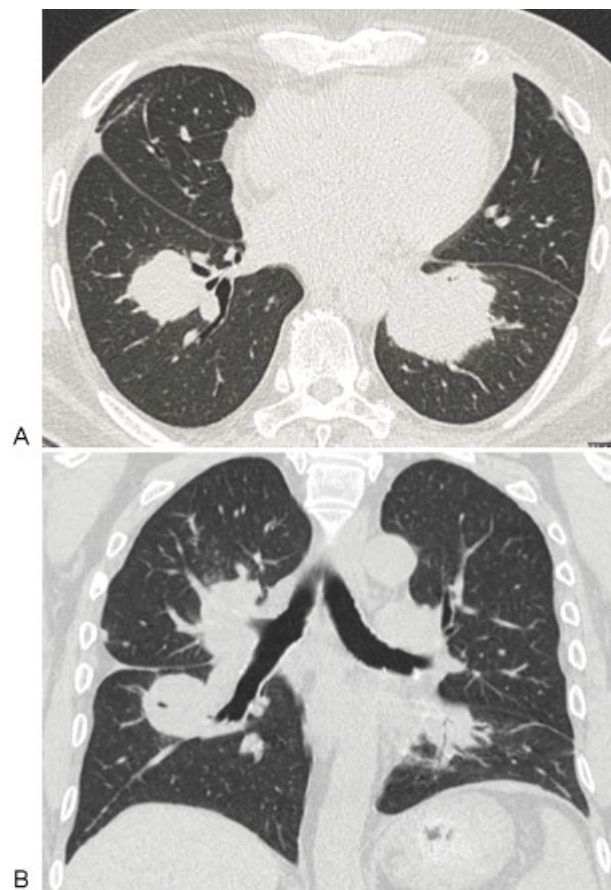


Fig. 1 A 60-year-old male patient presenting 6 months postbilateral lung transplant with dyspnea and wheezing. Chest CT (A = axial, B = sagittal sections) showed three mass-like densities in the right suprahilar, right infrahilar, and left infrahilar regions. Biopsy confirmed posttransplant lymphoproliferative disorder, monomorphic diffuse large B-cell type. EBV-EBER in situ hybridization was positive in many large neoplastic lymphocytes. CT, computed tomography; EBER, Epstein-Barr encoding region; EBV, Epstein-Barr virus.

stratifying a transplant recipient's risk of EBV infection and PTLD, as discussed further below. QNAT is often used to quantify EBV viral loads in the blood and assist in diagnosing EBV infection and PTLD, although the variation in QNAT assays used by different centers and lack of a universally recognized cutoff to assess the clinical significance can make test results difficult to interpret.¹⁷⁹ EBV QNAT assays are sensitive for detecting infection, but have limited specificity in terms of predicting PTLD.¹⁸⁷ In addition, as mentioned above, not all PTLD is EBV-related. BAL fluid with EBV detected has been reported as a more sensitive marker for identifying PTLD in pediatric lung and heart-lung transplant recipients than peripheral blood EBV PCR.¹⁸⁸

Radiographic imaging of EBV pneumonia resembles that of other viruses on computed tomography. Findings include reticular opacities, small nodules, or consolidation of one or more lobes.¹⁸¹ In cases of PTLD involving the thoracic region, plain radiographs or computed tomography (CT) images typically show single or multiple lung nodules or masses, infiltrates, adenopathy, or pleural effusion (→Fig. 1).¹⁸⁹ Positron emission tomography combined with CT may be more sensitive than CT alone in identifying PTLD.¹⁹⁰ Excisional biopsy can provide a reliable diagnosis if imaging has indicated a suspicious lesion, particularly in the setting of sustained EBV viremia.

Risk Factors

Several factors increase the likelihood of developing PTLD or reactivation of EBV. The impaired T cell function associated with the use of antirejection medications after transplantation or with HIV infection increases risk, and the degree of immunosuppression has significant impact on the magnitude of risk.^{158,166,191} Other risk factors include the transplant recipient age, with children at higher risk than adults, EBV serostatus, and type of organ transplanted.^{158,192} The incidence of PTLD is highest in haploidentical HCT, heart-lung and multivisceral transplantation (up to 20%), followed by liver (4.5%), heart and lung (2.5%), pancreas (2%), kidney (1–1.5%), and matched HCT (0.5–1%).¹⁷² Receipt of antithymocyte globulin (ATG) and other T cell depleting therapies increase risk^{192,193} as well as an HLA mismatch in HCT recipients.¹⁹⁴

Prognosis and Therapy

There are no large controlled trials to guide the management of severe EBV manifestations.¹⁵⁸ For PTLD, the most dire manifestation of EBV infection posttransplant, the primary treatment is a reduction in immunosuppression, which carries the risk of graft dysfunction or loss¹⁹⁵ and incomplete tumor response.¹⁹⁶ Therefore, surgical resection, local radiation, and pharmacologic therapy are other modalities that may be required.^{158,197,198} The role of antiviral therapy is unclear as there is limited evidence supporting its use, particularly in the absence of other therapeutic maneuvers.¹⁵⁸ Most EBV-infected cells within PTLD lesions are not undergoing lytic EBV DNA replication, the target for antiviral activity.¹⁹⁹ When antiviral treatment is used, ganciclovir is preferred to acyclovir given the

former's superior *in vitro* activity against EBV.^{158,200,201} Among patients with CD20+ PTLD, the use of rituximab, a monoclonal antibody that targets CD20, has been shown to achieve high rates of remission and improved 3- and 5-year survival rates.^{202–205} Treatment is generally well-tolerated, but the addition of chemotherapy may be required to prevent relapse, depending on specific risk factors.¹⁵⁸ Finally, adoptive transfer of EBV-specific cytotoxic T cells has been tried to both treat and prevent PTLD.^{206–209} The results are most promising for preemptive therapy,²⁰⁶ but this process is complex and few centers have the ability to perform this type of adoptive immunotherapy.

There have been several reports of regression of PTLD after changing immunosuppression to an antiproliferative agent such as sirolimus,^{210–213} although data are limited as to the relative benefits of reduction of immunosuppression compared with using sirolimus to exploit its potential antitumor activity.^{211,213} Supporting the use of sirolimus are reports of mTOR inhibitors preventing replication of EBV in cell lines via inhibition of cell cycle progression and interleukin (IL)-10 production, an important stimulator of EBV-related tumors.²¹⁴

For smooth muscle tumors, surgical resection is an option if there are limited numbers of tumors. However, when there are multiple tumors, surgical resection may be insufficient. In addition, these tumors are usually refractory to chemotherapy, particularly in individuals with AIDS, and mTOR inhibitors might be useful in such cases.¹⁸⁵

Prevention

Prophylactic use of antiviral therapy is not recommended for prevention of EBV reactivation or PTLD given the limited data supporting this practice.^{158,215,216} In a very small study, Höcker et al prospectively compared ganciclovir or valganciclovir prophylaxis ($N = 20$) to no prophylaxis ($N = 8$) in EBV-seronegative pediatric renal transplant recipients with EBV-seropositive donors.²¹⁷ EBV primary infection occurred in 45% of antiviral recipients compared with 100% of controls ($p < 0.0001$). However, additional data are needed to fully assess the efficacy of this approach. IVIG, including CMV immune globulin, has also been studied as a prophylactic agent for PTLD, but the data are inconclusive for this approach as well.^{215,218–220}

On the other hand, preemptive antiviral therapy may reduce the risk of PTLD, particularly in children.^{179,217,221–224} Hierro et al demonstrated that among 47 pediatric liver transplant recipients with detectable EBV DNA, an undetectable EBV viral load was achieved among almost half of patients with valganciclovir alone, largely without reduction in immunosuppression, and no new PTLD cases were seen.²²³ In a similar population, Venturi et al reported partial or complete response to 30 days of ganciclovir in 64% of cases with an inverse correlation between QNAT viral load and ganciclovir serum concentration.²²⁴ Among HCT recipients, rituximab has been used preemptively when high levels of EBV are detected by QNAT, and found to prevent approximately 90% of EBV-associated PTLD.²⁰⁹ However, there is no definitive

threshold of EBV viremia identified at which preemptive therapy is optimal. Patients at an increased risk for EBV reactivation and PTLD (e.g., seronegative SOT recipients of organs from seropositive donors and those receiving T cell depleting therapies such as ATG) should be closely monitored for clinical signs and symptoms of PTLD.¹⁵⁸

Herpes Simplex Viruses 1 and 2

Epidemiology and Prevalence

Herpes simplex virus type 1 (HSV-1) and herpes simplex virus type 2 (HSV-2) are common infections worldwide. In the United States, the seroprevalences of HSV-1 and HSV-2 are 58 and 17%, respectively.²²⁵ Transmission of these viruses is by direct contact with infected skin or infected secretions. Transmission can occur during periods of subclinical viral shedding, when symptoms are absent.²²⁶

Clinical Manifestations

Among immunocompetent adults, both HSV-1 and HSV-2 cause a variety of infections that involve mucocutaneous surfaces. Syndromes overlap, but HSV-1 typically causes orolabial herpes, while HSV-2 causes anogenital disease.²²⁷ Both syndromes are characterized by painful, ulcerating vesicles of the skin and mucous membranes of the affected region. After primary infection, HSV-1 and HSV-2 establish latent infection of sensory ganglion neurons.²²⁸ Reactivation of latent virus leads to recurrent mucocutaneous disease.^{229,230} Severe HSV-1 or HSV-2 disease is uncommon in immunocompetent adults. However, important neurologic syndromes, including Bell palsy, meningitis, and encephalitis can occur and are associated with significant morbidity and mortality.²³¹

Immunocompromised patients with HSV disease most commonly develop one of the mucocutaneous syndromes described above. Most infections in immunocompromised patients represent reactivation, and recurrences are often more frequent, more extensive, and of longer duration than in immunocompetent patients.²³²

The immunocompromised host is also at risk for both local extension of disease (e.g., HSV esophagitis) and disseminated infection. Although HSV is not considered a respiratory virus, the oropharyngeal HSV disease can extend to the lower respiratory tract, either by contiguous spread or by aspiration.²³³ The lower respiratory tract disease can present as tracheobronchitis or pneumonia and manifest as fever, cough, dyspnea, bronchospasm, and/or chest pain.²³³⁻²³⁵ Tracheobronchitis may be complicated by airway ulceration and hemorrhage. The most common radiographic findings reported with HSV pneumonia include bilateral symmetric ground glass attenuation, although consolidation has also been described.²³⁶ Disseminated HSV infection with involvement of noncontiguous visceral organs is associated with very high mortality, especially with HSV hepatitis.²³⁷ HSV hepatitis commonly presents with fever, transaminitis, hyperbilirubinemia, thrombocytopenia, and abdominal pain.²³⁷ HSV viremia is associated with visceral involvement and

increased mortality. Among a series of intensive care unit patients, HSV viremia had a high incidence of pneumonia (38%), hepatitis (15%), and death within 20 days (27%).²³⁸

Diagnosis

Mucocutaneous HSV lesions, including esophageal or tracheobronchial ulcerations viewed endoscopically, are often diagnosed based on their characteristic appearance. Scrapings or biopsies of lesions can be tested for HSV by viral culture or direct immunofluorescence assays (DFA), though a combined approach may have the highest diagnostic yield.²³⁰ Sampling early vesicular lesions is optimal; such lesions should be unroofed and scraped for culture or DFA. PCR-based identification of viral genomic material is both more sensitive and rapid than viral culture, and can be performed on blood or cerebrospinal fluid; CSF testing for HSV DNA is the gold standard for suspected herpes encephalitis.^{239,240}

HSV pneumonia is difficult to diagnose due to the lack of specificity of symptoms, radiological features, and detection of HSV in the airway.²³³ Historically, the diagnosis was often based upon autopsy findings.²³³ HSV can be detected in clinical respiratory specimens by viral culture or PCR-based techniques, but the isolation of HSV from BAL fluid does not necessarily indicate true disease. Asymptomatic HSV-1 viral shedding in the lower respiratory tract is relatively common, especially in critically ill and immunocompromised patients.²⁴¹ It is suggested that a higher HSV viral load in BAL fluid is associated with a worse outcome and with pneumonitis,²⁴¹ but a causative association has not been proven.²³³ Bronchoscopy does allow direct observation for signs of tracheobronchitis, but bronchoscopic examination can also be normal.²³³ Overall, HSV is considered to be an uncommon cause of pneumonia, even in immunocompromised patients. In one series of 63 immunocompromised patients diagnosed with pneumonia, HSV was determined to be the leading cause in 2 patients (3%).²⁴²

Prognosis and Therapy

For severe HSV infections or when absorption of oral medications may be impaired, intravenous acyclovir should be used for treatment.^{243,244} Oral valacyclovir, a prodrug of acyclovir, and famciclovir, a prodrug of penciclovir, exhibit superior oral bioavailability and can be used to treat limited HSV disease with simpler dosing regimens as compared with oral acyclovir.^{243,245} Acyclovir resistance is uncommon, but can be encountered among immunocompromised patients, and may occur in the setting of multiple courses of acyclovir for recurrent disease.^{246,247} Such strains are also famciclovir/penciclovir resistant, but can be treated with foscarnet or cidofovir.^{243,245} Topical cidofovir has been used successfully to treat acyclovir-resistant mucocutaneous HSV infection in immunocompromised persons, thus avoiding the nephrotoxicity of systemic therapy.²⁴⁸

Prevention

Chronic suppressive therapy should be considered in patients with a history of HSV infection, particularly if episodes are

recurrent.²⁴⁷ In addition, HSV-seropositive transplant recipients are given antiviral medication to suppress HSV around the time of transplant (typically for 1 month) even if they have not had symptomatic episodes in the past.²⁴⁷ Oral acyclovir or valacyclovir can be used, but most SOT recipients are administered valganciclovir for prophylaxis against CMV, and since this drug is also active against HSV, additional suppressive therapy directed at HSV is unnecessary.²⁴⁷ Immunosuppressed HSV-seronegative persons should be made aware of the risks of acquiring HSV infection and should avoid contact with persons who have active HSV lesions, although, as noted above, infection can also be acquired from asymptomatic persons.²⁴⁷ Daily antiviral therapy taken by an HSV-infected person is effective at preventing transmission to uninfected partners²⁴⁹ and is an option for serodiscordant couples.

Varicella-Zoster Virus

Varicella-zoster virus (VZV) is one of the most common opportunistic infections among hematopoietic stem cell transplant (HSCT)^{250,251} and SOT recipients.^{252–255} Primary varicella infection causes chickenpox, a febrile illness accompanied by a diffuse cutaneous vesicular exanthem.^{256,257} The course is usually self-limited, but immunocompromised hosts can rarely develop severe pneumonia, encephalitis, or visceral disease.^{256,258} Following resolution of the initial infection, VZV establishes latency within sensory ganglia.^{257,259} Reactivation of latent VZV may occur in individuals with impaired immunity and gives rise to stereotypical dermatomal vesicular skin lesions, termed herpes zoster (HZ) or “shingles.”^{250,257,259} Widespread cutaneous dissemination and visceral involvement can also occur in immunocompromised patients, but respiratory involvement is uncommon.^{250,260,261}

Epidemiology and Prevalence

Primary VZV infection in adults is unusual as more than 90% of adults in the United States are seropositive.^{251,257,258} HZ occurs in more than 1 million patients annually and the lifetime attack rate is 10 to 30%.^{257,259} The incidence of HZ increases with age, rising to 10 cases per 1,000 patient-years by age 75.^{257,259}

Patients with impaired cell-mediated immunity are at particularly high risk of HZ.^{250,257,259} The incidence of HZ (per 1,000 person-years) was 29.4 among HIV-infected individuals compared with 2.0 cases among HIV-seronegative controls.²⁶² Data from the Veterans Affairs health care system cited an incidence rate among 1,107 SOT recipients of 22.2 per 1,000 patient-years.²⁵² The risk of VZV infection reflects the intensity of immunosuppression and VZV serological status. Among SOT recipients, incidence rates are as follows: renal 3 to 10%^{252,254,263,264}, liver 5.7 to 12%^{263,265,266}; heart 6 to 16.8%^{252,263,267}; and lung 12.5 to 20.2%.^{255,263,268} The highest rates of VZV infections have been reported among HSCT recipients (23–67%).^{250,251,269} In one study of HSCT recipients, the incidence of HZ was 175 cases per 1,000 person-years, with cumulative incidence rates at 27% at 1 year; 36% at 2 years; and 44% at 3 years.²⁵¹

Clinical Manifestations

With primary VZV infection, pneumonia is a rare but potentially serious complication, with an estimated incidence of 2.3 in 400 cases.²⁷⁰ In contrast to HSV, involvement of the lungs occurs via the bloodstream rather than by local extension.²⁷¹ Typically, VZV pneumonia presents within 7 days of the onset of rash, but respiratory symptoms may precede rash.^{272,273} Among immunocompromised hosts, pneumonia is more common and may be more severe.^{274,275} Symptoms of VZV pneumonia include cough and dyspnea, and in severe cases hypoxemia, fulminant respiratory failure and death can occur. Classic chest radiographic manifestations of VZV pneumonia include diffuse interstitial nodular opacities that are often more severe than expected for the degree of clinical symptoms.^{272,275}

The majority of HZ infections are limited to vesicular cutaneous lesions in a single dermatome, even in immunocompromised patients.^{251,257,265} Dissemination with the involvement of noncontiguous dermatomes occurs in up to 10% of HSCT recipients.²⁵¹ However, visceral involvement, including respiratory tract involvement, and fatalities are rare (< 2%).^{250,255,261} Rarely, immunocompromised patients may present with visceral involvement in the absence of cutaneous lesions of HZ.²⁷⁶

Diagnosis

The diagnosis of primary VZV or HZ is often established clinically, but laboratory studies may be confirmatory.^{251,257} Direct detection methods, such as DFA, are more rapid and more sensitive than viral culture.²⁵⁷ VZV may also be detected by PCR in blood or tissue.²⁵⁷ PCR testing of serum or blood may be helpful in the immunocompromised patient who has visceral disease before the appearance of cutaneous lesions.²⁷⁶

Prognosis and Therapy

Acyclovir (oral or IV), valacyclovir, or famciclovir are the preferred agents for VZV infections.^{250,251,259,277} Ganciclovir and valganciclovir display excellent in vitro activity against VZV and can be used.²⁵³ Acyclovir resistance may occur,²⁷⁸ particularly with prolonged use.²⁵⁶ Foscarnet may be effective as salvage therapy for acyclovir-resistant VZV,^{279,280} but resistance to foscarnet may also develop.²⁸¹

Prevention

Prophylaxis with acyclovir or valacyclovir is effective in high risk immunosuppressed patients.^{253,282–285} In one study of 263 cases of SOT recipients treated with oral valacyclovir for 1 year posttransplant, no cases of VZV infections were observed.²⁵³

A live attenuated VZV vaccine (Oka strain; Zostavax Merck & Co., Inc., Kenilworth, NJ) has been shown to reduce the frequency and severity of VZV infections and postherpetic neuralgia in elderly adults and at-risk populations.^{286–288} This vaccine was designed to stimulate waning immunity in the elderly and is distinct from the varicella vaccine (Varivax Merck & Co., Inc., Kenilworth, NJ) used to immunize seronegative persons, as the latter contains 10 to 12-fold less virus.^{282,289,290} However, live

viruses are generally contraindicated in immunosuppressed individuals.^{288,291,292} Therefore, society guidelines recommend vaccination for varicella or herpes zoster before transplant,^{291,292} as long as there is at least 4 weeks between administration of a live vaccine and the initiation of highly immunosuppressive therapy.²⁹¹

Human Herpesvirus-6

Epidemiology and Prevalence

HHV-6, first isolated in 1986 from the peripheral blood mononuclear cells (PBMCs) of six adults with lymphoproliferative disorders,²⁹³ is classified in the β -herpesvirus subfamily, genus Roseolovirus, and is closely related to CMV.²⁹⁴ HHV-6 exhibits tropism for CD4 lymphocytes, endothelial cells, and the central nervous system.²⁹⁴ HHV-6 is a ubiquitous virus that infects > 80% of children by 3 years of age,^{295–298} and > 90% adults are seropositive.^{299,300} Two subtypes (A and B) exist; HHV-6B accounts for > 98% of HHV-6 infections in the United States, Japan, and Western countries,^{294,301} whereas HHV-6A predominates in sub-Saharan Africa.³⁰² HHV-6A is more neurotropic than HHV-6B.²⁹⁴

HHV-6 is the only HHV known to integrate into the germline.³⁰³ The complete HHV-6 genome may integrate into the telomeres of host cell chromosomes and be vertically transmitted.³⁰³ This condition, chromosomally integrated HHV-6, is present in approximately 1% of the populations of the United States and United Kingdom and results in very high viral loads (exceeding 5.5 log₁₀ copies/mL) which are typically asymptomatic.^{303,304} This condition must be discerned from HHV-6 primary infection or reactivation which may result in the manifestations described below.

Clinical Manifestations

Primary HHV-6 Infection

In 1988, Yamanishi et al implicated HHV-6 as the cause of roseola (exanthema subitum) or sixth disease in children.³⁰⁵ In 1989, HHV-6 was isolated from PBMCs from 100% (26/26) of infants with roseola during the first 3 days of fever; the rate of viral isolation fell to 17% by day 5 to 7 and 0 by day 8.³⁰⁶ Subsequent studies demonstrated that primary infection with HHV-6 was a common cause of acute febrile illness (with or without skin rash) in infants and young children.^{307–310} In a prospective study of 243 acutely ill children < 2 years old who presented to an emergency department (ED), HHV-6 viremia was detected in 34 (14%).³¹⁰ Symptoms of HHV-6 infection included: malaise (82%); fever > 40°C (65%); inflamed tympanic membranes (62%); nasal congestion (57%); rash (18%); seizure (3%). The typical rash of roseola was present in only three children. Only 2 were hospitalized and all 34 recovered, usually after an average of 4 days of fever.³¹⁰ In 1994, Hall et al studied 1,653 infants and young children (< age 3 years) who presented to an ED with acute febrile illnesses.³⁰⁹ Overall, 160 (9.7%) had a primary HHV-6 infection, as documented by viremia and seroconversion; 21 (13%) were hospitalized and 21 (13%) had seizures.³⁰⁹ Often

the seizures appeared late and were prolonged or recurrent. Conversely, no primary HHV-6 infections were found among 582 infants and young children with acute nonfebrile illnesses or among 352 controls without acute illness.³⁰⁹ In another cohort of 81 children < 2 years old with primary HHV-6 infections, the following symptoms were present: fever (57%); fussiness (69%); rhinorrhea (65%); diarrhea (26%); rash (31%); roseola (23%); and seizures (0%).²⁹⁷ A study in the United States followed 227 children born to HIV-seropositive mothers.³¹¹ The cumulative infection rates of HHV-6 DNAemia at 6 and 12 months of age were 28 and 78% in HIV-negative children compared with 11 and 33%, respectively, among HIV-infected children ($p < 0.001$).³¹¹ There was an association between high CD4 counts and HHV-6 infection, consistent with the tropism of this virus for CD4 lymphocytes. Among HIV-infected children, HHV-6 infection was associated with progression of HIV disease ($p < 0.05$).³¹¹ HHV-6 is endemic in sub-Saharan Africa in healthy young children.^{302,312} In a study of 371 asymptomatic infants in Zambia, serum HHV-6 DNAemia was present in 15% at 6 months and 19% by 18 months.³⁰² Two studies from Zambia detected HHV-6 DNA in the blood of 5 to 30% of HIV-negative children admitted to the hospital with febrile illnesses.^{302,313} A prospective study of 303 pediatric inpatients aged between 3 weeks and 2 years in Zambia detected HHV-6 DNAemia in 20.8%.³¹² Data regarding the importance of HHV-6 as a cause of community-acquired pneumonia (CAP) or acute respiratory infections in children are scant, as this pathogen is rarely looked for. However, in a study from rural China, Zhou et al obtained induced sputum from 354 hospitalized infants and children with acute respiratory infections (273 had CAP; 81, non-CAP).³⁰⁸ HHV-6 was detected in 50.9% of children with CAP and 42% among 81 with non-CAP. These various studies suggest that HHV-6 is a common cause of acute febrile illness with or without rash in children, and the course is usually benign and self-limited over several days.²⁹⁴ Pneumonia and seizures can occur, but are uncommon in immunocompetent hosts.

Primary HHV-6 infections are rare in older children or adults.^{294,301,309} However, even among immunocompetent subjects, rare cases of hepatitis, infectious mononucleosis-like syndrome, gastroenteritis, colitis, and neurological complications (seizures, encephalitis, chronic psychiatric disorders) may occur.^{294,314,315} Further, several studies suggest a link between chronic HHV-6 infection and multiple sclerosis.^{316–318} Fatal myocarditis, although rare, has been described.³¹⁹ Detection of HHV-6 in explanted hearts of children with idiopathic cardiomyopathy³²⁰ suggests a possible pathogenic link, given the tropism of HHV-6 for endothelial cells.³²¹ Additionally, maternal HHV-6 infection during pregnancy may lead to fetal infection and fetal death.^{294,314}

Reactivation of HHV-6 in Immunocompromised Hosts

Like other herpes viruses, HHV-6 establishes lifelong latency in the host and may reactivate under conditions of impaired immunity.²⁹⁴ Most severe HHV-6 infections occur in markedly immunocompromised children or adults²⁹⁴ including HCT^{322–325} or SOT recipients^{326–329}; or those with congenital

or acquired immunodeficiency disorders,^{296,330} HIV,^{312,331} or lymphomas or hematological malignancies receiving chemotherapy.^{293,324,332}

Among HCT recipients, asymptomatic HHV-6 DNAemia is common (30–60%),^{300,325,333,334} but the vast majority of infections are self-limited and do not require treatment.³¹⁴ In one study, 82 allogeneic HCT recipients had weekly blood tests for HHV-6 PCR; HHV-6 viremia was detected in 46 (56%) at a median of 23 days.³³⁵ In another study of 315 allogeneic HCT recipients, blood was drawn twice weekly for 3 months for HHV-6 PCR; viremia was detected in 111 (35%) at a median of 20 days post-HCT.³³³ In a recent study, plasma assays for HHV-6 DNA were performed in 106 pediatric allogeneic HCT recipients; HHV-6 viremia was detected in 48% at a mean of 20 days post-HCT and the onset of viremia coincided with the appearance of lymphocytes and monocytes in the peripheral blood.³³⁴ Among SOT recipients, HHV-6 has been isolated in > 20% of subjects when serial samples are obtained,^{299,300,333,336–339} but serious HHV-6 infections are uncommon. Cervera et al prospectively followed 193 SOT recipients for 1 year posttransplant to detect new HHV-6 infections.²⁹⁹ At baseline, 186 (97.4%) were seropositive; by 1 year, 4 of 7 seronegative SOT recipients seroconverted but only 1 developed clinically significant infection (cholestatic jaundice).

Clinically significant complications of reactivation of HHV-6 in transplant recipients (HCT or SOT) include: interstitial pneumonitis,^{322,323,340} bone marrow suppression, delayed engraftment and graft failure among HCT recipients,^{341,342} GVHD among HCT recipients,^{333,343} gastroenterocolitis,^{314,344–346} CMV coinfection,^{295,333} and encephalitis.^{295,342,347,348} Encephalitis may result in dementia, memory loss, loss of consciousness, seizures, and even death.²⁹⁵ Magnetic resonance imaging scans may show signal abnormalities in the limbic system,²⁹⁵ but are often normal.^{349,350} Among organ transplant recipients, HHV-6 infections have been associated with increased mortality.^{333,342,343} Among liver transplant recipients, HHV-6 may precipitate graft dysfunction or hepatitis,^{327,345,351} and may increase the risk of fungal infections and mortality.^{300,328} However, severe hepatic failure has been rare.³⁵² Among renal transplant recipients, HHV-6 viremia is common (> 26%) and is usually asymptomatic³³⁶ but fatal infections have been described.³⁵³ Clinically significant HHV-6 infections rarely complicate heart transplantation,³⁵⁴ but HHV-6 pericarditis³⁵⁵ and encephalitis³⁵⁶ have been reported. In a series of 30 lung or heart-lung transplant recipients, serial clinical specimens (blood, BAL fluid, tissue) were tested for HHV-6 PCR; HHV-6 was detected in 20 (66%) at a median of 18 days posttransplant.³³⁷ Although no clinical disease was linked to HHV-6 infection, mortality was higher in HHV-6-infected patients (7/20 expired) compared with uninfected patients (0/10 expired). Additionally, eight of nine viral or fungal infections were associated with HHV-6. Another series of 26 lung transplant recipients detected no cases of HHV-6 infections in peripheral blood.³⁵⁷ Costa et al examined 87 transbronchial biopsies from 30 lung transplant recipients by QNAT; HHV-6 DNA was detected in 6.9%, but

did not correlate with allograft rejection and the clinical significance was not clear.³⁵⁸ In another series, 22 lung or heart-lung transplant recipients were followed for 1 year posttransplant; HHV-6 antigenemia was detected in 20 (91%) in blood or BAL.³⁵⁹ Only two had clinically significant disease (pneumonitis in one; encephalitis in one).³⁵⁹ Neurohr et al followed 87 consecutive lung transplant recipients for a mean of 3.3 years; HHV-6 was detected in 20 (23%) and was associated with an increased risk of BOS.³³⁸ However, in a subsequent study, Manuel et al followed 93 lung transplant recipients for 3 years, and measured HHV-6 PCR in all BAL specimens.³³⁹ HHV-6 was detected in 20.4% of patients, but was not associated with acute lung allograft rejection or BOS. In summary, HHV-6 is isolated in blood or BAL in > 20% of lung transplant recipients but the clinical significance remains unclear. One case of HHV-6 colitis was reported in a lung transplant recipient.³⁴⁶

HHV-6 may infect HIV-positive patients, but is often clinically silent.^{360,361} In a study of 32 HIV-infected males, HHV-6 was detected more frequently (100% detection) in subjects with CD4 counts > 400 compared with 58% with CD4 counts < 400 (58% detection, $p < 0.06$), consistent with the tropism of HHV-6 for CD4 lymphocytes.³⁶⁰ Falasca et al evaluated the detection rate and viral load of HHV-6 in gastric, duodenal, and colon biopsies from HIV-positive ($n = 26$) and HIV-negative ($n = 27$) subjects.³³¹ HHV-6 DNA was detected in 88% of HIV-infected individuals compared with 63% of HIV-negative subjects. In a study of 50 HIV-infected children (aged 3–13 years), HHV-6 was detected in oral mucosal cells in 9 (18%).³⁶² In HIV-infected patients, endogenous reactivation of HHV-6 may occur.^{302,312} Primary HHV-6 infection in children with HIV has been associated with progression of HIV disease.³¹¹

Diagnosis

Identification of HHV-6 DNA in blood mononuclear cells, serum, or tissue and seroconversion have been the traditional methods to diagnose HHV-6 infection,^{294,297} but QNAT detection of HHV-6 DNA in biological samples by real-time PCR is the most convenient and most often used method currently.³⁰⁰ Still, the clinical significance of HHV-6 DNAemia is not clear, as most subjects are asymptomatic and do not require treatment.²⁹⁴ No threshold has been formally recognized to identify infection requiring treatment.²⁹⁴ The decision to treat should be based on clinical features, viral load, and host features, including severity of immunosuppression.

Prognosis and Therapy

The prognosis of HHV-6 infections is usually excellent; most cases spontaneously resolve without sequelae. The vast majority of patients infected with HHV-6 do not require treatment. However, treatment may be required for selected complications in immunocompetent patients, such as encephalitis, pneumonia, disseminated or life-threatening disease, or for clinically significant disease in immunocompromised hosts.^{294,326} When patients are on immunosuppressive drugs, cessation or minimization of immunosuppression is a key to a favorable outcome.²⁹⁴ The

role of specific antiviral agents is controversial. Randomized therapeutic trials have not been done. However, ganciclovir, valganciclovir, foscarnet, and cidofovir all display *in vitro* activity against HHV-6, and favorable responses have been cited in anecdotal cases and small series.^{294,300,363–365} Acyclovir is less active and should not be used.²⁹⁴ The role of routine surveillance tests for HHV-6 is controversial. In one study of HCT recipients, high-level HHV-6 infection was associated with increased incidence of CMV infection, acute GVHD, and mortality.³³³ By contrast, in another cohort of HHV-6 infected HCT recipients, early survival (3 and 6 months) was similar in patients receiving viral therapy or no treatment.³³⁵ Adoptive immunotherapy (transfer of HHV-6 specific T cells) may be an option in the future.³⁶⁶

Human Herpesvirus-7

Epidemiology and Prevalence

HHV-7, another lymphotropic virus that was first identified in 1990,³⁶⁷ belongs to the β herpesvirus family and has close homology with HHV-6.³⁶⁸ HHV-7 is a ubiquitous virus that is acquired early in life (usually during the first 5 years),³⁶⁹ presumably via contact with oropharyngeal secretions.³⁷⁰ Like HHV-6, it infects more than 90% of the human population.^{371,372} In a prospective study, 496 children < 3 years old seen in the ED or clinic were evaluated for primary infections with HHV-6 and HHV-7; three cohorts were studied: (1) 250 children with fever, signs of sepsis, or seizures, (2) 65 healthy children for seen for “well visits,” and (3) 161 children with chronic medical illness.³⁷³ In the first cohort, 29/250 (11.6%) had a primary HHV-6 infection and 8 (3.2%) had a primary HHV-7 infection. Seizures occurred in 75% with HHV-7 compared with 17% with HHV-6 ($p < 0.04$). Median age was 23 months in subjects with HHV-7 compared with 9 months for HHV-6. No cases of HHV-7 infections were seen in the other two cohorts.

Clinical Manifestations

Importantly, the clinical spectrum of HHV-7 has not been well defined. HHV-7 may cause diseases similar to HHV-6,³⁷⁴ including a roseola-like illness,³⁷⁵ acute febrile respiratory disease,^{373,374} and seizures in young children.^{372,373} Rare manifestations include encephalitis and Guillain-Barre syndrome.^{376,377} Like HHV-6, HHV-7 establishes latency in lymphocytes for the life of the host. Reactivation of HHV-7 may occur among immunocompromised hosts, but clinically important infections are much less common than with HHV-6.^{329,378} A recent study of 105 HCT recipients detected HHV-6 in 60.0% and HHV-7 in 8.6%, with peak detection approximately 21 days posttransplant.³²⁵

Diagnosis

HHV-7 PCR diagnostic assays are primarily used for research purposes as there is no common clinical scenario warranting HHV-7 diagnostic testing.³⁷⁹ Given the rarity of HHV-7, and limited data regarding clinical importance and management, we will not further discuss this agent.

Human Herpesvirus-8

HHV-8, first discovered by Chang et al in 1994,³⁸⁰ is closely related to EBV and is in the family of gamma herpesviruses.³⁸¹ HHV-8 is also termed Kaposi sarcoma-associated herpesvirus (KSHV). The importance of HHV-8 (KSHV) is its oncogenic properties. HHV-8 is the causative agent for at least three malignancies: (1) Kaposi sarcoma (KS), a lymphatic endothelial cell malignancy,^{326,381,382} (2) multicentric Castleman disease (MCD),^{381,383,384} and (3) primary effusion lymphoma (PEL).^{381,385–388} In addition to these three “hallmark” malignancies, rare cases of hemophagocytic lymphohistiocytosis^{381,382,389–392} have been associated with HHV-8. The pathogenesis of these malignancies likely results from viral and cellular angiogenic and inflammatory factors.³⁸¹ HHV-8 can stimulate cell proliferation and inhibit apoptosis of tumor cells in KS, MCD, and PEL.³⁸⁸

Epidemiology

HHV-8 is endemic in sub-Saharan Africa,^{393–400} with seroprevalence rates of 50 to 70%.^{313,393–395,397,398,401} In Uganda, the seroprevalence of HHV-8 increases with age as follows: 1.5 to 2 years old, 16%; 10 to 13 years old, 32%; 14 to 19 years old, 37%; adult > 50 years old, 49%.⁴⁰² In sub-Saharan Africa, factors that increase seropositivity for HHV-8 include HIV infection and malaria parasitemia.⁴⁰³ Seropositivity rates vary considerably among different regions/countries and are as follows: Europe 6 to 30%, with highest prevalence in Mediterranean countries⁴⁰⁴; Southeast Asia 4.9 to 15.5%⁴⁰⁴; the Caribbean 4.4%⁴⁰⁴; Latin America 3 to 16%^{405,406}; and United States 1.5 to 6%.^{388,404,407} High rates of KS and HHV-8 seroprevalence are also found among Amerindians from Brazil and Ecuador.⁴⁰⁵ Several distinct subtypes of HHV-8 have been described, with some subtypes preferentially found in specific geographic regions (e.g., Africa, Asian Pacific, United States, Europe, Middle East, etc.).³⁹³

HHV-8 may be transmitted by close contacts (e.g., saliva, bodily fluids)^{382,408–410} or by sexual transmission.^{410,411} Transmission via blood transfusion⁴¹² and organ transplantation^{413,414} has been described.

Primary infections with HHV-8 in immunocompetent subjects are mild and self-limited within a few days.³²⁶ Children may develop fever and rash⁴⁰⁰; in adults, fever, diarrhea, and lymphadenopathy may occur.^{326,415} Like other herpesviruses, following resolution of the primary infection, the virus persists in a latent state in lymphoid cells.³²⁶ In immunocompetent individuals, pathogen-specific CD8 T cells control HHV-8 replication, preventing progression to neoplastic disease.⁴¹⁵

HHV-8 may reactivate in individuals with severe impairment in immune defense,⁴¹⁶ particularly those infected by HIV,^{388,417} SOT recipients,^{329,382,395,418,419} and other congenital and acquired immunodeficiency syndromes.⁴²⁰ Globally, HIV infection is associated with an increased prevalence of HHV-8 seropositivity compared with HIV-negative persons (odds ratio [OR] = 1.99, 95% confidence interval [CI] = 1.70–2.34).⁴¹⁷ The association is strongest among HIV-positive men who have sex with men (OR = 3.95, 95% CI = 2.92–5.35) and those with

hemophilia (OR = 3.11, 95% CI = 1.19–8.11).⁴¹⁷ Additionally, HHV-8 is endemic in sub-Saharan Africa in both HIV-negative and HIV-positive individuals.⁴¹⁰

Diagnosis

Serology has limited utility in the diagnosis of acute HHV-8 infection and there is no standard serological test for clinical use.³⁸⁸ HHV-8 DNA can be quantified in plasma and PBMCs via PCR. HHV-8 viremia is invariably present with PEL and MCD,⁴²¹ and is associated with the clinical stage of KS.⁴²² Immunohistochemistry can identify HHV-8 proteins in tissue and is often used adjunctively in the diagnosis of KS, MCD, and PEL.⁴¹⁹

Clinical Manifestations

As noted above, HHV-8 has been associated with several distinct clinical manifestations, including KS, MCD, and PEL, and the clinical features of each are discussed separately below.

Kaposi Sarcoma

The disease most often associated with HHV-8 infection is KS, an angioproliferative cancer of endothelial cells.⁴²⁰ Histopathological features of KS include spindle-shaped cells, inflammatory infiltration, and angioproliferation with extravasating erythrocytes.⁴²³ Endothelial cell markers (CD31, CD34, factor VIII) and lymphatic endothelial markers may be present.⁴²³ HHV-8 latency-associated nuclear antigen (LANA) is present in spindle cells in KS.⁴²³

KS is classified as one of four epidemiologic forms: (1) Classic KS which primarily affects elderly Eastern European Jewish or Mediterranean men, (2) endemic KS which occurs in sub-Saharan Africa,^{393,398,424} (3) epidemic KS is seen in HIV-infected subjects with AIDS,^{396,409} and (4) iatrogenic KS from immunosuppressive therapy.³⁸¹

KS has a variable clinical course ranging from very indolent cutaneous forms to a rapidly progressive multiorgan or disseminated disease. The clinical manifestations vary depending upon the immune status of the patient and organs involved.^{389,425} In the following sections, clinical features, among the four epidemiological forms will be discussed.

Classic Kaposi Sarcoma in Immunocompetent Subjects

Classic KS primarily affects elderly Eastern European Jewish or Mediterranean men (male/female ratio: 10–15/1), typically presenting with indolent and chronic cutaneous plaques and nodules.³⁸⁸ The KS skin lesions are characterized by purplish discoloration, usually first appearing on the extremities.⁴¹⁹ Classical KS in immunocompetent patients is usually chronic, persistent over many years and is not life threatening.⁴²⁵ Disseminated disease is uncommon.³⁸⁸ For localized forms, surgical resection, radiotherapy, or intralesional injections may be adequate as therapy.

Endemic Kaposi Sarcoma in Sub-Saharan Africa

The African endemic form of KS, is found in HIV-negative or HIV-positive individuals (children or adults) in countries of East and Central Africa.^{393,394,398} KS is the most common

cancer in sub-Saharan Africa.^{404,424} Among an estimated 66,200 cases of KS worldwide, 58,800 are believed to have occurred in sub-Saharan Africa.⁴²⁶ The incidence of endemic KS in Africa is more common in males and adults > 35 year old.³⁹⁸

Endemic KS in Africa is more aggressive than classic KS in Europe and Mediterranean Countries.⁴⁰⁴ Typical cutaneous lesions are purplish/reddish in color, often affecting the lower extremities, and may infiltrate and destroy subcutaneous tissue and even bone.⁴²⁷ In African children and adults with endemic KS, oral manifestations (soft palate, gingiva) are common.^{428,429} Multicentric involvement of GI tract, lungs or bronchi, spleen, liver, and lymph nodes may occur.⁴²⁷ Males typically have a greater systemic tumor burden⁴²⁹ and widely disseminated disease is usually fatal within 3 years.⁴²⁷

Epidemic Kaposi Sarcoma in HIV-Infected Persons

Epidemic KS may complicate HIV infection in all areas of the world,⁴³⁰ with the highest incidence in Africa.^{381,396} During the pre-antiretroviral therapy (ART) era, KS was the most common malignancy among HIV-infected persons (incidence 1,500–2,500 cases per 100,000 person-years).^{431,432} The use of ART has resulted in a significant decline in incidence to < 500 cases/per 100,000 person-years in developed, resource rich nations.^{431,432} By comparison, the incidence of KS in the general population is approximately 1:100,000 person-years.⁴⁰⁴ The incidence of KS in HIV-positive individuals is approximately 1:20, with even higher rates (up to 30%) among HIV-infected men who have sex with men.^{404,409,411,430}

The radiographic features of pulmonary KS are varied; multiple pulmonary nodules, tumorous masses, bronchovascular bundle thickening, and pleural effusions are the most common findings on chest CT scans.⁴³³ Endobronchial KS may present as red or purple nodules or lesions at airway bifurcations⁴³⁴; because of the risk of bleeding, endobronchial biopsy is not recommended. Immune reconstitution inflammatory syndrome-associated KS flares have been reported in pulmonary KS.⁴³⁵ Musculoskeletal involvement with HIV-associated KS has rarely been described.⁴³⁶

HHV-8 infection enhances HIV replication. HIV-infected men who are seropositive to HHV-8 have impaired proliferative responses to HHV-8.⁴³⁷ Following ART in HIV-infected individuals with KS, cytotoxic lymphocyte responses to HHV-8 increase.³⁸⁸

Kaposi Sarcoma in Solid Organ Transplant Recipients

Organ transplant recipients are at an increased risk of developing KS,^{326,438,439} but the incidence varies considerably among different geographic regions. Among adult SOT recipients in the United States, Southeast Asia, and Northern Europe, the cumulative incidence of KS is approximately 0.5% compared with 6 to 28% incidence in regions of the Middle East and some Mediterranean regions.^{326,419}

Multicentric Castleman Disease

MCD, an aggressive lymphoproliferative disorder characterized by generalized lymphadenopathy, constitutional

symptoms, and anemia, has also been linked with HHV-8 in some, but not all cases.⁴⁴⁰ MCD associated with HHV-8 is the plasma cell variant.^{384,388} MCD is driven by hypersecretion of IL-6, a cytokine that promotes B cell growth and angiogenesis.³⁸¹ As with KS, the majority of HHV-8-infected cells in MCD are latently infected,³⁸¹ but a subset expresses lytic genes.^{381,441} Exacerbations of MCD correlate with increased HHV-8 viral load and increased IL-6 and IL-10 levels, underscoring the importance of viral replication and cellular cytokines in the pathogenesis of this disease.^{441–443}

Tumor cells in HIV-positive individuals with MCD are plasmablasts that are scattered in the mantle zone of follicles, express B cell antigens, and are usually MUM1 (+), CD138 (–), and CD138 (+).⁴⁴⁴ The HHV-8-infected cells may form small confluent clusters, sometimes coalesced into “microlymphomas” or large sheets of cells thought to represent frank lymphoma.⁴⁴⁴ Importantly, these plasma cells harbor latent and lytic HHV-8.⁴⁴⁴

MCD most commonly affects HIV-infected patients (> 90% males),^{440,443,445–447} but may also occur in HIV-negative immunosuppressed persons, especially SOT recipients.^{448–450} Among HIV-positive subjects, > 99% of cases of MCD are associated with HHV-8, as are > 50% of MCD among HIV-negative subjects.^{440,443,444,451}

Cardinal features of MCD in HIV-infected patients include fever, constitutional symptoms, lymphadenopathy, splenomegaly, cytopenias, polyclonal hypergammaglobulinemia, and elevated inflammatory markers (e.g., C-reactive protein [CRP] and IL-6).^{444,447} Among HIV-positive patients with MCD, 54 to 72% have coexistent KS.^{444,447} B-cell lymphomas occur 15 times more commonly in HIV-positive individuals with MCD compared with HIV-positive subjects without MCD.⁴⁵² MCD is characterized by recurrent flares with systemic symptoms, lymphadenopathy, inflammation, and high HHV-8 viral load.⁴⁴⁴ Recently, a new clinical entity characterized by severe systemic infection/reactivation, termed KSHV inflammatory syndrome, has been proposed.⁴⁵³ Serum IL-6 levels, HHV-8 viral load, and CRP may be useful as markers of disease activity and response to therapy.³⁸¹

Primary Effusion Lymphoma

PEL, a rare form of large B-cell lymphoma first described by Knowles et al in 1989,⁴⁵⁴ is caused by HHV-8 and is associated with serous effusions (pleural, peritoneal, ascites) in the absence of lymphadenopathy or organomegaly.⁴⁵⁵ Extracavitary or solid variants of PEL have been described,^{387,401,456} but are rare. Most cases of PEL (50–80%) are coinfecting with EBV.^{388,455} PEL cells most likely represent postgerminal center B cells with a plasma cell phenotype.^{381,457} In 1995, Cesarman et al identified HHV-8 DNA in all patients with PEL,³⁸⁵ underscoring the critical role of HHV-8 in the pathogenesis of this malignancy.³⁸¹

The tumor cells of PEL are large, with abundant basophilic cytoplasm, irregular nuclear contours, and prominent nucleoli with plasmablastic, immunoblastic, or anaplastic differentiation.^{401,458} Immunohistochemical stains typically are negative for pan-B cell markers such as CD19, CD20, CD79a, and PAX-5, but the lymphoma cells express plasma cell

markers including CD138, VS38c, and MUM1.^{387,388,456} The tumor cells often express CD30, CD38, CD71, and epithelial membrane antigen.⁴⁵⁶ Detecting HHV-8 in the tumor cells by in situ hybridization, PCR, or by immunohistochemistry against LANA is essential to diagnose PEL.^{387,401,458}

Most cases of PEL occur in HIV-infected patients,^{387,388,443,455,459} but a few cases have been reported after SOT.^{460–463} PEL represents approximately 1–4% of AIDS-related lymphomas and 0.3% of all aggressive lymphomas in HIV-negative subjects.^{388,464} Cases of PEL have also been reported in older immunocompetent patients from geographic areas where HHV-8 is endemic, such as sub-Saharan Africa and the Mediterranean region.⁴⁶⁵

PEL usually presents as a malignant pleural, peritoneal, and/or pericardial effusion without a detectable solid mass.⁴⁵⁵ Rare cases present as tumor masses and are considered to represent an extracavitary or a solid variant of PEL.^{387,401,456} Unusual sites of involvement include skin,⁴⁶⁶ GI tract,^{387,401} lung, central nervous system, and lymph nodes.⁴⁰¹

Prognosis and Therapy

Kaposi Sarcoma

The course of KS is more aggressive in persons with AIDS, compared with HIV-negative persons.^{388,467,468} In HIV-infected persons with KS, oral mucosa and craniofacial regions are affected in 30% at initial presentation,^{404,467} and visceral involvement (e.g., GI tract,⁴⁶⁹ liver, spleen, lymph nodes) is common.³⁸⁸ Lung involvement occurs in 15 to 30% of HIV-infected persons,⁴⁶⁸ and may be associated with hemoptysis which is sometimes fatal.⁴⁰⁴ Even in the post-ART era, pulmonary KS has been associated with a worse prognosis. In a single center study of 305 cases of KS in HIV-infected patients from 1996 to 2004, 5-year survival rates were 49% (median survival 1.6 years) in subjects with pulmonary involvement compared with 82% survival among those without pulmonary involvement.⁴⁶⁸

Survival rates for HIV-infected patients with KS are worse compared with HIV-negative subjects, but survival rates have improved in HIV-infected subjects in the post-ART era.³⁹⁷ In the pre-ART era, staging systems were developed to predict prognosis in HIV-infected patients with KS.⁴⁷⁰ In a cohort of 211 HIV-infected patients with KS, Italian investigators cited 3-year survival rates of > 80% among “good risk” subjects compared with 34% survival among “poor risk” patients.⁴⁷⁰ The use of ART has markedly reduced the incidence of KS in HIV-infected subjects in resource-rich countries,⁴⁷¹ but reductions have not yet been achieved in sub-Saharan Africa.⁴⁰⁴

Treatment of KS depends upon the immune state of the patient and the extent and severity of organ involvement. All patients with AIDS-associated KS should receive ART.³⁸⁸ Among HIV-negative individuals on immunosuppressive therapy, a reduction in immunosuppression should be performed when feasible.^{326,425} For limited, localized disease, intralesional or topical chemotherapy, laser, cryotherapy, radiation therapy, or surgical resection may be adequate.^{388,404} Multiagent chemotherapy is reserved for patients with severe symptoms, visceral involvement, or multiorgan disease, but relapses are common

and toxicities may be significant.^{404,419,425} Optimal treatment is controversial, as no randomized controlled trial data are available. Clinical responses have been cited with a variety of agents, alone or in combination, including doxorubicin, vinca-alkaloids, etoposide, gemcitabine, interferon- α 2, taxanes, and radiation therapy.^{326,388,419,425,472} In SOT recipients, a switch from calcineurin inhibitor therapy to sirolimus may also be useful based on the latter's known antiproliferative properties³²⁶; changing cyclosporine to sirolimus was associated with regression of KS in all of 15 renal transplant recipients undergoing this modification, with no episodes of acute rejection.⁴³⁸

Ganciclovir, valganciclovir, foscarnet, and cidofovir have in vitro activity against HHV-8.³⁸⁸ Novel strategies incorporating antiangiogenic factors, immunomodulatory agents, cytokines, and virus-activated cytotoxic therapy are being developed.^{384,404,416,470} Ganciclovir or valganciclovir as prophylactic antiviral therapy may reduce reactivation in high risk individuals.⁴⁷³

Multicentric Castleman Disease

Treatment of MCD is controversial, as randomized trials are lacking. Surgery and antiviral therapies including ART,⁴⁷⁴ interferon- α , and chemotherapy have proved largely ineffective.^{443,445,451} In one randomized trial, 79 HIV-negative and HHV-8-negative subjects with MCD were treated with the anti-IL-6 antibody siltuximab ($n = 53$) or placebo ($n = 26$); favorable responses were observed with siltuximab in 34% compared with 0% in the placebo group.⁴⁷⁵ In several studies, prolonged remissions were achieved with the anti-CD20 monoclonal antibody rituximab, at the expense of B cell depletion and flares of KS.^{445,447,451,476,477} Bower et al reported 49 HIV-positive patients with newly diagnosed MCD who were treated with rituximab with ($n = 14$) or without ($n = 35$) etoposide.⁴⁷⁸ Survival rates were 94% at 2 years and 90% at 5 years compared with 42 and 33%, respectively, in 12 patients treated before the introduction of rituximab ($p < 0.001$). Eight of 46 patients who achieved clinical remission suffered symptomatic, histologically confirmed relapse of MCD. All were successfully retreated and were alive in remission. The 2- and 5-year progression-free survival rates for all 49 patients treated with rituximab-based therapy were 85 and 61% respectively. In summary, HIV-associated MCD is a remitting-relapsing disease, but the outlook has improved dramatically in recent years with the introduction of rituximab-based therapy.⁴⁷⁸ Rituximab also reduced by 11-fold the risk of developing lymphoma in HIV-positive patients with MCD.⁴⁷⁶

Primary Effusion Lymphoma

The prognosis for PEL is poor, with a median survival of less than 6 months.^{443,456,459} Given the rarity of PEL, optimal therapy has not been elucidated. Anecdotal successes have been cited with chemotherapy and/or antiviral agents, but are rarely durable.^{386,388,419,460} Responses to intracavitary cidofovir have been cited in case reports.^{479,480} Sirolimus inhibits growth of PEL in vitro and in animal models⁴⁸¹ and has promise for treatment of PEL. Bortezomib exhibited antitumor effects in vitro cultures of PEL cells.⁴⁸²

References

- 1 Ho M. Epidemiology of cytomegalovirus infections. *Rev Infect Dis* 1990;12(Suppl 7):S701–S710
- 2 Krech U. Complement-fixing antibodies against cytomegalovirus in different parts of the world. *Bull World Health Organ* 1973; 49(1):103–106
- 3 Rubin RH. Impact of cytomegalovirus infection on organ transplant recipients. *Rev Infect Dis* 1990;12(Suppl 7):S754–S766
- 4 Kalil AC, Levitsky J, Lyden E, Stoner J, Freifeld AG. Meta-analysis: the efficacy of strategies to prevent organ disease by cytomegalovirus in solid organ transplant recipients. *Ann Intern Med* 2005; 143(12):870–880
- 5 Söderberg-Nauclér C, Fish KN, Nelson JA. Reactivation of latent human cytomegalovirus by allogeneic stimulation of blood cells from healthy donors. *Cell* 1997;91(1):119–126
- 6 Horwitz CA, Henle W, Henle G, et al. Clinical and laboratory evaluation of cytomegalovirus-induced mononucleosis in previously healthy individuals. Report of 82 cases. *Medicine (Baltimore)* 1986;65(2):124–134
- 7 Snyderman DR, Limaye AP, Potena L, Zamora MR. Update and review: state-of-the-art management of cytomegalovirus infection and disease following thoracic organ transplantation. *Transplant Proc* 2011;43(3, Suppl)S1–S17
- 8 Marcelin JR, Beam E, Razonable RR. Cytomegalovirus infection in liver transplant recipients: updates on clinical management. *World J Gastroenterol* 2014;20(31):10658–10667
- 9 Chou SW. Acquisition of donor strains of cytomegalovirus by renal-transplant recipients. *N Engl J Med* 1986;314(22): 1418–1423
- 10 Lowance D, Neumayer HH, Legendre CM, et al; International Valacyclovir Cytomegalovirus Prophylaxis Transplantation Study Group. Valacyclovir for the prevention of cytomegalovirus disease after renal transplantation. *N Engl J Med* 1999;340(19): 1462–1470
- 11 Ljungman P, Griffiths P, Paya C. Definitions of cytomegalovirus infection and disease in transplant recipients. *Clin Infect Dis* 2002;34(8):1094–1097
- 12 Gane E, Saliba F, Valdecasas GJ, et al; The Oral Ganciclovir International Transplantation Study Group. Randomised trial of efficacy and safety of oral ganciclovir in the prevention of cytomegalovirus disease in liver-transplant recipients. The Oral Ganciclovir International Transplantation Study Group [corrected]. [corrected] *Lancet* 1997;350(9093):1729–1733
- 13 Eid AJ, Arthurs SK, Deziel PJ, Wilhelm MP, Razonable RR. Emergence of drug-resistant cytomegalovirus in the era of valganciclovir prophylaxis: therapeutic implications and outcomes. *Clin Transplant* 2008;22(2):162–170
- 14 Humar A, Lebranchu Y, Vincenti F, et al. The efficacy and safety of 200 days valganciclovir cytomegalovirus prophylaxis in high-risk kidney transplant recipients. *Am J Transplant* 2010;10(5): 1228–1237
- 15 Humar A, Snyderman D; AST Infectious Diseases Community of Practice. Cytomegalovirus in solid organ transplant recipients. *Am J Transplant* 2009;9(Suppl 4):S78–S86
- 16 Paya C, Humar A, Dominguez E, et al; Valganciclovir Solid Organ Transplant Study Group. Efficacy and safety of valganciclovir vs. oral ganciclovir for prevention of cytomegalovirus disease in solid organ transplant recipients. *Am J Transplant* 2004;4(4): 611–620
- 17 Arthurs SK, Eid AJ, Pedersen RA, et al. Delayed-onset primary cytomegalovirus disease and the risk of allograft failure and mortality after kidney transplantation. *Clin Infect Dis* 2008; 46(6):840–846
- 18 Palmer SM, Limaye AP, Banks M, et al. Extended valganciclovir prophylaxis to prevent cytomegalovirus after lung transplantation: a randomized, controlled trial. *Ann Intern Med* 2010; 152(12):761–769

- 19 Singh N. Late-onset cytomegalovirus disease as a significant complication in solid organ transplant recipients receiving antiviral prophylaxis: a call to heed the mounting evidence. *Clin Infect Dis* 2005;40(5):704–708
- 20 Blyth D, Lee I, Sims KD, et al. Risk factors and clinical outcomes of cytomegalovirus disease occurring more than one year post solid organ transplantation. *Transpl Infect Dis* 2012;14(2):149–155
- 21 Limaye AP, Bakthavatsalam R, Kim HW, et al. Impact of cytomegalovirus in organ transplant recipients in the era of antiviral prophylaxis. *Transplantation* 2006;81(12):1645–1652
- 22 Linares L, Sanclemente G, Cervera C, et al. Influence of cytomegalovirus disease in outcome of solid organ transplant patients. *Transplant Proc* 2011;43(6):2145–2148
- 23 Peleg AY, Husain S, Kwak EJ, et al. Opportunistic infections in 547 organ transplant recipients receiving alemtuzumab, a humanized monoclonal CD-52 antibody. *Clin Infect Dis* 2007;44(2):204–212
- 24 Ison MG, Fishman JA. Cytomegalovirus pneumonia in transplant recipients. *Clin Chest Med* 2005;26(4):691–705, viii
- 25 Fishman JA. Infection in solid-organ transplant recipients. *N Engl J Med* 2007;357(25):2601–2614
- 26 Lautenschlager I, Halme L, Höckerstedt K, Krogerus L, Taskinen E. Cytomegalovirus infection of the liver transplant: virological, histological, immunological, and clinical observations. *Transpl Infect Dis* 2006;8(1):21–30
- 27 Razonable RR, Humar A; AST Infectious Diseases Community of Practice. Cytomegalovirus in solid organ transplantation. *Am J Transplant* 2013;13(Suppl 4):93–106
- 28 Hodson EM, Craig JC, Strippoli GF, Webster AC. Antiviral medications for preventing cytomegalovirus disease in solid organ transplant recipients. *Cochrane Database Syst Rev* 2008;(2):CD003774
- 29 Sagedal S, Hartmann A, Nordal KP, et al. Impact of early cytomegalovirus infection and disease on long-term recipient and kidney graft survival. *Kidney Int* 2004;66(1):329–337
- 30 Sagedal S, Rollag H, Hartmann A. Cytomegalovirus infection in renal transplant recipients is associated with impaired survival irrespective of expected mortality risk. *Clin Transplant* 2007;21(3):309–313
- 31 Koskinen PK, Kallio EA, Tikkanen JM, Sihvola RK, Häyry PJ, Lemström KB. Cytomegalovirus infection and cardiac allograft vasculopathy. *Transpl Infect Dis* 1999;1(2):115–126
- 32 Erdbruegger U, Scheffner I, Mengel M, et al. Impact of CMV infection on acute rejection and long-term renal allograft function: a systematic analysis in patients with protocol biopsies and indicated biopsies. *Nephrol Dial Transplant* 2012;27(1):435–443
- 33 Estenne M, Maurer JR, Boehler A, et al. Bronchiolitis obliterans syndrome 2001: an update of the diagnostic criteria. *J Heart Lung Transplant* 2002;21(3):297–310
- 34 Evans PC, Soin A, Wreghitt TG, Taylor CJ, Wight DG, Alexander GJ. An association between cytomegalovirus infection and chronic rejection after liver transplantation. *Transplantation* 2000;69(1):30–35
- 35 Humar A, Gillingham KJ, Payne WD, Dunn DL, Sutherland DE, Matas AJ. Association between cytomegalovirus disease and chronic rejection in kidney transplant recipients. *Transplantation* 1999;68(12):1879–1883
- 36 Kliem V, Fricke L, Wollbrink T, Burg M, Radermacher J, Rohde F. Improvement in long-term renal graft survival due to CMV prophylaxis with oral ganciclovir: results of a randomized clinical trial. *Am J Transplant* 2008;8(5):975–983
- 37 Kranz B, Vester U, Wingen AM, et al. Acute rejection episodes in pediatric renal transplant recipients with cytomegalovirus infection. *Pediatr Transplant* 2008;12(4):474–478
- 38 Nett PC, Heisey DM, Fernandez LA, Sollinger HW, Pirsch JD. Association of cytomegalovirus disease and acute rejection with graft loss in kidney transplantation. *Transplantation* 2004;78(7):1036–1041
- 39 Reischig T, Jindra P, Svecová M, Kormunda S, Opatrný K Jr, Treska V. The impact of cytomegalovirus disease and asymptomatic infection on acute renal allograft rejection. *J Clin Virol* 2006;36(2):146–151
- 40 Sagedal S, Nordal KP, Hartmann A, et al. The impact of cytomegalovirus infection and disease on rejection episodes in renal allograft recipients. *Am J Transplant* 2002;2(9):850–856
- 41 Stern M, Hirsch H, Cusini A, et al; Members of Swiss Transplant Cohort Study. Cytomegalovirus serology and replication remain associated with solid organ graft rejection and graft loss in the era of prophylactic treatment. *Transplantation* 2014;98(9):1013–1018
- 42 Westall GP, Michaelides A, Williams TJ, Snell GI, Kotsimbos TC. Bronchiolitis obliterans syndrome and early human cytomegalovirus DNAemia dynamics after lung transplantation. *Transplantation* 2003;75(12):2064–2068
- 43 Paraskeva M, Bailey M, Levvey BJ, et al. Cytomegalovirus replication within the lung allograft is associated with bronchiolitis obliterans syndrome. *Am J Transplant* 2011;11(10):2190–2196
- 44 Schlischewsky E, Fuehner T, Warnecke G, et al. Clinical significance of quantitative cytomegalovirus detection in bronchoalveolar lavage fluid in lung transplant recipients. *Transpl Infect Dis* 2013;15(1):60–69
- 45 Valantine HA, Gao SZ, Menon SG, et al. Impact of prophylactic immediate posttransplant ganciclovir on development of transplant atherosclerosis: a post hoc analysis of a randomized, placebo-controlled study. *Circulation* 1999;100(1):61–66
- 46 Lemström K, Koskinen P, Krogerus L, Daemen M, Bruggeman C, Häyry P. Cytomegalovirus antigen expression, endothelial cell proliferation, and intimal thickening in rat cardiac allografts after cytomegalovirus infection. *Circulation* 1995;92(9):2594–2604
- 47 Razonable RR, Rivero A, Rodriguez A, et al. Allograft rejection predicts the occurrence of late-onset cytomegalovirus (CMV) disease among CMV-mismatched solid organ transplant patients receiving prophylaxis with oral ganciclovir. *J Infect Dis* 2001;184(11):1461–1464
- 48 George MJ, Snyderman DR, Werner BG, et al. The independent role of cytomegalovirus as a risk factor for invasive fungal disease in orthotopic liver transplant recipients. Boston Center for Liver Transplantation CMVIG-Study Group. *Cytogam, MedImmune, Inc. Gaithersburg, Maryland. Am J Med* 1997;103(2):106–113
- 49 Hodson EM, Jones CA, Webster AC, et al. Antiviral medications to prevent cytomegalovirus disease and early death in recipients of solid-organ transplants: a systematic review of randomised controlled trials. *Lancet* 2005;365(9477):2105–2115
- 50 Nichols WG, Corey L, Gooley T, Davis C, Boeckh M. High risk of death due to bacterial and fungal infection among cytomegalovirus (CMV)-seronegative recipients of stem cell transplants from seropositive donors: evidence for indirect effects of primary CMV infection. *J Infect Dis* 2002;185(3):273–282
- 51 Walker RC, Marshall WF, Strickler JG, et al. Pretransplantation assessment of the risk of lymphoproliferative disorder. *Clin Infect Dis* 1995;20(5):1346–1353
- 52 Bosch W, Heckman MG, Pungpapong S, Diehl NN, Shalev JA, Hellinger WC. Association of cytomegalovirus infection and disease with recurrent hepatitis C after liver transplantation. *Transplantation* 2012;93(7):723–728
- 53 Einollahi B, Motalebi M, Salesi M, Ebrahimi M, Taghipour M. The impact of cytomegalovirus infection on new-onset diabetes mellitus after kidney transplantation: a review on current findings. *J Nephrothol* 2014;3(4):139–148
- 54 Pastacaldi S, Teixeira R, Montalto P, Rolles K, Burroughs AK. Hepatic artery thrombosis after orthotopic liver transplantation: a review of nonsurgical causes. *Liver Transpl* 2001;7(2):75–81
- 55 Razonable RR, Åsberg A, Rollag H, et al. Virologic suppression measured by a cytomegalovirus (CMV) DNA test calibrated to the World Health Organization international standard is predictive of

- CMV disease resolution in transplant recipients. *Clin Infect Dis* 2013;56(11):1546–1553
- 56 Kotton CN. CMV: Prevention, Diagnosis and Therapy. *Am J Transplant* 2013;13(Suppl 3):24–40, quiz 40
 - 57 Cope AV, Sabin C, Burroughs A, Rolles K, Griffiths PD, Emery VC. Interrelationships among quantity of human cytomegalovirus (HCMV) DNA in blood, donor-recipient serostatus, and administration of methylprednisolone as risk factors for HCMV disease following liver transplantation. *J Infect Dis* 1997;176(6):1484–1490
 - 58 Emery VC, Sabin CA, Cope AV, Gor D, Hassan-Walker AF, Griffiths PD. Application of viral-load kinetics to identify patients who develop cytomegalovirus disease after transplantation. *Lancet* 2000;355(9220):2032–2036
 - 59 Hirsch HH, Lautenschlager I, Pinsky BA, et al. An international multicenter performance analysis of cytomegalovirus load tests. *Clin Infect Dis* 2013;56(3):367–373
 - 60 Caliendo AM, Schuurman R, Yen-Lieberman B, et al; CMV Working Group of the Complications of HIV Disease RAC, AIDS Clinical Trials Group. Comparison of quantitative and qualitative PCR assays for cytomegalovirus DNA in plasma. *J Clin Microbiol* 2001;39(4):1334–1338
 - 61 Grim SA, Pereira E, Guzman G, Clark NM. CMV PCR as a diagnostic tool for CMV gastrointestinal disease after solid organ transplantation. *Transplantation* 2010;90(7):799–801
 - 62 Mazzulli T, Drew LW, Yen-Lieberman B, et al. Multicenter comparison of the digene hybrid capture CMV DNA assay (version 2.0), the pp65 antigenemia assay, and cell culture for detection of cytomegalovirus viremia. *J Clin Microbiol* 1999;37(4):958–963
 - 63 Buffone GJ, Frost A, Samo T, Demmler GJ, Cagle PT, Lawrence EC. The diagnosis of CMV pneumonitis in lung and heart/lung transplant patients by PCR compared with traditional laboratory criteria. *Transplantation* 1993;56(2):342–347
 - 64 Chemaly RF, Yen-Lieberman B, Chapman J, et al. Clinical utility of cytomegalovirus viral load in bronchoalveolar lavage in lung transplant recipients. *Am J Transplant* 2005;5(3):544–548
 - 65 Storch GA, Ettinger NA, Ockner D, et al. Quantitative cultures of the cell fraction and supernatant of bronchoalveolar lavage fluid for the diagnosis of cytomegalovirus pneumonitis in lung transplant recipients. *J Infect Dis* 1993;168(6):1502–1506
 - 66 Westall GP, Michaelides A, Williams TJ, Snell GI, Kotsimbos TC. Human cytomegalovirus load in plasma and bronchoalveolar lavage fluid: a longitudinal study of lung transplant recipients. *J Infect Dis* 2004;190(6):1076–1083
 - 67 Rayes N, Seehofer D, Lullius SG, et al. Monitoring of human cytomegalovirus, HHV-6 and HHV-7 infection in kidney transplant recipients by molecular methods to predict HCMV disease after transplantation: a prospective study. *Ann Transplant* 2005;10(2):23–28
 - 68 Hardie DR, Korsman SN, Hsiao NY. Cytomegalovirus load in whole blood is more reliable for predicting and assessing CMV disease than pp65 antigenaemia. *J Virol Methods* 2013;193(1):166–168
 - 69 Marchetti S, Santangelo R, Manzara S, D'onghia S, Fadda G, Cattani P. Comparison of real-time PCR and pp65 antigen assays for monitoring the development of Cytomegalovirus disease in recipients of solid organ and bone marrow transplants. *New Microbiol* 2011;34(2):157–164
 - 70 Levitsky J, Singh N, Wagener MM, Stosor V, Abecassis M, Ison MG. A survey of CMV prevention strategies after liver transplantation. *Am J Transplant* 2008;8(1):158–161
 - 71 Humar A, Mazzulli T, Moussa G, et al; Valganciclovir Solid Organ Transplant Study Group. Clinical utility of cytomegalovirus (CMV) serology testing in high-risk CMV D+/R- transplant recipients. *Am J Transplant* 2005;5(5):1065–1070
 - 72 Weber B, Fall EM, Berger A, Doerr HW. Screening of blood donors for human cytomegalovirus (HCMV) IgG antibody with an enzyme immunoassay using recombinant antigens. *J Clin Virol* 1999;14(3):173–181
 - 73 Manuel O, Husain S, Kumar D, et al. Assessment of cytomegalovirus-specific cell-mediated immunity for the prediction of cytomegalovirus disease in high-risk solid-organ transplant recipients: a multicenter cohort study. *Clin Infect Dis* 2013;56(6):817–824
 - 74 Montejo M, Montejo E, Gastaca M, et al. Prophylactic therapy with valganciclovir in high-risk (cytomegalovirus D+/R-) liver transplant recipients: a single-center experience. *Transplant Proc* 2009;41(6):2189–2191
 - 75 Kuo HT, Ye X, Sampaio MS, Reddy P, Bunnapradist S. Cytomegalovirus serostatus pairing and deceased donor kidney transplant outcomes in adult recipients with antiviral prophylaxis. *Transplantation* 2010;90(10):1091–1098
 - 76 Ugarte-Torres A, Hoegh-Petersen M, Liu Y, et al. Donor serostatus has an impact on cytomegalovirus-specific immunity, cytomegalovirus disease incidence, and survival in seropositive hematopoietic cell transplant recipients. *Biol Blood Marrow Transplant* 2011;17(4):574–585
 - 77 Zhou W, Longmate J, Lacey SF, et al. Impact of donor CMV status on viral infection and reconstitution of multifunction CMV-specific T cells in CMV-positive transplant recipients. *Blood* 2009;113(25):6465–6476
 - 78 Ljungman P, Brand R, Hoek J, et al; Infectious Diseases Working Party of the European Group for Blood and Marrow Transplantation. Donor cytomegalovirus status influences the outcome of allogeneic stem cell transplant: a study by the European group for blood and marrow transplantation. *Clin Infect Dis* 2014;59(4):473–481
 - 79 Ariza-Heredia EJ, Neshler L, Chemaly RF. Cytomegalovirus diseases after hematopoietic stem cell transplantation: a mini-review. *Cancer Lett* 2014;342(1):1–8
 - 80 Kotton CN, Kumar D, Caliendo AM, et al; Transplantation Society International CMV Consensus Group. Updated international consensus guidelines on the management of cytomegalovirus in solid-organ transplantation. *Transplantation* 2013;96(4):333–360
 - 81 Portela D, Patel R, Larson-Keller JJ, et al. OKT3 treatment for allograft rejection is a risk factor for cytomegalovirus disease in liver transplantation. *J Infect Dis* 1995;171(4):1014–1018
 - 82 Brown RA, Gralewski JH, Razonable RR. The R753Q polymorphism abrogates toll-like receptor 2 signaling in response to human cytomegalovirus. *Clin Infect Dis* 2009;49(9):e96–e99
 - 83 Cervera C, Lozano F, Linares L, et al. Influence of mannose-binding lectin gene polymorphisms on the invasiveness of cytomegalovirus disease after solid organ transplantation. *Transplant Proc* 2009;41(6):2259–2261
 - 84 Kang SH, Abdel-Masih RC, Brown RA, Dierkhising RA, Kremers WK, Razonable RR. Homozygosity for the toll-like receptor 2 R753Q single-nucleotide polymorphism is a risk factor for cytomegalovirus disease after liver transplantation. *J Infect Dis* 2012;205(4):639–646
 - 85 Cervera C, Lozano F, Saval N, et al. The influence of innate immunity gene receptors polymorphisms in renal transplant infections. *Transplantation* 2007;83(11):1493–1500
 - 86 Kwakkel-van Erp JM, Paantjens AW, van Kessel DA, et al. Mannose-binding lectin deficiency linked to cytomegalovirus (CMV) reactivation and survival in lung transplantation. *Clin Exp Immunol* 2011;165(3):410–416
 - 87 Abate D, Saldan A, Mengoli C, et al. Comparison of cytomegalovirus (CMV) enzyme-linked immunosorbent spot and CMV quantiferon gamma interferon-releasing assays in assessing risk of CMV infection in kidney transplant recipients. *J Clin Microbiol* 2013;51(8):2501–2507
 - 88 Goldfarb NS, Avery RK, Goormastic M, et al. Hypogammaglobulinemia in lung transplant recipients. *Transplantation* 2001;71(2):242–246

- 89 Cytovene [package insert]. San Francisco, CA: Genetech, Inc; 2010
- 90 Asberg A, Humar A, Rollag H, et al; VICTOR Study Group. Oral valganciclovir is noninferior to intravenous ganciclovir for the treatment of cytomegalovirus disease in solid organ transplant recipients. *Am J Transplant* 2007;7(9):2106–2113
- 91 Asberg A, Humar A, Jardine AG, et al; VICTOR Study Group. Long-term outcomes of CMV disease treatment with valganciclovir versus IV ganciclovir in solid organ transplant recipients. *Am J Transplant* 2009;9(5):1205–1213
- 92 Humar A, Kumar D, Boivin G, Caliendo AM. Cytomegalovirus (CMV) virus load kinetics to predict recurrent disease in solid-organ transplant patients with CMV disease. *J Infect Dis* 2002;186(6):829–833
- 93 Sullivan T, Brodgin A, Patel G, Huprikar S. The role of secondary cytomegalovirus prophylaxis for kidney and liver transplant recipients. *Transplantation* 2015;99(4):855–859
- 94 Alexander BT, Hladnik LM, Augustin KM, et al. Use of cytomegalovirus intravenous immune globulin for the adjunctive treatment of cytomegalovirus in hematopoietic stem cell transplant recipients. *Pharmacotherapy* 2010;30(6):554–561
- 95 Boivin G, Goyette N, Gilbert C, Humar A, Covington E. Clinical impact of ganciclovir-resistant cytomegalovirus infections in solid organ transplant patients. *Transpl Infect Dis* 2005;7(3–4):166–170
- 96 Limaye AP, Corey L, Koelle DM, Davis CL, Boeckh M. Emergence of ganciclovir-resistant cytomegalovirus disease among recipients of solid-organ transplants. *Lancet* 2000;356(9230):645–649
- 97 Lurain NS, Chou S. Antiviral drug resistance of human cytomegalovirus. *Clin Microbiol Rev* 2010;23(4):689–712
- 98 Mincec LR, Nguyen MH, Mitsani D, et al. Ganciclovir-resistant cytomegalovirus infections among lung transplant recipients are associated with poor outcomes despite treatment with foscarnet-containing regimens. *Antimicrob Agents Chemother* 2014;58(1):128–135
- 99 Mylonakis E, Kallas WM, Fishman JA. Combination antiviral therapy for ganciclovir-resistant cytomegalovirus infection in solid-organ transplant recipients. *Clin Infect Dis* 2002;34(10):1337–1341
- 100 Zuk DM, Humar A, Weinkauff JG, Lien DC, Nador RG, Kumar D. An international survey of cytomegalovirus management practices in lung transplantation. *Transplantation* 2010;90(6):672–676
- 101 Nashan B, Gaston R, Emery V, et al. Review of cytomegalovirus infection findings with mammalian target of rapamycin inhibitor-based immunosuppressive therapy in de novo renal transplant recipients. *Transplantation* 2012;93(11):1075–1085
- 102 Alain S, Revest M, Veyer D, et al. Maribavir use in practice for cytomegalovirus infection in French transplantation centers. *Transplant Proc* 2013;45(4):1603–1607
- 103 Avery RK, Marty FM, Strasfeld L, et al. Oral maribavir for treatment of refractory or resistant cytomegalovirus infections in transplant recipients. *Transpl Infect Dis* 2010;12(6):489–496
- 104 Chou S, Komazin-Meredith G, Williams JD, Bowlin TL. Cytomegalovirus mutants resistant to ganciclovir and cidofovir differ in susceptibilities to synguanol and its 6-ether and 6-thioether derivatives. *Antimicrob Agents Chemother* 2014;58(3):1809–1812
- 105 Härter G, Michel D. Antiviral treatment of cytomegalovirus infection: an update. *Expert Opin Pharmacother* 2012;13(5):623–627
- 106 Kaul DR, Stoelben S, Cober E, et al. First report of successful treatment of multidrug-resistant cytomegalovirus disease with the novel anti-CMV compound AIC246. *Am J Transplant* 2011;11(5):1079–1084
- 107 Levi ME, Mandava N, Chan LK, Weinberg A, Olson JL. Treatment of multidrug-resistant cytomegalovirus retinitis with systemically administered leflunomide. *Transpl Infect Dis* 2006;8(1):38–43
- 108 Marschall M, Stamminger T, Urban A, et al. In vitro evaluation of the activities of the novel anticytomegalovirus compound AIC246 (letermovir) against herpesviruses and other human pathogenic viruses. *Antimicrob Agents Chemother* 2012;56(2):1135–1137
- 109 Florescu D, Mercer D, Grimley M, et al. Brincidofovir (CMX001) for the treatment of serious or life-threatening double-stranded DNA virus infections in patients receiving liver transplant as part of multiorgan transplantation. Paper presented at: World Transplant Congress; July 26–31, 2014; San Francisco, CA. Abstract A2979
- 110 Mullane K, Florescu D, Kwak EJ, et al. Brincidofovir (CMX001) experience in renal transplant patients for treatment of refractory CMV infection. Paper presented at: World Transplant Congress; July 26–31, 2014; San Francisco, CA. Abstract D2364
- 111 Painter W, Robertson A, Trost LC, Godkin S, Lampert B, Painter G. First pharmacokinetic and safety study in humans of the novel lipid antiviral conjugate CMX001, a broad-spectrum oral drug active against double-stranded DNA viruses. *Antimicrob Agents Chemother* 2012;56(5):2726–2734
- 112 Asporid C, Laurin D, Richard MJ, Vie H, Chaperot L, Plumas J. Induction of antiviral cytotoxic T cells by plasmacytoid dendritic cells for adoptive immunotherapy of posttransplant diseases. *Am J Transplant* 2011;11(12):2613–2626
- 113 Gerdemann U, Katari UL, Papadopoulos A, et al. Safety and clinical efficacy of rapidly-generated trivirus-directed T cells as treatment for adenovirus, EBV, and CMV infections after allogeneic hematopoietic stem cell transplant. *Mol Ther* 2013;21(11):2113–2121
- 114 Bodro M, Sabé N, Lladó L, et al. Prophylaxis versus preemptive therapy for cytomegalovirus disease in high-risk liver transplant recipients. *Liver Transpl* 2012;18(9):1093–1099
- 115 Lautenschlager I, Loginov R, Mäkisalo H, Höckerstedt K. Prospective study on CMV-reactivations under preemptive strategy in CMV-seropositive adult liver transplant recipients. *J Clin Virol* 2013;57(1):50–53
- 116 Small LN, Lau J, Snyderman DR. Preventing post-organ transplantation cytomegalovirus disease with ganciclovir: a meta-analysis comparing prophylactic and preemptive therapies. *Clin Infect Dis* 2006;43(7):869–880
- 117 Opelz G, Döhler B, Ruhentrostroth A. Cytomegalovirus prophylaxis and graft outcome in solid organ transplantation: a collaborative transplant study report. *Am J Transplant* 2004;4(6):928–936
- 118 Opelz G, Döhler B. Reduced rate of cardiovascular death after cytomegalovirus prophylaxis in renal transplant recipients. *Transplantation* 2015;99(6):1197–1202
- 119 Malouf MA, Chhajed PN, Hopkins P, Plit M, Turner J, Glanville AR. Anti-viral prophylaxis reduces the incidence of lymphoproliferative disease in lung transplant recipients. *J Heart Lung Transplant* 2002;21(5):547–554
- 120 Munoz-Price LS, Slifkin M, Ruthazer R, et al. The clinical impact of ganciclovir prophylaxis on the occurrence of bacteremia in orthotopic liver transplant recipients. *Clin Infect Dis* 2004;39(9):1293–1299
- 121 Florescu DF, Qiu F, Schmidt CM, Kalil AC. A direct and indirect comparison meta-analysis on the efficacy of cytomegalovirus preventive strategies in solid organ transplant. *Clin Infect Dis* 2014;58(6):785–803
- 122 Manuel O, Kralidis G, Mueller NJ, et al; Swiss Transplant Cohort Study. Impact of antiviral preventive strategies on the incidence and outcomes of cytomegalovirus disease in solid organ transplant recipients. *Am J Transplant* 2013;13(9):2402–2410
- 123 Khoury JA, Storch GA, Bohl DL, et al. Prophylactic versus preemptive oral valganciclovir for the management of cytomegalovirus infection in adult renal transplant recipients. *Am J Transplant* 2006;6(9):2134–2143
- 124 Reischig T, Jindra P, Hes O, Svecová M, Klaboch J, Treska V. Valacyclovir prophylaxis versus preemptive valganciclovir therapy to prevent cytomegalovirus disease after renal transplantation. *Am J Transplant* 2008;8(1):69–77

- 125 Witzke O, Hauser IA, Bartels M, Wolf G, Wolters H, Nitschke M; VIPP Study Group. Valganciclovir prophylaxis versus preemptive therapy in cytomegalovirus-positive renal allograft recipients: 1-year results of a randomized clinical trial. *Transplantation* 2012; 93(1):61–68
- 126 Couzi L, Helou S, Bachelet T, et al. High incidence of anticytomegalovirus drug resistance among D+R- kidney transplant recipients receiving preemptive therapy. *Am J Transplant* 2012;12(1): 202–209
- 127 Kruger RM, Shannon WD, Arens MQ, Lynch JP, Storch GA, Trulock EP. The impact of ganciclovir-resistant cytomegalovirus infection after lung transplantation. *Transplantation* 1999;68(9): 1272–1279
- 128 Limaye AP, Raghu G, Koelle DM, Ferrenberg J, Huang ML, Boeckh M. High incidence of ganciclovir-resistant cytomegalovirus infection among lung transplant recipients receiving preemptive therapy. *J Infect Dis* 2002;185(1):20–27
- 129 Boeckh M, Nichols WG, Chemaly RF, et al. Valganciclovir for the prevention of complications of late cytomegalovirus infection after allogeneic hematopoietic cell transplantation: a randomized trial. *Ann Intern Med* 2015;162(1):1–10
- 130 Snyderman DR, Falagas ME, Avery R, et al. Use of combination cytomegalovirus immune globulin plus ganciclovir for prophylaxis in CMV-seronegative liver transplant recipients of a CMV-seropositive donor organ: a multicenter, open-label study. *Transplant Proc* 2001;33(4):2571–2575
- 131 Snyderman DR, Werner BG, Dougherty NN, et al; Boston Center for Liver Transplantation CMVIG Study Group. Cytomegalovirus immune globulin prophylaxis in liver transplantation. A randomized, double-blind, placebo-controlled trial. *Ann Intern Med* 1993;119(10):984–991
- 132 Zamora MR, Nicolls MR, Hodges TN, et al. Following universal prophylaxis with intravenous ganciclovir and cytomegalovirus immune globulin, valganciclovir is safe and effective for prevention of CMV infection following lung transplantation. *Am J Transplant* 2004;4(10):1635–1642
- 133 Stevens DR, Sawinski D, Blumberg E, Galanakis N, Bloom RD, Trofe-Clark J. Increased risk of breakthrough infection among cytomegalovirus donor-positive/recipient-negative kidney transplant recipients receiving lower-dose valganciclovir prophylaxis. *Transpl Infect Dis* 2015;17(2):163–173
- 134 Winston DJ, Saliba F, Blumberg E, et al; 1263–301 Clinical Study Group. Efficacy and safety of maribavir dosed at 100 mg orally twice daily for the prevention of cytomegalovirus disease in liver transplant recipients: a randomized, double-blind, multicenter controlled trial. *Am J Transplant* 2012;12(11): 3021–3030
- 135 Marty FM, Ljungman P, Papanicolaou GA, et al; Maribavir 1263-300 Clinical Study Group. Maribavir prophylaxis for prevention of cytomegalovirus disease in recipients of allogeneic stem-cell transplants: a phase 3, double-blind, placebo-controlled, randomized trial. *Lancet Infect Dis* 2011;11(4):284–292
- 136 Chemaly RF, Ullmann AJ, Stoelben S, et al; AIC246 Study Team. Letermovir for cytomegalovirus prophylaxis in hematopoietic-cell transplantation. *N Engl J Med* 2014;370(19):1781–1789
- 137 Marty FM, Winston DJ, Rowley SD, et al; CMX001-201 Clinical Study Group. CMX001 to prevent cytomegalovirus disease in hematopoietic-cell transplantation. *N Engl J Med* 2013;369(13): 1227–1236
- 138 Wiita AP, Roubinian N, Khan Y, et al. Cytomegalovirus disease and infection in lung transplant recipients in the setting of planned indefinite valganciclovir prophylaxis. *Transpl Infect Dis* 2012; 14(3):248–258
- 139 Gerna G, Lilleri D, Callegaro A, et al. Prophylaxis followed by preemptive therapy versus preemptive therapy for prevention of human cytomegalovirus disease in pediatric patients undergoing liver transplantation. *Transplantation* 2008;86(1): 163–166
- 140 Humar A, Paya C, Pescovitz MD, et al. Clinical utility of cytomegalovirus viral load testing for predicting CMV disease in D+/R-solid organ transplant recipients. *Am J Transplant* 2004;4(4): 644–649
- 141 Lisboa LF, Preiksaitis JK, Humar A, Kumar D. Clinical utility of molecular surveillance for cytomegalovirus after antiviral prophylaxis in high-risk solid organ transplant recipients. *Transplantation* 2011;92(9):1063–1068
- 142 Kumar D, Chernenko S, Moussa G, et al. Cell-mediated immunity to predict cytomegalovirus disease in high-risk solid organ transplant recipients. *Am J Transplant* 2009;9(5):1214–1222
- 143 Westall GP, Mifsud NA, Kotsimbos T. Linking CMV serostatus to episodes of CMV reactivation following lung transplantation by measuring CMV-specific CD8+ T-cell immunity. *Am J Transplant* 2008;8(8):1749–1754
- 144 Weseslindtner L, Kerschner H, Steinacher D, et al. Prospective analysis of human cytomegalovirus DNAemia and specific CD8+ T cell responses in lung transplant recipients. *Am J Transplant* 2012;12(8):2172–2180
- 145 Griffiths PD, Stanton A, McCarrell E, et al. Cytomegalovirus glycoprotein-B vaccine with MF59 adjuvant in transplant recipients: a phase 2 randomised placebo-controlled trial. *Lancet* 2011;377(9773):1256–1263
- 146 Kharfan-Dabaja MA, Boeckh M, Wilck MB, et al. A novel therapeutic cytomegalovirus DNA vaccine in allogeneic haemopoietic stem-cell transplantation: a randomised, double-blind, placebo-controlled, phase 2 trial. *Lancet Infect Dis* 2012; 12(4):290–299
- 147 Rieder F, Steininger C. Cytomegalovirus vaccine: phase II clinical trial results. *Clin Microbiol Infect* 2014;20(Suppl 5):95–102
- 148 Salimnia H, Fairfax MR, Chandrasekar PH. Detection and pharmacokinetics of a cytomegalovirus (CMV) DNA plasmid in human plasma during a clinical trial of an intramuscular CMV vaccine in hematopoietic stem cell transplant recipients. *Transpl Infect Dis* 2014;16(6):914–918
- 149 A study to evaluate a therapeutic vaccine, ASP0113, in cytomegalovirus (CMV)-seropositive recipients undergoing allogeneic, hematopoietic cell transplant (HCT) (HELIOS). Available at: <http://www.clinicaltrials.gov/ct2/show/NCT01877655?term=transvax+and+phase+3&rank=1>. Accessed June 22, 2016
- 150 Crawford DH. Biology and disease associations of Epstein-Barr virus. *Philos Trans R Soc Lond B Biol Sci* 2001;356(1408):461–473
- 151 Pereira MS, Blake JM, Macrae AD. EB virus antibody at different ages. *BMJ* 1969;4(5682):526–527
- 152 Tischendorf P, Shramek GJ, Balagtas RC, et al. Development and persistence of immunity to Epstein-Barr virus in man. *J Infect Dis* 1970;122(5):401–409
- 153 Balfour HH Jr, Sifakis F, Sliman JA, Knight JA, Schmeling DO, Thomas W. Age-specific prevalence of Epstein-Barr virus infection among individuals aged 6–19 years in the United States and factors affecting its acquisition. *J Infect Dis* 2013;208(8): 1286–1293
- 154 Henle G, Henle W. Immunofluorescence, interference, and complement fixation technics in the detection of the herpes-type virus in Burkitt tumor cell lines. *Cancer Res* 1967;27(12): 2442–2446
- 155 Porter DD, Wimberly I, Benyesh-Melnick M. Prevalence of antibodies to EB virus and other herpesviruses. *JAMA* 1969;208(9): 1675–1679
- 156 Higgins CD, Swerdlow AJ, Macsween KF, et al. A study of risk factors for acquisition of Epstein-Barr virus and its subtypes. *J Infect Dis* 2007;195(4):474–482
- 157 Allen U, Alfieri C, Preiksaitis J, et al; Canadian PTLD Workshop Group - 1999. Epstein-Barr virus infection in transplant recipients: Summary of a workshop on surveillance, prevention and treatment. *Can J Infect Dis Med Microbiol* 2002;13(2):89–99
- 158 Allen UD, Preiksaitis JK; AST Infectious Diseases Community of Practice. Epstein-Barr virus and posttransplant

- lymphoproliferative disorder in solid organ transplantation. *Am J Transplant* 2013;13(Suppl 4):107–120
- 159 Thorley-Lawson DA, Hawkins JB, Tracy SI, Shapiro M. The pathogenesis of Epstein-Barr virus persistent infection. *Curr Opin Virol* 2013;3(3):227–232
 - 160 de-Thé G, Geser A, Day NE, et al. Epidemiological evidence for causal relationship between Epstein-Barr virus and Burkitt's lymphoma from Ugandan prospective study. *Nature* 1978;274(5673):756–761
 - 161 Epstein MA, Achong BG, Barr YM. Virus Particles in Cultured Lymphoblasts from Burkitt's Lymphoma. *Lancet* 1964;1(7335):702–703
 - 162 Hjalgrim H, Askling J, Rostgaard K, et al. Characteristics of Hodgkin's lymphoma after infectious mononucleosis. *N Engl J Med* 2003;349(14):1324–1332
 - 163 Cohen JL. Epstein-Barr virus infection. *N Engl J Med* 2000;343(7):481–492
 - 164 Forte E, Luftig MA. The role of microRNAs in Epstein-Barr virus latency and lytic reactivation. *Microbes Infect* 2011;13(14–15):1156–1167
 - 165 Clark NM, Lynch JP III, Sayah D, Belperio JA, Fishbein MC, Weigt SS. DNA viral infections complicating lung transplantation. *Semin Respir Crit Care Med* 2013;34(3):380–404
 - 166 Nourse JP, Jones K, Gandhi MK. Epstein-Barr virus-related post-transplant lymphoproliferative disorders: pathogenetic insights for targeted therapy. *Am J Transplant* 2011;11(5):888–895
 - 167 Gulley ML, Swinnen LJ, Plaisance KT Jr, Schnell C, Grogan TM, Schneider BG; Southwest Oncology Group. Tumor origin and CD20 expression in posttransplant lymphoproliferative disorder occurring in solid organ transplant recipients: implications for immune-based therapy. *Transplantation* 2003;76(6):959–964
 - 168 Verschuuren E, van der Bij W, de Boer W, Timens W, Middeldorp J, The TH. Quantitative Epstein-Barr virus (EBV) serology in lung transplant recipients with primary EBV infection and/or post-transplant lymphoproliferative disease. *J Med Virol* 2003;69(2):258–266
 - 169 Kinch A, Cavellier L, Bengtsson M, et al. Donor or recipient origin of posttransplant lymphoproliferative disorders following solid organ transplantation. *Am J Transplant* 2014;14(12):2838–2845
 - 170 Olagne J, Caillard S, Gaub MP, Chenard MP, Moulin B. Post-transplant lymphoproliferative disorders: determination of donor/recipient origin in a large cohort of kidney recipients. *Am J Transplant* 2011;11(6):1260–1269
 - 171 Sanz J, Arango M, Senent L, et al. EBV-associated post-transplant lymphoproliferative disorder after umbilical cord blood transplantation in adults with hematological diseases. *Bone Marrow Transplant* 2014;49(3):397–402
 - 172 Dierickx D, Tousseyn T, Gheysens O. How I treat posttransplant lymphoproliferative disorders. *Blood* 2015;126(20):2274–2283
 - 173 Caillard S, Lamy FX, Quelen C, et al; French Transplant Centers. Epidemiology of posttransplant lymphoproliferative disorders in adult kidney and kidney pancreas recipients: report of the French registry and analysis of subgroups of lymphomas. *Am J Transplant* 2012;12(3):682–693
 - 174 Tai R, Tirumani SH, Tirumani H, Shinagare AB, Hornick JL, Ramaiya NH. Is there a difference in post-transplant lymphoproliferative disorder in adults after solid organ and haematologic stem cell transplantation? Experience in 41 patients. *Br J Radiol* 2015;88(1052):20140861
 - 175 Xu LP, Zhang CL, Mo XD, et al. Epstein-Barr virus-related post-transplantation lymphoproliferative disorder after unmanipulated human leukocyte antigen haploidentical hematopoietic stem cell transplantation: incidence, risk factors, treatment, and clinical outcomes. *Biol Blood Marrow Transplant* 2015;21(12):2185–2191
 - 176 Jensen HB. Epstein-Barr virus. *Pediatr Rev* 2011;32(9):375–383, quiz 384
 - 177 Mughtar E, Kramer MR, Vidal L, et al. Posttransplantation lymphoproliferative disorder in lung transplant recipients: a 15-year single institution experience. *Transplantation* 2013;96(7):657–663
 - 178 Vakiani E, Basso K, Klein U, et al. Genetic and phenotypic analysis of B-cell post-transplant lymphoproliferative disorders provides insights into disease biology. *Hematol Oncol* 2008;26(4):199–211
 - 179 Green M, Michaels MG. Epstein-Barr virus infection and post-transplant lymphoproliferative disorder. *Am J Transplant* 2013;13(Suppl 3):41–54, quiz 54
 - 180 Kremer BE, Reshef R, Misleh JG, et al. Post-transplant lymphoproliferative disorder after lung transplantation: a review of 35 cases. *J Heart Lung Transplant* 2012;31(3):296–304
 - 181 Franquet T. Imaging of pulmonary viral pneumonia. *Radiology* 2011;260(1):18–39
 - 182 Krumbholz A, Sandhaus T, Göhlert A, et al. Epstein-Barr virus-associated pneumonia and bronchiolitis obliterans syndrome in a lung transplant recipient. *Med Microbiol Immunol (Berl)* 2010;199(4):317–322
 - 183 Thijsen SF, Luderer R, van Gorp JM, Oudejans SJ, Bossink AW. A possible role for Epstein-Barr virus in the pathogenesis of pleural effusion. *Eur Respir J* 2005;26(4):662–666
 - 184 Takei H, Mody D. Epstein-Barr virus-positive pleural effusion: Clinical features, cytomorphologic characteristics, and flow cytometric immunophenotyping. *Am J Clin Pathol* 2014;142(6):788–794
 - 185 Brescia AA, Khullar OV, Gal AA, Neujahr D, Force SD. Epstein-Barr virus-associated pulmonary smooth muscle tumor after lung transplantation. *Ann Thorac Surg* 2015;99(6):e145–e146
 - 186 Huang J, Loh KS, Petersson F. Epstein-barr virus-associated smooth muscle tumor of the larynx: report of a rare case mimicking leiomyosarcoma. *Head Neck Pathol* 2010;4(4):300–304
 - 187 Tsai DE, Douglas L, Andreadis C, et al. EBV PCR in the diagnosis and monitoring of posttransplant lymphoproliferative disorder: results of a two-arm prospective trial. *Am J Transplant* 2008;8(5):1016–1024
 - 188 Michelson P, Watkins B, Webber SA, Wadowsky R, Michaels MG. Screening for PTLD in lung and heart-lung transplant recipients by measuring EBV DNA load in bronchoalveolar lavage fluid using real time PCR. *Pediatr Transplant* 2008;12(4):464–468
 - 189 Liu QF, Fan ZP, Luo XD, Sun J, Zhang Y, Ding YQ. Epstein-Barr virus-associated pneumonia in patients with post-transplant lymphoproliferative disease after hematopoietic stem cell transplantation. *Transpl Infect Dis* 2010;12(4):284–291
 - 190 Panagiotidis E, Quigley AM, Pencharz D, et al. (18)F-fluorodeoxyglucose positron emission tomography/computed tomography in diagnosis of post-transplant lymphoproliferative disorder. *Leuk Lymphoma* 2014;55(3):515–519
 - 191 Bustami RT, Ojo AO, Wolfe RA, et al. Immunosuppression and the risk of post-transplant malignancy among cadaveric first kidney transplant recipients. *Am J Transplant* 2004;4(1):87–93
 - 192 Opelz G, Döhler B. Lymphomas after solid organ transplantation: a collaborative transplant study report. *Am J Transplant* 2004;4(2):222–230
 - 193 Duvoux C, Pageaux GP, Vanlemmens C, et al. Risk factors for lymphoproliferative disorders after liver transplantation in adults: an analysis of 480 patients. *Transplantation* 2002;74(8):1103–1109
 - 194 Sundin M, Le Blanc K, Ringdén O, et al. The role of HLA mismatch, splenectomy and recipient Epstein-Barr virus seronegativity as risk factors in post-transplant lymphoproliferative disorder following allogeneic hematopoietic stem cell transplantation. *Haematologica* 2006;91(8):1059–1067
 - 195 Aull MJ, Buell JF, Trofe J, et al. Experience with 274 cardiac transplant recipients with posttransplant lymphoproliferative

- disorder: a report from the Israel Penn International Transplant Tumor Registry. *Transplantation* 2004;78(11):1676–1682
- 196 Reshef R, Vardhanabhuti S, Luskin MR, et al. Reduction of immunosuppression as initial therapy for posttransplantation lymphoproliferative disorder. *Am J Transplant* 2011;11(2):336–347
 - 197 Petrara MR, Giunco S, Serraino D, Dolcetti R, De Rossi A. Post-transplant lymphoproliferative disorders: from epidemiology to pathogenesis-driven treatment. *Cancer Lett* 2015;369(1):37–44
 - 198 Taplitz RA, Jordan MC. Pneumonia caused by herpesviruses in recipients of hematopoietic cell transplants. *Semin Respir Infect* 2002;17(2):121–129
 - 199 Schauer E, Webber S, Kingsley L, Green M, Rowe D. Increased Ig-null B lymphocytes in the peripheral blood of pediatric solid organ transplant recipients with elevated Epstein-Barr viral loads. *Pediatr Transplant* 2009;13(3):311–318
 - 200 Friedrichs C, Neyts J, Gaspar G, De Clercq E, Wutzler P. Evaluation of antiviral activity against human herpesvirus 8 (HHV-8) and Epstein-Barr virus (EBV) by a quantitative real-time PCR assay. *Antiviral Res* 2004;62(3):121–123
 - 201 Keever-Taylor CA, Behn B, Konings S, Orentas R, Davies B, Margolis D. Suppression of EBV release from irradiated B lymphoblastoid cell-lines: superior activity of ganciclovir compared with acyclovir. *Cytotherapy* 2003;5(4):323–335
 - 202 Chan TS, Hwang YY, Gill H, et al. Post-transplant lymphoproliferative diseases in Asian solid organ transplant recipients: late onset and favorable response to treatment. *Clin Transplant* 2012;26(5):679–683
 - 203 Elstrom RL, Andreadis C, Aquil NA, et al. Treatment of PTLD with rituximab or chemotherapy. *Am J Transplant* 2006;6(3):569–576
 - 204 Orjuela MA, Alobeid B, Liu X, et al. CD20 expression predicts survival in paediatric post-transplant lymphoproliferative disease (PTLD) following solid organ transplantation. *Br J Haematol* 2011;152(6):733–742
 - 205 Trappe R, Oertel S, Leblond V, et al; German PTLD Study Group; European PTLD Network. Sequential treatment with rituximab followed by CHOP chemotherapy in adult B-cell post-transplant lymphoproliferative disorder (PTLD): the prospective international multicentre phase 2 PTLD-1 trial. *Lancet Oncol* 2012;13(2):196–206
 - 206 Bollard CM, Gottschalk S, Torrano V, et al. Sustained complete responses in patients with lymphoma receiving autologous cytotoxic T lymphocytes targeting Epstein-Barr virus latent membrane proteins. *J Clin Oncol* 2014;32(8):798–808
 - 207 Doubrovina E, Oflaz-Sozmen B, Prockop SE, et al. Adoptive immunotherapy with unselected or EBV-specific T cells for biopsy-proven EBV+ lymphomas after allogeneic hematopoietic cell transplantation. *Blood* 2012;119(11):2644–2656
 - 208 Sherritt MA, Bharadwaj M, Burrows JM, et al. Reconstitution of the latent T-lymphocyte response to Epstein-Barr virus is coincident with long-term recovery from posttransplant lymphoma after adoptive immunotherapy. *Transplantation* 2003;75(9):1556–1560
 - 209 Styczynski J, Einsele H, Gil L, Ljungman P. Outcome of treatment of Epstein-Barr virus-related post-transplant lymphoproliferative disorder in hematopoietic stem cell recipients: a comprehensive review of reported cases. *Transpl Infect Dis* 2009;11(5):383–392
 - 210 Cullis B, D'Souza R, McCullagh P, et al. Sirolimus-induced remission of posttransplantation lymphoproliferative disorder. *Am J Kidney Dis* 2006;47(5):e67–e72
 - 211 Boratyńska M, Smolska D. Inhibition of mTOR by sirolimus induces remission of post-transplant lymphoproliferative disorders. *Transpl Int* 2008;21(6):605–608
 - 212 Boratyńska M, Watorek E, Smolska D, Patrzalek D, Klinger M. Anticancer effect of sirolimus in renal allograft recipients with de novo malignancies. *Transplant Proc* 2007;39(9):2736–2739
 - 213 Ashrafi F, Shahidi S, Ebrahimi Z, Mortazavi M. Outcome of rapamycin therapy for post-transplant-lymphoproliferative disorder after kidney transplantation: case series. *Int J Hematol Oncol Stem Cell Res* 2015;9(1):26–32
 - 214 Krams SM, Martinez OM. Epstein-Barr virus, rapamycin, and host immune responses. *Curr Opin Organ Transplant* 2008;13(6):563–568
 - 215 Opelz G, Daniel V, Naujokat C, Fickenscher H, Döhler B. Effect of cytomegalovirus prophylaxis with immunoglobulin or with antiviral drugs on post-transplant non-Hodgkin lymphoma: a multicentre retrospective analysis. *Lancet Oncol* 2007;8(3):212–218
 - 216 Humar A. Reactivation of viruses in solid organ transplant patients receiving cytomegalovirus prophylaxis. *Transplantation* 2006;82(2, Suppl)S9–S14
 - 217 Höcker B, Böhm S, Fickenscher H, et al. (Val-)Ganciclovir prophylaxis reduces Epstein-Barr virus primary infection in pediatric renal transplantation. *Transpl Int* 2012;25(7):723–731
 - 218 Jaksch P, Wiedemann D, Kocher A, Muraközy G, Augustin V, Klepetko W. Effect of cytomegalovirus immunoglobulin on the incidence of lymphoproliferative disease after lung transplantation: single-center experience with 1157 patients. *Transplantation* 2013;95(5):766–772
 - 219 Green M, Michaels MG, Katz BZ, et al. CMV-IVIG for prevention of Epstein Barr virus disease and posttransplant lymphoproliferative disease in pediatric liver transplant recipients. *Am J Transplant* 2006;6(8):1906–1912
 - 220 Humar A, Hébert D, Davies HD, et al. A randomized trial of ganciclovir versus ganciclovir plus immune globulin for prophylaxis against Epstein-Barr virus related posttransplant lymphoproliferative disorder. *Transplantation* 2006;81(6):856–861
 - 221 Manlhiot C, Pollock-Barziv SM, Holmes C, et al. Post-transplant lymphoproliferative disorder in pediatric heart transplant recipients. *J Heart Lung Transplant* 2010;29(6):648–657
 - 222 Funch DP, Walker AM, Schneider G, Ziyadeh NJ, Pescovitz MD. Ganciclovir and acyclovir reduce the risk of post-transplant lymphoproliferative disorder in renal transplant recipients. *Am J Transplant* 2005;5(12):2894–2900
 - 223 Hierro L, Díez-Dorado R, Díaz C, et al. Efficacy and safety of valganciclovir in liver-transplanted children infected with Epstein-Barr virus. *Liver Transpl* 2008;14(8):1185–1193
 - 224 Venturi C, Bueno J, Gavalda J, et al. Impact of valganciclovir on Epstein-Barr virus polymerase chain reaction in pediatric liver transplantation: preliminary report. *Transplant Proc* 2009;41(3):1038–1040
 - 225 Xu F, Sternberg MR, Kottiri BJ, et al. Trends in herpes simplex virus type 1 and type 2 seroprevalence in the United States. *JAMA* 2006;296(8):964–973
 - 226 Tronstein E, Johnston C, Huang ML, et al. Genital shedding of herpes simplex virus among symptomatic and asymptomatic persons with HSV-2 infection. *JAMA* 2011;305(14):1441–1449
 - 227 Nahmias AJ, Roizman B. Infection with herpes-simplex viruses 1 and 2. *N Engl J Med* 1973;289(15):781–789
 - 228 Corey L, Spear PG. Infections with herpes simplex viruses. *N Engl J Med* 1986;314(11):686–691
 - 229 Engelberg R, Carrell D, Krantz E, Corey L, Wald A. Natural history of genital herpes simplex virus type 1 infection. *Sex Transm Dis* 2003;30(2):174–177
 - 230 Lafferty WE, Coombs RW, Benedetti J, Critchlow C, Corey L. Recurrences after oral and genital herpes simplex virus infection. Influence of site of infection and viral type. *N Engl J Med* 1987;316(23):1444–1449
 - 231 Whitley RJ. Viral encephalitis. *N Engl J Med* 1990;323(4):242–250
 - 232 Singh N, Dummer JS, Kusne S, et al. Infections with cytomegalovirus and other herpesviruses in 121 liver transplant recipients: transmission by donated organ and the effect of OKT3 antibodies. *J Infect Dis* 1988;158(1):124–131

- 233 Simoons-Smit AM, Kraan EM, Beishuizen A, Strack van Schijndel RJ, Vandenbroucke-Grauls CM. Herpes simplex virus type 1 and respiratory disease in critically-ill patients: Real pathogen or innocent bystander? *Clin Microbiol Infect* 2006;12(11):1050-1059
- 234 Smyth RL, Higenbottam TW, Scott JP, et al. Herpes simplex virus infection in heart-lung transplant recipients. *Transplantation* 1990;49(4):735-739
- 235 Engelmann I, Gottlieb J, Meier A, et al. Clinical relevance of and risk factors for HSV-related tracheobronchitis or pneumonia: results of an outbreak investigation. *Crit Care* 2007;11(6):R119
- 236 Brodoefel H, Vogel M, Spira D, et al. Herpes-Simplex-Virus 1 pneumonia in the immunocompromised host: high-resolution CT patterns in correlation to outcome and follow-up. *Eur J Radiol* 2012;81(4):e415-e420
- 237 Kusne S, Schwartz M, Breinig MK, et al. Herpes simplex virus hepatitis after solid organ transplantation in adults. *J Infect Dis* 1991;163(5):1001-1007
- 238 Lepiller Q, Sueur C, Solis M, et al. Clinical relevance of herpes simplex virus viremia in Intensive Care Unit patients. *J Infect* 2015;71(1):93-100
- 239 Ramaswamy M, McDonald C, Smith M, et al. Diagnosis of genital herpes by real time PCR in routine clinical practice. *Sex Transm Infect* 2004;80(5):406-410
- 240 Boivin G. Diagnosis of herpesvirus infections of the central nervous system. *Herpes* 2004;11(Suppl 2):48A-56A
- 241 Linssen CF, Jacobs JA, Stelma FF, et al. Herpes simplex virus load in bronchoalveolar lavage fluid is related to poor outcome in critically ill patients. *Intensive Care Med* 2008;34(12):2202-2209
- 242 Witt MN, Braun GS, Ihrler S, Schmid H. Occurrence of HSV-1-induced pneumonitis in patients under standard immunosuppressive therapy for rheumatic, vasculitic, and connective tissue disease. *BMC Pulm Med* 2009;9:22
- 243 British Society for Antimicrobial Chemotherapy Working Party on Antiviral Therapy. Management of herpes virus infections following transplantation. *J Antimicrob Chemother* 2000;45(6):729-748
- 244 Chou S, Gallagher JG, Merigan TC. Controlled clinical trial of intravenous acyclovir in heart-transplant patients with mucocutaneous herpes simplex infections. *Lancet* 1981;1(8235):1392-1394
- 245 Tan HH, Goh CL. Viral infections affecting the skin in organ transplant recipients: epidemiology and current management strategies. *Am J Clin Dermatol* 2006;7(1):13-29
- 246 Danve-Szatanek C, Aymard M, Thouvenot D, et al. Surveillance network for herpes simplex virus resistance to antiviral drugs: 3-year follow-up. *J Clin Microbiol* 2004;42(1):242-249
- 247 Wilck MB, Zuckerman RA; AST Infectious Diseases Community of Practice. Herpes simplex virus in solid organ transplantation. *Am J Transplant* 2013;13(Suppl 4):121-127
- 248 Muluneh B, Dean A, Armistead P, Khan T. Successful clearance of cutaneous acyclovir-resistant, foscarnet-refractory herpes virus lesions with topical cidofovir in an allogeneic hematopoietic stem cell transplant patient. *J Oncol Pharm Pract* 2013;19(2):181-185
- 249 Corey L, Wald A, Patel R, et al; Valacyclovir HSV Transmission Study Group. Once-daily valacyclovir to reduce the risk of transmission of genital herpes. *N Engl J Med* 2004;350(1):11-20
- 250 Sørensen GV, Rosthøj S, Würtz M, Danielsen TK, Schrøder H. The epidemiology of herpes zoster in 226 children with acute lymphoblastic leukemia. *Pediatr Blood Cancer* 2011;57(6):993-997
- 251 Su SH, Martel-Laferrrière V, Labbé AC, et al. High incidence of herpes zoster in nonmyeloablative hematopoietic stem cell transplantation. *Biol Blood Marrow Transplant* 2011;17(7):1012-1017
- 252 Pergam SA, Forsberg CW, Boeckh MJ, et al. Herpes zoster incidence in a multicenter cohort of solid organ transplant recipients. *Transpl Infect Dis* 2011;13(1):15-23
- 253 Razonable RR, Brown RA, Humar A, Covington E, Alecock E, Paya CV; PV16000 Study Group. Herpesvirus infections in solid organ transplant patients at high risk of primary cytomegalovirus disease. *J Infect Dis* 2005;192(8):1331-1339
- 254 Mustapic Z, Basic-Jukic N, Kes P, et al. Varicella zoster infection in renal transplant recipients: prevalence, complications and outcome. *Kidney Blood Press Res* 2011;34(6):382-386
- 255 Manuel O, Kumar D, Singer LG, Cobos I, Humar A. Incidence and clinical characteristics of herpes zoster after lung transplantation. *J Heart Lung Transplant* 2008;27(1):11-16
- 256 Sauerbrei A, Taut J, Zell R, Wutzler P. Resistance testing of clinical varicella-zoster virus strains. *Antiviral Res* 2011;90(3):242-247
- 257 Gnann JW Jr, Whitley RJ. Clinical practice. Herpes zoster. *N Engl J Med* 2002;347(5):340-346
- 258 Chow J, Golan Y. Vaccination of solid-organ transplantation candidates. *Clin Infect Dis* 2009;49(10):1550-1556
- 259 Gershon AA, Gershon MD, Breuer J, Levin MJ, Oaklander AL, Griffiths PD. Advances in the understanding of the pathogenesis and epidemiology of herpes zoster. *J Clin Virol* 2010;48(Suppl 1):S2-S7
- 260 Wiegering V, Schick J, Beer M, et al. Varicella-zoster virus infections in immunocompromised patients - a single centre 6-years analysis. *BMC Pediatr* 2011;11:31
- 261 Matsuzaki A, Suminoe A, Koga Y, et al. Fatal visceral varicella-zoster virus infection without skin involvement in a child with acute lymphoblastic leukemia. *Pediatr Hematol Oncol* 2008;25(3):237-242
- 262 Buchbinder SP, Katz MH, Hessel NA, et al. Herpes zoster and human immunodeficiency virus infection. *J Infect Dis* 1992;166(5):1153-1156
- 263 Gourishankar S, McDermid JC, Jhangri GS, Preiksaitis JK. Herpes zoster infection following solid organ transplantation: incidence, risk factors and outcomes in the current immunosuppressive era. *Am J Transplant* 2004;4(1):108-115
- 264 Arness T, Pedersen R, Dierkhising R, Kremers W, Patel R. Varicella zoster virus-associated disease in adult kidney transplant recipients: incidence and risk-factor analysis. *Transpl Infect Dis* 2008;10(4):260-268
- 265 Levitsky J, Kalil A, Meza JL, Hurst GE, Freifeld A. Herpes zoster infection after liver transplantation: a case-control study. *Liver Transpl* 2005;11(3):320-325
- 266 Herrero JJ, Quiroga J, Sangro B, et al. Herpes zoster after liver transplantation: incidence, risk factors, and complications. *Liver Transpl* 2004;10(9):1140-1143
- 267 Hsu RB, Fang CT, Chang SC, et al. Infectious complications after heart transplantation in Chinese recipients. *Am J Transplant* 2005;5(8):2011-2016
- 268 Fuks L, Shitrit D, Fox BD, et al. Herpes zoster after lung transplantation: incidence, timing, and outcome. *Ann Thorac Surg* 2009;87(2):423-426
- 269 Leung TF, Chik KW, Li CK, et al. Incidence, risk factors and outcome of varicella-zoster virus infection in children after haematopoietic stem cell transplantation. *Bone Marrow Transplant* 2000;25(2):167-172
- 270 Choo PW, Donahue JG, Manson JE, Platt R. The epidemiology of varicella and its complications. *J Infect Dis* 1995;172(3):706-712
- 271 Weigle KA, Grose C. Varicella pneumonitis: immunodiagnosis with a monoclonal antibody. *J Pediatr* 1984;105(2):265-269
- 272 Mohsen AH, McKendrick M. Varicella pneumonia in adults. *Eur Respir J* 2003;21(5):886-891
- 273 Weinstein L, Meade RH. Respiratory manifestations of chicken pox; special consideration of the features of primary varicella pneumonia. *AMA Arch Intern Med* 1956;98(1):91-99
- 274 Popara M, Pendle S, Sacks L, Smego RA Jr, Mer M. Varicella pneumonia in patients with HIV/AIDS. *Int J Infect Dis* 2002;6(1):6-8

- 275 Mohsen AH, Peck RJ, Mason Z, Mattock L, McKendrick MW. Lung function tests and risk factors for pneumonia in adults with chickenpox. *Thorax* 2001;56(10):796–799
- 276 de Jong MD, Weel JF, van Oers MH, Boom R, Wertheim-van Dillen PM. Molecular diagnosis of visceral herpes zoster. *Lancet* 2001;357(9274):2101–2102
- 277 Dworkin RH, Johnson RW, Breuer J, et al. Recommendations for the management of herpes zoster. *Clin Infect Dis* 2007;44(Suppl 1):S1–S26
- 278 Brink AA, van Gelder M, Wolffs PF, Bruggeman CA, van Loo IH. Compartmentalization of acyclovir-resistant varicella zoster virus: implications for sampling in molecular diagnostics. *Clin Infect Dis* 2011;52(8):982–987
- 279 Hatchette T, Tipples GA, Peters G, Alsuwaidi A, Zhou J, Mailman TL. Foscarnet salvage therapy for acyclovir-resistant varicella zoster: report of a novel thymidine kinase mutation and review of the literature. *Pediatr Infect Dis J* 2008;27(1):75–77
- 280 Lee MY, Kim KS, Lee WK. Intravitreal foscarnet for the treatment of acyclovir-resistant acute retinal necrosis caused by varicella zoster virus. *Ocul Immunol Inflamm* 2011;19(3):212–213
- 281 Visse B, Dumont B, Huraux JM, Fillet AM. Single amino acid change in DNA polymerase is associated with foscarnet resistance in a varicella-zoster virus strain recovered from a patient with AIDS. *J Infect Dis* 1998;178(Suppl 1):S55–S57
- 282 Pergam SA, Limaye AP; AST Infectious Diseases Community of Practice. Varicella zoster virus in solid organ transplantation. *Am J Transplant* 2013;13(Suppl 4):138–146
- 283 Rogers JE, Cumpston A, Newton M, Craig M. Onset and complications of varicella zoster reactivation in the autologous hematopoietic cell transplant population. *Transpl Infect Dis* 2011;13(5):480–484
- 284 Boeckh M, Kim HW, Flowers ME, Meyers JD, Bowden RA. Long-term acyclovir for prevention of varicella zoster virus disease after allogeneic hematopoietic cell transplantation—a randomized double-blind placebo-controlled study. *Blood* 2006;107(5):1800–1805
- 285 Erard V, Guthrie KA, Varley C, et al. One-year acyclovir prophylaxis for preventing varicella-zoster virus disease after hematopoietic cell transplantation: no evidence of rebound varicella-zoster virus disease after drug discontinuation. *Blood* 2007;110(8):3071–3077
- 286 Oxman MN, Levin MJ, Johnson GR, et al; Shingles Prevention Study Group. A vaccine to prevent herpes zoster and postherpetic neuralgia in older adults. *N Engl J Med* 2005;352(22):2271–2284
- 287 Sanford M, Keating GM. Zoster vaccine (Zostavax): a review of its use in preventing herpes zoster and postherpetic neuralgia in older adults. *Drugs Aging* 2010;27(2):159–176
- 288 Löbermann M, Boršo D, Hilgendorf I, Fritzsche C, Zettl UK, Reisinger EC. Immunization in the adult immunocompromised host. *Autoimmun Rev* 2012;11(3):212–218
- 289 Avery RK, Michaels M. Update on immunizations in solid organ transplant recipients: what clinicians need to know. *Am J Transplant* 2008;8(1):9–14
- 290 Cohen JL. Strategies for herpes zoster vaccination of immunocompromised patients. *J Infect Dis* 2008;197(Suppl 2):S237–S241
- 291 Rubin LG, Levin MJ, Ljungman P, et al; Infectious Diseases Society of America. 2013 IDSA clinical practice guideline for vaccination of the immunocompromised host. *Clin Infect Dis* 2014;58(3):e44–e100
- 292 Danziger-Isakov L, Kumar D; AST Infectious Diseases Community of Practice. Vaccination in solid organ transplantation. *Am J Transplant* 2013;13(Suppl 4):311–317
- 293 Salahuddin SZ, Ablashi DV, Markham PD, et al. Isolation of a new virus, HBLV, in patients with lymphoproliferative disorders. *Science* 1986;234(4776):596–601
- 294 Agut H. Deciphering the clinical impact of acute human herpesvirus 6 (HHV-6) infections. *J Clin Virol* 2011;52(3):164–171
- 295 Ogata M, Fukuda T, Teshima T. Human herpesvirus-6 encephalitis after allogeneic hematopoietic cell transplantation: what we do and do not know. *Bone Marrow Transplant* 2015;50(8):1030–1036
- 296 De Bolle L, Naesens L, De Clercq E. Update on human herpesvirus 6 biology, clinical features, and therapy. *Clin Microbiol Rev* 2005;18(1):217–245
- 297 Zerr DM, Meier AS, Selke SS, et al. A population-based study of primary human herpesvirus 6 infection. *N Engl J Med* 2005;352(8):768–776
- 298 Hall CB, Caserta MT, Schnabel K, et al. Chromosomal integration of human herpesvirus 6 is the major mode of congenital human herpesvirus 6 infection. *Pediatrics* 2008;122(3):513–520
- 299 Cervera C, Marcos MA, Linares L, et al. A prospective survey of human herpesvirus-6 primary infection in solid organ transplant recipients. *Transplantation* 2006;82(7):979–982
- 300 Lautenschlager I, Razonable RR. Human herpesvirus-6 infections in kidney, liver, lung, and heart transplantation: review. *Transpl Int* 2012;25(5):493–502
- 301 Hall CB, Caserta MT, Schnabel KC, et al. Persistence of human herpesvirus 6 according to site and variant: possible greater neurotropism of variant A. *Clin Infect Dis* 1998;26(1):132–137
- 302 Bates M, Monze M, Bima H, et al. Predominant human herpesvirus 6 variant A infant infections in an HIV-1 endemic region of Sub-Saharan Africa. *J Med Virol* 2009;81(5):779–789
- 303 Pellett PE, Ablashi DV, Ambros PF, et al. Chromosomally integrated human herpesvirus 6: questions and answers. *Rev Med Virol* 2012;22(3):144–155
- 304 Leong HN, Tuke PW, Tedder RS, et al. The prevalence of chromosomally integrated human herpesvirus 6 genomes in the blood of UK blood donors. *J Med Virol* 2007;79(1):45–51
- 305 Yamanishi K, Okuno T, Shiraki K, et al. Identification of human herpesvirus-6 as a causal agent for exanthem subitum. *Lancet* 1988;1(8594):1065–1067
- 306 Asano Y, Yoshikawa T, Suga S, et al. Viremia and neutralizing antibody response in infants with exanthem subitum. *J Pediatr* 1989;114(4 Pt 1):535–539
- 307 Asano Y, Yoshikawa T, Suga S, et al. Clinical features of infants with primary human herpesvirus 6 infection (exanthem subitum, roseola infantum). *Pediatrics* 1994;93(1):104–108
- 308 Zhou W, Lin F, Teng L, et al. Prevalence of herpes and respiratory viruses in induced sputum among hospitalized children with non typical bacterial community-acquired pneumonia. *PLoS ONE* 2013;8(11):e79477
- 309 Hall CB, Long CE, Schnabel KC, et al. Human herpesvirus-6 infection in children. A prospective study of complications and reactivation. *N Engl J Med* 1994;331(7):432–438
- 310 Pruksananonda P, Hall CB, Insel RA, et al. Primary human herpesvirus 6 infection in young children. *N Engl J Med* 1992;326(22):1445–1450
- 311 Kositanont U, Wasi C, Wanprapar N, et al. Primary infection of human herpesvirus 6 in children with vertical infection of human immunodeficiency virus type 1. *J Infect Dis* 1999;180(1):50–55
- 312 Tembo J, Kabwe M, Chilukutu L, et al. Prevalence and risk factors for betaherpesvirus DNAemia in children >3 weeks and <2 years of age admitted to a large referral hospital in sub-Saharan Africa. *Clin Infect Dis* 2015;60(3):423–431
- 313 Kasolo FC, Mpabalwani E, Gompels UA. Infection with AIDS-related herpesviruses in human immunodeficiency virus-negative infants and endemic childhood Kaposi's sarcoma in Africa. *J Gen Virol* 1997;78(Pt 4):847–855
- 314 Revest M, Minjolle S, Veyer D, Lagathu G, Michelet C, Colimon R. Detection of HHV-6 in over a thousand samples: new types of infection revealed by an analysis of positive results. *J Clin Virol* 2011;51(1):20–24

- 315 Al-Zubeidi D, Thangarajh M, Pathak S, et al. Fatal human herpesvirus 6-associated encephalitis in two boys with underlying POLG mitochondrial disorders. *Pediatr Neurol* 2014;51(3):448–452
- 316 Yao K, Crawford JR, Komaroff AL, Ablashi DV, Jacobson S. Review part 2: Human herpesvirus-6 in central nervous system diseases. *J Med Virol* 2010;82(10):1669–1678
- 317 Leibovitch EC, Jacobson S. Evidence linking HHV-6 with multiple sclerosis: an update. *Curr Opin Virol* 2014;9:127–133
- 318 Opsahl ML, Kennedy PG. Early and late HHV-6 gene transcripts in multiple sclerosis lesions and normal appearing white matter. *Brain* 2005;128(Pt 3):516–527
- 319 Yoshikawa T, Ihira M, Suzuki K, et al. Fatal acute myocarditis in an infant with human herpesvirus 6 infection. *J Clin Pathol* 2001;54(10):792–795
- 320 Comar M, D'Agaro P, Campello C, et al. Human herpes virus 6 in archival cardiac tissues from children with idiopathic dilated cardiomyopathy or congenital heart disease. *J Clin Pathol* 2009;62(1):80–83
- 321 Caruso A, Favilli F, Rotola A, et al. Human herpesvirus-6 modulates RANTES production in primary human endothelial cell cultures. *J Med Virol* 2003;70(3):451–458
- 322 Cone RW, Hackman RC, Huang ML, et al. Human herpesvirus 6 in lung tissue from patients with pneumonitis after bone marrow transplantation. *N Engl J Med* 1993;329(3):156–161
- 323 Buchbinder S, Elmaagacli AH, Schaefer UW, Roggendorf M. Human herpesvirus 6 is an important pathogen in infectious lung disease after allogeneic bone marrow transplantation. *Bone Marrow Transplant* 2000;26(6):639–644
- 324 Bissinger AL, Einsele H, Hamprecht K, et al. Infectious pulmonary complications after stem cell transplantation or chemotherapy: diagnostic yield of bronchoalveolar lavage. *Diagn Microbiol Infect Dis* 2005;52(4):275–280
- 325 Inazawa N, Hori T, Hatakeyama N, et al. Large-scale multiplex polymerase chain reaction assay for diagnosis of viral reactivations after allogeneic hematopoietic stem cell transplantation. *J Med Virol* 2015;87(8):1427–1435
- 326 Razonable RR. Human herpesviruses 6, 7 and 8 in solid organ transplant recipients. *Am J Transplant* 2013;13(Suppl 3):67–77, quiz 77–78
- 327 Humar A, Kumar D, Caliendo AM, et al. Clinical impact of human herpesvirus 6 infection after liver transplantation. *Transplantation* 2002;73(4):599–604
- 328 Rogers J, Rohal S, Carrigan DR, et al. Human herpesvirus-6 in liver transplant recipients: role in pathogenesis of fungal infections, neurologic complications, and outcome. *Transplantation* 2000;69(12):2566–2573
- 329 Le J, Gantt S; AST Infectious Diseases Community of Practice. Human herpesvirus 6, 7 and 8 in solid organ transplantation. *Am J Transplant* 2013;13(Suppl 4):128–137
- 330 Endo A, Watanabe K, Ohye T, et al. Molecular and virological evidence of viral activation from chromosomally integrated human herpesvirus 6A in a patient with X-linked severe combined immunodeficiency. *Clin Infect Dis* 2014;59(4):545–548
- 331 Falasca F, Maida P, Gaeta A, et al. Detection and quantification of EBV, HHV-6 and CMV DNA in the gastrointestinal tract of HIV-positive patients. *Infection* 2014;42(6):1033–1037
- 332 Safdar A, Brown AE, Malkin M. Acute febrile myelodysplasia and pneumonitis due to human herpesvirus 6 after accelerated chemotherapy. *Am J Med* 2001;111(4):329–330
- 333 Zerr DM, Boeckh M, Delaney C, et al. HHV-6 reactivation and associated sequelae after hematopoietic cell transplantation. *Biol Blood Marrow Transplant* 2012;18(11):1700–1708
- 334 Verhoeven DH, Claas EC, Jol-van der Zijde CM, et al. Reactivation of human herpes virus-6 after pediatric stem cell transplantation: risk factors, onset, clinical symptoms and association with severity of acute graft-versus-host disease. *Pediatr Infect Dis J* 2015;34(10):1118–1127
- 335 Betts BC, Young JA, Ustun C, Cao Q, Weisdorf DJ. Human herpesvirus 6 infection after hematopoietic cell transplantation: is routine surveillance necessary? *Biol Blood Marrow Transplant* 2011;17(10):1562–1568
- 336 Van Leer-Buter CC, Sanders JS, Vroom HE, Riezebos-Brilman A, Niesters HG. Human herpesvirus-6 DNAemia is a sign of impending primary CMV infection in CMV sero-discordant renal transplantations. *J Clin Virol* 2013;58(2):422–426
- 337 Jacobs F, Knoop C, Brancart F, et al; Brussels Heart and Lung Transplantation Group. Human herpesvirus-6 infection after lung and heart-lung transplantation: a prospective longitudinal study. *Transplantation* 2003;75(12):1996–2001
- 338 Neurohr C, Huppmann P, Leuchte H, et al; Munich Lung Transplant Group. Human herpesvirus 6 in bronchoalveolar lavage fluid after lung transplantation: a risk factor for bronchiolitis obliterans syndrome? *Am J Transplant* 2005;5(12):2982–2991
- 339 Manuel O, Kumar D, Moussa G, et al. Lack of association between beta-herpesvirus infection and bronchiolitis obliterans syndrome in lung transplant recipients in the era of antiviral prophylaxis. *Transplantation* 2009;87(5):719–725
- 340 Seo S, Renaud C, Kuypers JM, et al. Idiopathic pneumonia syndrome after hematopoietic cell transplantation: evidence of occult infectious etiologies. *Blood* 2015;125(24):3789–3797
- 341 Lagadinou ED, Marangos M, Liga M, et al. Human herpesvirus 6-related pure red cell aplasia, secondary graft failure, and clinical severe immune suppression after allogeneic hematopoietic cell transplantation successfully treated with foscarnet. *Transpl Infect Dis* 2010;12(5):437–440
- 342 Zerr DM, Corey L, Kim HW, Huang ML, Nguy L, Boeckh M. Clinical outcomes of human herpesvirus 6 reactivation after hematopoietic stem cell transplantation. *Clin Infect Dis* 2005;40(7):932–940
- 343 Dulery R, Salleron J, Dewilde A, et al. Early human herpesvirus type 6 reactivation after allogeneic stem cell transplantation: a large-scale clinical study. *Biol Blood Marrow Transplant* 2012;18(7):1080–1089
- 344 Amo K, Tanaka-Taya K, Inagi R, et al. Human herpesvirus 6B infection of the large intestine of patients with diarrhea. *Clin Infect Dis* 2003;36(1):120–123
- 345 Halme L, Arola J, Höckerstedt K, Lautenschlager I. Human herpesvirus 6 infection of the gastroduodenal mucosa. *Clin Infect Dis* 2008;46(3):434–439
- 346 Lamoth F, Jayet PY, Aubert JD, et al. Case report: human herpesvirus 6 reactivation associated with colitis in a lung transplant recipient. *J Med Virol* 2008;80(10):1804–1807
- 347 Ogata M, Satou T, Kawano R, et al. Plasma HHV-6 viral load-guided preemptive therapy against HHV-6 encephalopathy after allogeneic stem cell transplantation: a prospective evaluation. *Bone Marrow Transplant* 2008;41(3):279–285
- 348 Ogata M, Satou T, Kawano R, et al. Correlations of HHV-6 viral load and plasma IL-6 concentration with HHV-6 encephalitis in allogeneic stem cell transplant recipients. *Bone Marrow Transplant* 2010;45(1):129–136
- 349 Hill JA, Koo S, Guzman Suarez BB, et al. Cord-blood hematopoietic stem cell transplant confers an increased risk for human herpesvirus-6-associated acute limbic encephalitis: a cohort analysis. *Biol Blood Marrow Transplant* 2012;18(11):1638–1648
- 350 Bhanushali MJ, Kranick SM, Freeman AF, et al. Human herpes 6 virus encephalitis complicating allogeneic hematopoietic stem cell transplantation. *Neurology* 2013;80(16):1494–1500
- 351 Pischke S, Gösling J, Engelmann I, et al. High intrahepatic HHV-6 virus loads but neither CMV nor EBV are associated with decreased graft survival after diagnosis of graft hepatitis. *J Hepatol* 2012;56(5):1063–1069
- 352 Härmä M, Höckerstedt K, Lautenschlager I. The long-term outcomes of patients transplanted due to acute liver failure with hepatic human herpesvirus-6 infection. *Transplant Proc* 2013;45(5):1910–1912

- 353 Pilmore H, Collins J, Dittmer I, et al. Fatal human herpesvirus-6 infection after renal transplantation. *Transplantation* 2009; 88(6):762–765
- 354 Moschetti D, De Milito A, Catucci M, et al. Detection of human herpesviruses 6 and 7 in heart transplant recipients by a multiplex polymerase chain reaction method. *Eur J Clin Microbiol Infect Dis* 1998;17(2):117–119
- 355 Yoshida M, Nakamae H, Okamura H, et al. Pericarditis associated with human herpesvirus-6 reactivation in a patient after unrelated cord blood transplant. *Exp Clin Transplant* 2015
- 356 Nash PJ, Avery RK, Tang WH, Starling RC, Taeye AJ, Yamani MH. Encephalitis owing to human herpesvirus-6 after cardiac transplant. *Am J Transplant* 2004;4(7):1200–1203
- 357 Michaelides A, Glare EM, Spelman DW, et al. beta-Herpesvirus (human cytomegalovirus and human herpesvirus 6) reactivation in at-risk lung transplant recipients and in human immunodeficiency virus-infected patients. *J Infect Dis* 2002;186(2):173–180
- 358 Costa C, Curtoni A, Bergallo M, et al. Quantitative detection of HHV-6 and HHV-7 in transbronchial biopsies from lung transplant recipients. *New Microbiol* 2011;34(3):275–280
- 359 Lehto JT, Halme M, Tukiainen P, Harjula A, Sipponen J, Lautenschlager I. Human herpesvirus-6 and -7 after lung and heart-lung transplantation. *J Heart Lung Transplant* 2007;26(1):41–47
- 360 Fairfax MR, Schacker T, Cone RW, Collier AC, Corey L. Human herpesvirus 6 DNA in blood cells of human immunodeficiency virus-infected men: correlation of high levels with high CD4 cell counts. *J Infect Dis* 1994;169(6):1342–1345
- 361 Fabio G, Knight SN, Kidd IM, et al. Prospective study of human herpesvirus 6, human herpesvirus 7, and cytomegalovirus infections in human immunodeficiency virus-positive patients. *J Clin Microbiol* 1997;35(10):2657–2659
- 362 Pinheiro RdosS, Ferreira DdeC, Nóbrega F, Santos NS, Souza IP, Castro GF. Current status of herpesvirus identification in the oral cavity of HIV-infected children. *Rev Soc Bras Med Trop* 2013; 46(1):15–19
- 363 De Clercq E, Naesens L, De Bolle L, Schols D, Zhang Y, Neyts J. Antiviral agents active against human herpesviruses HHV-6, HHV-7 and HHV-8. *Rev Med Virol* 2001;11(6):381–395
- 364 Ljungman P. Beta-herpesvirus challenges in the transplant recipient. *J Infect Dis* 2002;186(Suppl 1):S99–S109
- 365 Ishiyama K, Katagiri T, Hoshino T, Yoshida T, Yamaguchi M, Nakao S. Preemptive therapy of human herpesvirus-6 encephalitis with foscarnet sodium for high-risk patients after hematopoietic SCT. *Bone Marrow Transplant* 2011;46(6):863–869
- 366 Gerdemann U, Keukens L, Keirnan JM, et al. Immunotherapeutic strategies to prevent and treat human herpesvirus 6 reactivation after allogeneic stem cell transplantation. *Blood* 2013;121(1):207–218
- 367 Frenkel N, Schirmer EC, Wyatt LS, et al. Isolation of a new herpesvirus from human CD4+ T cells. *Proc Natl Acad Sci U S A* 1990;87(2):748–752
- 368 Berneman ZN, Ablashi DV, Li G, et al. Human herpesvirus 7 is a T-lymphotropic virus and is related to, but significantly different from, human herpesvirus 6 and human cytomegalovirus. *Proc Natl Acad Sci U S A* 1992;89(21):10552–10556
- 369 Ward KN. The natural history and laboratory diagnosis of human herpesviruses-6 and -7 infections in the immunocompetent. *J Clin Virol* 2005;32(3):183–193
- 370 Dockrell DH, Paya CV. Human herpesvirus-6 and -7 in transplantation. *Rev Med Virol* 2001;11(1):23–36
- 371 Clark DA, Freeland ML, Mackie LK, Jarrett RF, Onions DE. Prevalence of antibody to human herpesvirus 7 by age. *J Infect Dis* 1993;168(1):251–252
- 372 Ward KN, Andrews NJ, Verity CM, Miller E, Ross EM. Human herpesviruses-6 and -7 each cause significant neurological morbidity in Britain and Ireland. *Arch Dis Child* 2005;90(6):619–623
- 373 Caserta MT, Hall CB, Schnabel K, Long CE, D'Heron N. Primary human herpesvirus 7 infection: a comparison of human herpesvirus 7 and human herpesvirus 6 infections in children. *J Pediatr* 1998;133(3):386–389
- 374 Kimberlin DW. Human herpesviruses 6 and 7: identification of newly recognized viral pathogens and their association with human disease. *Pediatr Infect Dis J* 1998;17(1):59–67, quiz 68
- 375 Tanaka K, Kondo T, Torigoe S, Okada S, Mukai T, Yamanishi K. Human herpesvirus 7: another causal agent for roseola (exanthem subitum). *J Pediatr* 1994;125(1):1–5
- 376 Epstein LG, Shinnar S, Hesdorffer DC, et al; FEBSTAT study team. Human herpesvirus 6 and 7 in febrile status epilepticus: the FEBSTAT study. *Epilepsia* 2012;53(9):1481–1488
- 377 Schwartz KL, Richardson SE, Ward KN, et al. Delayed primary HHV-7 infection and neurologic disease. *Pediatrics* 2014;133(6):e1541–e1547
- 378 Humar A, Asberg A, Kumar D, et al; VICTOR study group. An assessment of herpesvirus co-infections in patients with CMV disease: correlation with clinical and virologic outcomes. *Am J Transplant* 2009;9(2):374–381
- 379 Safronetz D, Humar A, Tipples GA. Differentiation and quantitation of human herpesviruses 6A, 6B and 7 by real-time PCR. *J Virol Methods* 2003;112(1–2):99–105
- 380 Chang Y, Cesarman E, Pessin MS, et al. Identification of herpesvirus-like DNA sequences in AIDS-associated Kaposi's sarcoma. *Science* 1994;266(5192):1865–1869
- 381 Schulz TF, Cesarman E. Kaposi Sarcoma-associated Herpesvirus: mechanisms of oncogenesis. *Curr Opin Virol* 2015;14:116–128
- 382 Dow DE, Cunningham CK, Buchanan AM. A review of human herpesvirus 8, the Kaposi's sarcoma-associated herpesvirus, in the pediatric population. *J Pediatric Infect Dis Soc* 2014;3(1):66–76
- 383 Hleyhel M, Belot A, Bouvier AM, et al; FHDH-ANRS CO4. Trends in survival after cancer diagnosis among HIV-infected individuals between 1992 and 2009. Results from the FHDH-ANRS CO4 cohort. *Int J Cancer* 2015;137(10):2443–2453
- 384 Dittmer DP, Damania B. Kaposi sarcoma associated herpesvirus pathogenesis (KSHV)—an update. *Curr Opin Virol* 2013;3(3):238–244
- 385 Cesarman E, Chang Y, Moore PS, Said JW, Knowles DM. Kaposi's sarcoma-associated herpesvirus-like DNA sequences in AIDS-related body-cavity-based lymphomas. *N Engl J Med* 1995; 332(18):1186–1191
- 386 Régnier-Rosencher E, Barrou B, Marcelin AG, et al. [Primary effusion lymphoma in two kidney transplant recipients]. *Ann Dermatol Venerol* 2010;137(4):285–289
- 387 Liao G, Cai J, Yue C, Qing X. Extracavitary/solid variant of primary effusion lymphoma presenting as a gastric mass. *Exp Mol Pathol* 2015;99(3):445–448
- 388 Sullivan RJ, Pantanowitz L, Casper C, Stebbing J, Dezube BJ. HIV/AIDS: epidemiology, pathophysiology, and treatment of Kaposi sarcoma-associated herpesvirus disease: Kaposi sarcoma, primary effusion lymphoma, and multicentric Castleman disease. *Clin Infect Dis* 2008;47(9):1209–1215
- 389 Vijgen S, Wyss C, Meylan P, et al. Fatal outcome of multiple clinical presentations of human herpesvirus 8-related disease after solid organ transplantation. *Transplantation* 2016;100(1):134–140
- 390 Li CF, Ye H, Liu H, Du MQ, Chuang SS. Fatal HHV-8-associated hemophagocytic syndrome in an HIV-negative immunocompetent patient with plasmablastic variant of multicentric Castleman disease (plasmablastic microlymphoma). *Am J Surg Pathol* 2006; 30(1):123–127
- 391 Grossman WJ, Radhi M, Schauer D, Gerday E, Grose C, Goldman FD. Development of hemophagocytic lymphohistiocytosis in triplets infected with HHV-8. *Blood* 2005;106(4):1203–1206
- 392 Stebbing J, Ngan S, Ibrahim H, et al. The successful treatment of haemophagocytic syndrome in patients with human immunodeficiency virus-associated multi-centric Castleman's disease. *Clin Exp Immunol* 2008;154(3):399–405

- 393 Tornesello ML, Biryahwaho B, Downing R, et al. Human herpesvirus type 8 variants circulating in Europe, Africa and North America in classic, endemic and epidemic Kaposi's sarcoma lesions during pre-AIDS and AIDS era. *Virology* 2010;398(2):280–289
- 394 Wakeham K, Johnston WT, Nalwoga A, et al. Trends in Kaposi's sarcoma-associated Herpesvirus antibodies prior to the development of HIV-associated Kaposi's sarcoma: a nested case-control study. *Int J Cancer* 2015;136(12):2822–2830
- 395 De Bruin GP, Stefan DC. Children with Kaposi sarcoma in two southern African hospitals: clinical presentation, management, and outcome. *J Trop Med* 2013;2013:213490
- 396 Stein L, Urban MI, O'Connell D, et al. The spectrum of human immunodeficiency virus-associated cancers in a South African black population: results from a case-control study, 1995–2004. *Int J Cancer* 2008;122(10):2260–2265
- 397 Ngalamika O, Minhas V, Wood C. Kaposi's sarcoma at the University Teaching Hospital, Lusaka, Zambia in the antiretroviral therapy era. *Int J Cancer* 2015;136(5):1241–1242
- 398 Ziegler J, Newton R, Bourbouli D, et al; Uganda Kaposi's Sarcoma Study Group. Risk factors for Kaposi's sarcoma: a case-control study of HIV-seronegative people in Uganda. *Int J Cancer* 2003;103(2):233–240
- 399 Shebl FM, Dollard SC, Pfeiffer RM, et al. Human herpesvirus 8 seropositivity among sexually active adults in Uganda. *PLoS ONE* 2011;6(6):e21286
- 400 Minhas V, Brayfield BP, Crabtree KL, Kankasa C, Mitchell CD, Wood C. Primary gamma-herpesviral infection in Zambian children. *BMC Infect Dis* 2010;10:115
- 401 Kim Y, Leventaki V, Bhaijee F, Jackson CC, Medeiros LJ, Vega F. Extracavitary/solid variant of primary effusion lymphoma. *Ann Diagn Pathol* 2012;16(6):441–446
- 402 Butler LM, Were WA, Balinandi S, et al. Human herpesvirus 8 infection in children and adults in a population-based study in rural Uganda. *J Infect Dis* 2011;203(5):625–634
- 403 Wakeham K, Webb EL, Sebina I, et al. Risk factors for seropositivity to Kaposi sarcoma-associated herpesvirus among children in Uganda. *J Acquir Immune Defic Syndr* 2013;63(2):228–233
- 404 La Ferla L, Pinzone MR, Nunnari G, et al. Kaposi's sarcoma in HIV-positive patients: the state of art in the HAART-era. *Eur Rev Med Pharmacol Sci* 2013;17(17):2354–2365
- 405 Mohanna S, Maco V, Bravo F, Gotuzzo E. Epidemiology and clinical characteristics of classic Kaposi's sarcoma, seroprevalence, and variants of human herpesvirus 8 in South America: a critical review of an old disease. *Int J Infect Dis* 2005;9(5):239–250
- 406 de Sanjose S, Mbisa G, Perez-Alvarez S, et al. Geographic variation in the prevalence of Kaposi sarcoma-associated herpesvirus and risk factors for transmission. *J Infect Dis* 2009;199(10):1449–1456
- 407 Dukers NH, Rezza G. Human herpesvirus 8 epidemiology: what we do and do not know. *AIDS* 2003;17(12):1717–1730
- 408 Dedicat M, Newton R, Alkharsah KR, et al. Mother-to-child transmission of human herpesvirus-8 in South Africa. *J Infect Dis* 2004;190(6):1068–1075
- 409 Casper C, Redman M, Huang ML, et al. HIV infection and human herpesvirus-8 oral shedding among men who have sex with men. *J Acquir Immune Defic Syndr* 2004;35(3):233–238
- 410 Taylor MM, Chohan B, Lavreys L, et al. Shedding of human herpesvirus 8 in oral and genital secretions from HIV-1-seropositive and -seronegative Kenyan women. *J Infect Dis* 2004;190(3):484–488
- 411 Engels EA, Atkinson JO, Graubard BI, et al. Risk factors for human herpesvirus 8 infection among adults in the United States and evidence for sexual transmission. *J Infect Dis* 2007;196(2):199–207
- 412 Hladik W, Dollard SC, Mermin J, et al. Transmission of human herpesvirus 8 by blood transfusion. *N Engl J Med* 2006;355(13):1331–1338
- 413 Luppi M, Barozzi P, Santagostino G, et al. Molecular evidence of organ-related transmission of Kaposi sarcoma-associated herpesvirus or human herpesvirus-8 in transplant patients. *Blood* 2000;96(9):3279–3281
- 414 Barozzi P, Luppi M, Facchetti F, et al. Post-transplant Kaposi sarcoma originates from the seeding of donor-derived progenitors. *Nat Med* 2003;9(5):554–561
- 415 Wang QJ, Jenkins FJ, Jacobson LP, et al. Primary human herpesvirus 8 infection generates a broadly specific CD8(+) T-cell response to viral lytic cycle proteins. *Blood* 2001;97(8):2366–2373
- 416 Bhutani M, Polizzotto MN, Uldrick TS, Yarchoan R. Kaposi sarcoma-associated herpesvirus-associated malignancies: epidemiology, pathogenesis, and advances in treatment. *Semin Oncol* 2015;42(2):223–246
- 417 Rohner E, Wyss N, Heg Z, et al. HIV and human herpesvirus 8 coinfection across the globe: Systematic review and meta-analysis. *Int J Cancer* 2016;138(1):45–54
- 418 Celtik C, Ünüvar A, Aydoğan A, et al. Human herpes virus type 8-associated Kaposi sarcoma in a pediatric liver transplant recipient. *Pediatr Transplant* 2011;15(5):E100–E104
- 419 Ariza-Heredia EJ, Razonable RR. Human herpes virus 8 in solid organ transplantation. *Transplantation* 2011;92(8):837–844
- 420 Jackson CC, Dickson MA, Sadjadi M, et al. Kaposi sarcoma of childhood: inborn or acquired immunodeficiency to oncogenic HHV-8. *Pediatr Blood Cancer* 2016;63(3):392–397
- 421 Tedeschi R, Marus A, Bidoli E, Simonelli C, De Paoli P. Human herpesvirus 8 DNA quantification in matched plasma and PBMCs samples of patients with HHV8-related lymphoproliferative diseases. *J Clin Virol* 2008;43(3):255–259
- 422 Tedeschi R, Enbom M, Bidoli E, Linde A, De Paoli P, Dillner J. Viral load of human herpesvirus 8 in peripheral blood of human immunodeficiency virus-infected patients with Kaposi's sarcoma. *J Clin Microbiol* 2001;39(12):4269–4273
- 423 Pantanowitz L, Otis CN, Dezube BJ. Immunohistochemistry in Kaposi's sarcoma. *Clin Exp Dermatol* 2010;35(1):68–72
- 424 Chu KM, Mahlangu G, Swannet S, Ford NP, Boule A, Van Cutsem G. AIDS-associated Kaposi's sarcoma is linked to advanced disease and high mortality in a primary care HIV programme in South Africa. *J Int AIDS Soc* 2010;13:23
- 425 Régnier-Rosencher E, Guillot B, Dupin N. Treatments for classic Kaposi sarcoma: a systematic review of the literature. *J Am Acad Dermatol* 2013;68(2):313–331
- 426 Mohanlal RD, Pather S. Kaposi's sarcoma, a South African perspective: Demographic and pathological features. *S Afr Med J* 2015;105(5):375–378
- 427 Sissolak G, Mayaud P. AIDS-related Kaposi's sarcoma: epidemiological, diagnostic, treatment and control aspects in sub-Saharan Africa. *Trop Med Int Health* 2005;10(10):981–992
- 428 Feller L, Khammissa RA, Gugushe TS, et al. HIV-associated Kaposi sarcoma in African children. *SADJ* 2010;65(1):20–22
- 429 Mwakigonja AR, Pak F, Pyakurel P, et al. Oral Kaposi's sarcoma in Tanzania: presentation, immunopathology and human herpesvirus-8 association. *Oncol Rep* 2007;17(6):1291–1299
- 430 O'Brien TR, Kedes D, Ganem D, et al. Evidence for concurrent epidemics of human herpesvirus 8 and human immunodeficiency virus type 1 in US homosexual men: rates, risk factors, and relationship to Kaposi's sarcoma. *J Infect Dis* 1999;180(4):1010–1017
- 431 International Collaboration on HIV and Cancer. Highly active antiretroviral therapy and incidence of cancer in human immunodeficiency virus-infected adults. *J Natl Cancer Inst* 2000;92(22):1823–1830
- 432 Shiels MS, Pfeiffer RM, Gail MH, et al. Cancer burden in the HIV-infected population in the United States. *J Natl Cancer Inst* 2011;103(9):753–762
- 433 Khalil AM, Carette MF, Cadranet JL, Mayaud CM, Bigot JM. Intrathoracic Kaposi's sarcoma. CT findings. *Chest* 1995;108(6):1622–1626

- 434 Hamm PG, Judson MA, Aranda CP. Diagnosis of pulmonary Kaposi's sarcoma with fiberoptic bronchoscopy and endobronchial biopsy. A report of five cases. *Cancer* 1987;59(4):807-810
- 435 Leidner RS, Aboulafla DM. Recrudescence Kaposi's sarcoma after initiation of HAART: a manifestation of immune reconstitution syndrome. *AIDS Patient Care STDS* 2005;19(10):635-644
- 436 Caponetti G, Dezube BJ, Restrepo CS, Pantanowitz L. Kaposi sarcoma of the musculoskeletal system: a review of 66 patients. *Cancer* 2007;109(6):1040-1052
- 437 Guihot A, Dupin N, Marcelin AG, et al. Low T cell responses to human herpesvirus 8 in patients with AIDS-related and classic Kaposi sarcoma. *J Infect Dis* 2006;194(8):1078-1088
- 438 Stallone G, Schena A, Infante B, et al. Sirolimus for Kaposi's sarcoma in renal-transplant recipients. *N Engl J Med* 2005;352(13):1317-1323
- 439 Hosseini-Moghaddam SM, Soleimanirahbar A, Mazzulli T, Rotstein C, Husain S. Post renal transplantation Kaposi's sarcoma: a review of its epidemiology, pathogenesis, diagnosis, clinical aspects, and therapy. *Transpl Infect Dis* 2012;14(4):338-345
- 440 Casper C. The aetiology and management of Castleman disease at 50 years: translating pathophysiology to patient care. *Br J Haematol* 2005;129(1):3-17
- 441 Uldrick TS, Polizzotto MN, Aleman K, et al. High-dose zidovudine plus valganciclovir for Kaposi sarcoma herpesvirus-associated multicentric Castleman disease: a pilot study of virus-activated cytotoxic therapy. *Blood* 2011;117(26):6977-6986
- 442 Lumley S, Madge S, Nugent D, et al. High-level human herpesvirus-8 viremia and multicentric Castleman's disease following initiation of highly active antiretroviral therapy. *AIDS* 2014;28(11):1698-1700
- 443 Andrei G, Snoeck R. Kaposi's sarcoma-associated herpesvirus: the role of lytic replication in targeted therapy. *Curr Opin Infect Dis* 2015;28(6):611-624
- 444 Carbone A, De Paoli P, Glohini A, Vaccher E. KSHV-associated multicentric Castleman disease: A tangle of different entities requiring multitarget treatment strategies. *Int J Cancer* 2015;137(2):251-261
- 445 Stebbing J, Pantanowitz L, Dayyani F, Sullivan RJ, Bower M, Dezube BJ. HIV-associated multicentric Castleman's disease. *Am J Hematol* 2008;83(6):498-503
- 446 Gérard L, Bérezné A, Galicier L, et al. Prospective study of rituximab in chemotherapy-dependent human immunodeficiency virus associated multicentric Castleman's disease: ANRS 117 CastlemaB Trial. *J Clin Oncol* 2007;25(22):3350-3356
- 447 Mylona EE, Baraboutis IG, Lekakis LJ, Georgiou O, Papastamopoulos V, Skoutelis A. Multicentric Castleman's disease in HIV infection: a systematic review of the literature. *AIDS Rev* 2008;10(1):25-35
- 448 Al Otaibi T, Al Sagheir A, Ludwin D, Meyer R. Post renal transplant Castleman's disease resolved after graft nephrectomy: a case report. *Transplant Proc* 2007;39(4):1276-1277
- 449 Gaitonde S, Vidanovic V, Ni H. Concomitant and fatal HHV-8+ multicentric Castleman's disease and Kaposi's sarcoma in the same lymph node of an HIV- liver transplant patient. *Histopathology* 2007;50(7):954-958
- 450 Lim EJ, Crowley P, Mitchell CA, Angus PW. Post-liver transplantation multicentric Castleman disease treated with valganciclovir and weaning of immunosuppression. *Am J Transplant* 2011;11(1):169-172
- 451 Rokx C, Rijnders BJ, van Laar JA. Treatment of multicentric Castleman's disease in HIV-1 infected and uninfected patients: a systematic review. *Neth J Med* 2015;73(5):202-210
- 452 Oksenhendler E, Boulanger E, Galicier L, et al. High incidence of Kaposi sarcoma-associated herpesvirus-related non-Hodgkin lymphoma in patients with HIV infection and multicentric Castleman disease. *Blood* 2002;99(7):2331-2336
- 453 Uldrick TS, Wang V, O'Mahony D, et al. An interleukin-6-related systemic inflammatory syndrome in patients co-infected with Kaposi sarcoma-associated herpesvirus and HIV but without Multicentric Castleman disease. *Clin Infect Dis* 2010;51(3):350-358
- 454 Knowles DM, Inghirami G, Ubriaco A, Dalla-Favera R. Molecular genetic analysis of three AIDS-associated neoplasms of uncertain lineage demonstrates their B-cell derivation and the possible pathogenetic role of the Epstein-Barr virus. *Blood* 1989;73(3):792-799
- 455 Nador RG, Cesarman E, Chadburn A, et al. Primary effusion lymphoma: a distinct clinicopathologic entity associated with the Kaposi's sarcoma-associated herpes virus. *Blood* 1996;88(2):645-656
- 456 Chadburn A, Hyjek E, Mathew S, Cesarman E, Said J, Knowles DM. KSHV-positive solid lymphomas represent an extra-cavitary variant of primary effusion lymphoma. *Am J Surg Pathol* 2004;28(11):1401-1416
- 457 Jenner RG, Maillard K, Cattini N, et al. Kaposi's sarcoma-associated herpesvirus-infected primary effusion lymphoma has a plasma cell gene expression profile. *Proc Natl Acad Sci U S A* 2003;100(18):10399-10404
- 458 Brimo F, Michel RP, Khetani K, Auger M. Primary effusion lymphoma: a series of 4 cases and review of the literature with emphasis on cytomorphologic and immunocytochemical differential diagnosis. *Cancer* 2007;111(4):224-233
- 459 Simonelli C, Spina M, Cinelli R, et al. Clinical features and outcome of primary effusion lymphoma in HIV-infected patients: a single-institution study. *J Clin Oncol* 2003;21(21):3948-3954
- 460 Boulanger E, Afonso PV, Yahiaoui Y, Adle-Biassette H, Gabarre J, Agbalika F. Human herpesvirus-8 (HHV-8)-associated primary effusion lymphoma in two renal transplant recipients receiving rapamycin. *Am J Transplant* 2008;8(3):707-710
- 461 Dotti G, Fiocchi R, Motta T, et al. Primary effusion lymphoma after heart transplantation: a new entity associated with human herpesvirus-8. *Leukemia* 1999;13(5):664-670
- 462 Jones D, Ballesta ME, Kaye KM, et al. Primary-effusion lymphoma and Kaposi's sarcoma in a cardiac-transplant recipient. *N Engl J Med* 1998;339(7):444-449
- 463 Meng YX, Spira TJ, Bhat GJ, et al. Individuals from North America, Australasia, and Africa are infected with four different genotypes of human herpesvirus 8. *Virology* 1999;261(1):106-119
- 464 Schulz TF. Epidemiology of Kaposi's sarcoma-associated herpesvirus/human herpesvirus 8. *Adv Cancer Res* 1999;76:121-160
- 465 Carbone A, Gaidano G. HHV-8-positive body-cavity-based lymphoma: a novel lymphoma entity. *Br J Haematol* 1997;97(3):515-522
- 466 Pielasinski U, Santonja C, Rodríguez-Pinilla SM, Requena L. Extracavitary primary effusion lymphoma presenting as a cutaneous tumor: a case report and literature review. *J Cutan Pathol* 2014;41(9):745-753
- 467 Wamburu G, Masenga EJ, Mushi EZ, Schmid-Grendelmeier P, Kempf W, Orfanos CE. HIV - associated and non - HIV associated types of Kaposi's sarcoma in an African population in Tanzania. Status of immune suppression and HHV-8 seroprevalence. *Eur J Dermatol* 2006;16(6):677-682
- 468 Palmieri C, Dhillon T, Thirlwell C, et al. Pulmonary Kaposi sarcoma in the era of highly active antiretroviral therapy. *HIV Med* 2006;7(5):291-293
- 469 Danzig JB, Brandt LJ, Reinus JF, Klein RS. Gastrointestinal malignancy in patients with AIDS. *Am J Gastroenterol* 1991;86(6):715-718
- 470 Nasti G, Talamini R, Antinori A, et al; AIDS Clinical Trial Group Staging System in the Haart Era—the Italian Cooperative Group on AIDS and Tumors and the Italian Cohort of Patients Naive from Antiretrovirals. AIDS-related Kaposi's Sarcoma: evaluation of potential new prognostic factors and assessment of the AIDS Clinical Trial Group Staging System in the Haart Era—the Italian Cooperative Group on AIDS and Tumors and the Italian Cohort of

- Patients Naive From Antiretrovirals. *J Clin Oncol* 2003;21(15):2876–2882
- 471 Semeere AS, Busakhala N, Martin JN. Impact of antiretroviral therapy on the incidence of Kaposi's sarcoma in resource-rich and resource-limited settings. *Curr Opin Oncol* 2012;24(5):522–530
- 472 Chagaluka G, Stanley C, Banda K, et al. Kaposi's sarcoma in children: an open randomised trial of vincristine, oral etoposide and a combination of vincristine and bleomycin. *Eur J Cancer* 2014;50(8):1472–1481
- 473 Gantt S, Casper C. Human herpesvirus 8-associated neoplasms: the roles of viral replication and antiviral treatment. *Curr Opin Infect Dis* 2011;24(4):295–301
- 474 Aaron L, Lidove O, Yousry C, Roudiere L, Dupont B, Viard JP. Human herpesvirus 8-positive Castleman disease in human immunodeficiency virus-infected patients: the impact of highly active antiretroviral therapy. *Clin Infect Dis* 2002;35(7):880–882
- 475 van Rhee F, Wong RS, Munshi N, et al. Siltuximab for multicentric Castleman's disease: a randomised, double-blind, placebo-controlled trial. *Lancet Oncol* 2014;15(9):966–974
- 476 Gérard L, Michot JM, Burcheri S, et al. Rituximab decreases the risk of lymphoma in patients with HIV-associated multicentric Castleman disease. *Blood* 2012;119(10):2228–2233
- 477 Bower M, Powles T, Williams S, et al. Brief communication: rituximab in HIV-associated multicentric Castleman disease. *Ann Intern Med* 2007;147(12):836–839
- 478 Bower M, Newsom-Davis T, Naresh K, et al. Clinical features and outcome in HIV-associated multicentric Castleman's disease. *J Clin Oncol* 2011;29(18):2481–2486
- 479 Halfdanarson TR, Markovic SN, Kalokhe U, Luppi M. A non-chemotherapy treatment of a primary effusion lymphoma: durable remission after intracavitary cidofovir in HIV negative PEL refractory to chemotherapy. *Ann Oncol* 2006;17(12):1849–1850
- 480 Luppi M, Trovato R, Barozzi P, et al. Treatment of herpesvirus associated primary effusion lymphoma with intracavity cidofovir. *Leukemia* 2005;19(3):473–476
- 481 Sin SH, Roy D, Wang L, et al. Rapamycin is efficacious against primary effusion lymphoma (PEL) cell lines in vivo by inhibiting autocrine signaling. *Blood* 2007;109(5):2165–2173
- 482 An J, Sun Y, Fisher M, Rettig MB. Antitumor effects of bortezomib (PS-341) on primary effusion lymphomas. *Leukemia* 2004;18(10):1699–1704