



Since January 2020 Elsevier has created a COVID-19 resource centre with free information in English and Mandarin on the novel coronavirus COVID-19. The COVID-19 resource centre is hosted on Elsevier Connect, the company's public news and information website.

Elsevier hereby grants permission to make all its COVID-19-related research that is available on the COVID-19 resource centre - including this research content - immediately available in PubMed Central and other publicly funded repositories, such as the WHO COVID database with rights for unrestricted research re-use and analyses in any form or by any means with acknowledgement of the original source. These permissions are granted for free by Elsevier for as long as the COVID-19 resource centre remains active.

Pathogenesis of gut virus infection

A. F. M. SALIM
A. D. PHILLIPS
M. J. G. FARTHING

INTRODUCTION

Acute infectious diarrhoea continues to be a major health problem throughout the world. It has been estimated that approximately 500 million preschool children suffer from acute gastroenteritis worldwide, predominantly in the developing world, and about 5 million of these children die each year due to dehydration and other complications (Grant, 1987). Cumulative data from epidemiological studies show that approximately 20–50% of these cases are attributable to known bacterial or parasitic pathogens (Wanke et al, 1987), which suggests that viruses might be responsible for the remainder. In fact, viral gastroenteritis has been found to be the second most common clinical entity in developed countries, following closely behind viral upper respiratory tract illness (Kapikian et al, 1980). A number of viruses have now been associated with acute gastroenteritis. These include rotavirus, adenoviruses, Norwalk and Norwalk-like viruses, astroviruses, caliciviruses, and coronaviruses. In this chapter, we will discuss the pathogenetic mechanisms underlying the diarrhoea caused by some of these viruses.

In infants and children, information is restricted because of ethical considerations. Adult volunteer studies and a variety of animal models have therefore been used for this purpose. Studies of the intestinal tract of animals experimentally infected with human or animal gastrointestinal viruses have given some insight into the mechanisms of mucosal injury.

ROTAVIRUS

Although rotavirus is the most common cause of acute gastroenteritis in infants and children worldwide (Kapikian et al, 1976; Black et al, 1980), its pathogenesis remains uncertain.

Route of infection

Rotavirus infection is spread primarily by the faecal–oral route. Although

rotavirus is relatively acid-labile, it can easily survive the pH of an infant stomach, which usually remains above pH 3.0 for at least 1 h after a meal (Weiss and Clarke, 1985). An adult volunteer study showed that as few as 10^5 to 10^6 virus particles per millilitre were sufficient to cause infection in eight of 11 volunteers, six of whom developed gastrointestinal symptoms (Ward et al, 1986).

How the virus enters the intestinal epithelial cell remains uncertain. It has been shown that pre-treatment with trypsin enhances the growth of rotavirus in a tissue culture system (Almeida et al, 1978). Successful propagation of human rotavirus in cultured cell lines is now possible (Sato et al, 1981; Urasawa et al, 1981). Despite this, it remains unclear whether whole virus particles are taken into the cell by endocytosis, or whether there is an as yet undetected receptor on the cell membrane which enhances the entry of the genome directly into the enterocyte.

Human studies

In man, the vast majority of information relating to the mechanisms of mucosal injury following rotavirus infection comes from the study of small intestinal biopsies. The major focus was therefore to detect how virus damages these absorptive cells. It has been shown that rotavirus infects the mature enterocytes in the mid and upper villous epithelium (Middleton et al,

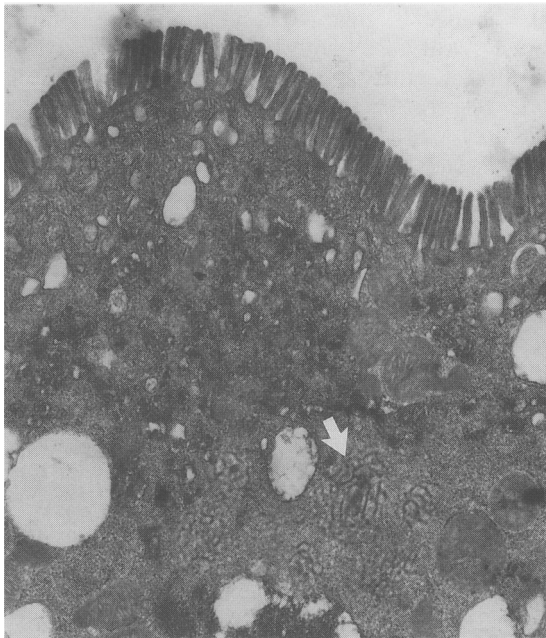


Figure 1. Rotavirus particles in aggregate form (arrow) in the cytoplasm of a syncytial cell at 24 hours post-infection (13,500).

1974; Davidson et al, 1975). Virus particles have also been detected by electron microscopy in goblet cells (Suzuki and Konno, 1975), in macrophages in the lamina propria (Suzuki and Konno, 1975; Phillips, 1981) and epithelial endocrine cells (unpublished observations, A. D. Phillips). In enterocytes, viral particles are usually found in the distended cisternae of the endoplasmic reticulum (Figure 1) and in the cisternae between the inner and the outer nuclear membranes (Bishop et al, 1973). Rotavirus has also been detected in lysosomal bodies (Suzuki and Konno, 1975; Phillips, 1981).

Enterocytes invaded by rotavirus degenerate. The microvilli are often irregular and distorted, and there is disruption of the terminal web (Suzuki and Konno, 1975). The number of cytolysosomes is increased. Swelling of the mitochondria and multivesicular and lysosome-like bodies can be observed (Suzuki and Konno, 1975). Ultimately, cell death and villous atrophy occur. This produces a malabsorptive state as a result of reduced surface area and loss of digestive capacity. Healing of the mucosa occurs within 3–8 weeks (Davidson and Barnes, 1979). It is possible that during this rapid recovery phase, enteroblast-like cells populate the epithelium. However, in a recent study it has been shown that alkaline phosphatase activity in the virus-infected group was similar to those in controls and, therefore, the enteroblastic replacement theory probably does not hold (Phillips, 1989).

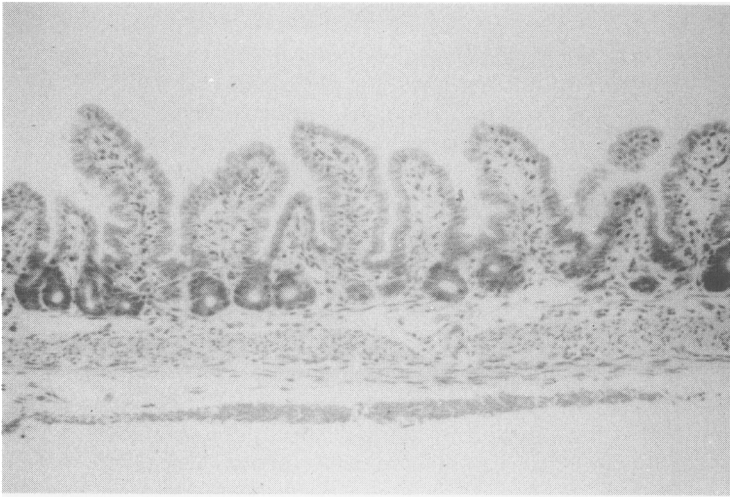
Information concerning the extent of gut involvement in rotavirus infection is limited as most of the studies have involved the upper gut. However, abnormal D-xylose absorption (Mavromichalis et al, 1977) and immunofluorescence studies in autopsy specimens (Hamilton et al, 1976) suggest that the infection can involve the entire small intestine, and even the colon.

Animal studies

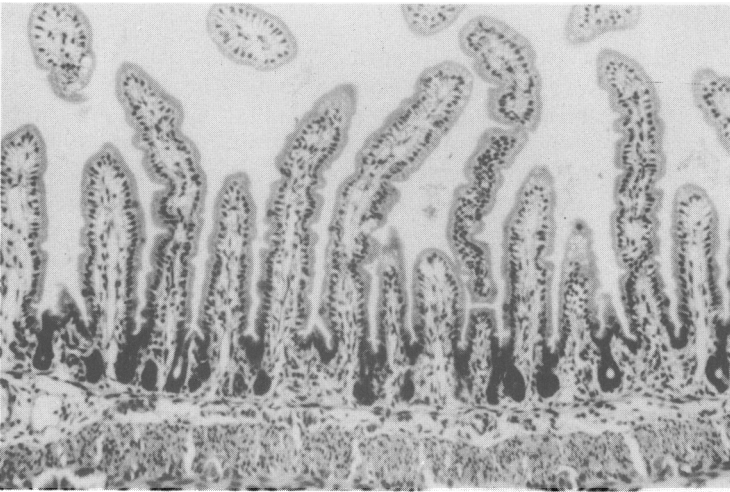
Group A rotavirus also infects the enterocytes of animals; the epithelial cells die and are sloughed as virus replicates (Theil et al, 1978). This effect of group A rotavirus is observed in piglets (Crouch and Woode, 1978; McAdaragh et al, 1980), calves (Mebus and Newman, 1977), lambs (Snodgrass et al, 1977, 1979a) and dogs (Johnson et al, 1986). Diarrhoea is usually observed between 12–24 h post-infection. Following the rapid and extensive loss of enterocytes, there is increased production of cells in the crypts with an associated increase in crypt depth (Crouch and Woode, 1978; Snodgrass et al, 1979a). Villous height/crypt depth ratio is thus reduced. Infected enterocytes become swollen and microvilli may be shorter, broader and unevenly spaced (Pearson and McNulty, 1979).

Unlike the above animals, the pathogenetic mechanism in neonatal mice infected with group A rotavirus [epizootic diarrhoea of infant mice (EDIM) virus] is different. In these animals a biphasic infection is seen, with two peaks of virus excretion: the first at day 1–2, and the second on day 5 post-infection (Eydelloth et al, 1984; Starkey et al, 1986). Rotavirus infects the enterocytes on the upper half of the villus and multiplies within these cells. Extensive vacuolation of infected enterocytes is a constant finding (Starkey et al, 1986).

Alkaline phosphatase and lactase activities are decreased while thymidine kinase activity is increased. Precocious maturation profiles of sucrase and maltase are found but there is no change in the activities of Na-K-ATPase and adenylate or guanylate cyclase (Collins et al, 1988). However, in these animals significant shortening of villi and increase in crypt depth does not occur (Starkey et al, 1986). Recently it has been proposed that villous ischaemia causing anoxia and enterocyte destruction is the basis of patho-



(a)



(b)

Figure 2. Rat jejunum 24 h post-infection with rat rotavirus (a) showing partial villous atrophy and (b) non-infected control.

logical changes in rotavirus diarrhoea of infant mice (Osborne et al, 1988; Stephen and Osborne, 1988).

Group B rotavirus is similar to group A rotavirus except that it causes enterocyte syncytia formation (Askaa and Bloch, 1984; Vonderfecht et al, 1984). Eight-day-old neonatal rats infected with group B rotavirus, develop diarrhoea at 24 h post-infection; however, histology and morphometry reveal that significant villous shortening precedes diarrhoea, occurring at 12 h in the ileum and at 18 h in the jejunum (Figures 2 and 3) (Salim et al, 1988, 1989a). Syncytial cells are found at 18 and 24 h and a significant increase in crypt depth occurs at 48 h in the ileum and 72 h in the jejunum

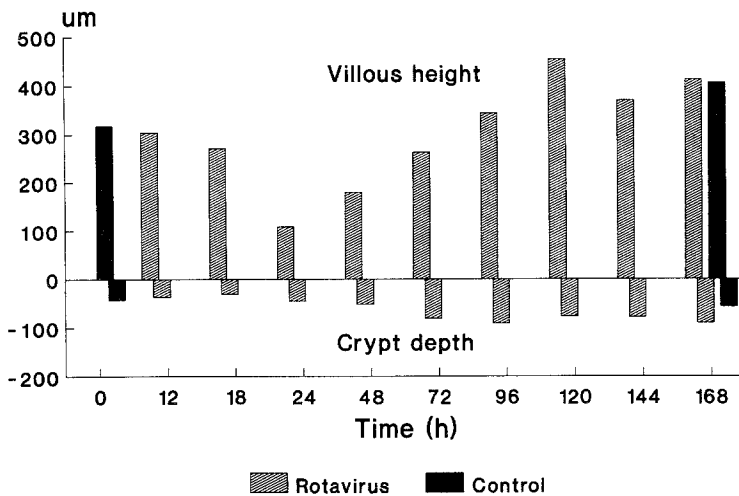


Figure 3. Villous height and crypt depth in rat jejunum 0–168 h post-infection with rotavirus (Salim et al, unpublished observations).

(Figure 3). Diarrhoea continues for 4–5 days and virus is excreted in stool for up to 72 h post-infection. A study of the microcirculation in these animals by direct visualization of the red blood cells in the villi via their endogenous peroxidase activity, demonstrated no differences in the distribution of red blood cells between infected animals and non-infected controls (Figure 4) (Salim et al, 1990). Thus, villous ischaemia does not appear to be involved in the pathogenesis of group B rotavirus infection in rats.

Davidson et al (1977) have studied sodium and chloride fluxes in vitro in jejunal epithelium of neonatal pigs infected with a human rotavirus. They found that glucose-coupled sodium transport was severely impaired at the height of diarrhoea. These findings were later confirmed by in vivo studies of 30 cm segments of jejunum of neonatal pigs infected with porcine rotavirus (Graham et al, 1984). These latter investigators measured the osmolalities of the stools collected from diarrhoeic piglets and concluded that diarrhoea in rotavirus infection in piglets is osmotic due to nutrient malabsorption, of

which carbohydrate was the most important (Graham et al, 1986). The studies of Theil et al (1978) support the view that malabsorption is the primary cause of diarrhoea in this model.

However, *in vitro* perfusion studies in neonatal mice have shown that a secretory state exists in the presence of a glucose-free electrolyte solution, which can be reversed to absorption by the addition of glucose (Starkey et al, 1987). In the neonatal rat model *in vivo*, steady-state perfusion of the whole small intestine has shown that water absorption is significantly lower than controls at 12 h post-infection and there is a net secretory state for water from 18 to 48 h (Salim et al, 1989b). These data correlate well with morphometric findings which showed that mucosal damage antedates the onset of diarrhoea. Colonic salvage of sodium and water probably plays a significant role, such that diarrhoea only becomes evident when the colon is unable to handle the amount of fluid presented to it (Read, 1982). It has also been shown that net secretion of water is reversed to absorption by glucose-electrolyte solutions, which concurs with the findings of Starkey et al (1987). Thus, despite severe damage to the epithelium, glucose-coupled sodium transport remains intact in many animals.

We conclude that the villous atrophy of rotavirus infection is a result of rapid and extensive infection of the mature and differentiated villous epithelial cells, leading to cell death and extrusion into the lumen. These changes contribute to the induction of an acute, transient malabsorptive

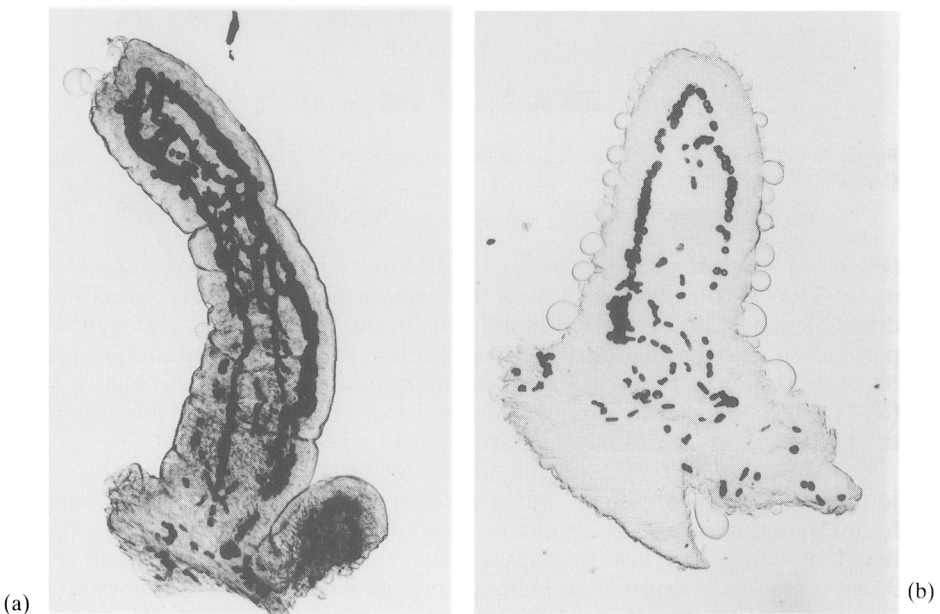


Figure 4. Villous microcirculation (a) in control and (b) rotavirus infected rat jejunum. (Salim et al, unpublished observations).

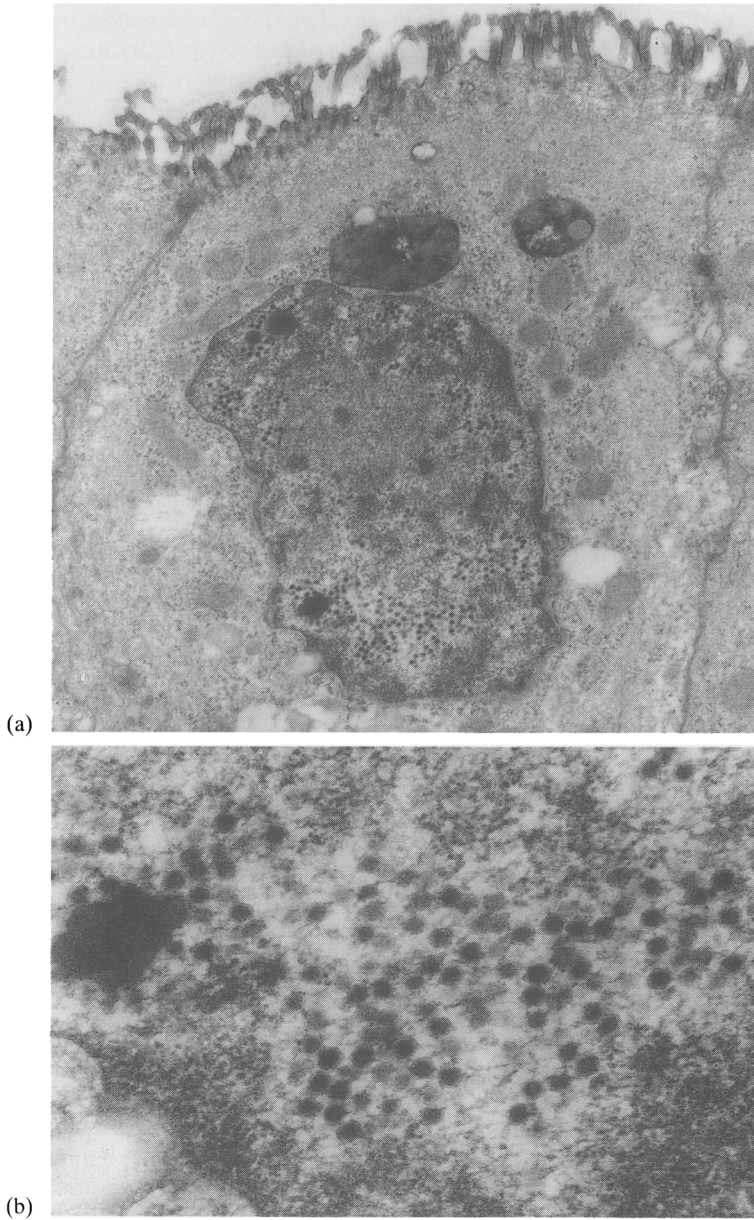


Figure 5. Adenovirus: (a) within nucleus of surface exposed epithelium. $\times 18\,300$. (b) Detail showing intranuclear adenovirus particles. $\times 69\,600$. (Figures reduced by 80% of original.)

diarrhoea that persists until the villi are repopulated with differentiated columnar epithelial cells. Villous ischaemia occurring in neonatal mice is not found in neonatal rats and therefore is unlikely to be a universal explanation for the pathophysiological disturbances seen in rotavirus diarrhoea.

ADENOVIRUSES

Although several serotypes of adenovirus are associated with diarrhoea, two distinct serotypes, 40 and 41, are mostly responsible for acute gastroenteritis in children. These viruses cannot be cultivated readily but can be detected by stool electron microscopy, and are called enteric or fastidious adenoviruses (de Jong et al, 1983). The fastidious adenoviruses are now recognized as being the second most commonly identified agent (after rotavirus) in stools of infants and young children with diarrhoea (Vesikari et al, 1981; Kidd et al, 1982; Yolken et al, 1982; Brandt et al, 1983; Uhnoo et al, 1986). Despite the growing importance of these viruses, however, the mechanism by which they produce diarrhoea in children is not well characterized and has only been studied comprehensively in pigs.

Adenovirus has been detected, however, within the small intestinal mucosa in man. Two cases were studied at autopsy (Whitelaw et al, 1977; Phillips, 1981) giving limited information because of the post mortem changes. Another infant with protracted diarrhoea had a small intestinal biopsy performed when adenovirus (serotype 40/41) was detected in the stools (Phillips, 1989). The virus was found in the mucosa in nuclei of enterocytes and was present in areas of cell extrusion (Figure 5). The enterocytes containing adenovirus had shortened microvilli and contained an increased number of autophagic vacuoles and polyribosomes. Virus was not detected in crypt epithelium or lamina propria.

In pigs experimentally infected with adenovirus both shortened and normal villi have been seen in the distal jejunum and ileum (Ducatelle et al, 1982). Immunoperoxidase staining and electron microscopic examination revealed that about 10–20% of the epithelial cells on the sides or at the base of the shortened villi were infected. Intranuclear inclusion bodies were seen in infected enterocytes. The nuclei were enlarged, rounded and were protruding into the lumen; microvilli were damaged and there were vacuoles in the cytoplasm. Some of the cells had ruptured with the cytoplasm extruding into the lumen. There was infiltration of the lamina propria with mononuclear cells.

It is not clear from these studies whether direct damage to the enterocyte is the only pathogenetic mechanism underlying adenovirus infection. Hall (1987) suggests that following initial destruction of the enterocytes, viraemia occurs which could account for the infection of other tissues. However, from the above experimental study we can not exclude the possibility that concurrent infection with conventional adenoviruses might be responsible for the symptoms produced in other systems.

NORWALK AGENT AND NORWALK-LIKE VIRUSES

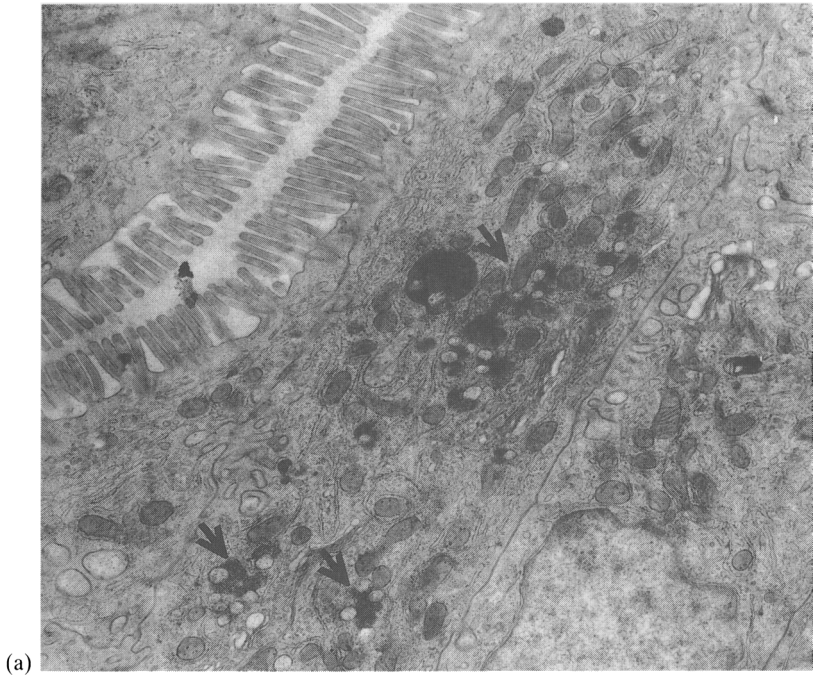
Norwalk and Norwalk-like viruses usually cause diarrhoea in older children and adults. These viruses have been associated with large numbers of outbreaks of gastroenteritis, especially in communities such as schools, colleges, restaurants and even on cruise ships at sea (Greenberg et al, 1979; Kaplan et al, 1982). However, numerous attempts to infect a wide range of animals including primates have failed to produce clinical disease. Therefore, the information relating to pathogenesis comes from small intestinal biopsies performed before, during and after administration of Norwalk and similar viruses to adult volunteers (Agus et al, 1973; Schreiber et al, 1974). Following oral administration of the virus, partial villous atrophy with broadening of villi and disorganization of the enterocytes was noted at the height of illness. Dilatation of the rough and smooth endoplasmic reticulum and an increase in multivesiculate bodies inside the enterocytes was observed. Microvilli of infected cells were shortened and the intercellular spaces were widened and filled with amorphous electron dense material. The lamina propria was infiltrated moderately with mononuclear cells. However, virus could not be identified in the infected mucosa, which returned spontaneously to normal within 2 weeks.

Schreiber et al (1974) have shown that the intestinal lesions in adult volunteers infected with stool filtrates containing Hawaii agent are similar to those seen with Norwalk virus infection. Some enterocytes were flattened while others contained vacuolated cytoplasm. The intercellular spaces between enterocytes and the lamina propria were infiltrated with mononuclear and polymorphonuclear leucocytes. Similar findings were reported by Dolin et al (1975) who used the same agent for experimental infection of volunteers. The villi returned to normal within 2-3 weeks.

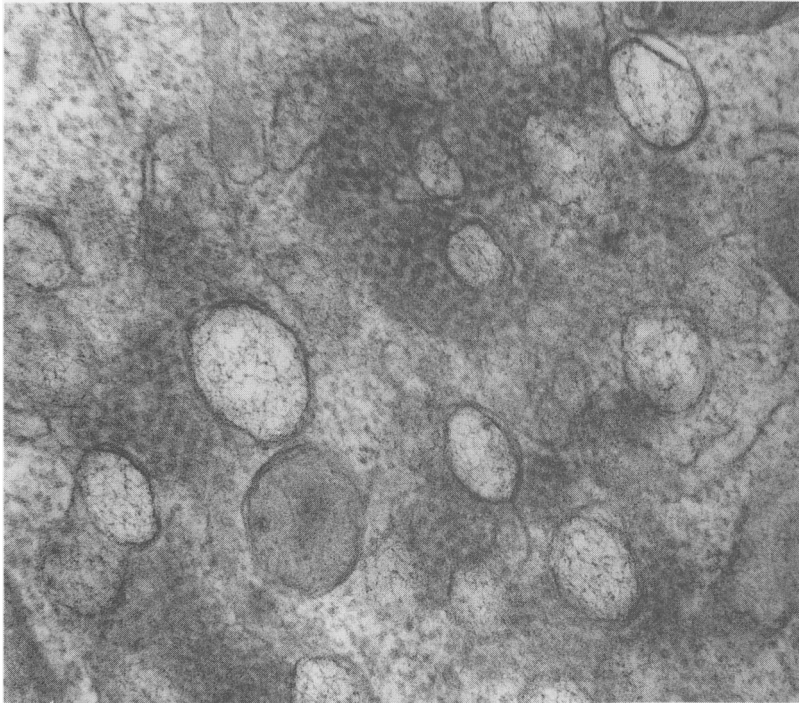
The above findings suggest that the pathogenetic mechanism underlying diarrhoea caused by these viruses is probably destruction of the absorptive cells resulting in malabsorption of nutrients and fluids. However, the role of decreased activities of jejunal brush border enzymes, such as alkaline phosphatase, sucrose and trehalase (Agus et al, 1973) also might play some role in the pathogenesis.

ASTROVIRUSES

Astroviruses are small (around 28 nm diameter) viruses that exhibit a six-pointed star-like surface structure on electron microscopy (Madeley and Cosgrove, 1976). They have been associated with several paediatric outbreaks of gastroenteritis (Ashley et al, 1978; Konno et al, 1982). In man, the virus apparently infects the enterocytes in the lower part of the villus. In one study, the virus was detected in the lower villous epithelium in four cases and in the surface epithelium of a flat biopsy in a fifth case (Phillips et al, 1982). Virus particles were found in association with membrane-bound vesicles containing flocculent material (Figure 6). Virus was neither seen in expanded rough endoplasmic reticulum nor in the nucleus. No particles



(a)



(b)

Figure 6. Astrovirus (a) within low villous epithelium (arrows). $\times 11\,000$. (b) Detail of cytoplasmic crystalline arrays of viral particles next to membrane-bound vesicles containing flocculent material. Note normal appearance of rough ER. $\times 77\,600$. (Figure 6a reduced by 95% and Figure 6b by 90% of the original.)

were found in crypt cells. Virus-like particles were also seen in the inclusion bodies of lamina propria macrophages.

In animals, the pathogenetic mechanisms vary from species to species (Hall, 1987). In lambs, mature enterocytes at the upper part of the villus are affected. As these die and are sloughed, the villi become shortened and the crypts hypertrophy. Virus particles were seen in lysosomes of enterocytes and lamina propria macrophages (Snodgrass and Gray, 1977; Snodgrass et al, 1979b; Gray et al, 1980). In calves, however, the epithelium covering the dome of the jejunal and ileal Peyer's patches is infected (Woode et al, 1984). The infected cells exfoliate and inflammatory cells migrate on to the surface of the dome. Infected epithelial cells change from columnar to cuboidal in shape, and the lamina propria of the dome villi become infiltrated with increased numbers of neutrophils. The germinal centres are depleted of lymphoid cells centrally while the remaining cells resemble macrophages, with eosinophilic cytoplasm and prominent nuclei. However, it is not clear whether infection of the epithelium of dome villi and subsequent depletion of lymphoid cells in the germinal centre affects the immune response. This could have consequences for the natural history of current and subsequent infections.

CALICIVIRUSES

Caliciviruses of human origin were first reported in the faeces of children with gastroenteritis by Madeley and Cosgrove (1976) and Flewett and Davies (1976). Little is known about the ways in which human caliciviruses cause intestinal disease. Flewett and Davies (1976), using negative staining electron microscopy, detected calicivirus in a small intestinal sample from a child who had died of acute gastroenteritis. However, experimental infection of calves with a calicivirus, the Newbury agent (Hall et al, 1984), has shown that the lesions were restricted to the proximal small intestine. Infected cells were swollen, their intracellular organelles were damaged and microvilli were abnormal or absent. The cells degenerate and are ultimately exfoliated. The villi became stunted and sometimes the lamina propria was exposed at the villus tip. There was increased infiltration with inflammatory cells in the lamina propria and the crypts were lengthened. The stunted villi returned to normal by 10 days after infection (Hall, 1987). However, villous height was increased in the terminal ileum, where no damage occurred. It has been suggested that the gut hormone enteroglucagon might act as a promoter of mucosal growth throughout the small intestine (Hall, 1987). Plasma enteroglucagon concentrations were found to be increased in calves infected with enteropathogenic viruses but not in calves infected with non-enteropathogenic viruses (Hall et al, 1985). However, the role of enteroglucagon in man following infection with calicivirus remains uncertain.

SUMMARY

In summary, the pathogenesis of many gut virus infections remains

uncertain. However, human and animal studies indicate that the majority of gut viruses infect villous enterocytes. Viruses appear to have different affinities for enterocytes at different sites on the villus. Infection of enterocytes leads to cell death, extrusion into the lumen, and villous atrophy when the rate of cell production in the crypts cannot keep pace with the rate of enterocyte loss. This results in a reduced surface area as well as impairment of digestive and absorptive functions. This may also result in a net secretory state. All these changes, along with others such as reduced enzymatic activity and reduced epithelial integrity, may contribute to the induction of an acute but transient malabsorptive diarrhoea which may persist until the digestive/absorptive functions of the enterocyte are restored. However, if colonic compensation is sufficient to handle the increased fluid load, diarrhoea may not be evident. The roles of villous ischaemia, altered countercurrent exchanger or altered immune responses still remain uncertain and require further investigation.

Acknowledgements

A. F. M. Salim gratefully acknowledges financial support by the Association of Commonwealth Universities. MJGF is a Wellcome Trust Senior Lecturer. The authors thank Ms Nicola Herrera for her assistance in the preparation of the manuscript.

REFERENCES

- Agus SG, Dolin R, Wyatt RG, Tousimis AJ & Northrup RS (1973) Acute infectious non-bacterial gastroenteritis: intestinal histopathology. Histologic and enzymatic alterations during illness produced by the Norwalk agent in man. *Annals of Internal Medicine* **79**: 18–25.
- Almeida JD, Hall T, Banatvala JE, Totterdell BM & Chrystie IL (1978) The effect of trypsin on the growth of rotavirus. *Journal of General Virology* **40**: 213–218.
- Ashley CR, Caul EO & Pavere WK (1978) Astrovirus-associated gastroenteritis in children. *Journal of Clinical Pathology* **31**: 939–943.
- Askaa J & Bloch B (1984) Infection in piglets with a porcine rotavirus-like virus. Experimental inoculation and ultrastructural examination. *Archives of Virology* **80**: 291–303.
- Bishop RF, Davidson GP, Holmes IH & Ruck BJ (1973) Virus particles in epithelial cells of duodenal mucosa from children with acute non-bacterial gastroenteritis. *The Lancet* **ii**: 1281–1283.
- Black RE, Merson MH, Rahman ASMM et al (1980) A two year study of bacterial, viral and parasitic agents associated with diarrhoea in rural Bangladesh. *Journal of Infectious Diseases* **142**: 660–664.
- Brandt CD, Kim HW, Rodriguez WJ et al (1983) Pediatric viral gastroenteritis during eight years of study. *Journal of Clinical Microbiology* **18**: 71–78.
- Collins J, Starkey WG, Wallis TS et al (1988) Intestinal enzyme profiles in normal and rotavirus infected mice. *Journal of Pediatric Gastroenterology and Nutrition* **7**: 264–272.
- Crouch CF & Woode GN (1978) Serial studies of virus multiplication and intestinal damage in gnotobiotic piglets infected with rotavirus. *Journal of Medical Microbiology* **11**: 325–334.
- Davidson GP & Barnes GL (1979) Structural and functional abnormalities of the small intestine in infants and young children with rotavirus enteritis. *Acta Paediatrica Scandinavica* **68**: 181–186.
- Davidson GP, Goller I, Bishop RF, Townley RRW, Holmes IH & Ruck BJ (1975) Immuno-

- fluorescence in duodenal mucosa of children with acute enteritis due to a new virus. *Journal of Clinical Pathology* **28**: 263–266.
- Davidson GP, Gall DG, Petric M, Butler DG & Hamilton JR (1977) Human rotavirus enteritis induced in conventional piglets. Intestinal structure and transport. *Journal of Clinical Investigation* **60**: 1402–1409.
- Dolin R, Levy AG, Wyatt RG, Thornhill TS & Gardner JD (1975) Viral gastroenteritis induced by the Hawaii agent. Jejunal histopathology and serologic response. *American Journal of Medicine* **59**: 761–768.
- Ducatelle R, Coussement W & Hoorens J (1982) Sequential pathological study of experimental porcine adenovirus enteritis. *Veterinary Pathology* **19**: 179–189.
- Eydelloth RS, Vonderfecht SL, Sheridan JF, Enders LD & Yolken RH (1984) Kinetics of viral replication and local and systemic immune responses in experimental rotavirus infection. *Journal of Virology* **50**: 947–950.
- Flewett TH & Davies H (1976) Caliciviruses in man. *The Lancet* **i**: 311.
- Graham DY, Sackman JW & Estes MK (1984) Pathogenesis of rotavirus induced diarrhea. Preliminary studies in miniature swine piglets. *Digestive Diseases and Sciences* **29**: 1029–1035.
- Graham DY, Estes MK & Sackman JW (1986) Rotavirus induces an osmotic diarrhea in miniature swine. *Gastroenterology* **82**: A1072.
- Grant JP (1987) *The State of the World's Children 1987*, pp 102–147. Oxford: Oxford University Press (published for UNICEF).
- Gray EW, Angus KW & Snodgrass DR (1980) Ultrastructure of the small intestine in astrovirus-infected lambs. *Journal of General Virology* **49**: 71–82.
- Greenberg HB, Valdesuso J, Yolken RH et al (1979) Role of Norwalk virus in outbreaks of non-bacterial gastroenteritis. *Journal of Infectious Diseases* **139**: 564–568.
- Hall GA (1987) Comparative pathology of infection by novel diarrhoea viruses. In *Novel Diarrhoea Viruses*, Ciba Foundation Symposium 128, pp 192–207. Chichester: John Wiley & Sons.
- Hall GA, Bridger JC, Brooker BE, Parsons KR & Ormerod E (1984) Lesions of gnotobiotic calves experimentally infected with a calici-like (Newbury) agent. *Veterinary Pathology* **21**: 208–215.
- Hall GA, Parsons KR, Bridger JC, Ghatei MA, Yin YC & Bloom SR (1985) Plasma enteroglucagon and neurotensin levels in gnotobiotic calves infected with enteropathogenic and non-enteropathogenic viruses. *Research in Veterinary Science* **38**: 99–103.
- Hamilton JG, Gall DG, Butler DG & Middleton PJ (1976) Viral gastroenteritis: Recent progress—remaining problems. In Elliot K & Knight J (eds) *Acute Diarrhoea in Childhood*, Ciba Foundation Symposium 42 (new series), pp 209–222. North Holland: Elsevier Excerpta Medica.
- Johnson CA, Snider TG, Henk WG & Fulton RW (1986) A scanning and transmission electron microscopic study of rotavirus induced intestinal lesions in neonatal gnotobiotic dogs. *Veterinary Pathology* **23**: 443–453.
- de Jong JC, Wigand R, Kidd AH et al (1983) Candidate adenoviruses 40 and 41: Fastidious adenoviruses from human infected stool. *Journal of Medical Virology* **11**: 215–231.
- Kapikian AZ, Kim HW, Wyatt RG et al (1976) Human reovirus-like agent as the major pathogen associated with 'winter' gastroenteritis in hospitalized infants and young children. *New England Journal of Medicine* **294**: 965–972.
- Kapikian AZ, Wyatt RG, Greenberg HB et al (1980) Approaches to immunization of infants and young children against gastroenteritis due to rotavirus. *Reviews of Infectious Diseases* **2**: 459–469.
- Kaplan JE, Gary GW, Baron RC et al (1982) Epidemiology of Norwalk gastroenteritis and the role of Norwalk virus in outbreaks of acute non-bacterial gastroenteritis. *Annals of Internal Medicine* **96**: 756–761.
- Kidd AH, Cosgrove BP, Brown RA & Madeley CR (1982) Faecal adenovirus from Glasgow babies. *Journal of Hygiene* **88**: 463–474.
- Konno T, Suzuki H, Ishida M, Chiba R, Mochizuki K & Tsunoda A (1982) Astrovirus-associated epidemic gastroenteritis in Japan. *Journal of Medical Virology* **9**: 11–17.
- McAdaragh JP, Bergelaud ME, Meyer RC et al (1980) Pathogenesis of rotaviral enteritis in gnotobiotic pigs: a microscopic study. *American Journal of Veterinary Research* **41**: 1572–1581.

- Madeley CR & Cosgrove BP (1976) Calicivirus in man. *The Lancet* **i**: 199–200.
- Mavromichalis J, Evans E, McNeish AS, Bryden AS, Davies HA & Flewett TH (1977) Intestinal damage in rotavirus and adenovirus gastroenteritis assessed by D-xylene malabsorption. *Archives of Disease in Childhood* **52**: 589–591.
- Mebus CA & Newman LE (1977) Scanning electron, light and immunofluorescent microscopy of intestine of gnotobiotic calf infected with reovirus-like agent. *Journal of Veterinary Research* **38**: 553–558.
- Middleton PJ, Szymanski MT, Abbott GD, Bartolussi R & Hamilton JR (1974) Orbivirus acute gastroenteritis of infancy. *The Lancet* **ii**: 1241–1244.
- Osborne MP, Haddon SJ, Spencer AJ et al (1988) An electron microscopic investigation of time related changes in the intestine of neonatal mice infected with murine rotavirus. *Journal of Pediatric Gastroenterology and Nutrition* **7**: 236–248.
- Pearson GR & McNulty MS (1979) Ultrastructural changes in small intestinal epithelium of neonatal pigs infected with pig rotavirus. *Archives of Virology* **59**: 127–136.
- Phillips AD (1981) Small intestinal mucosa in childhood in health and disease. *Scandinavian Journal of Gastroenterology* **16** (supplement **70**): 65–85.
- Phillips AD (1989) Mechanisms of mucosal injury: human studies. In Farthing MJG (ed.) *Viruses and the Gut. Proceedings of the 9th BSG-SK&F International Workshop*, pp 30–40. Windsor.
- Phillips AD, Rice SJ & Walker-Smith JA (1982) Astrovirus within human small intestinal mucosa. *Gut* **23**: A923–A924.
- Read NW (1982) Diarrhoea: the failure of colonic salvage. *Lancet* **ii**: 481–483.
- Salim AFM, Walker-Smith JA & Farthing MJG (1988) Characterization of experimental rotavirus diarrhoea in rat. *Gut* **29**: A1433–A1434.
- Salim AFM, Phillips AD, Walker-Smith JA & Farthing MJG (1989a) Experimental rotavirus infection in neonatal rats. *Pediatric Research* **26**: 280.
- Salim AFM, Walker-Smith JA & Farthing MJG (1989b) Intestinal water and solute transport in a neonatal rat model of rotavirus diarrhoea. *Pediatric Research* **26**: 280.
- Salim AFM, Phillips AD, Walker-Smith JA & Farthing MJG (1990) Villous ischaemia and the pathogenesis of rotavirus diarrhoea. *Gut* **31**: A610.
- Sato K, Inaba Y, Shinozaki T, Fuji R & Matumoto M (1981) Isolation of human rotavirus in cell culture. *Archives of Virology* **69**: 155–160.
- Schreiber DS, Blacklow NR & Trier JS (1974) The small intestinal lesion induced by Hawaii agent acute infectious non-bacterial gastroenteritis. *Journal of Infectious Diseases* **129**: 705–708.
- Snodgrass DR & Gray EW (1977) Detection and transmission of 30 nm virus particles (astroviruses) in faeces of lambs with diarrhoea. *Archives of Virology* **55**: 278–291.
- Snodgrass DR, Angus KW & Gray EW (1977) Rotavirus infection in lambs: pathogenesis and pathology. *Archives of Virology* **55**: 263–274.
- Snodgrass DR, Ferguson A, Allan F, Angus KW & Mitchell B (1979a) Small intestinal morphology and epithelial cell kinetics in lamb rotavirus infections. *Gastroenterology* **76**: 477–481.
- Snodgrass DR, Angus KW, Gray EW, Menzies JD & Paul G (1979b) Pathogenesis of diarrhoea caused by astrovirus infection in lambs. *Archives of Virology* **60**: 217–226.
- Starkey WG, Collins J, Wallis TS, Clark GJ, Spencer AJ et al (1986) Kinetics, tissue specificity and pathological changes in murine rotavirus infection of mice. *Journal of General Virology* **67**: 2625–2634.
- Starkey WG, Collins J, Haddon SJ, Osbourn MP, Stephen J & Candy DCA (1987) Reversal of net water secretion in small intestinal segments of rotavirus infected mice by WHO oral rehydration solutions. *Gut* **28**: A1334.
- Stephen J & Osbourne MP (1988) Pathological mechanisms in diarrhoeal disease. In Donachie W, Griffiths E & Stephen J (eds) *Bacterial Infections of the Respiratory and Gastrointestinal Mucosa. SGM Special Publication 24*, pp 149–172. IRL Press, Oxford.
- Suzuki H & Konno T (1975) Reovirus-like particles in jejunal mucosa of a Japanese infant with acute infectious non-bacterial gastroenteritis. *Tohoku Journal of Experimental Medicine* **115**: 199–211.
- Theil KW, Bohl EH, Cross RF, Kohler EM & Agnes AG (1978) Pathogenesis of porcine rotaviral infection in experimentally inoculated gnotobiotic pigs. *American Journal of Veterinary Research* **39**: 213–220.

- Uhnno I, Olding-Stenkvist E & Kneuger A (1986) Clinical features of acute gastroenteritis associated with rotavirus enteric adenoviruses and bacteria. *Archives of Disease in Childhood* **61**: 732–738.
- Urasawa T, Urasawa S & Taniguchi K (1981) Sequential passages of human rotavirus in MA-104 cells. *Microbiology and Immunology* **25**: 1025–1035.
- Vesikari T, Maki M, Sarkkinen HK, Arstila PP & Halonen PE (1981) Rotavirus, adenovirus and non-viral enteropathogens in diarrhoea. *Archives of Disease in Childhood* **56**: 264–270.
- Vonderfecht SL, Huber AC, Eiden JJ, Mader LC & Yolken RH (1984) Infectious diarrhea of infant rats produced by a rotavirus-like agent. *Journal of Virology* **52**: 94–98.
- Wanke CA, Lima AAM & Guerrant RL (1987) Infectious diarrhoea in tropical and sub-tropical regions. *Baillière's Clinical Gastroenterology* **1(2)**: 335–359.
- Ward RL, Bernstein DI, Young EC, Sherwood JR, Knowlton DR & Schiff GM (1986) Human rotavirus studies in volunteers: determination of infectious dose and serological response to infection. *Journal of Infectious Diseases* **154**: 871–884.
- Weiss C & Clark HF (1985) Rapid inactivation of rotaviruses by exposure to acid buffer or acidic gastric juice. *Journal of General Virology* **66**: 2725–2730.
- Whitelaw A, Davies HA & Parry J (1977) Electron microscopy of fatal adenovirus gastroenteritis. *The Lancet* **i**: 361.
- Woode GN, Pohlenz JF, Gourlay NEG & Fagerland JA (1984) Astrovirus and Breda virus infection of dome cell epithelium of bovine ileum. *Journal of Clinical Microbiology* **19**: 623–630.
- Yolken RH, Lawrence F, Leister F, Takiff HE & Strauss SE (1982) Gastroenteritis associated with enteric type adenovirus in hospitalized infants. *Journal of Pediatrics* **101**: 21–26.