



Case Report

Corynebacterium Total Hip and Knee Arthroplasty Prosthetic Joint Infections

Nicholas M. Hernandez, MD^a, Michael W. Buchanan, BS^{c,*}, Mark M. Cullen, BS^c,
Bryan S. Crook, BS^c, Michael P. Bolognesi, MD^a, Jessica Seidelman, MD, MPH^b,
William A. Jiranek, MD^a

^a Department of Orthopaedic Surgery, Duke University, Durham, NC, USA

^b Department of Infectious Disease, Duke University, Durham, NC, USA

^c School of Medicine, Duke University, Durham, NC, USA

ARTICLE INFO

Article history:

Received 3 January 2020

Received in revised form

8 March 2020

Accepted 10 March 2020

Available online xxx

Keywords:

Total hip arthroplasty

Total knee arthroplasty

Prosthetic joint infection

Corynebacterium

Reoperation

ABSTRACT

Prosthetic joint infections (PJIs) are typically caused by *Staphylococcus aureus* and coagulase-negative *Staphylococci* species. *Corynebacterium* species are microorganisms of the human skin and mucous membranes that are often considered contaminants when grown in culture. In the past, *Corynebacterium* species were often classified as diphtheroids based on growing as gram-positive rods in aerobic environments, but with advances in technology, the identification of *Corynebacterium* species has improved. *Corynebacterium* can cause infection, but there are few case reports of orthopaedic infection. We present 3 cases of total hip arthroplasty and 3 cases of total knee arthroplasty PJI caused by *Corynebacterium* species. We found a high failure rate of surgical treatment of *Corynebacterium* PJI, defined as reoperation for infection. This information adds to the limited literature on these organisms in total joint arthroplasty PJI.

© 2020 The Authors. Published by Elsevier Inc. on behalf of The American Association of Hip and Knee Surgeons. This is an open access article under the CC BY-NC-ND license (<http://creativecommons.org/licenses/by-nc-nd/4.0/>).

Introduction

Total hip arthroplasty (THA) and total knee arthroplasty (TKA) reliably relieve pain from osteoarthritis. One of the dreaded complications for both patients and surgeons is prosthetic joint infection (PJI). PJIs have a large economic burden [1], and they are associated with both morbidity and possibly mortality for the patient [2,3]. Treatments for PJI typically include debridement, antibiotics, and implant retention (DAIR); one-stage exchange arthroplasty; or 2-stage exchange arthroplasty. The most commonly identified pathogens causing PJI are gram-positive cocci, specifically *Staphylococcus aureus* and coagulase-negative *Staphylococci* species [4].

Corynebacterium species are ubiquitous microorganisms of the human skin and mucous membranes and when isolated from various clinical samples are typically considered contaminants. However, *Corynebacterium* has increasingly been recognized as the causative pathogen in many clinical scenarios. Historically,

distinguishing between *Corynebacterium* species has been challenging as many biochemical tests are required and many were simply classified as diphtheroids based on growing as gram-positive rods in aerobic environments. However, the increasing presence of matrix-assisted laser desorption ionization-time of flight mass spectrometry has made identification of *Corynebacterium* species fast, cheap, and accurate [5]. As a result, many cultures that may have previously been identified as diphtheroids are now being identified as a particular *Corynebacterium* species.

Corynebacterium species are responsible for many types of infections including, but not limited to, skin and soft-tissue infections, pneumonia, postsurgical infections, urinary tract infections, prostatitis, cerebrospinal fluid infections, peritoneal dialysis-related infections, and endocarditis [6–13]. Although there are several case reports of *Corynebacterium* PJIs, joint infections, or bone infections [7,8,14–16], the data on diagnosing and treating THA and TKA PJI caused by *Corynebacterium* species are limited. We present 6 THA and TKA PJI cases thought to be caused by *Corynebacterium* species. The institutional database was retrospectively queried to find these cases. We classified patients by Musculoskeletal Infection Society (MSIS) criteria as well as host and extremity status as defined by McPherson et al. [17–19]. Follow-up

* Corresponding author. Duke University SoM, Durham, NC 27710, USA. Tel.: +1-605-377-4099.

E-mail address: mwb38@duke.edu

was defined as from the operation for *Corynebacterium* PJI to the most recent clinical follow-up. The operations for *Corynebacterium* PJI were performed by multiple surgeons at a single institution. Institutional review board approval was obtained for this investigation.

Case histories

Case 1

A 69-year-old woman with a preoperative body mass index (BMI) of 30 kg/m² and a past medical history of rheumatoid arthritis presented with a painful right THA. She underwent a right THA in January 2017 (Fig. 1). Twenty-two days postoperatively, she developed increasing pain, erythema, swelling, and drainage. On initial presentation, she had an erythrocyte sedimentation rate (ESR) of 100 mm/hr (Ref: 0–15 mm/hr), a C-reactive protein (CRP) of 24 mg/dL (reference: ≤ 0.6 mg/dL), and aspiration showed a synovial white blood cell (WBC) count of 17,650 cells/mm³ with 54% neutrophils. She underwent DAIR in February 2017, and 5 of 5 cultures grew *Corynebacterium striatum*. She had persistent drainage after surgery, and 2 weeks later, she underwent resection arthroplasty with placement of an articulating antibiotic spacer (Fig. 2). The patient's host and extremity status were B2. The patient met MSIS major criteria with 2 positive cultures for *C. striatum*. She completed antibiotic therapy with intravenous (IV) vancomycin for 6 weeks without additional oral antibiotics. Unfortunately, she had increased pain in her hip in August 2017. Laboratory tests showed her ESR had increased from 9 mm/hr in May to 22 mm/hr in August 2017; her CRP had increased from 4.4 mg/dL in July to 22.7 mg/dL in August 2017; and her aspiration had changed from 4 cells/mm³

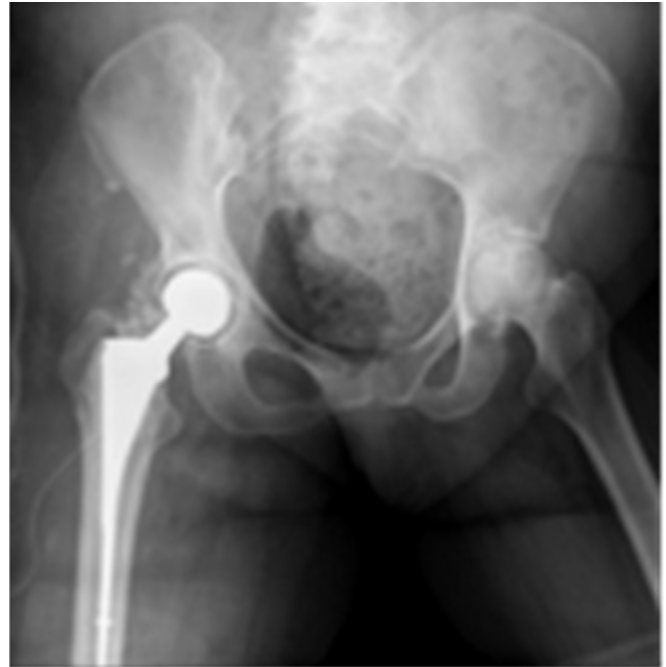

Figure 2. Articulating spacer in case 1.

with 60% neutrophils in July to 1446 cells/mm³ with 60% neutrophils in August 2017. It was decided that she may not have cleared her infection, or she had infection recurrence. In September 2017, she underwent a spacer exchange to another articulating spacer. From this surgery, 2 of 2 intraoperative cultures were positive for *Enterococcus faecalis*. She did well postoperatively, and aspiration before reimplantation showed a WBC count of 55 cells/mm³ with 8% neutrophils. Reimplantation was performed in May of 2018. She developed recurrent *E. faecalis* PJI 1 year later and underwent resection and placement of an articulating spacer. The current plan is to retain the articulating spacer if the patient has reasonable pain control and function. Any future infection or failure will likely be treated with a definitive resection arthroplasty. Her most recent clinical follow-up was August 2019, giving 30 months of follow-up.

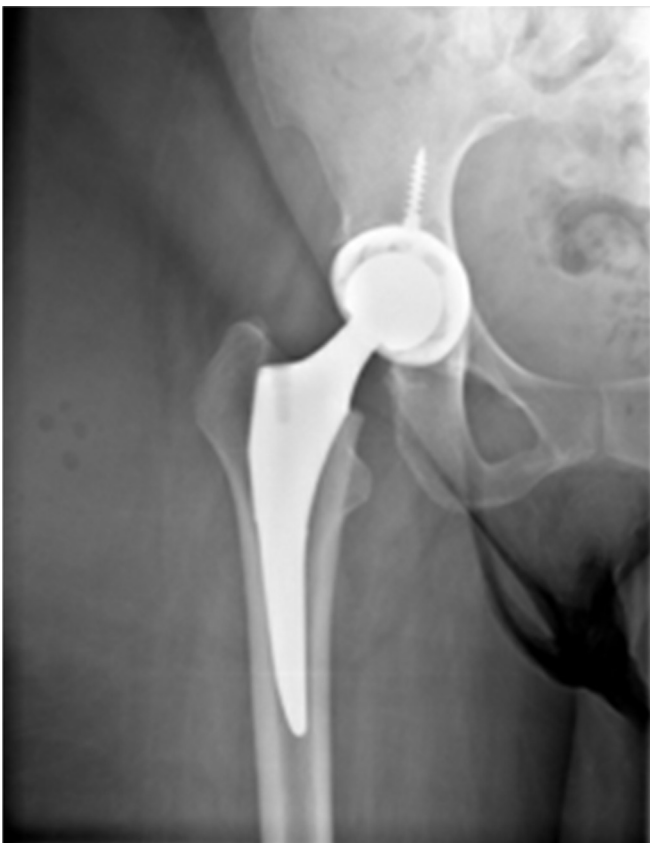

Figure 1. THA at presentation in case 1. THA, total hip arthroplasty.

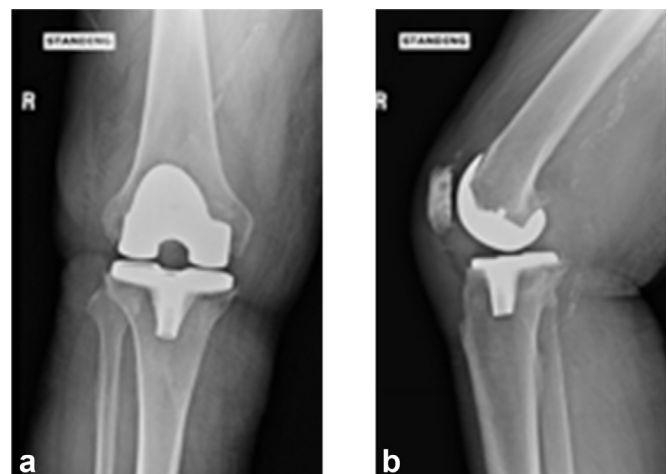


Figure 3. (a) and (b). AP and lateral radiograph of TKA at presentation in case 2. TKA, total knee arthroplasty.

Case 2

A 63-year-old man with a preoperative BMI of 40 kg/m² and a past medical history significant for type 2 diabetes, cerebrovascular accident, and tobacco use underwent right TKA in 2015 for osteoarthritis at an outside institution. He presented to our hospital in June of 2018 because of chronic right knee pain with a 15-degree flexion contracture. On presentation, his hemoglobin A1C was 8%, ESR was 46 mm/hr, CRP was 1.91 mg/dL, and aspiration showed an elevated synovial WBC count of 112,650 cells/mm³ and 92% neutrophils. His presenting radiographs are shown in Figure 3a and b. The patient had multiple interventions regarding smoking cessation without success. He underwent resection and placement of a static spacer in August of 2018 (Fig. 4). *C. striatum* grew from 3 of 6 operative cultures. The patient's host status and extremity status were B2. He met major MSIS criteria with 2 positive cultures of *C. striatum*. He was treated with 6 weeks of IV vancomycin. He underwent reimplantation in January of 2019. At his latest follow-up, his range of motion was 4 degrees shy of full extension with flexion to 100 degrees. His most recent clinical follow-up was in September 2019, giving 13 months of follow-up.

Case 3

A 70-year-old woman with a BMI of 28.8 kg/m² and a past medical history significant for rheumatoid arthritis, type 2 diabetes mellitus, and hypoalbuminemia underwent a left TKA for osteoarthritis in May 2018 at our institution. Her hemoglobin A1C was 6.3% before her index TKA. Seven weeks after index TKA, she was admitted for wound dehiscence, purulent drainage, and fever (Fig. 5). Aspiration on admission revealed synovial WBC count of 172,060 cells/mm³ with 84% neutrophils, and blood tests revealed an ESR of 116 mm/hr and CRP of 35 mg/dL. She underwent DAIR and was started on IV vancomycin and piperacillin-tazobactam postoperatively. Four of 4 intraoperative cultures were positive for *C. striatum*, and 3 of the 4 were also positive for *Peptoniphilus asaccharolyticus* and *Prevotella bivia*. She met major MSIS criteria for PJI with 2 positive cultures, and her host and extremity grade were C2. Two weeks later while still in the hospital, purulent drainage was noted from the incision site and she underwent a resection with placement of a static spacer. She continued to have signs of infection, leading to repeat irrigation and debridement (I&D). Vascular surgery was consulted for acutely increased left

lower extremity pain and darkening of her toes. A computed tomography angiogram revealed severe chronic multilevel vascular disease in her left leg, and she ultimately underwent above-knee amputation (AKA) in July 2018 after a multidisciplinary team concluded that amputation provided the best chance to eradicate her severe infection in the setting of poor blood supply. She was discharged in August 2018 after 6 revisions of her AKA. She subsequently required repeated hospitalizations for multiple infections and complications of peripheral vascular disease in the contralateral extremity, and she ultimately expired from sepsis 11 months after her index TKA in April 2019.

Case 4

A 77-year-old woman with a BMI of 37 kg/m² and past medical history significant for atrial fibrillation, bilateral TKA, and right THA presented to us with chronic THA PJI. She underwent index right THA in 2011 and had a 2-stage exchange in 2013 for PJI. She presented to our institution in January 2019 with continued hip pain, erythema, and a draining sinus tract while taking oral ampicillin and doxycycline for suppression (Fig. 6). Radiographs showed lucency around her cup, and the preoperative ESR and CRP were 90 mm/hr and 12.71 mg/dL, respectively. She underwent a resection arthroplasty in May of 2019 with placement of a static spacer. Five

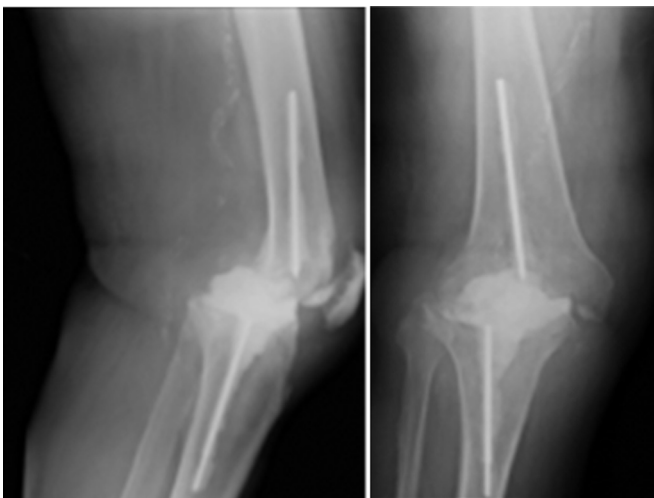


Figure 4. Static spacer in case 2.

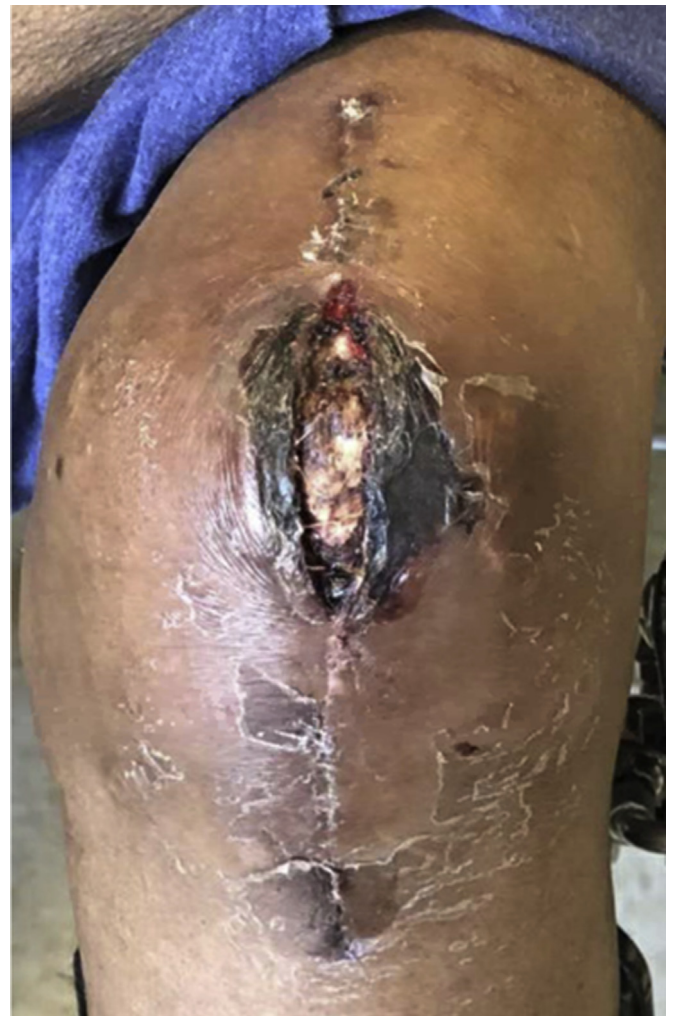

Figure 5. Wound dehiscence in case 3.

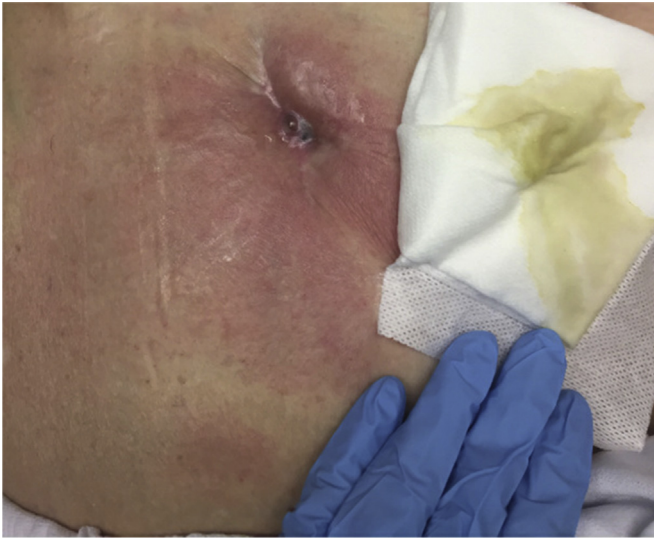

Figure 6. Draining sinus tract at presentation in case 4.

of 6 intraoperative cultures grew *C. striatum*, meeting major MSIS criteria for PJI. Her host and extremity status were A2. She received 8 weeks of IV vancomycin and ertapenem postoperatively. She was placed on ertapenem in addition to vancomycin because one of 6 intraoperative cultures grew *Mycobacterium avium*, and at presentation to our institution, she had a chronic sinus while on ampicillin and doxycycline. In August of 2019, she showed no signs or symptoms of infection, ESR and CRP remained within normal limits, and an aspiration of the hip had no microbial growth. She underwent reimplantation in November 2019. Seven weeks after her reimplantation, she suffered a dislocation that could not be closed reduced. She therefore underwent open reduction and her femoral head was exchanged from a 36- to 40-mm head. Ten weeks after her reimplantation, she presented to the emergency department with fevers and chills as well as new erythema and drainage at her incision site. The ESR was 129 mm/hr, CRP was 22.9 mg/dL, and joint aspirate was positive for *E. faecium*. She subsequently underwent DAIR in January of 2020. Four of 4 intraoperative cultures were positive for *E. faecium*, and 2 of 4 cultures were positive for *Staphylococcus epidermidis*. She was placed on a 6-week course of IV vancomycin. Her most recent follow-up was in February 2020, giving 9 months of follow-up.

Case 5

A 66-year-old man with a BMI of 24.13 kg/m² and with a past medical history significant for rheumatoid arthritis and left olecranon septic bursitis presented with a chronic, right TKA PJI. His index TKA was performed in 2015. The patient's infected olecranon bursitis first occurred after a rheumatoid nodule was removed in 2014 and his elbow was noted to have drainage; he underwent multiple I&Ds of the elbow. These were culture positive for *Pseudomonas aeruginosa*, *Staphylococcus warneri*, and *S. epidermidis*. The patient presented to our institution in February of 2018 with a sinus tract about his TKA. He continued to have medical care at an outside institution, and later in February, he underwent a DAIR at an outside hospital. He presented back to our institution in April with a nonhealing wound. Blood work from April 2018 showed an ESR of 65 mm/hr, CRP 43.9 mg/dL, and a knee aspirate showed a WBC count of 2853 cells/mm³ with 46% neutrophils. In April 2018, the patient underwent resection arthroplasty with placement of an articulating spacer and a right knee gastrocnemius flap to cover a soft-tissue defect. Seven intraoperative cultures were taken, 3 of

which were positive for *C. striatum*. The patient met major MSIS criteria with 2 positive cultures. The patient's host status and extremity status were C3. The patient completed 6 weeks of IV vancomycin. Three weeks after resection the patient began having subjective fevers and increased purulent and foul-smelling drainage (Fig. 7). The decision was made to perform an AKA in May 2018. This was further complicated by a surgical site abscess, and the patient underwent 5 additional debridements. At his most recent follow-up he has had no other issues with his leg. His most recent clinical follow-up was in May 2019, giving 12 months of follow-up.

Case 6

A 72-year-old female with a preoperative BMI of 36.13 kg/m² and past medical history significant for rheumatoid arthritis presented with a chronic, right THA PJI. She had her index surgery at our institution in 2012. In 2013, she underwent revision for aseptic loosening of her acetabular component. In 2015, the patient had a custom triflange acetabular component for pelvic discontinuity. In March 2015, 2 weeks after her revision, the patient was noted to have persistent drainage at her first post-operative visit, concerning for PJI. From March to December of 2015, she was treated with multiple DAIRs, with intraoperative cultures over this time period coming back positive for a variety of organisms including *Escherichia coli*, vancomycin-resistant *E. faecium*, *Proteus vulgaris*, and *Serratia marcescens*. The patient eventually underwent resection arthroplasty in December of 2015. The patient was stable on suppressive cephalexin until May 2018 when she presented with a sinus tract about the hip. Blood work showed an ESR of 108 mm/hr

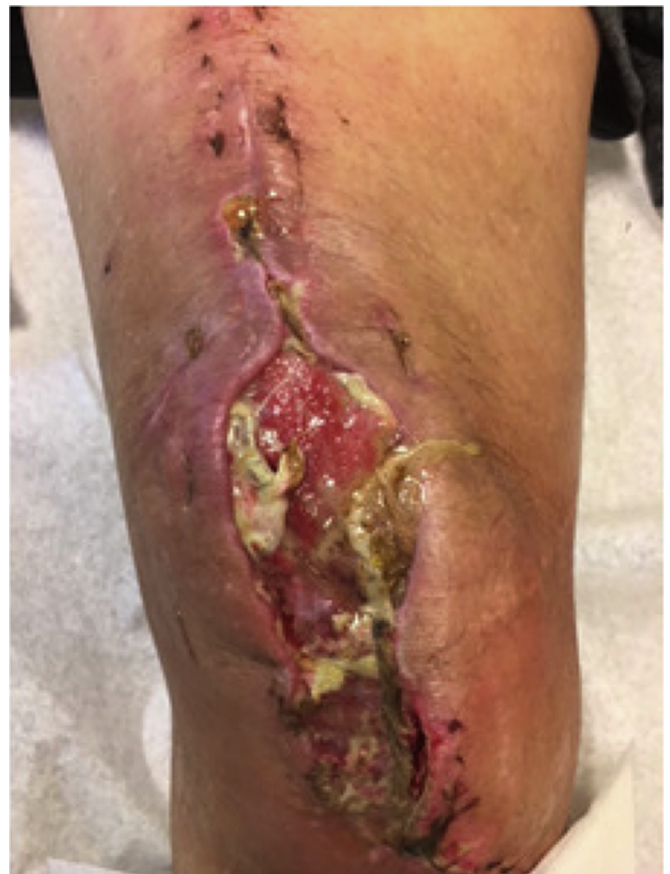

Figure 7. Poor wound healing with drainage after resection and before AKA in case 5. AKA, above-knee amputation.

and a CRP of 17.9 mg/dL. Aspiration of the hip showed an elevated synovial WBC count of 22,448 cells/mm³ with 92% neutrophils. The patient underwent an I&D in July 2018 with 4 of 5 intraoperative cultures positive for *C. striatum* and 3 of 5 cultures positive for vancomycin sensitive *E. faecium*. The patient met major MSIS criteria as she had a sinus tract. The patient's host status and extremity status were C2. The patient was treated with tedizolid for 8 weeks, as she developed bullous dermatitis previously on vancomycin and had a history of vancomycin resistant organisms. The patient was noted to have persistent drainage following the I&D. An aspiration in September 2018 showed a synovial WBC count of 18,310 cells/mm³ with 93% neutrophils. She underwent an I&D in November 2018. Three out of 3 intraoperative cultures grew *C. striatum*, and one of the 3 cultures was positive for vancomycin-sensitive *E. faecium*. At the most recent follow-up, she was noted to have a nonhealing wound over her hip, and she is currently being treated with local wound care. Her most recent clinical follow-up was in September 2019, giving her 14 months of follow-up. Given the persistent nature of her infection and poor host and extremity status, there is currently no plan for reimplantation.

Discussion

Corynebacterium is a rare but challenging pathogen that causes PJIs. In the current case series, we found a high failure rate of surgical and medical treatment of *Corynebacterium* PJI, defined as reoperation for infection (Table 1). Most patients were treated with IV antibiotics as these organisms are typically resistant to oral antibiotics. This information adds to the limited literature on these organisms and can aid surgeons, infectious disease physicians, and the patient regarding the difficult management of *Corynebacterium* PJIs.

There are limited reports of *Corynebacterium* orthopaedic infections. von Graevenitz et al. [16] found 73 *Corynebacterium* isolates from open fracture and PJIs in 60 patients over a 5-year time period. In this study, some of the most frequent species were

Corynebacterium amycolatum, *C. striatum*, and *Corynebacterium diphtheria*. Scholle [15] discussed the case of a spontaneous joint infection in a left knee with *C. striatum*. They noted that this isolate was resistant to most antibiotics. Achermann et al. [7] describes the case of a *Corynebacterium bovis* shoulder PJI. This patient was treated with a 2-stage exchange protocol and 3 months of antibiotics. Sonication of the prosthesis helped to identify the pathogen. These studies highlight that *Corynebacterium* can be difficult to detect and can cause true orthopaedic infection.

In our series, many patients had compromised host and extremity status, had undergone prior operations for PJI, or had polymicrobial infection, which could have been factors associated with the high rate of infection recurrence [20–22]. *Corynebacterium* is an opportunistic pathogen that has been reported in those with prolonged hospitalizations, immunocompromised states, or prosthetic devices [9]. It is challenging to tell if it is the *Corynebacterium* or the complex nature of the infections in this study that led to a high rate of infection recurrence, but it is likely that both play a role.

Rates of infection eradication vary depending on the surgical treatment and the organism. Two-stage exchange protocol in TJA has led to infection eradication in 73%–78% of patients [23,24], while DAIR has been less promising with success rates ranging from 37% to 66% [25–27]. In the present study, all 3 patients treated with DAIR or I&D required reoperation for infection. Only one patient with resection arthroplasty who went on to reimplantation has remained infection free at latest follow-up (Table 1). Neither DAIR nor 2-stage exchange was associated with good infection eradication, albeit in a very small series.

It is important to note that *Corynebacterium* species are resistant to many antibiotics. Isolates can be resistant to penicillin, levofloxacin, sparfloxacin, cephalosporins, clindamycin, erythromycin, minocycline, linezolid, and imipenem [15,28–31]. Because many *Corynebacterium* species are resistant to oral antibiotics, a course of IV antibiotics is typically necessary. This makes long-term suppression with oral antibiotics unlikely to be successful in these patients.

Table 1
Details of *Corynebacterium* prosthetic joint infections.

Patient case number	TKA or THA	Type of surgery for <i>Corynebacterium</i> -related PJI	Preoperative culture from aspirate	Intraoperative cultures	Type of antibiotic(s)	Duration of antibiotic(s) (wk)	Infection recurrence	Additional surgical treatment
1	THA	DAIR	NG	<i>Corynebacterium striatum</i> (5/5)	IV vancomycin	6	Yes	Resection and articulating spacer, spacer exchange, reimplantation, resection and articulating spacer Reimplantation
2	TKA	Resection arthroplasty with static spacer	<i>Corynebacterium striatum</i>	<i>Corynebacterium striatum</i> (3/6)	IV vancomycin	6	No	Reimplantation
3	TKA	DAIR	<i>Corynebacterium striatum</i>	<i>Corynebacterium striatum</i> (4/4), <i>Prevotella bivia</i> (3/4), <i>Peptoniphilus asaccharolyticus</i> (3/4)	IV vancomycin and piperacillin/tazobactam	12	Yes	Resection with static spacer, I&D, AKA with multiple debridements
4	THA	Resection arthroplasty with static spacer	No aspirate	<i>Corynebacterium striatum</i> (5/6), <i>Mycobacterium avium</i> (1/6)	IV vancomycin and ertapenem	8	Yes	Reimplantation, revision, DAIR
5	TKA	Resection arthroplasty with articulating spacer	<i>Corynebacterium striatum</i>	<i>Corynebacterium striatum</i> (3/7)	IV vancomycin	6	Yes	AKA with multiple debridements
6	THA	I&D	<i>Corynebacterium striatum</i>	<i>Corynebacterium striatum</i> (4/5), <i>Enterococcus faecium</i> (3/5)	PO tedizolid	8	Yes	I&D

THA, total hip arthroplasty; TKA, total knee arthroplasty; PJI, prosthetic joint infection; DAIR, debridement, antibiotics, and implant retention; NG, no growth; IV, intravenous; PO, oral; AKA, above-knee amputation; I&D, irrigation and debridement.

Summary

In conclusion, our case series of *Corynebacterium* PJI's demonstrates that this organism can be the cause of THA and TKA PJI. *C. striatum* was an organism in all our cases and was resistant to many oral antibiotics, eliminating the option for oral suppression. These infections were often present in patients who were medically compromised hosts and were associated with a high rate of recurrence. Therefore, these patients should be followed up closely by both orthopaedic surgery and infectious disease physicians for signs of infection recurrence. In addition, an effort should be made to medically optimize these patients before surgery.

Conflict of interest

Michael P. Bolognesi reports royalties from Zimmer Biomet and TJO; paid consultancy for Total Joint Orthopaedics and Zimmer Biomet; stock or stock options in TJO and Amedica; research support from or supplier as a principal investigator of DePuy, Synthes, Exactech, and PCORI; other financial or material support from Zimmer Biomet, DePuy, Stryker, TJO, Smith & Nephew, DJO, and Exactech; medical/orthopaedic publications editorial/governing board of *Arthroplasty Today*; and a board member/committee appointments for EOA, AAHKS, AAOS, JOA, and JSOA. William A. Jiranek reports royalties from DePuy; speakers bureau/paid presentations for DePuy; and a board member/committee appointments for Hip Society. The other authors declare no potential conflicts of interest.

References

- [1] Kurtz SM, Lau E, Watson H, Schmier JK, Parvizi J. Economic burden of periprosthetic joint infection in the United States. *J Arthroplasty* 2012;27(8 Suppl):61.
- [2] Lum ZC, Natsuhara KM, Shelton TJ, Giordani M, Pereira GC, Meehan JP. Mortality during total knee periprosthetic joint infection. *J Arthroplasty* 2018;33(12):3783.
- [3] Natsuhara KM, Shelton TJ, Meehan JP, Lum ZC. Mortality during total hip periprosthetic joint infection. *J Arthroplasty* 2019;34(7S):S337.
- [4] Tande AJ, Patel R. Prosthetic joint infection. *Clin Microbiol Rev* 2014;27(2):302.
- [5] Konrad R, Berger A, Huber I, et al. Matrix-assisted laser desorption/ionisation time-of-flight (MALDI-TOF) mass spectrometry as a tool for rapid diagnosis of potentially toxigenic *Corynebacterium* species in the laboratory management of diphtheria-associated bacteria. *Euro Surveill* 2010;15(43).
- [6] Chandran R, Puthukkichal DR, Suman E, Mangalore SK. Diphtheroids—important nosocomial pathogens. *J Clin Diagn Res* 2016;10(12):DC28.
- [7] Achermann Y, Trampuz A, Moro F, Wust J, Vogt M. *Corynebacterium bovis* shoulder prosthetic joint infection: the first reported case. *Diagn Microbiol Infect Dis* 2009;64(2):213.
- [8] Cazanave C, Greenwood-Quaintance KE, Hanssen AD, Patel R. *Corynebacterium* prosthetic joint infection. *J Clin Microbiol* 2012;50(5):1518.
- [9] Funke G, von Graevenitz A, Clarridge 3rd JE, Bernard KA. Clinical microbiology of coryneform bacteria. *Clin Microbiol Rev* 1997;10(1):125.
- [10] Hong HL, Koh HI, Lee AJ. Native Valve endocarditis due to *Corynebacterium striatum* confirmed by 16S ribosomal RNA sequencing: a case report and literature review. *Infect Chemother* 2016;48(3):239.
- [11] Mottola C, Mendes JJ, Cristino JM, Cavaco-Silva P, Tavares L, Oliveira M. Polymicrobial biofilms by diabetic foot clinical isolates. *Folia Microbiol (Praha)* 2016;61(1):35.
- [12] Reece RM, Cunha CB, Rich JD. *Corynebacterium minutissimum* vascular graft infection: case report and review of 281 cases of prosthetic device-related *Corynebacterium* infection. *Scand J Infect Dis* 2014;46(9):609.
- [13] van Asten SA, La Fontaine J, Peters EJ, Bhavan K, Kim PJ, Lavery LA. The microbiome of diabetic foot osteomyelitis. *Eur J Clin Microbiol Infect Dis* 2016;35(2):293.
- [14] Roux V, Drancourt M, Stein A, Riegel P, Raoult D, La Scola B. *Corynebacterium* species isolated from bone and joint infections identified by 16S rRNA gene sequence analysis. *J Clin Microbiol* 2004;42(5):2231.
- [15] Scholle D. A spontaneous joint infection with *Corynebacterium striatum*. *J Clin Microbiol* 2007;45(2):656.
- [16] von Graevenitz A, Frommelt L, Punter-Streit V, Funke G. Diversity of coryneforms found in infections following prosthetic joint insertion and open fractures. *Infection* 1998;26(1):36.
- [17] McPherson EJ, Tontz Jr W, Patzakis M, et al. Outcome of infected total knee utilizing a staging system for prosthetic joint infection. *Am J Orthop (Belle Mead NJ)* 1999;28(3):161.
- [18] McPherson EJ, Woodson C, Holtom P, Roidis N, Shufelt C, Patzakis M. Periprosthetic total hip infection: outcomes using a staging system. *Clin Orthop Relat Res* 2002;403:8.
- [19] Parvizi J, Gehrke T. International consensus group on periprosthetic joint I. Definition of periprosthetic joint infection. *J Arthroplasty* 2014;29(7):1331.
- [20] Bozic KJ, Lau E, Kurtz S, et al. Patient-related risk factors for periprosthetic joint infection and postoperative mortality following total hip arthroplasty in Medicare patients. *J Bone Joint Surg Am* 2012;94(9):794.
- [21] Ji B, Zhang X, Xu B, et al. The fate of immunocompromised patients in the treatment of chronic periprosthetic joint infection: a single-centre experience. *Int Orthop* 2018;42(3):487.
- [22] Tan TL, Kheir MM, Tan DD, Parvizi J. Polymicrobial periprosthetic joint infections: outcome of treatment and identification of risk factors. *J Bone Joint Surg Am* 2016;98(24):2082.
- [23] Ford AN, Holzmeister AM, Rees HW, Belich PD. Characterization of outcomes of 2-stage exchange arthroplasty in the treatment of prosthetic joint infections. *J Arthroplasty* 2018;33(7S):S224.
- [24] Mahmud T, Lyons MC, Naudie DD, Macdonald SJ, McCalden RW. Assessing the gold standard: a review of 253 two-stage revisions for infected TKA. *Clin Orthop Relat Res* 2012;470(10):2730.
- [25] Azzam KA, Seeley M, Ghanem E, Austin MS, Purtill JJ, Parvizi J. Irrigation and debridement in the management of prosthetic joint infection: traditional indications revisited. *J Arthroplasty* 2010;25(7):1022.
- [26] Parvizi J, Azzam K, Ghanem E, Austin MS, Rothman RH. Periprosthetic infection due to resistant staphylococci: serious problems on the horizon. *Clin Orthop Relat Res* 2009;467(7):1732.
- [27] Weston JT, Watts CD, Mabry TM, Hanssen AD, Berry DJ, Abdel MP. Irrigation and debridement with chronic antibiotic suppression for the management of infected total knee arthroplasty: a contemporary Analysis. *Bone Joint J* 2018;100-B(11):1471.
- [28] Kocazeybek B, Ozder A, Kucukoglu S, Kucukates E, Yuksel H, Olga R. Report of a case with polymicrobial endocarditis related to multiresistant strains. *Chemotherapy* 2002;48(6):316.
- [29] Otsuka Y, Ohkusu K, Kawamura Y, Baba S, Ezaki T, Kimura S. Emergence of multidrug-resistant *Corynebacterium striatum* as a nosocomial pathogen in long-term hospitalized patients with underlying diseases. *Diagn Microbiol Infect Dis* 2006;54(2):109.
- [30] Sierra JM, Martinez-Martinez L, Vazquez F, Giralt E, Vila J. Relationship between mutations in the *gyrA* gene and quinolone resistance in clinical isolates of *Corynebacterium striatum* and *Corynebacterium amycolatum*. *Antimicrob Agents Chemother* 2005;49(5):1714.
- [31] Tarr PE, Stock F, Cooke RH, Fedorko DP, Lucey DR. Multidrug-resistant *Corynebacterium striatum* pneumonia in a heart transplant recipient. *Transpl Infect Dis* 2003;5(1):53.