

# Patients with NSCLCs Harboring Internal Inversions or Deletion Rearrangements of the *ALK* Gene Have Durable Responses to *ALK* Kinase Inhibitors

This article was published in the following Dove Press journal:  
*Lung Cancer: Targets and Therapy*

Alexa B Schrock<sup>1</sup>  
 Russell Madison<sup>1</sup>  
 Mark Rosenzweig<sup>2</sup>  
 Justin M Allen<sup>2</sup>  
 Rachel L Erlich<sup>2</sup>  
 Siao-Yi Wang<sup>3</sup>  
 Tarek Chidiac<sup>4</sup>  
 Vodur Suresh Reddy<sup>5</sup>  
 Jonathan W Riess<sup>6</sup>  
 Ahmet Ersin Yassa<sup>6</sup>  
 Abdur Shakir<sup>7</sup>  
 Vincent A Miller<sup>1</sup>  
 Brian M Alexander<sup>1</sup>  
 Jeffrey Venstrom<sup>1</sup>  
 Kimberly McGregor<sup>1</sup>  
 Siraj M Ali<sup>1</sup>

<sup>1</sup>Foundation Medicine, Department of Clinical Development, Cambridge, MA, USA; <sup>2</sup>Foundation Medicine, Department of Translational Oncology and Clinical Reporting, Cambridge, MA, USA; <sup>3</sup>Loyola University Medical Center, Department of Hematology and Oncology, Maywood, IL, USA; <sup>4</sup>Zangmeister Cancer Center, Department of Hematology and Oncology, Columbus, OH, USA; <sup>5</sup>Cancer Care Specialists, Department of Hematology and Oncology, Reno, NV, USA; <sup>6</sup>UC Davis Comprehensive Cancer Center, Department of Hematology and Oncology Sacramento, CA, USA; <sup>7</sup>Sarah Bush Lincoln Health System, Department of Medical Oncology, Mattoon, IL, USA

Correspondence: Alexa B Schrock  
 Foundation Medicine, 150 Second Street,  
 Cambridge, MA 02141, USA  
 Tel +1617-418-2200  
 Email [aschrock@foundationmedicine.com](mailto:aschrock@foundationmedicine.com)

**Background:** *ALK* fusions are targetable drivers in non-small-cell lung cancer (NSCLC). However, patients with NSCLC harboring *ALK* rearrangements without a fusion partner identified in DNA have also been shown to respond to *ALK* inhibitors. We aimed to characterize complex *ALK* variants that may predict sensitivity to multiple approved *ALK* inhibitors.

**Methods:** Comprehensive genomic profiling (CGP) of DNA isolated from formalin-fixed paraffin-embedded (FFPE) tumor tissue or blood-based circulating tumor DNA was performed for 39,159 NSCLC patients during routine clinical care. For a subset of cases, RNA sequencing was performed, and prior *ALK* test results and clinical treatment information were collected from treating physicians.

**Results:** We queried the Foundation Medicine NSCLC database and identified *ALK* internal inversions, as well as internal deletions, as the sole *ALK* rearrangements in 6 (0.02%) and 3 (0.01%) of cases, respectively. In cases with *ALK* internal inversions, RNA testing identified an *EML4-ALK* fusion in 2/2 cases evaluated, and 3/3 patients treated with *ALK* inhibitors had durable responses. A single patient with an *ALK* internal deletion and clinical data available responded to multiple *ALK* inhibitors. RNA data available for a subset of non-NSCLC cases suggest that *ALK* internal deletions removing a portion of the N-terminus are drivers themselves and do not result in *ALK* fusions. Fluorescence in situ hybridization (FISH) results were inconsistent for both classes of DNA events.

**Conclusion:** Rare internal inversions of *ALK* appear to be indicative of *ALK* fusions, which can be detected in RNA, and response to *ALK* inhibitors in patients with NSCLC. In contrast, *ALK* internal deletions are not associated with *ALK* fusions in RNA but likely represent targetable drivers themselves. These data suggest that CGP of DNA should be supplemented with immunohistochemistry or RNA-based testing to further resolve these events and match patients to effective therapies.

**Keywords:** *ALK* rearrangement, inversion, deletion, genomic profiling, targeted therapy

## Introduction

*ALK* gene fusions are known oncogenic drivers in non-small-cell lung cancer (NSCLC) and other tumor types, and are targetable with multiple FDA-approved *ALK* tyrosine kinase inhibitors (TKIs).<sup>1</sup> *ALK* rearrangements, identified using fluorescence in situ hybridization (FISH), immunohistochemistry (IHC) or next-generation sequencing (NGS), typically result in the *ALK* kinase domain fused to a 5' dimerization partner. Patients with NSCLC positive for these alterations have excellent response rates to *ALK* TKIs.<sup>2-4</sup> The various accepted methods for

detection of *ALK* rearrangements are generally concordant; however, previous studies have shown that cases negative by *ALK* FISH can be positive using NGS, particularly cases with complex DNA events, and that these patients respond to *ALK* TKIs.<sup>5,6</sup> Given the efficacy of *ALK* TKIs as a class, deep understanding and exploration of these more complex *ALK* variants is warranted.

While the majority of *ALK* rearrangements detected using NGS are fusions with an identified 5' partner, in a subset of cases DNA rearrangements are detected without evidence of a gene fusion. Case reports of NSCLCs with *ALK* rearrangements but no fusion partner detected in DNA have demonstrated *ALK* fusions in RNA and responses to *ALK* TKIs; however the literature remains relatively scant.<sup>7–9</sup> In a subset of cases, the N-terminal domain of *ALK* is predicted to be separated from the kinase domain through rearrangement or alternative transcription, resulting in activation in the absence of a gene fusion.<sup>10,11</sup> In this report we present multiple patients whose tumors harbor novel rearrangements where both detected breakpoints occur within the *ALK* gene, and who experienced durable responses to *ALK* TKIs.

## Methods

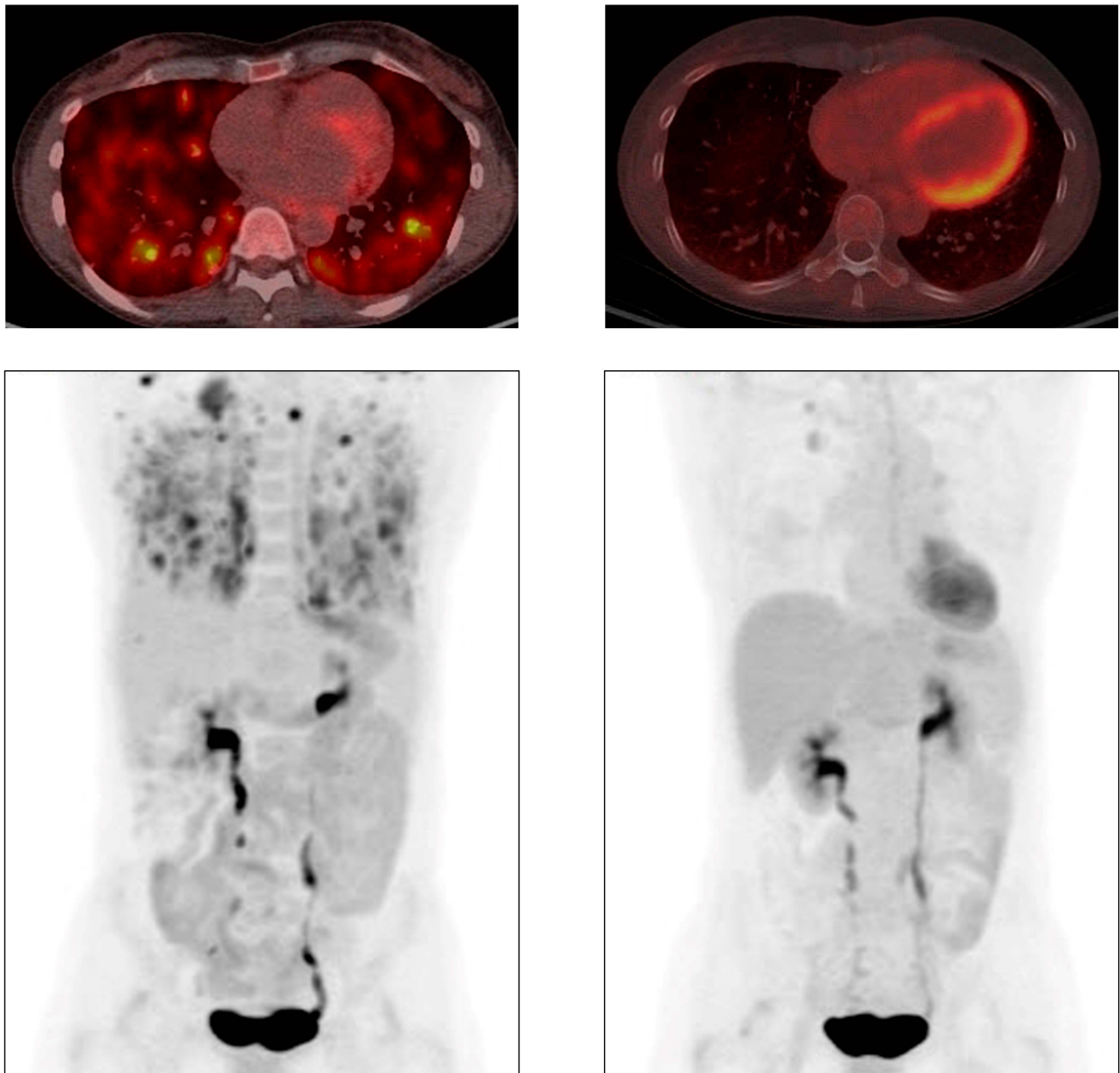
Hybrid-capture based comprehensive genomic profiling (CGP; FoundationOneCDx) was performed prospectively for 39,159 NSCLC patients on formalin-fixed paraffin-embedded (FFPE) tumor tissue or circulating tumor DNA (ctDNA) submitted during routine clinical care in a Clinical Laboratory Improvement Amendments-certified, College of American Pathologists-accredited, New York State-regulated reference laboratory (Foundation Medicine Inc., Cambridge, MA). DNA (>50ng) was extracted from FFPE NSCLC specimens; NGS was performed on hybridization-captured, adaptor ligation-based libraries to high, uniform coverage (>500x) for all coding exons of 236–405 cancer-related genes plus selected introns.<sup>12</sup> Additionally, since May 2016, hybrid-capture based NGS was performed on ctDNA.<sup>13</sup> Two 10-mL aliquots of peripheral whole blood were collected, a double-spin protocol was used to isolate plasma, and 50–100ng of ctDNA was extracted to create adapted sequencing libraries before hybrid-capture and sample-multiplexed sequencing of 62–70 genes plus selected introns to >5000x unique coverage. All *ALK* exons were baited; dedicated intron baiting was included for *ALK* introns 18 and 19 in ctDNA and intron 19 in tissue. DNA and RNA CGP (FoundationOneHeme) was performed on selected samples where indicated as assay previously described.<sup>14</sup>

Approval for this study, including a waiver of informed consent and a Health Insurance Portability and Accountability Act waiver of authorization, was obtained from the Western Institutional Review Board (protocol no. 20152817).

## Results

The index patient is a 50-year-old female never smoker diagnosed with stage III lung adenocarcinoma in 2015. *ALK* FISH testing, as well as *ROS1* FISH and *EGFR* mutation testing, was negative. She received carboplatin/pemetrexed/bevacizumab followed by nivolumab and discontinued both due to toxicity. The treating physician then ordered CGP of a right lung core biopsy which showed an *ALK* rearrangement (intron 17/19 breakpoints) predicted to result in an internal inversion. No alterations in other known drivers were detected. Subsequent *ALK* IHC testing was positive and the patient began treatment with crizotinib. Due to intolerance, after less than 2 months she was switched to alectinib with excellent partial response (PR) lasting 26 months (Figure 1). At progression on alectinib no resistance alterations within *ALK* were identified, although an inactivating *STK11* alteration was acquired, and the patient was recently switched to lorlatinib.

To assess the frequency and diversity of this class of *ALK* rearrangements we queried the Foundation Medicine database of 33,601 tissue and 4679 ctDNA samples from 39,159 NSCLC patients, which were submitted for CGP during clinical care (July 2015 - January 2019). DNA rearrangements with both breakpoints within *ALK* predicted to result in inversion of a portion of the N-terminus leaving the kinase domain (exons 20–29) intact were found in 25 cases (0.06%; 24 tissue and 1 ctDNA sample). In most cases (76%, 19/25), the inversion co-occurred with another *ALK* rearrangement, typically an *EML4-ALK* fusion, but in 6 cases the inversion was the only *ALK* alteration identified in DNA. All 6 cases were lung adenocarcinomas, 5/6 patients were female, and the median patient age was 60.5 years (range 23–82) (Table 1). There were no other known driver alterations in 5/6 cases; the sixth case, which was known to be treatment naïve, had a co-occurring *EGFR* L858R mutation (mutant allele frequency 30%). The 5' *ALK* breakpoint was in introns 8–17 and the 3' *ALK* breakpoint was in intron 18 (n=1) or intron 19 (n=5). Two cases were evaluated for *ALK* rearrangements in RNA and in both harbored an *EML4-ALK* RNA fusion.



**Figure 1** Response to alectinib in index case with *ALK* internal inversion. PET-CT scans just prior to initiation of alectinib (left) PET-CT scans after 3 months of treatment with alectinib (right).

Two additional patients with *ALK* internal inversions in DNA had clinical follow up data available. Case 2 is that of a 23-year-old male never-smoker diagnosed with stage IV lung adenocarcinoma in 2018. He had a right frontal lobe brain lesion resection, consistent with metastatic adenocarcinoma. CGP was ordered on a left lung biopsy, which showed an *ALK* rearrangement (intron 8/19 break-points) predicted to result in an internal inversion. *ALK* FISH testing on the lung biopsy was positive. Follow up DNA and RNA CGP on the resected brain tissue were performed showing the same *ALK* internal inversion in

DNA but an *EML4-ALK* fusion in RNA. The patient began treatment with alectinib and underwent stereotactic radiosurgery (SRS) to his brain lesion approximately 1 month later. The main mass in his left lung mass measured 7.2x2.5cm at diagnosis and decreased to 3.7x2.5cm at 5 weeks and 2.7x1.5cm at 14 weeks after initiation of alectinib and no other metastatic sites outside the brain were identified. A brain MRI 3.5 months after treatment initiation showed a new 11mm lesion and SRS was repeated. He remains on alectinib for 7 months with an ongoing response in the lung.

**Table 1** Clinical and Genomic Characteristics of NSCLC Cases with *ALK* Internal Rearrangements

	ALK Rearrangements in NSCLC Detected by CGP of DNA			
	ALK Internal Inversion Alone	ALK Internal Inversion + Co-Occurring ALK Rearrangement/Fusion	ALK Internal Deletion Alone	ALK Internal Deletion + Co-Occurring ALK Rearrangement/Fusion
# cases	6 (6 tissue, 0 ctDNA)	19 (18 tissue, 1 ctDNA)	3 (3 tissue, 0 ctDNA)	5 (3 tissue, 2 ctDNA)
Median age, years (range)	60.5 (23–82)	63 (49–83)	55 (33–66)	55 (38–58)
Gender M:F	1:5	7:12	2:1	2:3
ALK breakpoints	introns 8/19 (n=2) introns 11/18 introns 15/19 (n=2) introns 17/19	introns 1/19 (n=7) introns 3/19 (n=2) introns 4/19 (n=2) introns 8/19 introns 11/18 (n=2) introns 11/19 introns 12/17 introns 14/19 introns 15/19 introns 17/18	introns 1/18 introns 3/19 introns 12/19	introns 1/19 introns 3/19 introns 5/19 (n=3)
Co-occurring ALK rearrangement/fusion	N/A	EML4-ALK fusion (n=15) CLTC-ALK fusion CLIP4-ALK fusion ALK intron 19/MPV17 rearrangement ALK intron 19/intragenic space rearrangement	N/A	EML4-ALK fusion ALK-EML4 reciprocal only TYW1B-ALK fusion ALK intron 19/HDAC8 ALK intron 19/intragenic space rearrangement
# with other drivers present	1 (EGFR L858R)	1 (MET amplification)	0	0
ALK FISH/IHC status	ALK+ FISH <sup>a</sup> ALK+ IHC <sup>b</sup> ALK FISH negative (n=2) <sup>c, d</sup> Not performed or unknown (n=2)	NE	ALK FISH negative <sup>a</sup> ALK+ FISH <sup>e</sup> Not performed or unknown	NE
ALK rearrangement status on RNA	EML4-ALK (n=2) Not performed or unknown (n=4)	NE	NE*	NE

**Notes:** a: FISH testing performed by NeoGenomics; b: IHC testing performed by Genepath, clone ALKO1; c: FISH testing performed by Genepath; d: FISH testing performed by Integrated Oncology; e: FISH testing performed by Response Genetics. \*For 3/3 non-NSCLC cases with *ALK* internal deletions in DNA RNA testing showed only an *ALK* deletion and did not detect the presence of an *ALK* fusion.

**Abbreviations:** N/A: not applicable, NE: not evaluated for this study.

Case 3 is that of a 78-year-old female never-smoker diagnosed with stage IV lung adenocarcinoma in 2018. CGP was performed on a cell pellet from pleural fluid collected at diagnosis, which detected an *ALK* rearrangement (intron 15/19 breakpoints) predicted to result in an internal inversion. The patient received chemotherapy and immunotherapy for approximately 2 months with some intolerance and no evidence of response, before beginning alectinib. Subsequent *ALK* FISH testing was negative and alectinib was interrupted for approximately 2 weeks. DNA and RNA CGP were performed on the original pleural

fluid cell pellet and showed the same *ALK* internal inversion in DNA but an *EML4-ALK* fusion in RNA. Alectinib was resumed and the patient remains on therapy for 12 months with a complete response.

We also identified 8 NSCLC cases (0.02%) with DNA rearrangements with both breakpoints within the *ALK* gene predicted to result in deletion of a portion of the N-terminal region (Table 1). In 3/8 cases, no co-occurring *ALK* rearrangement or other drivers were detected. Clinical follow up data was available for 1 of these patients. Case 4 is that of a 66-year old female who

was diagnosed with Stage IIIA lung adenocarcinoma in 2016. She initially underwent tri-modality therapy including cisplatin/etoposide plus radiation therapy followed by R middle and lower lobectomy with lymph node dissection. As both the 4R node and primary tumor were *ALK* positive by FISH, she was started on crizotinib for residual unresectable disease. Treatment was discontinued after 3 months due to toxicity and imaging demonstrated no evidence of disease. She was subsequently found to have liver lesions 1 year later and CGP of a liver metastasis detected an *ALK* rearrangement (intron 12/19 breakpoints) predicted to result in an internal deletion. She was restarted on crizotinib with a PR and remained on treatment for 16 months until progression of liver lesions. She was switched to brigatinib but discontinued due to pneumonitis and subsequently began treatment with alectinib, ongoing for 10 months with a PR.

## Discussion

Following a dramatic prolonged response to alectinib in a patient with NSCLC harboring a previously uncharacterized *ALK* rearrangement, we queried a large genomic database of over 39,000 NSCLCs and found that *ALK* internal inversion rearrangements are rare (<0.1%) but recurrent events, sometimes difficult to detect using FISH but likely clinically actionable. These inversions involve a subset of exons 1–19 and typically include classic intron 19 breakpoints. They are often detected with other co-occurring *ALK* rearrangements but can occur as the sole *ALK* DNA event. FISH testing was available for 3/6 such cases and was positive in 1 instance (intron 8/19 breakpoints) but negative in the other 2 (intron 15/19 and 17/19 breakpoints), suggesting that detection by FISH may depend on the size of a given inversion. Importantly, subsequent analyses revealed that in 2/2 cases with only an *ALK* internal inversion in DNA, RNA testing detected a classic *EML4-ALK* fusion. *ALK* internal inversions as the sole *ALK* rearrangement were also detected in 5 additional cases in the Foundation Medicine database of ~170,000 non-NSCLC tumor samples; however, none of these cases had a canonical intron 19 breakpoints or RNA data available, so the functional status of these events is unclear.

A plausible biological explanation for our observation that 2/2 cases with *ALK* DNA internal inversions harbor RNA-only *ALK* fusions is that these inversions are not driver alterations per se but are indicators of more extensive rearrangement events affecting the *ALK* locus. Because typical commercial NGS sequencing technologies

use short sequencing reads to obtain raw sequencing data, which is then computationally assembled and mapped to the reference genome, the full extent of a complex DNA rearrangement can be difficult to capture. Thus, DNA rearrangements might sometimes appear as partner-less events or events of unclear biological significance, such as *ALK* internal inversions, while RNA sequencing of these cases reveals in-frame fusions. This phenomenon has been reported previously using other NGS platforms, suggesting a general limitation of the technology.<sup>15,16</sup>

An important implication of this finding is that for cases where NGS DNA sequencing uncovers rearrangements of unclear significance in known oncogenes, orthogonal testing, such as with RNA or protein-based assays should be considered to ascertain whether the detected rearrangements are incompletely-captured oncogenic fusions or likely non-productive events.

In the case of the index patient, she responded to alectinib for 26 months, and at progression CGP of ctDNA showed the initial *ALK* intron 17/19 deletion and an *ALK* rearrangement with an intron 18 breakpoint, which was unlikely to have been detected initially because the tissue CGP assay utilized initially lacks dedicated intron 18 baiting. Without RNA evidence for this case it is not possible to assess directly, but given the excellent clinical response, we speculate that an *ALK* fusion would likely be detected in RNA. No *ALK* resistance mutations were detected at progression on alectinib; however, an acquired *STK11* inactivating truncation was identified. *STK11* alterations have been identified as resistance mechanisms to immune checkpoint inhibitors in NSCLC,<sup>17</sup> but have not been described as acquired alterations driving resistance to *ALK* TKIs. However, in this case it's conceivable that the *STK11* alteration could be modulating the host anti-tumor response.

We also identified rare *ALK* N-terminal deletions and similar events have resulted in *ALK* activation in preclinical models.<sup>10,11</sup> In 3/8 cases the deletion was the sole *ALK* rearrangement in DNA, and FISH testing available for 2/3 cases and was negative in 1 case (intron 3/19 breakpoints) and positive in the other (intron 12/19 breakpoints). Although no RNA data was available for any of the 5 NSCLC cases with *ALK* deletions, we also identified *ALK* internal deletions in 11 cases in the Foundation Medicine database of ~170,000 non-NSCLC tumor samples. In 3/3 of these cases with RNA data available (rhabdomyosarcoma with deletion of exons 2–17, unknown primary malignant neoplasm with deletion exons 3–18 and undifferentiated sarcoma with deletion of exons

2–16) the DNA-identified *ALK* internal deletion was confirmed in RNA, but none of these cases had an *ALK* fusion detected in RNA. Our report herein of a patient with NSCLC positive for an *ALK* internal deletion who responded to crizotinib, and then alectinib, provides preliminary validation of preclinical data showing that *ALK* deletions within the extracellular domain are activating and suggests that such deletions may define a novel class of clinically targetable driver alterations in NSCLC.

Overall this work provides preliminary clinical evidence for targetability of 2 distinct rare rearrangement classes that are detected as variants affecting the N-terminus of *ALK*. Although these events are uncommon, it's possible that incomplete intron baiting leads to an underrepresentation in overall frequency. Limitations of this study include lack of clinical treatment data for a significant subset of patients, as well as incomplete FISH, IHC, and RNA sequencing data. However, available data suggest that *ALK* internal inversions detected in DNA correlate with the identification of *ALK* fusions in RNA (2/2 cases). Therefore, these events may be indicative of more extensive *ALK* rearrangements, and 100% (3/3) of patients with these events responded to ALK TKIs. Internal deletions in contrast do not appear to result in gene fusions (3/3 non-NSCLC cases with available RNA data were negative for *ALK* fusion) but do appear to be driver events with sensitivity to ALK TKIs. FISH results were mixed for both classes of rearrangements. This work suggests that CGP to identify these alterations, as well as supplemental RNA or IHC testing, is warranted to allow these patients to be matched to highly effective approved targeted therapies or enroll in clinical trials.

## Consent for Publication

We confirm written informed consent for the case details to be published has been obtained for all patients described in this study.

## Disclosure

ABS, RM, MR, JA, RLE, VAM, BA, JV, and KM are employees at Foundation Medicine, Inc., a wholly-owned subsidiary of Roche, and have Roche stock ownership. SMA was an employee at Foundation Medicine, Inc., at the time the study was conducted. JWR reports personal fees from Takeda, Celgene, and Abbvie; advisory board for Boehringer Ingelheim, Loxo Oncology, Spectrum Pharmaceuticals; grants from Merck, and grants provided to institution from Novartis and AstraZeneca, outside the submitted work. VAM is stockholder for Revolution Medicines and Mirati Therapeutics, outside the submitted

work. In addition, he has a patent USPO85014313 issued to Sloan Kettering Institute for Cancer Research. The authors report no other conflicts of interest in this work.

## References

- Hallberg B, Palmer RH. Mechanistic insight into ALK receptor tyrosine kinase in human cancer biology. *Nat Rev Cancer*. 2013;13(10):685–700. doi:10.1038/nrc3580
- Peters S, Camidge DR, Shaw AT, et al. Alectinib versus crizotinib in untreated ALK-positive non-small-cell lung cancer. *N Engl J Med*. 2017;377(9):829–838. doi:10.1056/NEJMoa1704795
- Solomon BJ, Besse B, Bauer TM, et al. Lorlatinib in patients with ALK-positive non-small-cell lung cancer: results from a global Phase 2 study. *Lancet Oncol*. 2018;19(12):1654–1667. doi:10.1016/S1470-2045(18)30649-1
- Camidge DR, Kim HR, Ahn M-J, et al. Brigatinib versus crizotinib in ALK-positive non-small-cell lung cancer. *N Engl J Med*. 2018;379(21):2027–2039. doi:10.1056/NEJMoa1810171
- Ali SM, Hensing T, Schrock AB, et al. Comprehensive genomic profiling identifies a subset of crizotinib-responsive alk-rearranged non-small cell lung cancer not detected by fluorescence in situ hybridization. *Oncologist*. 2016;21(6):762–770. doi:10.1634/theoncologist.2015-0497
- Li W, Zhang J, Guo L, Chuai S, Shan L, Ying J. Combinational analysis of FISH and immunohistochemistry reveals rare genomic events in ALK fusion patterns in NSCLC that responds to crizotinib treatment. *J Thorac Oncol*. 2017;12(1):94–101. doi:10.1016/j.jtho.2016.08.145
- Peled N, Palmer G, Hirsch FR, et al. Next-generation sequencing identifies and immunohistochemistry confirms a novel crizotinib-sensitive ALK rearrangement in a patient with metastatic non-small-cell lung cancer. *J Thorac Oncol*. 2012;7(9):e14–e16. doi:10.1097/JTO.0b013e3182614ab5
- Zhao R, Zhang J, Han Y, et al. Clinicopathological features of ALK expression in 9889 cases of non-small-cell lung cancer and genomic rearrangements identified by capture-based next-generation sequencing: a chinese retrospective analysis. *Mol Diagn Ther*. 2019;23(3):395–405. doi:10.1007/s40291-019-00389-y
- Ou S-HI, Lee TK, Young L, et al. Dual occurrence of ALK G1202R solvent front mutation and small cell lung cancer transformation as resistance mechanisms to second generation ALK inhibitors without prior exposure to crizotinib. Pitfall of solely relying on liquid re-biopsy? *Lung Cancer Amst Neth*. 2017;106:110–114. doi:10.1016/j.lungcan.2017.02.005
- Wiesner T, Lee W, Obenauf AC, et al. Alternative transcription initiation leads to expression of a novel ALK isoform in cancer. *Nature*. 2015;526(7573):453–457. doi:10.1038/nature15258
- Cazes A, Louis-Brennetot C, Mazot P, et al. Characterization of rearrangements involving the ALK gene reveals a novel truncated form associated with tumor aggressiveness in neuroblastoma. *Cancer Res*. 2013;73(1):195–204. doi:10.1158/0008-5472.CAN-12-1242
- Frampton GM, Fichtenholtz A, Otto GA, et al. Development and validation of a clinical cancer genomic profiling test based on massively parallel DNA sequencing. *Nat Biotechnol*. 2013;31(11):1023–1031. doi:10.1038/nbt.2696
- Clark TA, Chung JH, Kennedy M, et al. Analytical validation of a hybrid capture-based next-generation sequencing clinical assay for genomic profiling of cell-free circulating tumor DNA. *J Mol Diagn*. 2018;20(5):686–702. doi:10.1016/j.jmoldx.2018.05.004
- He J, Abdel-Wahab O, Nahas MK, et al. Integrated genomic DNA/RNA profiling of hematologic malignancies in the clinical setting. *Blood*. 2016;127(24):3004–3014. doi:10.1182/blood-2015-08-664649
- Benayed R, Offin M, Mullaney K, et al. High yield of RNA sequencing for targetable kinase fusions in lung adenocarcinomas with no mitogenic driver alteration detected by DNA sequencing and low tumor mutation burden. *Clin Cancer Res*. 2019;25(15):4712–4722. doi:10.1158/1078-0432.CCR-19-0225

16. Davies KD, Le AT, Sheren J, et al. Comparison of molecular testing modalities for detection of ROS1 rearrangements in a cohort of positive patient samples. *J Thorac Oncol.* 2018;13(10):1474–1482. doi:10.1016/j.jtho.2018.05.041
17. Skoulidis F, Goldberg ME, Greenawalt DM, et al. STK11/LKB1 mutations and PD-1 inhibitor resistance in KRAS-mutant lung adenocarcinoma. *Cancer Discov.* 2018;8(7):822–835. doi:10.1158/2159-8290.CD-18-0099

### Lung Cancer: Targets and Therapy

Dovepress

#### Publish your work in this journal

Lung Cancer: Targets and Therapy is an international, peer-reviewed, open access journal focusing on lung cancer research, identification of therapeutic targets and the optimal use of preventative and integrated treatment interventions to achieve improved outcomes, enhanced survival and quality of life for the cancer patient. Specific topics covered in the journal include: Epidemiology,

detection and screening; Cellular research and biomarkers; Identification of biotargets and agents with novel mechanisms of action; Optimal clinical use of existing anticancer agents, including combination therapies; Radiation and surgery; Palliative care; Patient adherence, quality of life, satisfaction; Health economic evaluations.

Submit your manuscript here: <http://www.dovepress.com/lung-cancer-targets-therapy-journal>