

COVID-19 Transmission Within a Family Cluster by Presymptomatic Carriers in China

Guoqing Qian,^{1,a} Naibin Yang,^{1,a} Ada Hoi Yan Ma,² Liping Wang,¹ Guoxiang Li,¹ Xueqin Chen,³ and Xiaomin Chen¹

¹Department of Internal General Medicine, Ningbo First Hospital, Ningbo, Zhejiang Province, China, ²Nottingham University Business School, University of Nottingham Ningbo China, Ningbo, Zhejiang Province, China, and ³Department of Chinese Traditional Medicine, Ningbo First Hospital, Ningbo, Zhejiang Province, China

We report a family cluster of coronavirus disease 2019 (COVID-19) caused by a presymptomatic case. There were 9 family members, including 8 laboratory-confirmed with COVID-19, and a 6-year-old child had no evidence of infection. Among the 8 patients, 1 adult and a 13-month-old infant were asymptomatic, and 1 adult was diagnosed as having severe pneumonia.

Keywords. COVID-19; family cluster; presymptomatic carriers.

Since the novel severe acute respiratory syndrome coronavirus 2 (SARS-CoV-2) was identified in early December 2019, the number of cases has been rapidly increasing [1]. Chan and colleagues reported SARS-CoV-2 in a family setting with person-to-person transmission [2]. We are here reporting a family cluster of coronavirus disease 2019 (COVID-19) transmission and clinical features in Zhejiang, China, after a visit to a temple.

On 19 January, a couple participated in a temple activity to celebrate the Chinese Spring Festival. The 58-year-old woman (index 1) fell ill with fever, fatigue, and headache on 24 January. However, the 60-year-old man (index 2) was without any symptoms.

In between the temple visit and the onset of symptoms, the couple's daughter, son-in-law, and 2 grandchildren (cases 1–4) had visited and stayed with them from 20 to 23 January. Index 1 went to hospital on 26 January, and was diagnosed with COVID-19 on 29 January by reverse-transcription polymerase chain reaction (RT-PCR).

Index 2 and cases 1–4 were all admitted to hospital as persons under investigation on the day index 1's diagnosis was confirmed. The daughter (case 1) presented with fever and cough on 27 January, and was diagnosed with COVID-19 after being tested positive by RT-PCR using throat swab specimen.

On 1 February, index 2 tested positive via throat swab RT-PCR but stayed asymptomatic. Case 1's husband (case 2) started to suffer fever and was laboratory-diagnosed on the same day. The 6-year-old daughter (case 3) showed no symptoms and tested negative 3 times for throat swab and negative once for rectal swab by RT-PCR, and remained clear in chest computed tomographic scans. She was the only family member who was uninfected by SARS-CoV-2. The 13-month-old daughter (case 4) was asymptomatic but was laboratory-confirmed on 5 February.

On 23 January 23, before index 1 showed any symptoms, cases 1–4 had dinner with case 2's mother (case 5), father (case 6), and grandmother (case 7). They were admitted to hospital as persons under observation on 1 February, and were laboratory-confirmed to have contracted COVID-19 on 2, 5, and 6 February, respectively. Case 6 was a 57-year-old man who was transferred to the intensive care unit (ICU) as the symptoms got worse and the level lactic acid continued to increase (Figure 1).

This series of laboratory-confirmed cases of COVID-19 was diagnosed in the Zhejiang province, which lies outside Wuhan. First, although the family members were from 3 households, they all were infected directly or indirectly from the same 2 index patients. The clinical features were diverse across patients; in particular, there were 2 asymptomatic patients and 1 patient whose symptoms were so severe that he had to be transferred to ICU. Second, this cluster demonstrated that COVID-19 is transmittable during the incubation period, as the daughter and her family caught the disease during the incubation period of index 1 and index 2. Third, patients can stay asymptomatic, such as index 2 and case 4 in this cluster. Given that Zou et al [3] found that the viral load of symptomatic and asymptomatic patients were similar, asymptomatic patients can still infect others. These "silent patients" may remain undiagnosed and be able to spread the disease to large numbers of people. Last, it appears that children may not be as susceptible to this new virus as adults and elderly persons, and they may fare better when they have contracted the virus. As reported in this family cluster, the 6-year-old child was not infected and the 13-month-old was infected but stayed asymptomatic.

In summary, there are variations across individuals in the clinical manifestations of COVID-19, indicating that we should

Received 11 March 2020; editorial decision 14 March 2020; accepted 20 March 2020; published online March 23, 2020.

^aG. Q. and N. Y. contributed equally to this work.

Correspondence: X. Chen, Department of General Internal Medicine, Ningbo First Hospital, No. 59 Liuting St, Haishu District, Ningbo, Zhejiang Province, China (chxmin@hotmail.com).

Clinical Infectious Diseases® 2020;71(15):861–2

© The Author(s) 2020. Published by Oxford University Press for the Infectious Diseases Society of America. This is an Open Access article distributed under the terms of the Creative Commons Attribution-NonCommercial-NoDerivs licence (<http://creativecommons.org/licenses/by-nc-nd/4.0/>), which permits non-commercial reproduction and distribution of the work, in any medium, provided the original work is not altered or transformed in any way, and that the work is properly cited. For commercial re-use, please contact journals.permissions@oup.com
DOI: 10.1093/cid/ciaa316

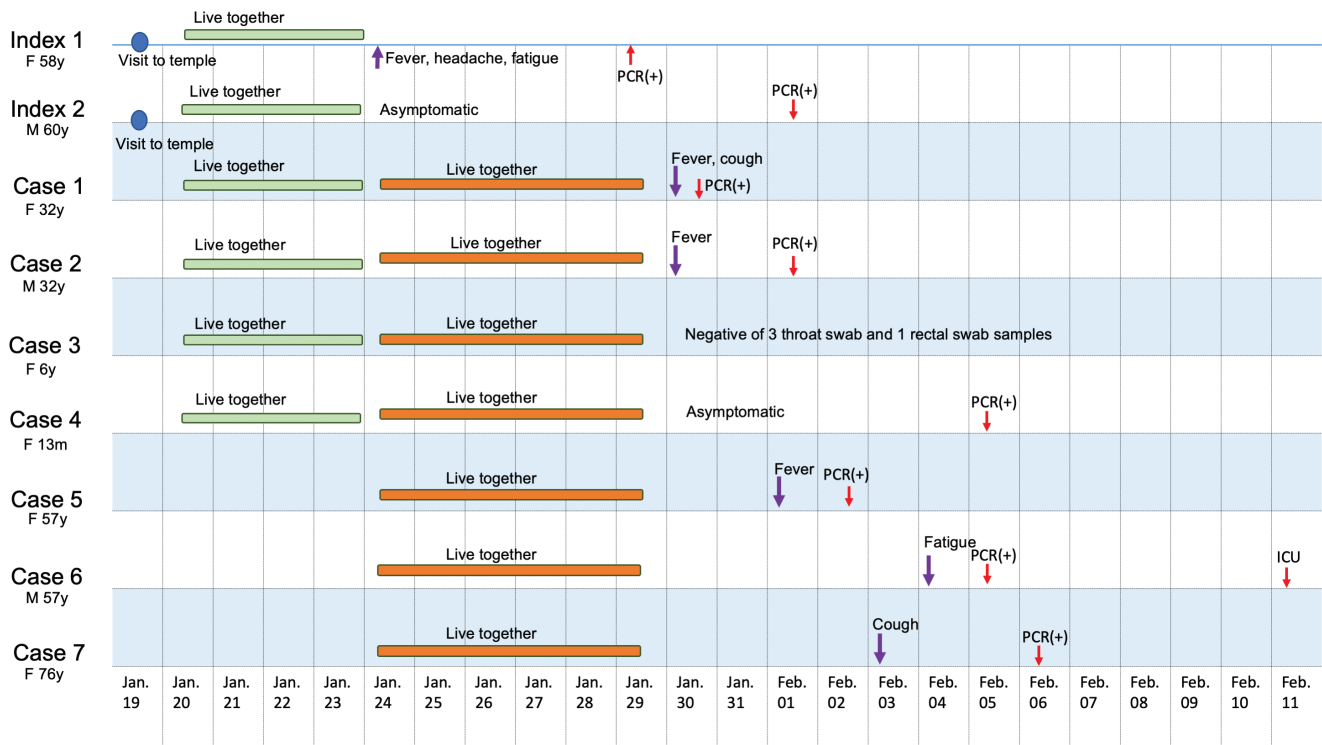


Figure 1. Timeline of exposure to index patients with coronavirus disease 2019 (COVID-19) in China. Abbreviations: F, female; ICU, intensive care unit; M, male; PCR, polymerase chain reaction.

pay attention to how to prevent people from being infected by asymptomatic patients and patients who are in the incubation period.

Notes

Author contributions. L. W. and Xue. C. collected the data. Xiao C., G. Q., and N. Y. conceived the idea. G. Q. and N. Y. drafted the manuscript. A. H. Y. M. reviewed the manuscript. All authors read and approved the final manuscript.

Acknowledgments. The study has been reviewed and approved by the Ningbo City First Hospital, Medical Ethical Committees (2020-R018).

Disclaimer. The funder had no role in study design, data collection and analysis, decision to publish, or preparation of the manuscript.

Financial support. This work was supported by the Natural Science Foundation of Zhejiang Province (grant number Q17H010001).

Potential conflicts of interest. The authors: No reported conflicts of interest. All authors have submitted the ICMJE Form for Disclosure of Potential Conflicts of Interest.

References

1. Zhu N, Zhang D, Wang W, et al. A novel coronavirus from patients with pneumonia in China, 2019. *N Engl J Med* 2020; 382:727–33.
2. Chan JF-W, Yuan S, Kok K-H, et al. A familial cluster of pneumonia associated with the 2019 novel coronavirus indicating person-to-person transmission: a study of a family cluster. *Lancet* 2020. doi:10.1016/S0140-6736(20)30154-9.
3. Zou L, Ruan F, Huang M, et al. SARS-CoV-2 viral load in upper respiratory specimens of infected patients. *New Engl J Med* 2020. doi:10.1056/NEJMc2001737.