

**Serial bedside lung ultrasonography in a critically ill COVID-19 patient**

**Running title: Lung ultrasonography findings in COVID-19 pneumonia**

Li Ji<sup>1,2\*</sup>, Chunyan Cao<sup>1,2\*</sup>, Qing Lv<sup>1,2</sup>, Yuman Li<sup>1,2#</sup>, Mingxing Xie<sup>1,2#</sup>

<sup>1</sup>Department of Ultrasound, Union Hospital, Tongji Medical College, Huazhong University of Science and Technology, Wuhan 430022, China.

<sup>2</sup>Hubei Province Key Laboratory of Molecular Imaging, Wuhan, China.

\*Dr Ji and Dr Cao contributed equally to this manuscript.

#CO-corresponding author:

Mingxing Xie, MD, Ph.D. Head of Department of Ultrasound, Union Hospital, Tongji Medical College, Huazhong University of Science and Technology, 1277# Jiefang Ave, Wuhan 430022, China.

E-mail: xiemx@hust.edu.cn, Tel: 86-27-85726430; Fax: 86-27-85726386.

Yuman Li, MD, Ph.D. Department of Ultrasound, Union Hospital, Tongji Medical College, Huazhong University of Science and Technology, 1277# Jiefang Ave, Wuhan 430022, China.

E-mail: liym@hust.edu.cn, Tel: 86-27-85726430; Fax: 86-27-85726386.

## **Learning points for clinicians**

During COVID-19 pandemic, chest CT has played a crucial role in the rapid diagnosis of this disease<sup>1</sup>.

While the increasing risk of contagiousness and moving unstable patients make chest CT a limited choice for critically ill patients with COVID-19 pneumonia. More recently, lung ultrasonography (LUS) has been identified as a sensitive and semi-quantitative tool in the assessment of pneumonia, especially in the intensive care unit. Herein we reported a case to describe serial bedside LUS findings in a critically ill COVID-19 patient.

## **Case presentation**

A 60-year-old woman living in Wuhan was admitted to a fever clinic on Feb 20, 2020, with symptoms of fever (up to 39.8°C), chills, dry cough, fatigue and dyspnea. At admission, her body temperature was 36.8°C(98.2°F), respiratory rate was 30 breaths per min, and oxygen saturation was 92% on room air and 98% under the condition of nasal ventilation. She had a medical history of hypertension and system lupus erythematosus. Laboratory tests showed an elevated erythrocyte sedimentation rate (20 mm/h) and C-reactive protein (10.23 mg/L) levels. Real-time PCR of the patient's throat swab was positive for COVID-19 nucleic acid. Chest CT showed multiple bilateral and peripheral ground-glass opacities (Fig 1A). Bedside LUS examination including all intercostal spaces was performed subsequently, which revealed multiple B-lines (B-lines total number: 88), small consolidations and pleural line thickening (Fig 1B and C). The extent of lesion on LUS was consistent with the CT findings.

After the patient received 20 days of treatment, combined with respiratory support and interferon inhalation, real-time PCR of the patient's pharyngeal swab became negative. Chest CT showed decreasing ground-glass opacities (Fig 1D). LUS demonstrated decreased B-lines (B-lines total number: 18) and the consolidation was disappeared (Fig 1E and F).

## **Discussion**

COVID-19 pneumonia is a new disease outbreak which has become a global health concern<sup>1</sup>, and this disease shares CT features of bilateral lung involvement, with lesions mainly located peripherally and subpleurally<sup>2</sup>. Therefore, bedside LUS can identify the pulmonary lesions timely and sensitively. Moreover, ultrasound is the sole imaging modality accessible to the bedside of patients for timely identification of pulmonary complications and tracking disease changes<sup>3</sup>. B-lines are hyperechoic artifacts on LUS which appear as vertical lines that arise from the pleural surface, and pulmonary consolidation is defined as an isoechoic tissue-like structure, which is caused by the loss of lung aeration<sup>3,4</sup>.

In our case, characteristic findings of this patient included multiple B-lines and thickening of the pleural line, with the presence of small consolidation. LUS findings improve rapidly in response to COVID-19 pneumonia therapy, which is consistent with chest CT features. Bedside LUS may present a useful and non-invasive method to monitor serial changes in COVID-19 pneumonia.

**Consent:** The patient's consent for the case report was obtained after well informed.

**Conflict of interest:** none declared.

## References

1. Wu F, Zhao S, Yu B, Chen YM, Wang W, Song ZG, et al. A new coronavirus associated with human respiratory disease in China. *Nature* 2020; 579: 265-269.
2. Shi H, Han X, Jiang N, Cao Y, Alwalid O, Gu J, et al. Radiological findings from 81 patients with COVID-19 pneumonia in Wuhan, China: a descriptive study. *Lancet Infect Dis* 2020; 20: 425-434.
3. Platz E, Merz AA, Jhund PS, Vazir A, Campbell R, McMurray JJ. Dynamic changes and prognostic value of pulmonary congestion by lung ultrasound in acute and chronic heart failure: a systematic review. *Eur J Heart Fail* 2017; 19:1154-1163.
4. Sezgin C, Gunalp M, Genc S, Acar N, Ustuner E, Oguz AB, et al. Diagnostic Value of Bedside Lung Ultrasonography in Pneumonia. *Ultrasound Med Biol* 2020; 46: 1189-1196.

### **Figure legends**

Figure: Chest CT and LUS findings.

A: Chest CT showed multiple bilateral and peripheral ground-glass opacities (red arrows). B and C:

Bedside LUS revealed multiple B-lines (white arrows), small consolidations (thin arrows) and pleural

line thickening. D through F: After treatment, Chest CT showed decreased ground-glass opacities and

LUS demonstrated decreased B-lines (white arrows).

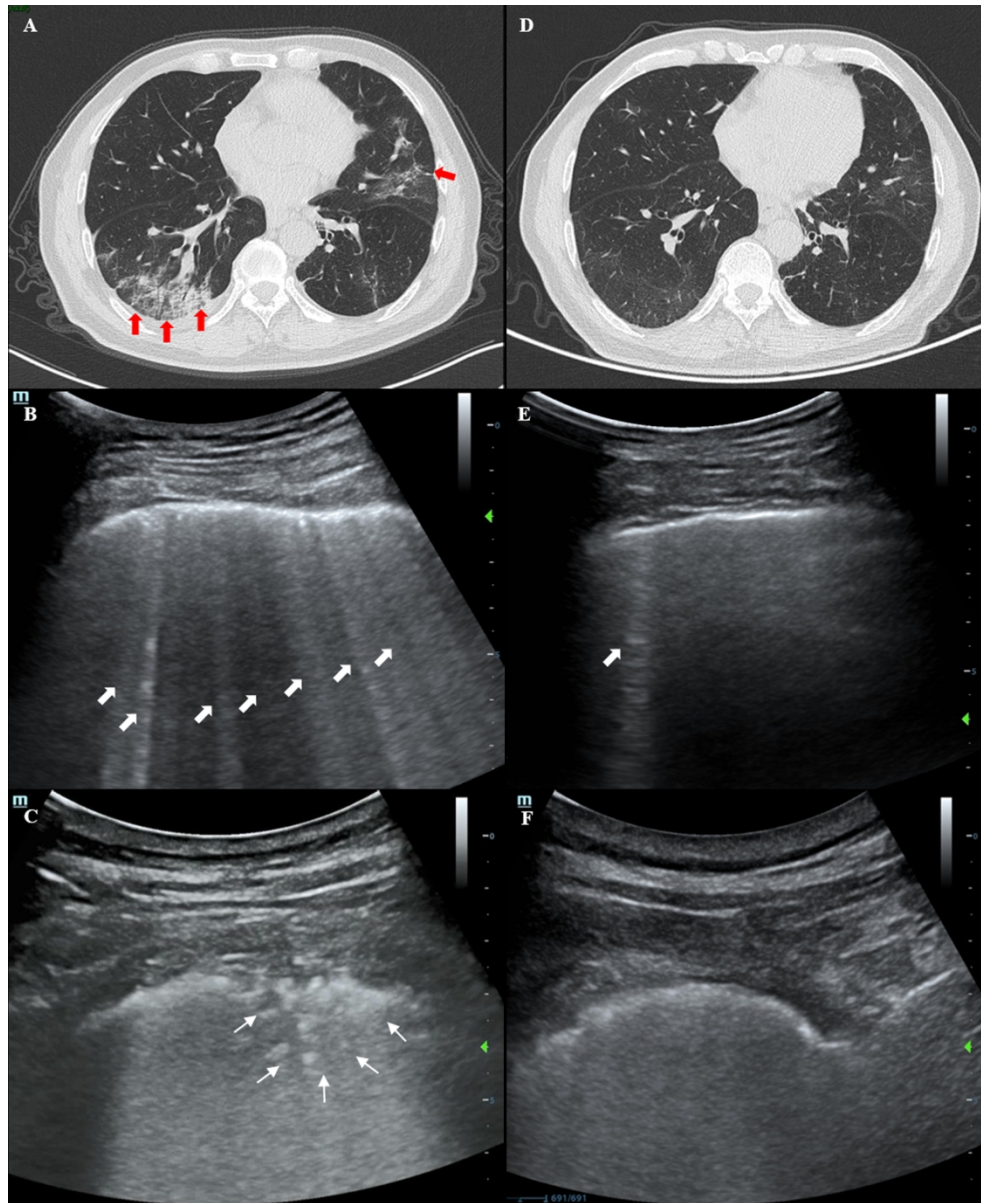


Figure: Chest CT and LUS findings.

A: Chest CT showed multiple bilateral and peripheral ground-glass opacities (red arrows). B and C: Bedside LUS revealed multiple B-lines (white arrows), small consolidations (thin arrows) and pleural line thickening. D through F: After treatment, Chest CT showed decreased ground-glass opacities and LUS demonstrated decreased B-lines (white arrows).

174x213mm (300 x 300 DPI)