

# Medial Patellofemoral Ligament Reconstruction With Growth Modulation in Children With Patellar Instability and Genu Valgum



Avi Shah, M.S., and Shital N. Parikh, M.D.

**Abstract:** Patellar instability is common in the second decade, and genu valgum is a risk factor for patellar instability. In skeletally immature patients, genu valgum can be gradually corrected using less-invasive, well-established, growth-modulation techniques. For skeletally immature patients with patellar instability and genu valgum, it would be desirable to address both instability and deformity. We describe our technique of physeal-respecting medial patellofemoral ligament reconstruction in skeletally immature patients using hamstring autograft and simultaneous transphyseal screw hemiepiphysiodesis to gradually correct genu valgum. The medial patellofemoral ligament reconstruction technique features posteromedial hamstring graft harvest, single patellar tunnel fixation without implant, and femoral attachment just below the distal femoral physis. The technique of growth modulation features percutaneous insertion of a single transphyseal screw through the distal medial femoral physis without interference with medial patellofemoral ligament graft placement. Our preliminary results have been encouraging with successful correction of genu valgum and satisfactory patellar stabilization without growth disturbances.

## Introduction (With Video Illustration)

The risk of patellar instability is greatest in the 10-17-year age group, with an incidence of approximately 43 per 100,000 children per year. Several techniques have been described to address patellar instability in skeletally immature patients.<sup>1</sup> Medial patellofemoral ligament (MPFL) reconstruction has shown promising results, but there is a 10% to 20% complication rate and an added risk for physeal injury in skeletally immature patients.<sup>2,3</sup> Thus, MPFL reconstruction in skeletally immature patients would require technical modifications to avoid these complications.

There are several risk factors that contribute to patellar instability; increased genu valgum is one such

risk factor that increases the laterally directed force and vector acting on the patella.<sup>4</sup> Correction of increased genu valgum could be achieved by growth modulation in skeletally immature patients with at least a year of remaining growth.<sup>5,6</sup> Our indications for distal femoral growth modulation are genu valgum  $>10^\circ$ , mechanical axis in or outside the lateral knee compartment, and a mechanical lateral distal femoral angle  $<84^\circ$  in a skeletally immature patient. The aim of the current report is to describe our technique of MPFL reconstruction (Video 1) and simultaneous growth modulation for correction of genu valgum in skeletally immature patients with recurrent patellar instability.

## Surgical Technique

Informed consent was obtained from all individual participants included in the study. Additional informed consent was obtained from all individual participants for whom identifying information is included in this article.

## Preoperative Planning

Knee radiographs and magnetic resonance imaging scans are evaluated for anatomic risk factors, MPFL tear pattern, and chondral injuries (Figs 1 and 2). A full-length, hip-to-ankle, standing radiograph is obtained with the patella facing forward. Deformity assessment is done to identify the source of genu valgum (Fig 3). A

From the Department of Orthopaedic Surgery (S.N.P.), Cincinnati Children's Hospital Medical Center (A.S., S.N.P.), Cincinnati, Ohio, U.S.A.

The authors report that they have no conflicts of interest in the authorship and publication of this article. Full ICMJE author disclosure forms are available for this article online, as [supplementary material](#).

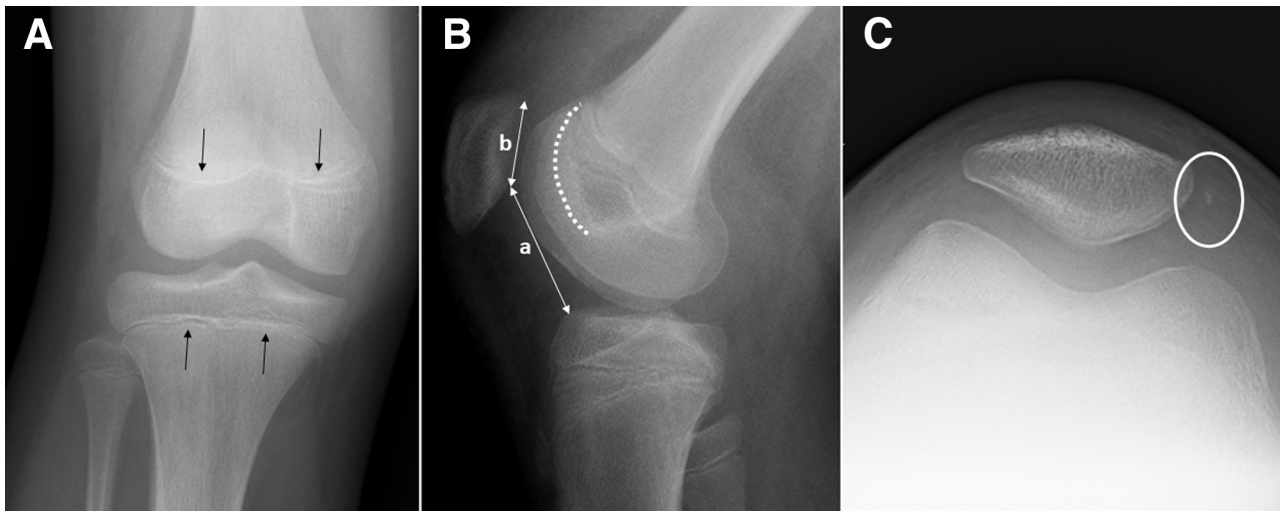
Received October 10, 2019; accepted December 17, 2019.

Address correspondence to Shital N. Parikh, M.D., Department of Orthopaedic Surgery, Cincinnati Children's Hospital Medical Center, 3333 Burnet Ave., Cincinnati, OH 45229. E-mail: [Shital.pariikh@cchmc.org](mailto:Shital.pariikh@cchmc.org)

© 2020 by the Arthroscopy Association of North America. Published by Elsevier. This is an open access article under the CC BY-NC-ND license (<http://creativecommons.org/licenses/by-nc-nd/4.0/>).

2212-6287/191255

<https://doi.org/10.1016/j.eats.2019.12.008>



**Fig 1.** Right knee radiographs including (A) anteroposterior, (B) lateral, and (C) Merchant view are obtained. The physis (black arrows) are open. Anatomic risk factors including trochlear dysplasia (white dashed line) and patellar height (a/b) are evaluated. The medial rim avulsion fracture of patella (circle) is common after patellar dislocation and does not need treatment.

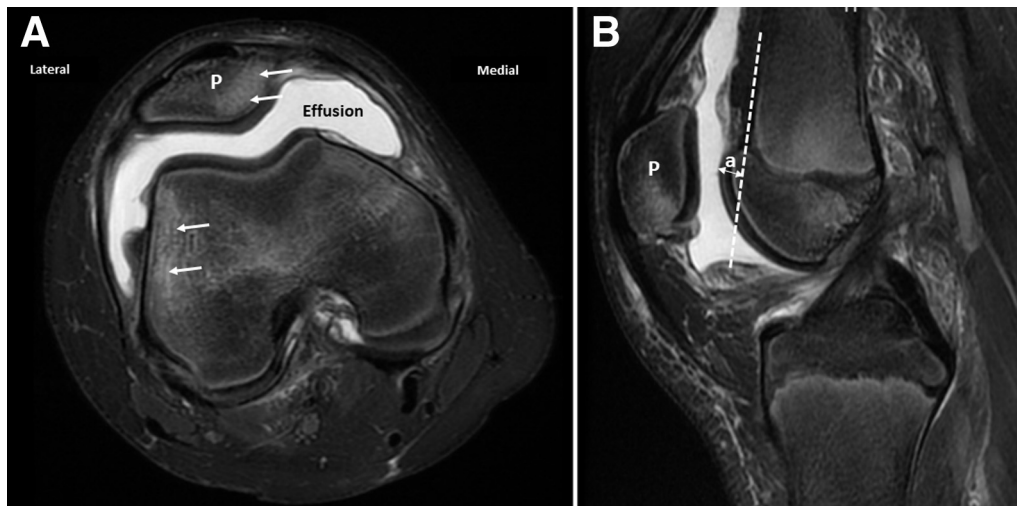
left-hand radiograph is obtained to assess skeletal age (Fig 4).

#### Patient Positioning

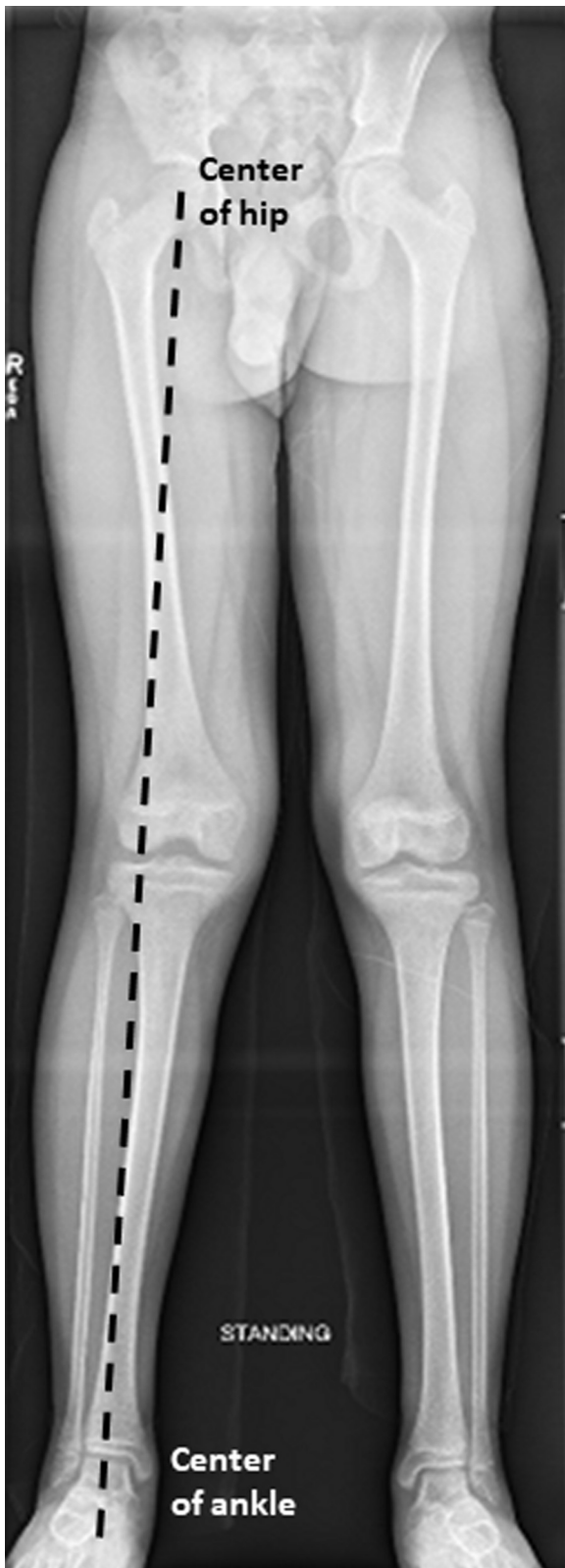The patient is positioned supine on a radiolucent table with a tourniquet over the proximal thigh. A leg elevator (Bone Foam Inc., Corcoran, MN) under the involved leg can facilitate lateral knee radiographs (Fig 5). General anesthesia and a preoperative femoral and sciatic nerve block are performed by the anesthesiologist. An examination of the knee is performed to evaluate the medial–lateral translation of the patella in extension and 30° flexion.

#### Medial Hemiepiphyseodesis

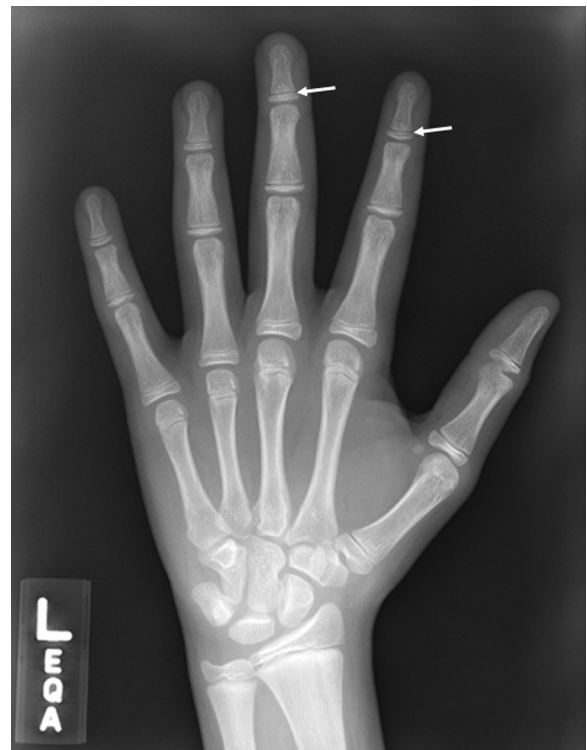
Under anteroposterior fluoroscopy, a 2.8-mm guide pin is inserted percutaneously in a retrograde direction from medial aspect of medial femoral condyle, avoiding the articular surface to intersect the distal femoral physis at its medial third–middle third junction (Figs 6 and 7, Table 1). On the lateral view, the guide pin should intersect the physis at its center and should be placed along the mid-coronal plane of the distal femur. The pin is passed to exit the lateral aspect of thigh and withdrawn from the lateral aspect of thigh until its tip is just inside the medial femoral condyle. A 1-cm longitudinal skin incision is placed around the pin and screw



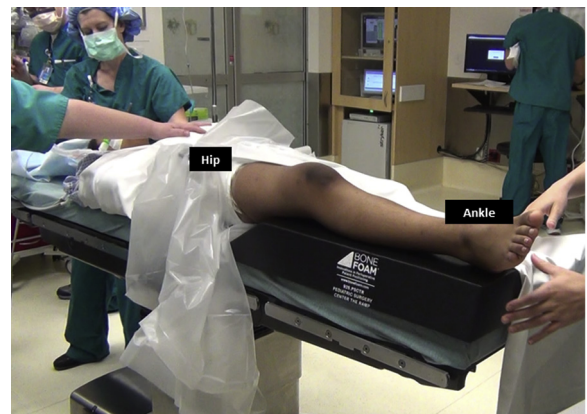**Fig 2.** Axial (A) and sagittal (B) T2-weighted magnetic resonance imaging views of the right knee show joint effusion and characteristic bruise pattern for patellar dislocation (arrows). Trochlear bump is calculated as the perpendicular distance “a” between the anterior femoral cortical line and anterior-most aspect of trochlea on mid-sagittal slice. (P, patella.)



**Fig 3.** A full-length standing radiograph shows valgus alignment of the right leg with the mechanical axis (dashed line from the center of the hip to the center of the ankle) in the lateral compartment.

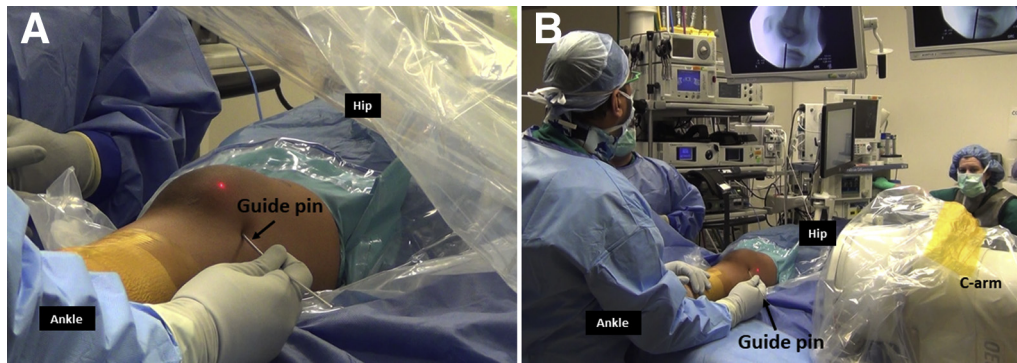


**Fig 4.** Left-hand radiograph shows open distal phalangeal physis (arrows), which indicates that the peak height velocity is not reached and patient has at least 2 years of remaining growth.

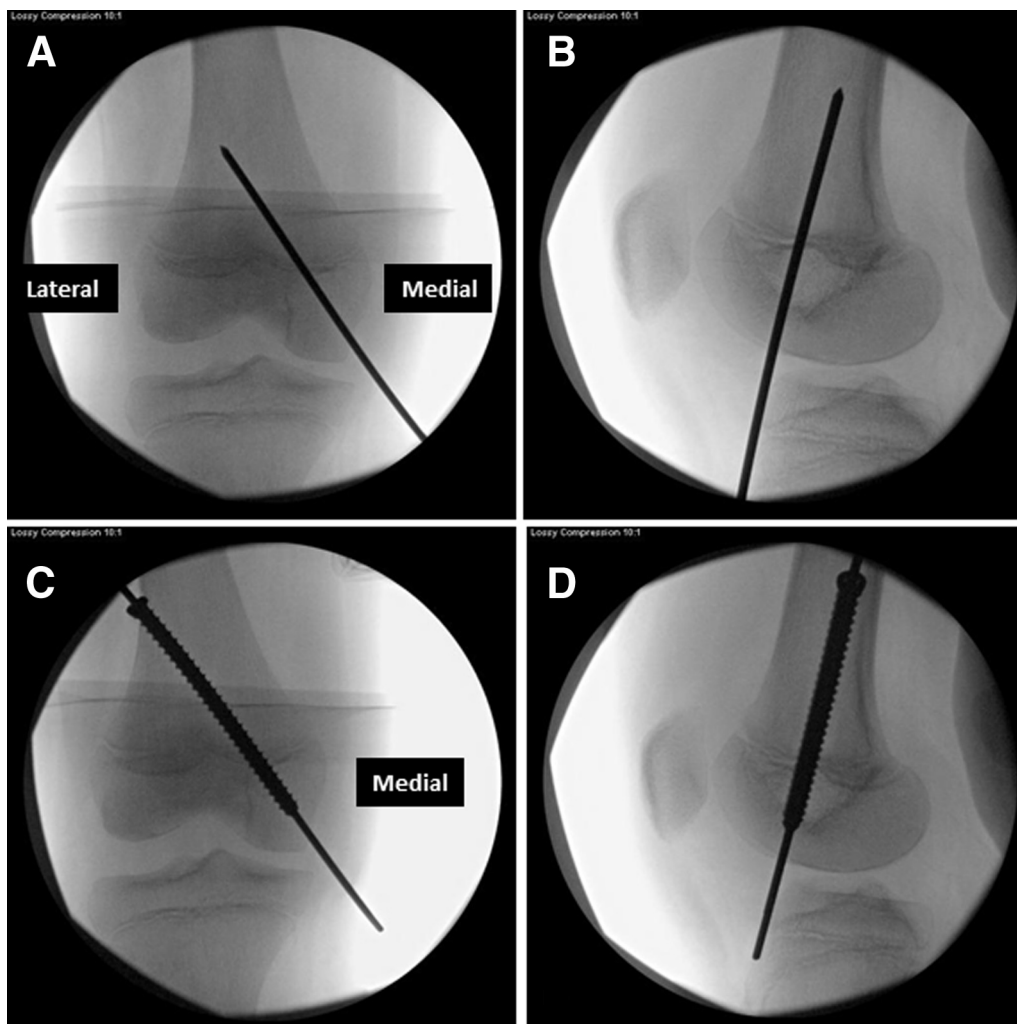


**Fig 5.** The patient is positioned supine on a radiolucent table with a well-padded tourniquet and a leg elevator under the right knee/leg to facilitate appropriate lateral radiographs.





**Fig 6.** Medial aspect of right knee. A 2.8-mm guide pin for transphyseal screw (arrow) is placed percutaneously in a retrograde direction from medial femoral condyle of the right knee. Its placement is checked on anteroposterior (A) and lateral (B) fluoroscopic images.



**Fig 7.** Fluoroscopic images of right knee. The retrograde guide pin inserted from medial femoral condyle should intersect the distal femoral physis of the knee at its medial third–middle third junction on anteroposterior (A) view and the center of the physis on the lateral (B) view. The guide pin would exit from the lateral thigh and then it is overdrilled. A 7-mm fully threaded cannulated screw is inserted over guide pin in an antegrade direction and its position is confirmed on anteroposterior (C) and lateral (D) view.

**Table 1.** Pearls and Pitfalls**Pearls**

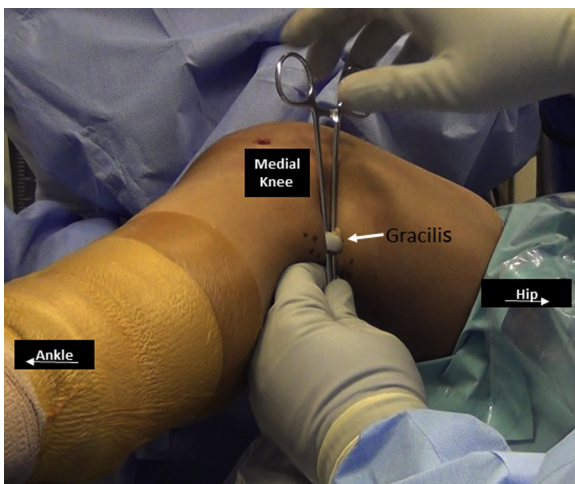
1. Flexion of the involved knee over leg support or triangle would allow for easy lateral fluoroscopic imaging.
2. Retrograde insertion of guide-pin for transphyseal screw insertion is easier and more precise than antegrade insertion as the starting point is nearer to the physis.
3. The transphyseal screw should be inserted before MPFL graft femoral attachment, so that the screw would not inadvertently damage or interfere with the MPFL graft.
4. A fully threaded screw is preferred for hemiepiphysiodesis as it would facilitate later removal if needed.
5. Gracilis autograft is the graft of choice due to its smaller diameter and hence the need for smaller (3.5 mm) patellar tunnel.
6. A posteromedial approach for graft harvest is cosmetic, easier and safer for the saphenous nerve compared with the traditional anteromedial approach.
7. Graft passage through patellar tunnels can be facilitated by trimming the graft ends or substance, chamfering the tunnels using curved curette, and by using mineral oil.
8. The guide-pin for femoral tunnel should be positioned on the distal femoral physis on the lateral view. This would correspond to the pin being distal to the physis on the anteroposterior view.
9. Once the MPFL graft is placed in the femoral tunnel, the knee is flexed and the pull-through sutures are clamped against the thigh. The knee is then extended and patellar mobility is assessed so as to avoid overextension of the MPFL graft.
10. Before final femoral fixation, an arthroscopic evaluation would help to confirm extra-articular position of the graft and to assess MPFL graft function with knee range of motion.
11. Complete insertion of the femoral interference screw is confirmed on fluoroscopic imaging.

**Pitfalls**

1. The transphyseal screw should pass through the center of the distal femoral physis on a perfect lateral view, so as to avoid any sagittal plane deformity.
2. During dissection on the medial side of patella, care should be taken to avoid joint capsule penetration. If the joint capsule is opened, it can be sutured before placement of the MPFL graft.
3. An 8- to 10-mm bone-bridge should be maintained between the patellar tunnels to prevent the graft from cutting through the tunnels.
4. The guide pin for femoral tunnel should be directed slightly anterior to avoid the intercondylar notch and slightly inferior to avoid distal femoral physis.
5. Dissection near the femoral tunnel entrance should be kept to minimum to avoid injuring the perichondral ring around the physis.
6. During percutaneous insertion of the graft in the femoral tunnel, a nitinol guidewire for interference screw should be placed in the tunnel prior to graft passage.
7. Before final femoral fixation, it should be checked that the MPFL graft has not bottomed out in the femoral tunnel or has not bunched up against femoral tunnel entrance. There should be no slack when the MPFL graft is gently pulled from the patellar side.

MPFL, medial patellofemoral ligament.

length is measured. The pin is overdrilled with a 4.5-mm drill bit, and a 7.0-mm fully-threaded, self-tapping, cannulated cancellous screw is inserted with at least 5 screw threads crossing the physis. Alternatively, a 6.5-mm cancellous screw can be used.



**Fig 8.** Posteromedial aspect of right knee. The gracilis tendon (arrow) is harvested through the posteromedial approach.

### Gracilis Tendon Harvest

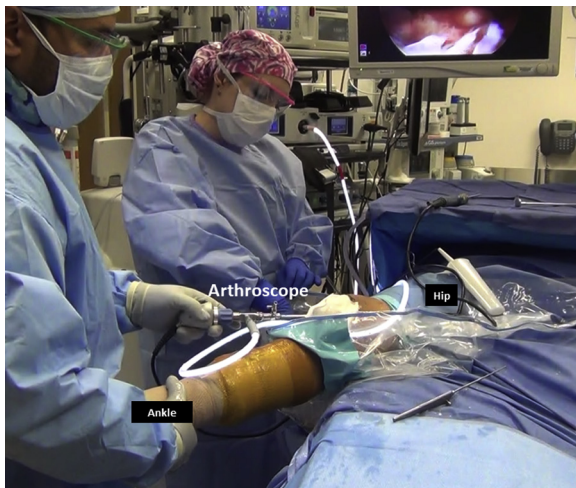With the hip in flexion and abduction and the knee in about 30° of flexion, a 2.5-cm transverse incision is placed in the medial aspect of popliteal crease over the palpable gracilis tendon. Dissection is performed toward the tendon and the fascia is opened along the tendon. A right-angle clamp is used to deliver the tendon out of the incision and it is freed of its attachments (Fig 8). An open-tendon harvester is used to detach the tendon from its tibial insertion distally and a closed-tendon harvester is used to detach the tendon proximally at its musculotendinous junction. The gracilis tendon is wrapped in a saline-soaked sponge for later use.

### Knee Arthroscopy

Diagnostic knee arthroscopy is performed using standard portals (Fig 9). Patellofemoral tracking is assessed. Any intra-articular lesions are addressed at this time. Arthroscopy from superolateral portal can provide better assessment of patellofemoral tracking.

### Patellar Tunnel

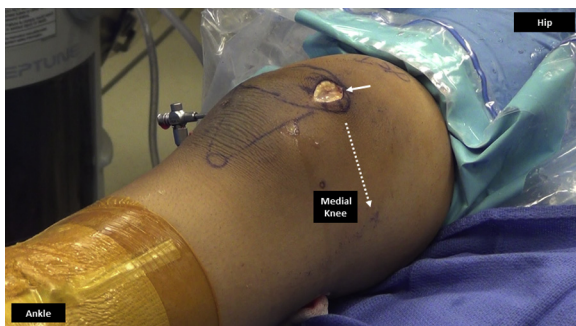
A 3- to 4-cm para-patellar incision is made along the medial border of patella and dissection is performed



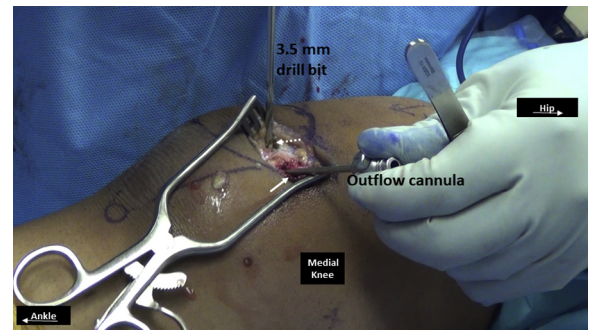
**Fig 9.** Diagnostic arthroscopy of right knee is performed with the arthroscope in the anterolateral portal. Patellofemoral tracking and chondral lesions are evaluated and treated as necessary.

down to the patella (Fig 10). The vastus medialis muscle fibers are identified (first layer). A subperiosteal dissection is performed using an electrocautery over the medial 5 mm of patella just above the widest part of patella. The plane between the medial retinaculum (second layer) and the capsule (third layer) is developed by cutting the transverse fibers of medial retinaculum.

The patellar tunnel is made just above the widest part of patella (center of superior two-thirds of patella). Two 1-cm drill holes are made using a 3.5-mm drill bit; first from medial to lateral and then from anterior to posterior to create a single 3.5-mm tunnel under a bone bridge (Fig 11). A curved curette is used to chamfer the tunnel and remove bone debris. A suture needle (0 VICRYL on OS-6 needle; Ethicon, Somerville, NJ) is passed through the tunnel and its suture end is looped to help graft passage. The thinner



**Fig 10.** Medial aspect of right knee. A 3-cm medial parapatellar incision (solid arrow) is made along the medial border of the patella and dissection is performed medially toward the medial epicondyle (dashed arrow) to create a plane between the second and third layer of the knee.

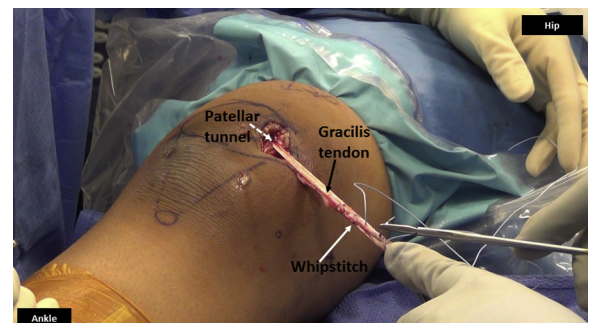


**Fig 11.** Medial side of right knee. A medial to lateral (solid arrow) and then an anterior to posterior (dashed arrow) tunnel is established using a 3.5-mm drill bit such that the tunnels converge to form a single patellar tunnel under a bone bridge. An outflow cannula or similar instrument is placed in the medial–lateral tunnel to identify its trajectory and facilitate safe anterior–posterior drilling.

musculotendinous end of the gracilis tendon is passed and pulled through the patellar tunnel. Both tendon ends are whip stitched with a #2 FiberWire suture (Arthrex, Naples, FL) (Fig 12). The doubled graft is sized using a graft sizer.

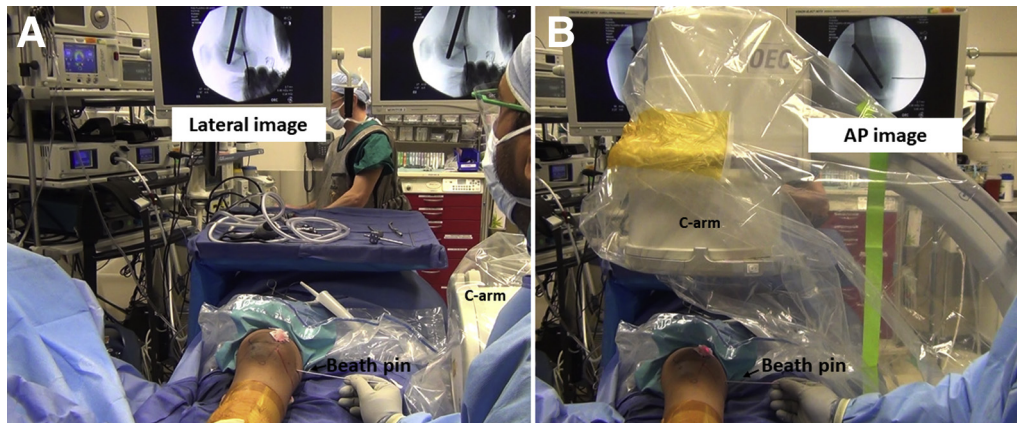
### Femoral Tunnel

On a perfect lateral fluoroscopic view with overlap of the femoral condyles, a 2-mm Beath pin is placed percutaneously at the femoral attachment point at the level of the distal femoral physis, just anterior to the posterior femoral cortex, and inserted about 1 cm using a mallet<sup>7</sup> (Fig 13). The position of the pin should be confirmed to be below the level of distal femoral physis on an anteroposterior view. The Beath pin is then advanced through the medial femoral epiphysis, under fluoroscopic guidance, from medial to lateral, posterior to anterior (to avoid the intercondylar notch) and inferior to the physis to exit from the lateral aspect of the knee. On the lateral view, the pin should be placed



**Fig 12.** Medial side of right knee. Both ends of the gracilis tendon (black arrow) are sutured together in a whipstitch fashion (white arrow) using nonabsorbable suture, once the tendon is passed through the patellar tunnel (dashed arrow).





**Fig 13.** For femoral tunnel position, a Beath pin (arrow) is placed under the guidance of lateral (A) fluoroscopic imaging of right knee. The pin is placed just anterior to the posterior femoral cortical line and at the level of the distal femoral physis. Its position is confirmed to be below the level of the distal femoral physis on an AP (B) image. (AP, anteroposterior.)

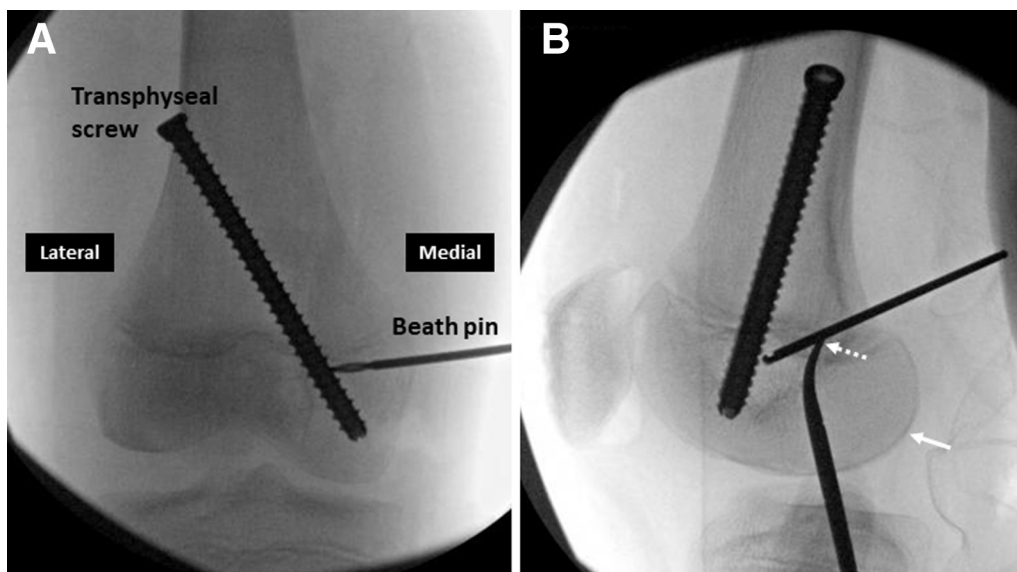
between the Blumensaat line and the transphyseal screw (Fig 14).

A 1-cm longitudinal incision is placed around the pin. Using a Kelly clamp and suture loop, the graft is shuttled between the second and third layer and out of the medial incision. An isometric assessment should be confirmed by wrapping the graft around the pin and putting the knee through flexion and extension to check for graft length changes (Fig 15). The Beath pin is overdrilled with an appropriate size reamer (5-6 mm) up to the opposite cortex.

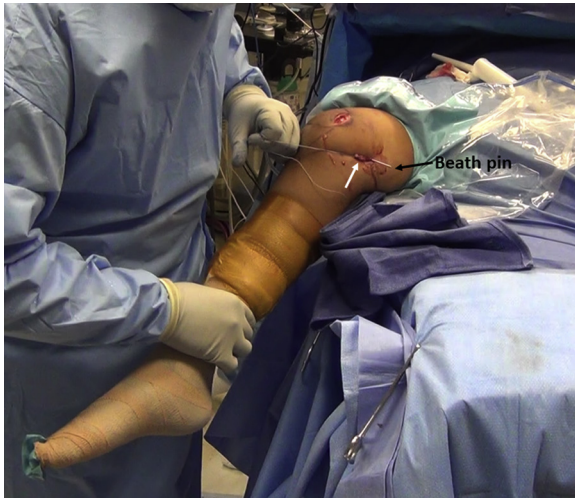A nitinol guide wire for interference screw is inserted into the drilled tunnel alongside the Beath pin (Fig 16).

#### Graft Passage and Fixation

The suture ends of the graft are placed through the eyelet of the Beath pin, which is pulled out from the lateral side pulling the graft into the femoral tunnel. With the knee in about 45° flexion and the patella engaged in the trochlea, the suture ends of the graft are clamped on the lateral side of the knee against the skin (Fig 17). Patellar mobility and tracking with knee



**Fig 14.** Fluoroscopic image of right knee. The position of Beath pin for femoral attachment of medial patellofemoral ligament on anteroposterior (A) and lateral (B) images of knee. On the lateral view, both femoral condyles should precisely overlap posteriorly and distally (solid arrow). The pin is directed anteriorly in the triangle formed by the Blumensaat line, distal femoral physis, and the transphyseal screw. A hemostat (dashed arrow) marks the entrance of the Beath pin.

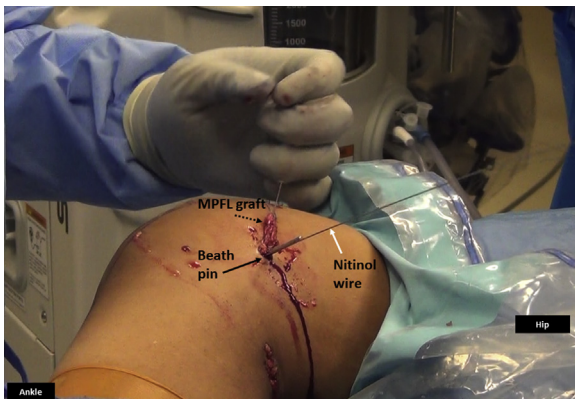


**Fig 15.** Medial side of right knee. The medial patellofemoral ligament graft (white arrow) is looped around the Beath pin (black arrow) and an isometric assessment of the graft is performed by knee flexion and extension and any graft length changes are noted.

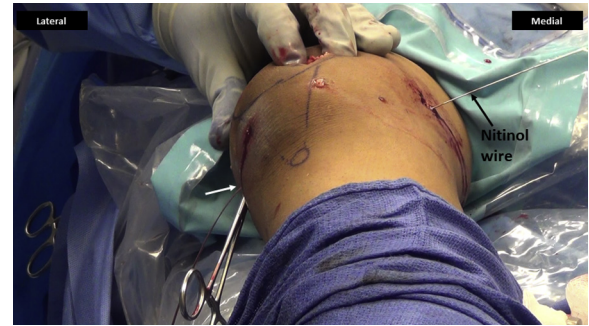flexion and extension is confirmed. Knee arthroscopy is performed to verify the extra-articular position and functioning of the graft (Fig 18). A biocomposite interference screw (Matryx; ConMed, Utica, NY) is inserted over the nitinol wire. The size of the screw is the same as femoral tunnel size and is 25 to 30 mm in length. The complete insertion of the screw is confirmed by fluoroscopic visualization of the screwdriver tip (Fig 19).

### Closure

The closure of medial retinaculum is performed with the knee flexed to prevent overtightening of medial



**Fig 16.** Medial side of the right knee. A nitinol wire (white arrow) is inserted in the femoral tunnel along the Beath pin (black arrow) to facilitate interference screw placement. The MPFL graft (dashed arrow) is ready to be placed in the femoral tunnel using pull-through sutures placed in the eyelet of the Beath pin. (MPFL, medial patellofemoral ligament.)

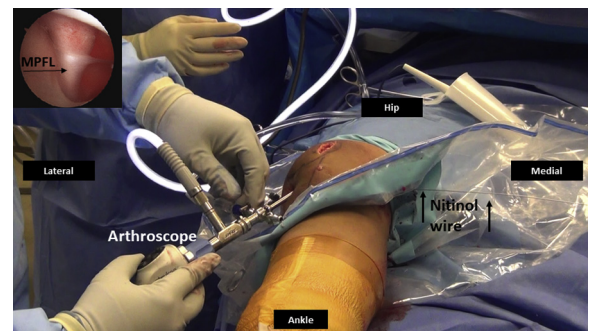


**Fig 17.** Right knee, seen from the foot end. The graft is passed in the femoral tunnel and clamped with a hemostat (white arrow) against the skin on the lateral side with the knee in about 45° of flexion. This would approximate final fixation and functioning of the graft. Nitinol wire (black arrow) is maintained in the femoral tunnel to facilitate percutaneous interference screw fixation.

structures. The medial retinaculum is imbricated in a pants-over-vest fashion using 2 to 3 absorbable sutures. All 3 incisions and portals are closed in a standard fashion. A well-padded dressing is applied, along with CryoCuff (DJO, Vista, CA) and a knee immobilizer.

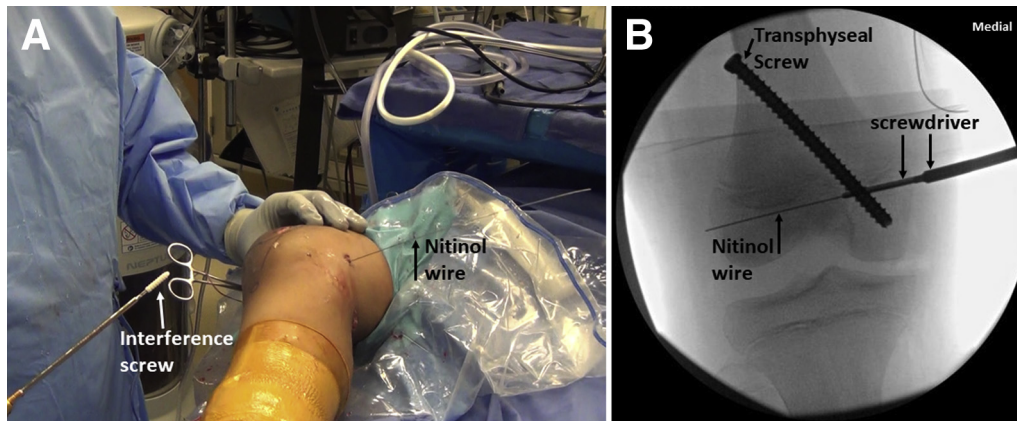
### Postoperative Course

Physical therapy is started within 3 to 4 days once the pain is under control. The patient is allowed weight bearing as tolerated in a knee immobilizer with crutches for 3 to 4 weeks, until quadriceps function is regained. Range of motion goals are 0 to 90° at 3 weeks and 0 to 120° at 6 weeks. Strengthening is initiated after 3 months. Functional strength tests including hop tests and isokinetic dynamometer (Biodex Medical Systems, Shirley, NY) tests are performed between 4 and



**Fig 18.** Right knee arthroscopy, viewing from anterolateral portal. The arthroscopy is performed to verify the extra-articular position and functioning of the MPFL graft. The MPFL graft is typically taut in extension (inset) and it would relax with flexion as the patella is constrained by trochlea. Nitinol wire (black arrows) is maintained in the femoral tunnel. (MPFL, medial patellofemoral ligament.)





**Fig 19.** Right knee. (A) An interference screw (white arrow) is inserted over the nitinol guide (black arrow) wire and its complete insertion is confirmed by fluoroscopic visualization of the screwdriver tip (B). The relationship between the transphyseal screw and interference screw can be seen.

6 months. Patients are released to full activities, including sports, typically at around 6 months, once all functional goals are achieved in physical therapy.

### Discussion

Pediatric cadaveric studies have demonstrated that the MPFL femoral attachment is predominantly below the level of the distal femoral physis.<sup>8</sup> The trajectory of the femoral tunnel is distal and inferior to the distal femoral physis and anterior to the intercondylar notch. This would allow a pull-out technique for the femoral guide pin and graft sutures.<sup>9</sup> Careful fluoroscopic guidance is critical during creation of femoral tunnel. We have not encountered any growth disturbances using this MPFL reconstruction technique in 79 skeletally immature patients. The alternate technique described in the literature has been to create a short and angled socket in the medial femoral epiphysis to avoid the physis and intercondylar notch penetration.<sup>9</sup>

The advantage of implant-mediated guided growth is that it does not require accurate growth prediction, as removal of the screw after deformity correction should restore normal growth (Table 2). The advantage of transphyseal screw, as compared with a tension-band plate for growth modulation, is that the screw would not interfere with the MPFL graft placement on the medial aspect of the knee. It would also avoid knee joint irritation, stiffness, and capsular penetration that could be seen with a plate. The disadvantage of transphyseal screw is its potential to damage the physis and cause growth disturbances. The transphyseal screw is inserted first, to ensure safety of the MPFL graft and sutures. We recommend full-length radiographs every 3 to 4 months until expected correction is achieved.

The current technique of MPFL reconstruction and simultaneous growth modulation is relatively simple to use and can correct an anatomic risk factor for patellar instability. Our experience has been reported with good

**Table 2.** Advantages, Disadvantages, Risks, and Limitations

1. The advantage of transphyseal screw for hemiepiphysiodesis is that it would not interfere with the placement of the MPFL graft, compared with a tension-band plate.
2. Compared with a tension-band plate, the transphyseal screw would not cause knee joint irritation or stiffness and would be inserted percutaneously.
3. The transphyseal screw should be avoided in very young children due to the risk of permanent physeal damage. The tension-band plate is a safer alternative.
4. The gracilis graft length may be inadequate if more graft is placed in the patellar tunnel or in larger patients. The alternative graft choices are semitendinosus, quadriceps tendon, patellar tendon or allograft.
6. In patients with physiologic hyperlaxity, there is a risk of stretching of the gracilis autograft over time. Allograft can be considered in these patients.
7. There is a risk of patellar fracture due to patellar tunnel placement. An alternative to patellar tunnel placement is to suture the graft to the periosteum, use suture anchors, or tunnel the graft through quadriceps tendon.
8. There is a risk of injury to the distal femoral physis during femoral tunnel placement.
9. There is a risk of change in MPFL graft position and isometricity with continued skeletal growth and with gradual correction of genu valgum. Staged surgery could be considered as an alternative.
10. Fluoroscopic identification of MPFL femoral tunnel landmarks has its limitations. An open approach to identification of MPFL femoral tunnel landmarks could be used as an alternative.

MPFL, medial patellofemoral ligament.

results and minimal complications.<sup>6</sup> The technique can be added to the surgical armamentarium when treating recurrent patellar instability in skeletally immature patients with genu valgum.

### References

1. Vavken P, Wimmer MD, Camathias C, Quidde J, Valderrabano V, Pagenstert G. Treating patella instability in skeletally immature patients. *Arthroscopy* 2013;29:1410-1422.
2. Seitlinger G, Moroder P, Fink C, Wierer G. Acquired femoral flexion deformity due to physeal injury during medial patellofemoral ligament reconstruction. *Knee* 2017;24:680-685.
3. Parikh SN, Nathan ST, Wall EJ, Eismann EA. Complications of medial patellofemoral ligament reconstruction in young patients. *Am J Sports Med* 2013;41:1030-1038.
4. Mizuno Y, Kumagai M, Mattessich SM, et al. Q-angle influences tibiofemoral and patellofemoral kinematics. *J Orthop Res* 2001;19:834-840.
5. Métaizeau JP, Wong-Chung J, Bertrand H, Pasquier P. Percutaneous epiphysiodesis using transphyseal screws (PETS). *J Pediatr Orthop* 1998;18:363-369.
6. Parikh SN, Redman C, Gopinathan NR. Simultaneous treatment for patellar instability and genu valgum in skeletally immature patients: A preliminary study. *J Pediatr Orthop B* 2019;28:132-138.
7. Huston KL, Okoroafor UC, Kaar SG, Wentt CL, Saluan P, Farrow LD. Evaluation of the Schöttle technique in the pediatric knee. *Orthop J Sports Med* 2017;5. 2325967117740078.
8. Shea KG, Polousky JD, Jacobs JC Jr, et al. The relationship of the femoral physis and the medial patellofemoral ligament in children: A cadaveric study. *J Pediatr Orthop* 2014;34:808-813.
9. Nelitz M, Reichel H, Dornacher D, Lippacher S. Anatomical reconstruction of the medial patellofemoral ligament in children with open growth-plates. *Arch Orthop Trauma Surg* 2012;132:1647-1651.