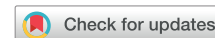

Inpatient use of mobile continuous telemetry for COVID-19 patients treated with hydroxychloroquine and azithromycin



James Gabriels, MD, Moussa Saleh, MD, David Chang, MD, Laurence M. Epstein, MD

From the Department of Cardiology, Division of Electrophysiology, North Shore University Hospital, Northwell Health, Manhasset, New York.

Introduction

The current COVID-19 pandemic has placed extreme stress on the global health care system. Novel approaches to managing COVID-19 patients are required. Preliminary results from a small trial suggest that a combination of hydroxychloroquine and azithromycin is efficacious for reducing the viral load in patients with COVID-19.¹ Although the arrhythmogenic risk of these medications is low, both of these medications alone, and in combination, can prolong the QT interval.¹⁻⁷ Patients receiving this regimen require, at a minimum, serial electrocardiograms (ECGs), which increases the risk of potential exposures for staff members and requires use of additional personal protective equipment. In addition, many of these patients have pre-existing cardiac conditions, including arrhythmias, and would benefit from inpatient telemetry monitoring. We describe the use of a mobile continuous telemetry monitor (MCOT) in a COVID-19-positive patient with a prior history of atrial fibrillation (AF) who was receiving hydroxychloroquine and azithromycin on a non-telemetry floor.

Case report

A 72-year-old woman with paroxysmal AF presented with several days of shortness of breath, cough, fevers, and chills. Her admission chest radiograph revealed a multifocal pneumonia and a nasopharyngeal swab tested positive for COVID-19. She was admitted to a non-telemetry floor with a cohort of other COVID-19 patients. Her home medications of apixaban 5 mg twice daily, metoprolol succinate 25 mg daily, and flecainide 50 mg twice daily were continued, and treatment with 400 mg of hydroxychloroquine twice daily (for 1 day, followed by 200 mg twice daily for 4 days) and 500 mg of intravenous azithromycin daily for 5 days was initiated. Her admission ECG, prior to starting hydroxychloroquine

and azithromycin, showed sinus rhythm with an interventricular conduction delay with a QRS duration (QRSd) of 128 ms and a QTc of 458 ms (Figure 1A). On the second day of admission, after the patient had received 1 dose of hydroxychloroquine and azithromycin, a repeat ECG showed a QRSd of 160 ms with a QTc of 472 ms (Figure 1B). Given that the inpatient telemetry units were fully occupied, and in light of the ECG changes that occurred after a single dose of these medications, an MCOT Patch monitor (BioTelemetry, Malvern, PA) was placed on the patient as a substitute for inpatient telemetry monitoring. Within hours of wearing the MCOT, she had an episode of AF that began at 6:07 PM in the setting of a fever of 102.6°F. At 6:28 PM the ventricular rate exceeded 150 beats per minute (Figure 1C) and the clinical team was notified of the arrhythmia by 6:31 PM. Given that the care providers were notified quickly, the patient was promptly given an additional dose of acetaminophen, flecainide 100 mg, and metoprolol tartrate 25 mg with quick resumption of sinus rhythm. On the following day the MCOT was used to obtain both the QRSd and QTc, which were 160 ms and 520 ms, respectively (Figure 1D). These values correlated with an ECG that was obtained simultaneously (QRSd: 160 ms, QTc: 517 ms). Her course of hydroxychloroquine and azithromycin was continued, with twice-daily monitoring of her QTc using the MCOT, without any further arrhythmic events and a stable QTc.

Discussion

This case demonstrates the utility of an MCOT in the inpatient setting for a patient being treated for COVID-19 with hydroxychloroquine and azithromycin. Based on the initial data from Gautret and colleagues,¹ there has been a drastic increase in the use of hydroxychloroquine and azithromycin as the number of confirmed cases of COVID-19 continues to rise.¹ In addition to hydroxychloroquine and azithromycin, chloroquine has also shown promising results in the treatment of COVID-19.⁸⁻¹⁰ In a similar fashion to hydroxychloroquine and azithromycin, chloroquine also can lead to QT prolongation.^{11,12} Our patient's QTc increased from 458 ms to 520 ms (Δ 62 ms) while receiving hydroxychloroquine and azithromycin.

KEYWORDS COVID-19; Mobile continuous telemetry; Inpatient; Arrhythmia (Heart Rhythm Case Reports 2020;6:241-243)

None of the authors has any financial support, conflicts of interest, or relationships with industry. **Address reprint requests and correspondence:** Dr James Gabriels, Department of Cardiology, Division of Electrophysiology, North Shore University Hospital, Northwell Health, 300 Community Drive, Manhasset, NY 11030. E-mail address: jamesgabriels@gmail.com.

KEY TEACHING POINTS

- With a finite number of telemetry beds, novel ways to monitor cardiac arrhythmias on non-telemetry floors are needed as the number of COVID-19 patients being treated with hydroxychloroquine, azithromycin, and chloroquine continues to rise.
- Mobile continuous telemetry patches, which provide near real-time notification of arrhythmias, can be used to monitor inpatients on non-telemetry units.
- These monitors can also provide serial assessments of the QT interval in patients receiving QT-prolonging medications.

The change in the QTc was, in part, due to an increase in the QRSd from 128 ms to 160 ms ($\Delta 32$ ms), which likely resulted from the additional dose of 100 mg of flecainide. Clinicians treating patients with SARS-CoV-2 must balance the potential benefits of these medications with the increased risks of QT prolongation and torsades des pointes. In the setting of this global pandemic, a 5-day course of these QT-prolonging medications is likely worth the small risk of torsades des pointes, almost irrespective of the patient's baseline QTc.

As the inpatient volume of COVID-19 patients continues to rise, the ability to monitor every patient that is receiving hydroxychloroquine and azithromycin on a telemetry unit will not be possible. Our quaternary hospital, with 392 medical/surgical beds, is only equipped to monitor 192 patients on telemetry (93 of these are intensive care unit beds). As of March 24, 2020, there were 81 COVID-19-positive inpatients receiving hydroxychloroquine and azithromycin on non-telemetry floors. We are currently in the process of expanding the use of inpatient monitoring with MCOTs to all of these patients and to similar patients at 4 other hospitals in our health system. The MCOT monitor, which uses the Bazett formula to derive the QTc, received Food and Drug Administration approval for use in patients that require measurement, analysis, and reporting of the QT interval in 2017. In addition to QT monitoring, as this case demonstrates, the use of an MCOT Patch monitor results in a near real-time notification when an arrhythmia occurs. In our experience, there was a delay of 3 minutes between when the patient's ventricular rate went above the notification threshold to the point when the clinical team was alerted. Although a span of 3 minutes may be an exceedingly long time for patients that develop ventricular arrhythmias, the ability to serially monitor the QTc intervals of these patients may facilitate a clinical intervention prior to those arrhythmias occurring. Most important, given the bed shortage, monitoring with an MCOT is a significant improvement when compared to no monitoring at all. Furthermore, given that the patch can be

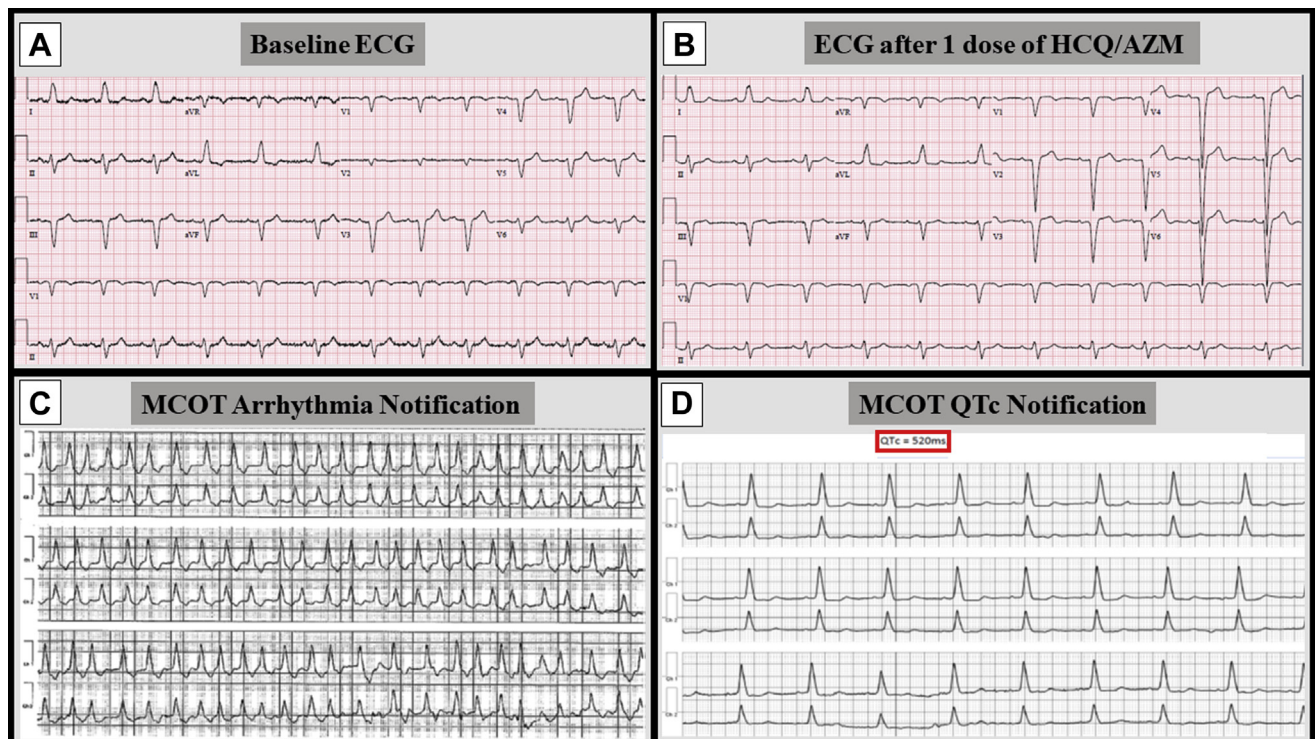


Figure 1 Electrocardiograms (ECG) and mobile continuous telemetry recordings from a patient with COVID-19 treated with hydroxychloroquine (HCQ) and azithromycin (AZM). **A:** Baseline ECG prior to HCQ/AZM, QRS duration (QRSd): 128 ms, QTc: 458 ms. **B:** ECG after 1 dose of HCQ/AZM, QRSd: 160 ms, QTc: 472 ms. **C:** Notification from mobile continuous telemetry (MCOT) of atrial fibrillation with a ventricular rate >150 beats per minute. **D:** Notification from MCOT with QTc measurement (520 ms).

left in place for the full 5-day course of hydroxychloroquine and azithromycin, widespread use of the MCOTs will lead to a significant reduction in the number of potential exposures to health care workers and a reduction in the need for personal protective equipment, as obtaining serial ECGs to monitor the QT interval will no longer be necessary.

Conclusion

As our health care system continues to be inundated with COVID-19 patients, the need for unique and innovative approaches to manage these patients becomes increasingly important. With the rising use of hydroxychloroquine and azithromycin or chloroquine, and a finite number of telemetry beds, new methods for cardiac rhythm monitoring of inpatients on non-telemetry floors is needed. This case report demonstrates that an MCOT can provide both prompt notification when an arrhythmia occurs and serial QTc measurements for inpatients on non-telemetry floors.

References

- Gautret P, Lagier JC, Parola P, et al. Hydroxychloroquine and azithromycin as a treatment of COVID-19: results of an open-label non-randomized clinical trial [published online ahead of print March 17, 2020]. *Int J Antimicrob Agents*. doi:10.1016/j.ijantimicag.2020.105949.
- Matsunaga N, Oki Y, Prigollini A. A case of QT-interval prolongation precipitated by azithromycin. *N Z Med J* 2003;116:U666.
- Samarendra P, Kumari S, Evans SJ, Sacchi TJ, Navarro V. QT prolongation associated with azithromycin/amiodarone combination. *Pacing Clin Electrophysiol* 2001;24:1572–1574.
- Russo V, Puzio G, Siniscalchi N. Azithromycin-induced QT prolongation in elderly patient. *Acta Biomed* 2006;77:30–32.
- Chen CY, Wang FL, Lin CC. Chronic hydroxychloroquine use associated with QT prolongation and refractory ventricular arrhythmia. *Clin Toxicol (Phila)* 2006;44:173–175.
- Morgan ND, Patel SV, Dvorkina O. Suspected hydroxychloroquine-associated QT-interval prolongation in a patient with systemic lupus erythematosus. *J Clin Rheumatol* 2013;19:286–288.
- Negoescu A, Thornback A, Wong E, Ostor A. Long QT and hydroxychloroquine; a poorly recognized problem in rheumatology patients. *Arthritis Rheumatol* 2013; 65:2045.
- Colson P, Rolain J, Raoult D. Chloroquine for the 2019 novel coronavirus SARS-CoV-2. *Int J Antimicrob Agents* 2020;55:105923.
- Colson P, Rolain JM, Lagier JC, Brouqui P, Raoult D. Chloroquine and hydroxychloroquine as available weapons to fight COVID-19 [published online ahead of print March 4, 2020]. *Int J Antimicrob Agents*. doi:10.1016/j.ijantimicag.2020.105932.
- Yao X, Zhang M, Cui C, et al. In vitro activity and projection of optimized dosing design of hydroxychloroquine for the treatment of severe acute respiratory syndrome coronavirus 2 (SARS-CoV-2). *Clin Infect Dis* [published online ahead of print March 9, 2020]. doi:10.1093/cid/ciaa237.
- Stats P, Faes D, Noyens P. Conduction disorder and QT prolongation secondary to long-term treatment with chloroquine. *Int J Cardiol* 2008;127:e80–e82.
- Li M, Ramos LG. Drug-induced QT prolongation and torsade de pointes. *Heart* 2003;89:1363–1372.