



Since January 2020 Elsevier has created a COVID-19 resource centre with free information in English and Mandarin on the novel coronavirus COVID-19. The COVID-19 resource centre is hosted on Elsevier Connect, the company's public news and information website.

Elsevier hereby grants permission to make all its COVID-19-related research that is available on the COVID-19 resource centre - including this research content - immediately available in PubMed Central and other publicly funded repositories, such as the WHO COVID database with rights for unrestricted research re-use and analyses in any form or by any means with acknowledgement of the original source. These permissions are granted for free by Elsevier for as long as the COVID-19 resource centre remains active.

Image in medicine

Rapid immunoglobulin test confirms a suspected case of COVID-19

El test rápido de inmunoglobulinas confirma un caso sospechoso de COVID-19

Judit Constán-Rodríguez*, Concepción Fernández-Roldán, Concepción López-Robles

Unidad de Enfermedades Infecciosas, Hospital Universitario Virgen de las Nieves, Granada, Spain

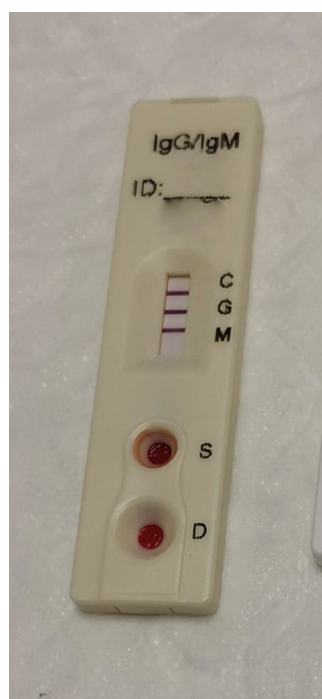


Figure 1. Rapid immunoglobulin test.

A 50-year-old man was admitted for acute motor aphasia, he was treated with fibrinolysis by stroke in the left brain media artery territory. Before admission, he had fever and dyspnea for 5 days. He presented hypoxemic bilateral interstitial pneumonia highly suggestive for COVID 19 infection, although 3 samples (two nasopharyngeal and one bronchial exudates) for PCR were negative. The blood test revealed lymphocytopenia and an increase in LDH, AST, ALT, C-reactive protein and D-dimer.

Getting worse that requires invasive mechanical ventilation, so that treatment with azithromycin, hydroxychloroquine, lopinavir/ritonavir was initiated.

Ten days after the respiratory symptoms the IgM and IgG rapid detection test for SARS-Cov 2 was performed, being positive for both (Fig. 1).

Clinical and radiological improvement were demonstrated after adding pronation and the administration of tocilizumab.

Immunoglobulin detection by immunochromatography can confirm coronavirus infection when PCR is negative when have passed at least 6–10 days since the onset of symptoms.

* Corresponding author.

E-mail address: juditconstan@gmail.com (J. Constán-Rodríguez).