

Case report

A case of cow's milk allergy in the neonatal period - evidence for intrauterine sensitization?

Feiterna-Sperling C, Rammes S, Kewitz G, Versmold H, Niggemann B. A case of cow's milk allergy in the neonatal period - evidence for intrauterine sensitization?

Pediatr Allergy Immunol 1997; 8: 153-155. © Munksgaard 1997.

Clinical manifestations of cow's milk allergy rarely occur in the first days after birth. We report on a newborn presenting with hemorrhagic meconium in the first hour of life followed by bloody diarrhea in the next few days. At day 14, an elevated total IgE, specific IgE to cow's milk and an eosinophilia in peripheral blood were found. Symptoms disappeared when the milk feed was changed to an extensively hydrolyzed casein-formula. Two challenges with cow's milk formula (on day 30 and at 7 months of age) were followed by recurrence of vomiting, watery diarrhea and failure to thrive. At the age of 17 months cow's milk was tolerated well. Although other pathogenetic mechanisms cannot completely be ruled out, there is strong evidence that cow's milk allergy - induced by intra-uterine sensitization - explains the symptoms in our patient. In conclusion, cow's milk allergy can occur even in the first days of life, and our clinical observation supports the concept of intra-uterine sensitization to allergens.

**Cornelia Feiterna-Sperling¹,
Stefanie Rammes²,
Gabriele Kewitz², Hans Versmold²
and Bodo Niggemann¹**

¹Children's Hospital, Charité-Virchow-Klinikum,
Humboldt University, Berlin, Germany

²Department of Pediatrics, Benjamin Franklin
Clinic, Free University, Berlin, Germany

Cornelia Feiterna-Sperling, M.D., Charité-Virchow-
Clinic, Children's Hospital, Augustenburger
Platz 1, 13353 Berlin, Germany

Key words: cow's milk allergy; diarrhea; intra-uter-
ine sensitization

Received June 27, 1997

Accepted July 28, 1997

Cow's milk allergy (CMA) is an immunologically mediated reproducible adverse reaction to nutritional cow's milk proteins (1). Immunological mechanisms leading to this type of food allergy are mainly based on IgE-mediated (Type I) hypersensitivity, but IgG-antibody-dependent cell mediated cytotoxicity, immune complex mechanisms and cellular immune responses may also be involved (2, 3). The reported prevalence of CMA varies from 0.3%-7.5%, probably due to differences in diagnostic criteria (4-6). CMA is a disease of early infancy, and most infants develop first symptoms approximately 1 week after introduction of a cow's milk based formula. Onset before 1 month and after the age of 12 months is rare (1). The most commonly affected organ system in the first months of life is the gastrointestinal tract leading to vomiting, diarrhea, colic, malabsorption, colitis and gastrointestinal bleeding. Other clinical manifestations of CMA are localized in the respiratory tract (e.g., bronchial obstruction) or skin (e.g., atopic eczema, urticaria, angioedema) and occasionally anaphylactic reactions can occur (7). Clinical symptoms may develop within a few minutes or up to 1 hour after exposure to cow's milk ("immediate onset") or later than 1 hour ("intermediate onset") or even after some days ("late onset") (8).

We describe a case of a neonate presenting with an uncommonly early manifestation of cow's milk allergy on the first day of life, suggesting that both sensitization to cow's milk proteins and the presumably IgE-mediated allergic response in the gut occurred during the prenatal period.

Case report

After an inconspicuous pregnancy a male infant appropriate for gestational age was born at term (37 weeks' gestation) by spontaneous delivery. It was the third child of apparently healthy parents without a family history of allergic diseases. The grandmother was said to have an intolerance to milk products. The mother had no history of milk intolerance and ingested on average 1-2 glasses of milk daily during pregnancy. Birth weight was 3.350 kg, the amniotic fluid was meconium-stained and partly hemorrhagic. Already in the delivery room the neonate discharged hemorrhagic meconium, followed by bloody diarrhea up to 8 times a day. The initial laboratory tests showed normal coagulation studies (prothrombin time [Quick] 51%, partial thromboplastin time 22 sec, fibrinogen 2.53 g/l, anti-thrombin III 92%); the hematocrit fell from 0.48 l/l

on the first day to 0.35 l/l on day 11. White blood cell count was 11 000/ μ l with a pronounced eosinophilia (peak of 1 540/ μ l, 14%) in the differential count noted; platelets and C-reactive protein (CRP) were normal.

After 24 hours, the infant was fed with a cow's milk based formula for the first time. The following days there was ongoing intermittent bloody diarrhea and vomiting. There were no peritoneal signs and the results of abdominal ultrasound and X-rays of the abdomen were normal. Repeated stool cultures did not identify a viral (Rotavirus, Adenovirus, Coronavirus like particle) or bacterial (Salmonella, Shigella, Campylobacter, Yersinia, Aeromonas) pathogen. Serological tests for infectious diseases including toxoplasmosis, rubella, cytomegalovirus infection, herpes simplex, hepatitis B and HIV-1 were negative. Because of clinical deterioration with dehydration and hypokalemia treatment with intravenous fluids was started on day 11 (see Fig. 1). An allergy was suspected in view of a markedly increased total IgE (208 kU/l) as well as the detection of specific IgE-antibodies to cow's milk protein (13.6 kU/l; CAP class 3) both analyzed on day 14. Consequently, enteral nutrition with an extensively hydrolyzed casein-formula (Nutramigen®) and breast feeding was started on day 16. The mother was advised to minimize the intake of dairy products and avoid fish and eggs in her diet during lactation. The further course under cow's milk-free diet showed normalizing stool in terms of frequency and quality, as well as an adequate weight gain.

On day 30 a challenge with 10 ml of a cow's milk formula resulted in the recurrence of vomiting and watery diarrhea within 4 hours. Thereafter the child received only Nutramigen® and breast feeding. In the following months the child gained weight ade-

quately reaching the 50th percentile at the age of 3 months. At the age of 7 months a rechallenge with a cow's milk based formula again led to vomiting and watery diarrhea. Therefore the diet of the child remained free from cow's milk. At the age of 17 months cow's milk products were introduced in the child's diet and since then all milk products have been tolerated well. Subsequently, the child did not develop any other atopic symptoms such as eczema or asthma.

Discussion

We report on a case of cow's milk allergy, presenting with bloody diarrhea during the early neonatal period. Coagulation disorders were excluded by laboratory tests and clinical examination, the absence of peritoneal signs and the clinical course argues against a vascular disorder as a cause of the gastrointestinal bleeding. Infectious causes were unlikely, because of negative stool cultures for common viral and bacterial pathogens as well as negative serological findings. A marked eosinophilia in the differential blood count was noted on the first day of life and furthermore an increased total IgE as well as specific IgE-antibodies to cow's milk protein could be demonstrated as early as on day 14. The eosinophilia and the specific IgE to cow's milk protein in conjunction with the repeated positive oral challenges with cow's milk formula indicate that a cow's milk allergy may have been the cause of the symptoms in this newborn. In addition, the clinical course with subsequent tolerance to cow's milk exclude an inborn lactose intolerance as an etiologic factor in the disease. Additional other factors such as unknown infections, or vascular disorders are very unlikely, although they cannot be completely ruled out.

Clinical symptoms of CMA often develop within one week after the introduction of cow's milk protein to the diet but CMA has rarely been described in the first week of life and only in few cases at the first intake of cow's milk (5, 9–11). Our case may represent the first report of a manifestation of CMA directly after delivery. From our observation the following inferences can be made: sensitization must have occurred *in utero* due to either cow's milk antigen present in the amniotic fluid or antigen crossing the placenta to elicit an allergic response in the fetus. Intrauterine sensitization to food allergens has been described by Kuroume et al. (12). The mechanism, however, remains obscure. One hypothesis may be that *in utero* oral intake of cow's milk proteins presumably present in the amniotic fluid has led to an early intestinal manifestation of CMA. This may indicate that the fetus is able to exhibit an allergic response in the gastrointestinal tract even before oral intake.

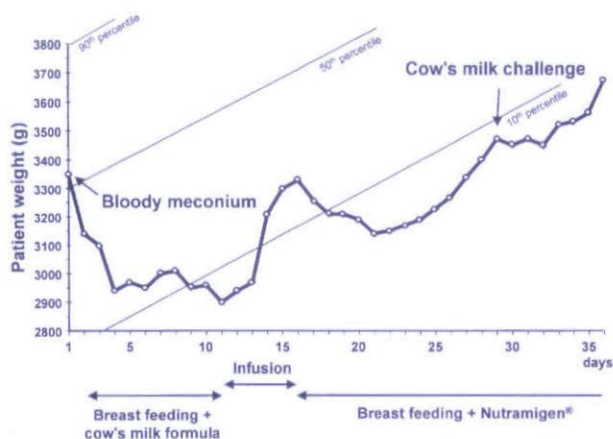


Fig. 1. Nutrition and weight development during the first 36 days of life.

Two recent studies provide further evidence that *in utero* fetal exposure at around 22 weeks gestation can result in primary sensitization to common allergens and the fetal immune system is capable of developing a specific immune response (13, 14). Additionally, reports have demonstrated specific IgE antibodies to cow's milk proteins in cord blood of some newborns, although these results were not reproduced by others (15).

We conclude that there is strong evidence for a cow's milk allergy in our patient. The symptom of bloody diarrhea at birth may already have been the first sign.

This implies that cow's milk allergy should be taken into consideration if immediate type symptoms occur in the presence of specific sensitization – even in the first days of life.

References

1. HØST A. Cow's milk protein allergy and intolerance in infancy. *Pediatr Allergy Immunol* 1994; 5 (Suppl. 5): 5–36.
2. BAHNA SL. Pathogenesis of milk hypersensitivity. *Immunol Today* 1985; 6: 153–5.
3. HILL DJ, HOSKING CS. Cow milk allergy in infancy and early childhood. *Clin Exp Allergy* 1996; 26: 243–6.
4. GERRARD JW, MACKENZIE JWA, GOLUBOFF N, GARSON JZ, MANINGAS CS. Cow's milk allergy: prevalence and manifestations in an unselected series of newborn. *Acta Paediatr Scand* 1973; 234 (Supplement): 1–21.
5. JACOBSSON O, LINDBERG T. A prospective study of cow's milk protein intolerance in Swedish infants. *Acta Paediatr Scand* 1979; 68: 853–9.
6. HØST A, HUSBY S, ØSTERBALLE O. A prospective study of cow's milk allergy in exclusively breast-fed infants. *Acta Paediatr Scand* 1988; 77: 663–70.
7. WILSON NW, HAMBURGER RN. Allergy to cow's milk in the first year of life and its prevention. *Ann Allergy* 1988; 61: 323–7.
8. HILL DJ, FIRER MA, SHELTON MJ, HOSKING CS. Manifestations of milk allergy in infancy: clinical and immunological findings. *J Pediatr* 1986; 109: 272–6.
9. WILSON NW, SELF TW, HAMBURGER RN. Severe cow's milk induced colitis in an exclusively breast-fed neonate. *Clin Pediatr* 1990; 29: 77–80.
10. HILL DJ, DAVIDSON GP, CAMERON DJS, BARNES GL. The spectrum of cow's milk allergy in childhood: clinical, gastroenterological and immunological studies. *Acta Paediatr Scand* 1979; 68: 847–52.
11. GERRARD JW, SHENASSA M. Food allergy: two common types as seen in breast and formula fed babies. *Ann Allergy* 1983; 50: 375–9.
12. KUROUME T, OGURI M, MATSUMURA T, et al. Milk sensitivity and soybean sensitivity in the production of eczematous manifestations in breast-fed infants with particular reference to intra-uterine sensitization. *Ann Allergy* 1976; 37: 41–6.
13. JONES AC, MILES EA, WARNER JO, COLWELL BM, BRYANT TN, WARNER JA. Fetal peripheral blood mononuclear cell proliferative responses to mitogenic and allergenic stimuli during gestation. *Pediatr Allergy Immunol* 1996; 7: 109–16.
14. SZÉPFALUSI Z, NENTWICH I, GERSTMAYR M, et al. Prenatal allergen contact with milk proteins. *Clin Exp Allergy* 1997; 27: 28–35.
15. HØST A, HUSBY S, GJESING B, LARSEN JN, LØWENSTEIN H. Prospective estimation of IgG, IgG subclass and IgE antibodies to dietary proteins in infants with cow milk allergy. Levels of antibodies to whole milk protein BLG and ovalbumin in relation to repeated milk challenge and clinical course of cow milk allergy. *Allergy* 1992; 47: 218–29.

This document is a scanned copy of a printed document. No warranty is given about the accuracy of the copy. Users should refer to the original published version of the material.