

Letter to the Editor

Computed tomography (CT) scan challenges the result of SARS-CoV-2 nucleic acid test in a suspected COVID-19 case

Kun Yan MS^{1,a}, Jingfeng Zhang MD, PhD^{1,2,a}, Yangfan Zhang BS³, Shun Zhang MS¹, Ting Cai MS^{1,2} and Jianjun Zheng MS^{1,2}

¹Hwa Mei Hospital, University of Chinese Academy of Sciences, Ningbo, Zhejiang, China, ²Ningbo Institute of Life and Health, University of Chinese Academy of Sciences, Ningbo, Zhejiang, China and ³Ningbo University School of Medicine, Ningbo, Zhejiang, China

To the Editor—At present, COVID-19 is a global pandemic. The reverse-transcriptase polymerase chain reaction (RT-PCR) test is the gold standard for diagnosing COVID-19. We report a case with the false-positive result of SARS-CoV-2 nucleic acid testing in which chest computed tomography (CT) findings challenged the diagnosis of COVID-19 pneumonia.^{1,2}

On February 16, 2020, a 36-year-old man presented to a local primary healthcare clinic with a mild cough and subjective fever for 1 day. He had no history of contact with COVID-19 patients. Physical examination revealed a body temperature of 38.4°C. A routine blood panel showed normal ranges of white blood cells count ($8.9 \times 10^9/L$), neutrophils ($6.1 \times 10^9/L$), and lymphocytes ($1.8 \times 10^9/L$), as well as a high level of C reactive protein (25.2 mg/L). An oropharyngeal swab tested negative for influenza A and B but positive for SAR-CoV-2 by RT-PCR on February 17. The patient's chest CT showed large, mixed, ground-glass opacity (GGO) in the lower lobe of right lung with partial consolidation, distribution along with bronchovascular bundles, and a little effusion of the right oblique fissure (Fig. 1, Panel A).

On February 18, the patient was transferred to our hospital for isolation and treatment as a “confirmed case.” According to a consultation among a multidisciplinary team, the diagnosis for COVID-19 seemed to be questionable according to the CT manifestations. Therefore, some imperative measures were taken as follows: (1) the patient was isolated in a single ward; (2) the same

specimen was recollected as soon as possible and testing was repeated; (3) the patient's serum was tested for the virus-specific antibody of IgM for SAR-CoV-2; (4) a blood culture for bacteria or fungi was performed; and (5) an antibacterial agent was administered (moxifloxacin hydrochloride tablets, 0.4 g orally 4 times per day) as well as an antiviral agent (lopinavir/ritonavir tablets 400 mg/100 mg orally twice daily).

The patient's serum tested negative for SARS-CoV-2-specific IgM antibody on February 18. Consecutive samples were collected for SARS-CoV-2 testing daily from February 18 to February 20 (ie, oropharyngeal swab and sputum). All of the repeated tests of viral nucleic acid were negative. A 5-day blood culture demonstrated no growth of bacteria or fungi. The patient's symptoms gradually improved. A repeat chest CT scan on February 21 showed that the lesions in the right lower lobe had been partially absorbed (Fig. 1, panel B).

On February 22, bronchoalveolar lavage fluid was collected for SARS-CoV-2 testing by RT-PCR and the result was also negative. On February 24, the patient's serum tested negative for SARS-CoV-2-specific IgG antibody. All of his symptoms had disappeared by February 26. A follow-up chest CT on February 29 showed that the lesions in the right lower lobe had completely resolved (Fig. 1, panel C). After a consultation with the COVID-19 prevention and control committee in our hospital, the diagnosis was revised to community-acquired pneumonia (CAP)

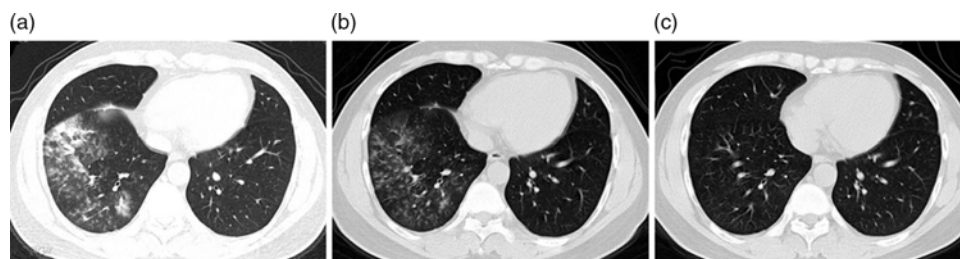


Fig. 1. Chest computed tomography (CT) images of a 36-year-old man with a false-positive nucleic acid test result for SARS-CoV-2. The revised diagnosis was community-acquired pneumonia. Panel A: chest CT obtained on February 16 shows large, mixed, ground-glass opacity (GGO) in the right lower lobe with partial consolidation, distribution along with bronchovascular bundles, and a little effusion of the right oblique fissure. Panel B: a CT image obtained on February 21 demonstrates that the lesions in the right lower lobe have been partially absorbed. Panel C: a CT image obtained on February 29 shows that the lesions in the lower right lobe have completely resolved.

Author for correspondence: Jianjun Zheng, E-mail: zhengjianjun@ucas.ac.cn

^aAuthors of equal contribution.

Cite this article: Yan K, et al. (2020). Computed tomography (CT) scan challenges the result of SARS-CoV-2 nucleic acid test in a suspected COVID-19 case. *Infection Control & Hospital Epidemiology*, <https://doi.org/10.1017/ice.2020.171>

considering no history of contact with COVID-19 patients and the negative results of consecutive repeat RT-PCR tests and the serum antibody test. The patient was released from quarantine and was discharged on the same day.

Yan *et al*³ reported that failing to consider COVID-19 because of a positive rapid test result for dengue fever, which has serious implications not only for the patient but also for public health. Our case highlights the importance of timely recognition of a false-positive result for SARS-CoV-2 when chest CT findings do not conform to the typical changes of COVID-19 pneumonia. From the epidemic control perspective, it is imperative to isolate individuals with suspected cases of COVID-19 to protect the uninfected population. However, the suspected cases should not be housed with confirmed cases of COVID-19 to prevent the spread of this disease.

Acknowledgments. We are appreciated with Dr.Chuyi Cai and Prof. Getu Zhaori for their kind help to translate and polish some contents of the manuscript.

Financial support. This work was supported by Key Research Foundation of Hwa Mei Hospital, University of Chinese Academy of Sciences, China (Grant No. 2020HMZD19, 2020HMZD20).

Conflicts of interest. All authors report no conflicts of interest relevant to this article.

References

1. Bernheim A, Mei X, Huang M, *et al*. Chest CT findings in coronavirus disease-19 (COVID-19): relationship to duration of infection. *Radiology* February 20, 2020 [Epub ahead of print]. doi: [10.1148/radiol.2020200463](https://doi.org/10.1148/radiol.2020200463).
2. Chua F, James DA, Desai SR, *et al*. The role of CT in case ascertainment and management of COVID-19 pneumonia in the UK: insights from high-incidence regions. *Lancet Infect Dis* March 25, 2020 [Epub ahead of print]. doi: [10.1016/S2213-2600\(20\)30132-6](https://doi.org/10.1016/S2213-2600(20)30132-6).
3. Yan G, Lee CK, Lam LTM, *et al*. Covert COVID-19 and false-positive dengue serology in Singapore. *Lancet Infect Dis* 2020 March 4 [Epub ahead of print]. doi: [10.1016/S1473-3099\(20\)30158-4](https://doi.org/10.1016/S1473-3099(20)30158-4).