



# Sudden death due to acute pulmonary embolism in a young woman with COVID-19

Veli Polat<sup>1</sup> · Güngör İlayda Bostancı<sup>1</sup>

Published online: 11 May 2020  
© Springer Science+Business Media, LLC, part of Springer Nature 2020

## Abstract

Coronavirus disease 2019 (COVID-19) is an infectious disease that primarily affects the respiratory system, but it may cause cardiovascular complications such as thromboembolism. Rarely, pulmonary embolism may be encountered in patients with severe COVID-19 infection, especially in intensive care units. An asymptomatic young case of COVID-19 presenting with sudden death due to acute massive pulmonary embolism has not been previously described. We report a 41-year-old woman presented to emergency department with sudden death during physical activity. She had only history of diabetes mellitus and she was asymptomatic until sudden death. CT pulmonary angiography and chest CT scans revealed acute massive embolism and typical imaging findings of COVID-19 pneumonia, respectively. Interestingly, the patient had no symptoms or signs of infection and also had no risk factors for thromboembolism. COVID-19 infection appears to induce venous thromboembolism, especially pulmonary embolism. The case is remarkable in terms of showing how insidious and life-threatening COVID-19 infection can be.

**Keywords** COVID-19 · Pulmonary embolism · Sudden death · Case report

## Highlights

- Nowadays, the world is threatened by the severe acute respiratory syndrome coronavirus 2 (SARS-CoV-2) outbreak, the novel coronavirus that causes COVID-19 infection.
- COVID-19 infection may cause cardiovascular complications that can even lead to death, such as thromboembolic events.
- The patients who are admitted to the hospital with a clinical picture of pulmonary embolism without signs and symptoms of infection during pandemic should also be evaluated for possible underlying COVID-19 infection.
- Anticoagulant therapy is crucial and necessary for the prevention of thromboembolic complications in patients with COVID-19 infection.

- Acute pulmonary embolism should come to mind in the case of sudden clinical deterioration, hypoxia, hemodynamic deterioration or cardiac arrest in patients with COVID-19 infection.

## Introduction

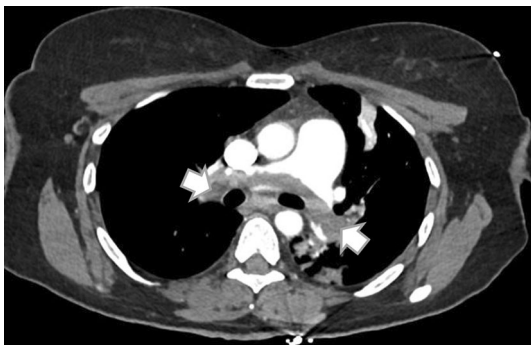Coronavirus disease 2019 (COVID-19) is a clinical syndrome caused by infection with the novel coronavirus called severe acute respiratory syndrome coronavirus 2. COVID-19 is an infectious disease that primarily affects the respiratory system, but it can also cause other complications, such as cardiovascular problems. Although the symptoms of COVID-19 may resemble the symptoms of pulmonary embolism (PE), in some cases, PE may accompany COVID-19 [1]. Lately, cases of acute PE associated with severe COVID-19 infection have been reported. These reported cases are generally in the elderly group and there is no robust risk factor to explain acute PE [2–5]. We report a case of acute massive PE, resulting in sudden death associated with COVID-19.

✉ Veli Polat  
dr.velipolat@gmail.com

<sup>1</sup> Department of Cardiology, Bakirkoy Dr. Sadi Konuk Training and Research Hospital, Zuhuratbaba Mah, Dr. Tevfik Sağlık Cd No:11, Bakırköy, 34147 Istanbul, Turkey

## Case report

A 41-year-old woman presented to the emergency department with sudden death during physical activity. She had no known history of disease other than diabetes mellitus and she had no history of medication usage including oral contraceptives except insulin. According to the information received from the patient's relatives, she was asymptomatic until sudden death. Spontaneous circulation was achieved in the patient after 20 min of successful cardiopulmonary resuscitation. Since she had no spontaneous breathing, she was intubated, and mechanical ventilation was initiated. Laboratory tests displayed slightly elevated C-reactive protein level of 14 mg/L, leukocytosis of  $14.010/\text{mm}^3$ , modest increased troponin I level of 45 pg/mL and elevated D-dimer level of 7.29  $\mu\text{g}/\text{mL}$ . She was afebrile but her nasopharyngeal swab reverse transcription polymerase chain reaction test was positive for SARS-CoV-2. Her measured blood gas

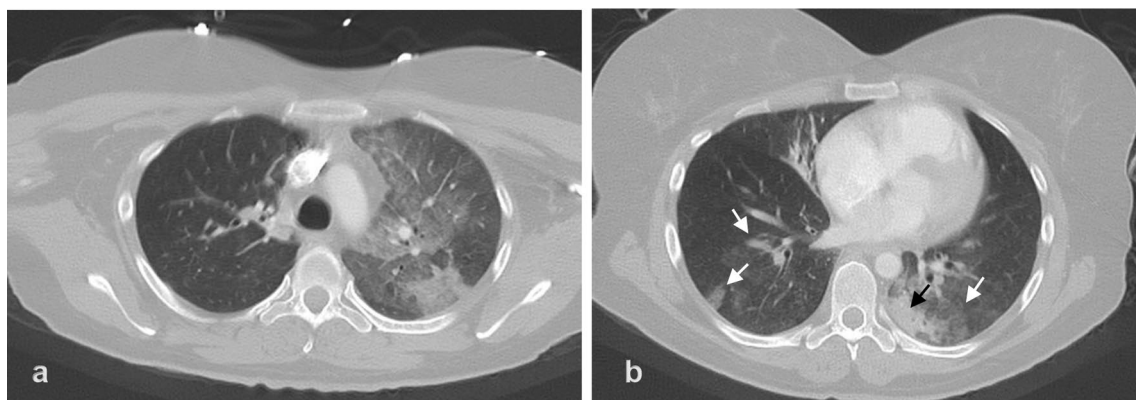


**Fig. 1** The CT pulmonary angiography showing partially obliteration of the both right and left pulmonary arteries with thrombus, as indicated by white arrows

values were 52.8 mmHg for partial oxygen pressure and 84.3 mmHg for partial carbon dioxide pressure. Straight after these tests, her 12-lead electrocardiogram was obtained and it revealed sinus tachycardia, ST elevation in  $V_1 \geq 1 \text{ mV}$  and in a  $VR \geq 1 \text{ mV}$ , Qr in  $V_1$ , prominent S wave in lead I. An immediate hand-held echocardiogram showed right ventricular systolic dysfunction, enlargement in the right heart chambers and moderate tricuspid regurgitation. In computed tomography (CT) pulmonary angiography, the diagnosis of acute massive pulmonary embolism was made after detecting that the right and left pulmonary arteries were partially obliterated with thrombus (Fig. 1). Simultaneous chest CT scan determined peripheral ground-glass opacities in bilateral lung parenchyma with consolidation in the left upper lobe (Fig. 2). The chest CT scan findings of the patient were typical for COVID-19 pneumonia [6, 7]. She had no known risk factor for venous thromboembolism. In addition, thrombus was not detected in the bilateral lower extremity venous Doppler examination. She was promptly treated with intravenous tissue plasminogen activator (100 mg/2 h) and subcutaneous enoxaparin (1 mg/kg twice a day). She had a sudden cardiac arrest within the 4 h of the thrombolytic therapy. Unfortunately, despite early cardiopulmonary resuscitation in the intensive care unit, spontaneous circulation was not achieved, and she was declared dead.

## Discussion

COVID-19 may lead to arterial and venous thromboembolic events by either inducing excessive systemic inflammatory response, procoagulant activity, immobilization, and hypoxia, or causing disseminated intravascular coagulation [3, 8, 9]. A few cases and trials of acute PE associated with COVID-19 infection have recently been reported [2, 3, 5,



**Fig. 2** The axial chest CT scan demonstrating extensive multifocal patchy ground-glass opacities in the left lung parenchyma (a). The axial chest CT scan displaying bilateral peripheral ground-glass opac-

ities (white arrows) with predominance on the left side with consolidation (black arrow) in the left upper lobe (b)

10]. To the best of our knowledge, this is the first reported case of COVID-19 infection, which was presented with acute massive PE without any symptoms of COVID-19 infection. This case suggests that sudden, unexpected deaths outside of hospital may also be associated with COVID-19 infection during the pandemic period. COVID-19 pneumonia was detected in addition to massive PE during chest CT imaging, which was planned according to electrocardiogram and echocardiographic findings compatible with pulmonary embolism.

Viral infections may induce coagulopathy by affecting coagulation cascade, fibrinolysis and primary hemostasis. Particularly, respiratory tract viral infections are known to raise the risk of deep venous thrombosis and PE. In severe acute respiratory syndrome caused by coronaviruses between 2003 and 2004, the occurrence of pulmonary infarction has been reported due to damage in small and medium-sized pulmonary vessels, deep vein thrombosis, diffuse intravascular coagulation and pulmonary thromboembolism [11].

## Conclusions

COVID-19 infection appears to trigger venous thromboembolism, especially PE, even without underlying risk factor. It should be kept in mind that patients who are admitted to the hospital with a clinical picture of PE without signs and symptoms of infection during pandemic may also have COVID-19 infection. This case also emphasizes the importance of anticoagulant therapy in the prevention of thromboembolic complications in COVID-19 patients. Furthermore, in the case of sudden clinical deterioration, hypoxia, hemodynamic deterioration or cardiac arrest in COVID-19 patient during the follow-up, acute PE should be considered even if the patient is receiving anticoagulant therapy.

## Compliance with ethical standards

**Conflict of interest** There is no conflicts of interest in this report.

## References

1. Zuckier LS, Moadel RM, Haramati LB, Freeman LM (2020) Diagnostic evaluation of pulmonary embolism during the COVID-19 pandemic. *J Nucl Med*. <https://doi.org/10.2967/jnumed.120.245571> (**In press**)
2. Danzi GB, Loffi M, Galeazzi G, Gherbesi E (2020) Acute pulmonary embolism and COVID-19 pneumonia: a random association? *Eur Heart J*. <https://doi.org/10.1093/eurheartj/ehaa254>
3. Klok FA, Kruip MJHA, van der Meer NJM et al (2020) Incidence of thrombotic complications in critically ill ICU patients with COVID-19. *Thromb Res*. <https://doi.org/10.1016/j.thromres.2020.04.013> (**In press**)
4. Rotzinger DC, Beigelman-Aubry C, von Garnier C, Qanadli SD (2020) Pulmonary embolism in patients with COVID-19: time to change the paradigm of computed tomography. *Thromb Res*. <https://doi.org/10.1016/j.thromres.2020.04.011> (**In press**)
5. Xie Y, Wang X, Yang P, Zhang S (2020) COVID-19 complicated by acute pulmonary embolism. *Radiol Cardiothorac Imaging* 2(2):e200067
6. Chen N, Zhou M, Dong X et al (2020) Epidemiological and clinical characteristics of 99 cases of 2019 novel coronavirus pneumonia in Wuhan, China: a descriptive study. *Lancet* 395(10223):507–513
7. Xie X, Zhong Z, Zhao W, Zheng C, Wang F, Liu J (2020) Chest CT for typical 2019-nCoV pneumonia: relationship to negative RT-PCR testing. *Radiology*. <https://doi.org/10.1148/radiol.2020.00343> (**In press**)
8. Zhou F, Yu T, Du R et al (2020) Clinical course and risk factors for mortality of adult inpatients with COVID-19 in Wuhan, China: a retrospective cohort study. *Lancet* 395(10229):1054–1062
9. Ranucci M, Ballotta A, Di Dedda U et al (2020) The procoagulant pattern of patients with COVID-19 acute respiratory distress syndrome. *J Thromb Haemost*. <https://doi.org/10.1111/jth.14854> (**In press**)
10. Grillet F, Behr J, Calame P, Aubry S, Delabrousse E (2020) Acute pulmonary embolism associated with COVID-19 pneumonia detected by pulmonary CT angiography. *Radiology*. <https://doi.org/10.1148/radiol.2020201544> (**In press**)
11. Goeijenbier M, van Wissen M, van de Weg C et al (2012) Review: viral infections and mechanisms of thrombosis and bleeding. *J Med Virol* 84(10):1680–1696

**Publisher's Note** Springer Nature remains neutral with regard to jurisdictional claims in published maps and institutional affiliations.