



Since January 2020 Elsevier has created a COVID-19 resource centre with free information in English and Mandarin on the novel coronavirus COVID-19. The COVID-19 resource centre is hosted on Elsevier Connect, the company's public news and information website.

Elsevier hereby grants permission to make all its COVID-19-related research that is available on the COVID-19 resource centre - including this research content - immediately available in PubMed Central and other publicly funded repositories, such as the WHO COVID database with rights for unrestricted research re-use and analyses in any form or by any means with acknowledgement of the original source. These permissions are granted for free by Elsevier for as long as the COVID-19 resource centre remains active.

- 1 Scientific Advisory Group for Emergencies. SPI-M-O: consensus view on behavioural and social interventions. March 9, 2020. https://assets.publishing.service.gov.uk/government/uploads/system/uploads/attachment_data/file/874290/05-potential-impact-of-behavioural-social-interventions-on-an-epidemic-of-covid-19-in-uk-1.pdf (accessed April 24, 2020).
- 2 Black JRM, Bailey C, Swanton C. COVID-19: the case for health-care worker screening to prevent hospital transmission. *Lancet* 2020; **395**: 1418–20.
- 3 Task force COVID-19 del Dipartimento Malattie Infettive e Servizio di Informatica, Istituto Superiore di Sanità. Epidemia COVID-19, Aggiornamento nazionale: 23 aprile 2020. April 24, 2020. https://www.epicentro.iss.it/coronavirus/bollettino/Bollettino-sorveglianza-integrata-COVID-19_23-aprile-2020.pdf (accessed April 24, 2020).
- 4 Verbeek JH, Rajamaki B, Ijaz S, et al. Personal protective equipment for preventing highly infectious diseases due to exposure to contaminated body fluids in healthcare staff. *Cochrane Database Syst Rev* 2020; **4**: CD011621.
- 5 Lazzarini M, Barbi E, Apicella A, Marchetti F, Cardinale F, Trobia G. Delayed access or provision of care in Italy resulting from fear of COVID-19. *Lancet Child Adolesc Health* 2020; **4**: e10–e11.



Retinal findings in patients with COVID-19

Coronavirus disease 2019 (COVID-19) has been shown to affect different parts of the body, and ophthalmological changes have been associated with ocular external diseases such as conjunctivitis.¹

Optical coherence tomography (OCT) is a non-invasive imaging technique that is useful for demonstrating subclinical retinal changes in systemic conditions such as diabetes, Parkinson's disease, and Alzheimer's disease, as well as many viral infections.² We used OCT to evaluate patients infected by severe acute respiratory syndrome coronavirus 2 (SARS-CoV-2). The protocol was approved by INVIRARE Pesquisa Clínica Auditoria e Consultoria Institutional Review Board Ethics Committee.

Here we report retinal and OCT changes in 12 adults (six men and six women, aged 25–69 years), examined 11–33 days after COVID-19 symptom onset. All patients had fever, asthenia, and dyspnoea, and 11 patients also presented with anosmia. Two patients were admitted to hospital but none required intensive care. Nine patients were physicians, and two were health-care workers. All patients had normal blood parameters at the time of ophthalmological evaluation. Nine patients tested positive for SARS-CoV-2 by PCR (using nasal and oral swabs), and two patients tested positive in antibody tests for COVID-19. Two different OCT devices were used: DRI-OCT Triton Swept Source (Topcon,

Tokyo, Japan) and XR Avanti SD-OCT (Optovue, Fremont, CA, USA).

All patients showed hyper-reflective lesions at the level of ganglion cell and inner plexiform layers more prominently at the papillomacular bundle in both eyes (figure). Results of OCT-angiography and ganglionar cells complex analysis appeared normal. Furthermore, four patients presented subtle cotton wool spots and microhaemorrhages along the retinal arcade, observed on fundus examination, color fundus photography, and red-free imaging. Visual acuity and pupillary reflexes were normal in all eyes, and we detected no symptoms or signs of intraocular inflammation.

Although animal models suggest ocular lesions could include retinitis and optic neuritis,^{3,4} this is, to the best of our knowledge, the first report of retinal findings possibly associated with COVID-19 infection in humans. Ganglion cell and plexiform layer findings could be associated with CNS manifestations that have been described in animal studies⁴ and in COVID-19 neurological events.⁵

We declare no competing interests.

Paula M Marinho, Allexya A A Marcos, André C Romano, *Heloisa Nascimento, Rubens Belfort Jr
helomn@gmail.com

Instituto Paulista de Estudos e Pesquisas em Oftalmologia, São Paulo, Brazil; and Instituto da Visão, Federal University of São Paulo, São Paulo 04023-062, Brazil

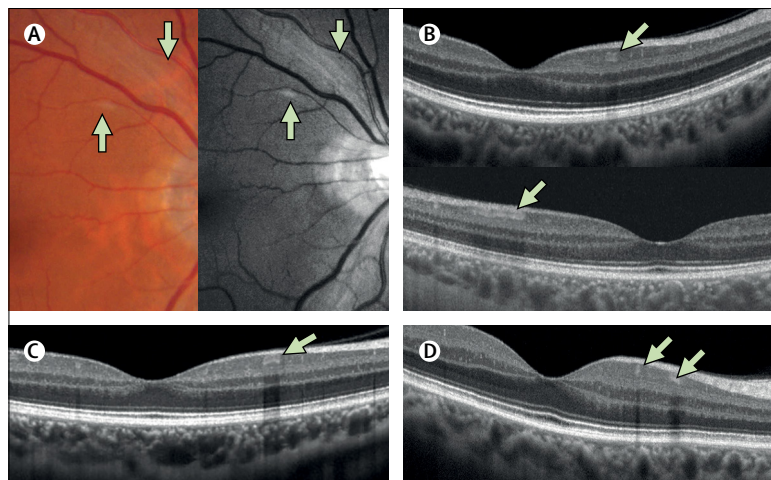


Figure: Retinal findings in four patients with COVID-19

Panels A–D represent four different patients. (A) Colour fundus photography and red-free imaging show a cotton wool spot at the superior retinal arcade with subtle microhaemorrhage. (B–D) Cross-sectional B-scan OCT in three patients shows hyper-reflective lesions at the level of the inner plexiform and ganglion cell layers, a feature observed in all patients. COVID-19=coronavirus disease 2019. OCT=optical coherence tomography.

- 1 Wu P, Duan F, Luo C, et al. Characteristics of ocular findings of patients with coronavirus disease 2019 (COVID-19) in Hubei province, China. *JAMA Ophthalmol* 2020; published online March 31. DOI:10.1001/jamaophthalmol.2020.1291.
- 2 Kurup SP, Khan S, Gill MK. Spectral domain optical coherence tomography in the evaluation and management of infectious retinitis. *Retina* 2014; **34**: 2233–41.
- 3 Seah I, Agrawal R. Can the coronavirus disease 2019 (COVID-19) affect the eyes? A review of coronaviruses and ocular implications in humans and animals. *Ocul Immunol Inflamm* 2020; **28**: 391–95.
- 4 Wang Y, Detrick B, Yu ZX, Zhang J, Chesky L, Hooks JJ. The role of apoptosis within the retina of coronavirus-infected mice. *Invest Ophthalmol Vis Sci* 2000; **41**(10): 3011–18.
- 5 Moriguchi T, Harii N, Goto J, et al. A first case of meningitis/encephalitis associated with SARS-coronavirus-2. *Int J Infect Dis* 2020; **94**: 55–58.