

Treatment of Proximal Femoral Fragility Fractures in Patients with COVID-19 During the SARS-CoV-2 Outbreak in Northern Italy

Francesco Catellani, MD, Andrea Coscione, MD, Riccardo D'Ambrosi, MD, Luca Usai, MD, Claudio Roscitano, MD, and Gennaro Fiorentino, MD

Investigation performed at Humanitas Gavazzeni, Bergamo, Italy

Background: From February 20 to April 2020, the coronavirus SARS (severe acute respiratory syndrome)-CoV-2 spread in northern Italy, drastically challenging the care capacities of the national health care system. Unprepared for this emergency, hospitals have quickly reformulated paths of assistance in an effort to guarantee treatment for infected patients. Orthopaedic departments have been focused on elderly traumatology, especially the treatment of femoral neck fractures in patients with coronavirus disease-2019 (COVID-19). The purpose of the present study was to evaluate the orthopaedic management strategy for femoral fragility fractures in COVID-19-positive patients with the hypothesis that operative treatment may contribute to the overall stability of the patient.

Methods: Sixteen patients affected by proximal femoral fracture and a recent history of fever, shortness of breath, and desaturation were admitted to the emergency room. Thoracic computed tomography (CT) and oropharyngeal swabs confirmed that they were positive for COVID-19, requiring hospitalization and prophylaxis with low-molecular-weight heparin.

Results: Three patients died before surgery because of severe respiratory insufficiency and multiple-organ-failure syndrome. Ten patients underwent surgery on the day after admission, whereas 3 patients had suspended their use of direct thrombin inhibitors and needed surgery to be delayed until the third day after admission. In all patients except 1, we noted an improvement in terms of O₂ saturation and assisted respiration. In 9 patients, hemodynamic and respiratory stability was observed at an average of 7 days postoperatively. Four patients who underwent surgical treatment died of respiratory failure on the first day after surgery (1 patient), the third day after surgery (2 patients), or the seventh day after surgery (1 patient).

Conclusions: We noted a stabilization of respiratory parameters in 12 COVID-19-positive patients who underwent surgery treatment of proximal femoral fractures. We believe that in elderly patients with COVID-19 who have proximal femoral fractures, surgery may contribute to the overall stability of the patient, seated mobilization, improvement in physiological ventilation, and general patient comfort in bed.

Level of Evidence: Prognostic Level IV. See Instructions for Authors for a complete description of levels of evidence.

From February to April 2020, the coronavirus SARS (severe acute respiratory syndrome)-CoV-2 spread rapidly in northern Italy, resulting in a severe emergency for the national health-care system. Despite the best efforts of the health-care network of Lombardy to manage a large number of patients, the rapid spread of infection quickly led to a saturation of intensive-care units throughout the region¹. As of April 1, 2020, >9,171 cases have been diagnosed in the city of Bergamo

alone². In our hospital, Humanitas Gavazzeni of Bergamo (Lombardy, Italy), both medical and surgical activities have been rapidly reformulated and are key to maximizing assistance to patients affected by viral interstitial pneumonia as a result of SARS-CoV-2. The orthopaedic unit has been focused on elderly traumatology, especially the treatment of femoral neck fractures in patients with coronavirus disease-2019 (COVID-19). The diagnostic and therapeutic paths to be taken

Disclosure: The authors indicated that no external funding was received for any aspect of this work. The **Disclosure of Potential Conflicts of Interest** forms are provided with the online version of the article (<http://links.lww.com/JBJS/F867>).

for these patients with fractures in the pandemic emergency setting have been organized as follows: surgical treatment within 24 hours in an attempt to stabilize the patient, reduction of blood loss, and improvement of respiratory function with the goal of minimizing the need for admittance to the intensive-care unit. The purpose of the present study was to evaluate the orthopaedic management strategy for femoral fragility fractures in COVID-19-positive patients with the hypothesis that surgery may contribute to the overall stability of the patient.

Materials and Methods

The present study was conducted according to the STROBE (Strengthening the Reporting of Observational Studies in Epidemiology) checklist for case series³. Informed consent was obtained from all individual participants who were included in the study. Nineteen patients with an average age of 85 years (range, 74 to 90 years) were admitted to the emergency orthopaedic room for the treatment of a proximal femoral fracture; the fractures were classified as OTA/AO⁴ type 31-A1 (8 fractures;

TABLE I Comorbidities, Type of Mechanical Ventilation, and O₂ Saturation in ER in Patients with COVID-19 and Proximal Femoral Fractures

Case	Sex, Age (yr)	Type of Fracture	Comorbidities	pO ₂ Saturation, Ventilation
1	F, 89	31-A1	Diabetes type II Hypertension Mitral insufficiency	96%, 4 L/min Venturi mask
2	F, 89	31-B2	Diabetes type II Hypertension Hypothyroidism Depressive anxiety syndrome	97%, 3 L/min Venturi mask
3	M, 84	31-B3	Hypertension Ischemic cardiopathy	90%, 15 L/min Venturi mask
4	M, 84	31-A1	Hypertension Hepatitis C	94%, 12 L/min Venturi mask
5	M, 90	31-A2	Hypertension Ischemic cardiopathy Chronic heart failure	90%, 6 L/min Venturi mask
6	F, 90	31-A2	Hypertension Previous cerebral ischemia Vascular dementia Chronic heart failure	90%, 10 L/min Venturi mask
7	M, 74	31-A2	Hypertension Obesity Depressive anxiety syndrome	94%, ambient air
8	M, 82	31-A1	Chronic kidney disease Benign prostatic hyperplasia	94%, ambient air
9	M, 86	31-A1	Hypertension Hypothyroidism	96%, 10 L/min Venturi mask
10	M, 88	31-B2	Diabetes type II Ischemic cardiopathy Benign prostatic hyperplasia	94%, 6 L/min Venturi mask
11	M, 85	31-A2	Ischemic cardiopathy Benign prostatic hyperplasia	96%, 10 L/min Venturi mask
12	M, 82	31-B2	Hypertension Previous cerebral ischemia	97%, 10 L/min Venturi mask
13	F, 85	31-B2	Depressive anxiety syndrome	94%, 6 L/min Venturi mask
14	F, 79	31-A1	Hypertension Hypothyroidism Obesity	96%, 10 L/min Venturi mask
15	F, 80	31-A1	Diabetes type II	97%, 10 L/min Venturi mask
16	M, 82	31-A2	Diabetes type II Chronic kidney disease	94%, 6 L/min Venturi mask

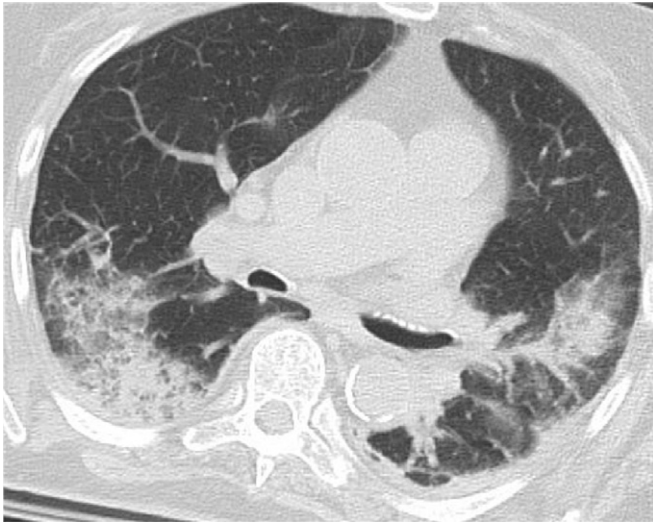

Fig. 1
Preoperative CT scan showing bilateral patchy consolidation and multiple ground-glass opacities.

42.1%), 31-A2 (5 fractures; 26.3%), 31-B2 (5 fractures; 26.3%), or 31-B33 (1 fracture; 5.3%)⁵. Three patients had no history of fever or respiratory symptoms and were excluded from the study. Sixteen patients had reported fever and shortness of breath 3 to 7 days before hospitalization, and all had accidentally fallen at home with no signs of head injury. All 16 patients presented with symptoms of fever and oxygen desaturation on ambient air; 14 of them needed respiratory support. Clinical features, comorbidities, and the type of assisted ventilation administered at the time of hospitalization for symptomatic patients are shown in [Table I](#). All patients were tested with thoracic computed tomography (CT) screening and oropharyngeal swabs ([Fig. 1](#)). The 3 asymptomatic patients with no signs of interstitial pneumonia on the CT scan and no requirement for ventilatory support were promptly transferred to a clinic close to our hospital (Humanitas Gavazzeni, Bergamo, Italy), to which patients are usually assigned for same-day procedures or relief hospitalization, to await the result of the swab test before treatment.

Sixteen patients with a positive result for interstitial pneumonia or related respiratory symptoms on CT scanning were hospitalized in our unit, and prophylaxis with low-molecular-weight heparin (LMWH), standard hydration, hydroxychloroquine (200 mg × 2 per day), and azithromycin (500 mg × 2 per day) was administered according to our hospital's protocol for patients with COVID-19. Three patients died on the wards, before surgery, as a result of severe respiratory insufficiency and multiple-organ-failure syndrome (MOFS). For the other 13 patients, as per the recommendations of the anesthesiologists and trauma team, the criteria for surgery were a peripheral oxygen saturation (pO₂) of >90% and a body temperature of <38°C. Ten patients were operatively treated on the first day, 12 to 24 hours after admission. Three patients had suspended their use of direct thrombin inhibitors and needed surgery to be delayed until the third day after recovery. Ac-

cording to our usual clinical practice, all patients received regional anesthesia, a combination of neuraxial anesthesia and a peripheral femoral block to avoid any type of sedation. We performed reduction and osteosynthesis with an intramedullary nail (Gamma3; Stryker) for lateral femoral neck fractures ([Fig. 2](#)) and with an endoprosthesis (Corail; DePuy Synthes) for medial femoral neck fractures, with an average operative time of 30 and 50 minutes, respectively. All patients were encouraged to assume the sitting position on a wheelchair or armchair on the first day postoperatively, and they were assisted by physiotherapists to improve physiological ventilation. Postoperative pain management was based on a non-opioid multimodal strategy, and blood loss was minimized by avoiding fluid overload and managing patients who had hemoglobin values of ≤9 g/dL with concentrated red blood-cell transfusion.

Results

All of the operatively managed patients had a positive result on oropharyngeal swabs. In all patients except 1 (Case 4), we noted improved O₂ saturation and assisted respiratory support. Detailed data on the outcomes on the first, third, and seventh days postoperatively are shown in [Table II](#). Nine patients demonstrated hemodynamic and respiratory stability at an average of 7 days (range, 5 to 10 days) postoperatively. Two patients (Cases 1 and 2) were dismissed to a rehabilitation

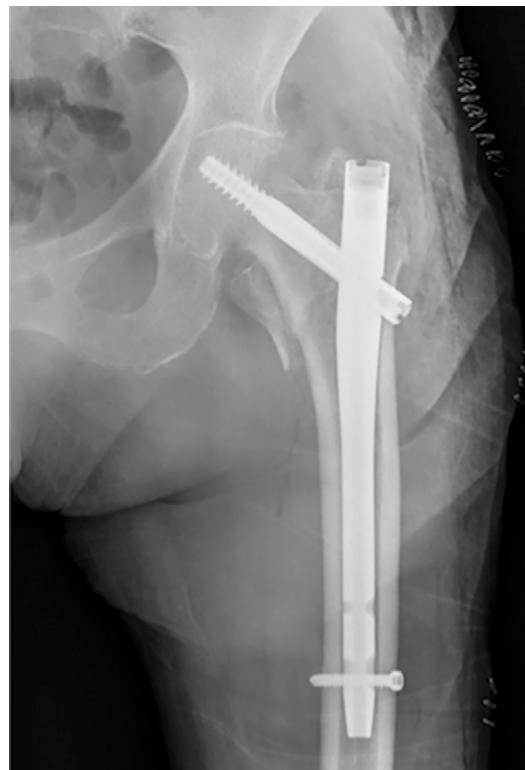


Fig. 2
Anteroposterior radiograph of the left hip, showing reduction and osteosynthesis with an intramedullary nail for the treatment of a lateral femoral neck fracture.

TABLE II O₂ Saturation and Assisted Respiratory Support Before Surgery and on First, Third, and Seventh Days After Surgery

Patient	Type of Surgery	pO ₂ Saturation, Ventilation		
		1st Postop. Day	3rd Postop. Day	7th Postop. Day
1	Intramedullary nail	93%, 2 L/min Venturi mask	98%, 2 L/min Venturi mask	98%, ambient air
2	Partial hip replacement	96%, 8 L/min Venturi mask	97%, 6 L/min Venturi mask	96%, 2 L/min Venturi mask
3	Partial hip replacement	88%, 15 L/min reservoir	92%, 5L Venturi mask	92%, 5 L/min Venturi mask
4	Intramedullary nail	92%, 12 L/min Venturi mask	92%, 12 L/min Venturi mask	90%, 12 L/min Venturi mask
5	Intramedullary nail	90%, 4 L/min Venturi mask	96%, 4 L/min Venturi mask	96%, 4 L/min Venturi mask
6	Intramedullary nail	96%, 4 L/min Venturi mask	96%, 4 L/min Venturi mask	96%, 4 L/min Venturi mask
7	Intramedullary nail	96%, 10 L/min Venturi mask	96%, 10 L/min Venturi mask	96%, 8 L/min Venturi mask
8	Intramedullary nail	90%, 15 L/min Venturi mask	Deceased	—
9	Partial hip replacement	Deceased	—	—
10	Partial hip replacement	90%, 15 L/min Venturi mask	88%, 15 L/min reservoir	Deceased
11	Partial hip replacement	94%, 6 L/min Venturi mask	94%, 2 L/min Venturi mask	94%, 2 L/min Venturi mask
12	Intramedullary nail	96%, 10 L/min Venturi mask	96%, 10 L/min Venturi mask	94%, 6 L/min Venturi mask
13	Intramedullary nail	88%, 15 L/min reservoir	Deceased	—

center to continue treatment for COVID-19. Four patients who underwent operative treatment died on the ward for respiratory failure on the first day after surgery (Case 9), the third day after surgery (Cases 8 and 13), or the seventh day after surgery (Case 10).

Discussion

The main results of the present study concern the substantial respiratory improvements in COVID-19-positive patients undergoing surgery for the treatment of proximal femoral fracture. In a pandemic emergency scenario, patient comorbidities and life expectancy play a key role in medical therapy decision-making. Femoral fracture in elderly patients is a life-threatening condition, and delayed surgical treatment may negatively affect the clinical course by prolonging pain and bed rest, increasing use of medication, and necessitating intensive care.

COVID-19 is a new pandemic disease that has spread rapidly in northern Italy since the first Italian case in the country was isolated on February 20, 2020⁶. According to data provided by the Minister of Public Health of Italy, at the end of March 2020, >80,000 people had tested positive for SARS-CoV-2 with >36,000 cases being in the region of Lombardy⁷. Our city of Bergamo and its metropolitan area still have the highest number of infections, with >9,000 cases. Rapid saturation of intensive-care units and the associated demand for additional space is still the most challenging problem faced by hospital coordination units. Since the first cases of SARS-CoV-2 appeared in the region of Lombardy, our hospital promptly restructured paths of assistance to maximize hospitalization for patients with COVID-19. Our Orthopaedic and Traumatology Unit has suspended elective surgery. In accordance with the anesthesiology team, we created 2 management pathways for trauma cases. All trauma patients in the orthopaedic emergency room (ER) were screened with thoracic CT scans and oropharyngeal swabs.

Patients with no recent history (>3 weeks) of fever or upper respiratory tract symptoms and CT scans that were not suggestive of interstitial pneumonia were transferred to a clinic close to our hospital (Humanitas Gavazzeni of Bergamo). We believe that locating a clean spot to hospitalize trauma patients who test negative for infection may help to reduce the risk of contamination. Instead of a hospital, we selected a clinic close to our center. Patients sent to this clinic were initially isolated in a room until the results of the oropharyngeal swab were obtained and confirmed that they were COVID-19-negative. We did not find any positive swabs in asymptomatic patients with negative thoracic CT scans, and all negative cases were treated urgently. Patients with COVID-19-suggestive symptoms (including fever, headache, rough cough, anosmia, ageusia, shortness of breath, dyspnea, and positive CT thoracic scan for interstitial pneumonia) were hospitalized in our unit.

At the time of hospitalization, 14 elderly patients with proximal femoral fractures presented with dyspnea and desaturation and needed ventilation support with a Venturi mask.

Italian epidemiological data collected by the Istituto Superiore di Sanità, the most important government agency on public health, revealed a mean age of 78 years (median, 79 years; range, 26 to 100 years) for patients dying from COVID-19 infection⁷. Of those patients, 24.5% had 2 comorbidities and 51.7% had ≥3 preexisting diseases⁸. Beyond ethical dilemmas, our main concern during our emergency was to reformulate pathways of assistance, ensuring “COVID-free” paths for elderly patients in need of orthopaedic surgery and establishing operability criteria for vulnerable elderly patients affected by COVID-19 (Fig. 3). The orthopaedic literature has confirmed that the advantages of early treatment of proximal femoral fractures in the elderly include promoting early movement, reducing bed rest, achieving better quality of life, controlling pain, and preventing blood loss and overall mortality⁹. However, severe pneumonia and respiratory

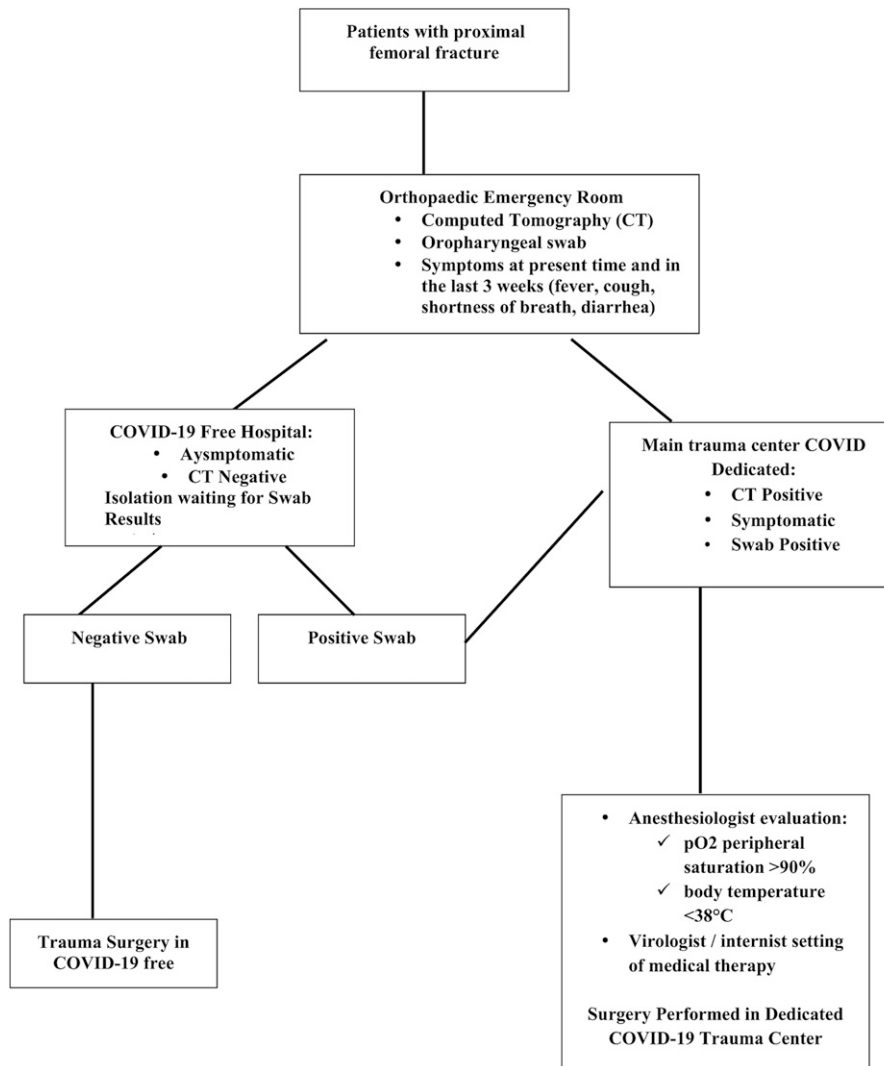


Fig. 3

Algorithm for the treatment of COVID-19-positive patients with a lateral femoral neck fracture.

insufficiency may represent a contraindication to anesthetic and surgical procedures because of the associated high risk¹⁰. We decided, as per recommendations of our anesthesiology team, to proceed with early surgery in patients with a pO_2 of $>90\%$ and a body temperature of $<38^\circ\text{C}$. Spinal anesthesia was used for all patients in order to avoid any type of sedation and was combined with a peripheral femoral nerve block to decrease opioid consumption and to achieve better pain management in the postoperative period^{11,12}.

Conclusions

We noted a stabilization of respiratory parameters in 12 COVID-19-positive patients who underwent surgery treatment of proximal femoral fractures. Despite early surgical treatment, 4 patients died. We believe that in elderly patients with COVID-19 who have proximal femoral fractures, surgery may contribute to the overall stability of the patient, seated mobilization, improvement in

physiological ventilation, and general patient comfort in bed. Nevertheless, elderly patients with COVID-19 with comorbidities and a proximal femoral fracture, especially those with a critical clinical presentation in the ER such as severe dyspnea ($pO_2 < 90\%$), hyperpyrexia ($>38^\circ\text{C}$), and signs of systemic organ dysfunction, are in a life-threatening condition and are not eligible for orthopaedic surgery. ■

NOTE: The authors thank Dr. G. Albano, Dr. E. Bombardieri, Dr. M. Arduini, Dr. A. Moretti, Dr. V.R. Perrino, Dr. F. De Amicis, Dr. S. Giambartino, Dr. R. Orlandi, and Dr. G. Cortina.

Francesco Catellani, MD¹
 Andrea Coscione, MD¹
 Riccardo D'Ambrosi, MD²
 Luca Usai, MD¹
 Claudio Roscitano, MD¹
 Gennaro Fiorentino, MD¹

¹Department of Orthopaedics and Traumatology, Humanitas Gavazzeni, Bergamo, Italy

²IRCCS Istituto Ortopedico Galeazzi, Milan, Italy

Email address for F. Catellani: francesco.catellani@gavazzeni.it

Email address for A. Coscione: andrea.coscione@gavazzeni.it

Email address for R. D'Ambrosi: riccardo.dambrosi@hotmail.it

Email address for L. Usai: luca.usai@gavazzeni.it

Email address for C. Roscitano: claudio.roscitano@gavazzeni.it

Email address for G. Fiorentino: gennaro.fiorentino@gavazzeni.it

ORCID iD for F. Catellani: [0000-0003-2247-7953](https://orcid.org/0000-0003-2247-7953)

ORCID iD for A. Coscione: [0000-0002-7701-4887](https://orcid.org/0000-0002-7701-4887)

ORCID iD for R. D'Ambrosi: [0000-0002-1216-792X](https://orcid.org/0000-0002-1216-792X)

ORCID iD for L. Usai: [0000-0003-2880-8960](https://orcid.org/0000-0003-2880-8960)

ORCID iD for C. Roscitano: [0000-0002-2349-2947](https://orcid.org/0000-0002-2349-2947)

ORCID iD for G. Fiorentino: [0000-0002-9528-491X](https://orcid.org/0000-0002-9528-491X)

References

- Livingston E, Bucher K. Coronavirus Disease 2019 (COVID-19) in Italy. *JAMA*. 2020 Mar 17. Epub 2020 Mar 17.
- Buoro S, Di Marco F, Rizzi M, Fabretti F, Lorini FL, Cesa S, Fagioli S. Papa Giovanni XXIII Bergamo Hospital at the time of the COVID-19 outbreak: letter from the warfront. *Int J Lab Hematol*. 2020 Mar 28. Epub 2020 Mar 28.
- von Elm E, Altman DG, Egger M, Pocock SJ, Gøtzsche PC, Vandenbroucke JP; STROBE Initiative. The Strengthening the Reporting of Observational Studies in Epidemiology (STROBE) statement: guidelines for reporting observational studies. *J Clin Epidemiol*. 2008 Apr;61(4):344-9.
- Meinberg EG, Agel J, Roberts CS, Karam MD, Kellam JF. Fracture and dislocation classification compendium-2018. *J Orthop Trauma*. 2018 Jan;32(Suppl 1):S1-170.
- Crijns TJ, Janssen SJ, Davis JT, Ring D, Sanchez HB; Science of Variation Group. Reliability of the classification of proximal femur fractures: Does clinical experience matter? *Injury*. 2018 Apr;49(4):819-23. Epub 2018 Mar 15.
- Albarelo F, Pianura E, Di Stefano F, Cristofaro M, Petrone A, Marchioni L, Palazzolo C, Schininà V, Nicastrì E, Petrosillo N, Campioni P, Eskild P, Zumla A, Ippolito G; COVID 19 INMI Study Group. 2019-novel Coronavirus severe adult respiratory distress syndrome in two cases in Italy: An uncommon radiological presentation. *Int J Infect Dis*. 2020 Feb 26;93:192-7. Epub 2020 Feb 26.
- Ministero della Salute. Nuovo coronavirus. Accessed 2020 Apr 14. <http://www.salute.gov.it/portale/home.html>
- Emami A, Javanmardi F, Pirbonyeh N, Akbari A. Prevalence of underlying diseases in hospitalized patients with COVID-19: a systematic review and meta-analysis. *Arch Acad Emerg Med*. 2020 Mar 24;8(1):e35.
- Merloz P. Optimization of perioperative management of proximal femoral fracture in the elderly. *Orthop Traumatol Surg Res*. 2018 Feb;104(1S):S25-30. Epub 2018 Jan 17.
- Desai V, Chan PH, Prentice HA, Zohman GL, Diekmann GR, Maletis GB, Fasig BH, Diaz D, Chung E, Qiu C. Is anesthesia technique associated with a higher risk of mortality or complications within 90 days of surgery for geriatric patients with hip fractures? *Clin Orthop Relat Res*. 2018 Jun;476(6):1178-88.
- Chen DX, Yang L, Ding L, Li SY, Qi YN, Li Q. Perioperative outcomes in geriatric patients undergoing hip fracture surgery with different anesthesia techniques: A systematic review and meta-analysis. *Medicine (Baltimore)*. 2019 Dec;98(49):e18220.
- Hsu YP, Hsu CW, Chu KCW, Huang WC, Bai CH, Huang CJ, Cheng SW, Chen JH, Chen C. Efficacy and safety of femoral nerve block for the positioning of femur fracture patients before a spinal block - A systematic review and meta-analysis. *PLoS One*. 2019 May 2;14(5):e0216337.