



Since January 2020 Elsevier has created a COVID-19 resource centre with free information in English and Mandarin on the novel coronavirus COVID-19. The COVID-19 resource centre is hosted on Elsevier Connect, the company's public news and information website.

Elsevier hereby grants permission to make all its COVID-19-related research that is available on the COVID-19 resource centre - including this research content - immediately available in PubMed Central and other publicly funded repositories, such as the WHO COVID database with rights for unrestricted research re-use and analyses in any form or by any means with acknowledgement of the original source. These permissions are granted for free by Elsevier for as long as the COVID-19 resource centre remains active.

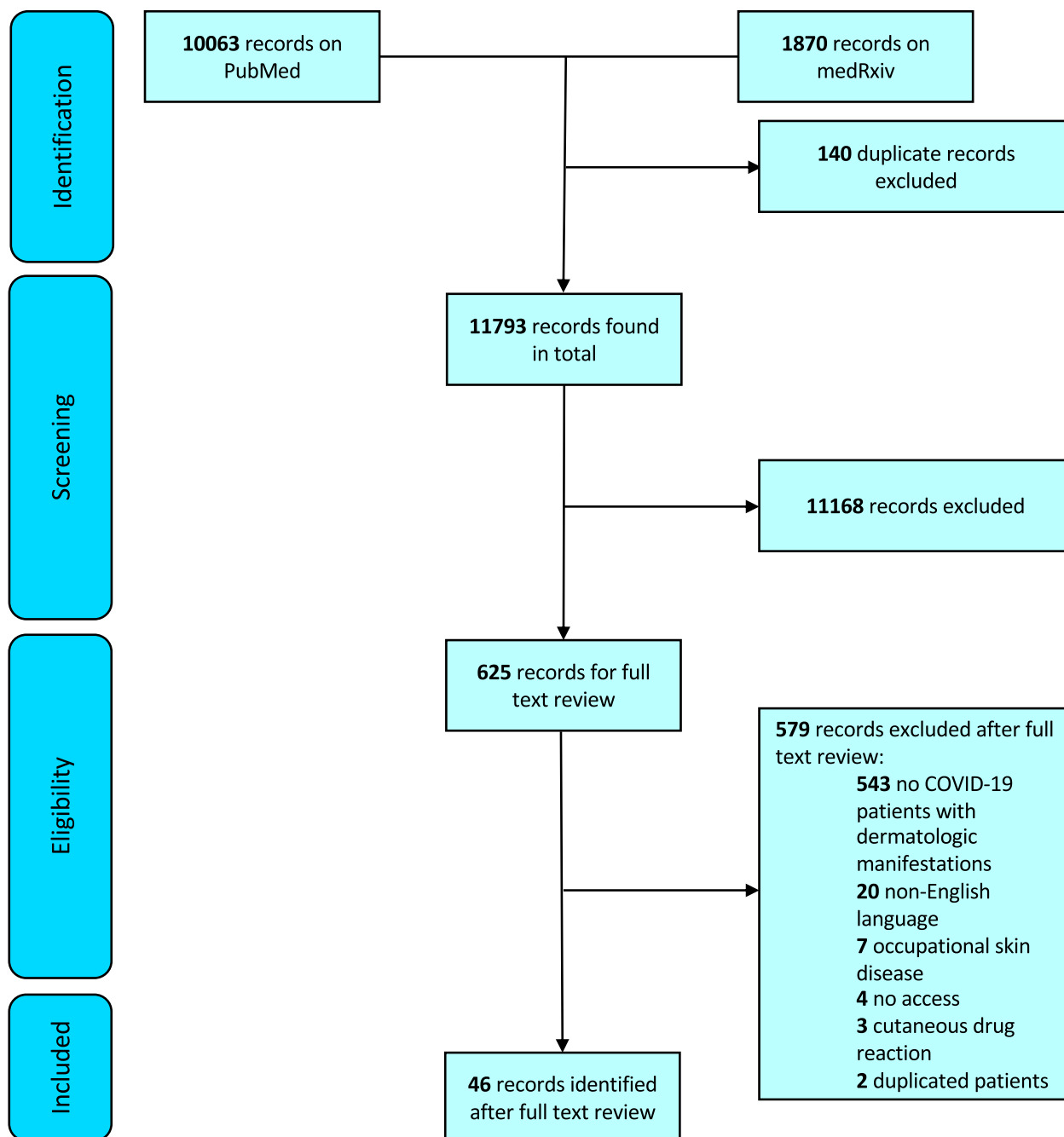
### Cutaneous manifestations of COVID-19: A preliminary review



*To the Editor:* First described in Wuhan, China, in late December 2019, coronavirus disease 2019 (COVID-19) has emerged as a global public health emergency. Countries across the world are rapidly reporting new infections and case fatalities.<sup>1</sup> As the COVID-19 pandemic rapidly evolves, understanding symptoms and clinical characteristics of affected persons is

essential. Patients with COVID-19 often present with fever, cough, and fatigue, although organ-specific symptoms have been reported.<sup>2,3</sup> The primary aim of this study was to systematically review published and preprint articles describing cutaneous symptoms associated with COVID-19 presentation.

Literature for this review was identified by searching the PubMed/MEDLINE database for published articles and the medRxiv database for preprint ones. Search terms “COVID-19,” “2019-nCoV,” and



**Fig 1.** PRISMA diagram for inclusion of records in systematic review.

**Table I.** Articles with more than 5 patients that described skin disease associated with presentation of COVID-19

Article	Year and location	Design	Population	Cases with cutaneous manifestations related to COVID-19 (%)	Cutaneous manifestations	Anatomic location of skin lesion	Notes
Bouaziz et al <sup>4</sup>	2020; France	Retrospective; multicenter	14	14 (100)	Inflammatory lesions (7), vascular lesions (7)		COVID-19 symptoms before skin lesion onset (14)
Duong et al <sup>5</sup>	2020; France	Prospective; crowdsourced social media	295	295 (100)	Chilblain-like lesion (146), other skin eruption (149)		
Fernandez-Nieto et al <sup>6</sup>	2020; Spain	Retrospective	346	132 (38.2)*	Chilblain-like lesion (95), erythema multiform-like lesion (37)	Chilblain-like lesions (hand [33], feet [73]), erythema multiform-like lesions (hand [8], feet [35])	Skin lesion at COVID-19 symptom onset (3), COVID-19 symptoms before skin lesion onset (16); no diagnosis of pneumonia (132/132)
Galván Casas et al <sup>7</sup>	2020; Spain	Prospective; crowdsourced survey	429	375 (87.4)	Maculopapular lesion (176), urticarial lesion (73), pseudo-chilblain lesion (71), vesicular lesion (34), livedoid/necrotic lesion (21)	Pseudo-chilblain (acral), vesicular (some trunk, limbs, diffuse), urticarial (mostly trunk or diffuse, few palmar), maculopapular (diffuse, few extremities), livedoid/necrotic (trunk, acral)	Itch (213), pain (32), burning (22)
Landa et al <sup>8</sup>	2020; Spain	Retrospective; multicenter	6	6 (100)	Chilblain-like lesions (6)	Foot (5), hand and foot (1)	Pain (3), itch (2); skin lesion led to diagnosis of pneumonia (1)
Marzano et al <sup>9</sup>	2020; Italy	Prospective; multicenter	22	22 (100)	Varicella-like exanthem (22)	Trunk (18), trunk and limbs (4)	Itch (8), pain (2), burning (2), itch/burning (1); COVID-19 symptoms usually before skin findings
Piccolo et al <sup>10</sup>	2020; Italy	Prospective; crowdsourced survey	63	63 (100)	Chilblain-like lesions ([63: 54 had photos]; 31/54 erythematous-edematous, 23/54 blistering)	Feet (86%), hands (6%), both (7%)	Pain (27%), itch (27%), pain/itch (21%); most patients had lesions at diagnosis
Recalcati <sup>11</sup>	2020; Italy	Prospective; single institution	88	18 (20.5)	Erythematous rash (14), widespread urticaria (3), chicken pox-like vesicles (1)	Trunk was most involved region	Cutaneous manifestations at onset (8); cutaneous manifestation developed after hospitalization (10)
Recalcati et al <sup>12</sup>	2020; Italy	Prospective; single institution	121	14 (11.6)	Erythematoviolaceous acral rash, digital welling	Feet (8), hands (4), hands and feet (2)	Itch (3); children (11), young adults (3)

COVID-19, Coronavirus disease 2019.

\*Nonacral skin lesions excluded from counts per article methods.

“coronavirus” were used to capture articles associated with COVID-19. All articles published between December 31, 2019, and May 3, 2020, were included. Screening and review of articles were conducted in accordance with the Preferred Reporting Items for Systematic and Meta-Analysis (Fig 1). Reviewers conducted full-text reviews for 625 articles to identify English-language studies describing cutaneous manifestations associated with COVID-19.

Forty-six articles met inclusion criteria, with a pooled total of 998 unique patients from 9 countries with skin manifestations related to COVID-19. A minority of articles contained more than 5 patients with cutaneous presentations of COVID-19 (Table D). The most commonly reported skin finding was chilblain-like lesions (402, 40.2%), followed by maculopapular lesions (227, 22.7%), urticarial lesions (89, 8.9%), vesicular lesions (64, 6.4%), livedoid and necrotic lesions (28, 2.8%), and other or nondescript rashes and skin lesions (192, 19.8%). Pain and burning was reported in at least 85 cases, and itch was reported in at least 256 cases. Reported prevalence of cutaneous manifestations of COVID-19 were variable. In non-case report studies that contained patients with and without skin findings related to COVID-19, skin disease prevalence varied from 0.19% to 20.45%.<sup>11,13</sup>

Higher reporting of chilblain-like lesions may have occurred because some studies focused on this finding or anatomic region specifically.<sup>6,8,10</sup> Disparities among reported cutaneous manifestation prevalence suggest a potential underreporting of skin diseases associated with COVID-19. This is concerning because cutaneous manifestations can be the presenting complaint of COVID-19 patients amid mild or absent more common COVID-19 symptoms.<sup>6,8,14</sup> For instance, the presenting symptom for one patient with COVID-19 was urticaria; the patient sought care twice before being identified as having coronavirus.<sup>14</sup> Misclassification of COVID-19 patients as not having the disease can hinder community transmission control efforts because of potential asymptomatic transmission.<sup>15</sup> Future studies should include race/ethnicity information because some skin findings may be more common in skin of color. Limitations of this systematic review include few large or comprehensive studies, and that some articles included patients with suspected but unverified COVID-19.

The American Academy of Dermatology has recently launched a much-needed COVID-19 registry to track cutaneous manifestations associated with disease presentation.<sup>16,17</sup> Careful documentation and robust reporting of cutaneous manifestations associated with COVID-19 are needed to augment

our understanding of disease presentation and epidemiology.<sup>17</sup> Improved understanding of cutaneous manifestations, comorbidities, and treatments will enhance our ability to provide better clinical care and support our colleagues on the front lines of this rapidly evolving pandemic.

Justin L. Jia, BS,<sup>a</sup> Marija Kamceva, BS,<sup>a</sup> Saieesh A. Rao, BS,<sup>b</sup> and Eleni Linos, MD, DrPH<sup>a†</sup>

From the Department of Dermatology, Stanford University School of Medicine, California<sup>a</sup>; and Pritzker School of Medicine, University of Chicago, Illinois.<sup>b</sup>

Funding sources: None.

Conflicts of interest: None disclosed.

Reprints not available from the authors.

Correspondence to: Eleni Linos, MD, DrPH, 269 Campus Dr, Stanford Department of Dermatology, Stanford, CA 94305

E-mail: [linos@stanford.edu](mailto:linos@stanford.edu)

#### REFERENCES

1. World Health Organization. Coronavirus disease 2019 (COVID-19) situation report - 112. [https://www.who.int/docs/default-source/coronaviruse/situation-reports/20200511-covid-19-sitrep-112.pdf?sfvrsn=813f2669\\_2](https://www.who.int/docs/default-source/coronaviruse/situation-reports/20200511-covid-19-sitrep-112.pdf?sfvrsn=813f2669_2). Accessed May 4, 2020.
2. Guan W, Ni Z, Hu Y, et al. Clinical characteristics of coronavirus disease 2019 in China. *N Engl J Med*. 2020;382(18):1708-1720.
3. Gu J, Han B, Wang J. COVID-19: gastrointestinal manifestations and potential fecal-oral transmission. *Gastroenterology*. 2020;158(6):1518-1519.
4. Bouaziz JD, Duong T, Jachiet M, et al. Vascular skin symptoms in COVID-19: a French observational study. *J Eur Acad Dermatol Venereol*. 2020. <https://doi.org/10.1111/jdv.16544>.
5. Duong TA, Velter C, Rybojad M, et al. Did Whatsapp® reveal a new cutaneous COVID-19 manifestation? *J Eur Acad Dermatol Venereol*. 2020. <https://doi.org/10.1111/jdv.16534>.
6. Fernandez-Nieto D, Jimenez-Cauhe J, Suarez-Valle A, et al. Characterization of acute acro-ischemic lesions in non-hospitalized patients: a case series of 132 patients during the COVID-19 outbreak. *J Am Acad Dermatol*. 2020;83(1):e61-e63.
7. Galván Casas C, Català A, Carretero Hernández G, et al. Classification of the cutaneous manifestations of COVID-19: a rapid prospective nationwide consensus study in Spain with 375 cases. *Br J Dermatol*. 2020. <https://doi.org/10.1111/bjd.19163>.
8. Landa N, Mendieta-Eckert M, Fonda-Pascual P, Aguirre T. Chilblain-like lesions on feet and hands during the COVID-19 pandemic. *Int J Dermatol*. 2020;59:739-743.
9. Marzano AV, Genovese G, Fabbrocini G, et al. Varicella-like exanthem as a specific COVID-19-associated skin manifestation: multicenter case series of 22 patients. *J Am Acad Dermatol*. 2020;83(1):280-285.
10. Piccolo V, Neri I, Filippeschi C, et al. Chilblain-like lesions during COVID-19 epidemic: a preliminary study on 63 patients.

- J Eur Acad Dermatol Venereol.* 2020. <https://doi.org/10.1111/jdv.16526>.
11. Recalcati S. Cutaneous manifestations in COVID-19: a first perspective. *J Eur Acad Dermatol Venereol.* 2020;34:e212-e213.
  12. Recalcati S, Barbagallo T, Frasin LA, et al. Acral cutaneous lesions in the time of COVID-19. *J Eur Acad Dermatol Venereol.* 2020. <https://doi.org/10.1111/jdv.16533>.
  13. Guan W, Liang W, Zhao Y, et al. Comorbidity and its impact on 1590 patients with Covid-19 in China: A Nationwide Analysis. *Eur Respir J.* 2020. <https://doi.org/10.1183/13993003.00547-2020>.
  14. Lu S, Lin J, Zhang Z, et al. Alert for non-respiratory symptoms of coronavirus disease 2019 (COVID-19) patients in epidemic period: a case report of familial cluster with three asymptomatic COVID-19 patients. *J Med Virol.* <https://doi.org/10.1002/jmv.25776>.
  15. Bai Y, Yao L, Wei T, et al. Presumed asymptomatic carrier transmission of COVID-19. *JAMA.* 2020;323:1406-1407.
  16. Freeman EE, McMahon DE, Fitzgerald ME, et al. The AAD COVID-19 Registry: crowdsourcing dermatology in the age of COVID-19. *J Am Acad Dermatol.* 2020;83(2):509-510.
  17. Grant-Kels JM, Sloan B, Kantor J, Elston DM. Letter from the editors: big data and cutaneous manifestations of COVID-19. *J Am Acad Dermatol.* 2020;83(2):365-366.

<https://doi.org/10.1016/j.jaad.2020.05.059>