

Chest Imaging Appearance of COVID-19 Infection

Weifang Kong, MD • Prachi P. Agarwal, MBBS, MD, MS

From the Department of Radiology, Sichuan Academy of Medical Science, Sichuan Provincial People's Hospital, Chengdu, China (W.K.); and Division of Cardiothoracic Radiology, Department of Radiology, University of Michigan Health System, 1500 E Medical Center Dr, CVC 5383, Ann Arbor, MI 48109 (P.P.A.). Received February 5, 2020; accepted February 10. Address correspondence to P.P.A. (e-mail: prachia@med.umich.edu).

See editorial by Kay and Abbara in this issue.

Conflicts of interest are listed at the end of this article.

Radiology: Cardiothoracic Imaging 2020; 2(1):e200028 • <https://doi.org/10.1148/ryct.2020200028> • Content code: **GH**

Coronavirus disease 2019 (COVID-19) (previously known as novel coronavirus [2019-nCoV]), first reported in China, has now been declared a global health emergency by the World Health Organization. As confirmed cases are being reported in several countries from all over the world, it becomes important for all radiologists to be aware of the imaging spectrum of the disease and contribute to effective surveillance and response measures.

© RSNA, 2020

The outbreak of coronavirus disease 2019 (COVID-19) was first reported from Wuhan, China, in December 2019, and has quickly spread to other regions in China, as well as other countries in the last few weeks. The estimates continue to be updated, and on February 4, 2020, the number of confirmed cases reached 20 630 globally in 24 countries, most occurring in China (20,471 cases) (1). The clinical severity ranges from asymptomatic individuals to death. So far, 425 deaths have been reported in China and one death in the Philippines (1). In the United States, there are confirmed cases in five states (CA, WA, AZ, IL, MA), and as many as 36 states have people under investigation (2).

While literature on clinical presentation (3) and modes of transmission have started to emerge, there is a paucity of reports describing radiologic appearance of this entity (4,5). As the disease has evolved into a global concern, it becomes important for radiologists to be familiar with the imaging appearance and have a basic understanding about the clinical course and current magnitude of the COVID-19 infection.

We present a series of three confirmed cases of COVID-19 infection from China.

Case 1

A 59-year-old woman from Sichuan Provincial People's Hospital presented with fever and chills. She had no history of sick contacts in the family, but she referred a plane ride 5 days prior to onset of symptoms from London, England, to Chengdu, China. Chest radiograph (Fig 1a) and chest CT (Fig 1b,1c) at presentation showed patchy right lower lobe ground-glass opacities. Follow-up chest CT images (Fig 1d, 1e) obtained 2 days later showed improvement of the ground-glass opacities, with development of subpleural curvilinear lines.

Case 2

A 62-year-old woman from Sichuan Provincial People's Hospital presented 7 days after contact with a relative

who had recently traveled from Wuhan, China. Symptoms at presentation included paroxysmal cough, productive sputum, and fever. Chest CT showed a small solitary nodular ground-glass opacity in the left upper lobe (Fig 2a), which progressed in 3 days to multifocal nodular and peripheral ground-glass opacities involving both upper lobes (Fig 2b, 2c). Another follow-up CT performed 5 days from presentation showed a new tiny cavity (Fig 2d) and increasing component of consolidation (Fig 2e) admixed with ground-glass opacities and crazy-paving pattern.

Case 3

A 45-year-old woman from Sichuan Provincial People's Hospital presented with fever, cough, and chest pain after recent travel to Japan. Her CT at presentation showed extensive peripheral predominant ground-glass opacities in bilateral upper lobes (Fig 3a). A reversed halo sign was also noted in the left upper lobe (Fig 3a). Follow-up CT 2 days later showed organizing changes with decrease in extent of the ground-glass opacities and increasing parenchymal density (Fig 3b, 3c).

Discussion

Infectious Agent

Coronaviruses are named for their crownlike appearance due to surface spikes and are categorized into four major groups (alpha, beta, gamma, and delta). Most coronaviruses affect animals, although they are zoonotic and can be transmitted between animals and humans. To date, seven types of human coronaviruses are known. These typically lead to a mild illness, but in the last 2 decades, two human coronaviruses have been known to cause severe respiratory illnesses and even death. These viruses included severe acute respiratory syndrome coronavirus (SARS-CoV) that was first recognized in China in 2002 (transmitted from civet cats) and the Middle East respiratory syndrome coronavirus (MERS-CoV) which

Key Points

- It is important for all radiologists to be aware of the imaging spectrum of the disease and contribute to effective surveillance and response measures.
- Ground-glass opacities and consolidation can demonstrate an organizing pneumonia pattern.
- Cavitation can also occur in areas of airspace disease.

was first reported in 2012 in Saudi Arabia (transmitted from dromedary camels). COVID-19 is the latest addition to this group and has been reported to affect patients who worked at or lived around the local Huanan seafood wholesale market; where live animals on sale indicate possible animal-to-human transmission (2). More recently, cases have been confirmed with no exposure to animal markets, indicating person-to-person spread of virus.

Clinical Course and Management

The most common clinical manifestations include fever (83%), cough (82%), and shortness of breath (31%) (3). The combination of clinical findings and epidemiologic risk factors that fulfill Centers for Disease Control and Prevention criteria for a person under investigation are provided in the Table (2). These cases need to be notified to the institutional infection control as well as local or state health authorities.

For laboratory confirmed cases, no specific treatment is available, and care is primarily supportive with appropriate precautions to stop person-to-person transmission. The severity of disease can range from asymptomatic and mild cases to acute respiratory distress syndrome and death (3).

Imaging Findings

Reports on imaging findings are now emerging (4,5). The largest case series of chest imaging in 21 patients described multi-

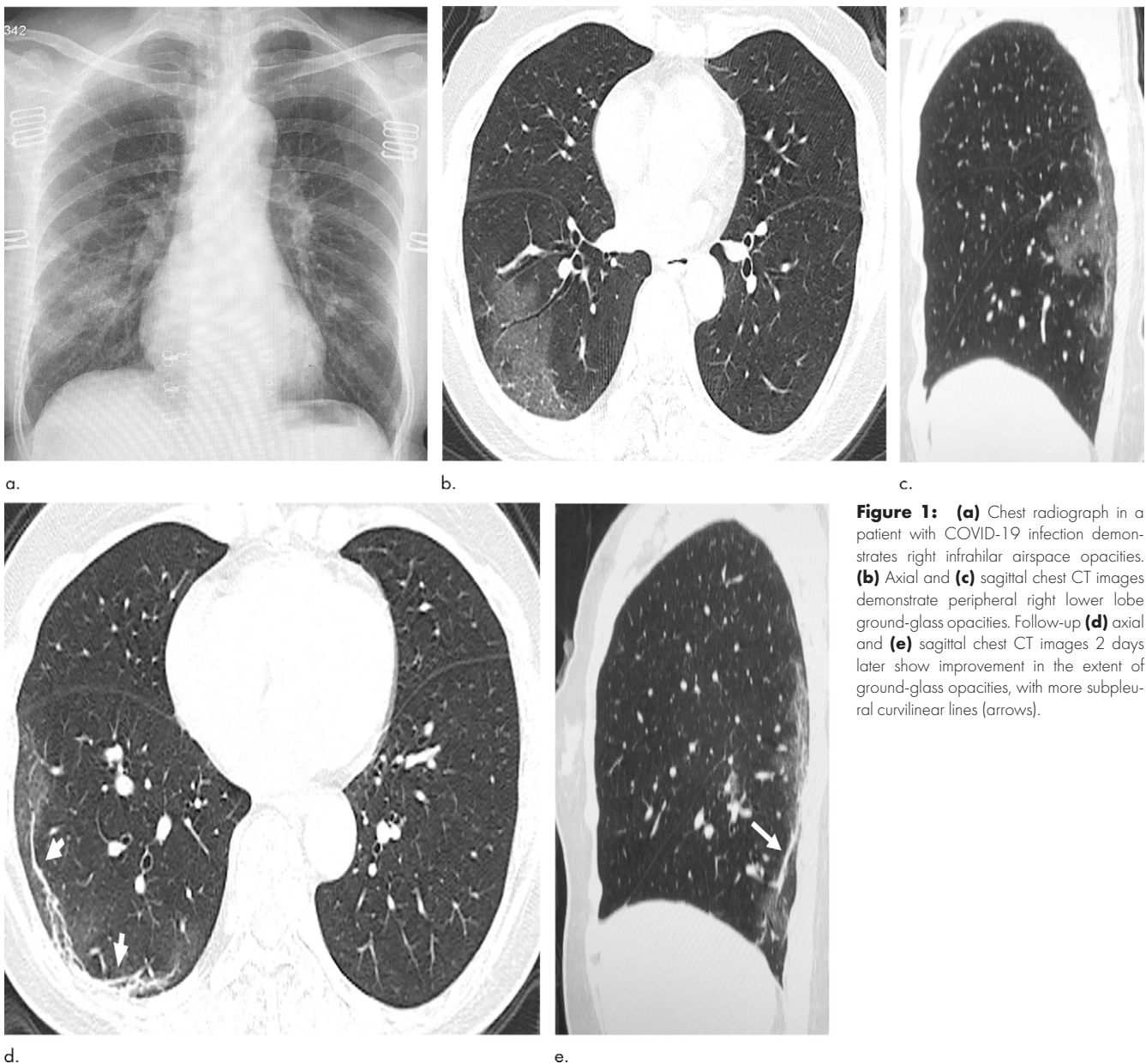


Figure 1: (a) Chest radiograph in a patient with COVID-19 infection demonstrates right infrahilar airspace opacities. (b) Axial and (c) sagittal chest CT images demonstrate peripheral right lower lobe ground-glass opacities. Follow-up (d) axial and (e) sagittal chest CT images 2 days later show improvement in the extent of ground-glass opacities, with more subpleural curvilinear lines (arrows).

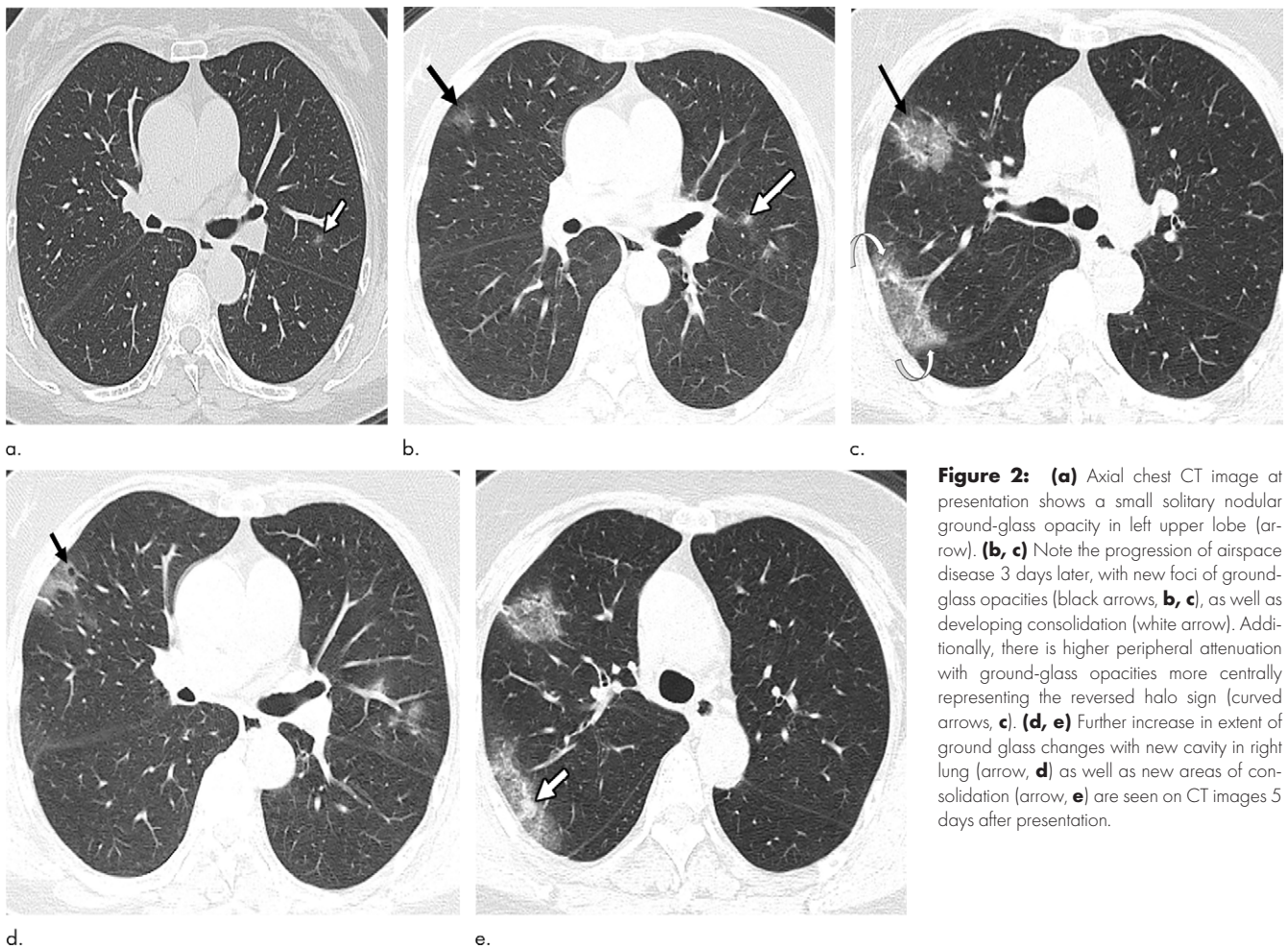


Figure 2: (a) Axial chest CT image at presentation shows a small solitary nodular ground-glass opacity in left upper lobe (arrow). (b, c) Note the progression of airspace disease 3 days later, with new foci of ground-glass opacities (black arrows, b, c), as well as developing consolidation (white arrow). Additionally, there is higher peripheral attenuation with ground-glass opacities more centrally representing the reversed halo sign (curved arrows, c). (d, e) Further increase in extent of ground glass changes with new cavity in right lung (arrow, d) as well as new areas of consolidation (arrow, e) are seen on CT images 5 days after presentation.

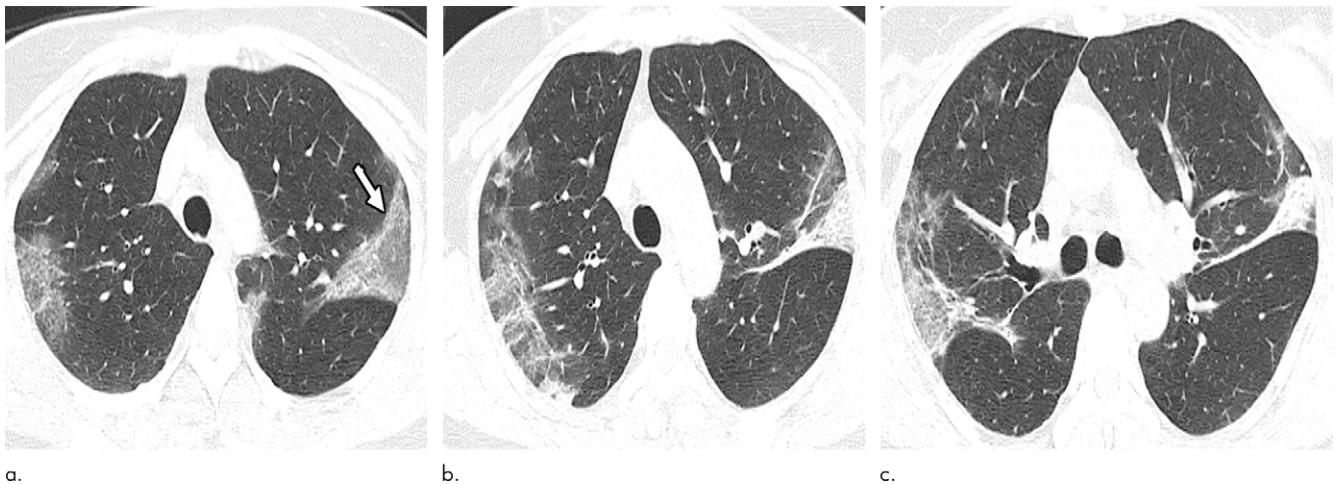


Figure 3: (a) Note the peripheral predominant airspace opacities with a reversed halo pattern in the left upper lobe (arrow). (b, c) Organizing changes with increasing attenuation are noted on follow-up CT images.

lobar involvement and rounded as well as peripheral airspace opacities (4). The opacities most commonly were described to have ground glass (57%) and mixed attenuation (29%), similar to our presented cases. Given the predominance of ground-glass opacities, chest CT is more sensitive, and findings can be missed on radiographs. Notably, confirmed cases can have

normal chest CT as well (4). Imaging findings share several similarities with previously described findings in SARS-CoV and MERS-CoV (5–7).

In our case series, we noted an organizing pattern characterized by peripheral predominant distribution and reversed halo or atoll sign in some cases. Additionally, one of our cases also

developed a small focus of cavitation, which has not been previously described (4); although one of the 99 patients in the study by Chen et al had a pneumothorax (3). As larger case series become available, new imaging patterns may emerge.

In conclusion, imaging findings can be nonspecific for a particular infection, but in the context of a travel history or exposure, the presence of nodular and peripheral ground-glass opacities should alert the radiologists to this possibility.

Disclosures of Conflicts of Interest: W.K. disclosed no relevant relationships. P.P.A. disclosed no relevant relationships.

References

1. World Health Organization. Novel Coronavirus (2019-nCoV) Situation report-15. https://www.who.int/docs/default-source/coronaviruse/situation-reports/20200204-sitrep-15-ncov.pdf?sfvrsn=88fe8ad6_2. Accessed February 2020.
2. 2019 Novel Coronavirus (2019-nCoV) in the U.S. Centers for Disease Control and Prevention <https://www.cdc.gov/coronavirus/2019-ncov/cases-in-us.html>. Accessed February 2020.
3. Chen N, Zhou M, Dong X, et al. Epidemiological and clinical characteristics of 99 cases of 2019 novel coronavirus pneumonia in Wuhan, China: a descriptive study. *Lancet* 2020 Jan 30 [Epub ahead of print].
4. Lei J, Li J, Li X, Qi X. CT Imaging of the 2019 Novel Coronavirus (2019-nCoV) Pneumonia. *Radiology* 2020 Jan 31:200236 [Epub ahead of print].
5. Chung M, Bernheim A, Mei X, et al. CT Imaging Features of 2019 Novel Coronavirus (2019-nCoV). *Radiology* 2020 Feb 4:200230 [Epub ahead of print].
6. Kanne JP. Chest CT Findings in 2019 Novel Coronavirus (2019-nCoV) Infections from Wuhan, China: Key Points for the Radiologist. *Radiology* 2020 Feb 4:200241 [Epub ahead of print].
7. Müller NL, Ooi GC, Khong PL, Zhou LJ, Tsang KW, Nicolaou S. High-resolution CT findings of severe acute respiratory syndrome at presentation and after admission. *AJR Am J Roentgenol* 2004;182(1):39–44.

Criteria for Person under Investigation

Subjective or confirmed fever or signs/symptoms of lower respiratory illness

AND

EITHER close contact with a patient with laboratory-confirmed COVID-19 within 14 days of symptom onset

OR A history of travel from Hubei Province, China within 14 days of symptom onset

Subjective or confirmed fever or signs/symptoms of lower respiratory illness requiring hospitalization

AND

A history of travel from mainland China within 14 days of symptom onset