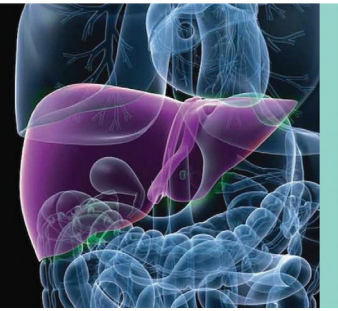

SARS-CoV-2 and the Liver: Considerations in Hepatitis B and Hepatitis C Infections

K. Rajender Reddy, M.D. 

Globally, the severe acute respiratory syndrome coronavirus 2 (SARS-CoV-2) virus has variably affected the various parts of the world and has been a major cause for significant morbidity and mortality. Coronavirus disease 2019 (COVID-19), the disease caused by SARS-CoV-2, has been reported to have multiple clinical manifestations, although primarily they have been pulmonary manifestations. Hepatic manifestations have variably been present in up to 50% of infected individuals.^{1,2} The spectrum ranges from asymptomatic abnormalities in hepatic biochemical tests to the rare case of acute liver failure. The cause for hepatic manifestations is unclear at this stage and may be caused by a variety of reasons, such as a manifestation of a systemic illness, ischemic liver injury, immune-mediated liver injury, drug-induced liver injury, or a direct cytopathic effect of the virus.³⁻⁶ Not uncommonly, patients have concomitant infections, such as human immunodeficiency virus (HIV), hepatitis B virus (HBV), and hepatitis C virus

(HCV) infection, either alone or as co-infections, and the impact of the pandemic and SARS-CoV-2 on these infections and associated liver diseases is unknown. Further, the implications in people who inject drugs (PWIDs) may be unique. Observations continue to evolve regarding hepatic manifestations and challenges with COVID-19 and the liver, and as such, expectations and guidance on issues relevant to the multiple viral infections are important.

A meta-analysis, primarily involving reports from China, noted a 3% prevalence rate of underlying chronic liver disease in those with COVID-19, although it does not provide specific data on the prevalence of HBV and HCV infections.⁷ HBV and HCV are chronic infections that are frequently encountered worldwide, and the former is particularly common in China, where the first cases of COVID-19 were reported. Thus, there has been concern about the impact of SARS-CoV-2 infection on the course of HCV and

Abbreviations: ART, antiretroviral therapy; COVID-19, coronavirus disease 2019; DDI, drug-drug interaction; HBV, hepatitis B virus; HCV, hepatitis C virus; HIV, human immunodeficiency virus; ICU, intensive care unit; PWID, person who injects drugs; SARS-CoV-2, severe acute respiratory syndrome coronavirus 2.

From the Division of Gastroenterology and Hepatology, University of Pennsylvania, Perelman School of Medicine, Philadelphia, PA.

Potential conflict of interest: K.R.R. consults for Mallinckrodt, Merck, and Gilead, and his institution receives grants from Mallinckrodt, Gilead, Merck, HepQuant, Exact Sciences, BMS, Sequana, and Intercept.

Received May 1, 2020; accepted May 8, 2020.

View this article online at wileyonlinelibrary.com

© 2020 by the American Association for the Study of Liver Diseases

TABLE 1. SARS-COV-2/COVID-19 AND HEPATITIS B AND C

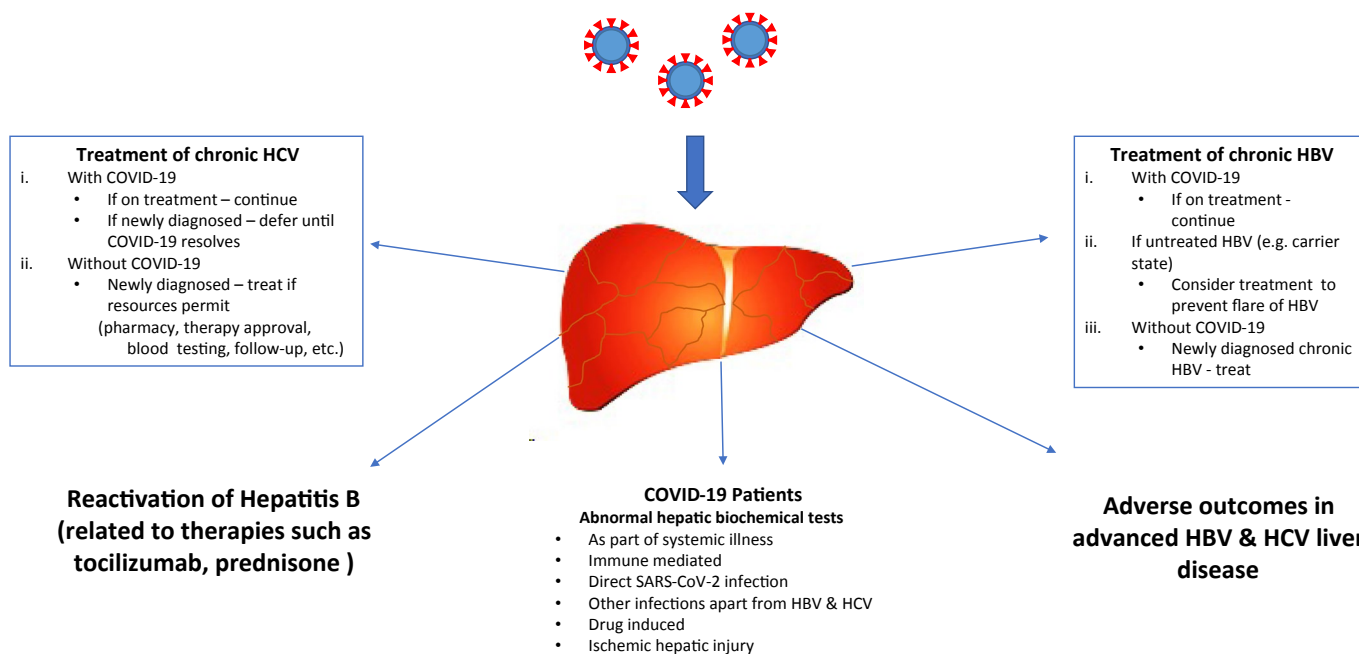
Authors	Infection	Study Characteristics	Observations	Unique Considerations
Chen et al. ¹⁰	HBV	Retrospective analysis of hospitalized patients with COVID-19 in a single center in Wuhan, China	<ul style="list-style-type: none"> 12.2% (15/123) of patients were HBV infected A higher percentage with comorbid HBV developed a severe outcome (46.7% versus 24.1%) Total bilirubin level was higher in patients with comorbid HBV Patients with comorbid HBV had a higher mortality rate (13.3% versus 2.8%) 6.5% (2/31) of patients were HBV infected Association found between HBV infection and prolonged SARS-CoV-2 clearance 0.1% (8/5700) of patients were HBV infected 	<ul style="list-style-type: none"> Heterogeneous data on the prevalence of HBV infection in COVID-19 and on the interaction between HBV and COVID-19 Risk for HBV reactivation with some experimental COVID-19 therapies (tocilizumab, corticosteroids) Some investigational COVID-19 medications may be contraindicated in HBV-infected patients with decompensated cirrhosis
Zha et al. ¹¹		Observational study investigating the efficacy of corticosteroid treatment in hospitalized patients with COVID-19 in China	<ul style="list-style-type: none"> 2.1% (23/1099) of patients were HBV infected HBV-infected individuals represented 2.4% of nonsevere cases and 0.6% of severe cases <0.1% (3/5700) of patients were HCV infected 	<ul style="list-style-type: none"> Low incidence of HCV in hospitalized patients with COVID-19 No studies to date have reported the effect of HCV on COVID-19 outcomes Some investigational COVID-19 medications may be contraindicated in patients with HCV-related decompensated cirrhosis
Richardson et al. ⁸		Case series of hospitalized patients with COVID-19 in 12 hospitals in the New York City metro area	<ul style="list-style-type: none"> 0.92% of patients were HIV infected 0 died, 2 were admitted to the ICU (1 remained in the ICU at publication) 	<ul style="list-style-type: none"> Low incidence of hospitalized patients with COVID-19 and HIV
Guan et al. ⁹		Retrospective multicenter analysis of hospitalized patients with COVID-19 in China	<ul style="list-style-type: none"> ART regimens adapted to protease inhibitor in all patients 	<ul style="list-style-type: none"> ART may need to be adapted Although no studies have investigated COVID-19 in PWIDs, that population has risk factors for severe disease course, including weaker immune system, cardiac pathology, and renal insufficiency
Richardson et al. ⁸	HCV	Case series of hospitalized patients with COVID-19 in 12 hospitals in the New York City metro area	<ul style="list-style-type: none"> Comorbid diabetes and heavy smoker Antibody/antigen test gave positive HIV results (no previous ART) Nonsevere COVID-19 pneumonia Had ongoing ART HIV treatment (tenofovir, lamivudine, efavirenz) 	<ul style="list-style-type: none"> Heterogeneous data on time to antibody response and time to clinical improvement
Chen et al. ¹⁵		Case study in China in a HIV/SARS-CoV-2 co-infected patient	<ul style="list-style-type: none"> After COVID-19 diagnosis, given lopinavir/ritonavir Shortened disease course and quick resolution of pulmonary lesions 	
Chen et al. ¹⁵		Case study in China in a patient co-infected with HIV/SARS-CoV-2	<ul style="list-style-type: none"> In limited cases, study highlighted that COVID-19 infection improved in cases using regular ART with viral suppression 	
Aydin et al. ¹⁴		Case series of 4 patients co-infected with HIV/SARS-CoV-2 in Turkey	<ul style="list-style-type: none"> One patient died of sudden cardiac arrest Resolution of radiological findings and time to antibody formation were similar to HIV-uninfected patients with COVID-19 	
Zhao et al. ¹⁶	HCV+HIV	Case study in China of HIV/HCV co-infected patient with COVID-19	<ul style="list-style-type: none"> Negative SARS-CoV-2 RNA test and delayed antibody response Was taking anti-HIV ART 	

HBV. Thus far, fortunately, COVID-19 has been reported infrequently in those with HBV and HCV infections in the United States. In a large series of 5700 hospitalized patients with COVID-19 in the northeastern United States, HBV and HCV infections were encountered in 0.1% and <0.1% of patients, respectively⁸ (Table 1). In contrast, a large hospitalized patient series from Wuhan, China, observed that 2.1% (23/1099) of patients were HBV infected and represented 2.4% of nonsevere cases and 0.6% of severe cases.⁹ A single-center retrospective study from China noted that 12.2% (15/123) of patients with COVID-19 had HBV infection, and a higher percentage with comorbid HBV, relative to HBV-negative patients, had higher total bilirubin levels, developed a more severe course (46.7% versus 24.1%), and had a higher mortality rate (13.3% versus 2.8%).¹⁰ Zha et al.¹¹ noted a background HBV prevalence rate of 6.5% (2/31) while reporting on their experience with the use of corticosteroids in COVID-19; further, they observed delayed SARS-CoV-2 clearance in those with HBV infection.

There have been only sparse reports, involving case series, on the impact of COVID-19 in patients with HIV infection.¹²⁻¹⁵ A Barcelona experience with hospitalized patients with COVID-19 noted that HIV-infected individuals accounted for close to only 1% of these patients. Those with HIV infection were younger than 50 years, they

self-identified as men who have sex with men, their clinical picture was similar to those who were HIV negative/COVID-19 positive, and there was no mortality reported.¹² There have been only sporadic reports of COVID-19 in those co-infected with HIV and HCV, and unique considerations in either HIV mono-infected or HIV/HCV co-infected patients would be of adjustments to antiretroviral therapy (ART) based on potential drug-drug interactions (DDIs); further, antibody response to SARS-CoV-2 may be impaired or delayed in this population.¹⁶ Thus far, studies have not been presented on the frequency and impact of COVID-19 in PWIDs, a population vulnerable to the consequences of SARS-CoV-2 due to several comorbidities, such as other viral infections, heart disease, and renal disease.¹⁷

Unique considerations in those with HBV and HCV infections involve possible precautions for HBV and HCV therapies in those with or without SARS-CoV-2 infection and COVID-19 manifestations of abnormalities in hepatic biochemical tests (Fig. 1). As per the American Association for the Study of Liver Diseases guidance document, it would seem reasonable to initiate HCV therapy, in newly diagnosed cases of HCV, in those without a SARS-CoV-2 infection if adequate resources are available and if those resources have not been deployed for COVID-19 activities (e.g., pharmacy services, personnel for approval of therapy, blood testing service, follow-up facilities through



*SARS-COV-2 refers to the viral strain *severe acute respiratory syndrome coronavirus 2*; COVID-19 refers to the respiratory illness caused by SARS-COV-2

FIG 1 SARS-CoV-2 and COVID-19: considerations in HBV and HCV. COVID-19 refers to the respiratory illness caused by SARS-CoV-2.

telemedicine or face-to-face).¹⁸ In those with COVID-19 in the background of a recently diagnosed HCV infection, it seems reasonable to defer HCV therapy until a time when COVID-19 has cleared, whereas already initiated therapy can be continued while monitoring for DDIs. In those patients with HBV, it is important to be aware of the risk for HBV reactivation related to medications, such as tocilizumab and corticosteroids, used in the context of COVID-19. Reactivation of HBV following the use of tocilizumab and prednisone has been described, and thus prophylaxis against HBV reactivation should be a consideration.^{19,20} In addition, chronic HBV therapy where indicated as per guidelines²¹ can be initiated in those with newly diagnosed HBV and continued if receiving therapy, regardless of COVID-19. Last but not least, caution needs to be exercised in initiating COVID-19-related therapy in those with advanced liver disease; thus, established guidelines on such use need to be followed to minimize the risk for hepatic decompensation, although the risk/benefit of an intervention is likely to weigh in heavily in dealing with the highly lethal condition of COVID-19.

CORRESPONDENCE

K. Rajender Reddy, Division of Gastroenterology and Hepatology, Perelman School of Medicine, University of Pennsylvania. 2 Dulles, 3400 Spruce Street, HUP, Philadelphia, PA 19104, USA. E-mail: reddy@penmedicine.upenn.edu

REFERENCES

- Bangash MN, Patel J, Parekh D. COVID-19 and the liver: little cause for concern. *Lancet Gastroenterol Hepatol*. Available at: [https://doi.org/10.1016/S2468-1253\(20\)30084-4](https://doi.org/10.1016/S2468-1253(20)30084-4)
- Zhang C, Shi L, Wang F-S. Liver injury in COVID-19: management and challenges. *Lancet Gastroenterol Hepatol* 2020;5:428-430.
- Sun J, Aghemo A, Forner A, et al. COVID-19 and liver disease. *Liver Int*. Available at: <https://doi.org/10.1111/liv.14470>
- Xu Z, Shi L, Wang Y, et al. Pathological findings of COVID-19 associated with acute respiratory distress syndrome. *Lancet Respir Med* 2020;8:420-422.
- Liu J, Li S, Liu J, et al. Longitudinal characteristics of lymphocyte responses and cytokine profiles in the peripheral blood of SARS-CoV-2 infected patients. *eBiomedicine* 2020;55:102763.
- Chai X, Hu L, Zhang Y, et al. Specific ACE2 expression in cholangiocytes may cause liver damage after 2019-nCoV infection. *bioRxiv*. Available at: <https://doi.org/10.1101/2020.02.03.931766>
- Mantovani A, Beatrice G, Dalbeni A. Coronavirus disease 2019 and prevalence of chronic liver disease: a meta-analysis. *Liver Int*. Available at: <https://doi.org/10.1111/liv.14465>
- Richardson S, Hirsch JS, Narasimhan M, et al. Presenting characteristics, comorbidities, and outcomes among 5700 patients hospitalized with COVID-19 in the New York City area. *JAMA*. Available at: <https://www.doi.org/10.1001/jama.2020.6775>
- Guan WJ, Ni ZY, Hu Y, et al. Clinical characteristics of coronavirus disease 2019 in China. *N Engl J Med* 2020;382:1708-1720.
- Chen X, Jiang Q, Ma Z, et al. Clinical characteristics of hospitalized patients with SARS-CoV-2 and hepatitis B virus co-infection. *medRxiv*. Available at: <https://doi.org/10.1101/2020.03.23.20040733>
- Zha L, Li S, Pan L, et al. Corticosteroid treatment of patients with coronavirus disease 2019 (COVID-19). *Med J Australia*. Available at: <https://doi.org/10.5694/mja2.50577>
- Blanco JL, Ambrosioni J, Garcia F, et al. COVID-19 in patients with HIV: clinical case series. *Lancet HIV* 2020;7:e314-e316.
- Zhu F, Cao Y, Xu S, et al. Co-infection of SARS-CoV-2 and HIV in a patient in Wuhan city, China. *J Med Virol* 2020;92:529-530.
- Altuntas Aydin O, Kumbasar Karaosmanoglu H, Kart Yasar K. HIV/SARS-CoV-2 co-infected patients in Istanbul, Turkey. *J Med Virol*. Available at: <https://doi.org/10.1002/jmv.25955>
- Chen J, Cheng X, Wang R, et al. Computed tomography imaging of an HIV-infected patient with coronavirus disease 2019 (COVID-19). *J Med Virol*. Available at: <https://doi.org/10.1002/jmv.25879>
- Zhao J, Liao X, Wang H, et al. Early virus clearance and delayed antibody response in a case of COVID-19 with a history of co-infection with HIV-1 and HCV. *Clin Infect Dis*. Available at: <https://doi.org/10.1093/cid/ciaa408>
- Farhoudian A, Baldacchino AM, Clark N, et al. COVID-19 and substance use disorders: recommendations to a comprehensive healthcare response. An International Society of Addiction Medicine (ISAM) Practice and Policy Interest Group position paper. *Basic Clin Neurosci*. Available at: <https://www.doi.org/10.32598/bcn.11.covid.19.1>
- Fix OK, Hameed B, Fontana RJ, et al. Clinical best practice advice for hepatology and liver transplant providers during the COVID-19 pandemic: AASLD expert panel consensus statement. *Hepatology*. Available at: <https://doi.org/10.1002/hep.31281>
- Reddy KR, Beavers KL, Hammond SP, et al. American Gastroenterological Association Institute guideline on the prevention and treatment of hepatitis B virus reactivation during immunosuppressive drug therapy. *Gastroenterology* 2015;148:215-219.
- Chen L-F, Mo Y-Q, Jing J, et al. Short-course tocilizumab increases risk of hepatitis B virus reactivation in patients with rheumatoid arthritis: a prospective clinical observation. *Int J Rheum Dis* 2017;20:859-869.
- Terrault NA, Lok AS, McMahon BJ, et al. Update on prevention, diagnosis, and treatment of chronic hepatitis B: AASLD 2018 hepatitis B guidance. *Hepatology* 2018;67:1560-1599.