



Since January 2020 Elsevier has created a COVID-19 resource centre with free information in English and Mandarin on the novel coronavirus COVID-19. The COVID-19 resource centre is hosted on Elsevier Connect, the company's public news and information website.

Elsevier hereby grants permission to make all its COVID-19-related research that is available on the COVID-19 resource centre - including this research content - immediately available in PubMed Central and other publicly funded repositories, such as the WHO COVID database with rights for unrestricted research re-use and analyses in any form or by any means with acknowledgement of the original source. These permissions are granted for free by Elsevier for as long as the COVID-19 resource centre remains active.

**Echocardiographic Features of COVID-19 Illness and Association with Cardiac Biomarkers**



**To the Editors:**

Recent studies have reported cardiac abnormalities in patients with coronavirus disease 2019 (COVID-19).<sup>1</sup> Echocardiography remains an essential diagnostic tool in this climate, particularly with emerging data that myocardial injury appears to be associated with adverse prognosis<sup>2</sup> and that echocardiography may add important prognostic information.<sup>3,4</sup> We present our institutional experience with echocardiography in the current pandemic with the goal of assessing the prevalence and reversibility of left ventricular (LV) dysfunction.

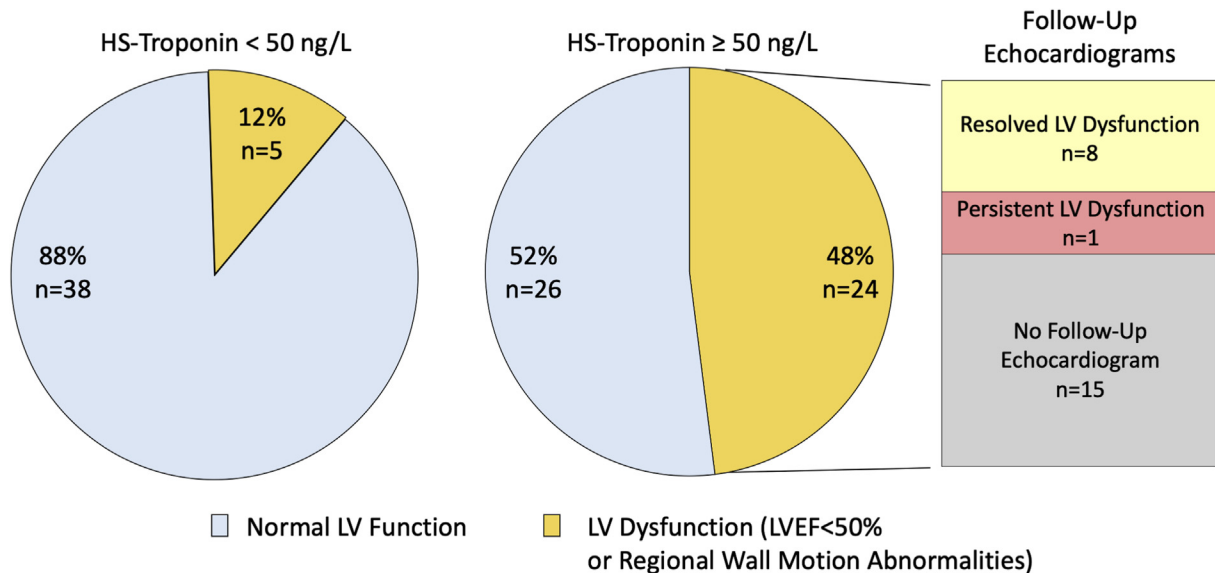
Requests for echocardiograms in patients with COVID-19 were screened for appropriateness by echocardiography laboratory physicians; all performed studies ( $n = 125$  patients over 49 days, all hospitalized) were included in this report. Studies were performed on standard (EPIQ; Philips Healthcare, Andover, MA), laptop-sized (Vivid I; GE Healthcare, Milwaukee, WI), or tablet (Lumify; Philips Healthcare) machines. Echocardiographic measurements were made according to society guidelines.<sup>5</sup> Echocardiographic data were extracted from the clinical report and clinical information from the medical record.

Average patient age was  $64 \pm 15$  years, and 50 (40%) were women. The most common comorbidities included hypertension (60%), diabetes mellitus (41%), and obesity (50%; mean body mass index,  $31 \pm 7$  kg/m<sup>2</sup>). The majority ( $n = 85$  [69%]) of patients were in the intensive care unit at time of echocardiography, with 75 (88%) requiring mechanical ventilation and 60 (71%) vasopressor support.

LV ejection fraction was normal or hyperdynamic in 97 patients (78%) and impaired (<50%) in 28 (22%). Wall motion abnormalities, evaluable in 115 patients, were present in 16 (14%). Combined, a total of 33 patients (26%) had LV dysfunction, defined as either LV ejection fraction < 50% or segmental wall motion abnormalities; LV dysfunction was preexisting in six of 33. Follow-up echocardiograms were obtained after a median of 14 days in 11 of 33 patients with LV dysfunction (including one patient with prior LV dysfunction), revealing resolution of abnormalities (improvement in wall motion abnormalities and/or LV ejection fraction normalization) without procedural intervention in nine of 11 (82%) and persistent LV dysfunction in two of 11 (18%), including the aforementioned individual with preexisting LV dysfunction.

Among patients with cardiac biomarkers measured within 3 days before echocardiography ( $n = 93$ ), median peak high-sensitivity troponin was 51 ng/L (interquartile range, 24–139 ng/L) and median peak N-terminal pro-brain natriuretic peptide 1,643 pg/mL (interquartile range, 374–8,278 pg/mL). In the subset ( $n = 50$ ) with troponin  $\geq 50$  ng/L, 24 patients (48%) had evidence of LV dysfunction (Figure 1). Nine patients in this group (LV dysfunction and troponin  $\geq 50$  ng/L) underwent follow-up echocardiography, with resolution of LV abnormalities in eight (with the sole exception noted above with previously documented LV dysfunction). Median peak troponin was 613 ng/L (interquartile range, 251–1,585 ng/L) among those with LV recovery, compared with 280 ng/L in the patient without improvement.

We describe here our initial experience with echocardiography during the COVID-19 pandemic and highlight two important findings. First, LV dysfunction was common, affecting 26% overall and 48% of those with troponin  $\geq 50$  ng/L. Second, although follow-up



**Figure 1** LV dysfunction in patients with COVID-19 stratified by high-sensitivity (HS) troponin level. The presence or absence of LV dysfunction, defined by LV ejection fraction (LVEF) < 50% or regional wall motion abnormalities, is shown in the group of patients with high-sensitivity troponin < 50 ng/L (left;  $n = 43$ ) and  $\geq 50$  ng/L (right;  $n = 50$ ). Of the 24 patients with some form of LV dysfunction in the elevated troponin group, nine underwent follow-up echocardiography, with the majority ( $n = 8$ ) demonstrating resolution of LV abnormalities with the exception of one patient with previously documented LV dysfunction.

Conflicts of interest: None.  
 Alan S. Pearlman, MD, FASE, served as guest editor for this report.

echocardiography was limited, resolution of LV dysfunction was noted in nine of 11 cases and in eight of nine with troponin  $\geq$  50 ng/L. We acknowledge that the screening process for echocardiography requests creates important selection bias, and we do not suggest that these findings apply across all patients with COVID-19. Prospective studies, and correlation of echocardiographic data with disease severity, biomarkers, and clinical outcomes, will be required to understand the range of cardiovascular involvement in COVID-19.

Timothy W. Churchill, MD  
Philippe B. Bertrand, MD, PhD  
Samuel Bernard, MD  
Mayooran Namasivayam, MBBS, PhD  
Jessica Churchill, RDCS  
Daniela Crousillat, MD  
Esther F. Davis, MBBS, DPhil  
Judy Hung, MD  
Michael H. Picard, MD  
Echocardiography Laboratory  
Massachusetts General Hospital  
Boston, Massachusetts

## REFERENCES

1. Clerkin KJ, Fried JA, Raikhelkar J, Sayer C, Griffin JM, Masoumi A, et al. Coronavirus disease 2019 (COVID-19) and cardiovascular disease. *Circulation* 2020;141:1648-55.
2. Shi S, Qin M, Shen B, Cai Y, Liu T, Yang F, et al. Association of cardiac injury with mortality in hospitalized patients with COVID-19 in Wuhan, China. *JAMA Cardiol*. Available at: <https://jamanetwork.com/journals/jamacardiology/fullarticle/2763524>. Accessed May 28, 2020.
3. Li Y, Li H, Zhu S, Xie Y, Wang B, He L, et al. Prognostic value of right ventricular longitudinal strain in patients with COVID-19. *JACC Cardiovasc Imaging*. Available at: <https://imaging.onlinejacc.org/content/early/2020/04/20/j.jcmg.2020.04.014>. Accessed May 28, 2020.
4. Argulian E, Sud K, Vogel B, Bohra C, Garg VP, Talebi S, et al. Right ventricular dilation in hospitalized patients with COVID-19 infection. *JACC Cardiovasc Imaging*. Available at: <https://imaging.onlinejacc.org/content/early/2020/05/13/j.jcmg.2020.05.010?download=true>. Accessed May 28, 2020.
5. Lang RM, Badano LP, Mor-Avi V, Afilalo J, Armstrong A, Ernande L, et al. Recommendations for cardiac chamber quantification by echocardiography in adults: an update from the American Society of Echocardiography and the European Association of Cardiovascular Imaging. *J Am Soc Echocardiogr* 2015;28:1-39.e14.

<https://doi.org/10.1016/j.echo.2020.05.028>

## Echocardiographic Findings in Patients with COVID-19 with Significant Myocardial Injury



### To the Editor:

Myocardial injury has been commonly described in patients with coronavirus disease 2019 (COVID-19) and has been suggested to have prognostic significance.<sup>1</sup> Multiple possible mechanisms have been suggested.<sup>2,3</sup> Echocardiography allows the noninvasive assessment of biventricular function and can provide important insights into possible mechanisms.<sup>4</sup> We aimed to describe echocardiographic

findings in hospitalized patients with COVID-19 with significant myocardial injury.

In this retrospective study, we enrolled consecutive hospitalized patients with COVID-19 who underwent clinically indicated transthoracic echocardiography at Mount Sinai Morningside Hospital.<sup>5</sup> Echocardiography was performed following a time-efficient protocol with appropriate protective gear. Portable ultrasound machines were used: CX50 (Philips Medical Systems, Andover, MA) and VividS70 (GE Healthcare, Little Chalfont, United Kingdom). Echocardiographic studies were interpreted by experienced, board-certified echocardiography attending physicians. Significant myocardial injury was defined as a peak cardiac troponin I level  $>1$  ng/mL (reference  $<0.01$  ng/mL). Continuous variables are presented as mean  $\pm$  SD or as median (interquartile range [IQR]) and categorical variables as proportions.

A total of 24 patients with significant myocardial injury were identified among 110 patients who underwent echocardiography (five were excluded because of poor study quality). The mean age was  $64.5 \pm 13.8$  years, and 11 patients (46%) were women. Ten patients (42%) were mechanically ventilated at the time of echocardiography. Five patients (21%) had known histories of coronary artery disease. The median troponin level was 5.0 ng/mL (IQR, 1.8–14.0 ng/mL). Among these 24 patients, three had electrocardiographic findings consistent with ST-segment elevation myocardial infarction, and one patient had diffuse ST-segment elevation consistent with pericarditis. The remaining did not have any distinct clinical or electrocardiographic characteristic to suggest the underlying mechanism of injury. Left ventricular (LV) dysfunction, defined as regional and/or global systolic dysfunction, was present in 13 patients (54%). Eleven (46%) had regional wall motion abnormalities (median troponin level, 12.4 ng/mL; IQR, 5.8–27.0 ng/mL): three confirming aforementioned ST-segment elevation myocardial infarction, two with preexisting wall motion abnormalities, and six with presumed new abnormalities (three of these six had previous echocardiograms depicting preserved LV function). Among patients with new wall motion abnormalities, wall motion pattern was confined to a single coronary territory in four patients and more than single territory in one patient; one patient had a typical wall motion pattern suggestive of stress cardiomyopathy. Only two patients (8%) had diffuse LV hypokinesis. Other findings included isolated right ventricular dysfunction in four patients (17%), with a median troponin level of 1.5 ng/mL (IQR, 1.3–3.1 ng/mL). The presence of more than trivial pericardial effusion was noted in eight patients (33%). Importantly, five patients (21%) had no significant echocardiographic findings with preserved biventricular function and no pericardial effusion (Figure 1). The median troponin level in these patients was 2.1 ng/mL (IQR, 1.3–4.3 ng/mL). Among patients without significant myocardial injury ( $n = 81$ ), 15 patients (19%) had isolated regional or global LV dysfunction, 19 patients (24%) had isolated right ventricular dysfunction, and five patients (6%) had biventricular dysfunction.

This was a small, retrospective, single-center study. The population was selected from the total number of patients with COVID-19 admitted to our hospital during this time period. Confirmatory testing including advanced cardiac imaging and coronary angiography was lacking in most patients.

In conclusion, among hospitalized patients with COVID-19 and significant myocardial injury, 37% had isolated LV dysfunction, 17% had isolated right ventricular dysfunction, 17% had biventricular dysfunction, and remaining 29% had preserved biventricular function. Regional LV dysfunction appears to be the most common