



Since January 2020 Elsevier has created a COVID-19 resource centre with free information in English and Mandarin on the novel coronavirus COVID-19. The COVID-19 resource centre is hosted on Elsevier Connect, the company's public news and information website.

Elsevier hereby grants permission to make all its COVID-19-related research that is available on the COVID-19 resource centre - including this research content - immediately available in PubMed Central and other publicly funded repositories, such as the WHO COVID database with rights for unrestricted research re-use and analyses in any form or by any means with acknowledgement of the original source. These permissions are granted for free by Elsevier for as long as the COVID-19 resource centre remains active.



# How to Perform a Nasopharyngeal Swab – An Otolaryngology Perspective

Adam C. Kaufman, MD, PhD,<sup>a</sup> Ryan Brewster, BA,<sup>b</sup> Karthik Rajasekaran, MD<sup>a</sup>

<sup>a</sup>Department of Otorhinolaryngology, Head and Neck Surgery, University of Pennsylvania, Perelman School of Medicine, Philadelphia;

<sup>b</sup>Stanford University School of Medicine, Stanford University, Stanford, Calif.

## INTRODUCTION

SARS-CoV-2, the virus that causes COVID-19, represents a once-in-a-lifetime global threat. In a matter of 4 months, the virus spread from Wuhan, China, to nearly 95% of all countries in the world. As of mid-April, there were more than 2 million confirmed cases with more than 134,000 deaths worldwide.<sup>1</sup> This exponential growth is partially explained by its transmission during the presymptomatic or mildly symptomatic phases of illness.<sup>2</sup>

This rapid unknown transmission threatens to overwhelm health systems as has already been seen in locations within China, Italy, Spain, and the United States. Currently there are no known effective pharmaceutical treatments for the illness, forcing hospitals to rely on routine supportive care. Governments across the globe have instituted a number of limitations on movement and encouraged social distancing to help limit spread.

Countries, after crossing peak transmission of the virus, are beginning to slowly lift these restrictions; however, to do this safely there is a need for widespread testing. Unfortunately, the dominant method of testing, reverse transcription polymerase chain reaction (RT-PCR), has been shown to only have specificity as low as 70%.<sup>3</sup> Additionally, the anatomical site with the highest yield for testing is the nasopharynx.<sup>4</sup>

Swabbing the nasopharynx is performed by palpation alone without any direct visualization. From the perspective of otolaryngologists who perform multiple nasal endoscopies on a daily basis, we would contend this is the most challenging aspect of the procedure. Incorrectly performing a nasopharyngeal swab can lead to an increased false-

negative rate, giving patients and clinicians a false sense of security.

In light of the of the tremendous number of health care workers who will need to be involved in the deployment of these tests and their varying degrees of familiarity with nasal anatomy, we believe it is useful to provide guidelines on proper technique and common challenges. To our knowledge, none of the current articles or videos describe the actual landmarks, measurements, challenges, and solutions in passing the swab through the nasal cavity to reach the nasopharynx. Our objective is to not only provide this information but also a unique graphic handout, which can serve as a quick reference when performing the procedure.

## PROCEDURE

### 1. Preparation and Equipment

- a. The health care worker will need to wear personal protective equipment (PPE), which includes a gown, nonsterile gloves, a mask, and a face shield. The specifics of the PPE is often dictated by the health care worker's institution.
- b. All necessary supplies should then be assembled prior to beginning the procedure. The swab container should be opened carefully to avoid contamination.
- c. The patient should be comfortably seated with the head supported by a headrest. Because there can be some minor discomfort during the procedure, this ensures the patient does not pull away from the swab. This also allows the health care worker to have more control over where the swab is going within the nasal cavity.

1. If a headrest is not available, then the health care worker should use the nondominant hand to support the back of the patient's head.

**Funding:** None.

**Conflicts of Interest:** None.

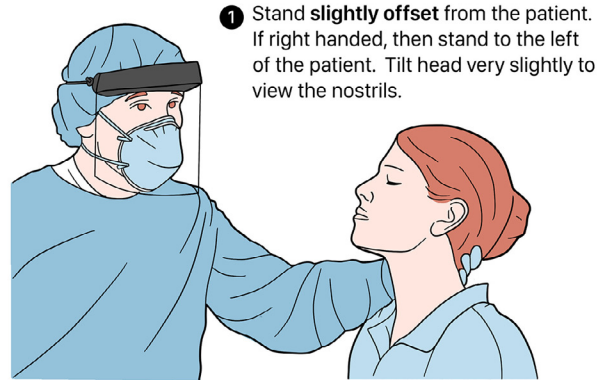
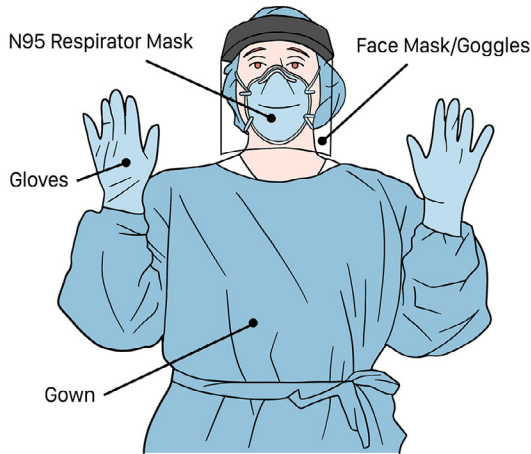**Authorship:** All authors had access to the data and a role in writing this manuscript.

Requests for reprints should be addressed to Karthik Rajasekaran, MD, Department of Otorhinolaryngology – Head and Neck Surgery, University of Pennsylvania, 800 Walnut St, 18th Floor, Philadelphia, PA, 19107.

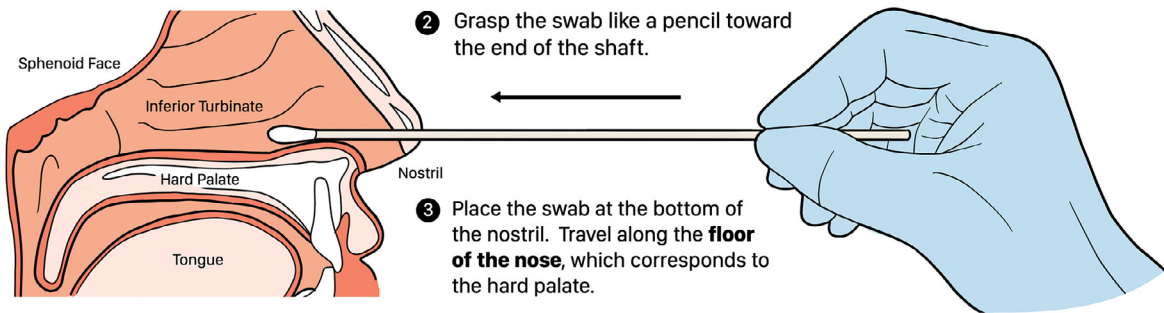
E-mail address: [Karthik.rajasekaran@pennmedicine.upenn.edu](mailto:Karthik.rajasekaran@pennmedicine.upenn.edu)

# Obtaining a Nasopharyngeal Swab

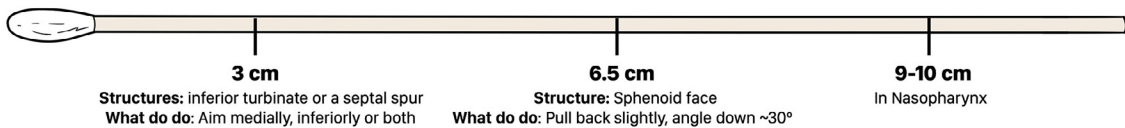
## Set Up



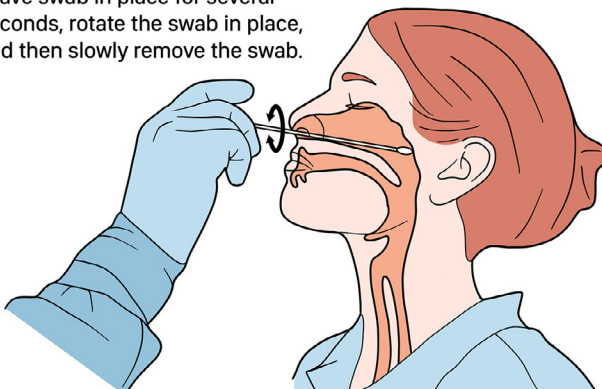
## Procedure



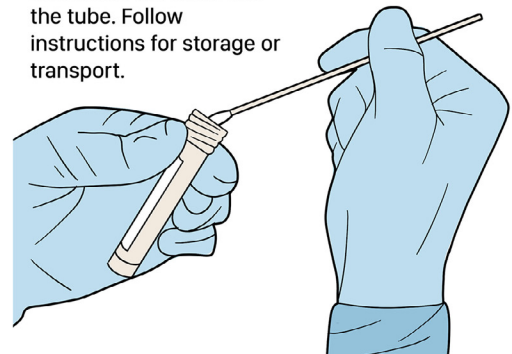
### Possible Resistance



4 Leave swab in place for several seconds, rotate the swab in place, and then slowly remove the swab.



5 Open the collection tube and insert the swab into the tube. Follow instructions for storage or transport.



Figure

## 2. Steps (Figure)

- a. The patient should be asked to blow their nose prior to the start of the procedure to clear secretions from the nasal passageways.
- b. Next, the patient should keep the head level or at most tilt the head back 30 degrees.

1. There are some manufacturers who recommend an increased head angle; however, we feel that that position increases the likelihood of hitting the nasal sill or tracking along the nasal dorsum. Both of these scenarios are uncomfortable for the patient and will not lead to nasopharynx.

- c. The swab should then be gently inserted as close to the floor of the nose as possible. It should be aimed both parallel to the floor of the nose and septum. This technique will allow the swab to pass easily through the internal nasal valve, which is the smallest area within the nasal cavity, measuring only 0.65 cm<sup>2</sup> in cross-section.<sup>5</sup>
- d. If there are no obstructions from the nasal anatomy and the swab follows this trajectory, it will meet resistance once it has reached the nasopharynx.

1. Traditionally, it was believed that measuring the length from the philtrum to the tragus estimates the distance to the nasopharynx. However, no correlation between these 2 values has been found.<sup>6</sup>

2. The average distance from the nasal aperture to the nasopharynx in the adult female is  $9.4 \pm 0.6$  cm and in the adult male it is  $10.0 \pm 0.5$  cm.<sup>6</sup>

- e. Once in the nasopharynx, the swab should be left in place for several seconds to absorb the secretions. It is then rotated gently, completing 2 full 360-degree rotations and then slowly withdrawn.

## 3. Specimen handling

The swab should then be inserted into the viral culture media. The most proximal portion of the swab handle should be snapped off at the indicator line allowing the media vial to be closed.

## 4. Challenges

Along the way from the nasal aperture to the nasopharynx, there are several locations where the swab can meet resistance.

- a. If resistance is met almost immediately, the swab has likely hit the nasal sill. To overcome this, the swab should be aimed slightly higher to rise above this mound of tissue.
- b. If resistance is felt at approximately 3 cm, the swab has hit the inferior turbinate. To get past the inferior turbinate, the swab should be aimed lower, medially, or both.<sup>7</sup>

- c. As the swab is advanced, the next point of potential resistance is the anterior face of the sphenoid sinus, which is found at approximately 6.5 cm.<sup>8</sup> To resolve this issue, the swab should be pulled back slightly and angled down about 30 degrees to allow passage through the choana to enter the nasopharynx.

Obstructions felt at other depths not listed could represent a septal deviation, polyps, mucosal hypertrophy, or nasal masses and potentially should be evaluated by a qualified clinician at a later date after the pandemic has resolved. If the swab still does not reach 9-10 cm despite the maneuvers described, the swab has not reached the nasopharynx. In such cases, the swab should be withdrawn and discarded, and the procedure should be attempted in the contralateral nasal cavity.

## CONCLUSION

Performing an effective nasopharyngeal swab without causing significant discomfort to the patient is more complicated than it may appear at first glance. We recommend marking out the expected travel distance on the swab until the health care worker becomes comfortable with the depth of the nasal cavity. With knowledge of the relevant nasal anatomy and overseen practice, a health care worker can be taught the technique quickly and be confident that an adequate sample is acquired. This information is essential to allow for widespread distribution of tests to permit countries across the world to return a state of normalcy.

## References

1. World Health Organization. Coronavirus disease 2019 situation reports. Available at: <https://www.who.int/emergencies/diseases/novel-coronavirus-2019/situation-reports>. Accessed April 15, 2020.
2. Bai Y, Yao L, Wei T et al. Presumed asymptomatic carrier transmission of COVID-19 [e-pub ahead of print]. *JAMA*. <https://doi.org/10.1001/jama.2020.2565>. Accessed April 15, 2020.
3. Ai T, Yang Z, Hou H, et al. Correlation of chest CT and RT-PCR testing in coronavirus disease 2019 (COVID-19) in China: a report of 1014 cases [e-pub ahead of print]. *Radiology*. <https://doi.org/10.1148/radiol.2020200642>. Accessed April 15, 2020.
4. Wang W, Xu Y, Gao R, et al. Detection of SARS-CoV-2 in different types of clinical specimens [e-pub ahead of print]. *JAMA* 2020;323(18):1843-4.
5. Englhard AS, Wiedmann M, Ledderose GJ, et al. Imaging of the internal nasal valve using long-range Fourier domain optical coherence tomography. *Laryngoscope* 2016;126(3):E97-E102.
6. Lim H, Lee JH, Son KK, Han Y-J, Ko S. A method for optimal depth of the nasopharyngeal temperature probe: the philtrum to tragus distance. *Korean J Anesthesiol* 2014;66(3):195-8.
7. Singh DP, Forte AJV, Apostolides JG, et al. Transoral submucosal resection of the inferior turbinate: a novel approach to functional rhinoplasty. *Ann Plast Surg* 2012;68(1):46-8.
8. Djambazov K, Yovchev I, Baltadjiev G. Anatomic-topographic landmarks on the lateral wall of nasal cavity used in endonasal surgery. *Folia Med (Plovdiv)* 1999;41(2):27-32.