
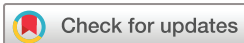

# Remarkably high prevalence of overuse-related knee complaints and MRI abnormalities in youth competitive alpine skiers: a descriptive investigation in 108 athletes aged 13–15 years

Stefan Fröhlich,<sup>1,2</sup> Loris Peterhans,<sup>1,2</sup> Christoph Stern,<sup>3</sup> Walter O Frey,<sup>2</sup> Reto Sutter,<sup>3</sup> Jörg Spörri <sup>1,2</sup>

**To cite:** Fröhlich S, Peterhans L, Stern C, *et al*. Remarkably high prevalence of overuse-related knee complaints and MRI abnormalities in youth competitive alpine skiers: a descriptive investigation in 108 athletes aged 13–15 years. *BMJ Open Sport & Exercise Medicine* 2020;**6**:e000738. doi:10.1136/bmjsem-2020-000738

Accepted 18 April 2020



© Author(s) (or their employer(s)) 2020. Re-use permitted under CC BY-NC. No commercial re-use. See rights and permissions. Published by BMJ.

<sup>1</sup>Sports Medical Research Group, Department of Orthopaedics, Balgrist University Hospital, University of Zurich, Zurich, Switzerland

<sup>2</sup>University Centre for Prevention and Sports Medicine, Department of Orthopaedics, Balgrist University Hospital, University of Zurich, Zurich, Switzerland

<sup>3</sup>Department of Radiology, Balgrist University Hospital, University of Zurich, Zurich, Switzerland

## Correspondence to

Dr Jörg Spörri;  
joerg.spoerri@balgrist.ch

## ABSTRACT

**Background/aim** Competitive alpine skiing is known to be associated with a high risk of traumatic knee injuries. However, little is known about the exact prevalence of knee overuse injuries and their associations with structural changes, particularly in youth skiers. Accordingly, the aim of the present study was to describe the overuse-related knee complaints and MRI abnormalities in a cohort of youth skiers around the growth spurt.

**Methods** 108 youth competitive alpine skiers aged 13–15 years were examined using an MRI of both knees, an interview on existing knee complaints and a physical examination. As a common baseline for these assessments, skiers were prospectively monitored by the use of the Oslo Sports Trauma Research Centre questionnaire on health problems over a period of 12 months preceding the major investigations.

**Results** 88.0% of the youth skiers showed at least one MRI abnormality in the knees. The most frequent findings were distal femoral cortical irregularities (63%), focal periphyseal oedema (FOPE) zones (25.0%) and cartilage lesions (18.5%). 47.2% of all skiers suffered from at least one overuse-related knee complaint during the 12 months preceding the MRI examination, mostly at the distal and proximal patellar tendon. However, despite a certain association with corresponding MRI abnormalities, the sensitivity of an MRI-based detection of such complaints was strongly limited.

**Conclusion** Youth competitive alpine skiers suffer from a remarkably large number of knee overuse injuries. Accordingly, an effective prevention strategy should include a systematic screening of clinical complaints, ideally already starting around the growth spurt.

## INTRODUCTION

In competitive alpine skiing, the risk to sustain a traumatic knee injury is known to be relatively high.<sup>1–3</sup> Accordingly, previous research primarily focused on traumatic injuries, whereas overuse-related injuries have received little attention.<sup>4</sup> However, while skiing, the knee joint has to withstand

## What are the new findings?

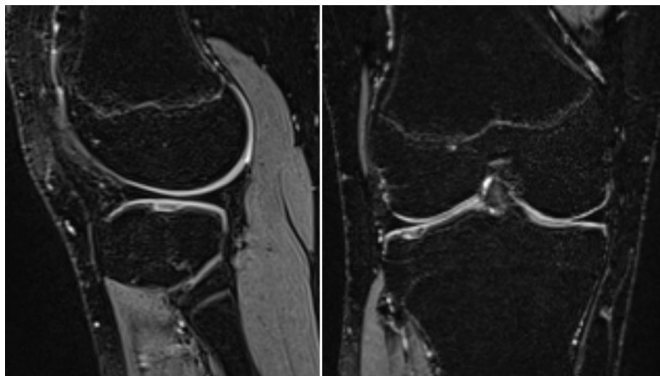
- ▶ This is the first investigation that assessed the prevalence of knee overuse-related clinical complaints and MRI abnormalities in a cohort of youth competitive alpine skiers, whose knees are particularly exposed to adverse loads. It revealed remarkably high rates of patellar tendon-related complaints, for which despite clear clinical signs, the sensitivity of an MRI-based detection was limited.

## How it might impact on clinical practice in the near future?

- ▶ Based on our findings, it is strongly recommended to systematically screen youth athletes for knee overuse injuries in general and the patellar tendon in particular. Moreover, the current study is expected to stimulate future research focusing on novel innovative assessment tools to detect early (or even subclinical) stages of such injuries.

enormous mechanical stress,<sup>5 6</sup> plausibly putting athletes at high risks for accumulating structural damages over time. This risk for irreparable joint deteriorations might be particularly high in competitive alpine skiers (typical single leg loadings of up to 1.75 times body weight<sup>7</sup>) and youth athletes around the growth spurt, whose bodies are still maturing and, therefore, are especially vulnerable to adverse loadings. Moreover, youth athletes are not regularly seen by any medical staff yet, and in less severe cases, affected persons might not immediately ask for professional help.

In sports other than competitive alpine skiing, several abnormal (however mostly asymptomatic) knee MRI findings have been reported.<sup>8–12</sup> In adolescent high-level



**Figure 1** Sagittal (left) and coronal (right) fat-suppressed T2-weighted image of a cartilage lesion in the lateral tibial plateau.

volleyball players, degenerative changes of the knee like osteophytes and subarticular cysts were detected; however, they showed no change in prevalence or severity within a 2-year follow-up.<sup>13</sup> In asymptomatic adolescent swimmers, significantly more abnormalities such as fat pad oedema, bone marrow oedema and joint effusion were observed than in age-matched and weight-matched controls.<sup>12</sup> Across the literature, the occurrence of patellar tendon-related health problems appears to be remarkably high.<sup>14–16</sup> However, to date, no study has assessed the exact prevalence of knee overuse injuries and their specific associations with structural changes in competitive alpine skiers; whereas, a more fundamental understanding of the corresponding onset, patterns and severity would help to define more effective prevention strategies in the near future.

Accordingly, the aim of the present study was to describe the knee overuse-related clinical complaints and MRI abnormalities in a cohort of youth competitive alpine skiers around the growth spurt.

## MATERIALS AND METHODS

### Participants and study design

In this cross-sectional study, 108 Swiss youth competitive alpine skiers aged 13–15 years were evaluated. In Switzerland, the skiers of the highest level advance to a national squad at the age of 16–17 years. During the preceding years, they are organised in certified regional performance centres (RLZ/CRP). Thus, the examinations took place during their years at the RLZ/CRP. Study participation was voluntary, and none of the participants reported systemic pathologies such as inflammatory arthritis or diabetes mellitus that would have been reasons.

### MRI examination

All youth skiers underwent an MRI scan of both knees. Examinations were performed using a 3T MR scanner (MAGNETOM Prisma, Siemens Healthcare, Erlangen, Germany) and a dedicated knee coil. The standardised protocol was an isotropic fat-suppressed T2-weighted three-dimensional sequence (SPACE) with the following parameters: in-plane resolution 0.63×0.63 mm, slice

thickness 0.63 mm, field of view (FOV) 160×160, Matrix 256×256, echo time (TE) 108 ms, repetition time (TR) 1000 ms, receiver bandwidth 415 Hz/Px, parallel imaging acceleration factor 4, duration 4:42 min. An example image is presented in [figure 1](#).

### Assessment of anthropometrics and biological maturation

In addition to the MRI examinations, the anthropometrics and biological maturation of all participating skiers were assessed. Body mass index (BMI) was defined as *body weight* in kilogram divided by squared *body height* in centimetre.  $\Delta$ *height* was defined as the absolute growth in centimetre within the last 12 months. Athletes' age at peak height velocity and their *maturity offset* were determined using the sex-specific formulae of Mirwald and colleagues<sup>17</sup> that based on the anthropometric input parameters body height, sitting height and subischial leg length.

### Assessment of clinical complaints

Over a period of 12 months preceding the MRI examinations, and as a common baseline for all other clinical assessments, athletes were prospectively monitored by a questionnaire on health problems that was completed in 14-day intervals (Oslo Sports Trauma Research Centre (OSTRC) questionnaire).<sup>18, 19</sup> This questionnaire was particularly recommended to detect overuse injuries and to quantify their severity.<sup>18</sup> All health problems were classified as illness, traumatic or overuse injury.<sup>20</sup> If athletes selected the option 'registered for the first time' in the questionnaire, a health problem was defined as being a 'new' incident. Illnesses and all injuries that were not related to the knee were not further considered for the current analysis. Immediately prior the MRI examinations, athletes underwent a systematic physical examination of their knees combined with an additional retrospective interview. The interview was intended to verify all OSTRC entries during the preceding 12 months and to complete the information on existing knee-related health problems (ie, to get additional relevant information on the knee problems previously reported in the questionnaire such as specific diagnosis or therapy) and, in rare cases, to possibly detect additional problems that might have been missed by the questionnaire. The physical examination was intended to exactly classify specific conditions like distal patellar tendon complaints (Osgood-Schlatter's disease) and to detect other joint pathologies like ligamentous injuries. The assessments included inspection, palpation, evaluation of range of motion and stability in the sagittal and frontal plane. All examinations and interviews were performed by the same experienced physician specialised in orthopaedics and sports medicine. Finally, athletes were classified as 'symptomatic' when they suffered from at least one verified knee overuse-related health problem episode within the last 12 months prior to the MRI examination.

**Table 1** Definition of the MRI findings assessed

MRI finding	Definition
Meniscal degeneration	Significant hyperintense signal change within the meniscus without contact to the surface.
Meniscal tear	Significant linear hyperintense signal change within the meniscus with contact to the surface.
Cartilage lesion	Focal substance loss of the cartilage ICRS first to ICRS fourth degree.
ACL and PCL abnormalities	Tears, partial tears and significant signal alterations of the ACL or the PCL as well as the presence of a graft after ligament reconstruction.
Abnormalities of the patellar tendon or the quadriceps tendon (overall and subclassified with respect to location)	Morphological changes of the insertion or the tendon itself (hyperintense signal change, tendon thickening, oedema and ossicles).
Trochlear dysplasia	Flattened trochlear groove (Dejour type A–D).
Bone marrow oedema of the femoral condyles	Significant hyperintense signal change within the bone of the medial or lateral femoral condyle close to the articular surface.
Distal femoral cortical irregularities	Circumscribed area of signal hyperintensity with a dark rim at the periphery at the insertion sites of the medial or lateral head of the gastrocnemius or the adductor magnus at the distal femur.
FOPE zones	Focal bone marrow oedema (significant hyperintense signal change) adjacent to areas of physeal fusion.
Joint effusion	Presence of increased intra-articular fluid.
Baker's cyst	Popliteal fluid collection between medial head of the M. gastrocnemius and M. semimembranosus.
Hoffa's fat pad oedema	Significant hyperintense signal change in the Hoffa's fat pad.

ACL, anterior cruciate ligament; FOPE, focal periphyseal oedema; ICRS, International Cartilage Repair Society; PCL, posterior cruciate ligament.

### MRI interpretation

All MR images were systematically assessed by the same experienced radiologist specialised in musculoskeletal imaging. They were evaluated for the following findings: meniscus abnormalities, cartilage lesions, abnormalities of the ligaments and tendons, bone marrow oedema, trochlear dysplasia, distal femoral cortical irregularities, focal periphyseal oedema (FOPE) zones, joint effusion, Baker's cyst and Hoffa's fat pad oedema. The changes

were classified as abnormal if they met the criteria listed in [table 1](#).

### Patient and public involvement

Participating athletes and their parents were regularly informed and empowered for maintaining a superior adherence to the study tasks, such as the 2 weekly questionnaire on health problems. Individual findings were communicated to the participants by email and were, on request, discussed with their coaches. Overall findings were disseminated to all relevant expert stakeholders within the National Ski Federation Swiss-Ski and within the associated RLZ/CRP youth development structures by means of regular presentations and advanced training activities.

### Statistical analysis

Statistical analyses were performed in Microsoft Excel and/or IBM SPSS statistics software V.23. For the purpose of this study, the following analysis steps were conducted: first, as suggested by Razali and Wah,<sup>21</sup> the Shapiro-Wilk test, graphical techniques (ie, histograms and quantile-quantile plots) and shape parameters (ie, skewness and kurtosis coefficients) were used to check distribution normality in any metric data. Due to a slight departure from normality (as defined in West *et al*<sup>22</sup>), all statistical tests including *age*, *Øheight* and *BMI* were backed-up by bias-corrected accelerated (BCa) bootstrapping with 10 000 samples; otherwise standard parametric tests were used. Second, the participants' baseline characteristics were expressed as mean±SD and differences in subgroups were tested for significance using unpaired sample t-tests ( $p<0.05$ ). Third, the prevalence of skiers suffering from specific clinical complaints and MRI findings of the knee was described as the number of skiers with corresponding indications, as well as by their percentage proportion (number of subjects affected/total number of subjects per group or subgroup \* 100). Corresponding sex differences, or differences between asymptomatic and symptomatic athletes, were analysed by Pearson  $\chi^2$  tests ( $p<0.05$ ). Fourth, if a pursuing analysis was indicated, univariate binary logistic regression models were used to assess the relationships between specific anthropometrics, clinical complaints and MRI abnormalities. Finally, the sensitivity and specificity for an MRI-based detection of patellar tendon-related clinical complaints were calculated.

## RESULTS

### Baseline characteristics

The baseline characteristics of the participating athletes at the time of the MRI examinations are summarised in [table 2](#).

### MRI findings and sex differences

The major MRI findings observed in the knees of youth female and male competitive alpine skiers are summarised in [table 3](#). As much as 88.0% of the youth skiers showed at least one MRI-detected abnormality in



**Table 2** Baseline characteristics

	Overall (n=108)	Women (n=42)	Men (n=66)
Age (years)	14.83±0.58	14.74±0.66	14.88±0.52
Maturity offset (years)	1.27±1.09	2.26±0.59	0.64±0.83***
APHV (years)	13.56±1.05	12.48±0.46	14.24±0.68***
Body height (cm)	166.4±7.7	163.1±5.9	168.5±8.0***
Δheight (cm)	4.95±3.06	2.70±2.54	6.39±2.44***
Body weight (kg)	56.6±9.2	55.3±7.5	57.4±10.2
BMI (kg/m <sup>2</sup> )	20.33±2.34	20.78±2.50	20.04±2.20

All data are expressed as mean±SD. Level of significance based on unpaired sample t-tests and backed-up by bias-corrected accelerated bootstrapping with 10 000 samples: \*\*\*p<0.001. APHV, age at peak height velocity; BMI, body mass index; Δheight, growth in body height during the last year.

the knee. The most frequent MRI-detected knee abnormalities of athletes around the growth spurt were with 63% distal femoral cortical irregularities. They were generally located close to tendon insertions (95% at the femoral insertion of the medial head of the gastrocnemius muscle, 5% at the femoral insertion of the lateral head of the gastrocnemius muscle). In this connection, there was found a significant association between the predictor variable 'increase in body height within the last 12 months' and the dependent variable 'occurrence of distal femoral cortical irregularities (univariate binary logistic regression analysis backed-up by BCa bootstrapping with 10 000 samples:  $\chi^2=13.533$ , p<0.001,  $R^2_{Nagelkerke}=0.161$ , n=108 and B=0.257 with the 95% CI 0.122 to 0.433),  $SE_B=0.079$ ,

$e^B=1.293$ , p<0.001). Other frequent MRI findings were FOPE zones (25.0%) and cartilage lesions (18.5%) and bone marrow oedemas of the femoral condyles (13.9%). In view of the high proportion of athletes with clinical complaints at the distal or proximal patellar tendon (overall: 30.6%), there were relatively few MRI abnormalities on the distal insertion of the patellar tendon (11.1%) and even no MRI findings related to the proximal insertion and midportion of the patellar tendon. Comparing the different sexes, women showed a significantly higher prevalence of meniscal tears and a trend towards more cartilage lesions than males. However, within the 108 youth skiers assessed, there was only one case in which the MRI findings required an immediate stop of participating in ski training and competitions.

### Clinical complaints and sex differences

The response rate to the OSTRC questionnaire during the 12-month observation period was 97.1%±2.5% on average. As much as 47.2% of all skiers suffered at least one overuse-related knee complaint during the preceding 12 months (table 4). Distal patellar complaints (17.6%) and proximal patellar complaints (18.5%) were most prevalent, whereas 16.7% had to be classified as indistinct overuse complaints. The only sex difference with respect to clinical complaints was found for traumatic knee sprains (overall: 10/108 skiers (9.3%); women: 8/42 skiers (19.0%); men: 2/66 skiers (3.0%),  $\chi^2=7.112$ , p=0.008).

### MRI findings in skiers with and without overuse-related knee complaints

Table 5 summarises the MRI findings in the knees of youth competitive alpine skiers with (symptomatic) and

**Table 3** MRI findings in the knees of youth female and male competitive alpine skiers

MRI finding	Overall (n=108)	Women (n=42)	Men (n=66)	$\chi^2$	P value
≥1 MRI finding	95 (88.0)	35 (83.3)	60 (90.9)	0.167	0.682
Meniscal degeneration	11 (10.2)	5 (11.9)	6 (9.1)	0.200	0.655
Meniscal tear	6 (5.6)	5 (11.9)	1 (1.5)*	4.987	0.026
Cartilage lesion	20 (18.5)	12 (28.6)	8 (12.1) <sup>(†)</sup>	3.751	0.053
ACL and PCL abnormalities	7 (6.5)	4 (9.5)	3 (4.5)	0.981	0.322
Abnormalities of the distal insertion of the patellar tendon	12 (11.1)	3 (7.1)	9 (13.6)	0.974	0.324
Trochlear dysplasia	7 (6.5)	4 (9.5)	3 (4.5)	0.981	0.322
Bone marrow oedema of the femoral condyles	15 (13.9)	3 (7.1)	12 (18.2)	2.252	0.133
Distal femoral cortical irregularities	68 (63.0)	24 (57.1)	44 (66.7)	0.370	0.543
FOPE zones	27 (25.0)	7 (16.7)	20 (30.3)	1.909	0.167
Joint effusion	11 (10.2)	3 (7.1)	8 (12.1)	0.625	0.429
Baker's cyst	15 (13.9)	3 (7.1)	12 (18.2)	2.252	0.133
Hoffa's fat pad oedema	8 (7.4)	2 (4.8)	6 (9.1)	0.650	0.420

Prevalence data are expressed as the number of skiers with specific MRI findings, as well as their percentage proportion (number of subjects affected/total number of subjects per group or subgroup \* 100; (%)) in brackets. Level of significance for sex differences based on Pearson's  $\chi^2$  tests: <sup>(†)</sup>p<0.10; \*p<0.05.

FOPE, focal periphyseal oedema.

**Table 4** Overuse-related knee complaints of youth female and male competitive alpine skiers

Overuse-related knee complaints	Overall (n=108)	Women (n=42)	Men (n=66)	$\chi^2$	P value
≥1 clinical complaint	51 (47.2)	21 (50.0)	30 (45.5)	0.112	0.738
Distal patellar tendon complaint	19 (17.6)	5 (11.9)	14 (21.2)	1.264	0.261
Proximal patellar tendon complaint	20 (18.5)	9 (21.4)	11 (16.7)	0.314	0.575
Indistinct overuse complaint	18 (16.7)	9 (21.4)	9 (13.6)	0.935	0.334

Prevalence data are expressed as the number of skiers with specific clinical indications, as well as their percentage proportion (number of subjects affected/total number of subjects per group or subgroup \* 100; (%)) in brackets. Level of significance for sex differences are based on Pearson's  $\chi^2$  tests. There were no significant results at  $p < 0.05$ .

without (asymptomatic) overuse-related knee complaints. Comparing the groups of asymptomatic versus symptomatic skiers in general, there were no significant differences at  $p < 0.05$ . The only exceptions were abnormalities of the distal insertion of the patellar tendon, which were significantly higher in symptomatic (21.6%) versus asymptomatic (1.8%) skiers ( $p < 0.01$ ).

### Sensitivity and specificity of MRI-based assessments of the patellar tendon

Indeed, an additional univariate logistic regression analysis revealed a direct association of the predictor variable 'abnormalities of the distal insertion of the patellar tendon' and the clinical indication 'distal patellar tendon complaint' (eg, Osgood-Schlatter disease) as the dependent variable ( $\chi^2 = 29.924$ ,  $p < 0.001$ ,  $R^2_{\text{Nagelkerke}} = 0.400$ ,  $n = 108$  and  $B = 3.878$ ,  $SE_B = 0.850$ ,  $e^B = 48.333$ ,  $p < 0.001$ ). However, the sensitivity of an MRI-based detection of a 'distal patellar tendon complaint' (ie, a clinically diagnosed Osgood-Schlatter disease) by the MRI finding

'abnormalities of the distal insertion of the patellar tendon' was 0.526, while the specificity revealed to be 0.978 ( $n = 108$ ; positive: 19; negative: 89 → true positive: 10; false negative: 9; true negative: 87; false positive: 2). For athletes with the clinical indication 'proximal patellar complaint', even no MRI-detected abnormalities were observed.

### DISCUSSION

The major findings of the study were: (1) in 88.0% of the analysed youth competitive alpine skiers at least one knee-related MRI abnormality was found; (2) the most frequent MRI findings were distal femoral cortical irregularities, FOPE zones and cartilage lesions and bone marrow oedemas of the femoral condyles; (3) highly prevalent clinical complaints were distal and proximal patellar tendon-related problems; (4) the only MRI findings differing between a group of youth skiers with and without overuse-related knee complaints were

**Table 5** MRI findings in the knees of youth competitive alpine skiers with (symptomatic) and without (asymptomatic) overuse-related knee complaints

MRI finding	Overall (n=108)	Asymptomatic (n=57)	Symptomatic (n=51)	$\chi^2$	P value
≥1 MRI finding	95 (88.0)	47 (82.5)	48 (94.1)	0.416	0.519
Meniscal degeneration	11 (10.2)	7 (12.3)	4 (7.8)	0.520	0.471
Meniscal tear	6 (5.6)	4 (7.0)	2 (3.9)	0.464	0.496
Cartilage lesion	20 (18.5)	10 (17.5)	10 (19.6)	0.062	0.803
ACL and PCL abnormalities	7 (6.5)	5 (8.8)	2 (3.9)	0.978	0.323
Abnormalities of the distal insertion of the patellar tendon	12 (11.1)	1 (1.8)	11 (21.6)**	9.510	0.002
Trochlear dysplasia	7 (6.5)	5 (8.8)	2 (3.9)	0.978	0.323
Bone marrow oedema of the femoral condyles	15 (13.9)	8 (14.0)	7 (13.7)	0.002	0.966
Distal femoral cortical irregularities	68 (63.0)	31 (54.4)	37 (72.5)	1.410	0.235
FOPE zones	27 (25.0)	13 (22.8)	14 (27.5)	0.232	0.630
Joint effusion	11 (10.2)	5 (8.8)	6 (11.8)	0.237	0.626
Baker's cyst	15 (13.9)	9 (15.8)	6 (11.8)	0.314	0.575
Hoffa's fat pad oedema	8 (7.4)	2 (3.5)	6 (11.8)	2.476	0.116

Prevalence data are expressed as the number of skiers with specific MRI findings, as well as their percentage proportion (number of subjects affected/total number of subjects per group or subgroup \* 100; (%)) in brackets. Level of significance for sex differences are based on Pearson's  $\chi^2$  tests: \*\* $p < 0.01$ .

FOPE, focal periphyseal oedema.



abnormalities of the distal insertion of the patellar tendon; and (5) despite a certain association between clinical complaints and MRI abnormalities related to the distal insertion of the patellar tendon, as well as a superior determination specificity, an MRI-based detection of such complaints was strongly limited with respect to sensitivity.

### High prevalence of MRI abnormalities and overuse-related knee complaints in youth competitive alpine skiers

As revealed in this study, youth competitive alpine skiers suffer from a remarkably large number of knee MRI abnormalities (88.0%); most frequently, these are distal femoral cortical irregularities, FOPE zones, cartilage lesions and bone marrow oedemas of the femoral condyle (table 3). The prevalence of cartilage lesions is as high as 18.5%. Compared with literature, this is a relatively high proportion. A study evaluating 44 knees of 44 adult asymptomatic volunteers aged 20–68 years found cartilage lesions in 11%.<sup>23</sup> Another study looking at 100 asymptomatic knees of 100 subjects with symptoms on the contralateral side (aged 18–73 years) found cartilage lesions in 25%.<sup>24</sup> In 40 knees of 20 professional basketball players, 47.5% had cartilage lesions.<sup>10</sup> During the 2016 Summer Olympics, 64 cartilage lesions were seen in the MRIs of 113 athletes of different sports.<sup>25</sup> However, these studies did not target on youth athletes. In 18 adolescent volleyball players, for instance, no cartilage lesions were detected.<sup>13</sup>

The distal femoral cortical irregularities appear to be of no clinical relevance and, therefore, are considered as incidental findings. It is assumed that they are the result of tensile stress at the tendinous attachment sites of skeletal muscles in areas with excessive growth-dependent metaphyseal cortical remodelling.<sup>26 27</sup> This presumption is further supported by our finding of a significant association between the increase in body height within the last 12 months and the occurrence of distal femoral cortical irregularities. In literature, they are generally considered benign and self-limiting.<sup>27 28</sup> The same applies to FOPE zones. They are discussed as a potential reason for knee pain,<sup>29 30</sup> but the actual clinical importance remains unclear.

Bone marrow oedemas of the femoral condyle were certainly common (13.9%) but not associated with clinical symptoms. This finding in youth competitive alpine skiers is in line with other studies focusing on that abnormality in different populations.<sup>9 11 12 31–33</sup> However, the clinical value of this MRI finding remains unclear.<sup>12 34 35</sup> Some authors claim that bone marrow oedemas represent an unspecific stress reaction and not a relevant pathology.<sup>9 33 36</sup>

The number of youth skiers reporting at least one overuse-related knee complaint during the preceding 12 months was with 47.2% also relatively high (table 4). A previous study evaluating 45 skiers of a slightly higher mean age of 17, even found a higher prevalence magnitude of 73%.<sup>37</sup> This suggests that the rate is still increasing

at that age. Thus, effective prevention measures should ideally be established before the age at which our examinations were conducted.

### Sex differences with respect to MRI abnormalities and overuse-related knee complaints

The significantly higher prevalence of meniscus tears in women with respect to a similar prevalence of meniscus degenerations for both sexes (table 3) is most likely an incidental finding. It might be explained by the significantly higher rate of knee sprains (8/42 (19.0%) women, 2/66 (3.0%) men,  $\chi^2$  7.112,  $p=0.008$ ) during the observation period. The same applies to the trend towards a higher prevalence of cartilage injuries in women. In the literature, no other studies detecting female sex as a risk factor for meniscal injuries in adolescents are available. It has been shown that meniscal tears often heal spontaneously in that age group.<sup>38</sup>

### The clinically most relevant complaints relate to the distal and proximal patellar tendon

Patellar tendinopathy is relatively common in adolescent athletes. In the literature, prevalence magnitudes of 5.8% ( $n=760$ , average age 13 years) and 7% ( $n=134$ , age 14–18 years) were reported for different sports.<sup>39 40</sup> In elite volleyball players aged 15–19 years, the rate of jumper's knee was as high as 11%.<sup>41</sup> An ultrasound study of 119 young soccer players (mean age 15.97 years) showed high rates of structural abnormalities within the tendon,<sup>42</sup> and other studies demonstrated a high correlation between a clinical tendinopathy and structural intratendinous alterations in ultrasound.<sup>43 44</sup> In the current study with a cohort of youth skiers, even a higher proportion of the athletes had clinical complaints at the distal or proximal patellar tendon (overall: 31.5%; distal: 17.6%; proximal: 18.5%). While in most cases the clinical diagnosis 'Osgood-Schlatter disease' (ie, distal patellar tendon complaints) was accompanied by radiological findings in the MRI, for the clinical diagnosis 'proximal patellar tendinopathy/jumper's knee' (ie, proximal patellar tendon complaints), no radiological equivalent (including radiological signs of Sinding-Larsen-Johansson disease) was found. Sinding-Larsen-Johansson disease describes the combination of the clinical condition with a fragmentation or calcification at the inferior pole of the patella.<sup>14 45</sup> However, regardless of whether radiological signs are present or not, it is worth pointing out that due to the high prevalence of the patellar tendon-related problems, these problems should be of primary prevention focus in youth skiers.

### The sensitivity of an MRI-based early recognition of patellar tendon-related problems: so far not so good

As shown in this study, despite clear clinical signs, the sensitivity of MRI to detect indications of patellar tendon-related complaints was strongly limited. Accordingly, an effective patellar tendon screening approach in youth



competitive alpine skiers should rather include a systematic assessment of clinical complaints than an MRI.

### Methodological considerations

There are a couple of limitations one should be aware of when interpreting the study findings. First, the collection of data on clinical complaints may suffer from a recall and/or reporting bias. In an attempt to reduce the recall bias, data on knee overuse injuries were collected prospectively in 2-week intervals. To verify the correctness and completeness of the prospectively self-reported questionnaire data and to counteract the risk of a reporting bias, retrospective interviews with a team physician were conducted. Moreover, for being able to provide a complete picture of the occurring knee overuse injuries (eg, including specific clinical diagnoses), additionally physical examinations were conducted. Second, the cross-sectional nature of the major examinations of the clinical complaints and MRI abnormalities does not allow conclusively answering questions on causal relationships and on the process of development of overuse injuries over time. Thus, for clarifying the clinical relevance of certain (so far) asymptomatic MRI findings, further longitudinal studies are required. Nevertheless, at least in some cases, associations between specific clinical complaints and MRI abnormalities were already evident, implying valuable new insights for the prevention of knee overuse injuries in youth competitive alpine skiers.

### CONCLUSION

Youth competitive alpine skiers present a remarkably large number of knee MRI abnormalities. The only clinically relevant MRI abnormalities were those at the distal insertion of the patellar tendon, which were directly associated with clinical signs of Osgood-Schlatter disease. However, despite clear complaints related to the distal patellar tendon, the sensitivity of MRI to detect such clinical conditions was strongly limited. Accordingly, an effective prevention strategy should primarily include a systematic screening of clinical complaints, ideally starting in youth athletes around the growth spurt.

**Acknowledgements** We would like to thank all participants, parents and coaches involved. A special thank goes to Serge Allemand, the U16 Coordinator of Swiss-Ski, and the Swiss Centre for Musculoskeletal Imaging, SCMI, Balgrist Campus AG, Zürich, where the study was conducted.

**Contributors** JS and RS conceptualised and designed the study. JS recruited the participants and organised the data collection. SF, LP and JS collected the data. SF, LP, CS and JS evaluated the data and performed the statistical analysis. All authors substantially contributed to the interpretation of data. SF and JS drafted the current manuscript; all authors revised it critically, approved the final version of the manuscript and agreed to be accountable for all aspects of the work.

**Funding** This study was generously supported by the Balgrist Foundation, Swiss-Ski, the 'Stiftung Passion Schneesport' and the 'Stiftung zur Förderung des alpinen Skisportes in der Schweiz'.

**Competing interests** None declared.

**Patient and public involvement** Patients and/or the public were involved in the design, or conduct, or reporting, or dissemination plans of this research. Refer to the Methods section for further details.

**Patient consent for publication** Not required.

**Ethics approval** The underlying study protocol was approved by the local ethics committee (KEK-ZH-NR: 2017-01395).

**Provenance and peer review** Not commissioned; externally peer reviewed.

**Data availability statement** All data relevant to the study are included in the article or uploaded as supplementary information.

**Open access** This is an open access article distributed in accordance with the Creative Commons Attribution Non Commercial (CC BY-NC 4.0) license, which permits others to distribute, remix, adapt, build upon this work non-commercially, and license their derivative works on different terms, provided the original work is properly cited, appropriate credit is given, any changes made indicated, and the use is non-commercial. See: <http://creativecommons.org/licenses/by-nc/4.0/>.

### ORCID iD

Jörg Spörri <http://orcid.org/0000-0002-0353-1021>

### REFERENCES

- 1 Flørenes TW, Bere T, Nordsletten L, *et al*. Injuries among male and female world cup alpine skiers. *Br J Sports Med* 2009;43:973–8.
- 2 Bere T, Flørenes TW, Nordsletten L, *et al*. Sex differences in the risk of injury in world cup alpine skiers: a 6-year cohort study. *Br J Sports Med* 2014;48:36–40.
- 3 Haaland B, Steenstrup SE, Bere T, *et al*. Injury rate and injury patterns in FIS world cup alpine skiing (2006–2015): have the new Ski regulations made an impact? *Br J Sports Med* 2016;50:32–6.
- 4 Supej M, Senner V, Petrone N, *et al*. Reducing the risks for traumatic and overuse injury among competitive alpine skiers. *Br J Sports Med* 2017;51:1–2.
- 5 Klous M, Müller E, Schwameder H. Three-Dimensional knee joint loading in alpine skiing: a comparison between a carved and a skidded turn. *J Appl Biomech* 2012;28:655–64.
- 6 Zorko M, Nemec B, Babič J, *et al*. The waist width of Skis influences the kinematics of the knee joint in alpine skiing. *J Sports Sci Med* 2015;14:606–19.
- 7 Kröll J, Spörri J, Gilgien M, *et al*. Effect of Ski geometry on aggressive Ski behaviour and visual aesthetics: equipment designed to reduce risk of severe traumatic knee injuries in alpine giant slalom Ski racing. *Br J Sports Med* 2016;50:20–5.
- 8 Brunner MC, Flower SP, Evancho AM, *et al*. MRI of the athletic knee. findings in asymptomatic professional basketball and collegiate football players. *Invest Radiol* 1989;24:72–5.
- 9 Chang X-D, Yang P, Mu X-Y, *et al*. Evaluation of knees in asymptomatic amateur ice hockey players using 3.0-T magnetic resonance imaging: a case-control study. *Chin Med J* 2018;131:1038–44.
- 10 Kaplan LD, Schurhoff MR, Selesnick H, *et al*. Magnetic resonance imaging of the knee in asymptomatic professional basketball players. *Arthroscopy* 2005;21:557–61.
- 11 Pappas GP, Vogelsong MA, Staroswiecki E, *et al*. Magnetic resonance imaging of asymptomatic knees in collegiate Basketball players: the effect of one season of play. *Clin J Sport Med* 2016;26:483–9.
- 12 Soder RB, Mizerkowski MD, Petkowicz R, *et al*. MRI of the knee in asymptomatic adolescent swimmers: a controlled study. *Br J Sports Med* 2012;46:268–72.
- 13 Boeth H, MacMahon A, Eckstein F, *et al*. MRI findings of knee abnormalities in adolescent and adult volleyball players. *J Exp Orthop* 2017;4:6.
- 14 Medlar RC, Lyne ED. Sinding-Larsen-Johansson disease. its etiology and natural history. *J Bone Joint Surg Am* 1978;60:1113–6.
- 15 Atanda A, Shah SA, O'Brien K. Osteochondrosis: common causes of pain in growing bones. *Am Fam Physician* 2011;83:285–91.
- 16 Peace KAL, Lee JC, Healy J. Imaging the infrapatellar tendon in the elite athlete. *Clin Radiol* 2006;61:570–8.
- 17 Mirwald RL, Baxter-Jones ADG, Bailey DA, *et al*. An assessment of maturity from anthropometric measurements. *Med Sci Sports Exerc* 2002;34:689–94.
- 18 Clarsen B, Myklebust G, Bahr R. Development and validation of a new method for the registration of overuse injuries in sports injury epidemiology: the Oslo sports trauma research centre (OSTRC) overuse injury questionnaire. *Br J Sports Med* 2013;47:495–502.
- 19 Hirschmüller A, Steffen K, Fassbender K, *et al*. German translation and content validation of the OSTRC questionnaire on overuse injuries and health problems. *Br J Sports Med* 2017;51:260–3.
- 20 Clarsen B, Rønsen O, Myklebust G, *et al*. The Oslo sports trauma research center questionnaire on health problems: a new approach to prospective monitoring of illness and injury in elite athletes. *Br J Sports Med* 2014;48:754–60.



- 21 Razali NM, Wah YB. Power comparisons of Shapiro-Wilk, Kolmogorov-Smirnov, Lilliefors and Anderson-Darling tests. *J Stat Model Anal* 2011;2:21–33.
- 22 West SG, Finch JF, Curran PJ. Structural equation models with nonnormal variables: problems and remedies. In: *Structural equation modeling: concepts, issues, and applications*. Thousand Oaks, CA, US: Sage Publications, Inc, 1995: 56–75.
- 23 Beattie KA, Boulos P, Pui M, et al. Abnormalities identified in the knees of asymptomatic volunteers using peripheral magnetic resonance imaging. *Osteoarthritis Cartilage* 2005;13:181–6.
- 24 Zanetti M, Pfirrmann CWA, Schmid MR, et al. Patients with suspected meniscal tears: prevalence of abnormalities seen on MRI of 100 symptomatic and 100 contralateral asymptomatic knees. *AJR Am J Roentgenol* 2003;181:635–41.
- 25 Koppel AJ, Murakami AM, Engebretsen L, et al. Mri-Detected sports-related knee injuries and abnormalities at the Rio de Janeiro 2016 summer Olympic Games. *AJR Am J Roentgenol* 2018;211:880–6.
- 26 Goldin A, Muzykewicz DA, Dwek J, et al. The aetiology of the non-ossifying fibroma of the distal femur and its relationship to the surrounding soft tissues. *J Child Orthop* 2017;11:373–9.
- 27 Vieira RLR, Bencardino JT, Rosenberg ZS, et al. Mri features of cortical desmoid in acute knee trauma. *AJR Am J Roentgenol* 2011;196:424–8.
- 28 Tscholl PM, Biedert RM, Gal I. Cortical desmoids in adolescent top-level athletes. *Acta Radiol Open* 2015;4:205846011558087.
- 29 Leschied JR, Udager KG. Imaging of the pediatric knee. *Semin Musculoskelet Radiol* 2017;21:137–46.
- 30 Zbojnicz AM, Laor T, Edema FP. Focal Periphyseal edema (FOPE) zone on MRI of the adolescent knee: a potentially painful manifestation of physiologic physeal fusion? *AJR Am J Roentgenol* 2011;197:998–1004.
- 31 Kornaat PR, Van de Velde SK. Bone marrow edema lesions in the professional runner. *Am J Sports Med* 2014;42:1242–6.
- 32 Major NM, Helms CA. MR imaging of the knee: findings in asymptomatic collegiate basketball players. *AJR Am J Roentgenol* 2002;179:641–4.
- 33 Soder RB, Simões JD, Soder JB, et al. MRI of the knee joint in asymptomatic adolescent soccer players: a controlled study. *AJR Am J Roentgenol* 2011;196:W61–5.
- 34 Culvenor AG, Øiestad BE, Hart HF, et al. Prevalence of knee osteoarthritis features on magnetic resonance imaging in asymptomatic uninjured adults: a systematic review and meta-analysis. *Br J Sports Med* 2019;53:1268–78.
- 35 Kornaat PR, de Jonge MC, Maas M. Bone marrow edema-like signal in the athlete. *Eur J Radiol* 2008;67:49–53.
- 36 Krajnc Z, Ruprecht M, Drobnic M. Quantitative evaluation of growth plates around the knees of adolescent soccer players by diffusion-weighted magnetic resonance imaging. *Biomed Res Int* 2015;2015:1–6.
- 37 Bergström KA, Brandseth K, Fretheim S, et al. Activity-Related knee injuries and pain in athletic adolescents. *Knee Surg Sports Traumatol Arthrosc* 2001;9:146–50.
- 38 Ekås GR, Laane MM, Larmo A, et al. Knee pathology in young adults after pediatric anterior cruciate ligament injury: a prospective case series of 47 patients with a mean 9.5-Year follow-up. *Am J Sports Med* 2019;47:1557–66.
- 39 Cassel M, Baur H, Hirschmüller A, et al. Prevalence of Achilles and Patellar tendinopathy and their association to intratendinous changes in adolescent athletes. *Scand J Med Sci Sports* 2015;25:e310–8.
- 40 Cook JL, Khan KM, Kiss ZS, et al. Patellar tendinopathy in junior basketball players: a controlled clinical and ultrasonographic study of 268 Patellar tendons in players aged 14–18 years. *Scand J Med Sci Sports* 2000;10:216–20.
- 41 Gisslén K, Gyulai C, Söderman K, et al. High prevalence of jumper's knee and sonographic changes in Swedish elite junior volleyball players compared to matched controls. *Br J Sports Med* 2005;39:298–301.
- 42 Bode G, Hammer T, Karvouniaris N, et al. Patellar tendinopathy in young elite soccer- clinical and sonographical analysis of a German elite soccer Academy. *BMC Musculoskelet Disord* 2017;18:344.
- 43 Cassel M, Risch L, Intziagianni K, et al. Incidence of Achilles and Patellar tendinopathy in adolescent elite athletes. *Int J Sports Med* 2018;39:726–32.
- 44 Gisslén K, Alfredson H. Neovascularisation and pain in jumper's knee: a prospective clinical and sonographic study in elite junior volleyball players. *Br J Sports Med* 2005;39:423–8.
- 45 Iwamoto J, Takeda T, Sato Y, et al. Radiographic abnormalities of the inferior pole of the patella in juvenile athletes. *Keio J Med* 2009;58:50–3.