

- Antimicrob Agents*. 2020 [Epub ahead of print]. <https://doi.org/10.1016/j.ijantimicag.2020.105954>.
11. Xu X, Han M, Li T, Sun W, Wang D, Fu B, *et al*. Effective treatment of severe COVID-19 patients with Tocilizumab. *Proc Natl Acad Sci USA*. 2020 [Epub ahead of print]. <https://doi.org/10.1073/pnas.2005615117>.
  12. Zhou F, Yu T, Du R, Fan G, Liu Y, Liu Z, *et al*. Clinical course and risk factors for mortality of adult inpatients with COVID-19 in Wuhan, China: a retrospective cohort study. *Lancet*. 2020;**395**:1054–62.
  13. Augustson BM, Begum G, Dunn JA, Barth NJ, Davies F, Morgan G, *et al*. Early mortality after diagnosis of multiple myeloma: analysis of patients entered onto the United Kingdom Medical Research Council trials between 1980 and 2002—Medical Research Council Adult Leukaemia Working Party. *J Clin Oncol*. 2005;**23**:9219–26.
  14. Al Saleh AS, Sher T, Gertz MA. Multiple myeloma in the time of COVID-19. *Acta Haematol*. 2020 [Epub ahead of print]. 0.1159/000507690.

## Arterial thromboembolic complications in COVID-19 in low-risk patients despite prophylaxis

We present a case series of three patients with coronavirus disease 2019 (COVID-19) who developed arterial vascular complications, one who developed an acute cerebrovascular accident, one who developed popliteal artery occlusion and one who developed both during their hospital course.

We present a case series of three patients admitted to Northwell Plainview Hospital in Plainview, New York with COVID-19 as confirmed by polymerase chain reaction. The clinical disease course of COVID-19 has been well documented in China and Europe and most recently, the USA. Publications highlighting the non-respiratory complications of COVID-19 have been limited.<sup>1,2</sup> Acute cardiac injury and arrhythmia in the intensive care unit (ICU) have been described as major complications of COVID-19.<sup>3</sup> A few publications have highlighted the incidence of venous thromboembolic complications in COVID-19.<sup>4,5</sup>

We present three patients who were found to have arterial thrombosis as a complication of COVID-19. All three patients were admitted to Northwell Plainview Hospital during March or April of 2020 and were on prophylactic or full-dose anti-coagulation at the time of these events. The patients all received intravenous (IV) steroid [methylprednisolone (Solu-Medrol) 1–2 mg/kg per day × 5–8 days] and tocilizumab (400 mg IV × 1) during what was assumed to be the cytokine storm phase of the clinical course (Table I).<sup>6</sup>

**Patient 1** is a 50-year-old male with past medical history (PMH) of hypertension and hyperlipidaemia. The patient presented with dyspnoea on day 14 of symptoms. His deep vein thrombosis (DVT) prophylaxis was increased to enoxaparin 40 mg subcutaneously twice a day. On day 23 of symptoms, the patient was noted to have left upper extremity weakness, code ‘stroke’ was called. Serial computed

**Table I.** Patients with arterial thromboembolic complications.

Variable	Patient 1	Patient 2	Patient 3
Age, years	50	65	69
BMI, kg/m <sup>2</sup>	32.5	26.6	24.1
eGFR, ml/min/1.73 m <sup>2</sup>	58	83	47
Day of symptoms, admission, event	14, 25	8, 21	10, 23
D-dimer, ng/ml, baseline, event	249, 13341	<150, 41693	329, 2620
Increase from baseline D-dimer	53.6×	277×	7.96×
PT, s, baseline, event	15.9, 17.1	14.5, 16.4	13.1, 13.4
PTT, s, baseline, event	35.1	29.9, 76.3 on heparin drip	33.2, 29.1
INR, baseline, event	1.4, 1.51	1.28, 1.45	1.16, 1.19
Platelets, × 10 <sup>9</sup> /l, baseline, event	375, 808	219, 108	150, 337
Oxygen requirement at time of event	Intubated	Intubated	98% room air
DVT prophylaxis at event	Yes	Yes	Yes
Tocilizumab	Yes	Yes	Yes
Steroids	Yes	Yes	Yes
Plaquenil	No	Yes	Yes
tPA	Yes	Yes	No

BMI, body mass index; DVT, deep vein thrombosis; eGFR, estimated glomerular filtration rate; INR, international normalised ratio; PT, prothrombin time; PTT, partial thromboplastin time; tPA, tissue plasminogen activator.

tomography (CT) showed a non-haemorrhagic right parietal infarct and the patient was given tissue plasminogen activator (tPA). The patient's neurological deficits resolved after tPA, but then he had an acute mental status change and was intubated to protect his airway. The patient was started on a full dose of enoxaparin for new onset rapid atrial fibrillation. On day 25 of symptoms, the patient developed a cool left lower extremity. Arterial Doppler showed no flow distal to the popliteal artery while on enoxaparin 1 mg/kg twice a day. He was transferred for surgical intervention, but did not undergo any surgical intervention and ultimately died.


**Patient 2** is a 65-year-old male with PMH of dilated aortic root. The patient presented to the Emergency Department with progressively worsening dyspnoea on day 8 of symptoms. On symptom day 17, the patient had an acute increase in D-dimer to 12 597, was started on argatroban drip, transferred to the ICU and started on Hi-flow nasal cannula. On symptom day 19, right arterial Doppler showed no significant flow in the right popliteal artery, posterior tibial, anterior tibial, peroneal or dorsalis pedis arteries. Vascular surgery performed fasciotomy with thromboembolectomy of the right lower extremity. On symptom day 20, the patient was started on a heparin drip after failing argatroban drip post-thromboembolectomy. On symptom day 21, the patient went for a second emergent thromboembolectomy, went into ventricular tachycardic arrest intraoperatively, but achieved return of spontaneous circulation, and was found to have a massive pulmonary embolism with right ventricular strain by transthoracic echocardiogram and was treated with tPA.

**Patient 3** is a 69-year-old male with PMH of coronary artery disease, insulin-dependent type 2 diabetes mellitus, hypertension and chronic kidney disease Stage III. The patient presented with dyspnoea, non-productive cough, fatigue, chills, headache, profuse watery diarrhoea and intermittent fevers on day 10 of symptoms. On day 11 of symptoms, the patient was intubated for acute hypoxic respiratory failure. The patient remained intubated for 7 days. On day 23 of symptoms, the patient had a syncopal event for which a CT head showed an ill-defined low-density focus within the left thalamus, suspicious for acute infarct. Magnetic resonance imaging showed a hyper-intense signal within the left thalamus, with a small amount of associated enhancement, interpreted as likely a subacute infarct. The patient was discharged on aspirin, clopidogrel and statin therapy. The patient initially did well, but 1 day after finishing a taper of steroids he was readmitted with laryngeal oedema. He did well after additional steroids were given.

## Discussion

The mechanism for coagulopathy in patients with COVID-19 is currently unknown.<sup>7</sup> The thromboembolic events described in these cases occurred after the cytokine storm and during the third week of the disease, despite having no risk factors for thromboembolism and being on intermediate prophylaxis

dose. The arterial clots removed at surgery in the patient described in case two were white and consistent with being platelet-rich.<sup>8</sup> It is unclear and perhaps unlikely that the same mechanisms are involved in venous as in arterial clots, but this gross appearance suggested an important role of platelets and the possibility that anti-platelet agents, such as aspirin, may play a role in preventing arterial thromboembolic complications.<sup>9</sup> In terms of preventing and treating venous thromboembolic disease there remains limited evidence or guidance from well-controlled trials on whether low-molecular-weight heparin, unfractionated heparin, direct factor Xa inhibitors, direct thrombin inhibition or other approaches are optimal.<sup>10</sup>

**Daniel O. Griffin**<sup>1,2</sup>   
**Alexandra Jensen**<sup>3</sup>  
**Mushmoom Khan**<sup>3</sup>  
**Jessica Chin**<sup>3</sup>  
**Kelly Chin**<sup>3</sup>  
**Ryan Parnell**<sup>3</sup>  
**Christopher Awwad**<sup>3</sup>  
**Darshan Patel**<sup>3</sup>

<sup>1</sup>Department of Biochemistry and Molecular Biophysics, Columbia University Medical Center, <sup>2</sup>Division of Infectious Diseases, Department of Medicine, College of Physicians and Surgeons, Columbia University, New York and <sup>3</sup>Donald and Barbara Zucker School of Medicine at Hofstra/Northwell, Hempstead, NY, USA.  
 E-mail: dg2810@cumc.columbia.edu

**Keywords:** COVID-19, hypercoagulability, pulmonary embolism, thromboembolic

First published online 28 May 2020  
 doi: 10.1111/bjh.16792

## References

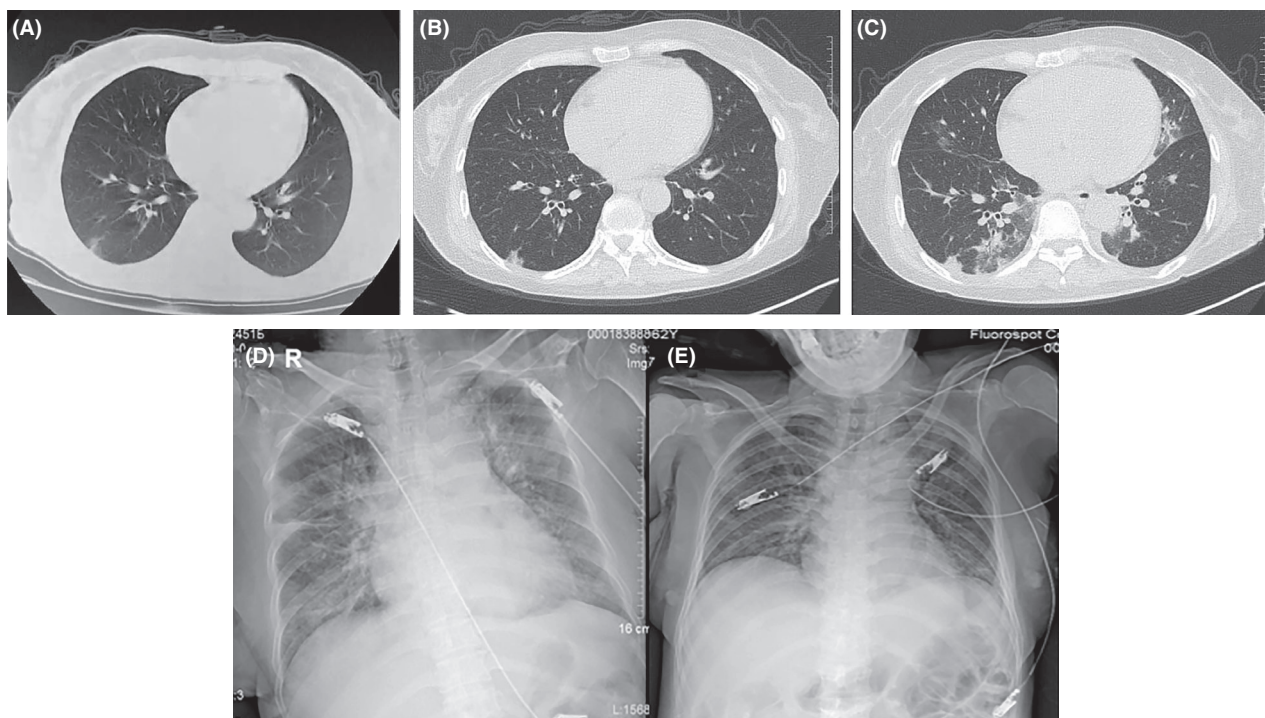
- Zhou F, Yu T, Du R, Fan G, Liu Y, Liu Z, et al. Clinical course and risk factors for mortality of adult inpatients with COVID-19 in Wuhan, China: a retrospective cohort study. *Lancet*. 2020;**395**:1054–62.
- Griffin DO, Jensen A, Khan M, Chin J, Chin K, Saad J, et al. Pulmonary embolism and increased levels of d-dimer in patients with coronavirus disease. *Emerg Infect Dis* 2020 [Epub ahead of print]. DOI: <https://doi.org/10.3201/eid2608.201477>.
- Wang D, Hu B, Hu C, Zhu F, Liu X, Zhang J, et al. Clinical characteristics of 138 hospitalized patients with 2019 novel coronavirus-infected pneumonia in Wuhan, China. *JAMA*. 2020;**323**:1061–9.
- Kollias A, Kyriakoulis KG, Dimakakos E, Poulakou G, Stergiou GS, Strygos K. Thromboembolic risk and anticoagulant therapy in COVID-19 patients: emerging evidence and call for action. *Br J Haematol*. 2020 [Epub ahead of print]. DOI: <https://doi.org/10.1111/bjh.16727>.
- Llitis JF, Leclerc M, Chochois C, Monsallier JM, Ramakers M, Auvray M, et al. High incidence of venous thromboembolic events in anticoagulated severe COVID-19 patients. *J Thromb Haemost*. 2020 [Epub ahead of print]. DOI: <https://doi.org/10.1111/jth.14869>.
- Zhang C, Wu Z, Li JW, Zhao H, Wang GQ. The cytokine release syndrome (CRS) of severe COVID-19 and Interleukin-6 receptor (IL-6R) antagonist Tocilizumab may be the key to reduce the mortality. *Int J Antimicrob Agents*. 2020;105954.

7. Bikdeli B, Madhavan MV, Jimenez D, Chuich T, Dreyfus I, Driggin E, et al. COVID-19 and thrombotic or thromboembolic disease: implications for prevention, antithrombotic therapy, and follow-up. *J Am Coll Cardiol*. 2020 [Epub ahead of print]. DOI: <https://doi.org/10.1016/j.jacc.2020.04.031>.
8. Koupenova M, Kehrel BE, Corkrey HA, Freedman JE. Thrombosis and platelets: an update. *Eur Heart J*. 2017;**38**:785–91.
9. Mekaj YH, Daci FT, Mekaj AY. New insights into the mechanisms of action of aspirin and its use in the prevention and treatment of arterial and venous thromboembolism. *Ther Clin Risk Manag*. 2015;**11**:1449–56.
10. Oudkerk M, Buller HR, Kuijpers D, van Es N, Oudkerk SF, McLoud TC, et al. Diagnosis, prevention, and treatment of thromboembolic complications in COVID-19: report of the national institute for public health of the Netherlands. *Radiology*. 2020 [Epub ahead of print]. DOI: <https://doi.org/10.1148/radiol.2020201629>.

## COVID-19 in a patient with pre-existing acute lymphoblastic leukaemia

Coronavirus disease 2019 (COVID-19) is a novel respiratory infection caused by severe acute respiratory syndrome coronavirus 2 (SARS-CoV-2), newly discovered since December 2019.<sup>1–3</sup> According to a World Health Organization situation report on April 1, 2020,<sup>4</sup> a total of 823,626 cases and over 40,000 deaths had been documented globally, suggesting the situation was rapidly evolving into a pandemic. As reported by previous studies, patients with pre-existing health conditions are more likely to progress to severe COVID-19 pneumonia.<sup>2,5–7</sup> Here, we report a COVID-19 case with pre-existing acute lymphoblastic leukaemia (ALL).

A 62-year-old woman with previous history of ALL was admitted on February 1, 2020, for two days of productive cough and fatigue. This patient was diagnosed with ALL in July 2016 and received chemotherapy and CAR-T therapy in a teaching hospital in Wuhan. In July 2019, results of bone marrow puncture confirmed a relapse of ALL. She went to Wuhan city on December 17, 2019, for the first course of chemotherapy after relapse. On January 17, 2020, she returned to her hometown after discharge from Wuhan hospital. She denied the exposure to any confirmed case of COVID-19 on that trip.



**Fig 1.** Radiological characteristics of the chest. (A) Day 1, mild infusion in the right lung in CT; (B) Day 6, mild infusion in the right lung in CT, without obvious deterioration; (C) Day 17, expansion of the lung lesions in CT; (D) Day 22, patchy high-density shadow in both lungs in X-rays; (E) Day 29, substantial improvement with a reduction of pulmonary exudative lesions in X-rays.