



Since January 2020 Elsevier has created a COVID-19 resource centre with free information in English and Mandarin on the novel coronavirus COVID-19. The COVID-19 resource centre is hosted on Elsevier Connect, the company's public news and information website.

Elsevier hereby grants permission to make all its COVID-19-related research that is available on the COVID-19 resource centre - including this research content - immediately available in PubMed Central and other publicly funded repositories, such as the WHO COVID database with rights for unrestricted research re-use and analyses in any form or by any means with acknowledgement of the original source. These permissions are granted for free by Elsevier for as long as the COVID-19 resource centre remains active.



## Epidemiological, clinical characteristics of cases of SARS-CoV-2 infection with abnormal imaging findings

Xiaoli Zhang<sup>1</sup>, Huan Cai<sup>1</sup>, Jianhua Hu<sup>1</sup>, Jiangshan Lian, Jueqing Gu, Shanyan Zhang, Chanyuan Ye, Yingfeng Lu, Ciliang Jin, Guodong Yu, Hongyu Jia, Yimin Zhang, Jifang Sheng<sup>\*</sup>, Lanjuan Li<sup>\*</sup>, Yida Yang<sup>\*</sup>

State Key Laboratory for Diagnosis and Treatment of Infectious Diseases, National Clinical Research Center for Infectious Diseases, Collaborative Innovation Center for Diagnosis and Treatment of Infectious Diseases, The First Affiliated Hospital, College of Medicine, Zhejiang University, No. 79 QingChun Road, Hangzhou, Zhejiang 310003, China

### ARTICLE INFO

#### Article history:

Received 26 February 2020  
Received in revised form 11 March 2020  
Accepted 15 March 2020

#### Keywords:

SRAS-CoV-2  
Imaging findings  
Epidemiological  
Clinical  
Predictive factors

### ABSTRACT

**Purpose:** To investigate the epidemiological and clinical characteristics of COVID-19 patients with abnormal imaging findings.

**Methods:** Patients confirmed with SARS-CoV-2 infection in Zhejiang province from January 17 to February 8 who had undergone CT or X-ray were enrolled. Epidemiological and clinical data were analyzed among those with abnormal or normal imaging findings.

**Results:** Excluding 72 patients with normal images, 230 of 573 patients showed abnormalities affecting more than two lung lobes. The median radiographic score was 2.0, and there was a negative correlation between that score and the oxygenation index ( $\rho = -0.657, P < 0.001$ ). Patients with abnormal images were older ( $46.65 \pm 13.82$ ), with a higher rate of coexisting condition (28.8%), a lower rate of exposure history, and longer time between onset and confirmation (5 days) than non-pneumonia patients (all  $P < 0.05$ ). A higher rate of fever, cough, expectoration and headache, a lower level of lymphocytes, albumin, and serum sodium levels and a higher total bilirubin, creatine kinase, lactate dehydrogenase, and C-reactive protein levels and a lower oxygenation index were observed in pneumonia patients (all  $P < 0.05$ ). Muscle ache, shortness of breath, nausea and vomiting, lower lymphocytes levels, and higher serum creatinine and radiographic score at admission were predictive factors for the severe/critical subtype. **Conclusion:** Patients with abnormal images have more obvious clinical manifestations and laboratory changes. Combining clinical features and radiographic scores can effectively predict severe/critical types.

© 2020 The Author(s). Published by Elsevier Ltd on behalf of International Society for Infectious Diseases. This is an open access article under the CC BY-NC-ND license (<http://creativecommons.org/licenses/by-nc-nd/4.0/>).

### Introduction

At the end of 2019, several cases of atypical pneumonia of unknown aetiology, were initially detected and reported in Wuhan, Hubei province, China. Shortly afterwards, the Chinese Center for Disease Control and Prevention (CDC) identified the novel coronavirus from the throat swab sample of a patient as the causative agent, and officially announced it on 7 January 2020 (Tan and Ma, 2020; World Health Organization, 2020a). The International Committee on Taxonomy of Viruses (Gorbalenya SCB et al., 2020) renamed the previously provisionally named 2019-nCoV as severe acute

respiratory syndrome coronavirus-2 (SARS-CoV-2), one month after the first novel coronavirus infected disease (COVID-19) was diagnosed. As of Feb 9 (18:00 GMT), 2020, there have been 34598 confirmed cases in China, including 723 deaths related to the illness, and 288 cases have been cumulatively reported from other countries, which has caused worldwide concern (World Health Organization, 2020b).

Coronavirus is a kind of enveloped positive-sense RNA virus, named for the crown-like spikes on its surface. It is a complex pathogen due to the ability to infect multiple hosts and cause different diseases in spite of a common association with acute respiratory infections in humans (Fung and Liu, 2019). Frequent interactions of human beings and wild animals make them a common source of zoonotic infections. SRAS-CoV-2 was another identified coronavirus with human infection ability apart from Severe Acute Respiratory Syndrome Coronavirus (SARS-CoV) as was Middle Eastern Respiratory Syndrome Coronavirus (MERS-CoV)

<sup>\*</sup> Corresponding authors.

E-mail addresses: [jifang\\_sheng@zju.edu.cn](mailto:jifang_sheng@zju.edu.cn) (J. Sheng), [ljl@zju.edu.cn](mailto:ljl@zju.edu.cn) (L. Li), [yidayang65@zju.edu.cn](mailto:yidayang65@zju.edu.cn) (Y. Yang).

<sup>1</sup> Xiaoli Zhang, Huan Cai, Jianhua Hu contributed equally to this article.

(Kickbusch and Leung, 2020) and its genomic sequences showed close relation to bat-SL-CoVZC45 and bat-SL-CoVZXC21; homology modeling revealed a similar receptor-binding domain structure to SARS-CoV (Lu et al., 2020).

Viral diagnostics has an important role in this battle against SARS-CoV-2. However, due to the conduction of diagnostic testing for SARS-CoV-2 only at the CDC and the strain of spectrum of the available diagnostic tools for this newly discovered virus at this time (Phan, 2020), imaging examination is one of the quick and convenient methods to diagnosis and monitor disease progress during treatment. However, imaging findings of pneumonia caused by viruses can be completely different, sometimes overlapping with other infectious and inflammatory diseases. It was mentioned in a recent study that included 21 symptomatic patients at the time of initial presentation, that CT findings are variable, ranging from normal to multiple lobes involvement, and as well, patients show different radiologic progression (Chung et al., 2020). Up to now, there is limited information about the clinical features of patients of COVID-19 with abnormal imaging findings. In view of the crucial role of imaging for a diagnostic workup of suspected cases and subsequent care of patients, we retrospectively evaluated the epidemiological, clinical features and laboratory data of 573 cases of COVID-19 presenting with abnormal images.

## Materials and methods

### Subjects and data

For this retrospective study, 645 patients confirmed with SARS-CoV-2 infection between January 17 and February 8, 2020, underwent a CT examination or X-ray, in Zhejiang, China. Patients were admitted to different designated hospitals according to the government emergency rule of Zhejiang province.

Data, including epidemiological, clinical characteristics, laboratory results, and imaging findings, were uniformly collected by the Health Commission of Zhejiang. All data from included cases have been shared with WHO, and the primary analytic results were reported to the authority of Zhejiang. Case collection and analysis were regulated by the Health Commission of Zhejiang under a national authorization. Our study was approved by the medical ethics committee of the First Affiliated Hospital, College of Medicine, Zhejiang University; it conformed to the ethical guidelines of the Helsinki Declaration.

During analysis, patients were divided into two groups according to imaging findings (pneumonia group vs. non-pneumonia group).

### Diagnostic criteria

The diagnosis of novel coronavirus disease (COVID-19) was based on WHO interim guidance (World Health Organization, 2020 c); subtype definition of COVID-19 was according to the diagnosis and treatment scheme for SARS-CoV-2 of China (5th edition) (National Administration of Traditional Chinese Medicine, 2020). For the mild type: slight clinical symptoms with no pneumonia presentation in imaging. For the common type: manifestations such as fever and/or respiratory presentation with pneumonia by radiography. For the severe type (meeting any of the following conditions): (1) dyspnea, RR  $\geq$  30 times/minute; (2) finger oxygen saturation under resting  $\leq$  93%; (3) arterial PaO<sub>2</sub>/FiO<sub>2</sub>  $\leq$  300 mmHg (1 mmHg = 0.133 kPa). For the critical type (meeting any of the following conditions): (1) respiratory failure requiring mechanical ventilation; (2) shock; (3) combined with other organ failures, requiring an intensive care unit.

### Radiographic and pulmonary injury evaluation

The location of the lesion was analyzed by the lobes of the lung. To quantitatively evaluate the pulmonary involvement of all these abnormalities, a semi-quantitative scoring system was proposed according to the chest X-ray scoring standard in the Murray score. Each of the five lung lobes (the upper, lower lobe of the left lung and upper, middle, lower lobe of the right lung) was used as a scoring unit and was visually scored from 0 to 1 thus 0, no involvement, 1, involvement. The total score was the sum of the individual lobar scores with a range from 0 to 5. Radiographs were scored by consensus of two physician reviewers.

Lung injury and hypoxemia can be caused by SARS-CoV-2 infection. To evaluate hypoxemia, arterial blood gas analysis is always adopted. Due to the fact that most patients were supplied oxygen before blood gas analysis was performed, the arterial partial pressure of oxygen (PaO<sub>2</sub>) was not appropriate. Since Horovitz proposed that the oxygenation index was measured by the arterial partial pressure of oxygen to the fraction of inspired oxygen, it has been used as a criterion for acute respiratory distress syndrome and lung injury (Horovitz et al., 1974; Ranieri et al., 2012). Thus, we used the oxygenation index to evaluate pulmonary function.

### Statistical analysis

Statistical analyses were performed using SPSS software (Version 23.0). Continuous variables with a normal distribution were represented by mean  $\pm$  standard deviation (SD), and medians (interquartile range, IQR) were used for abnormally distributed data. The comparison between groups was performed by *t*-test or non-parametric tests when appropriate. Categorical variables were expressed as number (%), and the chi-square test was used for comparison between groups. To assess the association of the radiographic score and oxygenation index, Spearman correlation analysis was used. Binary logistic regression analysis was used for predictive factors associated with severe/critical type pneumonia. All *P*-values were based on a two-tailed test of significance. Statistical significance was always defined as a *P*-value  $<$  0.05.

## Result

### Imaging findings

645 patients infected with SARS-CoV-2 who underwent CT scan or chest radiography at admission, were included in this study; 72 patients had entirely normal CT and radiographic examinations. Excluding those with a normal initial imaging finding, the remaining 573 of 645 patients, by definition, had ground-glass opacities, consolidation, or both, affecting at least one lobe. 139 (21.5%) patients of the total 645 patients had one affected lobe, 204 (31.6%) patients had two affected lobes, 136 (21.1%) patients had three lobes affected, 66 (10.2%) had four affected lobes, and 28 (4.4%) patients had five affected lobes. Of the 645 patients, 432 (67.0%) patients had bilateral lung disease. The right upper lobe was involved in 172 (26.7%) patients, the right middle lobe was involved in 118 (18.3%) patients, and the right lower lobe was involved in 433 (67.1%) patients. 219 (34.0%) patients had the left upper lobe affected, and the left lower lobe was involved in 417 (64.7%) patients (shown in Table 1).

The median of the total radiographic score was 2.0; the radiographic score was significantly correlated with the oxygenation index ( $\rho = -0.657$ ,  $P < 0.001$ ) (Figure 1).

**Table 1**  
Findings on initial imaging in 645 patients.

Characteristics	Patients (n = 645)
Ground-glass opacities and consolidation	
Absence of both ground-glass opacities and consolidation	72 (11.2%)
Presence of either ground-glass opacities or consolidation or both	573 (88.8%)
Number of lobes affected	
1	139 (21.5%)
2	204 (31.6%)
3	136 (21.1%)
4	66 (10.2%)
5	28 (4.4%)
More than 2 lobes affected	230 (35.7%)
Bilateral lung disease	432 (67.0%)
Frequency of lobe involvement	
Right upper lobe	172 (26.7%)
Right middle lobe	118 (18.3%)
Right lower lobe	433 (67.1%)
Left upper lobe	219 (34.0%)
Left lower lobe	417 (64.7%)
Total radiographic score	2.0 (1.0–3.0)

### Demographic, epidemiologic characteristics

The demographic and epidemiologic characteristics of patients are shown in Table 2. 295 (51.5%) of 573 patients were men, and only 37 (6.5%) patients were current smokers. The average age of those with pneumonia was  $46.65 \pm 13.82$  years, which was significantly older than that of those with normal imaging findings ( $P < 0.001$ ). Patients with at least one coexisting underlying conditions and patients with hypertension were observed in 28.8% and 16.8% of the 573 patients, respectively, which was significantly higher than the non-pneumonia patients (all  $P < 0.05$ ). Intriguingly, among the patients with abnormal imaging findings, the proportion who had a clear exposure to Wuhan and/or confirmed patients was 81.0%; this was significantly lower than that of 91.7% of those with normal imaging findings ( $P < 0.05$ ). More importantly, the median time from onset to SARS-CoV-2 infection confirmation was 5.0 (2.5–7.0) days among patients with

abnormal imaging, which was significantly longer when compared to that of non-pneumonia patients ( $P < 0.05$ ).

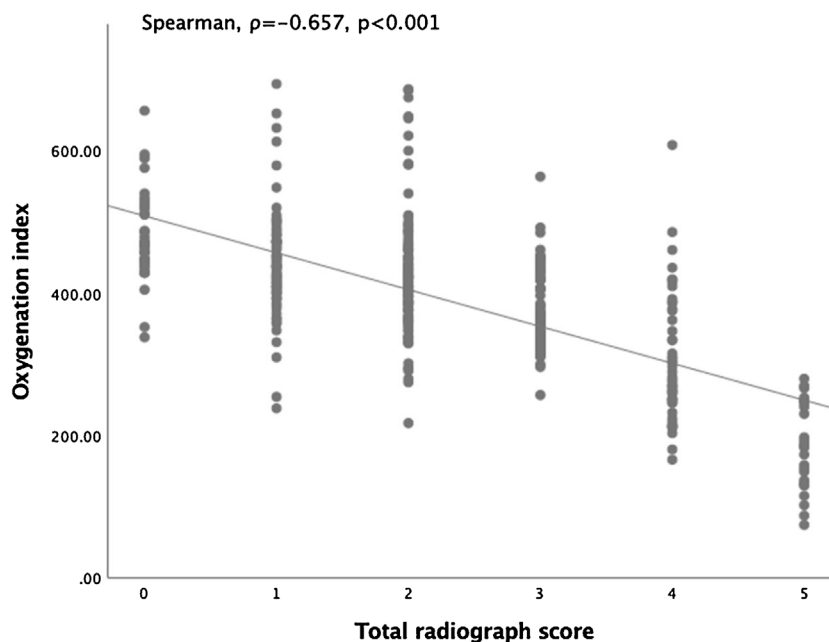
### Clinical symptoms and Laboratory results

The clinical features and characteristics of patients with imaging abnormalities are shown in Table 3. Generally, the symptoms of fever, cough, expectoration, sore throat, and headache were initiated in 85.9%, 68.4%, 36.3%, 14.0%, 11.3% of patients with novel coronavirus pneumonia, respectively, all of which were significantly higher than their respective counterparts with normal imaging findings (all  $P < 0.05$ ). However, concerning other symptoms of COVID-19, including fatigue, shortness of breath, and diarrhea, there were no significant differences between those with normal and those with abnormal imaging findings.

In addition, in the pneumonia patients, the levels of lymphocytes, albumin, and serum sodium were significantly lower as compared to non-pneumonia patients ( $1.23 \pm 0.52$  vs.  $1.39 \pm 0.61$ ;  $41.02 \pm 4.47$  vs.  $42.53 \pm 4.70$ ;  $137.93 \pm 3.76$  vs.  $138.99 \pm 2.79$ , respectively, all  $P < 0.05$ ). Significantly higher levels of total bilirubin, creatine kinase, and lactate dehydrogenase were observed in those with abnormal imaging findings ( $11.26 \pm 8.04$  vs.  $9.11 \pm 4.86$ ;  $73.0$  vs.  $62.5$ ;  $213.0$  vs.  $174.5$ , respectively, all  $P < 0.05$ ). As for infection-related biomarkers, it was observed that the C-reactive protein level of patients with imaging abnormalities was significantly higher than in patients with normal imaging findings (8.8 vs. 2.3,  $P < 0.05$ ). A significantly lower oxygenation index was observed in patients with the appearance of pneumonia compared to the index in those with normal imaging findings (381.46 vs. 478.79,  $P < 0.001$ ) (shown in Table 3).

### Complications and treatment

All patients were treated in isolation with supportive and empiric medication in designated hospitals. As shown in Table 4, 488 (85.2%) patients in the pneumonia group, and 56 (77.8%) patients with non-pneumonia were administered antiviral treatment. If the oxygenation index ( $\text{PaO}_2/\text{FiO}_2$ ) is  $< 300$  mmHg, glucocorticoid therapy is considered; it is not recommended for mild patients. A significantly high rate of corticosteroid therapy



**Figure 1.** The total radiographic score was significantly correlated with the oxygenation index.

**Table 2**  
Demographic and epidemiologic characteristics of patients infected with 2019-nCoV with normal or abnormal imaging findings.

Characteristics	Normal imaging findings (n = 72)	Abnormal imaging findings (n = 573)	P value
Age	34.90 ± 14.20	46.65 ± 13.82	<0.001
Sex (male/female)	33 (45.8%)/39 (54.2%)	295 (51.5%)/278 (48.5%)	0.366
Current smoker (yes/no)	4 (5.6%)/68 (94.4%)	37 (6.5%)/536 (93.5%)	0.969
Exposure history: from Wuhan and/or contact with confirmed patients (yes/no)	66 (91.7%)/6 (8.3%)	464 (81.0%)/109 (19.0%)	0.026
Coexisting condition (yes/no)			
Any (yes/no)	12 (16.7%)/60 (83.3%)	165 (28.8%)/408 (71.2%)	0.03
Hypertension (yes/no)	4 (5.6%)/68 (94.4%)	96 (16.8%)/477 (83.2%)	0.013
Diabetes (yes/no)	4 (5.6%)/68 (94.4%)	44 (7.7%)/529 (92.3%)	0.518
Heart disease (yes/no)	0 (0.0%)/72 (100.0%)	5 (1.0%)/568 (99.0%)	1.000
COPD (yes/no)	0 (0.0%)/72 (100.0%)	1 (0.0%)/572 (100.0%)	1.000
Chronic liver disease (yes/no)	2 (2.8%)/70 (97.2%)	23 (4.0%)/550 (96.0%)	0.851
Chronic renal disease (yes/no)	0 (0.0%)/72 (100.0%)	6 (1.0%)/567 (99.0%)	0.825
Cancer (yes/no)	0 (0.0%)/72 (100.0%)	6 (1.0%)/567 (99.0%)	0.825
Others (yes/no)	3 (4.2%)/69 (95.8%)	37 (6.5%)/536 (93.5%)	0.617
Time from onset to be confirmed (days)	2 (1–4)	5 (2.5–7)	<0.001

**Table 3**  
Clinical characteristics and laboratory results of patients infected with 2019-nCoV with normal or abnormal imaging findings.

Characteristics	Normal imaging findings (n = 72)	Abnormal imaging findings (n = 573)	P value
Fever (yes/no)	48 (66.7%)/24 (33.3%)	492 (85.9%)/81 (14.1%)	<0.001
Cough (yes/no)	33 (45.8%)/39 (54.2%)	392 (68.4%)/181 (31.6%)	0.016
Expectoration (yes/no)	17 (23.6%)/55 (76.4%)	208 (36.3%)/365 (63.7%)	0.033
Hemoptysis (yes/no)	0 (0.0%)/72 (100.0%)	11 (2.0%)/562 (98.0%)	0.482
Sore throat (yes/no)	17 (23.6%)/55 (76.4%)	80 (14.0%)/493 (86.0%)	0.031
Nasal obstruction (yes/no)	7 (9.7%)/65 (90.3%)	29 (5.1%)/544 (94.9%)	0.177
Muscle ache (yes/no)	5 (7.0%)/67 (93.0%)	66 (11.5%)/507 (88.5%)	0.243
Fatigue (yes/no)	9 (12.5%)/63 (87.5%)	109 (19.0%)/464 (81.0%)	0.177
Shortness of breath (yes/no)	0 (0.0%)/72 (100.0%)	26 (4.5%)/547 (95.5%)	0.127
Diarrhea (yes/no)	8 (11.1%)/64 (88.9%)	45 (7.9%)/528 (92.1%)	0.343
Nausea and vomiting (yes/no)	0 (0.0%)/72 (100.0%)	22 (3.8%)/551 (96.2%)	0.178
Headache (yes/no)	2 (2.8%)/70 (97.2%)	65 (11.3%)/508 (88.7%)	0.025
Blood routine			
Leucocytes (× 10 <sup>9</sup> per L; normal range 4–10)	5.42 ± 2.00	5.01 ± 1.87	0.079
Neutrophils (× 10 <sup>9</sup> per L; normal range 2–7)	3.48 ± 1.88	3.29 ± 1.68	0.397
Lymphocytes (× 10 <sup>9</sup> per L; normal range 0.8–4)	1.39 ± 0.61	1.23 ± 0.52	0.021
Hemoglobin (g/L; normal range : male 131–172, female 113–151)	141.04 ± 15.62	138.09 ± 16.47	0.15
Platelets (× 10 <sup>9</sup> per L; normal range: male 83–303, female 101–320)	198.44 ± 58.44	185.22 ± 62.42	0.088
International normalized ratio (normal range 0.85–1.15)	1.03 ± 0.09	1.04 ± 0.10	0.384
Blood biochemistry			
Albumin (g/L; normal range 40–55)	42.53 ± 4.70	41.02 ± 4.47	0.007
Alanine aminotransferase (U/L; male normal range 9–50, female 7–40)	25.53 ± 19.96	29.37 ± 25.71	0.222
Aspartate aminotransferase (U/L; male normal range 15–40, female 13–35)	25.67 ± 15.52	30.08 ± 20.37	0.077
Total bilirubin (μmol/L; normal range 0–26)	9.11 ± 4.86	11.26 ± 8.04	0.027
Serum potassium (mmol/L; normal range 3.5–5.3)	3.88 ± 0.42	3.85 ± 0.44	0.632
Serum sodium (mmol/L; normal range 137–147)	138.99 ± 2.79	137.93 ± 3.76	0.021
Blood urea nitrogen (mmol/L; normal range 3.1–8)	3.90 ± 1.13	4.04 ± 1.69	0.505
Serum creatinine (μmol/L; normal range: male 57–97, female 41–73)	65.54 ± 13.16	69.17 ± 24.52	0.053
Creatine kinase (U/L; normal range 50–310)	62.5 (47–83.75)	73.0 (48.0–111.0)	0.01
Lactate dehydrogenase (U/L; normal range 120–250)	174.5 (148–235.5)	213.0 (173.0–268.0)	<0.001
Glucose (mmol/L; normal range 3.9–6.1)	6.57 ± 3.24	6.62 ± 2.91	0.891
Infection-related biomarkers			
Procalcitonin (ng/mL; normal range 0.0–0.5)	0.05 (0.04–0.07)	0.05 (0.04–0.08)	0.415
C-reactive protein (mg/L; normal range 0.0–5.0)	2.3 (0.9–9.5)	8.8 (3.1–22.0)	<0.001
Oxygenation index (PO <sub>2</sub> /FiO <sub>2</sub> )	478.79 (468.93–478.79)	381.46 (354.73–419.05)	<0.001

was recorded in the pneumonia patients compared to the non-pneumonia group (13.4% vs. 0.0%,  $P = 0.001$ ).

As well, a significantly higher rate of oxygen therapy was recorded in patients with abnormal imaging findings than in patients with normal imaging (43.6% vs. 11.1%,  $P < 0.001$ ). Nine of 573 patients received mechanical ventilation. Up until Feb 8, only four patients had been admitted into the intensive-care unit. No patients were treated with continuous blood purification and extracorporeal membrane oxygenation (EMCO).

Liver injury was the most common complication (in 75 patients), followed by acute respiratory distress (in 14 patients)

among the pneumonia patients. By the end of Feb 8, all patients survived.

#### Clinical predictive factors for severe/critical novel coronavirus pneumonia

According to the diagnosis and treatment protocols for SARS-CoV-2 of China (5th edition), a total of 64 patients were confirmed with severe/critical novel coronavirus pneumonia among those with abnormal images. Our univariate analysis showed that 30 risk factors (age, gender, time from onset to be confirmed, etc., shown

**Table 4**

Complications and treatments of patients infected with 2019-nCoV with normal or abnormal imaging findings.

	Normal imaging findings (n = 72)	Abnormal imaging findings (n = 573)	P value
<b>Complications</b>			
Acute respiratory distress syndrome (yes/no)	0 (0.00)/72 (100.0%)	14 (2.4%)/559 (97.6%)	0.362
Shock (yes/no)	0 (0.00)/72 (100.0%)	2 (0.3%)/571 (99.7%)	1.000
Liver function abnormality (yes/no)	6 (8.3%)/66 (91.7%)	75 (13.1%)/498 (86.9%)	0.251
Acute kidney injury (yes/no)	0 (0.00)/72 (100.0%)	2 (0.3%)/571 (99.7%)	1.000
<b>Treatments</b>			
Anti-coronavirus treatment (yes/no)	56 (77.8%)/16 (22.2%)	488 (85.2%)/85 (14.8%)	0.104
Glucocorticoids (yes/no)	0 (0.00)/72 (100.0%)	77 (13.4%)/496 (86.6%)	0.001
Oxygen therapy (yes/no)	8 (11.1%)/64 (88.9%)	250 (43.6%)/323 (56.4%)	<0.001
Mechanical ventilation (including non-invasive and invasive)	0 (0.0%)/72 (100.0%)	9 (1.6%)/564 (98.4%)	0.591
CRRT (yes/no)	0 (0.0%)/72 (100.0%)	0 (0.0%)/573 (100.0%)	
ECMO (yes/no)	0 (0.0%)/72 (100.0%)	0 (0.0%)/573 (100.0%)	
Admission to intensive unit (yes/no)	0 (0.0%)/72 (100.0%)	4 (0.7%)/569 (99.3%)	0.622

in Table 5) were associated with severe/critical novel coronavirus pneumonia when compared with mild and common subtypes ( $P < 0.05$ ). However, further multivariate analysis was performed based on these variables; this analysis showed that symptoms of muscle ache ( $P = 0.002$ ), shortness of breath ( $P = 0.002$ ), nausea and vomiting ( $P = 0.001$ ), combined with higher serum creatinine level ( $P = 0.004$ ) and lower lymphocytes levels ( $P = 0.008$ ) and accompanied with a higher total radiographic score were the possible predictive factors for the severe/critical subtype (shown in Table 5)

## Discussion

The recent emergence of SARS-CoV-2 has caused an outbreak of unusual viral pneumonia in patients in Wuhan, China. In a short period, national spreading and global dispersal of the causative agent have become a significant threat to global health (Biscayart et al., 2020; World Health Organization, 2020a). The symptoms of COVID-19 are similar to other respiratory viruses, including fever, cough, fatigue, diarrhea, and vomiting, with radiographs showing invasive lesions in the lung. Some of these patients may present with serious complications such as acute respiratory distress syndrome or shock (Chen et al., 2020; Huang et al., 2020; Zhu et al., 2020). With the continuous improvement of modern imaging technology, an imaging examination is more conducive to the objective assessment and early detection of lung abnormalities. In view of the current situation that radiographic images conform to features of SARS-CoV-2 pneumonia while the etiology test is negative at initial testing, until subsequent repeated tests are positive (Xie et al., 2020), it is necessary to combine imaging with clinical features for the best diagnosis. In our retrospective study, we evaluated and compared the epidemiological, clinical features, and laboratory data of those with abnormal imaging findings.

The imaging findings of SARS-CoV-2 pneumonia are similar to acute respiratory syndrome (SARS) and Middle East respiratory syndrome (MERS), which are characterized as pulmonary ground-glass opacities and consolidation (Das et al., 2016; Kanne, 2020; Wong et al., 2003). On the basis of our study, we found a total of 72 patients infected with SARS-CoV-2 were absent of both ground-glass opacities and consolidation. More than two lobes affected with the appearance of ground-glass or consolidation was observed in 230 (35.7%) patients, suggesting COVID-19 is prone to multifocal involvement, consistent with a previous report (Chung et al., 2020). There are some identifiable characteristics of chest images of this novel coronavirus pneumonia. However, there is limited information about the difference between cases of COVID-19 presenting with or without abnormal imaging findings.

We evaluated the basic and clinical characteristics of SARS-CoV-2 pneumonia. Among those with abnormal images, fever and

cough are the most common symptoms, followed by sputum production; this is consistent with a former report (Chen et al., 2020). Different from the previous report, which showed a tendency for infection in older (median 55.5y), men (68%) with an underlying medical condition (50%), the average age of novel coronavirus pneumonia was  $46.65 \pm 13.82y$ , the gender ratio was close to 1:1, and the rate of patients with the coexisting condition was 28.8% in our study (Chen et al., 2020). One possible explanation for this difference was that the number of cases of our study was larger than that of 99 cases. Another was that our study was carried out in Zhejiang province, far away from Wuhan. Another explanation is that SARS-CoV-2 itself may have had changes in virulence during human-to-human dissemination, including its epidemiological features. Our results may suggest a general susceptibility.

Compared to patients with normal imaging findings, the average age of the patients with the appearance of pneumonia was older, and the rate of at least one coexisting medical condition was higher. This may suggest that relatively older patients with accompanying chronic diseases are more prone to have lung injury. Interestingly, the rates of exposure history from Wuhan and/or contact with confirmed patients were higher, and the time from onset to SARS-CoV-2 infection confirmation was shorter in non-pneumonia patients. A possible explanation for these results was that those patients were in the process of medical observation. These patients were asked to submit to testing, if they experienced any discomfort, to determine whether the SARS-CoV-2 was positive; some patients even initiated a request to ask for testing.

In addition, we identified a significantly higher rate of symptoms of fever, cough, sputum production, and headache in patients with abnormal imaging findings. However, the rate of a sore throat in patients with abnormal images was substantially lower than that of their counterpart. Since a former report indicated that the initial and early-progress radiograph can be normal (Holshue et al., 2020), the clinical symptoms were neither typical nor obvious. The imaging of non-pneumonia patients at initial admission may gradually progress. There was no obvious abnormality in CT examination of patients with a positive nucleic acid test, which suggested that there might be some lag between X-ray and CT examination; those patients should be monitored closely in case of necessary timely treatment. However, in contrast with patients infected with H1N1 in which diarrhea is associated with chest X-ray abnormalities (Cao et al., 2009), differences in gastrointestinal symptoms of the two groups in our study were not significant. One possible explanation is that SARS-CoV-2 can bind to ACE2 in the intestinal tract (Hao Zhang et al., 2020; Wan et al., 2020) while H1N1 binds to Sa $\alpha$ 2, 3Gal receptor (Riquelme et al., 2009); however, the specific mechanism is not clear at present.

**Table 5**  
Univariate and multivariate logistic regression analysis of predictors for severe/critical pneumonia.

Variable	Univariate analysis			Multivariate analysis		
	OR	95% CI	P-value	OR	95% CI	P-value
Age	1.04	1.02–1.06	<0.001			
Sex (male/female)	2.09	1.21–3.62	0.009			
Time from onset to be confirmed	1.11	1.04–1.18	0.001			
Coexisting Condition (yes/no)						
Any	4.08	2.39–6.96	<0.001			
Hypertension	3.95	2.26–6.93	<0.001			
Diabetes	2.22	1.01–4.84	0.047			
Cancer	8.30	1.64–42.01	0.011			
Symptoms (yes/no)						
Fever	3.68	1.13–12.02	0.031			
Cough	2.73	1.36–5.50	0.005			
Expectoration	2.03	1.20–3.43	0.008			
Hemoptysis	7.11	2.10–23.99	0.002			
Muscle ache	2.74	1.44–5.25	0.002	4.67	1.75–12.46	0.002
Fatigue	1.97	1.10–3.52	0.023			
Shortness of breath	38.11	14.55–99.82	<0.001	9.02	2.20–37.01	0.002
Diarrhea	3.80	1.88–7.70	<0.001			
Nausea and vomiting	5.05	2.03–12.57	<0.001	15.55	2.86–84.50	0.001
Headache	1.99	1.00–3.96	0.051			
Laboratory results						
Leucocytes	1.19	1.05–1.33	0.005			
Neutrophils	1.33	1.17–1.51	<0.001			
Lymphocytes	0.12	0.054–0.25	<0.001	0.26	0.09–0.70	0.008
International normalized ratio	10.98	1.20–100.69	0.034			
Albumin	0.83	0.77–0.88	<0.001			
Aspartate aminotransferase	1.01	1.00–1.02	0.043			
Serum sodium	0.93	0.87–0.99	0.023			
Blood urea nitrogen	1.18	1.04–1.33	0.012			
Serum creatinine	1.02	1.01–1.03	0.004	1.03	1.00–1.05	0.004
Creatine kinase	1.001	1.000–1.002	0.007			
Lactate dehydrogenase	1.003	1.001–1.004	0.004			
Glucose	1.10	1.03–1.18	0.004			
C-reactive protein	1.03	1.02–1.04	<0.001			
Total radiograph score	6.43	4.35–9.49	<0.001	6.28	3.90–10.10	<0.001

Laboratory results were also monitored, since we found that the patients with imaging abnormalities had lower lymphocytes, albumin, serum sodium levels, and higher lactate dehydrogenase and C-reactive protein levels. This finding may suggest that having pneumonia may be associated with severe disease, thus these patients tended to have more severe clinical features. This was in accordance with a lower oxygenation index, an index to evaluate the respiratory function and the severity of the disease. For further study, a radiographic score which may be helpful for a rough estimation of lung lesions was proposed. Then we found a significant negative correlation ( $\rho = -0.657, P < 0.001$ ) between the radiographic score and the oxygenation index. Therefore, we presume that the more involvement of the lobes, the worse are pulmonary functions.

Currently, no effective antiviral therapy for COVID-19 was confirmed (Zhang and Liu, 2020). Interferon- $\alpha$ , Lopinavir/Ritonavir, and Arbidol were used based upon previous experience; however, there is a lack of evidence for a unified treatment plan. Given the significantly higher rate of glucocorticoid application in patients with abnormal imaging than that of their counterpart, a former study showed proper use of corticosteroids in critical SARS reduced mortality (Chen et al., 2006). Thus, patients with multiple lobes involvement may be considered for corticosteroids to control the progression of disease. Oxygen therapy plays a key role in the supportive treatment of patients. Generally, patients with hypoxemia ( $\text{PaO}_2 < 60$  mmHg or  $\text{SaO}_2 < 90\%$  in the air condition) or with the symptoms of dyspnea may be considered for oxygen therapy by nasal cannula or mask. When the symptom of hypoxemia is improved ( $\text{SaO}_2 > 90\%$  or the level of  $\text{PaO}_2$  reaches 60–70 mmHg), the flow of oxygen can be gradually reduced and even stopped. Otherwise, high flow oxygen inhalation or noninvasive ventilation

should be considered, and invasive ventilation can be adopted if the disease still progresses (National Administration of Traditional Chinese Medicine, 2020). However, some patients may be administered low flow oxygen therapy on admission to reduce the burden on the lungs. In our study, we also found the rate of oxygen therapy in patients with abnormal imaging was significantly higher, which may be related to a lower oxygenation index. Given the current stage of exploring a standard treatment regimen, we are not sure that the early use of oxygen therapy is helpful for prognosis, which should be further studied.

We also analyzed in depth the predictive factors of severe/critical novel coronavirus pneumonia. Patients with symptoms of shortness of breath, nausea and vomiting tended to be severe. Similar results related to H1N1 pneumonia had been found in a previous report, showing that these symptoms mentioned above were risk factors (Kanchana et al., 2013; Na et al., 2011). Lower lymphocytes level at initial admission was also a significant predictive factor; this was also described as a prognostic indicator for ARDS and death in H5N1 and H1N1 infections (Chotpitayasu-nondh et al., 2005; Reyes et al., 2011). In addition, we found higher serum creatinine was one of the predictors, similarly to a former study that revealed acute kidney injury was a common complication of severe H1N1 infection associated with a higher mortality (Trimarchi et al., 2010). A higher radiographic score was associated with the severity of the disease, following a previous report which used different CT score (Xu et al., 2020). These clinical features may be a useful tool for predicting the severe/critical type as they are convenient to use in hospitals.

There are several limitations to our study. Firstly, at the time of this writing, only preliminary data have been collected, and many patients still remained in the hospital; it is better to obtain

progressive images and to follow the outcomes of patients. Secondly, the description of radiographic images should be more detailed, both of which may be helpful for the analysis of the disease and the treatment in later stages. Thirdly, our study was limited by the observational nature of the investigation. Finally, according to the admission data, risk factors for severe/critical type of COVID-19 were identified; however, we still lack a prediction model for disease progression.

In conclusion, there are certain characteristics of the chest imaging of COVID-19 patients; we reported the differences in specific epidemiological and clinical features between patients with abnormal or normal imaging, including fever, cough and sputum production, and relatively poor laboratory results. Symptoms of muscle ache, shortness of breath and nausea and vomiting, lower lymphocytes, and higher serum creatinine and radiograph score were predictive factors for severe/critical subtype.

## Funding

National Major Science and Technology Research projects for the Control and Prevention of Major Infectious Diseases in China (2017ZX10202202).

## Acknowledgments

We thank the Health Commission of Zhejiang Province, China, for coordinating data collection.

## Conflict of interest

None declared.

## References

- Gorbalenya SCB AE, Baric RS, de Groot RJ, Drosten C, Gulyaeva AA, Haagmans BL, et al. Severe acute respiratory syndrome-related coronavirus: the species and its viruses—a statement of the Coronavirus Study Group. *bioRxiv* 2020;. doi:<http://dx.doi.org/10.1101/20200207937862> [Accessed 11 Mar 2020].
- Biscayart C, Angeleri P, Lloveras S, TdSS Chaves, Schlagenhaut P, Rodriguez-Morales AJ. The next big threat to global health? 2019 novel coronavirus (2019-nCoV): what advice can we give to travellers? - interim recommendations January 2020, from the Latin-American Society for Travel Medicine (SLAMVI). *Travel Med Infect Dis* 2020;101567.
- Cao B, Li XW, Mao Y, Wang J, Lu HZ, Chen YS, et al. Clinical features of the initial cases of 2009 pandemic influenza A (H1N1) virus infection in China. *N Engl J Med* 2009;361(26):2507–17.
- Chen N, Zhou M, Dong X, Qu J, Gong F, Han Y, et al. Epidemiological and clinical characteristics of 99 cases of 2019 novel coronavirus pneumonia in Wuhan, China: a descriptive study. *Lancet* 2020;.
- Chen RC, Tang XP, Tan SY, Liang BL, Wan ZY, Fang JQ, et al. Treatment of severe acute respiratory syndrome with glucocorticoids: the Guangzhou experience. *Chest* 2006;129(6):1441–52.
- Chotpitayasunondh T, Ungchusak K, Hanshaoworakul W, Chunsuthiwat S, Sawanpanyalert P, Kijphati R, et al. Human disease from influenza A (H5N1), Thailand, 2004. *Emerg Infect Dis* 2005;11(2):201–9.
- Chung M, Bernheim A, Mei X, Zhang N, Huang M, Zeng X, et al. CT imaging features of 2019 Novel Coronavirus (2019-nCoV). *Radiology* 2020;200230.
- Das KM, Lee EY, Langer RD, Larsson SG. Middle east respiratory syndrome coronavirus: what does a radiologist need to know?. *Am J Roentgenol* 2016;206(6):1193–201.
- Fung TS, Liu DX. Human coronavirus: host-pathogen interaction. *Annu Rev Microbiol* 2019;73:529–57.
- Hao Zhang ZKHG, Da X, Jing W, Zifu Li. The digestive system is a potential route of 2019-nCoV infection: a bioinformatics analysis based on single-cell transcriptomes. *bioRxiv* 2020;.
- Holshue ML, DeBolt C, Lindquist S, Lofy KH, Wiesman J, Bruce H, et al. First case of 2019 novel coronavirus in the United States. *N Engl J Med* 2020;.
- Horowitz JH, Carrico CJ, Shires GT. Pulmonary response to major injury. *Arch Surg* 1974;108(3):349–55.
- Huang C, Wang Y, Li X, Ren L, Zhao J, Hu Y, et al. Clinical features of patients infected with 2019 novel coronavirus in Wuhan, China. *Lancet* 2020;.
- Kanchana S, Kanchana S, Vijitsopa T, Thammakumpee K, Yamwong S, Sawanya-wisuth K. Clinical factors predictive of pneumonia caused by pandemic 2009 H1N1 influenza virus. *Am J Trop Med Hyg* 2013;88(3):461–3.
- Kanne JP. Chest CT findings in 2019 novel coronavirus (2019-nCoV) Infections from Wuhan, China: key points for the radiologist. *Radiology* 2020;200241.
- Kickbusch I, Leung G. Response to the emerging novel coronavirus outbreak. *BMJ* 2020;368:m406.
- Lu R, Zhao X, Li J, Niu P, Yang B, Wu H, et al. Genomic characterisation and epidemiology of 2019 novel coronavirus: implications for virus origins and receptor binding. *Lancet* 2020;.
- National Administration of Traditional Chinese Medicine. Diagnosis and treatment of novel coronavirus infected pneumonia (the fifth edition). 2020. <http://www.satcm.gov.cn>.
- Na S, Kim MN, Kim WY, Kim W, Hong SB, Lim CM, et al. Prevalence and clinical features of pneumonia in patients with laboratory-confirmed pandemic influenza A H1N1 2009 infection in South Korea. *Scand J Infect Dis* 2011;43(1):19–26.
- Phan T. Novel coronavirus: From discovery to clinical diagnostics. *Infect Genet Evol* 2020;79:104211.
- Ranieri VM, Rubenfeld GD, Thompson BT, Ferguson ND, Caldwell E, Fan E, et al. Acute respiratory distress syndrome: the Berlin definition. *JAMA* 2012;307(23):2526–33.
- Reyes S, Montull B, Martinez R, Cordoba J, Molina JM, Marti V, et al. Risk factors of A/H1N1 etiology in pneumonia and its impact on mortality. *Respir Med* 2011;105(9):1404–11.
- Riquelme A, Alvarez-Lobos M, Pavez C, Hasbun P, Dabanch J, Cofre C, et al. Gastrointestinal manifestations among Chilean patients infected with novel influenza A (H1N1) 2009 virus. *Gut* 2009;58(11):1567–8.
- Tan WJZX, Ma XJ. A novel coronavirus genome identified in a cluster of pneumonia cases—Wuhan, China 2019–2020. *China CDC Weekly* 2020;2:61–2.
- Trimarchi H, Greloni G, Campolo-Girard V, Giannasi S, Pomeranz V, San-Roman E, et al. H1N1 infection and the kidney in critically ill patients. *J Nephrol* 2010;23(6):725–31.
- Wan Y, Shang J, Graham R, Baric RS, Li F. Receptor recognition by novel coronavirus from Wuhan: an analysis based on decade-long structural studies of SARS. *J Virol* 2020;.
- Wong KT, Antonio GE, Hui DSC, Lee N, Yuen EHY, Wu A, et al. Severe acute respiratory syndrome: radiographic appearances and pattern of progression in 138 patients. *Radiology* 2003;228(2):401–6.
- World Health Organization. Novel coronavirus-China. Jan 12, 2020. 2020. <http://www.who.int/csr/don/12-january-2020-novel-coronavirus-china/en/>.
- World Health Organization. Novel coronavirus (2019-nCoV) situation report. [https://www.who.int/docs/default-source/coronaviruse/situation-reports/20200208-sitrep-19-ncov.pdf?sfvrsn=6e091ce6\\_2](https://www.who.int/docs/default-source/coronaviruse/situation-reports/20200208-sitrep-19-ncov.pdf?sfvrsn=6e091ce6_2).
- World Health Organization. Clinical management of severe acute respiratory infection when novel coronavirus (2019-nCoV) infection is suspected: interim guidance. Jan 11, 2020. [https://www.who.int/publications-detail/clinical-management-of-severe-acute-respiratory-infection-when-novel-coronavirus-\(ncov\)-infection-is-suspected](https://www.who.int/publications-detail/clinical-management-of-severe-acute-respiratory-infection-when-novel-coronavirus-(ncov)-infection-is-suspected).
- Xie X, Zhong Z, Zhao W, Zheng C, Wang F, Liu J. Chest CT for Typical 2019-nCoV pneumonia: relationship to negative RT-PCR testing. *Radiology* 2020;200343.
- Xu X, Yu C, Qu J, Zhang L, Jiang S, Huang D, et al. Imaging and clinical features of patients with 2019 novel coronavirus SARS-CoV-2. *Eur J Nucl Med Mol Imaging* 2020;.
- Zhang L, Liu Y. Potential interventions for novel coronavirus in China: A systematic review. *J Med Virol* 2020;.
- Zhu N, Zhang D, Wang W, Li X, Yang B, Song J, et al. A Novel Coronavirus from patients with pneumonia in China, 2019. *N Engl J Med* 2020;.