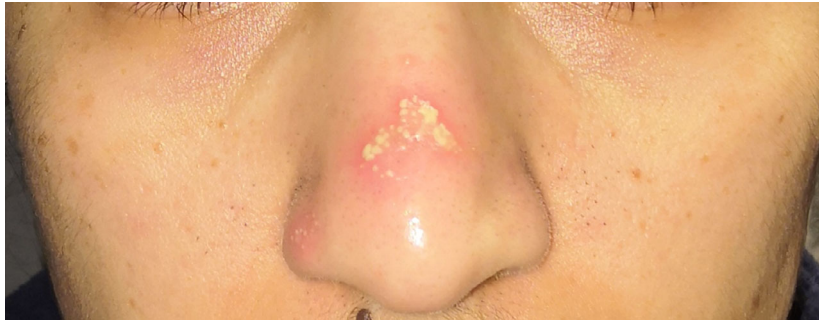



**Figure 1** Crops of 1–2 mm pustules with background erythema over the nasal bridge, sidewall and ala, clinically in keeping with localized miliaria.

background erythema were evident over the nasal bridge, sidewall and ala, clinically in keeping with localized miliaria (Fig. 1), with the differential being an occlusive (infective) folliculitis. Whilst tender on palpation, the area was not overtly cellulitic. Given that the epidermis was intact, and wanting to avoid further compromise to the skin barrier, bacterial swabs were not performed. Dermol<sup>®</sup> 500 (Dermal Laboratories Ltd, Hertfordshire, UK) lotion was prescribed as an antiseptic soap substitute and emollient. Two weeks later, post-inflammatory hyperpigmentation was apparent in each case, with some residual scaling and dryness.

Miliaria, otherwise known as heat rash, is a disorder of eccrine glands due to obstruction and retention of sweat. It is usually associated with immobility, hot/humid environments and improper clothing or bedding which traps heat and perspiration. Within the clinical setting, it is most often seen in febrile inpatients who have been supine for extended periods. There are three subtypes – miliaria crystallina (typically face and trunk), miliaria rubra/pustulosa (most common; typically on the back) and miliaria profunda (rare; trunk and extremities).<sup>5</sup>

To our knowledge, this is the first report of a localized facial miliaria secondary to FFP use. It is recognized that epidermal barrier interruption could enhance COVID-19 acquisition<sup>6</sup> and as such, it is fundamental that steps are taken to minimize tissue trauma from PPE use, and to report such cases.

### Acknowledgement

Informed written consent was gained for publication of clinical history and photographs.

### Funding source

none.

V. Campbell,<sup>1,\*</sup>  D. Middleton,<sup>1</sup> J. Donnelly,<sup>2</sup> H. Hunter<sup>1</sup>

<sup>1</sup>Department of Dermatology, Royal Victoria Hospital, Belfast, UK, <sup>2</sup>Tissue Viability Lead Nurse, Belfast Health & Social Care Trust, Belfast, UK

\*Correspondence: V. Campbell. E-mail: victoriacampbell@doctors.org.uk

### References

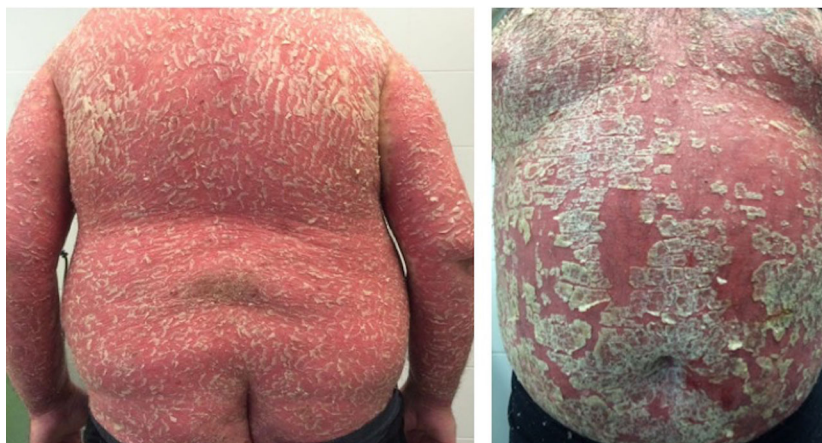- 1 Darlenski R, Tsankov N. Covid-19 pandemic and the skin - what should dermatologists know? *Clin Dermatol* 2020. (epub ahead of print).
- 2 NHS England. Helping prevent facial skin damage beneath personal protective equipment, 2020. URL [https://www.england.nhs.uk/coronavirus/wp-content/uploads/sites/52/2020/04/C0129\\_Preventing-skin-damage-under-PPE\\_9-April.pdf](https://www.england.nhs.uk/coronavirus/wp-content/uploads/sites/52/2020/04/C0129_Preventing-skin-damage-under-PPE_9-April.pdf) (last accessed: 20 April 2020).
- 3 Yan Y, Chen H, Chen L *et al*. Consensus of Chinese experts on protection of skin and mucous membrane barrier for healthcare workers fighting against coronavirus disease 2019. *Dermatol Ther* 2020: e13310.
- 4 Wang JV, Parish LC. Dermatologic manifestations of the 1918–1919 influenza pandemic. *Skinmed* 2019; **17**: 296–297.
- 5 Miliaria GG. *Inpatient Dermatology*, Springer, Cham, 2018: 383–385.
- 6 Tao J, Song Z, Yang L, Huang C, Feng A, Man X. Emergency management for preventing and controlling nosocomial infection of 2019 novel coronavirus: implications for the dermatology department. *Br J Dermatol* 2020 (epub ahead of print).

DOI: 10.1111/jdv.16624

## COVID-19 pulmonary infection in erythrodermic psoriatic patient with oligodendroglioma: safety and compatibility of apremilast with critical intensive care management

Dear Editor,

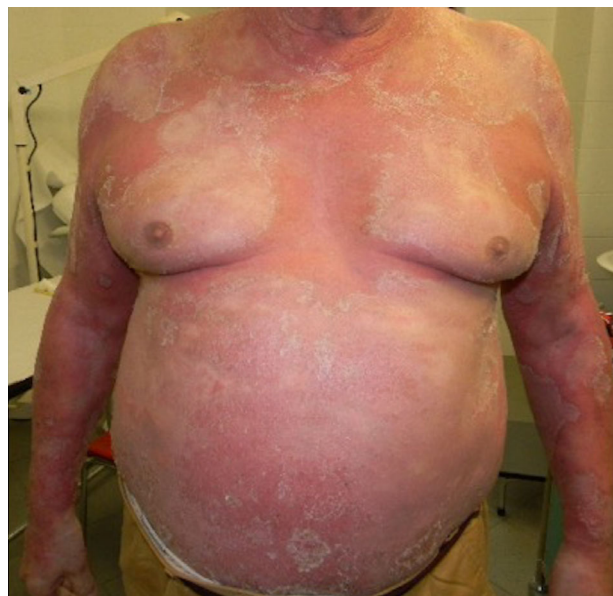Novel coronavirus 2019 (SARS-CoV2) pandemic has particularly affected Italy, with a profound impact on the therapeutic strategy for complex disorder such as psoriasis, whose extensive skin damage might expose to an increased infective risk compared to the general population.<sup>1–4</sup> Psoriasis treatment relies on immunosuppression, and although most experts agree that the benefit-to risk-ratio is in favour of maintaining selective biological therapies, and small molecules such as apremilast, they recommend dismission if severe COVID-19 symptoms occur.<sup>5,6</sup>



**Figure 1** Severe erythrodermic psoriasis (PASI 45) before apremilast treatment.

We report a patient with erythrodermic psoriasis, with contraindication to most treatments because of a recurrent brain oligodendroglioma, who was under apremilast therapy while contracting SARS-CoV-2 pneumonia. The 45-year-old obese (BMI 36.33) white man, with a decennial history of severe psoriasis and arthritis, treated with all traditional and biological drugs had to start chemotherapy with temozolomide, for the brain oligodendroglioma not operable recurrence. Its psoriasis had worsened to erythroderma (Fig. 1), only partially controlled by prednisone 50 mg/day, and in agreement with the neuro-oncologist, apremilast 30 mg orally twice a day was started. The patient gradually improved, allowing prednisone tapering to a minimal dose of 12.5 mg daily. On February 19, 2020, he was enough stabilized to travel to Milan, Northern Italy, to be evaluated for brain radiotherapy. On February 26, he developed a severe cough with high fever (TC 40°C) and a chest X-Ray revealed bilateral interstitial pneumonia with positive swab to SARS CoV2. After referral to the Infective Disease Unit, the patient started treatment with Lopinavir/Ritonavir 400/100 mg twice a day and intravenous Ceftriaxone 2 g/day. He was discharged on March 3, clinically healed after two consecutive negative SARS-CoV-2 swabs. Apremilast had never been stopped during the COVID-19 hospitalization, with acceptable control of the psoriasis, limited to mild scaling and erythema, especially on the trunk (Fig. 2).

The fact that patient with a severe form of psoriasis contracted the COVID-19 pneumonia, while on treatment with apremilast is worth of some considerations. First of all, the information of apremilast safety, not interfering with the infection, as the drug was not interrupted during the whole course of the infection. Our patient had several risk factors for a worst outcome: obesity, recent chemotherapy, persistence of brain oligodendroglioma and viral contagion in a nosocomial setting. By converse, the infection recovered rapidly and the patient was discharged 6 days after the onset of symptoms. Apremilast has previously demonstrated a



**Figure 2** The patient improvement under apremilast treatment, after the COVID-19 recovery.

long-term safety profile in the setting of serious infections such as HIV, HBV and HCV.<sup>7,8</sup> However, therapeutic strategy during severe COVID-19 pneumonia are still in the process of definition, and it was quite surprising apremilast was maintained. We cannot rule out that apremilast anti-inflammatory activity might have played a role in the rapid recovery. The selective inhibition of the enzyme phosphodiesterase 4 (PDE4) allows higher levels of cyclic AMP, which decreases the production of inflammatory cytokines such as tumour necrosis factor-alpha (TNF- $\alpha$ ).<sup>7</sup> Interestingly, the efficacy of apremilast has been reported in acute lung injury caused by the anticancer proteasome inhibitor carfilzomib,

characterized by an exaggerated inflammatory response.<sup>9</sup> Another experiment in mouse has documented an inhibitory effect of apremilast on the release of profibrotic cytokine from macrophages, including interleukin-6.<sup>10</sup> During COVID19, pneumonia has been documented a ‘cytokines storm’, with markedly higher levels of IL-6, and TNF- $\alpha$ , suggesting the use of interleukin-6 receptor blocker tocilizumab in severe cases.<sup>11</sup> Recently, another Italian psoriasis patient contracting COVID-19 under IL-23 inhibitor treatment (guselkumab) has been reported, and completely recovered from the infection.<sup>12</sup>



From our experience, apremilast confirms its safety in very critical patients with severe infections, including COVID-19. Its efficacy in our sub-erythrodermic psoriasis was not completely satisfactory, but other treatments were contraindicated for the recurrent brain oligodendroglioma. Further studies are warranted to explore the intriguing immune modulating activities of this very manageable drug.

### Acknowledgement

The patient in this manuscript has given written informed consent to the publication of his case details.

### Funding source

none.

C. Mugheddu, L. Pizzatti, S. Sanna, L. Atzori,\*   
F. Rongioletti 

Dermatology Clinic, Department of Medical Sciences and Public Health, University of Cagliari, Cagliari, Italy

\*Correspondence: L. Atzori. E-mail: atzoril@unica.it

Copyright: The authors certify that the manuscript is original, never submitted to other journal for publication before. All authors contributed equally to the manuscript and had the opportunity to revise and approve the final text.

### References

- Gisoni P, Piaserico S, Conti A, Naldi L. Dermatologists and SARS-CoV-2: The impact of the pandemic on daily practice. *J Eur Acad Dermatol Venereol* 2020. <https://doi.org/10.1111/jdv.16515>. [Epub ahead of print].
- Tartari F, Guglielmo A, Fuligni F, Pileri A. Changes in emergency service access after spread of COVID19 across Italy. *J Eur Acad Dermatol Venereol* 2020. <https://doi.org/10.1111/jdv.16553>. [Epub ahead of print].
- Radi G, Diotallevi F, Campanati A, Offidani A. Global coronavirus pandemic (2019-nCoV): implication for an Italian medium size dermatological clinic of a II level hospital. *J Eur Acad Dermatol Venereol* 2020. <https://doi.org/10.1111/jdv.16386>. [Epub ahead of print].
- Atzori L, Mugheddu C, Addis G *et al*. Psoriasis health care in the time of the coronavirus pandemic: insights from dedicated centers in sardinia (Italy). *J Eur Acad Dermatol Venereol* 2020. <https://doi.org/10.1111/jdv.16473>. [Epub ahead of print].
- Di Altobrando A, Patrizi A, Bardazzi F. Should SARS-CoV-2 influence immunosuppressive therapy for autoimmune blistering diseases? *J Eur Acad Dermatol Venereol* 2020. <https://doi.org/10.1111/jdv.16491>. [Epub ahead of print].
- Price KN, Frew JW, Hsiao JL, Shi VY. COVID-19 and Immunomodulator/Immunosuppressant use in dermatology. *J Am Acad Dermatol* **82**: e173–e175.
- Zerilli T, Ocheretyaner E. Apremilast (Otezla): a new oral treatment for adults with psoriasis and psoriatic arthritis. *Pharm Ther* 2015; **40**: 459–500.
- Sp R Shah VV, Wu Jj. Apremilast for a psoriasis patient with HIV and hepatitis C. *J Eur Acad Dermatol Venereol* 2017; **31**: e481–e482.
- Imam F, Al-Harbi NO, Al-Harbi MM *et al*. Apremilast ameliorates carfilzomib-induced pulmonary inflammation and vascular injuries. *Int Immunopharmacol* 2019; **66**: 260–266.
- Maier C, Ramming A, Bergmann C *et al*. Inhibition of phosphodiesterase 4 (PDE4) reduces dermal fibrosis by interfering with the release of interleukin-6 from M2 macrophages. *Ann Rheum Dis* 2017; **76**: 1133–1141.
- Zhang C, Wu Z, Li JW, Zhao H, Wang GQ. The cytokine release syndrome (CRS) of severe COVID-19 and Interleukin-6 receptor (IL-6R) antagonist Tocilizumab may be the key to reduce the mortality. *Int J Antimicrob Agents* 2020: 105954. <https://doi.org/10.1016/j.ijantimicag.2020.105954>
- Messina F, Piaserico S. SARS-CoV-2 infection in a psoriatic patient treated with IL-23 inhibitor. *J Eur Acad Dermatol Venereol* 2020. <https://doi.org/10.1111/jdv.16468>. [Epub ahead of print].

DOI: 10.1111/jdv.16625

## Personal protective equipment induced facial dermatoses in healthcare workers managing Coronavirus disease 2019

Editor,

During the coronavirus disease 2019 (COVID-19) pandemic, frontline healthcare workers (HCW) are working tirelessly for long hours to provide patient care. Although COVID is not dermatotropic, prolonged contact with personal protective equipment (PPE, i.e. goggles, face-shield/visor, N 95 respirator, double-layered gloves, coverall/gowns, head cover and shoe cover) may cause various dermatoses. Several dermatoses have been reported due to PPE, such as pressure injury, contact dermatitis, pressure urticaria and exacerbation of pre-existing skin diseases, including seborrheic dermatitis and acne.<sup>1,2</sup> We report a preliminary data of HCW who experienced facial dermatoses due to the use of PPE.

From 24 March 2020 to 16 April 2020, we came across with 43 patients comprising physicians, nurses and paramedical staff who involved (directly/indirectly) in managing patients of COVID-19. We used telemedicine to consult these patients. Their history, clinical findings including onset, duration, location, clinical features and other associated symptoms of dermatoses and type of PPE used were recorded. However, patch could not be performed. Final diagnosis was based on history, clinical findings and pattern of dermatoses and symptoms.

The most commonly noted dermatoses were irritant contact dermatitis (ICD; 39.5%) followed by friction dermatitis (25.5%). Goggles were the most common culprit agent among all PPE causing any one of the dermatoses (51.92%), followed by N95