

body. Prior to the development of the eruptions, he had a sleep disorder and had been treated with clonazepam for 5 months. He had also regularly been taking azilsartan for hypertension for 1 year.

Physical examination revealed eczematous eruptions, predominantly on the patient's trunk (Fig. 1a,b).

Laboratory assessment of a peripheral blood sample showed a normal leucocyte count of  $6.7 \times 10^9/L$  (normal range  $3.3\text{--}8.8 \times 10^9/L$ ) with raised eosinophils (10%,  $0.70 \times 10^9/L$ ; normal ranges 0–8%,  $0.07\text{--}0.45 \times 10^9/L$ , respectively). The serum level of thymus and activation-regulated chemokine (TARC) was elevated at 2818 pg/mL (normal level 450 pg/mL) and soluble interleukin-2 receptor levels were within normal limits.

Histological examination of a skin biopsy specimen revealed epidermal spongiosis, basal vacuolar change, and infiltration of lymphocytes and eosinophils in the papillary dermis (Fig. 1c). In addition, there were no atypical lymphocytes exhibiting cerebriform or convoluted nuclei, no haloed lymphocytes or true epidermotropism in the epidermis, and no papillary dermal fibrosis.

These findings did not favour a diagnosis of mycosis fungoides (MF), thus, based on the results, eczematous drug eruption due to clonazepam or azilsartan was most strongly suspected.


Consequently, 3 weeks after the eruptions appeared, clonazepam and azilsartan were discontinued, and the patient was treated with prednisolone 40 mg (0.74 mg/kg) daily and prednisolone 10 mg every 4 days, tapered over time. The eruptions disappeared within 3 weeks from initiation of prednisolone.

Nine days later, to confirm the causative agent, clonazepam was restarted after obtaining the patient's informed consent. Two weeks after restarting clonazepam administration, infiltrative erythema appeared on the head, trunk and bilateral thighs (Fig. 1d,e). The serum TARC level was increased at 11 300 pg/mL. A biopsy specimen demonstrated histopathological features similar to those of the previous biopsy specimen, consisting of vacuolar changes, spongiosis, oedema, and infiltration of lymphocytes and eosinophils in the superficial perivascular region (Fig. 1f). The drug-induced lymphocyte stimulation test was positive for clonazepam.

Consequently, we made a final diagnosis of eczematous drug eruption due to clonazepam, and clonazepam was discontinued. Ten weeks after discontinuing clonazepam, the eruptions disappeared and azilsartan was restarted. At follow-up 4 months after restarting azilsartan administration, there was no recurrence of eruptions, serum TARC level had decreased to 729 pg/mL, and blood eosinophil level was within the normal range at  $306/\mu L$ .

Clonazepam, one of the drugs in the benzodiazepine class, is used as an anti-anxiety medication. To our knowledge, this is the first case of an eczematous drug eruption due to clonazepam that was correlated with serum TARC levels. TARC is a T-helper 2-type

chemokine, and serum TARC levels are related to the disease activities of atopic dermatitis, bullous pemphigoid and MF.<sup>1–3</sup> A recent study showed that serum TARC levels were correlated with blood eosinophil counts in Type 2-mediated drug eruptions.<sup>4</sup> In addition, elevated serum TARC levels have been reported in association with eczematous drug eruptions secondary to everolimus.<sup>5</sup> Our case showed elevation of serum TARC levels after the oral challenge test with clonazepam. We also observed fluctuation of serum TARC levels in association with the clinical course of the eruption. Together with the results of previous studies, our findings indicate the possibility that measurement of serum TARC level is useful for management of eczematous drug eruptions and that clonazepam-induced eczematous drug eruption is mediated by a Type 2 immune reaction.

**A. Yoshida,<sup>1</sup> K. Sugita,<sup>1</sup> N. Tani<sup>1</sup>  and O. Yamamoto<sup>1</sup>**

<sup>1</sup>Division of Dermatology, Department of Medicine of Sensory and Motor Organs, Faculty of Medicine, Tottori University, Yonago, Japan

E-mail: ai-yoshida@tottori-u.ac.jp

Conflict of interest: the authors declare that they have no conflicts of interest.

Accepted for publication 13 May 2020

## References

- 1 Tan HT, Sugita K, Akdis CA. Novel biologicals for the treatment of allergic diseases and asthma. *Curr Allergy Asthma Rep* 2016; **16**: 70.
- 2 Sugita K, Kabashima K, Nishio D *et al*. Th2 cell fluctuation in association with reciprocal occurrence of bullous pemphigoid and psoriasis vulgaris. *J Eur Acad Dermatol Venereol* 2007; **21**: 569–70.
- 3 Ito A, Sugita K, Ikeda A *et al*. CD4/CD8 double-negative mycosis fungoides: a case report and literature review. *Yonago Acta Med* 2019; **62**: 153–8.
- 4 Komatsu-Fujii T, Kaneko S, Chinuki Y *et al*. Serum TARC levels are strongly correlated with blood eosinophil count in patients with drug eruptions. *Allergol Int* 2017; **66**: 116–22.
- 5 Habu M, Tohyama M, Sayama K. Two cases of eczematous eruptions caused by everolimus. *J Cutan Immunol Allergy* 2019; **2**: 135–8.

## Novel outbreak of acral lesions in times of COVID-19: a description of 74 cases from a tertiary university hospital in Spain

doi: 10.1111/ced.14294

Since the outbreak of the novel coronavirus disease 2019 (COVID-19), reports concerning suspicious COVID-19 skin manifestations have been progressively increasing. Morbilliform, varicelliform or urticarial rashes were described

**Table 1**

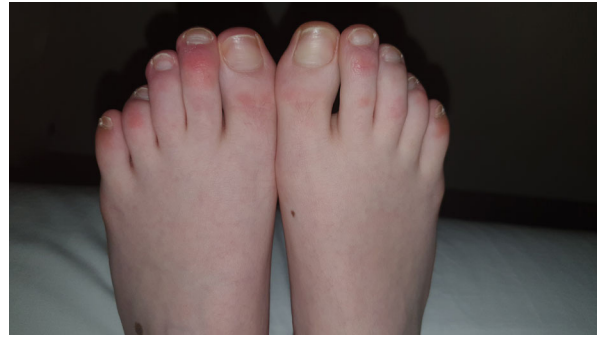	Result, %
Lesion morphology	
EP	76.4
PM	40.54
Both EP and PM	16.21
Erosion	10.8
Swelling	16.21
Distribution	
Hands	8.1
Feet	95.94
Both	4.05
Laterality	
Unilateral	31.08
Bilateral	68.91
Symmetry	
Symmetrical	51.35
Asymmetrical	44.59
Unknown	4.05
Symptoms	
Pruritus	32.4
Pain	27
Asymptomatic	48.6
Extracutaneous manifestations	
Frequency	29.6
Type	
Respiratory	50
General	50
Latency period, days	16.15
COVID-19 symptoms	
Symptoms present	
Cough	52.38
Fever	33.33
Asthenia/myalgia	28.57
Diarrhoea/nausea/vomiting	19
Dyspnoea	9.52
Anosmia/ageusia	4.76

EP, erythematous papules; PM, purpuric macules.

first.<sup>1</sup> Later, acral erythematous or purpuric lesions were reported.<sup>2–5</sup>

At the Araba University Hospital in Spain, which covers a population of 340 000 people, we designed a descriptive study of 74 patients. We recruited all patients presenting with suspicious acral manifestations for COVID-19 from 7 to 22 April 2020. The average temperature during this period was 14 °C. Patients with changes in their pharmacological drugs during the previous month were excluded. Owing to the pandemic, data on most patients reached us via tele dermatology. Age, sex, medical history, occupation and clinical characteristics were recorded for each patient. The results are shown in Table 1.

Of 74 patients, 42 (56.8%) were male. Mean age was 19.66 years (median 14.5 years, range 3–100 years). A small percentage (5.4%) were healthcare workers or had close contact with such workers, while 24.32% reported



**Figure 1** Typical acral cutaneous findings suspicious for COVID-19: erythematous chilblain-like plaques with an asymmetrical distribution in the dorsum of toes.

close contact with a person with confirmed or clinically diagnosed COVID-19.

Most patients had erythematous papules (76.4%), similar to chilblains (Fig. 1), while 40.54% had purpuric macules. Nearly all patients showed foot involvement (95.94%) and the hands were affected in 8.1%. Bilateral (68.91%) and symmetrical (51.35%) were the most usual distribution patterns. The dorsa of the toes/fingers was the main affected location (74.3% on toes and 100% on fingers).

Extracutaneous symptoms were found in 21 patients (29.6%), of which 50% also had clinical respiratory symptoms (cough and dyspnoea). In 66.7% of the cases, cutaneous manifestations developed after extracutaneous symptoms with a mean latency of 16.15 days. Two patients developed pneumonia (2.70%), both preceding the cutaneous symptoms.

In our area, COVID-19 PCR, which has a sensitivity of about 70%, was performed on 17 516 people and 4649 were positive. Owing to the limited availability of resources only 11 patients in our study underwent PCR, and 1 had a positive result. Six patients underwent blood investigations (including autoimmunity), which did not show relevant alterations; this is in line with a previous report.<sup>2</sup>

A skin biopsy was taken from a lesion on the toe of one patient who had a negative serology test for COVID-19, and histological examination revealed a lymphocytic perivascular and perieccrine infiltrate. Neither vascular occlusion nor intravascular thrombi were seen. Direct immunofluorescence study was negative. These findings are compatible with those previously described.<sup>2,3</sup>

The aetiology of these lesions remains unclear. A microangiopathic and inflammatory process is thought to occur.<sup>2,4–6</sup> Alternatively, activation of complement, leading to inflammation and thrombi formation has been proposed.<sup>6</sup> However, neither our case nor the others previously published have described thrombi.<sup>2</sup> More recent articles<sup>3,4</sup> have proposed a delayed antigen–


antibody immunological reaction, which could explain their development in asymptomatic and paucisymptomatic patients.

Interestingly, we noticed an increase in the number of acral lesions 25 days after the start of lockdown. Conversely, last April we did not have similar lesions registered. Thus, we wonder whether some factors related to quarantine might have been involved, such as lack of sun exposure and consequent low levels of vitamin D.

We hope this paper will encourage sturdier studies. If the results validate our findings, acral cutaneous manifestations will represent a useful clue to identify COVID-19 in asymptomatic and paucisymptomatic patients.

## Acknowledgement

We wish to thank the collaboration of all our colleagues in the Dermatology Department of the Araba University Hospital, as well as the pathologists (Dr Malo-Díez and Dr Martínez-Aracil). We also thank the primary care physicians, physicians from the emergency department, pediatricians and other specialists from our hospital and from the primary care centres in our area who collaborated and helped us to perform this study.

**A. Saenz Aguirre,<sup>1</sup>  F. J. De la Torre Gomar,<sup>1</sup> P. Rosés-Gibert,<sup>1</sup> J. Gimeno Castillo,<sup>1</sup> Z. Martínez de Lagrán Alvarez de Arcaya<sup>1</sup> and R. Gonzalez-Perez<sup>1</sup>**

<sup>1</sup>Department of Dermatology, Hospital Universitario Araba, Vitoria, Spain

E-mail: amaiaaenzaguirre@gmail.com

Conflict of interest: The authors declare that they have no conflicts of interest.

The first two authors contributed equally to this work and should be considered joint first authors.

Accepted for publication 13 May 2020

## References

- Recalcati S. Cutaneous manifestations in COVID-19: a first perspective. *J Eur Acad Dermatol Venereol* 2020; **34**: e212–13.
- Kolivras A, Dehavay F, Delplace D *et al.* Coronavirus (COVID-19) infection-induced chilblains: a case report with histopathological findings. *JAAD Case Rep* 2020; **6**: 489–92.
- Recalcati S, Barbagallo T, Frasin LA *et al.* Acral cutaneous lesions in the time of COVID-19. *J Eur Acad Dermatol Venereol* 2020; **34**: e346–7.
- Landa N, Mendieta-Eckert M, Fonda-Pascual P *et al.* Chilblain-like lesions on feet and hands during the COVID-19 pandemic. *Int J Dermatol* 2020; **59**: 739–43.
- López-Robles J, de la Hera I, Pardo J *et al.* Chilblain-like lesions: a case series of 41 patients during the COVID-19 pandemic. *Clin Exp Dermatol* 2020.
- Magro C, Mulvey JJ, Berlin D *et al.* Complement associated microvascular injury and thrombosis in the pathogenesis of severe COVID-19 infection: a report of five cases. *Transl Res* 2020.

## Retrospective study of COL1A1-PDGFB fusion gene-positive dermatofibrosarcoma protuberans in Kumamoto University

doi: 10.1111/ced.14312

Dermatofibrosarcoma protuberans (DFSP) is a rare superficial mesenchymal neoplasm derived from fibroblasts. Although most DFSP cases stain positive for CD34, 10% of DFSP cases stain negative for CD34 and 25% of DFSP cases stain positive for factor XIIIa.<sup>1</sup> The tumorigenic mechanism of DFSP is mainly defined by the formation of a fusion gene between the  $\alpha$ -helix domain of the collagen type 1 gene (*COL1A1*) and the platelet-derived growth factor- $\beta$  gene (*PDGFB*). Although *COL1A1/PDGFB* rearrangements are present in 85–96% of patients with DFSP,<sup>1</sup> *COL1A2-PDGFB*,<sup>2</sup> *COL6A3-PDGFB*<sup>3</sup> and elastin microfibril interface 2 (*EMILIN2*)-*PDGFB*<sup>4</sup> are newly reported fusion genes in DFSP.

To date, there are no reports in the literature describing the breakpoint in the *COL1A1/PDGFB* gene in DFSP. Therefore, we investigated the fusion site of the *COL1A1/PDGFB* gene and its relationship with clinical findings in 30 patients with DFSP treated at our hospital between 2007 and 2019.

Paraffin wax-embedded tissue was collected, and the *COL1A1/PDGFB* fusion gene was assessed as described in a previous report.<sup>5</sup> *COL1A1/PDGFB* fusion was detected in 25 (83%) of the 30 patients; the clinical findings and sequencing analysis results of these 25 *COL1A1/PDGFB*-positive patients with DFSP are outlined in Table 1. The breakpoint in the *PDGFB* gene was before exon 2 in all patients, while that in the *COL1A1* gene was after exon 25 in five patients, after exon 32 in four patients, after exons 39 and 46 in two patients each, and after exons 7, 8, 14, 28, 29, 31, 33, 35, 37, 39, 43 and 47 in one patient each. According to a previous report, breakpoints in the *COL1A1* gene were most common in exons 25, 29, 32, 43 and 46.<sup>1</sup> In our study, we found that exons 25 and 32 were also frequently involved. We did not find any correlation between the *COL1A1* breakpoint and clinical findings. To our knowledge, no report to date has described a case of DFSP with a breakpoint in exon 28 in the *COL1A1* gene.

## Acknowledgement

Dr H. Inh sadly died 13 March 2020.