

Pancreatico-gastric fistula mimicking malignant infiltration following transgastric EUS-FNA of resectable pancreatic ductal adenocarcinoma

Marco Le Grazie¹, Stefano Francesco Crinò¹, Armando Gabbrielli¹, Giuseppe Malleo², Stefano Marletta³, Paola Capelli³

¹Gastroenterology and Digestive Endoscopy Unit, The Pancreas Institute, Policlinico G. B. Rossi, University Hospital, ²Unit of General and Pancreatic Surgery, The Pancreas Institute, Policlinico G. B. Rossi, University Hospital, ³Department of Diagnostics and Public Health, Policlinico G. B. Rossi, University Hospital, Verona, Italy

INTRODUCTION

In the presence of a solid pancreatic mass suspicious for malignancy and without major vascular involvement, biopsy proof is not mandatory before proceeding with upfront resection.^[1] However, the steady global uptake of neoadjuvant chemotherapy for borderline resectable and even anatomically resectable pancreatic ductal adenocarcinoma (PDAC) has led to an increasing number of EUS-guided biopsies being performed. Novel end-cutting forward-acquiring EUS needles, including the SharkCore™ (Medtronic Parkway, Minneapolis, MN, USA), provide better core biopsy specimens and allow for molecular and genetic studies that will possibly aid in guiding therapy.^[2] When tumors are located in the pancreatic body and tail, tissue acquisition is performed through a transgastric route.^[3,4] Although exceedingly uncommon, needle tract seeding at the gastric wall level has been described.^[3,4]

We herein report two cases of intraoperatively found gastric wall infiltration following EUS-fine needle

biopsy (FNB) of resectable PDAC, that required associated partial gastric resection but was demonstrated to be nonneoplastic on final pathological analysis.

CASE 1

The first patient was a 72-year-old female, affected by an incidentally discovered 13 mm pancreatic solid lesion in the body of the pancreas, with upstream main pancreatic duct (MPD) dilation and parenchymal atrophy and without distant metastases on cross-sectional imaging. Ca 19.9 was normal. The lesion was hypoechoic on EUS and hypovascular after contrast injection (Sonovue™, Bracco S. p. a., Milan, Italy) [Figure 1a]. No ultrasonographic signs of neoplastic infiltration of the stomach by the pancreatic lesion were observed. To confirm the diagnosis, transgastric FNB was performed with three passes of a 22G SharkCore™ needle. Ten–twenty

This is an open access journal, and articles are distributed under the terms of the Creative Commons Attribution-NonCommercial-ShareAlike 4.0 License, which allows others to remix, tweak, and build upon the work non-commercially, as long as appropriate credit is given and the new creations are licensed under the identical terms.

For reprints contact: reprints@medknow.com

How to cite this article: Le Grazie M, Crinò SF, Gabbrielli A, Malleo G, Marletta S, Capelli P. Pancreatico-gastric fistula mimicking malignant infiltration following transgastric EUS-FNA of resectable pancreatic ductal adenocarcinoma. *Endosc Ultrasound* 2020;9:138-40.

Access this article online	
Quick Response Code: 	Website: www.eusjournal.com
	DOI: 10.4103/eus.eus_5_20

Address for correspondence

Dr. Marco Le Grazie, Gastroenterology and Digestive Endoscopy Unit, G. B. Rossi, University Hospital, P.le L.A. Scuro 10, Verona - 37134, Italy. E-mail: marcolegrazie89@gmail.com

Received: 2020-01-04; Accepted: 2020-03-05; Published online: 2020-04-15

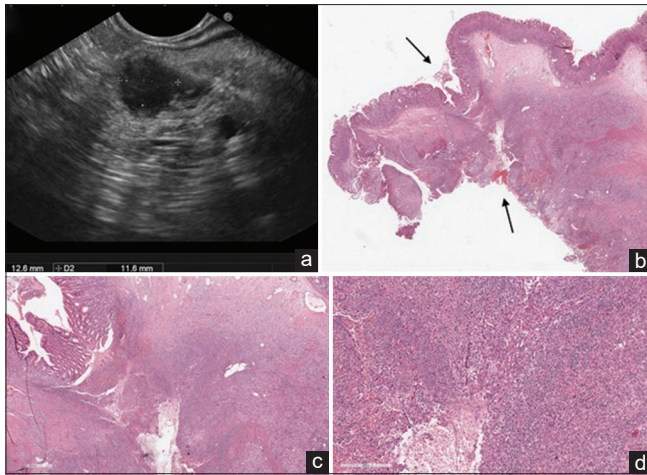


Figure 1. EUS examination revealing a small (13 mm) hypoechoic solid lesion in the body of the pancreas. No signs of suspected gastric infiltration were observed (a). Histological view of the portion of stomach firmly attached to the pancreas (black arrows) and resected during surgical operation (b, low magnification, H and E). A whole-thickness tumor-free gastric wall involved by inflammatory infiltrate with the histological hallmarks of granulation tissue that reach the gastric mucosa from the outer layers of the stomach (c, H and E, $\times 10$ and d, H and E $\times 40$). These are the pathological key features of a “fistula” and witness a secondary gastric involvement from an external underlying disease

to-and-fro movements using the slow-pull and the fanning techniques were performed. Histological diagnosis of PDAC was obtained.

CASE 2

The second patient was a 69-year-old male. A small (9 mm) solid lesion in the body of the pancreas was incidentally discovered. Laboratory tests (including Ca 19.9) were normal and features on cross-sectional imaging (upstream MPD dilatation with parenchymal atrophy, no distant metastases) and on EUS (hypoechoic/hypovascular lesion without signs of gastric wall infiltration) were similar to those observed in the first case. Transgastric FNB was performed with two passes of a 25G SharkCore™ needle using the same technique described for Case 1. Histological diagnosis of PDAC was obtained.

SURGICAL AND PATHOLOGICAL FINDINGS

During surgical exploration, in the both cases, unexpected infiltration of the posterior gastric wall was found, and a distal pancreatectomy with *en bloc* partial gastric resection was performed to achieve complete tumor clearance. The surgical specimens consisted of a distal splenopancreasectomy with an adherent portion of the gastric wall. Although a needle tract seeding

was suspected, histological examination revealed no malignant cells implantation, but an inflammatory infiltrate with granulation tissue through the gastric wall, from the outer to the inner layers [Figure 1b-d]. These pathologic hallmarks suggested the formation of a pancreatico-gastric fistula along the needle tract.^[5] It is likely that, given the small size of the lesions, the MPD was inadvertently injured during the back and forth movements of the needle, with subsequent leakage of pancreatic juice into the gastric cavity. To the best of our knowledge, this is the first report of EUS-FNB-related nonneoplastic fibroinflammatory reactions mimicking PDAC infiltration of the posterior gastric wall. Surgeons should be aware of this sampling-related adverse event to avoid intraoperative overestimation of tumor stage, especially when no evidence of pancreatico-gastric adherence is observed at preoperative imaging. Future larger prospective EUS-FNB studies employing end-cutting needles and including small resectable PDAC could assess the incidence of this adverse event.

Informed consent statement

The patients involved in this study gave their written informed consent authorizing use and disclosure of their protected health information.

Declaration of patient consent

The authors certify that they have obtained all appropriate patient consent forms. In the form, the patient has given her consent for her images and other clinical information to be reported in the journal. The patient understands that name and initials will not be published and due efforts will be made to conceal identity, but anonymity cannot be guaranteed.

Financial support and sponsorship

Nil.

Conflicts of interest

There are no conflicts of interest.

REFERENCES

- Asbun HJ, Conlon K, Fernandez-Cruz L, *et al.* When to perform a pancreaticoduodenectomy in the absence of positive histology? A consensus statement by the international study group of pancreatic surgery. *Surgery* 2014;155:887-92.
- Gleeson FC, Levy MJ, Roden AC, *et al.* EUS fine-needle pancreatic core biopsy can determine eligibility for tumor-agnostic immunotherapy. *Endosc Int Open* 2018;6:E1278-E1282.
- Minaga K, Takenaka M, Katanuma A, *et al.* Needle tract seeding: An overlooked rare complication of endoscopic ultrasound-guided fine-needle

aspiration. *Oncology* 2017;93 Suppl 1:107-12.

4. Minaga K, Kitano M, Enoki E, *et al.* Needle-tract seeding on the proximal gastric wall after EUS-guided fine-needle aspiration of a pancreatic mass. *Am J Gastroenterol* 2016;111:1515.
5. Lack EE. Pathology of the Pancreas, Gallbladder, Extrahepatic Biliary Tract, and Ampullary Region. New York: Oxford University Press; 2003. p. 93.