

**ORCID**

Shuzo Yoshida  <https://orcid.org/0000-0002-7652-9539>

**REFERENCES**

1. García-Carrasco M, Ramos-Casals M, Cervera R, et al. Cryoglobulinemia in systemic lupus erythematosus: Prevalence and clinical characteristics in a series of 122 patients. *Semin Arthritis Rheum.* 2001;30:366–373.
2. Terrier B, Krastinova E, Marie I, et al. Management of non-infectious mixed cryoglobulinemia vasculitis: Data from 242 cases included in the CryoVas survey. *Blood.* 2012;119:5996–6004.
3. Taniyama Y, Nakatani Y, Matsuoka T, et al. Efficacy of cryofiltration for treatment of mixed cryoglobulinemia: A report of four cases. *Ther Apher Dial.* 2017;21:238–242.
4. Tunncliffe DJ, Singh-Grewal D, Kim S, Craig JC, Tong A. Diagnosis, monitoring, and treatment of systemic lupus erythematosus: A systematic review of clinical practice guidelines. *Arthritis Care Res.* 2015;67:1440–1452.

## Selective C-reactive protein apheresis for Covid-19 patients suffering from organ damage



Dear Editor,

Up to May 19, 2020, severe acute respiratory syndrome-coronavirus 2 (SARS-CoV-2) infections (causing Covid-19) were confirmed in more than 4.5 million people worldwide. The mortality rate is approximately 7%; however, in the age group above 60 years it is more than 20%.<sup>1</sup> SARS-CoV-2 induces lung fibrosis and cardiac complications among other organ deteriorations in a small percentage of the infected population.<sup>2</sup> The current therapeutic approach focuses on the treatment of the acute respiratory distress syndrome, as it is the main cause of mortality, followed by cardiac and septic complications. Pulmonary fibrosis is accompanied by a first cytokine storm followed by a massive increase of CRP levels.<sup>3</sup> So far, there is no therapeutic option to reduce the extremely high synthesis of CRP. It triggers tissue damage itself and is thus also causally involved in the enlargement of destroyed tissue and contributes to irreversible tissue destruction.<sup>4,5</sup> During the clinical manifestation of Covid-19 infection, both IL-6 and CRP increase drastically.<sup>6</sup> While IL-6 is used as a classical prognostic marker of inflammation, the CRP concentration often correlates with the overall clinical picture and is strongly elevated (>150 mg/L) over several days, especially in severely ill patients with a high risk of death.<sup>3</sup>

With this background, the rapid reduction of extremely high CRP levels in medium and severe courses of Covid-19 could be a rationally comprehensible therapeutic approach.<sup>7</sup> Selective extracorporeal CRP apheresis lowers the CRP concentration drastically within a few hours, and the repeatable treatment is safe, efficient, and selective.<sup>4</sup> Clear evidence has been shown in previous clinical studies, which investigated CRP apheresis after

myocardial infarction, that CRP depletion reduces systemic inflammation and cardiac tissue damage. The pathomechanism derived from these previous findings<sup>4,5</sup> is shown schematically in Figure 1. According to this model, the infection of the epithelial cells leads to the production and release of SARS-CoV-2 and to the activation of proinflammatory cytokines and consequently CRP. This occurs in the sense of a vicious circle, that is, at the expense of the healthy cell population not only in the lung but also in other ischemic tissues and leads to a continuous decrease in the latter if regeneration cannot take place to the same extent. Specifically the strong and lasting increase of the CRP concentration is striking. Such extremely high CRP levels have never been observed in this magnitude in any other acute or chronic viral infectious disease. The ubiquitous molecular pathomechanism of CRP (complement-mediated) suggests that the tissue-protective effect of CRP apheresis also occurs in tissues other than the heart muscle, for example in the lung.

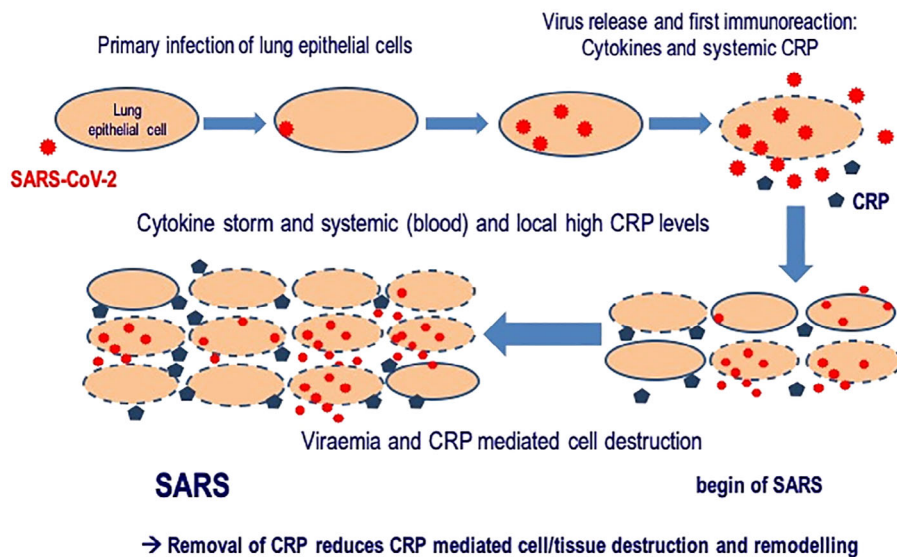
We hypothesize that it is beneficial for Covid-19 patients to be treated by CRP apheresis, especially in the early phase of incipient pulmonary fibrosis. This therapeutic option presents an extremely low risk and expected benefit for patients. Therefore, we propose to acknowledge this treatment and recommend a clinical pilot trial, which can evaluate CRP apheresis in patients suffering from Covid-19.

Stefan Kayser<sup>1</sup>  
 Rudolf Kunze<sup>2</sup>   
 Ahmed Sheriff<sup>1,3</sup> 

This is an open access article under the terms of the Creative Commons Attribution-NonCommercial License, which permits use, distribution and reproduction in any medium, provided the original work is properly cited and is not used for commercial purposes.

© 2020 The Authors. *Therapeutic Apheresis and Dialysis* published by John Wiley & Sons Australia, Ltd on behalf of International Society for Apheresis, Japanese Society for Apheresis, and Japanese Society for Dialysis Therapy

### Hypothesized pathomechanism of lung destruction by SARS-CoV-2 and immunoreaction



**FIGURE 1** Hypothesized pathomechanism of lung destruction by severe acute respiratory syndrome-coronavirus 2 (SARS-CoV-2) and the triggered immunoreaction. Infection of lung epithelial cells leads to the production and release of SARS-CoV-2 and to the activation of proinflammatory cytokines, and consequently CRP. This subsequently triggers more inflammation and leads to a vicious circle, finally damaging not only infected cells but also healthy tissue. The model adapts previous findings<sup>4,5</sup> [Color figure can be viewed at [wileyonlinelibrary.com](http://wileyonlinelibrary.com)]

<sup>1</sup>Pentracor GmbH, Hennigsdorf, Germany

<sup>2</sup>Science Office, Hessehagen, Germany

<sup>3</sup>Department of Gastroenterology/Infection/Rheumatology, Charité University Medicine, Berlin, Germany

#### Correspondence

Dr Ahmed Sheriff, CEO of Pentracor GmbH, Scientist at Charité Department of Gastroenterology/Infection/Rheumatology, Charité University Medicine, Berlin, Germany.

Email: [ahmed.sheriff@charite.de](mailto:ahmed.sheriff@charite.de)

#### ORCID

Rudolf Kunze <https://orcid.org/0000-0003-2176-9196>

Ahmed Sheriff <https://orcid.org/0000-0001-5074-1198>

#### REFERENCES

1. Huang C, Wang Y, Li X, et al. Clinical features of patients infected with 2019 novel coronavirus in Wuhan, China. *Lancet*. 2020;395(10223):497–506.

- Wadman M, Couzin-Frankel J, Kaiser J, Maticic C. A rampage through the body. *Science*. 2020;368(6489):356–360.
- Ruan Q, Yang K, Wang W, Jiang L, Song J. Clinical predictors of mortality due to COVID-19 based on an analysis of data of 150 patients from Wuhan, China. *Intensive Care Med*. 2020;46:846–848.
- Ries W, Heigl F, Garlichs C, Sheriff A, Torzewski J. Selective C-reactive protein-apheresis in patients. *Ther Apher Dial*. 2019;23:570–574.
- Sheriff A, Schindler R, Vogt B, et al. Selective apheresis of C-reactive protein: A new therapeutic option in myocardial infarction? *J Clin Apher*. 2015;30(1):15–21.
- Chen G, Wu D, Guo W, et al. Clinical and immunological features of severe and moderate coronavirus disease 2019. *J Clin Invest*. 2020;130(5):2620–2629.
- Torzewski J, Heigl F, Zimmermann O, et al. First-in-man: Case report of Selective C-reactive Protein Apheresis in a Patient with SARS-CoV-2 Infection. *Am J Case Rep*. 2020;21:e925020. <https://doi.org/10.12659/AJCR.925020>.

## Autologous arteriovenous fistula failed due to spontaneous axillary artery dissection in a female hemodialysis patient

Dear Editor,

Autologous arteriovenous fistula (AVF) is the preferred access for most uremic patients receiving maintenance HD; the creation of native fistula or synthetic graft before the start of chronic HD therapy prevents the need for

complication-prone dialysis catheters.<sup>1</sup> However, failed AVF is a major issue in the creation of functional HD vascular access. In fact, thrombosis and stenosis are the main causes of AVF failure;<sup>2</sup> however, the failure of AVF caused by the spontaneous axillary artery dissection