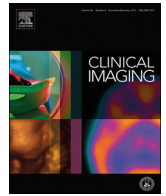



Since January 2020 Elsevier has created a COVID-19 resource centre with free information in English and Mandarin on the novel coronavirus COVID-19. The COVID-19 resource centre is hosted on Elsevier Connect, the company's public news and information website.

Elsevier hereby grants permission to make all its COVID-19-related research that is available on the COVID-19 resource centre - including this research content - immediately available in PubMed Central and other publicly funded repositories, such as the WHO COVID database with rights for unrestricted research re-use and analyses in any form or by any means with acknowledgement of the original source. These permissions are granted for free by Elsevier for as long as the COVID-19 resource centre remains active.



Cardiothoracic Imaging

Bringing radiology to patient's home using mobile equipment: A weapon to fight COVID-19 pandemic

Moreno Zanardo^a, Simone Schiaffino^{b,*}, Francesco Sardanelli^{a,b}^a Department of Biomedical Sciences for Health, Università degli Studi di Milano, Via Mangiagalli 31, 20133 Milano, Italy^b Unit of Radiology, IRCCS Policlinico San Donato, Via Morandi 30, 20097 San Donato Milanese, Italy

ARTICLE INFO

Keywords:

COVID-19

COVID-19 diagnostic testing

Radiography

Mobile radiography

Infection control

ABSTRACT

Because of coronavirus disease 2019 (COVID-19) high contagiousness, it is crucial to identify and promptly isolate COVID-19 patients. In this context, chest imaging examinations, in particular chest x-ray (CXR), can play a pivotal role in different settings, to triage in case of unavailability, delay of or first negative result of reverse transcriptase-polymerase chain reaction (RT-PCR), and to stratify disease severity. Considering the need to reduce, as much as possible, hospital admission of patients with suspected or confirmed infection, the use of mobile x-ray equipment could represent a safe approach. We picture a potential sequence of events, involving a team composed by a radiographer and a nurse, going to patient's home to perform CXR, nasopharyngeal swab (and, if needed, also a blood sample), with fast radiologist tele-reporting, and resulting patient management approach (home isolation or emergency room admission, when needed). This approach brings healthcare to patient's home, reducing the risk of infected subjects referring to family doctors' office or emergency departments, and strengthening community medicine while maintaining a strong connection with radiology departments.

Since the novel coronavirus disease, named COVID-19, was confirmed by the World Health Organization as pandemic on March 11th, 2020, measures have been taken to try flattening the epidemic curve and to allow healthcare systems to deal with the emergency.

Because of COVID-19 high contagiousness and spreading through respiratory droplets [1], it is crucial to identify and promptly isolate COVID-19 patients. In Italy, more than 22.000 health care providers resulted positive to COVID-19, and 154 physicians have died due to the disease (<https://portale.fnomceo.it/elenco-dei-medici-caduti-nel-corso-dellepidemia-di-covid-19/>), most of them being family doctors. To deal with pandemic, most countries organized constricted security measures, including lockdown, social distancing, and usage of personal protective equipment, partially continued also after the pandemic peak.

In this context, chest imaging examinations, in particular chest x-ray (CXR) [2] and computed tomography (CT) [3] can play a pivotal role in different settings, to triage in case of unavailability, delay of or first negative result of reverse transcriptase-polymerase chain reaction (RT-PCR) [4], and to stratify disease severity. We must consider the need to reduce, as much as possible, hospital admission of patients with suspected or confirmed severe acute respiratory syndrome coronavirus 2

(SARS-CoV-2) infection when they could receive care at home, as well as the access to emergency department of patients without SARS-CoV-2 infection. Indeed, the former may increase the infection outbreak, the latter may be unnecessarily exposed to risk of infection. The weakness of an effective community medicine practice, including home healthcare, has been judged as a strategic issue in the discussion on the pandemic outbreak in Italy, in particular in Lombardy.

The use of mobile x-ray equipment could represent a safe approach, enabling imaging of suspected or confirmed COVID-19 patients, performing examinations in their house or nursing home, reducing social contacts [5]. Of note, it has been already shown that x-ray examinations performed at home (or in the nursing home) using modern mobile equipment provide an image quality at least comparable to those obtained at hospital [6,7].

We picture the following sequence of events (Fig. 1): 1) a case of suspected COVID-19 patient is detected by any telephone service or doctor requested of a visit in the presence of symptoms or contact with a confirmed COVID-19 case; 2) a team composed by a radiographer and a nurse go to patient's home to perform CXR using a mobile equipment, nasopharyngeal swab (and, if needed, also a blood sample); 3) clinical

Abbreviations: COVID-19, coronavirus disease 2019; CXR, chest x-ray; CT, computed tomography; RT-PCR, reverse transcriptase-polymerase chain reaction; SARS-CoV-2, severe acute respiratory syndrome coronavirus 2

* Corresponding author at: Unit of Radiology, IRCCS Policlinico San Donato, Via Morandi 30, 20097 San Donato Milanese, Italy.

E-mail addresses: moreno.zanardo@unimi.it (M. Zanardo), schiaffino.simone@gmail.com (S. Schiaffino), francesco.sardanelli@unimi.it (F. Sardanelli).

<https://doi.org/10.1016/j.clinimag.2020.06.031>

Received 20 May 2020; Received in revised form 16 June 2020; Accepted 16 June 2020

Available online 18 June 2020

0899-7071/ © 2020 Elsevier Inc. All rights reserved.

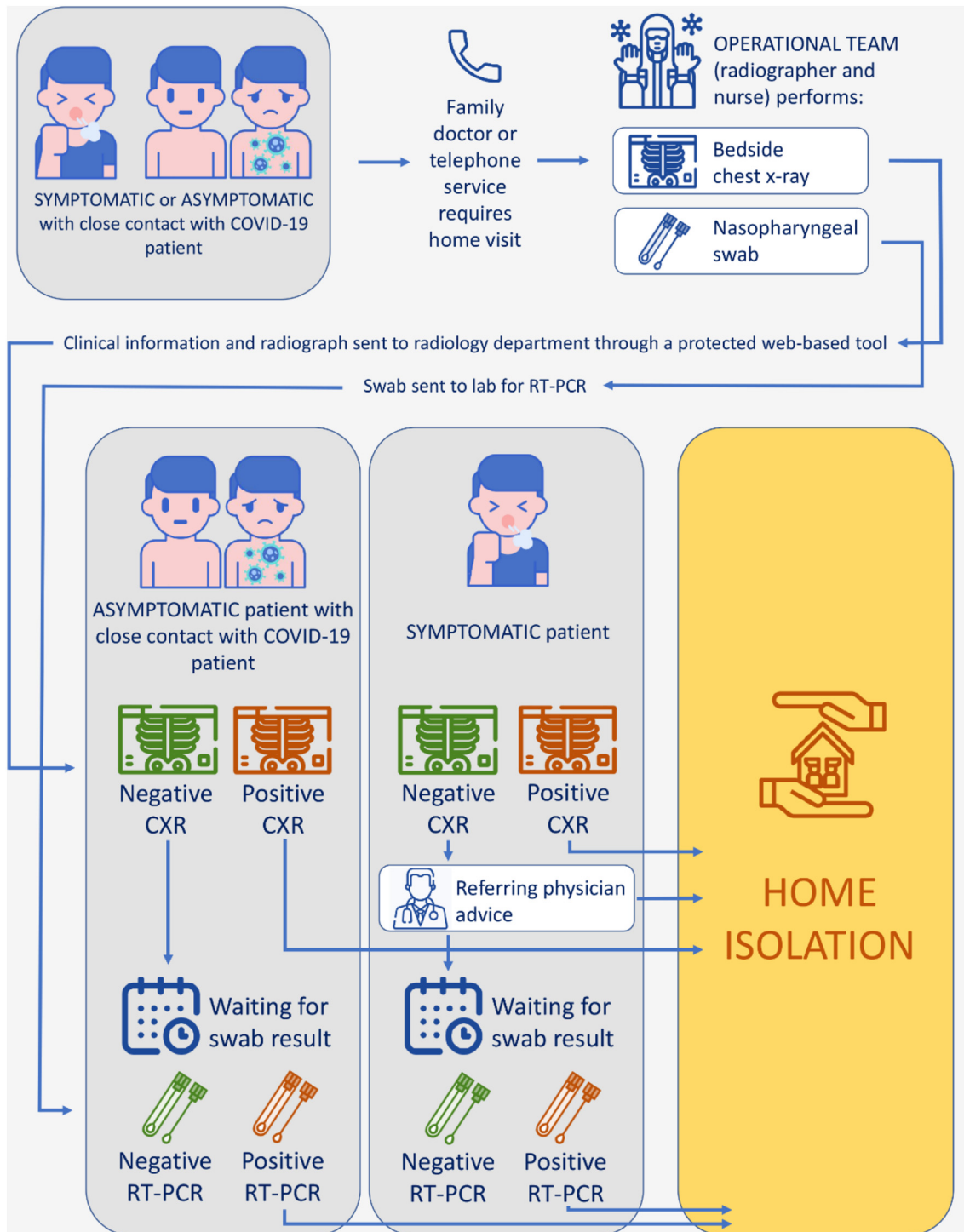


Fig. 1. Schematic representation of home management of patients with suspect severe acute respiratory syndrome coronavirus 2 (SARS-CoV-2) infection. Icons made by “<http://www.freepik.com/>” and “<https://www.flaticon.com/authors/flat-icons>”, authors: “Nikita Golubev”, “catkuro”, “Those Icons” and “photo3idea_studio”.

information and CXR images are sent to a radiology department through a protected web-based tool; 4) a radiologist immediately reports the examination; 5) the report is sent to the general practitioner or any other clinician for the best decision-making; 6) the team, being still at patient's home, can explain to patients and their family what to do and, if necessary, to start applying home isolation. The RT-PCR result will be considered as soon as it is available and a diagnostic pathway including history of contacts with COVID-19 patients, symptoms, CXR and RT-PCR result may guide the clinical decision-making.

To reduce health care workers potential exposure to COVID-19,

general precautions should be adopted while performing CXR and pharyngeal swab. The worker should wear a N95 mask or higher, disposable fluid-resistant gown, a pair of disposable gloves, goggles or visor for eye-protection. CXR machine should be covered with plastic sheeting to facilitate disinfection. After acquisition, CXR machine must be disinfected with low- or intermediate-level disinfectant, disposables properly disposed, and workers washed their hands [8].

This approach brings healthcare to patient's home, reducing the risk of infected subjects referring to family doctors' office or emergency departments. Further advantages include the following: a) cleaning and

disinfecting of all imaging equipment, including mobile x-ray machine and detectors can be performed quietly and carefully during the wait for the radiological report; b) the approximate effective radiation dose administered by modern integrated digital x-ray mobile units is very low (for an anteroposterior CXR, about 0.1 mSv, tenfold less than that usually delivered by a modern chest CT scan, about 1.0–1.5 mSv, as reported by the 2007 Recommendations of the International Commission on Radiological Protection (<http://www.icrp.org/publication.asp?id=ICRP%20Publication%20103>); c) the mobile equipment is relatively cheap and light (total weight less than 20 kg for some models); d) the overall cost of this approach should be lower than that including a general practitioner visit, nurse performing the swab and the possible transportation to a medical center or hospital for getting chest imaging.

In addition, artificial intelligence can further enhance the potential of this setting: convolutional neural networks have been shown to support the diagnosis of COVID-19 [9], so that the reporting radiologist could have a validated machine/deep learning second opinion to consider. This could be extremely useful in the current scenario of rapid change of COVID-19 prevalence, continuously modifying not only predictive values, but also sensitivity and specificity of diagnostic tests [10].

This approach has limitations, mainly related to the limits of each modality itself. Despite RT-PCR is considered the reference standard in the diagnosis of SARS-CoV-2 infection, is affected by variable false negative rates [3] and relatively long times to obtain the result. CXR is also affected by limited diagnostic performance, with reported sensitivity of 89% (95% confidence interval 85.5%–91.8%) and 60.6% specificity (95% confidence interval 51.6%–69.2%) [2], that must be kept in mind while interpreting the radiological report.

In conclusion, home radiology has great potential as weapon to fight the new virus, able to strengthen community medicine while maintaining a strong connection with radiology departments at hospital or medical centers. Well-designed prospective real-world studies are warranted to show the value of this approach.

Funding

This work was partially supported by Ricerca Corrente funding from Italian Ministry of Health to IRCCS Policlinico San Donato.

Conflicts of interest and financial disclosures

None.

Declaration of competing interest

M. Zanardo has no conflict of interest and has nothing to disclose. S. Schiaffino declares to be member of speakers' bureau for General Electric and to have received travel support from Bracco. F. Sardanelli declares to have received grants from or to be member of speakers' bureau/advisory board for Bayer, Bracco and General Electric.

Acknowledgements

This work was partially supported by Ricerca Corrente funding from Italian Ministry of Health to IRCCS Policlinico San Donato.

References

- [1] Zu ZY, Jiang MD, Xu PP, Chen W, Ni QQ, Lu G, et al. Coronavirus disease 2019 (COVID-19): a perspective from China. [published online ahead of print, 2020 Feb 21]. *Radiology*2020:200490<https://doi.org/10.1148/radiol.2020200490>.
- [2] Schiaffino S, Tritella S, Cozzi A, Carriero S, Blandi L, Ferraris L, et al. Diagnostic performance of chest x-ray for COVID-19 pneumonia during the SARS-CoV-2 pandemic in Lombardy, Italy. [published online ahead of print, 2020 May 12]. *J Thorac Imaging*2020. <https://doi.org/10.1097/RTI.0000000000000533>.
- [3] Ai T, Yang Z, Hou H, Zhan C, Chen C, Lv W, et al. Correlation of chest CT and RT-PCR testing in coronavirus disease 2019 (COVID-19) in China: a report of 1014 cases. [published online ahead of print, 2020 Feb 26]. *Radiology*2020:200642<https://doi.org/10.1148/radiol.2020200642>.
- [4] Lu H, Stratton CW, Tang YW. Outbreak of pneumonia of unknown etiology in Wuhan, China: the mystery and the miracle. *J Med Virol* 2020;92(4):401–2. <https://doi.org/10.1002/jmv.25678>.
- [5] Sawyer RH, Patel U, Horrocks AW. Domiciliary radiography: an important service? *Clin Radiol* 1995;50(1):51–5.
- [6] Precht H, Hansen DL, Ring-Pedersen BM, Møller Hansen LF, Waaler D, Tingberg A, et al. Comparison of image quality in chest, hip and pelvis examinations between mobile equipment in nursing homes and static indirect radiography equipment in the hospital. *Radiography (Lond)* May 2020;26(2):e31–7. <https://doi.org/10.1016/j.radi.2019.10.004>.
- [7] Zanardo M, Martini C, Monti CB, Cattaneo F, Ciaralli C, Cornacchione P, et al. Management of patients with suspected or confirmed COVID-19, in the radiology department. [published online ahead of print, 2020 Apr 20]. *Radiography (Lond)* 2020. <https://doi.org/10.1016/j.radi.2020.04.010>. S1078-8174(20)30062-6.
- [8] Kooraki S, Hosseiny M, Myers L, Gholamrezanezhad A. Coronavirus (COVID-19) outbreak: what the Department of Radiology Should Know. *J Am Coll Radiol* 2020;17(4):447–51. <https://doi.org/10.1016/j.jacr.2020.02.008>.
- [9] Castiglioni I, Ippolito D, Interlenghi M, Monti CB, Salvatore C, Schiaffino S, et al. <https://www.medrxiv.org/content/10.1101/2020.04.08.20040907v1>.
- [10] Sardanelli F, Di Leo G. Assessing the value of diagnostic tests in the new world of COVID-19 pandemic. [published online ahead of print, 2020 May 14]. *Radiology*2020:201845. <https://doi.org/10.1148/radiol.2020201845>.