

## Case report

Hereditary hemorrhagic telangiectasia and pulmonary arteriovenous malformations<sup>☆</sup>Saniye Girit<sup>a,\*</sup>, Ebru Senol<sup>b</sup>, Özge Karatas<sup>b</sup>, Ayşe İnci Yıldırım<sup>c</sup><sup>a</sup> Division of Pediatric Pulmonology, Department of Pediatrics, Istanbul Medeniyet University, Faculty of Medicine, Göztepe Training and Research Hospital, Istanbul, Turkey<sup>b</sup> Department of Pediatrics, University of Health Sciences Medical School Dr. Lutfi Kırdar Kartal Educational and Research Hospital, Istanbul, Turkey<sup>c</sup> Department of Pediatric Cardiology, University of Health Sciences Medical School Kartal Kosuyolu High Speciality Educational and Research Hospital, Istanbul, Turkey

## ARTICLE INFO

Handling Editor; Prof. B. Yawn

## ABSTRACT

Pulmonary arteriovenous malformations (PAVM) are generally congenital lesions caused by abnormal capillary development. Lesions can be in the form of isolated anomaly or as part of autosomal dominantly inherited hereditary hemorrhagic telangiectasia (HHT). HHT is the most common hereditary vascular disease characterized by mucocutaneous telangiectasia and visceral arteriovenous malformations. PAVMs can be asymptomatic or can present with effort dyspnea, palpitations and fatigue especially in cases with HHT. Herein, we present a 13 year-old girl diagnosed with PAVM with polycythemia, clubbing, cyanosis and radiological features; and had accompanying history of epistaxis in family and telangiectasia in oral mucosa as parts of HHT. She was treated by endovascular embolization.

## 1. Introduction

Hereditary Hemorrhagic Telangiectasia (HHT), also known as Osler-Weber-Rendu Syndrome, consists of mucocutaneous or visceral telangiectasia, epistaxis, family history and arteriovenous malformations. Around 15–50% of the patients with HHT have PAVM; and 70% of all PAVM are part of HHT [1]. Since both HHT and PAVM symptoms become more evident in adults, they are not commonly diagnosed in pediatric age [2]. Herein, we present a 13-year-old girl who presented with orthopnea, dyspnea and cyanosis; was diagnosed with PAVM and HHT and was treated successfully with multiple endovascular embolization.

## 2. Case presentation

13-year-old girl was referred to our clinic with cyanosis in the lips, chest pain and shortness of breath. She had history of fatigue and shortness of breath supervened in the last two months. In family history, 38-year-old father and 7-year-old sister had story of frequent epistaxis. In physical examination; weight was at the 3rd percentile, and height at

50-75th percentile, respiratory rate 30/minute, heart rate 118/minute, blood pressure 98/60 mmHg and transcutaneous oxygen saturation was 70%. Orthopnea was present and decreased lung sounds were detected on the right hemithorax by auscultation. She had clubbing and also cyanosis in labial mucosa, in the nails and telangiectasia in oral mucosa (Fig. 1). There were no specific findings in neurological and other system examinations. Laboratory examinations revealed blood pH:7.43; pCO<sub>2</sub>:32.4 mmHg; pO<sub>2</sub>:42.5 mmHg, hemoglobin:18 gr/dl, hematocrit:56.4%; leukocyte:6100/mm<sup>3</sup>, platelet:203000/mm<sup>3</sup>. Ferritin: 7 ng/mL and iron: 165 µg/dL. Other biochemical parameters were normal. Echocardiography showed mild mitral valve prolapse without any cardiac shunts. Pulmonary Arteriovenous shunt was confirmed in Contrast echocardiography (bubble echocardiography) which was done with physiologic saline solution injection and micro bubbles in the left ventricle was observed after 5 seconds of the injection.

Chest X-ray showed homogenous area of increased density with regular borders at the right pulmonary middle lobe (Fig. 2). Chest computerized tomography (CT) revealed soft tissue areas of probable dilated, tortuous pulmonary vascularization in the right pulmonary middle lobe lateral, middle lobe medial and in the lower lobe basal

<sup>☆</sup> This case was presented as a poster in 1. Congress of Pediatric Pulmonology; 2016, İstanbul.

\* Corresponding author. Division of Pediatric Pulmonology, Department of Pediatrics, Medeniyet University Medical School Göztepe Educational and Research Hospital, Kadıköy, İstanbul, Turkey. Tel.: +905323156874.

E-mail addresses: [saniyegirit@gmail.com](mailto:saniyegirit@gmail.com) (S. Girit), [drebrusenol@gmail.com](mailto:drebrusenol@gmail.com) (E. Senol), [drebrusenol@gmail.com](mailto:drebrusenol@gmail.com) (Ö. Karatas), [ayildirimmd@yahoo.com](mailto:ayildirimmd@yahoo.com) (A.İ. Yıldırım).

<https://doi.org/10.1016/j.rmcr.2020.101137>

Received 12 May 2020; Received in revised form 18 June 2020; Accepted 19 June 2020

Available online 24 June 2020

2213-0071/© 2020 Published by Elsevier Ltd. This is an open access article under the CC BY-NC-ND license (<http://creativecommons.org/licenses/by-nc-nd/4.0/>).

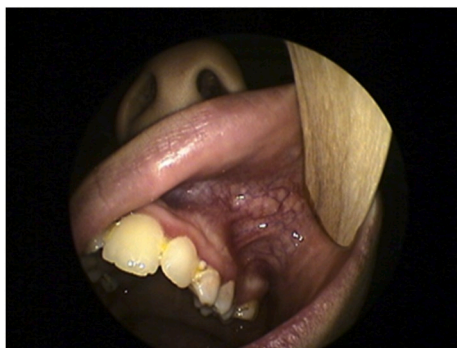


Fig. 1. Telangiectasia in the oral mucosa.

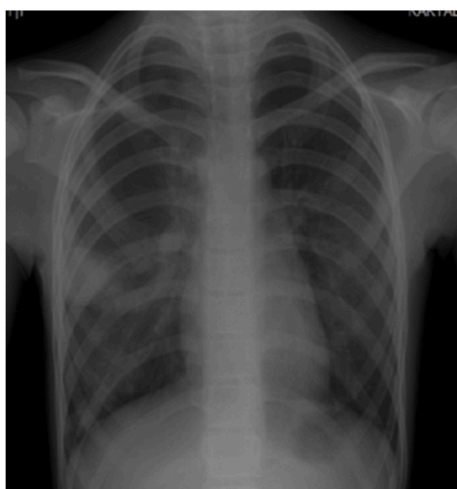


Fig. 2. Chest X-ray in presentation, area of increased density in right middle lobe, arrow.

segments. In CT angiography; dilated vascular structures of  $57 \times 33$  mm in between right middle and lower lobe; and dilated vascular structures of  $62 \times 37$  mm at right lower lobe superior and lateral basal segments connecting right middle and lower lobe pulmonary artery and its segmentary branches to right inferior pulmonary vein and segmentary branches were seen. Also an aneurysm of  $38 \times 32$  mm in the sub pleural area at the level of right middle and lower lobe intersection was detected (Fig. 3). Thereby PAVM was diagnosed.

Because of the presence of oral telangiectasias in our patient Curacao criteria were questioned for HHT diagnosis. Our patient, the father and sister also were diagnosed with HHT with positive Curacao criterias. At this stage, no pathology was observed in the brain MRI Angiography which was done for screening the situation of brain vascular structure.

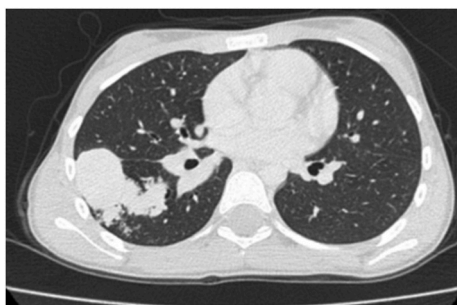


Fig. 3. Dilated vascular structures of  $57 \times 33$  mm in between right middle and lower lobe arteries and right inferior pulmonary vein in dynamic Chest CT.

Since she was symptomatic with hypoxemia, orthopnea, dyspnea and chest pain; endovascular embolization was performed. After the largest AV malformation was embolized with vascular plug in interventional pulmonary angiography (Fig. 4) her symptoms resolved and saturation rose to 95%. Our patient was informed for follow up and then discharged from the hospital. After 5 years, our patient presented again to our hospital with shortness of breath and fatigue with an Oxygen Saturation level of 85%.

Two different AV fistulas with an average of 2 cm in diameter were detected in angiography (Fig. 5a). After closing fistulas by placing transcatheter coils (Fig. 5b), symptoms disappeared and oxygen saturations rose to a level of 94%. Our patient was then discharged and followed up.

### 3. Discussion

HHT is the most common hereditary vascular disease; which is inherited autosomal dominantly with an estimated prevalence of 1:6000 [2]. Diagnosis is based on Curacao criteria in which, 3 of the following 4 criteria are needed for diagnosis: (1) spontaneous and recurrent epistaxis, (2) telangiectasia, (3) family history and (4) pulmonary, cerebral, liver, spinal or gastrointestinal AVM [3].

About 10–15% of patients will not have a mutation detected in a known HHT gene, and in these cases a diagnosis is made based on clinical evaluation alone [4]. Asymptomatic children of a parent with HHT should be considered to have HHT, unless the disease is excluded by genetic testing. Because many of the clinical manifestations of HHT may develop later in life, the Curacao criteria are less sensitive for diagnosing HHT in children [3,4].

Recurrent epistaxis is the most common presenting problem; however, some patients present with a serious event (e.g., hypoxemia, stroke, pulmonary hemorrhage) related to major organ involvement. AVMs develop in larger organ systems (i.e., lungs, liver, and brain). All patients with possible or confirmed HHT should be screened for pulmonary AVMs. Pulmonary AVMs occur in about one third of patients with HHT [5]. Symptoms of the PAVM depend on mostly size and less on number of the lesions. Solitary PAVM smaller than 2 cm are most commonly asymptomatic; whereas bigger lesions may present with symptoms. Main symptoms of cyanosis, polycythemia and clubbing are rarely seen in children. In our patient; AVM were larger than 2 cm and multiple [1]. Symptoms progressed from exertional dyspnea to dyspnea in rest very quickly. Also because of the high flow PAVM shunting; classical triad of cyanosis, polycythemia and clubbing was seen.

Also arteriovenous shunting may result with paradoxical emboli, hemiplegia and brain abscess [6]. Children with possible or confirmed HHT should be screened for cerebrovascular malformations in the first six months of life (or at the time of diagnosis) and at least one follow-up MRI at puberty since brain AVM development appears to correlate with times of growth. Routine screening for cerebral AVMs may detect occult

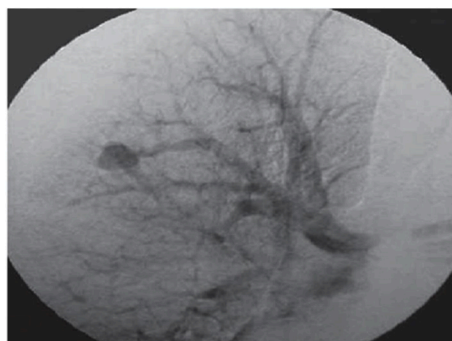


Fig. 4. Plug inserted in between right middle and lower lobe arteries and right inferior pulmonary vein in angiography, arrow.

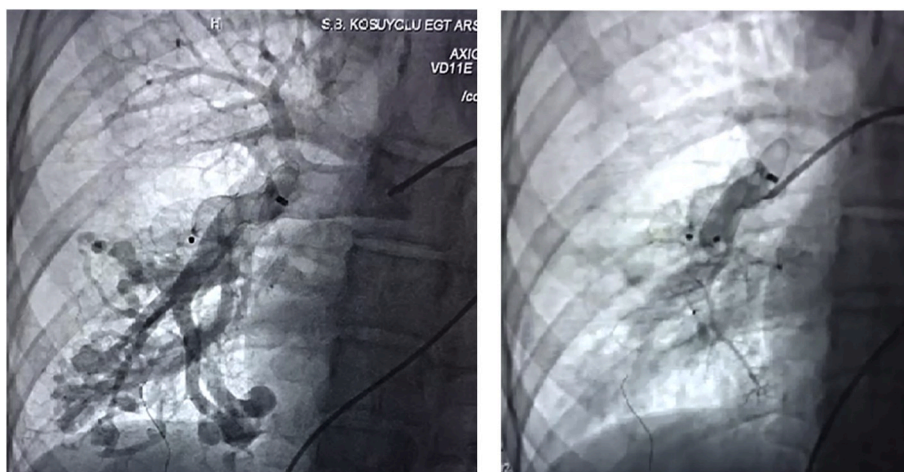


Fig. 5. a) Two different AV fistulas detected in blood vessels of the right lower lobe. b) Leak control after the transcatheter closure process with no leak seen.

lesions, which are present in approximately 10% of patients with HHT [7]. Patients with documented pulmonary AVMs (treated or untreated) should be advised to use antibiotic prophylaxis for any procedures that have a risk of bacteremia; to have air filters on all intravenous lines [8]. In our patient's first presentation, AVM were not observed in the MRI scan. The patient was referred to a dentist for dental control and hygiene. Antibiotic use was also suggested for possible bacteraemia situations.

Screening for GI and liver involvement is recommended only for patients who demonstrate possible symptoms such as GI bleeding, anaemia of unknown etiology, or hepatic failure [9].

Classical radiological appearance of PAVM is round or oval areas of uniformly increased density. But pulmonary X-rays are insufficient for the diagnosis. Other radiological measures include dynamic and conventional thorax CT. Pulmonary conventional angiography is not commonly used in the diagnosis as thorax CT is diagnostic for PAVM<sup>10</sup>. Thorax CT should be the choice of imaging in PAVM in which the lesions are seen as serpiginous or well-defined nodular masses. In dynamic thorax CT; AVM are typically contrasted after the right ventricle and pulmonary artery; and before the left atrium and ventricle [1,10]. Our patient's conclusive diagnosis was achieved by dynamic thorax CT. Pulmonary angiography was performed since she needed embolization.

In PAVM now can be treated with embolization in most of the patients. Before transcatheteric embolization method; AVM were treated with lobectomy, wedge resection or arterial ligation. Currently, surgery is reserved for the patients who have contraindications for embolization or PAVM which don't benefit from embolization or ruptured AVM causing hemothorax [2,10]. Embolization treatment is now recommended even for asymptomatic patients as it improves oxygenation, symptoms caused by right-to-left shunting and reduces risks from hemorrhage and paradoxical emboli [1]. Our patient was severely symptomatic with multiple lesions and transcatheteric embolization was performed successfully.

Lung AVM screening is recommended every 3–5 years, if a pulse oximetry test result is 97% or higher. If a pulse oximetry result is lower than 97%, or a child is short of breath, additional tests or treatment may be required [3]

#### 4. Conclusion

Our message from this case report should be to screen all pediatric HHT patients for PAVMs and brain AVMs. Screening for PAVMs in HHT patients should be done systematically and without waiting for any symptoms to develop.

#### Declaration of competing interest

No funding for The case of HEREDITARY HEMORRHAGIC TELANGIECTASIA AND PULMONARY ARTERIOVENOUS MALFORMATIONS IN 13-YEAR-OLD GIRL.

#### References

- [1] C.L. Shovlin, R. Condliffe, J.W. Donaldson, et al., British thoracic society clinical statement on pulmonary arteriovenous malformations, *Thorax* 72 (2017) 1154–1163.
- [2] S.D. Girod, V. Cottin, C.L. Shovlin, The lung in hereditary hemorrhagic telangiectasia, *Respiration* 94 (2017) 315–330.
- [3] C.L. Shovlin, A.E. Guttmacher, E. Buscarini, et al., Diagnostic criteria for hereditary hemorrhagic telangiectasia (Rendu-Osler-Weber syndrome), *Am. J. Med. Genet.* 91 (2000) 66–67.
- [4] A.M. Gefen, A.J. White, Asymptomatic pulmonary arteriovenous malformations in children with hereditary hemorrhagic telangiectasia, *Pediatr. Pulmonol.* 52 (9) (2017) 1194–1197.
- [5] J.R. Gossage, The role of echocardiography in screening for pulmonary arteriovenous malformations, *Chest* 123 (2) (2003) 320–322.
- [6] A. Kritharis, H. Al-Samkari, D.J. Kuter, Hereditary hemorrhagic telangiectasia: diagnosis and management from the hematologists' perspective, *Haematologica* 103 (9) (2018) 1433–1443.
- [7] B.J. Folz, A.C. Wollstein, H. Alfke, et al., The value of screening for multiple arterio-venous malformations in hereditary hemorrhagic telangiectasia: a diagnostic study, *Eur. Arch. Oto-Rhino-Laryngol.* 261 (9) (2004) 509–516.
- [8] E.C. te Veldhuis, A.H. te Veldhuis, F.S. van Dijk, et al., Rendu-Osler-Weber disease: update of medical and dental considerations, *Oral Surg. Oral Med. Oral Pathol. Oral Radiol. Endod.* 105 (2) (2008) 38–41.
- [9] E. Scott, Olitsky. Hereditary hemorrhagic telangiectasia: diagnosis and management, *Am. Fam. Physician* 8 (7) (2010) 785–790.
- [10] S. Tellapuri, H.S. Park, S.P. Kalva, Pulmonary arteriovenous malformations, *Int. J. Cardiovasc. Imag.* 35 (8) (2019) 1421–14287.