

## CASE REPORT

WILEY

# Congenital ichthyosiform erythroderma with a novel variant in *ABCA12* in a Chinese patient

Zhou Yang<sup>1\*</sup> | Zhan Qi<sup>2\*</sup> | Zhe Xu<sup>1</sup> | Wei Li<sup>2</sup> | Lin Ma<sup>1</sup>

<sup>1</sup>Department of Dermatology, Beijing Children's Hospital, Capital Medical University, National Center for Children's Health, Beijing, China

<sup>2</sup>Beijing Key Laboratory for Genetics of Birth Defects, MOE Key Laboratory of Major Diseases in Children, Center for Medical Genetics, Beijing Pediatric Research Institute, Beijing Children's Hospital, Capital Medical University, National Center for Children's Health, China

**Correspondence**

Lin Ma, Department of Dermatology, Beijing Children's Hospital, Capital Medical University, National Center for Children's Health, Beijing 100045, China.

Email: bch\_maleen@aliyun.com

\*These authors contributed equally to this work.

**Funding source**

National Natural Science Foundation of China (No. 81673042)

Received: 31 October, 2019

Accepted: 14 January, 2020

**ABSTRACT**

**Introduction:** Congenital ichthyosiform erythroderma (CIE) is characterized by fine, whitish scales on a background of erythematous skin over the whole body; it is reportedly caused by mutations in *ABCA12*, *ALOX12B*, *ALOXE3*, *CERS3*, *CYP4F22*, *NIPAL4*, *PNPLA1*, and *TGMI* genes.

**Case presentation:** A 15-month-old girl presented with CIE associated with compound heterozygous *ABCA12* mutations, a known missense mutation c.4139A>G (p.Asn1380Ser) from her father, and a novel missense mutation c.4300A>G (p.Thr1434Ala) from her mother.

**Conclusion:** This is the first report to indicate that compound heterozygous missense mutations in the first ATP-binding cassette of *ABCA12* could contribute to the onset of CIE.

**KEYWORDS**

Congenital ichthyosiform erythroderma, *ABCA12*, Gene mutation

**INTRODUCTION**

Mutations in *ABCA12* have been described in patients with autosomal recessive congenital ichthyoses including congenital ichthyosiform erythroderma (CIE), harlequin ichthyosis (HI), and lamellar ichthyosis (LI). The most severe phenotype, with the largest numbers of truncation or deletion mutations, has been observed in patients with HI. The presence of at least one non-truncating mutation

(predictive of residual protein function) typically causes less severe congenital ichthyosis (CIE or LI). The patients with these mutations are typically born with a collodion membrane, which is sheds in the first few weeks of life. Subsequently, CIE manifests as fine, whitish scales on a background of erythematous skin; while conversely, LI is characterized by the onset of large, thick, dark scales over the surface of the entire body, without serious background erythroderma.<sup>1-3</sup>

DOI: 10.1002/ped4.12182

This is an open access article under the terms of the Creative Commons Attribution-NonCommercial-NoDerivs License, which permits use and distribution in any medium, provided the original work is properly cited, the use is non-commercial and no modifications or adaptations are made.

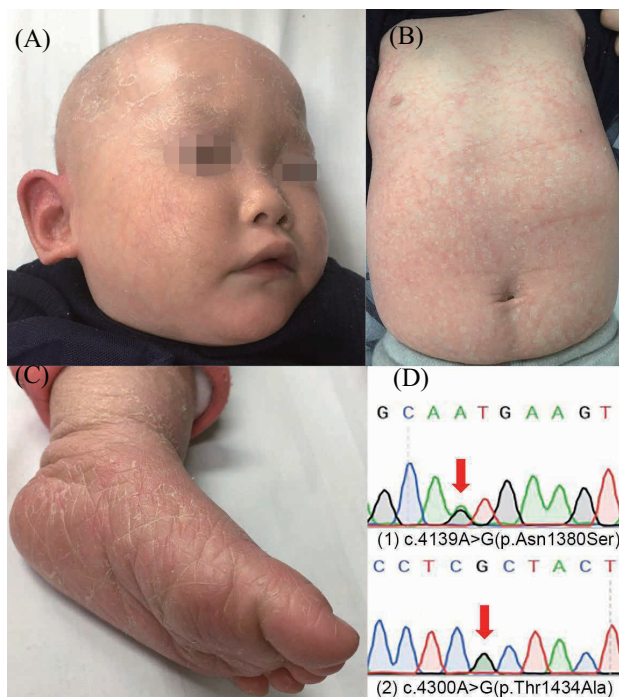
©2020 Chinese Medical Association. *Pediatric Investigation* published by John Wiley & Sons Australia, Ltd on behalf of Futang Research Center of Pediatric Development.

*ABCA12* mutations are reported to underlie autosomal recessive congenital ichthyoses in patients of European, African, Pakistani, Saudi Arabian, Israeli, and Spanish origin; in patients of Japanese origin, *ABCA12* mutations are frequently associated specifically with CIE.<sup>1-8</sup> However, such associations have rarely been reported in Chinese patients.<sup>4</sup> Here, we describe a Chinese girl with CIE who carried two *ABCA12* mutations, one of which was novel and not previously described.

## CASE REPORT

This study was approved by the Ethical Committee of Beijing Children's Hospital, Capital Medical University and was conducted in accordance with the principles of the Declaration of Helsinki. Informed consent was obtained from the patient's parents.

A 15-month-old girl with whitish scales on an erythematous background with slight ectropion and the absence of palmoplantar keratoderma was admitted to our hospital. Her hair, eyebrows, and eyelashes were noticeably sparse (Figure 1). She exhibited hypohidrosis and mild heat intolerance. Her hearing and vision were normal, and she showed no abnormalities in the heart or abdomen, based on ultrasound examinations. She was born with a collodion membrane; notably, no other members of her family had similar skin manifestations. She was finally diagnosed with CIE. Accordingly, emollients were used to control scaling and to improve the skin barrier function.



**FIGURE 1** Clinical features and genetic analysis of a 15-month-old girl with congenital ichthyosiform erythroderma. (A) Her hair, eyebrows, and eyelashes were clearly sparse with slight ectropion. (B) Whitish scales on an erythematous background. (C) Absence of palmoplantar keratoderma. (D) Compound heterozygous *ABCA12* mutations were detected in the patient.

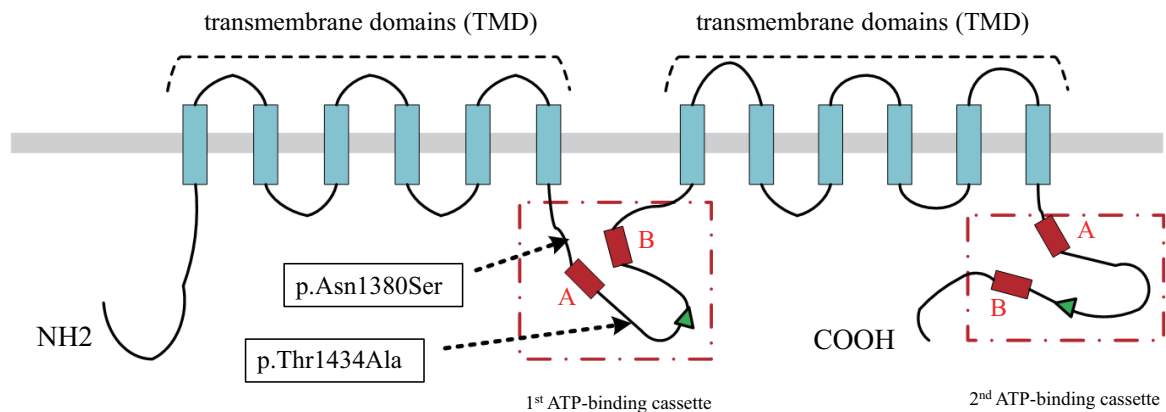
Blood was extracted from the patient and her parents to perform genetic diagnosis. Genomic DNA was isolated using standard procedures. The sequencing library constructed from the DNA sample of the patient was subjected to next-generation sequencing (NGS) for a panel of genes involved in ichthyosis (designed by Beijing Pediatric Research Institute). Coding regions of the target genes and 10-bp portions of adjacent introns were sequenced using custom-designed capture probes (Agilent Technologies, Santa Clara, CA, USA). Sequence variants identified in the patient by NGS were verified by Sanger sequencing in the patient and her parents. The results revealed compound heterozygous *ABCA12* mutations including a known paternal missense mutation c.4139A>G (p.Asn1380Ser), and a novel maternal missense mutation c.4300A>G (p.Thr1434Ala); the maternal mutation was predicted to be pathogenic by SIFT, Polyphen and Mutation taster. To the best of our knowledge, it has not been previously reported (based on searches of HGMD, ClinVar and PubMed) and is absent from the population (based on searches of 1000 Genomes, ExAC and dbSNPs).

## DISCUSSION

HI, LI, and CIE are autosomal recessive congenital ichthyoses, which form a heterogeneous group of non-syndromic disorders of keratinization. The genotype-phenotype correlation is not very clear in patients with these disorders, because mutations in the same genes may lead to divergent phenotypes, while a single phenotype may be associated with any of several underlying mutations. CIE can be caused by mutations in the *ABCA12*, *ALOX12B*, *ALOXE3*, *CERS3*, *CYP4F22*, *NIPAL4*, *PNPLA1*, and *TGMI* genes, as well as mutations in other unidentified genes.<sup>1-4</sup>

*ABCA12* belongs to a subfamily of the ATP-binding cassette transporter protein superfamily, which carries out energy-dependent transport of substrate molecules. Notably, *ABCA12* can bind and hydrolyze ATP to facilitate the transport of lipids into the trans-Golgi network and lamellar granules, thereby enabling the accumulation of lipids that are necessary in formation of the skin barrier.<sup>5,6</sup> Other findings suggest an additional essential role for *ABCA12* in transferring proteolytic enzymes that are required for normal desquamation.<sup>7</sup> *ABCA12* contains two transmembrane domains, each with approximately six membrane-spanning segments, and two ATP-binding cassettes in the cytoplasm (Figure 2). Importantly, *ABCA12* is expressed in keratinocytes. Therefore, *ABCA12* deficiency causes disruptions in lamellar granule lipid transport, which lead to defective intercellular lipid layers in the stratum corneum and altered integrity of the skin barrier function; these changes result in extreme compensatory hyperkeratosis.<sup>1,2</sup>

Distinct mutations in *ABCA12* may produce markedly disparate phenotypes. More than 93% of patients with HI reportedly exhibit homozygous or heterozygous



**FIGURE 2** Structure of the *ABCA12* protein and the two mutations detected in this patient. The ATP-binding cassettes contain three characteristic highly conserved motifs: Walker A motif (the red box A), Walker B motif (the red box B) and active transport signature (the green array).

truncation and deletion mutations in *ABCA12*, which lead to considerable loss of function. The most severe phenotype is present in patients with HI, which is characterized by thick, fissured, armor-plate hyperkeratosis; severe eclabium and ectropion; auricle malformation; and early complications. Patients with less severe congenital ichthyoses, such as CIE or LI, carry at least one non-truncating mutation, although a few have two truncation mutations.<sup>1-4</sup> Lefevre et al<sup>8</sup> reported that the mutations (homozygous p.Asn1380Ser, p.Gly1381Glu, p.Arg1514His, p.Glu1539Lys, and p.Gly1651Ser; compound heterozygous p.Asn1380Ser and p.Gly1651Ser) were clustered in the region of the first ATP-binding cassette (an active site essential for function); they presumed that these mutations underlie the LI phenotype in Africa. In CIE, which is prevalent in Japan, more than half of the mutations in *ABCA12* (e.g., missense, nonsense, deletion, and splice site mutations) are present in the transmembrane and protein-binding domains.<sup>9-12</sup> Akiyama<sup>9</sup> suggested that at least one missense mutation in transmembrane domains might underlie the CIE phenotype in Japan. In Spain, two unrelated patients with CIE demonstrated homozygous p.Asn1380Ser mutations, and a founder effect was reported.<sup>13</sup>

In conclusion, to the best of our knowledge, this is the first report to suggest that compound heterozygous missense mutations (p.Asn1380Ser and p.Thr1434Ala) in *ABCA12* may produce a partial loss of function leading to a mild ichthyosis phenotype (CIE), despite their location in a functional domain (i.e., the first ATP-binding cassette) (Figure 2). Our finding expands the phenotypic and genotypic spectrum of *ABCA12* mutations. In addition, it will aid in the prenatal genetic diagnosis when the patient's mother gives birth to another baby.

## ACKNOWLEDGMENTS

We would like to thank the patient and her family.

## CONSENT FOR PUBLICATION

Consent was obtained from the patient's parents.

## CONFLICT OF INTEREST

The authors declare no conflict of interest.

## REFERENCES

1. Fischer J. Autosomal recessive congenital ichthyosis. *J Invest Dermatol.* 2009;129:1319-1321.
2. Akiyama M. Novel *ABCA12* missense mutation p.Phe2144Ser underlies congenital ichthyosiform erythroderma. *J Dermatol.* 2013;40:581-582.
3. Pigg MH, Bygum A, Gånemo A, Virtanen M, Brandrup F, Zimmer AD, et al. Spectrum of autosomal recessive congenital ichthyosis in Scandinavia: Clinical characteristics and novel and recurrent mutations in 132 Patients. *Acta Derm Venereol.* 2016;96:932-937.
4. Yang Z, Xu Z, Xing H, Ma L. Novel *ABCA12* compound heterozygous mutations identified in a patient with congenital ichthyosiform erythroderma and aortopulmonary window. *Eur J Dermatol.* 2019;29:83-85.
5. Akiyama M, Sugiyama-Nakagiri Y, Sakai K, et al. Mutations in lipid transporter *ABCA12* in harlequin ichthyosis and functional recovery by corrective gene transfer. *J Clin Invest.* 2005;115:1777-1784.
6. Sakai K, Akiyama M, Sugiyama-Nakagiri Y, McMillan JR, Sawamura D, Shimizu H. Localization of *ABCA12* from Golgi apparatus to lamellar granules in human upper epidermal keratinocytes. *Exp Dermatol.* 2007;16:920-926.
7. Zhang L, Ferreyros M, Feng W, Hupe M, Crumrine DA, Chen J, et al. Defects in stratum corneum desquamation are the predominant effect of impaired *ABCA12* function in a novel mouse model of harlequin ichthyosis. *PLoS One.* 2016;11:e0161465.
8. Lefèvre C, Audebert S, Jobard F, Bouadjar B, Lakhdar H, Boughdene-Stambouli O, et al. Mutations in the transporter *ABCA12* are associated with lamellar ichthyosis type 2. *Hum Mol Genet.* 2003;12:2369-2378.
9. Akiyama M. *ABCA12* mutations and autosomal recessive congenital ichthyosis: A review of genotype/phenotype correlations and of pathogenetic concepts. *Hum Mutat.* 2010;31:1090-1096.

10. Shimizu Y, Sugiura K, Aoyama Y, Ogawa Y, Hitomi K, Iwatsuki K, et al. Novel *ABCA12* missense mutation p.Phe2144Ser underlies congenital ichthyosiform erythroderma. *J Dermatol*. 2013;40:581-582.
11. Wada Y, Kusakabe M, Nagai M, Yamamoto M, Imai Y, Ide YH, et al. Mild case of congenital ichthyosiform erythroderma with periodic exacerbation: Novel mutations in *ABCA12* and upregulation of calprotectin in the epidermis. *J Dermatol*. 2017;44:e282-e283.
12. Murase C, Takeichi T, Sugiura K, Kobayashi M, Shiomi K, Ikebuchi K, et al. Hearing impairment: A secondary symptom in a congenital ichthyosiform erythroderma patient with *ABCA12* mutations. *J Dermatol*. 2018;45:e303-e304.
13. Esperón-Moldes U, Ginarte M, Rodríguez-Pazos L, Fachal L, Pozo T, Aguilar JL, et al. *ABCA12* mutations in patients with autosomal recessive congenital ichthyosis: evidence of a founder effect in the Spanish population and phenotype-genotype implications. *J Dermatol Sci*. 2018;91:328-331.

**How to cite this article:** Yang Z, Qi Z, Xu Z, Li W, Ma L. Congenital ichthyosiform erythroderma with a novel variant in *ABCA12* in a Chinese patient. *Pediatr Invest*. 2020;4:51-54. <https://doi.org/10.1002/ped4.12182>