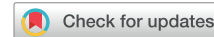



Since January 2020 Elsevier has created a COVID-19 resource centre with free information in English and Mandarin on the novel coronavirus COVID-19. The COVID-19 resource centre is hosted on Elsevier Connect, the company's public news and information website.

Elsevier hereby grants permission to make all its COVID-19-related research that is available on the COVID-19 resource centre - including this research content - immediately available in PubMed Central and other publicly funded repositories, such as the WHO COVID database with rights for unrestricted research re-use and analyses in any form or by any means with acknowledgement of the original source. These permissions are granted for free by Elsevier for as long as the COVID-19 resource centre remains active.

Convalescent plasma for coronavirus disease 2019 in pregnancy: a case report and review



OBJECTIVE: Pregnant women with coronavirus disease 2019 (COVID-19) show overall similar clinical features as that of nonpregnant adults with COVID-19, except perhaps for higher risk of admission to the intensive care unit (ICU) and mechanical ventilation.¹ Among pregnant women with COVID-19, more than 85% to 90% have no or mild symptoms, 5% to 10% have symptoms severe enough to warrant hospitalization and at times oxygen therapy but no mechanical ventilation, and 1% to 2% develop critical disease requiring mechanical ventilation and at times leading even to death.¹ Most promising therapeutic possibilities for severe acute respiratory syndrome coronavirus 2 (SARS-CoV-2) infection in pregnancy include currently remdesivir and convalescent plasma (CP). In this study, we present a case of a pregnant

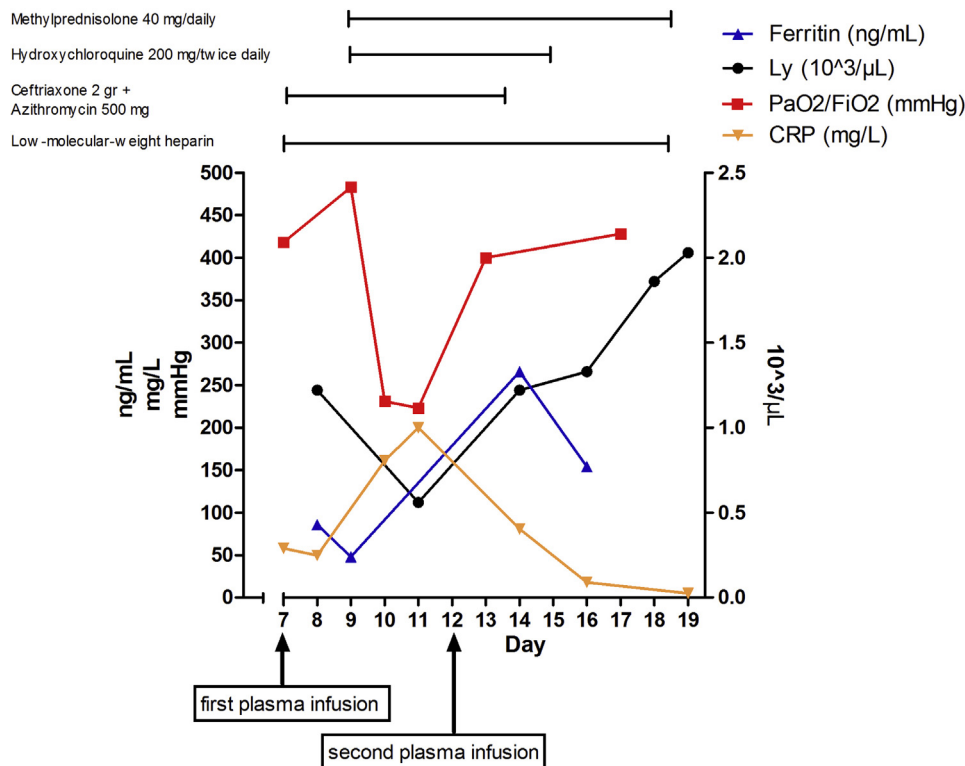
woman treated with CP at the city hospital of Mantova in Italy.

STUDY DESIGN: This study involved a 29-year-old gravida 2, para 1 patient (previous preterm birth at 36 4/7 weeks of gestation) with a body mass index of 31 and with a singleton gestation who presented at the emergency room on April 9, 2020 at 24 2/7 weeks of gestation with worsening cough and fever, which started approximately 7 days before.

At presentation, she was febrile (38.0°C) and normotensive, with a respiratory rate of 20 bpm and an O₂ saturation (SpO₂) of 95%. Laboratory tests showed normal white blood cell and procalcitonin values, a C-reactive protein concentration of 58.6 mg/L, and normal arterial blood gas values. The polymerase chain reaction (PCR) nasopharyngeal (NP)

FIGURE

Case report: graphical course of laboratory and clinical parameters



Normal range Ferritin 13 - 150 ng/mL
 Normal range C - Reactive Protein (CRP) < 5 mg/L
 Normal range Lymphocyte (Ly) count 1.30 - 4.80 *10³/μL
 Acute respiratory distress syndrome PaO₂/FiO₂ < 300

Grisolia. Convalescent plasma for coronavirus disease 2019 in pregnancy. AJOG MFM 2020.

TABLE
Clinical course of 3 pregnant women affected by COVID-19 treated with CP

Author	Gestational age	Severity of disease	Invasive procedures	Comorbidity	CP dose (units)	Other medications	Outcome	
Zhang et al ⁴	35 wk and 2 d	Severe ARDS	Mechanical ventilation	—	1	Lopinavir and ritonavir	Maternal well-being	
		Septic shock	CRRT			Ribavirin	Newborn death because of intrauterine asphyxia	
		MOF	ECMO			Imipenem		
			Cesarean delivery			Vancomycin		
Anderson et al ⁵	22 wk and 2 d	Severe ARDS	Mechanical ventilation	Type 2 DM	1	Remdesivir	Maternal well-being	
				Asthma		Ceftriaxone	Normal ongoing pregnancy	
				Class III obesity		Azithromycin		
						Hydroxychloroquine		
						Hydrocortisone		
Grisolia et al (present study)	24 wk and 2 d	Mild ARDS	—	Class I obesity	2	Ceftriaxone	Maternal well-being	
							Azithromycin	Normal ongoing pregnancy
							Hydroxychloroquine	
							Methylprednisolone	
							LMWH	

ARDS, acute respiratory distress syndrome; COVID-19, coronavirus disease 2019; CP, convalescent plasma; CRRT, continuous renal replacement therapy; DM, diabetes mellitus; ECMO, extracorporeal membrane oxygenation; LMWH, low-molecular-weight heparin; MOF, multiorgan failure.

Grisolia. Convalescent plasma for coronavirus disease 2019 in pregnancy. AJOG MFM 2020.

test for SARS-CoV-2 returned positive. Initial chest X-ray revealed a parenchymal thickening of the upper right lobe. Fetal well-being was assessed by obstetrical ultrasound and nonstress test, the latter not detecting uterine contractions. Antibiotic therapy (ceftriaxone and azithromycin) and prophylactic low-molecular-weight heparin (LMWH) were started. The following day, the patient showed a mild clinical worsening, with persistent dry cough, fatigue, dyspnea, fever (38.5°C), and lymphopenia; her SpO₂ was 95% on room air. Following a pneumological evaluation, considering gestational age, the patient was transfused with 300 mL of CP, with no adverse effects. Antepartum testing for fetal well-being was reassuring both before and after the transfusion. The following day, a clinical worsening was observed, with persistently high fever (39.5°C), tachypnoea (30 bpm), hypotension (90/60 mm Hg), and an SpO₂ of 91% on room air. Lymphopenia, elevated interleukin-6, and serum ferritin level were reported as well. However, it should be noted that her PCR NP test for SARS-CoV-2 returned negative. Chest ultrasound revealed bilateral pleural thickening with nodulations and several B lines (>4/field). Obstetrical ultrasound showed regular fetal biometry with normal umbilical arterial Doppler assessment. Because of the rapid worsening of her clinical condition and laboratory values (Figure), the patient was transferred to the ICU where she was given oxygen therapy via a nasal cannula (4 L/min). She was initiated on hydroxychloroquine, LMWH at a therapeutic dose, and methylprednisolone. The peak of severity was reached 2 days after admission to the ICU, when she developed acute respiratory distress syndrome. The ratio of the partial pressure of arterial oxygen to the percentage of inspired oxygen (PaO₂/FiO₂) fell to a minimum value of 223. She was supported with oxygen therapy via nasal cannula over noninvasive ventilation (FiO₂, 36%) without the need for intubation. Obstetrical ultrasound showed a normal umbilical artery pulsatility index (UA-PI) and fetal ductus venosus with an observed a wave. The middle cerebral artery peak systolic velocity (MCA-PSV) was >1.5 multiples of median, with diastolic reverse flow. As a result, the patient was again transfused with 300 mL of CP on day 12 from onset of symptoms, with no adverse reactions. The patient's clinical condition rapidly improved as shown by normalization of laboratory tests and vital signs within 3 days of the second CP transfusion (Figure). In particular, we observed a rapid normalization in body temperature and SpO₂ and a prompt resolution of dyspnea. The PCR NP test for SARS-CoV-2 was repeated on days 15 and 17 with both tests returning with negative results. The patient was discharged 13 days after admission. The mother's chest ultrasound showed near-complete resolution of bilateral pneumonia. Fetal Doppler assessment was normal, with UA-PI and MCA-PSV within the normal range for gestational age. The outpatient examinations, performed every week for 1 month, showed a complete recovery of pulmonary function. Pregnancy continued to be monitored after hospital discharge by fetal ultrasonography with Doppler assessment every 2

weeks. In the study, fetal biometry results were consistent with gestational age (34 weeks of gestation).

RESULTS: Comparing our patient with those in a US cohort of pregnant women with severe COVID-19,² the clinical course was similar, with hospital admission on day 7 after onset of symptoms, initiation of O₂ therapy on day 9, peak respiratory support on day 10, hydroxychloroquine treatment started on day 9, and symptom resolution on day 15. The rationales for the use of CP in our patient were to prevent the mother's condition from worsening, to avoid a possible cesarean delivery at a gestational age of severe prematurity, and to reduce potential maternal and fetal risk associated with the administration of various drugs utilized for COVID-19.

In 1 published randomized controlled trial, there is evidence that CP can be used effectively as a therapy for severe COVID-19 in nonpregnant adults, shortening time to clinical improvement by 5 days, and with trends for improvement in other outcomes, including death, without causing severe adverse events.³ Regarding SARS-CoV-2 infection in pregnancy, pregnancy is not a contraindication to blood component transfusion, and 2 other cases of pregnancies managed using CP have been reported (Table).^{4,5} In a single report, CP administration was associated with survival of the mother but resulted to death of the newborn.⁴ In the second case report, CP therapy in association with remdesivir successfully managed a critically ill obstetrical patient.⁵ The case in this study is the first treated with CP without antiviral drugs with a favorable outcome for both the mother and fetus.

CONCLUSION: This case report has several limitations, including the short follow-up (the patient was at 34 weeks of gestation and well) and the concomitant use of other medications that may confound the evaluation of CP effectiveness. Nevertheless, the close temporal association between CP transfusion and improvement in clinical and laboratory parameters represents an encouraging finding.

There are several ongoing randomized clinical trials regarding the use of CP in patients with COVID-19; in many of those trials, pregnancy is not considered as an exclusion criterion.⁶

We hope that further studies on plasma administration can be carried out during pregnancy, especially in a gestational age of severe prematurity, with the purpose of prolonging the course of pregnancy as long as possible. ■

Gianpaolo Grisolia, MD
Obstetrics and Gynecology Unit
Carlo Poma Hospital
Mantova, Italy

Massimo Franchini, MD
Claudia Glingani, BSc
Department of Hematology and Transfusion Medicine
Carlo Poma Hospital
Mantova, Italy
massimo.franchini@asst-mantova.it

Francesco Inglese, MD
Martina Garuti, MD
Massimiliano Beccaria, MD
Lung Unit
Carlo Poma Hospital
Mantova, Italy

Martina Capuzzo, MD
Department of Medical and Surgical Sciences for Mother, Child
and Adult
University of Modena and Reggio Emilia
Modena, Italy

Alessia Pinto, MD
Giorgia Pavan, MD
Lara Righetto, MD
Department of Surgery, Odontostomatology and Maternal and
Child Health
University of Verona
Verona, Italy

Cesare Perotti, MD
Immunohematology and Transfusion Service
Istituto di Ricovero e Cura a Carattere Scientifico Policlinico
San Matteo
Pavia, Italy
Paolo Zampriolo, MD
Obstetrics and Gynecology Unit
Carlo Poma Hospital
Mantova, Italy

Giuseppe De Donno, MD
Lung Unit
Carlo Poma Hospital
Mantova, Italy

This paper is part of a supplement that represents a collection of COVID-related articles selected for publication by the editors of AJOG MFM without additional financial support.

The authors report no conflict of interest.

REFERENCES

1. Center for Disease Control and Prevention. Data on COVID-19 during pregnancy. Available at: <https://www.cdc.gov/coronavirus/2019-ncov/cases-updates/special-populations/pregnancy-data-on-covid-19.html>. Accessed July 22, 2020.
2. Pierce-Williams RAM, Burd J, Felder L, et al. Clinical course of severe and critical COVID-19 in hospitalized pregnancies: a US cohort study. *Am J Obstet Gynecol MFM* 2020. [Epub ahead of print].
3. Li L, Zhang W, Hu Y, et al. Effect of convalescent plasma therapy on time to clinical improvement in patients with severe and life-threatening COVID-19: a randomized clinical trial. *JAMA* 2020. [Epub ahead of print].
4. Zhang B, Liu S, Tan T, et al. Treatment with convalescent plasma for critically ill patients with severe acute respiratory syndrome coronavirus 2 infection. *Chest* 2020;158:e9–13.
5. Anderson J, Schauer J, Bryant S, Graves CR. The use of convalescent plasma therapy and remdesivir in the successful management of a critically ill obstetric patient with novel coronavirus 2019 infection: a case report. *Case Rep Womens Health* 2020. [Epub ahead of print].
6. Valk SJ, Piechotta V, Chai KL, et al. Convalescent plasma or hyper-immune immunoglobulin for people with COVID-19: a rapid review. *Cochrane Database Syst Rev* 2020;5:CD013600.

© 2020 Elsevier Inc. All rights reserved. <https://doi.org/10.1016/j.ajogmf.2020.100174>