

Atrial fibrillation: a risk factor for unfavourable outcome in COVID-19? A case report

Sebastian Schnaubelt ^{1*}, Marie-Kathrin Breyer ², Jolanta Siller-Matula ^{3,4}, and Hans Domanovits¹

¹Department of Emergency Medicine, Medical University of Vienna, Vienna, Austria; ²Pulmonary Intensive Care Unit, Otto-Wagner Spital Vienna, Vienna, Austria; ³Division of Cardiology, Department of Internal Medicine II, Medical University of Vienna, Vienna, Austria; and ⁴Department of Experimental and Clinical Pharmacology, Centre for Preclinical Research and Technology (CEPT), Medical University of Warsaw, Warsaw, Poland

Received 15 April 2020; first decision 21 April 2020; accepted 19 May 2020; online publish-ahead-of-print 24 June 2020

Background

Fulminant cardiac involvement in COVID-19 patients has been reported; the underlying suspected mechanisms include myocarditis, arrhythmia, and cardiac tamponade. In parallel, atrial fibrillation is common in the elderly population which is at particularly high risk for COVID-19 morbidity and mortality.

Case summary

A 72-year-old male SARS-CoV2-positive patient was admitted to the intensive care unit due to delirium and acute respiratory failure. Atrial fibrillation known from history was exacerbated, and made complex rate and rhythm control necessary. Progressive heart failure with haemodynamic deterioration and acute kidney injury with the need for continuous renal replacement therapy were further aggravated by pericardial tamponade.

Discussion

Treatment of acute heart failure in COVID-19 patients with a cytokine storm complicated by tachycardic atrial fibrillation should include adequate rate or rhythm control, and potentially immunomodulation.

Keywords

COVID-19 • Atrial fibrillation • Multiorgan failure • Cardiac tamponade • Case report

Learning points

- Atrial fibrillation might pose an additional risk factor for unfavourable outcome in COVID-19 patients.
- Consider continuous cardio-selective beta-blockers in COVID-19 patients with supraventricular, non-compensatory tachycardia.

Introduction

Coronavirus disease (COVID)-19 is an emerging pandemic manifesting from asymptomatic infection to acute respiratory distress syndrome (ARDS) and multiorgan failure.¹ Various phenotypes have been described, including a procoagulatory state, acute kidney injury (AKI), or hyperinflammatory syndromes such as a cytokine storm.^{2,3} Myocardial involvement is a common finding in critically ill patients, the aetiology being coronary microvascular ischaemia, stress cardiomyopathy, or sometimes viral myocarditis.⁴ We report on an elderly male COVID-19 patient presenting with ARDS and fulminant heart failure aggravated by atrial fibrillation (AF) with fatal outcome.

*Corresponding author. Tel: +43 1 40400 19640, Fax: +43 1 40400 19650, E-mail: sebastian.schnaubelt@meduniwien.ac.at

Handling Editor: Borislav Dinov

Peer-reviewers: Philipp Sommer and Borislav Dinov

Compliance Editor: Christian Fielder Camm

Supplementary Material Editor: Ross Thomson

© The Author(s) 2020. Published by Oxford University Press on behalf of the European Society of Cardiology.

This is an Open Access article distributed under the terms of the Creative Commons Attribution Non-Commercial License (<http://creativecommons.org/licenses/by-nc/4.0/>), which permits non-commercial re-use, distribution, and reproduction in any medium, provided the original work is properly cited. For commercial re-use, please contact journals.permissions@oup.com

Timeline

Day	Events
-6 to 0	Patient suffering from fever, fatigue, and delirium tested positive for SARS-CoV2; home quarantine
1	Worsening of symptoms, subclinical hypoxaemia, ICU admission, and intubation; haemodynamically unstable, requiring catecholamine support; intermittent tachycardic atrial fibrillation
2-3	Continuous renal replacement therapy with immunoadsorption; clinically stable under ARDS-adapted ventilation, catecholamine support, and landiolol
4	Immunoadsorption stopped due to manufacturer's demands
5	Haemodynamic deterioration and intermittent tachycardic atrial fibrillation in spite of exhausted therapeutic options
6	Pericardial tamponade successfully drained
7-8	Deteriorating haemodynamics
9	Death from multiorgan failure

Case presentation

After having developed fever and fatigue, a 72-year-old male patient (body mass index 29.2) was diagnosed with COVID-19 and put in quarantine at home. Clinical worsening resulted in delirium. After 6 days, emergency medical services found the patient severely hypoxic (SpO_2 65%) despite his not complaining about dyspnoea. Oxygen was administered and the patient was transported to a designated COVID-19 pulmonary intensive care unit (ICU).

History revealed a non-insulin-dependent diabetes mellitus type 2 (recent Hba1c 6.4%), aortic dissection type B (stable over time in various CTs), persistent AF, a smoking history (cessation 20 years ago), and chronic obstructive sleep apnoea syndrome (no therapy). Chronic medication consisted of apixaban (5 mg twice daily), gabapentin (150 mg twice daily), bisoprolol (5 mg twice daily), and metformin (500 mg twice daily), and did not include angiotensin-converting enzyme inhibitors or angiotensin receptor blockers.

Upon arrival, the patient was normotensive with an irregular heart rhythm, appearing exhausted and perspiring, but not subjectively dyspnoeic. Auscultation revealed bilateral medium to coarse crackle sounds. He was intubated due to severe hypoxaemia [Horovitz index 111, positive end-expiratory pressure (PEEP) 18 cmH_2O , pressure control max. 32 cmH_2O , FiO_2 80%]. Sufficient oxygenation and normocapnia (pO_2 89 mmHg, pCO_2 45 mmHg) were achieved.

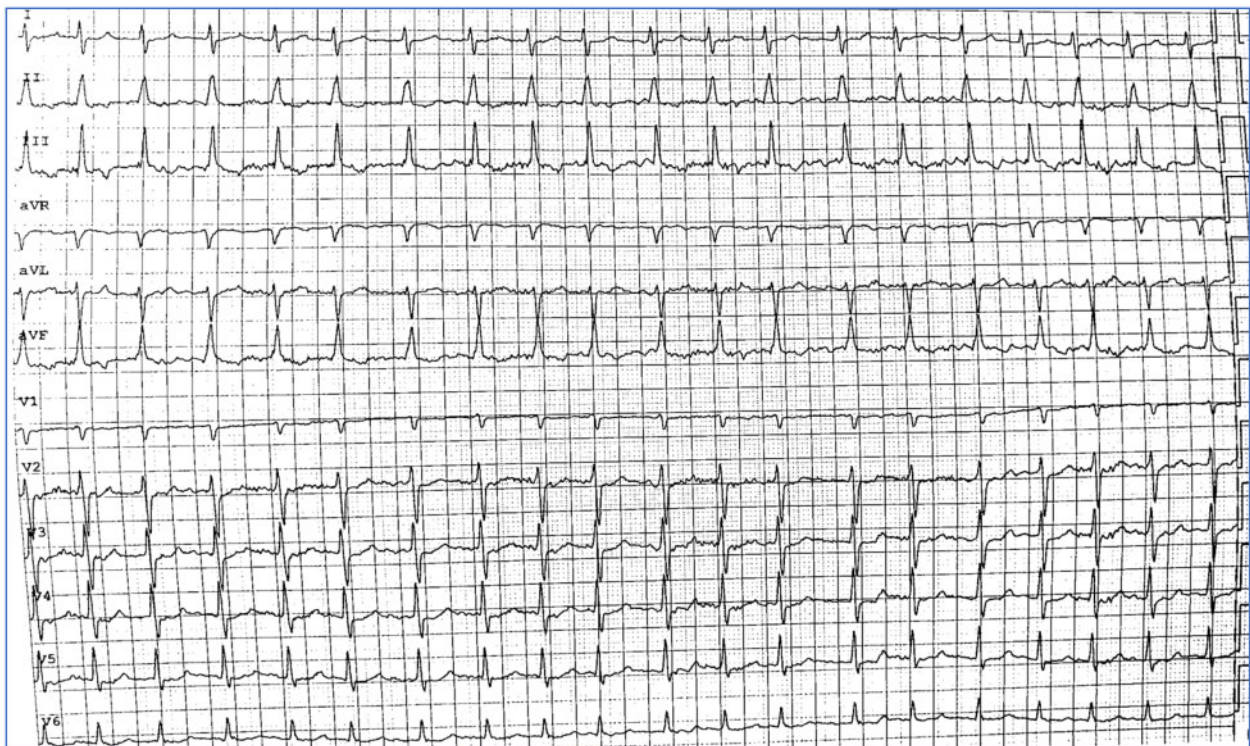


Figure 1 Electrocardiogram (25 mm/s) with atrial fibrillation as described in the text.

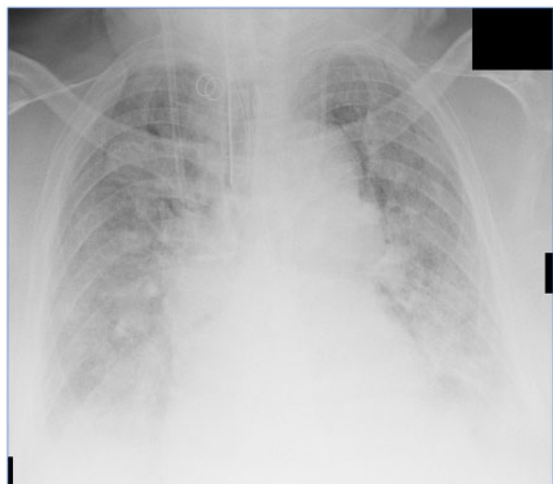

Figure 2 Chest X-ray showing bilateral consolidations as in acute respiratory distress syndrome as described in the text.

Tachycardic AF up to 180 b.p.m. (Figure 1) was successfully electrically cardioverted. However, bedside echocardiography showed globally reduced left ventricular systolic function (LVSF) and ejection fraction (EF, 30%), necessitating noradrenaline and dobutamine support (initial dosages 0.32 $\mu\text{g}/\text{kg}/\text{min}$ and 6.67 $\mu\text{g}/\text{kg}/\text{min}$, respectively). Pulse contour cardiac output monitoring was established (initial values: cardiac index 1.6 L/min/m², cardiac function index 2.2 L/min, global end-diastolic volume index 791 mL/m², pulse pressure variation 14%, extra-vascular lung water index 35.3 mL/kg, pulmonary-vascular permeability index 7.2) to guide further treatment, including careful volume resuscitation, argipressin (1.8 IU/h), hydrocortisone (8 mg/h), and continuous landiolol (initial dose 8 $\mu\text{g}/\text{kg}/\text{min}$) for control of reoccurring tachycardic AF.

A chest X-ray showed bilateral consolidations compatible with ARDS (Figure 2). Laboratory results showed AKI. Continuous renal replacement therapy (CRRT) was established and upgraded with an immunoabsorbant filter (Cytosorb[®]) for 48 h to counteract a suspected cytokine storm mirrored by rising interleukin-6 (IL-6) levels. The initial pro-brain natriuretic peptide (BNP) was 1612 ng/L, ultimately reaching 10-fold levels. High sensitivity troponin T (hs-TnT) values were undulant during the entire stay, with maximum levels of 200 ng/L. For the development of laboratory values over time, see Figure 3. Due to organizational reasons and potential cardiac side effects, it was chosen not to administer experimental therapeutics such as hydroxychloroquine, tocilizumab, or antiviral agents.

More frequent tachycardic AF episodes did not respond to electrical cardioversion, escalation of landiolol (up to 40 $\mu\text{g}/\text{kg}/\text{min}$ without effect of further escalation), or addition of amiodarone (300 mg in 30 min and 38 mg/h over 24 h thereafter). Also, digitoxin (0.25 mg daily) and ivabradine (5 mg twice daily)—initially showing promising results—ultimately proved ineffective. Progressing heart failure seemed to be mainly dependent on tachycardic AF. Levosimendan (10 $\mu\text{g}/\text{kg}/\text{min}$ for 10 min and 0.2 $\mu\text{g}/\text{kg}/\text{min}$ for 24 h thereafter) led to

a transient positive effect that only lasted \sim 24 h. In echocardiographic controls, pericardial effusion (circumference, 2–3 cm, Figure 4) developed in 48 h, leading to pericardial tamponade that was successfully drained (a SARS-CoV-2 test from the fluid was negative). After pericardiocentesis, haemodynamics improved only transiently, and LVSF/EF deteriorated rapidly. At this stage, an ultima ratio treatment option would have been veno-arterial extracorporeal membrane oxygenation (VA-ECMO). However, existing literature surrounding the role of VA-ECMO in the treatment of COVID-19-associated cardiogenic shock is scarce. Due to the multiple comorbidities, resource availability, and the perceived risk–benefit ratio, a decision against ECMO was made. In a multidisciplinary way, a do not resuscitate order was agreed on. Nine days after ICU admission, the patient died from multiorgan failure. Figure 5 gives an overview of the entire case.

Discussion

Cardiac (co-)injury has already been duly noted as a crucial possible COVID-19 characteristic: most reports include perimyocarditis and *de novo* or aggravated heart failure.⁵ Pericardial effusion or tamponade appear in up to 5% of cases.^{6–8} In our patient, perimyocarditis and pericardial effusion might have been triggered by the underlying mechanisms ranging from potential direct viral invasion of the myocardium⁹ and angiotensin-converting enzyme 2 signal pathways to a cytokine storm.^{2,5,10} With extreme levels of IL-6, a state of virally driven hyperinflammation can be suspected in our case. In the final disease stage, the reported patient was positive for secondary haemophagocytic lymphohistiocytosis (sHLH) as suggested by Mehta *et al.*^{2,11} After discontinuation of immunoabsorption, IL-6 values exacerbated, strengthening this theory. In future similar cases, the IL-6 antibody tocilizumab could be a therapeutic option, if available.

The arrhythmogenic effect of COVID-19 might still be underreported and was noted in up to 17% of patients; the literature still lacks more precise differentiation.⁵ Importantly, the presence of AF together with inadequate rate control might have a negative impact on patients' prognosis. With a large prevalence of AF in the general, and especially the elderly, population¹² and the known connection of arrhythmic burden and viral disease,¹³ AF may influence mortality. While there may or may not be a direct causal relationship between AF and COVID-19, the often-needed extensive catecholamine support can either initiate or aggravate AF, therefore inducing a vicious circle of cardiac injury through tachyarrhythmogenic and adrenergic stress.^{4,5,10} A possible treatment add-on in this dilemma would be milrinone, a synthetic non-catecholamine phosphodiesterase type III inhibitor. When compared with dobutamine, milrinone is associated with less tachycardia and increases the cardiac index, but reduces arterial blood pressure and pulmonary vascular resistance (the reason why it is often combined with noradrenaline and vasopressin).¹⁴ Such an approach might represent an alternative in cardiogenic shock with a high ventricular rate.

Besides management of respiratory complications, comorbidities of COVID-19 patients are known to be important risk factors for worse outcome⁵—and AF should be recognized as one of them. In patients with tachyarrhythmia, short-acting cardioselective beta-

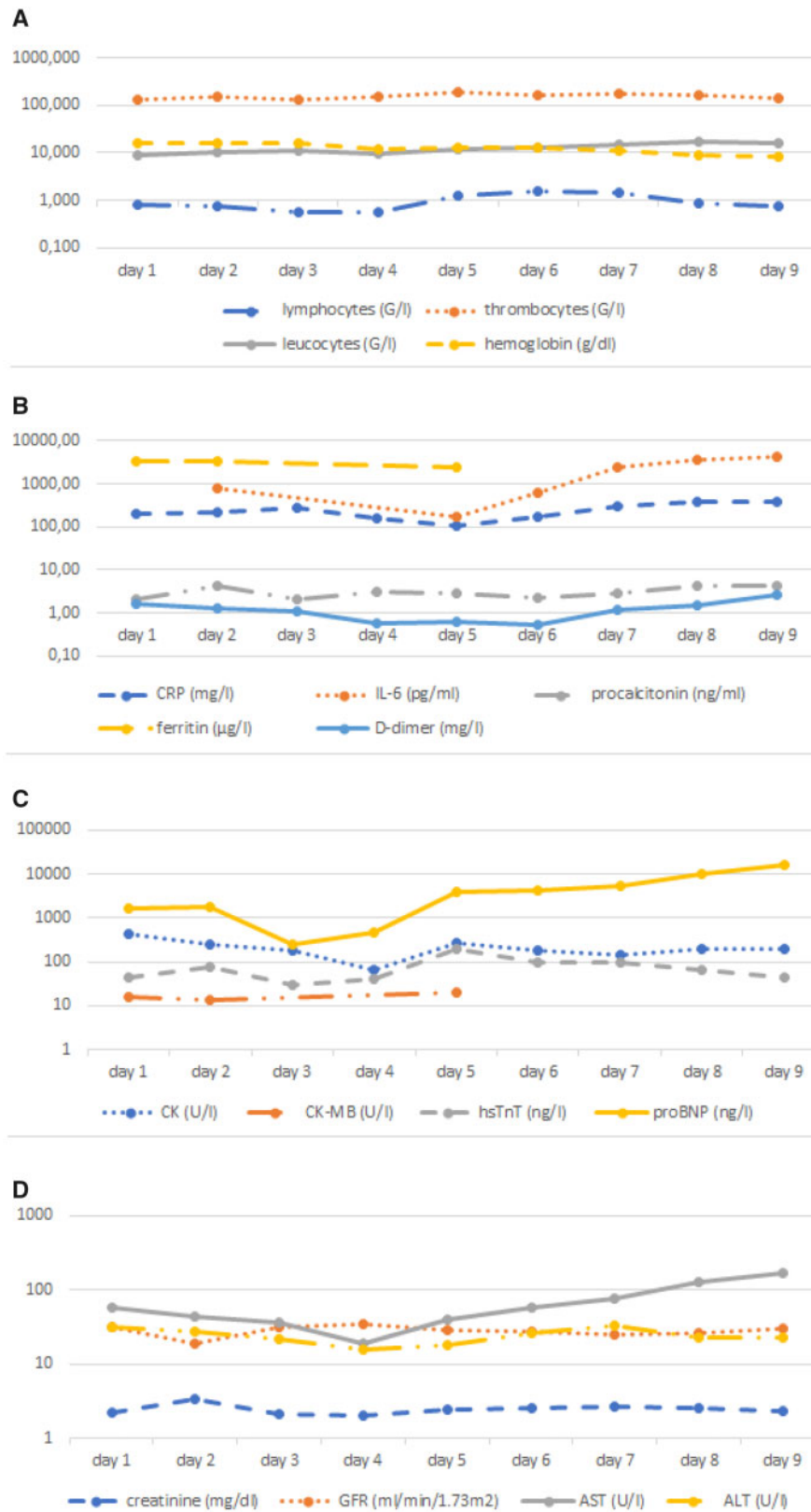


Figure 3 Laboratory values over time. (A) Blood count; (B) immune response; (C) cardiac markers; (D) renal and hepatic values. ALT = alanine aminotransferase; AST = aspartate aminotransferase; BNP = brain natriuretic peptide; CK = creatine kinase; CRP = C-reactive protein; GFR = glomerular filtration rate; hsTnT = high sensitivity troponin-T; IL-6 = interleukin-6.

blockers may be a good initial choice for heart rate control. Frequent reassessment of cardiac function by echocardiography will help to adapt treatment and to recognize complications in the course of the disease.

Conclusion

Treatment of acute heart failure in COVID-19 patients with a cytokine storm complicated by tachycardic AF should

include adequate rate or rhythm control, and potentially immunomodulation.

Lead author biography



Sebastian Schnaubelt is a resident physician at the Emergency Department of the Medical University of Vienna, Austria. His research focuses on arrhythmia, angiology and cardiopulmonary resuscitation under the lead of Prof. Hans Domanovits and Prof. Michael Holzer.

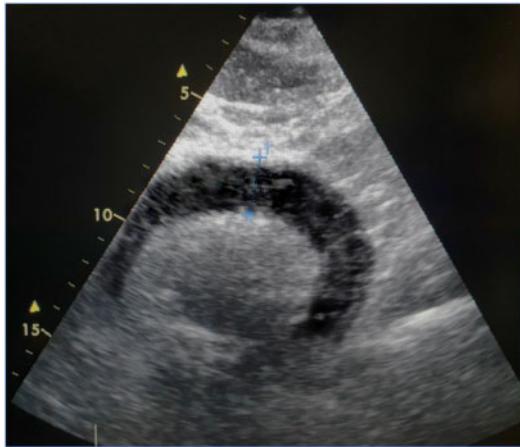


Figure 4 Pericardial tamponade seen in the subxiphoidal echocardiographic view.

Acknowledgements

We thank Professor Dr Anton Laggner, Professor Dr Sylvia Hartl, and the physician and nursing staff of the pulmonary ICU for their support.

Consent: The authors confirm that written consent for submission and publication of this case report including images and associated text has been obtained from the patient’s guardians in line with COPE guidance.

Conflicts of interest: none declared.

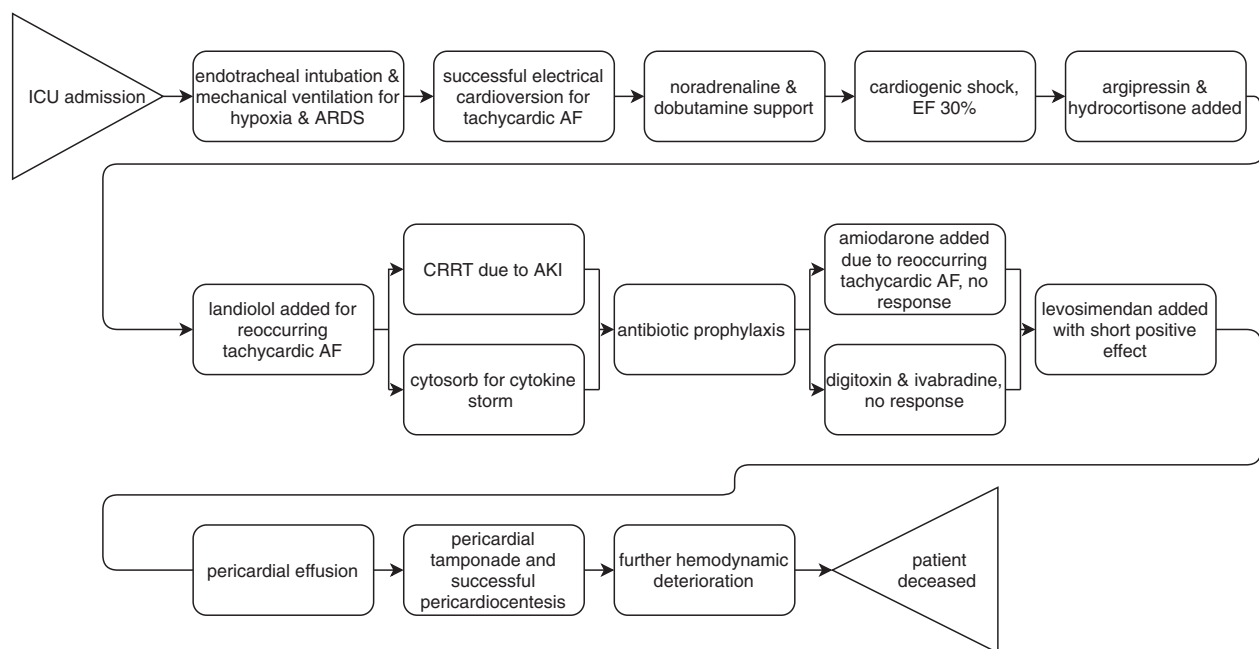


Figure 5 Overview of the case presentation. AF = atrial fibrillation; ARDS = acute respiratory distress syndrome; CRRT = continuous renal replacement therapy; EF = ejection fraction; ICU = intensive care unit.

References

1. Weiss P, Murdoch DR. Clinical course and mortality risk of severe COVID-19. *Lancet* 2020;**395**:1014–1015.
2. Mehta P, McAuley DF, Brown M, Sanchez E, Tattersall RS, Manson JJ. COVID-19: consider cytokine storm syndromes and immunosuppression. *Lancet* 2020;**395**:1033–1034.
3. Zhou F, Yu T, Du R, Fan G, Liu Y, Liu Z, Xiang J, Wang Y, Song B, Gu X, Guan L, Wei Y, Li H, Wu X, Xu J, Tu S, Zhang Y, Chen H, Cao B. Clinical course and risk factors for mortality of adult inpatients with COVID-19 in Wuhan, China: a retrospective cohort study. *Lancet* 2020;**395**:1054–1062.
4. Chapman AR, Bularga A, Mills NL. High-sensitivity cardiac troponin can be an ally in the fight against COVID-19. *Circulation* 2020;doi: 10.1161/CIRCULATIONAHA.120.047008.
5. Huang C, Wang Y, Li X, Ren L, Zhao J, Hu Y, Zhang L, Fan G, Xu J, Gu X, Cheng Z, Yu T, Xia J, Wei Y, Wu W, Xie X, Yin W, Li H, Liu M, Xiao Y, Gao H, Guo L, Xie J, Wang G, Jiang R, Gao Z, Jin Q, Wang J, Cao B. Clinical features of patients infected with 2019 novel coronavirus in Wuhan, China. *Lancet* 2020;**395**:497–506.
6. Hua A, O’Gallagher K, Sado D, Byrne J. Life-threatening cardiac tamponade complicating myo-pericarditis in COVID-19. *Eur Heart J* 2020;doi: 10.1093/eurheartj/ehaa253.
7. Shi S, Qin M, Shen B, Cai Y, Liu T, Yang F, Gong W, Liu X, Liang J, Zhao Q, Huang H, Yang B, Huang C. Association of cardiac injury with mortality in hospitalized patients with COVID-19 in Wuhan, China. *JAMA Cardiol* 2020;doi: 10.1001/jamacardio.2020.0950.
8. Li K, Wu J, Wu F, Guo D, Chen L, Fang Z, Li C. The clinical and chest CT features associated with severe and critical COVID-19 pneumonia. *Invest Radiol* 2020;**55**:327–331.
9. Tavazzi G, Pellegrini C, Maurelli M, Belliato M, Sciutti F, Bottazzi A, Sepe PA, Resasco T, Camporotondo R, Bruno R, Baldanti F, Paolucci S, Pelenghi S, Iotti GA, Mojoli F, Arbustini E. Myocardial localization of coronavirus in COVID-19 cardiogenic shock. *Eur J Heart Fail* 2020;doi: 10.1002/ejhf.1828.
10. South AM, Diz D, Chappell MC. COVID-19, ACE2, and the cardiovascular consequences. *Am J Physiol Heart Circ Physiol* 2020;**318**:H1084–H1090.
11. Rizzo P, Vieceli Dalla Sega F, Fortini F, Marracino L, Rapezzi C, Ferrari R. COVID-19 in the heart and the lungs: could we ‘Notch’ the inflammatory storm? *Basic Res Cardiol* 2020;**115**:31.
12. Kirchhof P, Benussi S, Kotecha D, Ahlsson A, Atar D, Casadei B, Castella M, Diener HC, Heidbuchel H, Hendriks J, Hindriks G, Manolis AS, Oldgren J, Popescu BA, Schotten U, Van Putte B, Vardas P. ESC Scientific Document Group. 2016 ESC Guidelines for the management of atrial fibrillation developed in collaboration with EACTS. *Eur Heart J* 2016;**37**:2893–2962.
13. Kochi AN, Tagliari AP, Forleo GB, Fassini GM, Tondo C. Cardiac and arrhythmic complications in Covid-19 patients. *J Cardiovasc Electrophysiol* 2020;**31**:1003–1008.
14. Ginwalla M, Tofovic DS. Current status of inotropes in heart failure. *Heart Fail Clin* 2018;**14**:601–616.