



Since January 2020 Elsevier has created a COVID-19 resource centre with free information in English and Mandarin on the novel coronavirus COVID-19. The COVID-19 resource centre is hosted on Elsevier Connect, the company's public news and information website.

Elsevier hereby grants permission to make all its COVID-19-related research that is available on the COVID-19 resource centre - including this research content - immediately available in PubMed Central and other publicly funded repositories, such as the WHO COVID database with rights for unrestricted research re-use and analyses in any form or by any means with acknowledgement of the original source. These permissions are granted for free by Elsevier for as long as the COVID-19 resource centre remains active.

Embryology and anatomy of the testis

Embryology	616
Prepubertal testis	622
Adult testis	626

Congenital anomalies of the testis

Alterations in number, size and location	632
Hamartomatous testicular lesions	641
Testicular ectopia	644
Undescended testes	646
Gonadal dysgenesis	653
True hermaphroditism	655
Male pseudohermaphroditism	656

Infertility

Testicular biopsy	665
Infertility and chromosomal anomalies	686
Other syndromes associated with hypergonadotropic hypogonadism	692

Secondary idiopathic hypogonadism	694
Hypogonadism secondary to endocrine gland dysfunction	697
Infertility secondary to physical and chemical agents	705
Infertility in patients with spinal cord injury	708

Inflammation and infection

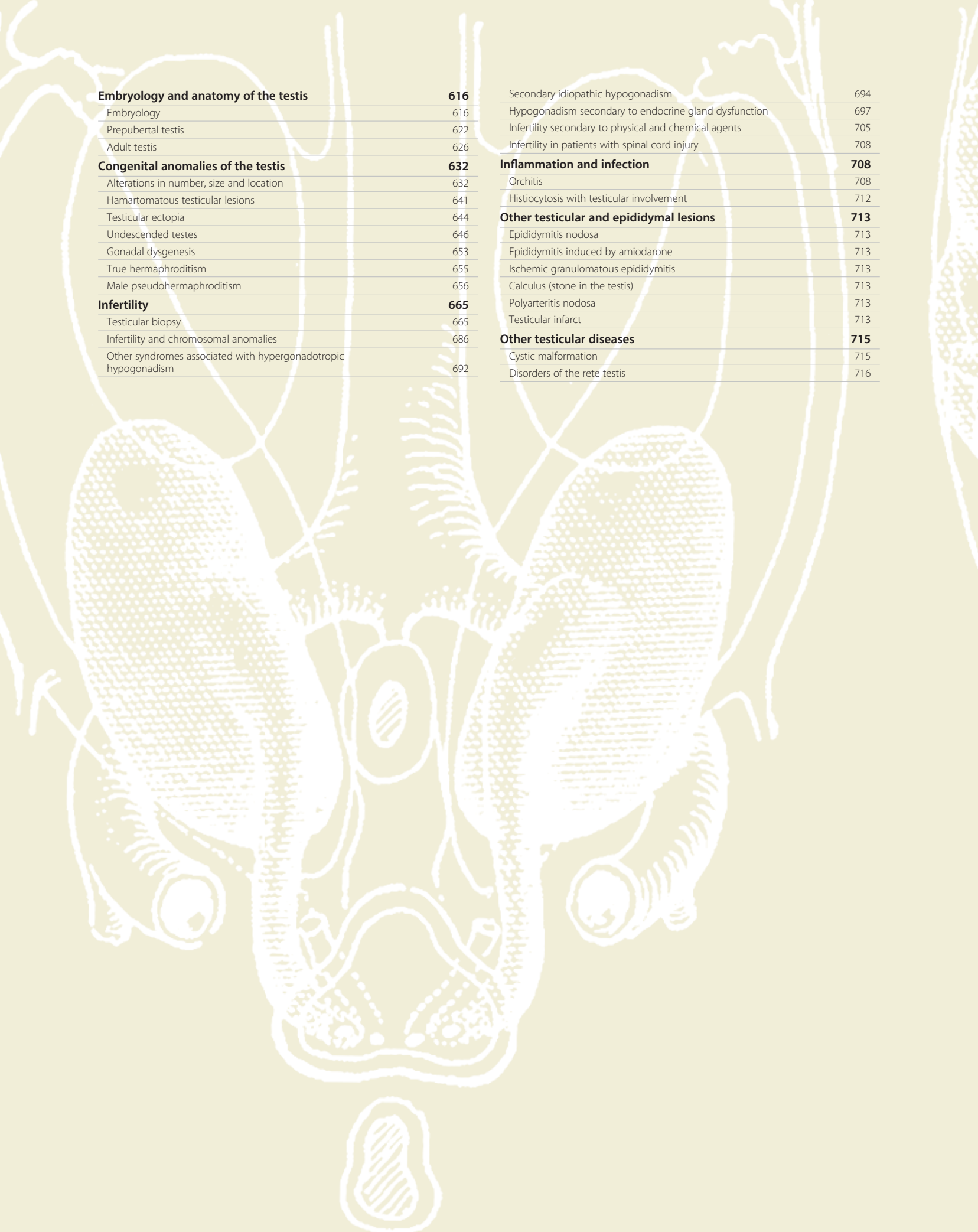
Orchitis	708
Histiocytosis with testicular involvement	712

Other testicular and epididymal lesions

Epididymitis nodosa	713
Epididymitis induced by amiodarone	713
Ischemic granulomatous epididymitis	713
Calculus (stone in the testis)	713
Polyarteritis nodosa	713
Testicular infarct	713

Other testicular diseases

Cystic malformation	715
Disorders of the rete testis	716





CHAPTER 12

**Non-neoplastic diseases
of the testis**

Manuel Nistal, Ricardo Paniagua

Embryology and anatomy of the testis

Embryology

Development of the testis

Genetic mechanisms involved in sex determination and testicular differentiation

Sexual differentiation is the result of complex genetic and endocrine mechanisms that are closely associated with the development of both the genitourinary system and the adrenal glands. Formation of the bipotential gonad and, subsequently, of the ovaries and testes, depends on gene expression in both sex and autosomal chromosomes. Testes secrete steroid and peptidic hormones that are necessary for the development of inner and outer male genitalia. These hormonal actions are mediated by specific receptors that are transcriptional regulators. Alteration of these genetic events leads to sexual dimorphism involving the inner and outer genitalia, and can also hinder the development of other organs.¹

Chromosomal gender is established at fecundation with formation of an egg with either a 46XY (male) or a 46XX (female) karyotype. Each chromosomal constitution initiates a cascade of genetic events leading to the development of female (ovaries) or male (testes) gonads (gonadal gender). Hormonal secretions from the ovaries or testes are essential for the development of external genitalia (phenotypic gender). The relationship between the individual and the environment determines the social gender.

There are multiple genes involved in the formation of the undifferentiated gonad. The two most important for the proper formation of the bipotential gonad are WT1 (Wilms' tumor gene) and NR5A1 (Fig. 12-1).

WT1 contains 10 exons located on chromosome 11p13, with two alternative splicing loci in introns 5 and 9. Intron 9 splicing can lead to the inclusion or exclusion of three amino acids (KTS: lysine, threonine and serine), giving rise to KTS+ or KTS- isoforms. An adequate KTS+/KTS- balance is crucial for normal expression of the gene. Translation of this gene may generate up to 24 isoforms with several zinc-finger domains. This gene is expressed mainly in the kidneys and gonads, and mediates the transition from stroma to epithelium and morphogenetic differentiation (inhibits those genes that encode proliferative factors and activates those that

enhance epithelial differentiation). WT1 gene anomalies lead to a wide variety of phenotypes; deletions are associated with minimal genitourinary alterations and predisposition to develop Wilms' tumor.²⁻⁴ Missense heterozygous mutations give rise to Denys-Drash syndrome (complete or partial 46XY gonadal dysgenesis, renal disease of early onset with diffuse mesangial sclerosis, and Wilms' tumor (OMIM 19408)).⁵ Loss of the KTS+ isoform accounts for Frasier's syndrome (46XY gonadal dysgenesis, renal disease of late onset and absence of Wilms' tumor (OMIM 136680)).⁶

NR5A1 gene product is termed SF-1 (steroidogenic factor 1). The gene has seven exons in chromosome 9q33.3, and is expressed in the urogenital ridge that forms the gonads and adrenal glands. SF-1 promotes the expression of the anti-müllerian hormone (AMH) and joins elements that regulate upstream the AMH gene. SF-1 is first detected in the developing Sertoli cells of sex cords, but later is mainly localized in Leydig cells.⁷ A heterozygous deletion causes a female phenotype in patients with 46XY, adrenal failure during the first weeks of extrauterine life, persistence of normal müllerian structures, and gonads consisting of poorly differentiated tubules embedded in abundant connective tissue. These patients do not respond to hCG stimulation.⁸ In 46XX patients, ovarian development is not modified by SF-1 mutations, and they present with adrenal failure only.⁹

LIM-1 is another gene involved in the formation of the bipotential gonad and kidneys. It was recently identified in mice that bore homozygous deletions and presented alterations in both organs.¹⁰ FGF-9 (fibroblastic growth factor 9) has also been related to gonadal development.

Both gonosomal and autosomal genes mediate the progression of the bipotential gonad toward testicular differentiation. The signal is triggered by the SRY gene on the distal portion of the short arm of the Y chromosome (sex-determining region of the Y chromosome; Yp11.3), also called TDF (testis determining factor gene).¹¹ This gene stimulates the differentiation of Sertoli cell precursors and germ cells, is responsible for the production of the anti-müllerian hormone,¹² and regulates other genes of the downstream cascade. These are either activated or inhibited by other genes in such a way that dozens of genes are involved in testicular differentiation.¹³

The SRY gene contains a single exon that encodes a 204 amino acid protein whose central part (79 amino acids) encodes a DNA-binding domain termed HMG (high mobil-

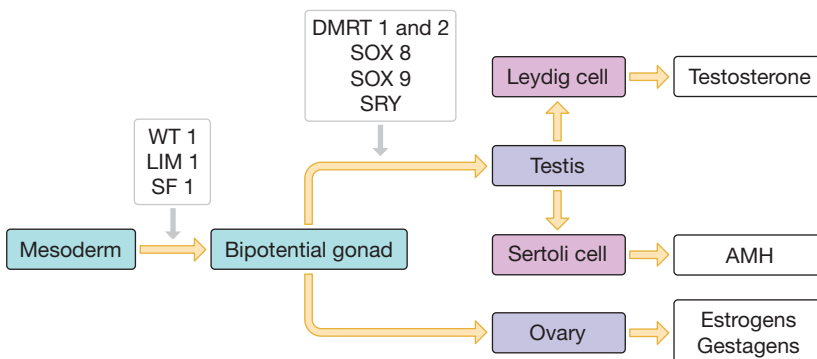


Fig. 12-1 Genetic mechanisms involved in sex determination and testicular differentiation.

ity group). Immunohistochemical studies have demonstrated expression of the SRY gene in the nuclei of both Sertoli cells and germ cells,¹⁴ suggesting that this gene acts in somatic cells of genital ridge and germ cells. SRY works with the AMH promoter gene and also regulates steroidogenic hormone expression.¹⁵ SRY mutations produce pure gonadal dysgenesis (Swyer's syndrome) or true hermaphroditism; the karyotype of patients with the male phenotype lacking Y chromosome is either 46XX SRY+ (80%) or 46XX SRY- (20%), and all have male external genitalia, testes, azoospermia and no müllerian structures. Some 46XX SRY- patients have SOX-9 duplication.¹⁶

Following discovery of the SRY gene, the knowledge about genes involved in gonadal formation advanced experimentally with knockout mice and the study of human syndromes. Now, there are numerous reported genes (including SOX-8, SOX-9, DAX-1, LHX-9, LIM-1 and DMRT-1) that encode associated transcription factors.

SOX-8 and SOX-9 (SRYY box 8 and 9 or SRY HMG-BOX gene 9) are related to autosomal genes. SOX-9 is on chromosome 17q24,3q25,1 and is expressed after SRY expression in the same cell type (the pre-Sertoli cell).¹⁷ This gene is also essential for the development of the cartilaginous extracellular matrix. In the mouse gonad, SOX-9 inhibits testicular development or Sertoli cell marker expression, and the gonad acquires an ovarian pattern.¹⁸ SOX-9 haploinsufficiency (loss of a functional allele) causes camptomelic dysplasia (a syndrome characterized by abnormal formation of cartilage) and a 46XY constitution with female phenotype,^{17,19} whereas SOX-9 duplication results in 46XX patients with male phenotype.²⁰

SOX-8 is other cofactor in AMH regulation and acts by protein-protein interaction with SF-1. Experimental models show that SOX-9 dysfunction results in replacement by SOX-8 expression via a feedback mechanism.²¹

DAX-1 (dosage-sensitive sex-reversal, adrenal hyperplasia, X-linked) gene is involved in the development of testes, ovaries, and adrenal glands. DAX-1, on X chromosome, is expressed during ovarian formation and inhibited by SRY during testicular formation. Duplication of the DAX-1 region in Xp21 results in 46XY gonadal dysgenesis.^{22,23} Conversely, DAX-1 mutations decrease gene expression, resulting in absence of adrenal cortex and hypogonadotropic hypogonadism;¹⁰ testicular determination is normal.

Deletions in chromosomes 9p²⁴ and 10q²⁵ are associated with the female phenotype in 46XY individuals. Chromosome 9p deletions are also associated with facial malformations, premature closure of the frontal suture, hydronephrosis, and delayed development. Deletions of two genes (DMRT1 and DMRT2) on chromosome 9p24.3 may be found in 46XY females. Terminal deletions in chromosome 10q are associated with genital malformations, multiple phenotypic anomalies, and mental retardation.

Histological differentiation of genital ridges

In the fourth week of gestation, the urogenital ridges appear as two parallel prominences along the posterior abdominal wall. These give rise to two important pairs of structures: the genital ridges arising from the medial

prominences, and the mesonephric ridges from the lateral prominences.

The genital ridges are the first primordium of the gonad and stand out as a pair of prominences about the midline. In 30–32-day embryos, each genital ridge is lateral to the aorta and medial to the mesonephric duct (Fig. 12-2). The celomic epithelium forming the genital ridges grows as cord-like structures to create the primary sex cords. Immediately beneath the celomic epithelium there are several mesonephric ductuli and glomeruli (Fig. 12-3).

The origin of the gonadal blastema results from the junction of two cell types: epithelial cells from the celomic epithelium and mesenchymal cells from the mesonephric region,^{26,27} although experimental data are conflicting. One of the earliest effects of SRY expression is induction of mesonephric cell migration toward the genital ridge.^{28,29} Histochemical studies revealed that an early event is also disruption of the celomic epithelium basal lamina, permitting the migration of these epithelial cells inside the gonad. If chromosomal constitution is XY, these cells give rise to Sertoli cells.³⁰ Cells derived from the celomic epithelium are recognized by their pale cytoplasm, large size,

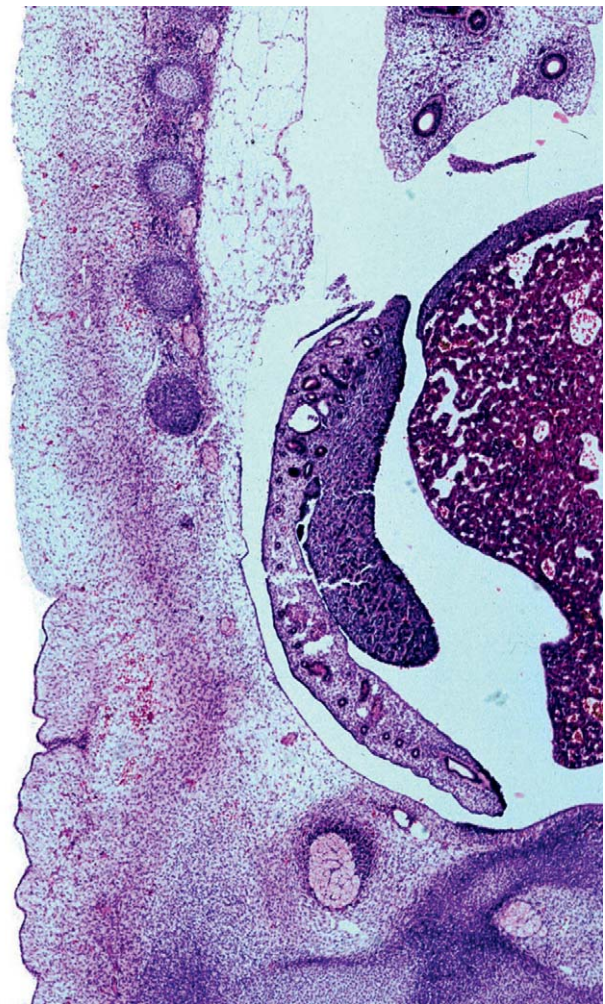

Fig. 12-2 Longitudinal section of a fetus showing the relationship of the primitive gonad, mesonephros, and metanephros.

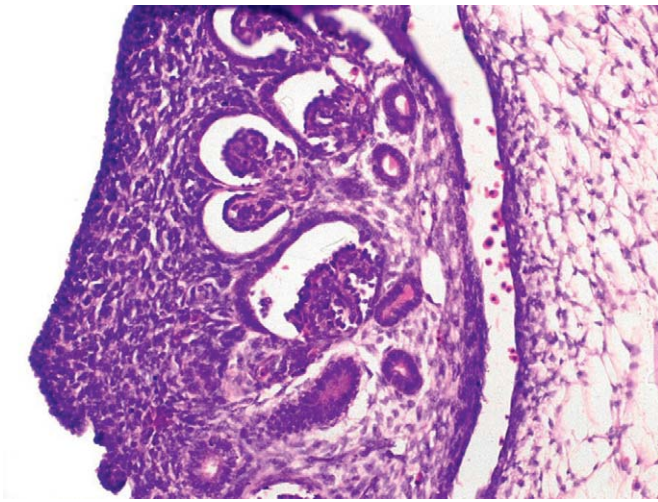


Fig. 12-3 Longitudinal section of the gonad showing the close relation between the gonadal blastema and mesonephric glomeruli.

and ovoid euchromatic nucleus. The cells of mesonephric origin are darker and have a mesenchymal pattern.

Initially, the genital ridges are devoid of germ cells. In the third week, primordial germ cells appear in the extraembryonal mesoderm lining the posterior wall of the yolk sac near the allantoic evagination. They are ovoid, measuring 12–14 μm in diameter, and are easily detected histochemically by a high content of alkaline phosphatase. The nuclei are spherical and possess one or two prominent central nucleoli. The cytoplasm contains mitochondria with tubular cristae, lysosomes, microfilaments, lipid inclusions, numerous ribosomes, and abundant glycogen granules. Attracted by chemotactic factors, the primordial germ cells migrate along the mesenchyma of the mesentery and reach the genital ridge by 32–35 days.

The seminiferous cords arise from the gonadal blastema.^{31,32} Many germ cells reach the seminiferous cords, but some degenerate during migration. The seminiferous cords are delimited from the stroma by a basement membrane³³ and lose their connection to the celomic epithelium, which reduces its depth to one or two cell layers only. The intercordal mesenchyma, composed chiefly of cells that migrated from the mesonephric stroma, differentiate later into myoid cells, Leydig cells, fibroblasts, and blood vessels.³⁴

Up to the sixth week, the gonads appear similar, although the incipient testes have more numerous blood vessels, more abundant stroma,³⁵ and a higher total DNA content, suggesting more rapid growth.

Sertoli cells arise from somatic sex cord cells. These cells differentiate at the end of the seventh week from the somatic cells in the cords, develop adherent junctions between them and a basal lamina on the other cord surface, and begin to express AMH.³⁶

In the eighth week, Leydig cells differentiate from the intercordal gonadal blastema,³⁷ and immunohistochemical detection of $3\beta\text{-HSD}$ is apparently the first step in this process. Leydig cell development peaks during the 18th week, and numbers subsequently decrease progressively.³⁸

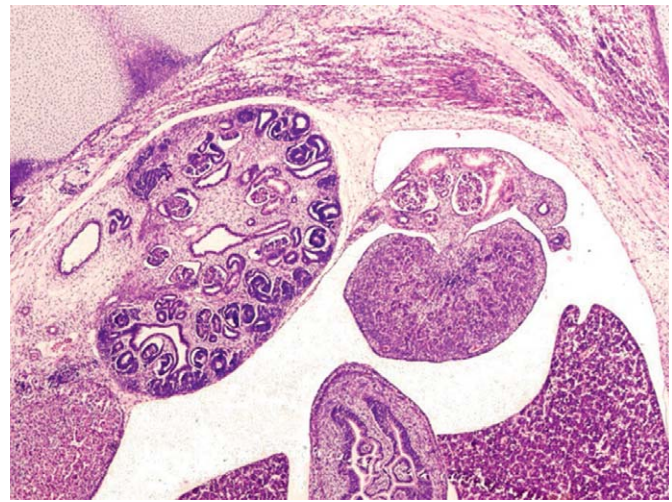


Fig. 12-4 Transverse section of a fetus showing the relationship between the fetal testis, mesonephros and metanephros.

The rete testis originates from mesonephric remnants of sex cords that are in continuity with the seminiferous cords. The connection between the testis and the mesonephros becomes progressively thinner (Fig. 12-4). The testis has a round transversal section, and remains located between two suspensory ligaments: the cranial and the caudal, the latter of which gives rise to the gubernaculum.

Development of the urogenital tract

The development of the urogenital tract begins at the stage of the undifferentiated gonad, with the appearance of two different pairs of ducts: the wolffian and the müllerian.

The wolffian ducts are formed in the mesonephros in the third week of gestation, when the cranial region of the segmented intermediate mesoderm gives rise to 10 pairs of tubules (the nephric tubules) that are metamericly arranged. These tubules form the pronephros. On each side of the body, the tubules converge to form a longitudinal duct that opens in the celomic cavity. In the fourth week, the pronephros disappears and is replaced by another tubular system (derived from the intermediate mesoderm, which is not segmented) that forms the mesonephros. The medial ends of the mesonephric tubules do not open to the celomic cavity but are connected to glomeruli at one end and the wolffian duct at the other. At the end of the second month of gestation, the mesonephros is replaced by the metanephros or definitive kidney. However, in the male, the most caudal mesonephric tubules and the wolffian duct persist. The former give rise to the ductuli efferentes, and the latter forms the ductus epididymidis, the ductus deferens, the seminal vesicle, and the ejaculatory duct.

Both müllerian ducts originate from a longitudinal invagination of the celomic epithelium in the anterolateral aspect of the genital ridge. The cranial end of each duct is a funnel that opens in the celomic cavity. Each duct runs parallel and lateral to the respective wolffian duct and, as they pass caudally, the müllerian duct crosses over the wolffian duct and lies medial to it. Finally, the two müllerian ducts fuse into the uterovaginal duct. This elongates caudally up to the posterior

aspect of the urogenital sinus, forming the müllerian tubercle. The wolffian ducts terminate at either side of this tubercle.

The remaining structures of the male genital system are derived from the urogenital sinus. Epithelium with endodermal origin forms the prostate, the urethra, and the bulbo-urethral and periurethral glands. The primitive urogenital sinus derives from the cloaca, a structure that appears at the end of the first month and which consists of a dilation of the terminal portion of the primitive posterior intestine. The cloaca is closed by the cloacal membrane. In the third week, mesenchyma proliferates in the outer aspect of the cloacal membrane to form the cloacal folds and the cloacal eminence. In the sixth week, the cloacal folds enlarge to form the genital (or urethral) tubercle. External to the genital folds, another mesenchymal thickening develops into the genital prominences or genital swellings.

In the fifth week, a septum forms, dividing the cloaca into two compartments. The anterior compartment is the primitive urogenital sinus that is covered by the urogenital membrane. The posterior compartment is the anorectal canal, covered by the anal membrane. The primitive urogenital sinus then divides into two new compartments: superior and inferior. The superior compartment is the vesicourethral canal that later forms the urinary bladder and the urethra. The inferior compartment is the definitive urogenital sinus that will develop later according to the gender.

Hormonal control

The development of the male genital system is directly influenced by the action of multiple hormones, including anti-

müllerian hormone (AMH), dihydrotestosterone (derived from testosterone), and the pituitary hormones follicle-stimulating hormone (FSH) and luteinizing hormone (LH) (Fig. 12-5).

AMH (müllerian inhibitory substance; MIS),³⁹ secreted by the Sertoli cells, is a glycoprotein polymer consisting of two identical 72 kDa subunits linked by disulfide bonds.⁴⁰⁻⁴² It belongs to the TGF- β family and is synthesized as a 560 amino-acid precursor protein with proteolytic cleavage at 109 amino acids from the C terminal. Cleavage is necessary to activate the hormone. AMH is encoded by a 2.75 kb gene that comprises five exons and is located on the p13.2 region of chromosome 19.

AMH is secreted by somatic cells only in both sexes: Sertoli cells in males and granulosa cells in females. It is detected by 6–7 weeks of gonadal development (8–9 weeks of gestation), probably as soon as germ cells make contact with pre-Sertoli cells, a week before the müllerian ducts lose their responsiveness.^{43,44} AMH is at high concentration in the second trimester, but drops precipitously in the third trimester.⁴⁵ Levels rise again during the first year after birth, are detectable during infancy and childhood, and finally drop definitively to undetectable levels at the onset of puberty. The secreted amount of AMH is inversely correlated to the degree of Sertoli cell maturation.

AMH regulation is incompletely understood. Its expression is controlled by steroidogenic factor 1 (SF-1), also called Ad4BP,⁴⁶ which is an orphan nuclear receptor that acts as a transcriptional regulator of all steroidogenic genes. AMH regulates SRY expression, which in Sertoli cells is detected

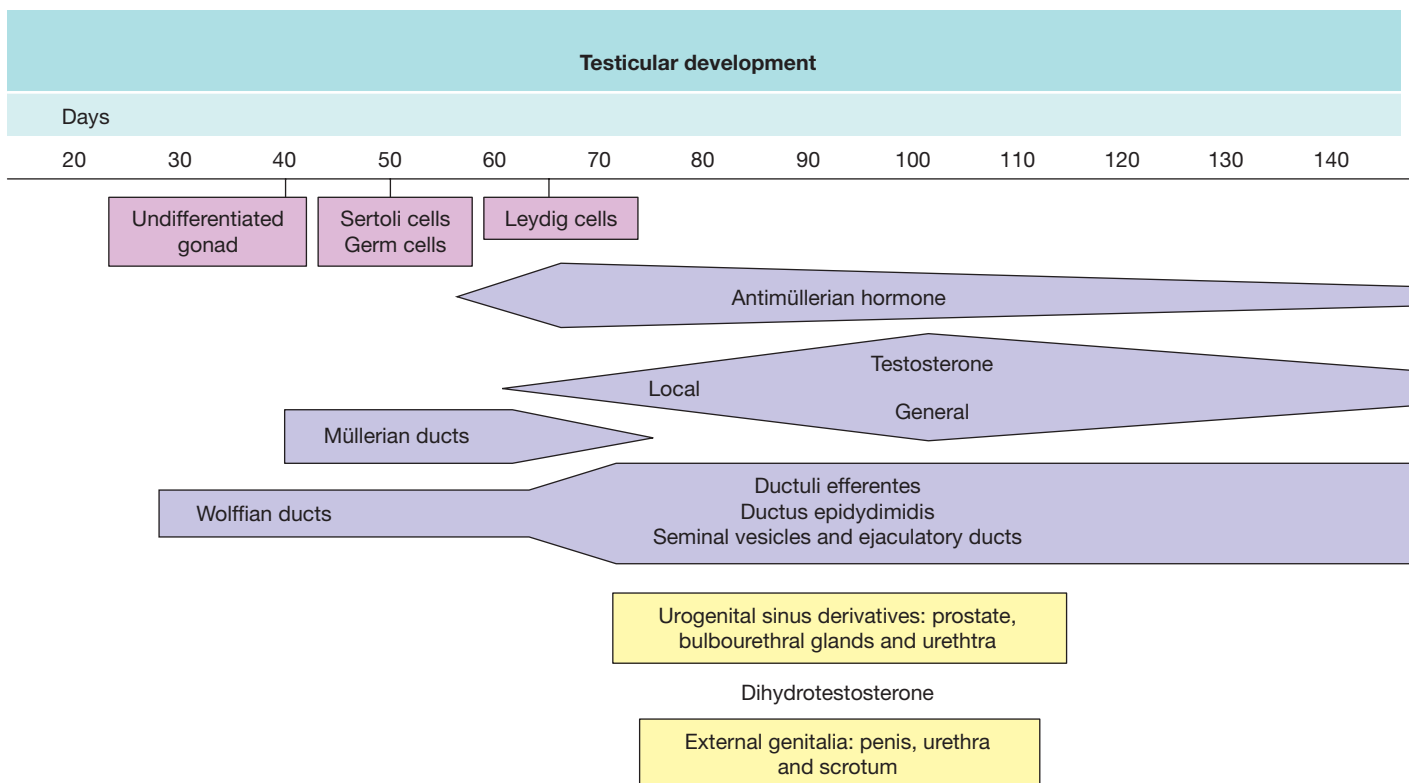


Fig. 12-5 Development of the genital system during the first months of intrauterine life.

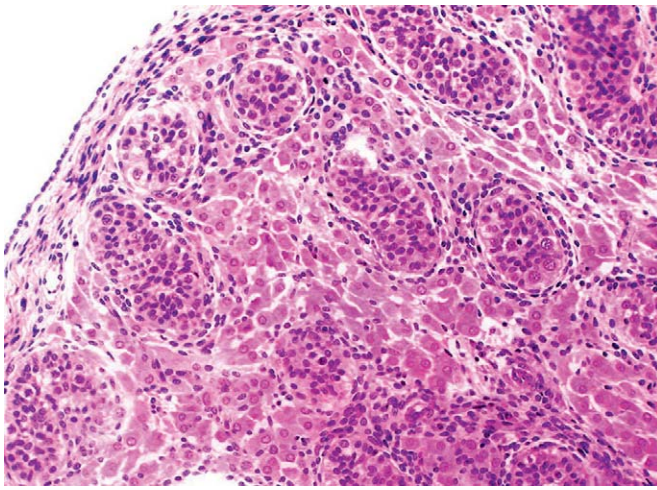


Fig. 12-6 A 16-week-old fetal testis showing slightly convoluted seminiferous tubules and numerous Leydig cells in the testicular interstitium.

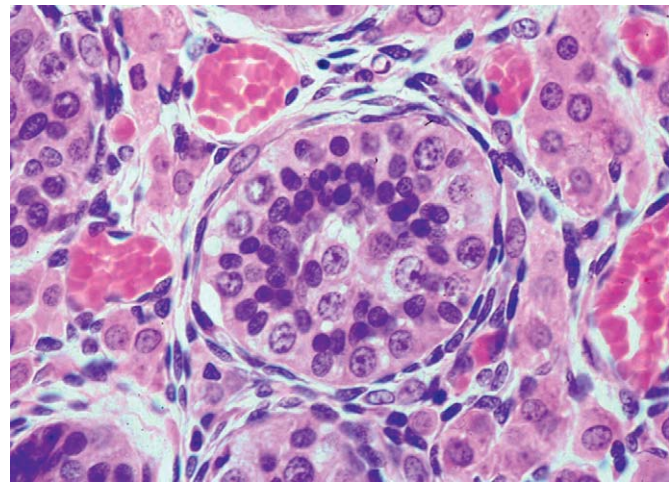


Fig. 12-7 Testis from a 24-week-old fetus. The seminiferous tubules contain Sertoli cells (small dark nuclei) and gonocytes (spherical cells with larger nuclei and central nucleoli). At this age, the interstitium still contains numerous Leydig cells.

immediately before AMH expression.⁴⁷ During puberty, AMH is negatively regulated by androgens.⁴⁸

AMH acts on the testis, genital tract, and extragenital structures. It causes involution of the ipsilateral müllerian duct. Action begins at the caudal testicular pole and progresses rapidly. In adults, remnants of the müllerian ducts include the appendix testis at the cranial end and the prostatic utricle (verumontanum) at the caudal end. AMH also stimulates development of the tunica albuginea, formed by insertion of mesenchyma between the celomic epithelium and primordial sex cords. This mesenchyma is also the origin of collagenized connective tissue, with deposition of collagen fibers in several layers that parallel the testicular surface.⁴⁹ AMH also hinders the entry of spermatogonia in meiosis.⁵⁰ The best-known function of AMH in the extragonadal system is the maturation of fetal lungs.⁵¹

Testosterone is synthesized by the Leydig cells. These first appear among the sex cords in the eighth week of gestation, and their number increases to 48 million per pair of testes by the 16th week,⁵² occupying about 50% of the testicular volume (Fig. 12-6). The relative number of Leydig cells decreases from the 16th to the 24th week, owing to rapid enlargement of the testis during this period. However, the absolute number of Leydig cells remains constant. From the 24th week to birth, the number of Leydig cells decreases to 18 million per pair of testes. Testosterone synthesis begins after the 56th day of gestation.

Testosterone secretion is regulated by hCG and LH concentrations. hCG peaks between weeks 11 and 17 and drops markedly thereafter; hCG-dependent testosterone is the most important determinant of genital differentiation. Wolffian duct differentiation occurs only as a response to the testosterone secreted by the ipsilateral testis. This secretion stimulates differentiation of the ductus epididymidis, ductus deferens, and seminal vesicle. Anomalies in androgen synthesis lead to incomplete masculinization and cryptorchidism.

Dihydrotestosterone (DHT) derives from testosterone by the action of the enzyme 5α -reductase and is responsible for differentiation of the prostate and the development of the external genitalia, male urethra, penis and scrotum. It induces fusion of the labioscrotal folds in the middle plane to form the scrotum and the middle scrotal raphe. The urethral folds become fused to form the penile urethra. The genital tubercle enlarges to form the glans penis. An ectodermal invagination of the glans tip forms the terminal portion of the urethra. The urogenital sinus gives rise to the urinary bladder, prostatic urethra, and prostate.⁵³ The initial effects of DHT (labioscrotal fusion) occur on approximately day 70; the urethral groove is closed on about day 74; and the external genitalia are completely developed by week 20.

The actions of these hormones occur at precise moments in development. Failure in the amount or timing of secretion or in the responsiveness of target tissues causes most of the malformations found in intersex conditions.⁵²

FSH and LH both play an important role in the last months of gestation. LH appears in the fetal circulation during the 10th week and peaks by the 18th, decreasing progressively and slowly thereafter until birth. LH chiefly regulates androgen production during the second half of fetal life. FSH is an essential mitogen for Sertoli cells that reach the highest mitotic ratio at the end of fetal life (Fig. 12-7).^{54,55}

Testicular descent

Testicular descent is the result of hormonal and mechanical actions that are not fully understood. Three steps are recognized: nephric displacement, transabdominal descent, and inguinal descent. In nephric displacement, the gonad detaches from the metanephros in the seventh week of gestation. Transabdominal descent occurs in the 12th week and consists of the displacement of the testis towards the deep inguinal ring. Inguinal descent occurs between the seventh month and birth.⁵⁶ Clinically, the term testicular descent often refers

only to this last step, in which the testis passes from the abdominal cavity to the scrotum.

Testicular descent is directed by the gubernaculum testis, a structure that appears in the sixth week as an elongate condensation of mesenchymal cells extending from the genital ridge to the presumptive inguinal region.^{57,58} At this level in the abdominal wall, the gubernaculum cells persist as a simple mesenchyma while the remaining abdominal wall cells differentiate into muscle. These mesenchymal cells give rise to the inguinal canal. Thus, the testis lies on a continuous column of mesenchyma limited by the cranial testicular ligament in the upper pole and by the plica gubernaculi that joins the testis to the future scrotal region in the inferior pole. The periphery of this mesenchymal tissue is invaded by the processus vaginalis, which develops from a peritoneal pouch that grows into this mesenchyma. Once the inguinal canal and the plica gubernaculi are formed, development slows. In the seventh month the processus vaginalis undergoes active growth, the cremasteric muscle develops from the mesenchyma outside the processus vaginalis, and the distal end of the gubernaculum enlarges markedly. Gubernacular enlargement occurs from the 16th to the 24th weeks of gestation period and is caused by hyperplasia, hypertrophy, and the absorption of a great volume of water by the glycosaminoglycans of the matrix.⁵⁹ The tissue is reminiscent of Wharton's jelly of the umbilical cord. By this time, the testis-epididymis complex is pear-shaped and its largest component is the gubernaculum. The testis and epididymis slide through the inguinal canal behind the gubernaculum. Simultaneously, development of the processus vaginalis is completed and the gubernaculum begins to shorten, the epididymis develops further, and the testicular blood vessels and vas deferens lengthen.⁶⁰

Testicular descent is a complex process integrating several essential factors, including normal function of the hypothalamopituitary-testicular axis, normal development of abdominal musculature, gubernaculum and the processus vaginalis,^{61,62} and a testis with normal endocrine function.

The critical role of normal hormonal function is supported by clinical and experimental observations: destruction of the hypophysis in laboratory animals impedes testicular descent; anencephalic fetuses usually have undescended testes; many cryptorchid patients have transitory neonatal hypogonadotropic hypogonadism; and some undescended testes descend after treatment with human chorionic gonadotropin or gonadotropin-releasing hormone. Adequate intra-abdominal pressure is another requisite.^{63,64} In the prune-belly syndrome, bilateral cryptorchidism is associated with urologic malformations and absence of the abdominal wall musculature. In a variant of this syndrome, termed pseudo-prune-belly syndrome, there is a positive correlation between the development of the abdominal wall musculature and testicular descent. Development of the processus vaginalis also plays a critical role in testicular descent. This structure grows within the gubernaculum; if it is partially replaced by fibrous tissue, the testis will follow other directions in its descent and end in an ectopic location. If fibrous tissue completely replaces the gubernaculum, the processus vaginalis and cremasteric muscle fail to

develop fully, and descent of the testis is mechanically blocked.⁶²

The hormonal requirements for testicular descent are not clear.⁶⁵ The most important factor in transabdominal descent is the androgen-independent peptide insulin-like factor 3 (INSF-3), a member of the relaxin-insulin family that is produced by fetal Leydig cells. This peptide stimulates gubernaculum cells to initiate gubernaculum swelling, a necessary step for the initiation of testicular descent.⁶⁶ Mutations in INSL-3 gene or its receptors LGRB-8 (leucine-rich repeat-containing G protein-coupled receptor 8) or GREAT (G protein-coupled receptor affecting testicular descent) interfere with transabdominal descent and cause cryptorchidism.^{67,68} AMH and androgens are also involved in the gubernaculum swelling reaction; androgens also facilitate regression of the cranial suspensory ligament.

Uncertainty exists regarding the mechanism of inguinoscrotal descent and its hormonal control. Androgens and the genitofemoral nerve are two factors strongly implicated in these processes. The role of androgens on the gubernaculum is very limited, because this structure has neither muscular cells⁶⁹ nor androgen receptors at the time of testicular descent. Androgenic effects are explained by the hypothesis of the genitofemoral nerve.⁷⁰ Androgens appear to act on the nucleus of the genitofemoral nerve in the spinal cord rather than directly on the gubernacula, producing masculinization of the neurons that form this nucleus⁷¹ (these neurons are much more numerous in males than in females) and secreting great amounts of calcitonin gene-related peptide (CGRP). In rats, CGRP causes rapid rhythmic contractions of the gubernaculum and it has been suggested that the gubernaculum might have embryonic cardiac muscle cells. However, it is also possible that CGRP acts on the cremasteric muscle that develops within the gubernaculum and is innervated by the genitofemoral nerve. This hypothesis is supported by the observation of neurogenic atrophy of this muscle in cryptorchid patients.⁷²

Other factors involved in testicular descent are estrogens and epidermal growth factor (EGF). During the first trimester of gestation, mothers of cryptorchid infants have free estradiol serum concentrations that are significantly higher than those of controls.⁷³ Experimental studies have shown that estradiol diminishes gubernacular swelling and stabilizes müllerian ducts. It has been proposed that estradiol inhibits the cell proliferation that causes gubernaculum swelling.^{74,75} EGF may facilitate testicular descent throughout the placental-gonadal axis. Maternal EGF levels increase just before fetal masculinization occurs.⁷⁶ The placenta has an elevated concentration of EGF receptors, and placental stimulation by EGF might stimulate hCG production, which may also stimulate fetal Leydig cells to produce androgens; hypothetically, these and/or other factors may determine testicular descent.

After birth, the gubernaculum and processus vaginalis regress. The gubernaculum is replaced by fibrous tissue that forms the scrotal ligament. The cephalic segment of the processus vaginalis atrophies after testicular descent. An exaggerated resorption of the processus vaginalis with pulling up of the testis may induce a testis that had descended normally to ascend, resulting in cryptorchidism.⁷⁷

Prepubertal testis

From birth to puberty the testis is a dynamic structure, an important consideration in interpreting biopsies from children. All testicular components undergo waves of proliferation and differentiation prior to puberty.⁷⁸ Three waves of germ cell proliferation occur: during the neonatal period, infancy, and puberty.⁷⁹ The last gives rise to complete spermatogenesis. There also are three waves of Leydig cell proliferation (fetal, neonatal, and pubertal); the last corresponds to the pubertal wave of germ cell proliferation.

Development of the testis from birth to puberty

The testis at birth

The newborn testis has a volume of about 0.57 mL⁸⁰ and is covered by a thin tunica albuginea from which the intratesticular septa arise. These divide the testis into lobules containing the seminiferous tubules and testicular interstitium (Fig. 12-8). The seminiferous tubules measure 60–65 μ m in diameter, with no apparent lumina, and are filled with Sertoli cells and germ cells. Sertoli cells are the most abundant, with 26–28 cells per tubular cross-section (Fig. 12-9).⁸¹ They form a pseudostratified cellular layer and have elongated to oval nuclei with darker chromatin than that of mature Sertoli cells, as well as one or two small peripheral nucleoli. The cytoplasm contains abundant rough endoplasmic reticulum, several Golgi complexes and numerous vimentin filaments, and expresses inhibin B (Fig. 12-10). No specialized intercellular junctions appear between Sertoli cells, but desmosome-like junctions are present between Sertoli cells and germ cells.⁸²

Two types of germ cell are present at birth: gonocytes and spermatogonia. Gonocytes are usually located near the center of the tubules, with voluminous nuclei and large central nucleoli.⁸² Gonocyte migration is probably facilitated by cell adhesion molecules such as P cadherin, which is expressed by Sertoli cells of immature testes.⁸³ Spermatogonia are mainly located on the basal lamina, and possess

smaller nuclei and less cytoplasm than gonocytes; the nucleoli are peripheral and very small. At birth, most spermatogonia correspond to the adult type A (see discussion on the adult testis below) (Fig. 12-11).

The testicular interstitium contains fetal Leydig cells that resemble adult Leydig cells but lack Reinke's crystalloids (Fig. 12-12).^{84,85} Additionally, mast cells, macrophages, and hematopoietic cell are present.⁸⁶

The first wave of testicular development occurs during the neonatal period and involves germ cells and Leydig cells. These changes are caused by a significant increase in secretion of both FSH and LH during the third postnatal month.^{87–89} Testicular weight and volume increase. LH stimulates the Leydig cells to produce testosterone,^{90,91} which stimulates the transformation of gonocytes to spermatogonia of the Ad type (Fig. 12-13). Afterwards, some of these

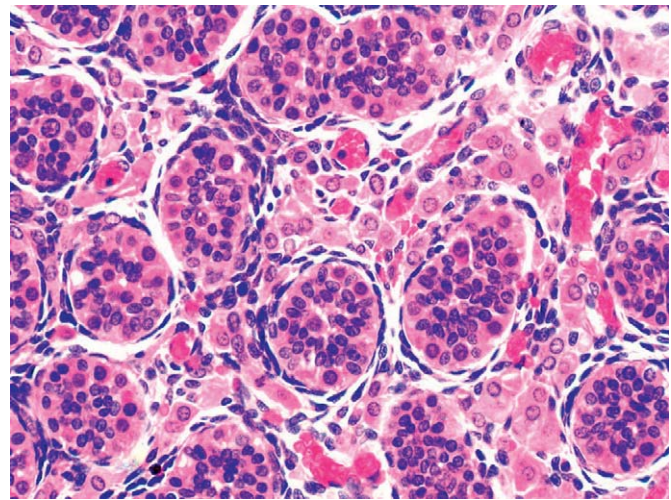


Fig. 12-9 The seminiferous tubules contain two germ cell types: gonocytes and spermatogonia. The gonocytes have large nuclei with large central nucleoli. The spermatogonia have smaller nuclei and pale cytoplasm. Several Leydig cells are seen in the interstitium.

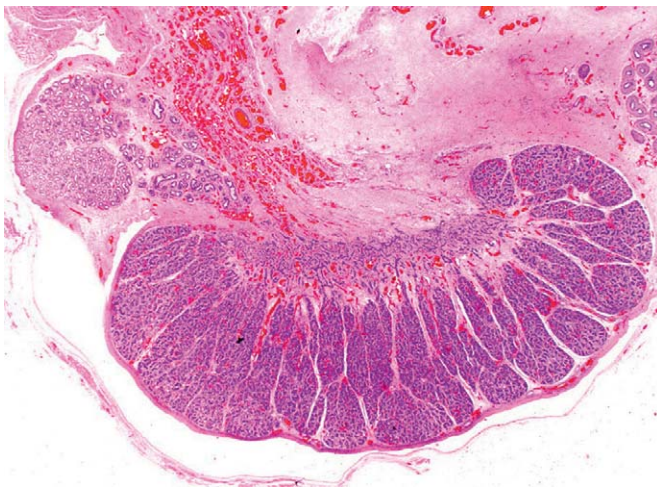


Fig. 12-8 Longitudinal section of the testis and the epididymis from a newborn. Intratesticular septa split the testis into lobules.

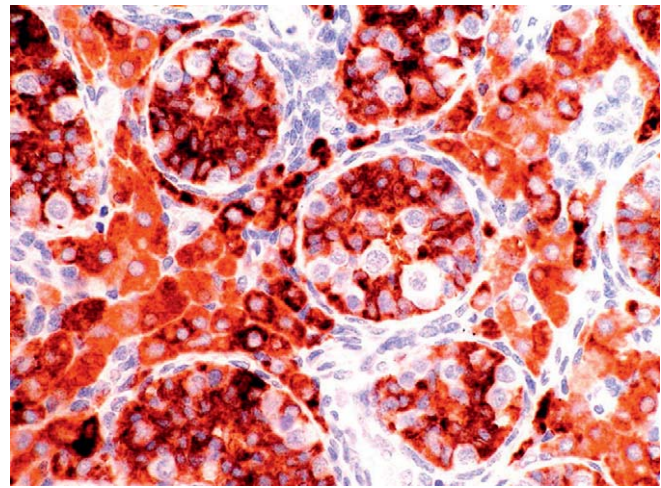


Fig. 12-10 Newborn testis. Both Sertoli cells and Leydig cells are intensely immunoreactive for inhibin.

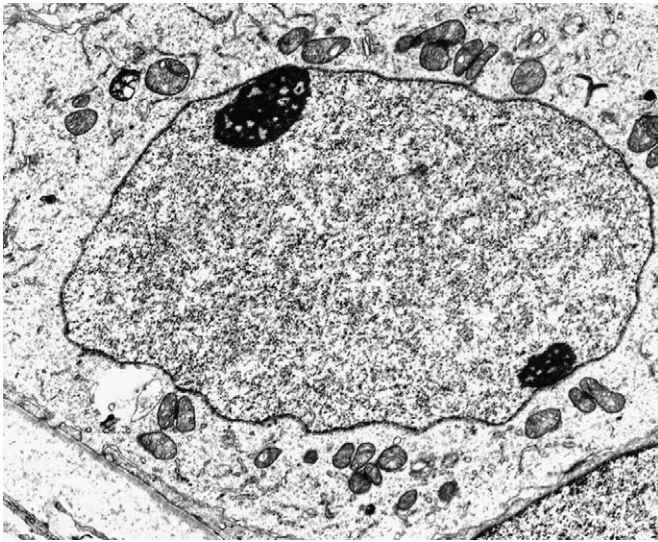


Fig. 12-11 Spermatogonia show wide cytoplasm and regularly outlined nuclei with eccentric nucleoli. The cytoplasm contains mitochondria joined by electron-dense bars.

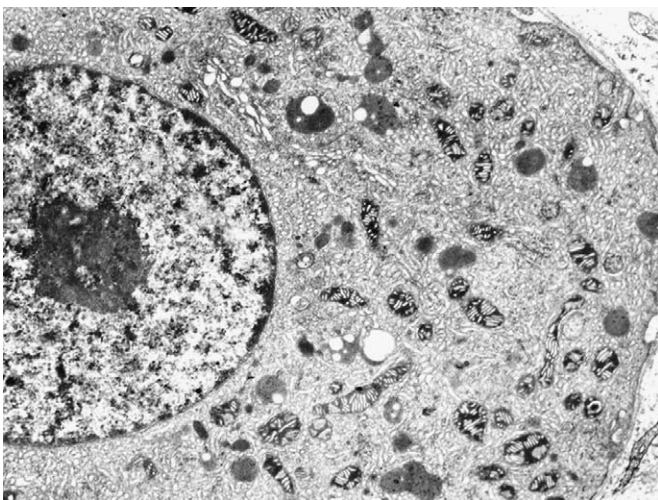


Fig. 12-12 Leydig cells have eccentric, round nuclei, abundant smooth endoplasmic reticulum and mitochondria, lysosomes, and stacks of rough endoplasmic reticulum cisternae.

divide to form Ap spermatogonia (see discussion on the adult testis below). Six months after birth, gonocytes are absent, coinciding with the loss of fetal germ cell markers (placental alkaline phosphatase and *c-kit*).

Paraganglia are often observed in epididymides and spermatic cords from newborns. This is not surprising, as paraganglia are the main source of catecholamine before birth (Fig. 12-14).⁹²

The testis in infancy

From the sixth month to approximately the second half of the third year of life, the testis is in a resting period; this quiescence is broken by the second wave of germ cell proliferation.⁹³ The number of Ap spermatogonia increases, and B spermatogonia (derived from Ap spermatogonia) appear.

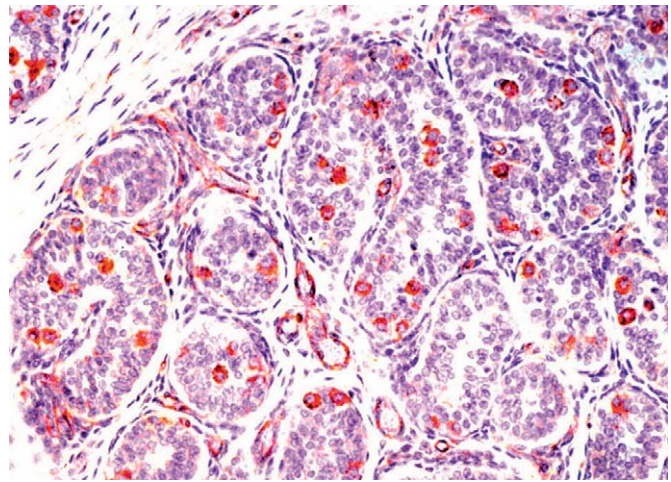


Fig. 12-13 Testis from a 4-day-old infant. Gonocytes are strongly immunoreactive for *c-kit*.

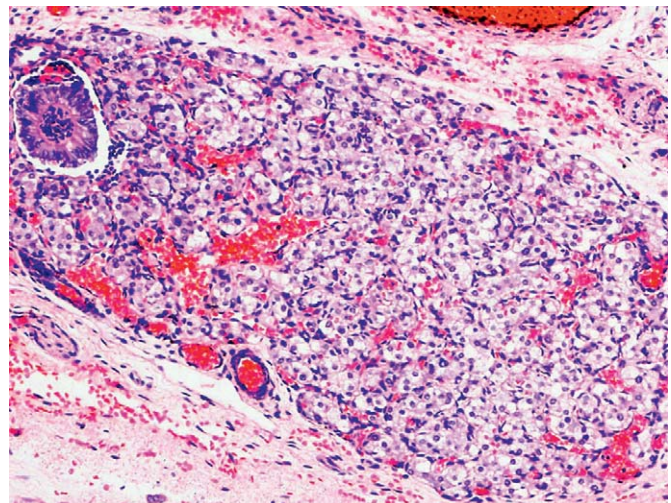


Fig. 12-14 Newborn epididymis showing a paraganglion around the epididymal duct.

In some normal testes at this age, meiotic primary spermatocytes and round spermatids are observed (Fig. 12-15). This spermatogenic attempt fails and many degenerate germ cells may be present.^{94,95} The testis continues to produce AMH (by Sertoli cells)⁹⁶ and inhibin B.⁹⁷ AMH modulates the number and function of Leydig cells by regulating differentiation of their mesenchymal precursors and the expression of steroidogenic enzymes.⁹⁸ Inhibin B plays a role in FSH inactivation during infancy.

The cause of this second wave of germ cell proliferation is unknown; there is no elevation of FSH or LH serum concentrations between 6 months and 10 years of life. After the sixth year, there is a slight increase in adrenal androgens, but testicular testosterone levels increase only after the 10th year.^{99,100} By the third year, most Leydig cells have degenerated: from a peak of about 18 million at birth, only 60 000 remain by the age of 6 years. At this age, testosterone levels

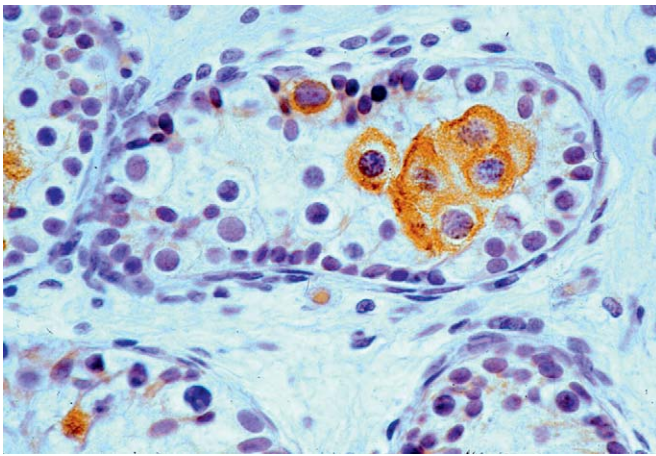


Fig. 12-15 Testis from a 4-year-old infant. The seminiferous tubules have spermatogonial proliferation and contain a central group of primary spermatocytes.

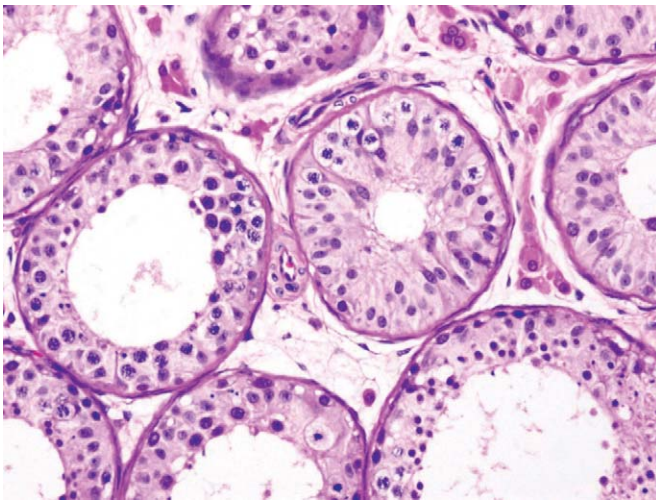


Fig. 12-16 Testis from an 11-year-old boy. Germ cell development varies from one tubule to another. The number of spermatogonia is lower than that of the adult testes. Residual immature Sertoli cells show elongated nuclei with small nucleoli. Leydig cells are scant.

are similar to those of girls,⁹⁹ and most androgens are of adrenal origin.

The testis in childhood

At about 9 years of age, the third and definitive wave of spermatogenesis begins,¹⁰¹ coinciding with a significant elevation of LH. This is followed by additional increases in the level of this hormone between 13 and 15 years of age. LH induces fibroblast-like Leydig cell precursors to differentiate into mature Leydig cells.¹⁰² By the end of puberty, the population of Leydig cells per testis has risen to about 786 million.¹⁰³ Leydig cells secrete androgens, which, together with the rise in FSH between 11 and 14 years of age, cause Sertoli cell maturation, germ cell development, and the appearance of tubular lumina (Fig. 12-16),¹⁰³ increasing the size of the testes between the ages of 11.5 and 12.5 years of life.¹⁰⁴ At 13.5 years, before the testis reaches adult size,

spermatozoa are present, secondary sex characteristics are completely developed, and the epiphyses close.¹⁰⁵

Interpretation of testicular biopsy from prepubertal testes

Testicular biopsy in children is useful for diagnosing those with ambiguous genitalia, a history of leukemia or lymphoma whose testes underwent a rapid enlargement, or precocious testicular maturation of unknown cause. In other situations, the value of testicular biopsy is less established. For example, the value of biopsy of cryptorchid testes during orchidopexy is controversial. Evaluation of biopsies of the prepubertal testis should involve the assessment of several features, including tunica albuginea thickness, mean tubular diameter, and the number of germ cells, Sertoli cells, and Leydig cells.

Tunica albuginea

The most frequent anomalies of the tunica albuginea include thin, poorly collagenized tunica albuginea with abnormal tubules typical of testicular dysgenesis (see the section on male pseudohermaphrodites with müllerian remnants, below); well-collagenized tunica albuginea containing ectopic seminiferous tubules, a frequent finding in cryptorchidism; and poorly collagenized tunica albuginea containing ovocytes characteristic of true hermaphroditic ovotestes.

Mean tubular diameter

The mean tubular diameter is an excellent indicator of the development of the seminiferous epithelium. In the prepubertal testis, tubular diameter depends principally on the Sertoli cells and thus indicates whether they are adequately stimulated by FSH. Tubular diameter varies throughout, being smallest in the end of the third year of life, slowly enlarging up to 9 years of age, and rapidly enlarging thereafter up to 15 years (Fig. 12-17).

The most frequent abnormality in the prepubertal testis is a low mean tubular diameter. This is seen in undescended testes as well as in hypogonadotropic or hypergonadotropic hypogonadism. In the latter, the lesion results from anomalous Sertoli cell responsiveness to FSH.¹⁰⁶

There are three levels of severity of low tubular diameter: slight tubular hypoplasia (up to 10% reduction in relation to the diameter normal for the age); marked tubular hypoplasia (from 10% to 30% reduction); and severe tubular hypoplasia (more than 30% reduction). Many testicular biopsies show malformed seminiferous tubules that vary from straight or branched tubules up to ring-shaped. These are megatubules formed by either tight spiral or bell-shaped tubules. The presence of these malformations suggests the child will be infertile in adulthood.

Diffuse increase in mean tubular diameter may be unilateral or bilateral. Unilateral increase is found in monorchidism (compensatory testicular hypertrophy) and some testes that are contralateral to cryptorchid testes. Most frequently, diffuse enlargement occurs with benign idiopathic macroorchidism or macroorchidism associated with fragile X chromosome, familial testotoxicosis, hypothyroidism, or different forms of precocious puberty. Focal increases in mean tubular

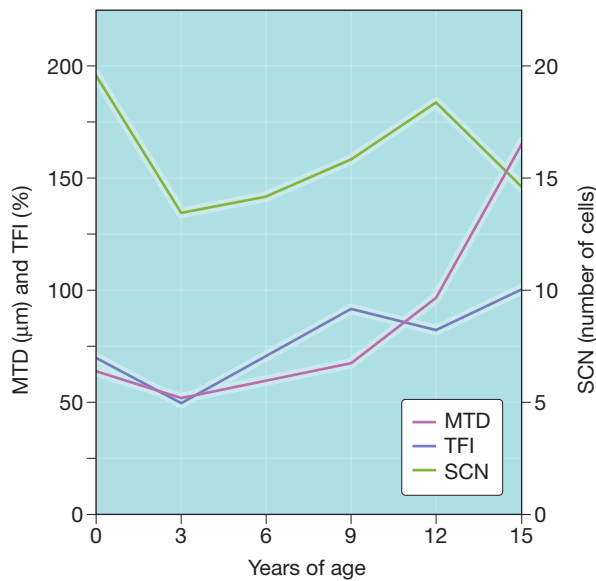


Fig. 12-17 Changes in mean tubular diameter (MTD), tubular fertility index (TFI), and Sertoli cell number per cross-sectioned tubule (SCN) from birth to puberty.

diameter are usually associated with precocious maturation of the seminiferous epithelium layers, and occur at the periphery of some Sertoli cell and Leydig cell tumors.

Germ cell number

Germ cells can be counted in two ways: calculation of the number of cells per tubular cross-section, or determination of the tubular fertility index. The former counts the number of germ cells in a light microscopic field and divides this by the number of cross-sectioned tubules in the same field. In the first 6 months of postnatal life the normal testis has two germ cells per cross-sectioned tubule. This number drops to 1.5 at the end of the first year and to 0.5 at the end of the third year. The number of germ cells increases to 1.8 cells at the age of 3–4 years, which coincides with the appearance of spermatocytes in some tubules.

The tubular fertility index reflects the percentage of tubular sections containing germ cells. In newborns, 68% of tubular sections contain at least one germ cell. From birth to 3 years this decreases to 50%, followed by a progressive increase to 100% at puberty.⁹³ If the numbers of gonocytes and spermatogonia are calculated separately, it is possible to determine when the transformation of gonocytes to spermatogonia occurs. The most accurate measure is calculation of total germ cell numbers per testis. This is more difficult because it requires morphometric assessment of intratubular volume and careful clinical measurement of the three axes of the testis.

Congenital decrease of germ cells occurs in numerous conditions, including trisomies 13, 18, and 21, some forms of primary hypogonadism such as Klinefelter's syndrome, anencephaly, many cryptorchid testes, and in patients with posterior urethral valves and severe obstruction of the urinary ducts.¹⁰⁷ An increased number of germ cells may be seen at the periphery of germ cell tumor, gonadal–stromal tumor,

and paratesticular sarcoma. At the periphery of Leydig cell tumor, seminiferous tubular cellular maturation may be complete.

Three levels of severity of germinal hypoplasia are recognized: slight (tubular fertility index >50), marked (tubular fertility index between 50 and 30), and severe (tubular fertility index <30) (Fig. 12-17). Marked and severe germinal hypoplasia is usually associated with marked or severe tubular hypoplasia, in most cases resulting from tubular dysgenesis. It also is useful to determine whether the seminiferous tubules devoid of germ cells are randomly distributed. If they are grouped, they probably belong to the same lobule or group of lobules that never will develop normally.

Other germ cells observed are multinucleate or hypertrophied spermatogonia and gonocyte-like cells; these latter may require immunohistochemical studies to exclude intratubular germ cell neoplasia.

Sertoli cell number

The number of Sertoli cells per tubular cross-section varies during childhood as a result of slow proliferation from 4 years to 12 years¹⁰⁸ and the redistribution of Sertoli cells as the seminiferous tubules become longer and broader. The pseudostratified cellular pattern characteristic of Sertoli cells at birth changes slowly to a columnar pattern at puberty (Fig. 12-17). Testicular biopsies may reveal hypoplasia or hyperplasia of Sertoli cells; hyperplasia is usually pronounced and a sign of tubular dysgenesis, often detected during the first year of life or the beginning of puberty.¹⁰⁹ Some biopsies reveal one or several tubular sections containing Sertoli cells with eosinophilic and granular cytoplasm that is positive to CD68 and α_1 -antitrypsin. These oncocytic changes are the result of lysosomal accumulation.¹¹⁰

Leydig cell number

Calculation of Leydig cell numbers during childhood is difficult because at this age the population is scant.¹⁰² Semi-thin sections or immunohistochemistry to detect testosterone-containing cells may be helpful.¹¹¹ Selection of the appropriate denominator to express the Leydig cell population is another problem. The most frequent measures are Leydig cell number per tubular section, per unit area, or total number per testis.¹⁰⁴

Low numbers of Leydig cell are observed in undescended testes, hypogonadotropic hypogonadism, some variants of male pseudohermaphroditism caused by a defect in the LH receptor, and in anencephalic fetuses. High numbers of Leydig cells occur in congenital Leydig cell hyperplasia,¹¹² triploid fetuses,¹¹³ variants of precocious puberty, several syndromes such as leprechaunism and Beckwith–Wiederman syndrome, and in most male pseudohermaphroditisms.

Intertubular connective tissue

An apparent increase in loose connective tissue is found in patients with marked tubular hypoplasia; in addition, disordered thick fusiform cell bundles are seen in patients with androgen insensitivity. Other alterations include the presence of excessively developed lymphatic vessels (lymphangiectasis), focal hematopoiesis, leukemic infiltration, and the presence of cells similar to those of the adrenal cortex (tumors of the adrenogenital syndrome).

Adult testis

Anatomy

The adult testis is an egg-shaped organ that hangs in the scrotum from the spermatic cord, the retroepididymal surface, and the scrotal ligament. Mean weight in Caucasian men is 21.6 ± 0.4 g for the right testis and 20 ± 0.4 g for the left. Mean testicular diameter is 4.6 cm (range, 3.6–5.5 cm) for the longest axis and 2.6 cm (range, 2.1–3.2 cm) for the shortest.^{114–117} Testicular volume varies from 15 to 25 mL.

Supporting structures

The tunica albuginea and interlobular septa make up the connective tissue framework of the testis. The tunica albuginea consists of three connective tissue layers and an outer surface covered by mesothelium. From the outer to the inner layers, the amount of collagen fibers decreases while the number of cells increases. The fibers and cells in the two outermost layers form planes parallel to the testicular surface; cell types include fibroblasts, myofibroblasts, and mast cells. Myofibroblasts are more numerous in the posterior portion of the testis. The thickness of the tunica albuginea increases with age from 400–450 μm in young men to more than 900 μm in elderly men.¹¹⁸ It acts as a semipermeable membrane that produces the fluid of the vaginal cavity. The presence of many contractile cells showing high concentrations of GMP suggests that the tunica albuginea undergoes impulses of contraction and relaxation. These cells might regulate testicular size¹¹⁹ and favor the transport of spermatozoa into the epididymis.¹²⁰

The innermost layer, the tunica vasculosa, consists of loose connective tissue containing blood and lymphatic vessels. The interlobular septa consist of fibrous connective tissue with blood vessels supplying the testicular parenchyma. The interlobular septa divide the testis into approximately 250 pyramidal lobules with their bases at the tunica albuginea and vertices at the mediastinum testis. Each lobule contains two to four seminiferous tubules and numerous Leydig cells.¹²¹

Seminiferous tubules

Adult seminiferous tubules are 180–200 μm in diameter and 30–80 cm long. The total combined length of the seminiferous tubules is about 540 m (range, 299–981 m).¹²² They are highly convoluted and tightly packed within the lobules. The seminiferous tubules comprise about 80% of testicular volume. The tubular lining of germ cells and Sertoli cells is surrounded by a lamina propria (tunica propria) (Fig. 12-18).

Sertoli cells

Sertoli cells are columnar cells that extend from the basal lamina to the tubular lumen, with 10–12 cells per cross-sectioned tubule. They are easily identified by their nuclear characteristics. The nucleus is located near the basal lamina and has a triangular shape with indented outline, pale chromatin, and a large central nucleolus (Fig. 12-19). Charcot-Böttcher's crystals and lipid droplets often are visible in the cytoplasm.^{123–126}

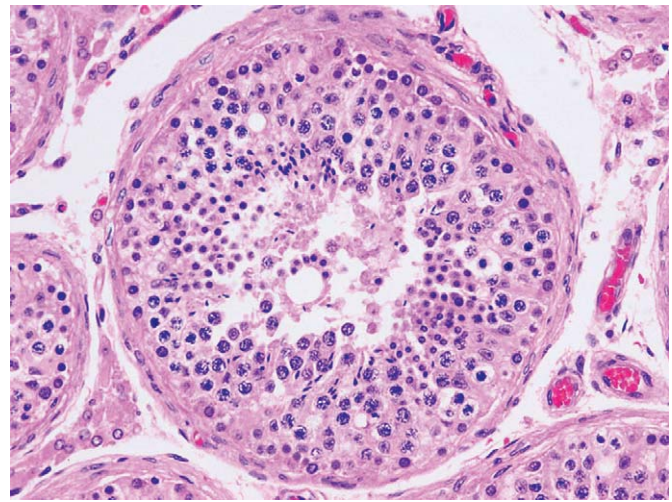


Fig. 12-18 Seminiferous tubule with complete spermatogenesis.

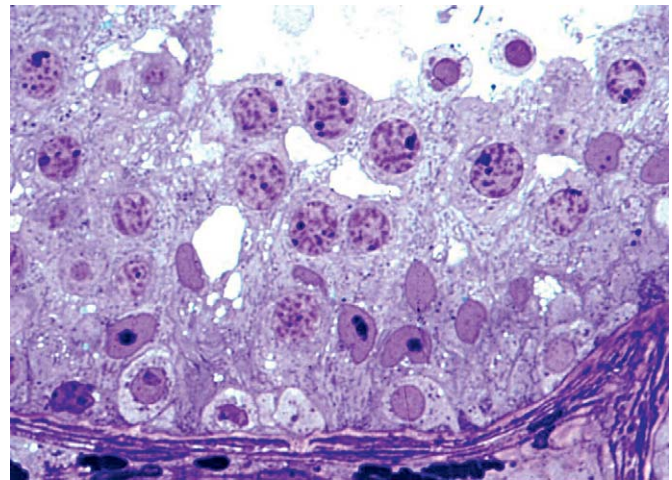


Fig. 12-19 Germ cell development progresses from the basal lamina towards the lumen of the tubule. Each germ cell type forms a different layer in the seminiferous tubules and may be identified by its nuclei. Spermatogonia are basal cells with pale cytoplasm, round nuclei, and eccentric nucleoli. Above these cells, the Sertoli cell nuclei may be recognized by their large central nucleoli. The inner layers consist of primary spermatocytes showing the chromatin pattern characteristic of meiosis. (Semi-thin section.)

Ultrastructurally, Sertoli cells have characteristic nucleoli, plasma membranes, and cytoplasmic components. The nucleolus has a tripartite structure with a round fibrillar center, a compact granular portion, and a three-dimensional net composed of intermingled fibrillar and granular portions.^{127–129} The plasma membrane has two types of intercellular junction which develop at puberty: junctions between adjacent Sertoli cells, and junctions between Sertoli cells and germ cells.¹³⁰ The inter-Sertoli cell junctions are tight-junction complexes. The adjacent cytoplasm has numerous actin filaments and parallel-arranged smooth endoplasmic reticulum cisternae. In adjacent plasma membranes there are adhesion molecules, including connexin-43. Between the

plasma membrane and the adjacent endoplasmic reticulum cisterna there are many molecules, including those required for actin filament anchorage, vinculin, zonula occludens-1, plakoglobin, and radixin. The inter-Sertoli cell junctions are the morphologic basis for the blood–testis barrier and divide the seminiferous epithelium into two compartments: the basal compartment (which contains spermatogonia and newly formed primary spermatocytes) and the adluminal compartment (which contains meiotic primary spermatocytes, secondary spermatocytes and spermatids). These junctions permit each compartment to have its own micro-environment for spermatogenic development.^{131–133} The Sertoli cell–germ cell junctions persist from the primary spermatocyte stage through spermatozoon release. These junctions are desmosomes and gap-type junctions. The adhesion among Sertoli cells and germ cells is mediated by *N*-cadherin. These junctions have also occasionally been observed between spermatogonia.¹³⁴

Sertoli cell cytoplasm contains abundant smooth endoplasmic reticulum, elongated mitochondria, annulate lamellae, lysosomes, residual bodies, glycogen granules,

microtubules, vimentin filaments around the nucleus (Fig. 12-20),¹³⁵ actin filaments in both inter-Sertoli cell junctions and ectoplasmic specializations that surround germ cells,¹³⁶ lipid droplets in amounts that vary with the seminiferous tubular cycle,¹³⁷ Charcot–Böttcher crystals (structures several micrometers long, formed of multiple parallel laminae of protein), and scant rough endoplasmic reticulum and ribosomes.¹³⁸

The number of Sertoli cells decreases with age, from about 250 million per testis in young men to 125 million in men over 50 years.^{139,140} There is a positive correlation between the number of Sertoli cells and daily sperm production.¹⁴¹ Sertoli cells are the target of FSH^{142,143} and androgen action (Fig. 12-21).¹⁴⁴ In adulthood, they produce testicular fluid through an active transport mechanism, and synthesize multiple products to ensure the nutrition, proliferation and maturation of germ cells, to stimulate other cells such as Leydig cells and peritubular cells,¹⁴⁵ and to contribute to hormonal regulation (inhibin secretion) (Table 12-1). The transport of small molecules (<600–700 Da) such as pyruvate, lactate, and probably choline from the Sertoli cell, to germ cells occurs through gap junctions. Large or small soluble molecules are transported by proteins that are synthesized by the Sertoli cell, and include androgen-binding protein, transferrin, ceruloplas-

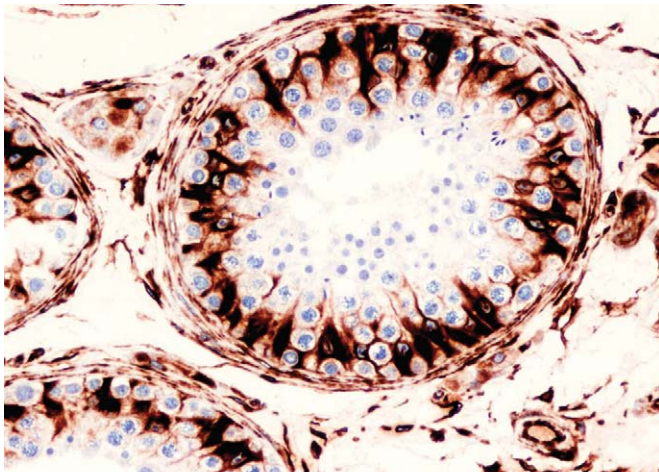


Fig. 12-20 Cross-section of seminiferous tubule showing Sertoli cells that are intensely immunoreactive for vimentin.

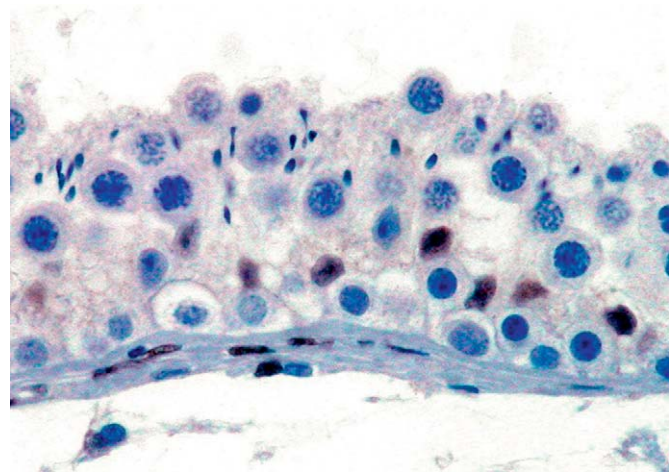


Fig. 12-21 Sertoli cell nuclei immunostained for androgen receptors.

Table 12-1 Sertoli cell–Leydig cell regulatory interactions

Paracrine factor	Origin	Receptor	Action
Androgens	Leydig cell	Sertoli cell	Regulate/maintain function and differentiation
Pro-opiomelanocortin peptides	Leydig cell	Sertoli cell	Decrease FSH actions
β -endorphin	Leydig cell	Sertoli cell	Decrease steroidogenesis
GnRH-like factor	Sertoli cell	Leydig cell	Decrease steroidogenesis
Estrogens	Sertoli cell	Leydig cell	Decrease steroidogenesis
TGF- α	Sertoli cell	Leydig cell	Decrease steroidogenesis
IL-1	Sertoli cell	Leydig cell	Decrease steroidogenesis
IGF-1	Sertoli cell	Leydig cell	Increase steroidogenesis

min, sulfated glycoproteins, α_2 -macroglobulin, and γ -glutamyl transpeptidase.¹⁴⁶ Activin and inhibin are Sertoli cell-secreted proteins that induce the proliferation and differentiation of germ cells. Whereas activin stimulates FSH production and, subsequently, spermatogonial proliferation, inhibin B inhibits FSH secretion, and is an important marker of spermatogenesis.¹⁴⁷ Other Sertoli cell secretions are interleukins, mainly IL-1,¹⁴⁸ and growth factors such as transforming growth factor- β (TGF- β), insulin growth factors 1 and 2 (IGF-1 and IGF-2), and seminiferous growth factor (SGF) or stem cell factor (SCF). Some of these growth factors, such as TGF- α , TGF- β , and IGF-1, are involved in the regulation of Leydig cell function. Other secreted substances include clusterin, the steroid 3- α -4-pregnen-20-one (3HP), and prostaglandin D synthase (Table 12-2).

Sertoli cells are also involved in migration of differentiating germ cells towards the tubular lumen. This movement leads to a continuous remodeling of the plasma membrane and requires synthesis of several proteases, including urokinase, tissue-type plasminogen activator, cyclic protein 2, collagenase IV, other metalloproteins, and several antiproteases, such as cystatin C, tissue inhibitor of metalloproteinase type 2, and α_2 -macroglobulin.¹⁴⁹ The Sertoli cell also regulates germ cell apoptosis by the production of Fas-ligand, which binds to the Fas-ligand receptor (APO-1, CD95) in germ cell plasma membranes. In addition, Sertoli cells possess receptors for several factors such as the nerve growth factor (NGF) produced by spermatocytes and young spermatids, emphasizing the complexity of the Sertoli cell-germ cell relationship. Sertoli cells also produce some steroid hormones (estradiol and testosterone) and several components of the seminiferous tubule wall, including laminin, type IV collagen, and heparin sulfate-rich proteoglycans.

Germ cells

The germ cells of the adult testis include spermatogonia, primary and secondary spermatocytes, and spermatids (Fig. 12-18).

Spermatogonia There are two types of spermatogonia: A and B. Type A are about 12 μ m in diameter, rest on the basal lamina, and are surrounded by the cytoplasm of the adjacent Sertoli cells. The nuclei of type A spermatogonia are spherical, contain several peripheral nucleoli, and have four different patterns: Ad (dark), Ap (pale), Al (long), and Ac (cloudy).^{150,151} The cytoplasm of these spermatogonia contains a moderate number of ribosomes, small ovoid mitochondria joined by electron-dense bars, and Lubarsch's crystals. These are several micrometers long and are composed of numerous 8–15 nm parallel filaments intermingled with ribosome-like granules.

Ad spermatogonia are thought to be stem cells in spermatogenesis. Some of them replicate DNA and, during replication, acquire the Al pattern. Afterwards, they divide to make another Ad (maintaining the stem cell reservoir) and an Ap spermatogonium. During replication, Ap spermatogonia become Ac and then divide to form two type B spermatogonia.^{152–154}

Type B spermatogonia are the most numerous, and their contact with the basal lamina is less extensive than that of

Table 12-2 Major Sertoli cell secretory products

Products	Functions and/or characteristics
Transport-Binding Proteins	
Androgen-binding protein (ABP)	Androgen transport
Transferrin	Iron transport
Ceruloplasmin	Copper transport
Sulfated glycoprotein-1	Sphingolipid binding
Regulatory Proteins	
Inhibin	Endocrine-paracrine agent
Müllerian duct inhibitory agent	Development
Sulfated glycoprotein-2	Sperm coating-immunosuppressant
Growth Factors	
TGF- α	Growth stimulation
TGF- β	Growth inhibition
IGF-1	Maintain growth/differentiation
IL-1	Growth regulation
Metabolites	
Lactate-pyruvate	Energy metabolites
Estrogens	Steroid hormone–endocrine–paracrine
Proteases/inhibitors	
Plasminogen activator	Plasminogen activation
Cyclic protein-2	Cathepsin activity
α_2 -Macroglobulin	Protease inhibitor
Extracellular Matrix Components	
Laminin	
Collagens I and IV	
Proteoglycans	
TGF, transforming growth factor; IGF-1, insulin-like growth factor; IL-1, interleukin.	

type A. The nuclei usually are more distant from the basal lamina than those of type A spermatogonia and contain one or two large central nucleoli. The cytoplasm contains more ribosomes than type A spermatogonia and intermitochondrial bars are usually not observed. Type B spermatogonia divide to form primary spermatocytes.

Primary spermatocytes Interphase primary spermatocytes lose contact with the basal lamina and inhabit cavities formed by the Sertoli cell cytoplasm. Their cytoplasm contains more rough endoplasmic reticulum than that of spermatogonia, and the Golgi complex is more developed.¹⁵⁵ Meiotic primary spermatocytes are readily identified by their chromatin pattern. The leptotene spermatocyte, with filamentous chromatin, leaves the basal compartment, migrates to an intermediate compartment and then to the adluminal compartment. In the zygotene spermatocyte, chromosomes are shorter and pairing of homologous chromosomes begins.

Ultrastructural studies show coarse chromatin masses in which synaptonemal complexes and sex pairs may be present. The nucleolus acquires a peculiar appearance, with segregation of the fibrillar and granular portions. Associated with the nucleolus is the round body that contains proteins but no nucleic acids.¹²⁸ In the pachytene spermatocyte, homologous chromosomes are completely paired, and on electron microscopy the chromatin masses appear larger and less numerous than in the zygotene spermatocyte. In the diplotene spermatocyte, paired homologous chromosomes begin to separate and remain joined by the points of interchange (chiasmata); neither synaptonemal complexes nor sex pairs are observed. The diakinesis spermatocyte shows maximal chromosome shortening and the chiasmata begin to resolve by displacement towards the chromosomal ends. The nuclear envelope and the nucleolus disintegrate. The spermatocyte completes the other phases of the first meiotic division (metaphase, anaphase and telophase), forming two secondary spermatocytes; the first meiotic division lasts 24 days.¹⁵⁶

Secondary spermatocytes are haploid cells, smaller than primary spermatocytes, and show coarse chromatin granules and abundant rough endoplasmic reticulum cisternae.¹⁵⁷ These cells rapidly undergo the second meiotic division and within 8 hours give rise to two spermatids. The newly formed spermatids differ from secondary spermatocytes, having smaller nuclei with homogeneously distributed chromatin. **Spermiogenesis** The transformation of spermatids into spermatozoa is called spermiogenesis. During this process pronounced changes occur in the nucleus and cytoplasm.¹⁵⁸ The nucleus becomes progressively darker and elongated.¹⁵⁹ The cytoplasm develops the acrosome and flagellum,¹⁶⁰ the mitochondria cluster around the first portion of the spermatozoon tail, and the remaining cytoplasm is phagocytosed by Sertoli cells.^{161,162} By electron microscopy, there are four tran-

sient stages of spermatid development: Golgi, cap, acrosome, and maturation. These correspond to those defined by light microscopy of nuclear morphology: Sa, Sb, Sb₁, Sb₂, Sc, Sd₁ and Sd₂.^{163,164} These phases may be grouped as early (or round) spermatids that comprise the stages with round nuclei (Sa and Sb), and as late (or elongated) spermatids that comprise the stages with elongated nuclei (Sc and Sd). Mature spermatids (Sd₂) are the spermatozoa that are released into the tubular lumen (spermiation). All the germ cells derived from the same stem cell remain interconnected by cytoplasmic bridges that ensure synchronous maturation during the spermatogenic process.¹⁶⁵

Cycle of the seminiferous epithelium At first glance, the arrangement of the germ cells in the seminiferous tubules appears disorderly. However, closer study reveals that these cells are grouped into six successive associations, designated I–VI. In contrast to other mammals, in humans the volume occupied by each association is small, so that several associations may be observed in the same tubular cross-section. Stereological studies have shown that the successive associations are organized helically along the length of the seminiferous tubule.^{126,165–167} Each association persists for a specific number of days (I, 4.8 days; II, 3.1 days; III, 1 day; IV, 1.2 days; V, 5 days; and VI, 0.8 days), and each successively transforms into the following one. Finally, at the end of association VI, the cycle is repeated; the spermatogenic process requires 4.6 cycles.¹⁶⁸ Because each cycle lasts 15.9 days, the transformation of spermatogonium into spermatozoon takes 74 days (Fig. 12-22).

The succession of different associations probably depends on cyclic Sertoli cell activity. Cyclic changes in the mitochondria, rough endoplasmic reticulum, Golgi complex, lysosomes, and lipid droplets have been reported.^{169–171} This cyclic activity is probably regulated by germ cell signals.¹⁷² The yield of human spermatogenesis is lower than that of

Fig. 12-22 The six different germ cell associations of the seminiferous tubules and the sequence of spermatogenesis. Completion of spermatogenesis requires more than four cycles and lasts for approximately 74 days. Each association is indicated by Roman numerals with its corresponding duration. Ad: dark type of A spermatogonia; Ap: pale type of a spermatogonia; B: B spermatogonia; I: interphase primary spermatocyte; L: leptotene primary spermatocyte; Z: zygotene primary spermatocyte; P: pachytene primary spermatocyte; II: secondary spermatocyte (only in stage VI). S_a, S_{b1}, S_{b2}, S_c, S_{d1}, and S_{d2} represent the progressive stages of spermatid differentiation into spermatozoa.

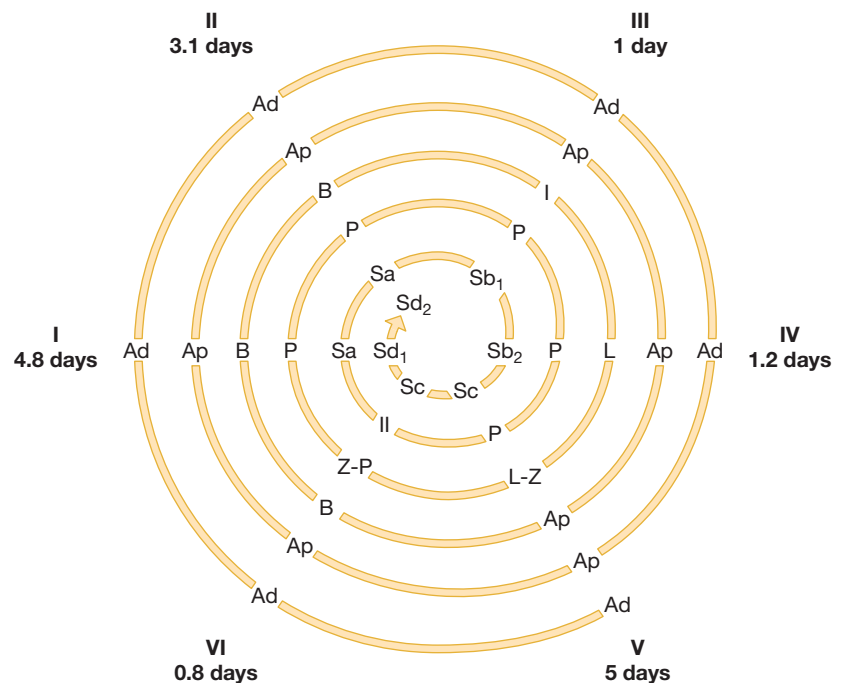


Table 12-3 Major peritubular cell secretory products

Products	Functions
P-mod-S	Paracrine regulatory agent
Plasminogen activator inhibitor	Inhibition of plasminogen activator activity
Fibronectin	Extracellular matrix component
Collagen I	Extracellular matrix component
Proteoglycans	Extracellular matrix component
TGF- α	Growth stimulation/EGF-like
TGF- β	Growth inhibition
IGF-1	Maintenance growth/differentiation

TGF, transforming growth factor; IGF-1, insulin-like growth factor.

most mammalian species, including primates, with maximal cell degeneration occurring at the end of meiosis.¹⁷³

Tunica propria

The seminiferous tubule is surrounded by a 6 μm thick lamina propria (tunica propria) consisting of a basement membrane, myofibroblasts, fibroblasts, collagen and elastic fibers, and extracellular matrix.^{174,175}

The basement membrane measures 100–200 nm in thickness, and displays three layers: lamina lucida (beneath the Sertoli cells), lamina densa (basal lamina), and lamina reticularis (a discontinuous layer containing fibers). The basal lamina contains laminin, type IV collagen, entactin (nidogen), and heparan sulfate.¹⁷⁶ External to the basal lamina there are five to seven layers of flattened, elongated peritubular cells that have important secretory functions (Table 12-3).¹⁷⁷ The cells forming the three to five innermost layers are myofibroblasts containing numerous actin, myosin, and desmin filaments. These cells play an important role in the rhythmic tubular contractions that propel spermatozoa toward the rete testis.^{178,179} The two outermost cell layers consist of fibroblasts without desmin filaments, and with less actin and myosin than the myofibroblasts.

Collagen fibers are present among the peritubular cells and are abundant between the basal lamina and the peritubular cells. Elastic fibers are located mainly at the periphery of peritubular cells. Because elastic fibers appear at puberty, their absence in adults is a sign of tubular immaturity or dysgenesis.¹⁸⁰ The extracellular matrix contains proteoglycans and fibronectin. In addition, the tubular wall contains capillaries and Leydig cells. These are very similar to the interstitial Leydig cells and are named peritubular Leydig cells.

The most important functions of myofibroblasts are contraction of seminiferous tubules and control of Sertoli cells.¹⁸¹ Myofibroblasts have α and β adrenergic and muscarinic receptors.¹⁸² Contractility depends on several factors produced in the testis (endothelin-1, vasopressin, oxytocin, and TGF- β) and prostaglandins. Relaxation can be facilitated by the NO/cGMP system because myofibroblasts are also able to synthesize nitric oxide. Sertoli cell control by myofibroblasts is facilitated by the production of P-Mod-S, which

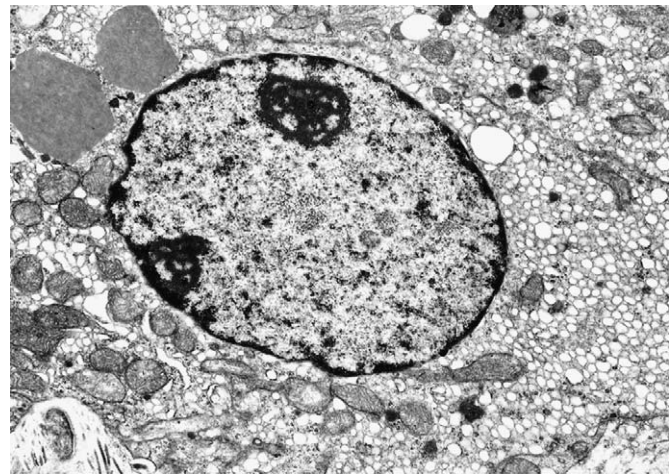


Fig. 12-23 Leydig cells with round nuclei, abundant smooth endoplasmic reticulum, and Reinke's crystalloids.

activates aromatase activity, inhibin production, and the secretion of androgen-binding protein and transferrin.

Testicular interstitium

The interstitium between the seminiferous tubules contain Leydig cells, macrophages, neuron-like cells, mast cells, blood vessels, lymphatic vessels, and nerves, accounting for 12–20% of testicular volume.¹⁸³

Connective tissue cells

The most numerous connective tissue cells are fibroblasts and myofibroblasts. The former are also known as interstitial dendritic cells or CD34-positive stromal cells. They display a network around the seminiferous tubules and Leydig cells, and also form the outermost layers of the tubular wall.¹⁸⁴ This distribution begins in fetal life. Some of these cells are in contact with typical macrophages, so it has been suggested that they might be involved in immune surveillance. Myofibroblasts, in addition to their presence in the inner layer of the tubular wall, are numerous in the tunica albuginea.

Leydig cells

Leydig cells are distributed single or in clusters, and form about 3.8% of testicular volume. Most are in the testicular interstitium, although they may also be found in the tubular tunica propria, mediastinum testis, tunica albuginea, epididymis, and spermatic cord. Extratesticular Leydig cells are usually seen within or near nerve trunks.^{185–187}

Leydig cells have spherical eccentric nuclei with one or two eccentric nucleoli and prominent nuclear lamina. The cytoplasm is abundant, eosinophilic, and contains lipid droplets and lipofuscin granules (residual bodies) (Fig. 12-23). Reinke's crystalloids are found only in the Leydig cells of adults and, although it was believed that these crystals were present exclusively in humans, they have also been observed in the wild bush rat. Reinke's crystalloids are up to 20 μm long and 2–3 μm wide, consisting of a complicated meshwork of 5 nm filaments with a trigonal lattice arrangement. Depending on the plane of section, three basic aspects of this lattice can be discerned. Frequently, the crystalloids display pale lines, con-

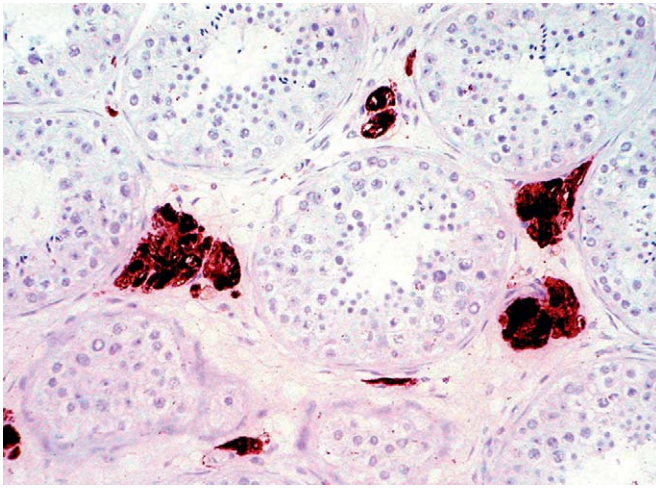


Fig. 12-24 Leydig cells form small intertubular clusters that are immunostained for calretinin.

sidered to be potential planes of cleavage. The filaments are grouped into 19 nm-wide hexagons visible on cross-section. In some areas there are aggregates of electron-dense, rod-shaped structures. Some Leydig cells contain other types of paracrystalline inclusion, the most common of which consists of multiple parallel-folded laminae.¹⁸⁸

Leydig cells contain abundant well-developed smooth endoplasmic reticulum, pleomorphic mitochondria with tubular cristae, lysosomes, and peroxisomes. Leydig cells react with antibodies to S100 protein and neuron-specific enolase.¹⁸⁹

Leydig cells immunoreact to LH receptors, 3- β -hydroxysteroid dehydrogenase (3- β -HSD), relaxin-like factor,¹⁹⁰ inhibin, and ghrelin.¹⁹¹ Relaxin-like factor, also known as insulin-like factor 3 (INSF-3), is a peptide that is involved in testicular descent and can be found in serum. Its concentration is a maker of the Leydig cell functional status. As occurs with testosterone, INSF-3 production is associated with that of LH.¹⁹² Leydig cells immunoreact with calretinin, a 29 kDa calcium-binding protein that has a buffering effect to avoid abnormal increases in intracellular calcium.¹⁹³ Calretinin is a more sensitive marker than inhibin, albeit less specific (Fig. 12-24).¹⁹⁴ Leydig cells also contain VEGF and its two receptors (Flt-1 and KDR), and endothelin and its two receptors (α and β). VEGF and endothelin are involved in paracrine and autocrine control of Leydig cells. Leydig cells near seminiferous tubules show immunoreactivity for glial fibrillar acid protein (GFAP)¹⁹⁵ (Fig. 12-24). The demonstration of several substances that are characteristic of nerve cells, such as substance P, neurofilament triplet proteins (NF-L, NF-M and NF-H), and the ultrastructural observation of microtubules, intermediate filaments, and clear and dense core vesicles, qualifies Leydig cells for inclusion within the family of the diffuse endocrine system or paraneurons.^{196,197}

Leydig cells of the adult testis originate from fibroblastic precursor cells at puberty under LH stimulation.¹⁹⁸ Experimental studies in rats have shown that adult Leydig cells differentiate from peritubular cells (myofibroblasts and

Table 12-4 Major Leydig cell secretory products

Products	Functions and/or characteristics
Androgens	Steroid hormone/endocrine–paracrine agent
Pro-opiomelanocortin peptides	Opiates/pro-opiomelanocortin regulatory agents
Inhibin	Endocrine–paracrine regulatory agent
IGF-1	Maintenance growth/differentiation

IGF-1, insulin-like growth factor.

blood capillary pericytes). Precursor Leydig cells are reminiscent of neural stem cells because they express nestin and eventually acquire properties of neurons and glial cells.¹⁹⁹

The human testis contains about 200 million Leydig cells. This number decreases with age: the testes of 60-year-old men contain about half as many as those of 20-year-old men.^{202–203} Mitotic figures are seen occasionally in normal Leydig cells.²⁰⁴

Leydig cells are the target cell of LH, in response to which they produce testosterone and other androgens necessary for the maintenance of spermatogenesis and many structures of the male genital tract, as well as other tissues such as bone, muscle, and skin.^{205–208} Testosterone acts on the Sertoli cells, either directly²⁰⁹ or via the P-mod-S factor secreted by the myofibroblasts in the tunica propria.^{210–212} Leydig cells also secrete numerous non-steroidal factors, including oxytocin, which acts on myofibroblasts and stimulates seminiferous tubule contraction; β endorphin, which inhibits Sertoli cell proliferation and function; EGF, which regulates spermatogenesis; and other factors with less known actions, such as angiotensin, pro-opiomelanocortin, and α -melanotropic stimulating hormone (Table 12-4). Together with Sertoli cells, peritubular cells, and endothelial cells, Leydig cells produce nitric oxide, which has a relaxing effect on smooth muscle.²¹³

Leydig cells are associated with cholinergic and adrenergic nerve fibers.¹⁸⁶ Varicosities containing synaptic vesicles in the proximity of Leydig cells and nerve endings in direct contact with Leydig cells have been reported, although the functional significance of this innervation is unknown.^{214,215}

Macrophages, neuron-like cells, and mast cells

Macrophages are a normal component of the testis^{216–218} and can be classified into two groups: resident and activated. Resident macrophages are an essential cell type of the testicular interstitium (about 25% of interstitial cells in mouse testis).²¹⁹ In young adult men, there is one macrophage per 10–15 Leydig cells, and this number increases with age. Macrophages are closely related to Leydig cells and play a role in proliferation and differentiation of Leydig cell fibroblastic precursors.²²⁰ Interaction between macrophages and Leydig cells is an example of paracrine function. In the rat, testicular macrophages produce 25-hydroxycholesterol (25-HC) and express 25-hydroxylase, which transforms cholesterol into 25-HC.^{221,222}

Activated macrophages produce interleukins 1 and 6 (IL-1 and IL-6), tumor necrotizing factor- α (TNF- α), and transforming growth factor- α (TGF- α).

Immunohistochemical techniques have demonstrated neuron-like cells in the testicular interstitium.²²³ These cells are an important source of intratesticular catecholamines, which appear to be increased in some disorders such as the Sertoli cell-only syndrome, and hypospermatogenesis.

Mast cells are a normal component of the testicular interstitium, where they are often found near blood vessels. Their number increases in several diseases.²²⁴

Blood and lymphatic vessels

The testis is supplied by the testicular artery, which arises from the abdominal aorta. In the spermatic cord, the testicular artery gives rise to two or three branches that obliquely penetrate the tunica albuginea testis and to multiple branches that run along the intralobular septa of the testis.²²⁵ These centripetal arteries lead to the mediastinum testis. Along their course, the centripetal arteries give off branches that abruptly reverse direction; these are called centrifugal arteries. At puberty, both the centripetal and the centrifugal arteries develop a pronounced spiral architecture.^{226,227} The centrifugal arteries develop additional branches in the testicular interstitium, giving rise to arterioles and capillaries that form intertubular plexuses, some of which are apposed to the tunica propria.^{228,229} Capillaries are of the continuous type, except for the seminiferous tubule capillaries, which are partially fenestrated,²³⁰ and their endothelial cells are similar to those of brain capillaries, with scant pinocytosis, intercellular junctions of the fascia adherens type, and low permeability. The mediastinum testis is poorly vascularized.

The inner two-thirds of the testicular parenchyma is drained by veins that follow the interlobular septa to the mediastinum testis (centripetal veins). The outer third is drained by veins that lead to the tunica albuginea (centrifugal veins). Both centripetal and centrifugal veins join to form the pampiniform plexus, which drains the testis via the spermatic cord.

Lymphatic vessels are poorly developed in the testis and limited to the tunica vasculosa and interlobular septa,²³¹ where they accompany arterioles and venules. Prelymphatic vessels have been reported in the interstitium and probably drain interstitial fluid into the true interlobular lymphatic vessels.

Nerves

Efferent innervation of the testis is mainly supplied by neurons of the pelvic ganglia, where contralateral and bilateral neural connections occur. Postganglionic nerve fibers enter the testis via the pelvic nerves, extend throughout the tunica vasculosa, and follow the interlobular septa to reach the interstitium. These nerve fibers end in the wall of arterioles, the wall of seminiferous tubules, and the Leydig cells.²³² Adrenergic nerve fibers innervate the tunica albuginea and the blood vessels of the tunica vasculosa.²³³ Peptidergic nerve endings are uncommon. Afferent nerve endings form corpuscles similar to those of Meissner and Pacini in the tunica albuginea.

Rete testis

The rete testis is a network of channels and cavities that connects the seminiferous tubules with the ductuli efferentes. Differences in the configuration and size of channels and cavities distinguish three portions of the rete testis: septal (intralobular), composed of the tubuli recti; mediastinal, composed of a network of interconnected channels; and extratesticular, composed of dilated cavities (up to 3 mm in diameter) termed the bullae retis.

The tubuli recti are short tubules (0.5–1 mm long) that connect the seminiferous tubules to the mediastinal rete, although some seminiferous tubules may connect directly to the mediastinal rete, principally those in the central region of the testis. The tubuli recti are lined by cuboidal epithelium. There are approximately 1500 tubuli recti (or their analogous seminiferous tubule segments). The tubuli recti in the cranial, central, and anterior testis are perpendicular to the mediastinal rete testis channel into which they drain, and those in the caudal testicular region are parallel to their respective channels. The transitional segments between the seminiferous tubules and the tubuli recti are formed by modified Sertoli cells.²³⁴

The epithelium of the mediastinal rete testis consists of flattened cells interspersed with small areas of columnar cells. Both cell types have single centrally located cilia and numerous microvilli on their free surfaces, and contain keratin and vimentin filaments.²³⁵ There are interdigitations between adjacent cells. The epithelium rests on a basal lamina, surrounded by a layer of myofibroblasts and a more peripheral layer of fibroblasts and collagen and elastic fibers.

The rete channels and cavities are traversed by the chordae rete, columns from 15 μm to 100 μm long and from 5 μm to 40 μm wide, arranged obliquely to the long axis of the cavity. The chordae consist of fibrous connective tissue with fibroblasts and are covered by flattened epithelium; the widest contain capillaries. The rete testis probably has the following functions: damping differences in pressure between the seminiferous tubules and ductuli efferentes; reabsorption of protein and potassium from tubular fluid; and, occasionally, phagocytosis of spermatozoa.

Congenital anomalies of the testis

Alterations in number, size and location

Anorchidism

Types

Anorchidism refers to the absence of one (monorchidism) or both testes (testicular regression syndrome). Monorchidism is estimated to occur in about 4.5% of cryptorchid testes,²³⁶ 40% of the testes that are impalpable in physical examination,²³⁷ or 1 in 5000 males. Bilateral anorchidism occurs in approximately 1 in 20 000 males.²³⁸

Monorchidism The hormonal pattern in prepubertal patients with monorchidism does not differ from that of normal children, whereas children lacking both testes have elevated levels of gonadotropins and fail to respond to stimulation

Table 12-5 Testicular regression syndromes

	Embryonal period		Fetal period		
	Early	Late	Early	Middle	Late
Müllerian structures	Vestigial	Differentiated	Differentiated/vestigial	Vestigial	Vestigial
Wolffian structures	Vestigial	Vestigial	Vestigial/differentiated	Differentiated	Differentiated
External genitalia	Female	Female	Ambiguous	Ambiguous-male	Male

with hCG.^{238–240} Although the hCG stimulation test is often positive in children with bilateral cryptorchidism, it is negative in some children with bilateral intra-abdominal cryptorchidism and this further complicates the differential diagnosis between anorchidism and cryptorchidism.²⁴¹

For unknown reasons, the left testis is more frequently absent (68.7%) than the right. In such cases the contralateral scrotal testis undergoes compensatory hypertrophy and its volume increases to more than 2 mL.²⁴² Compensatory hypertrophy has also been reported in association with abdominal cryptorchid testis.²⁴³

The absence of testicular parenchyma should be confirmed before diagnosing monorchidism. At exploration, the finding of a vas deferens ending near or in a hypoplastic epididymis is not sufficient for the diagnosis of monorchidism. The only acceptable finding is blind-ending spermatic vessels. If inguinoscrotal exploration fails to identify these vessels, intra-abdominal exploration is required to insure against an undescended testis and avoid the development of a testicular tumor.²²⁴ All remnants found at exploration should be removed.²⁴⁵

Testicular regression syndrome Testicular regression syndrome refers to a variety of conditions, including agonadism, anorchidism, testicular agenesis, rudimentary testes, hypoplastic testes, and embryonal testicular dysgenesis.²⁴⁶ Each of these syndromes shares a complete absence or involution of both testes²⁴⁷ but differ in the time of testicular disappearance during development. The most frequently observed are Swyer's syndrome (see discussion on gonadal dysgenesis below), true agonadism, rudimentary testes, bilateral anorchidism, vanishing testes syndrome, and Leydig cell-only syndrome (Table 12-5).

True agonadism (46XY gonadal agenesis syndrome) Patients with true agonadism have ambiguous external genitalia, fusion of the labia, and a short vagina, reflecting very early testicular regression (between the eighth and 12th weeks of embryonal development). The internal genitalia consist of a uterus and two uterine tubes, although both müllerian and wolffian derivatives may be absent. No gonads (not even in an ectopic location) are found. Patients are phenotypically girls, and the male gender may be discovered only at the time of referral for other symptoms.²⁴⁸ Both sporadic and familial cases with associated extragenital anomalies have been reported. In some cases the cause is a heterozygous mutation of WT1.²⁴⁹ In most familial cases inheritance is either recessive autosomal or X-linked, and the cause seems to be either unknown anomalies in the WT1 gene or known anomalies in other genes involved in development.²⁵⁰ A SRY molecular defect has never been observed.²⁵¹ Agonadism may be associ-

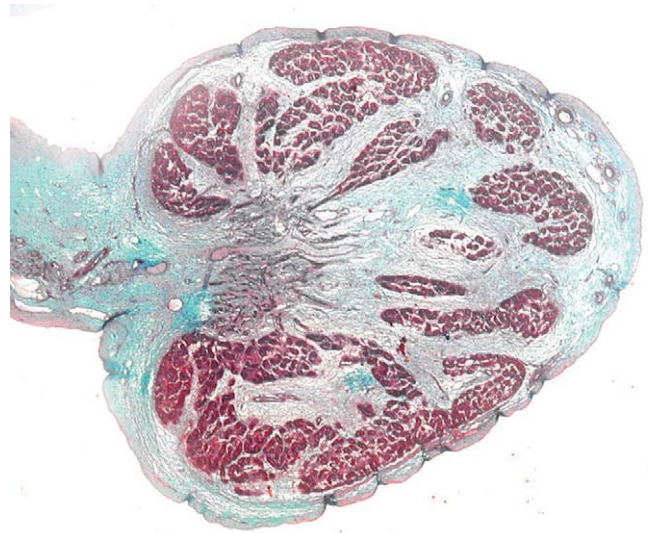


Fig. 12-25 Cross-sectioned rudimentary testis from a 2-year-old infant. Testicular lobules are separated by wide septa and contain scant seminiferous tubules.

ated with several syndromes, including those of PAGOD (hypoplasia of lungs and pulmonary artery, agonadism, omphalocele/diaphragmatic defect, dextrocardia),²⁵² Kennerknecht,²⁵³ Seckel,²⁵⁴ and CHARGE.²⁵⁵

Rudimentary testes syndrome Patients with rudimentary testes have a normal male phenotype. Müllerian remnants are absent and wolffian derivatives usually are found. The testes are cryptorchid and very small, less than 0.5 cm long. Seminiferous tubules are few (Fig. 12-25). The testicular regression occurs between the 14th and 20th weeks of gestation. This syndrome has been reported in several members of the same family,²⁵⁶ suggesting genetic transmission, but this is not a constant feature.^{257,258}

Congenital bilateral anorchidism Congenital bilateral anorchidism occurs in 1 in 20 000 newborns. The patients have male external genitalia, but the internal genitalia consist only of normal wolffian derivatives without müllerian derivatives, suggesting that the testes were present and functionally active up to approximately the 20th week of gestation. Patients have male external genitalia with hypoplasia of both the scrotum and penis. The karyotype is the normal male. The disorder may be associated with other malformations, such as anal atresia, rectourethral and rectovaginal fistula, and urinary exstrophy. Patients diagnosed at adulthood have male phenotype, androgen insufficiency symptoms, and elevated levels of both FSH and LH.^{259,260}

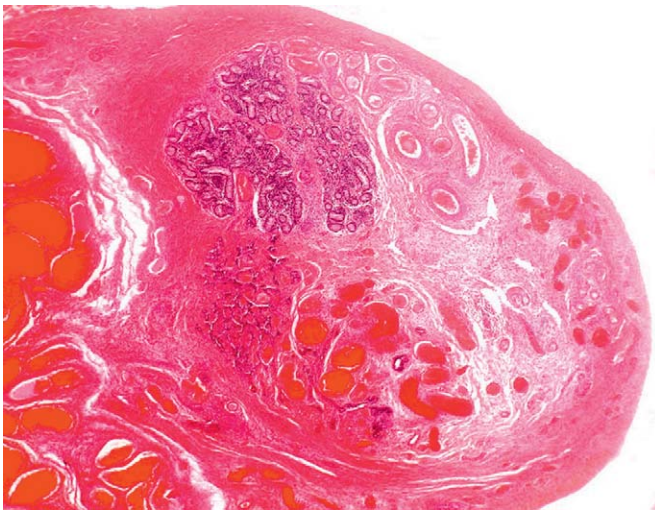

Fig. 12-26 Vanishing testis, consisting of a small group of seminiferous tubules, the rete testis, and numerous blood vessels.

Familial incidence in some cases suggests SRY gene mutation, but this has not been confirmed.^{261,262}

Vanishing testes syndrome This term refers to the disappearance of one or both testes between the last months of intrauterine life and the beginning of puberty.^{263–265} As testicular regression occurs after the seventh month, exploration finds the vas deferens in the inguinal canal or high in the scrotum; it may be accompanied by the epididymis and, less frequently, by testicular remnants consisting of small groups of seminiferous tubules (Fig. 12-26). Patients lacking both testes develop hypergonadotropic hypogonadism after puberty, with gynecomastia, infantile phallus, hypoplastic scrotum, and impalpable prostate. The condition is usually secondary to a perinatal scrotal torsion,²⁶⁶ although rarely there is a genetic cause.^{267,268}

Leydig cell-only syndrome Patients with Leydig cell-only syndrome have agonadism without eunuchoidism and a normal male phenotype, although meticulous surgical exploration fails to find testicular remnants. Study of serial sections from the spermatic cord reveals clusters of Leydig cells.²⁶⁹ Detection of testosterone in spermatic vein blood indicates that these ectopic Leydig cells are functionally active and synthesize testosterone in amounts sufficient to induce a rudimentary male phenotype but insufficient to support the complete development of secondary sex characteristics.

Macroscopic and microscopic findings

The morphology of spermatic cord remnants is similar in monorchidism and testicular regression syndrome occurring after the 20th week of gestation.^{270–272} Grossly, a small, firm mass is found at the end of the cord (Fig. 12-27). Histologic examination reveals vas deferens, epididymis, or small groups of seminiferous tubules in 69–83% of cases.²⁷³ Vas deferens is the most constant finding (79%), followed by epididymis (36%) and seminiferous tubules (5–13%). The spermatic vessels are abnormally small in 83% of cases.^{245,274} Areas of dystrophic calcification, hemosiderin deposition, and giant cell reaction may be found within the mass in place of the testis. Other findings include arterial and venous

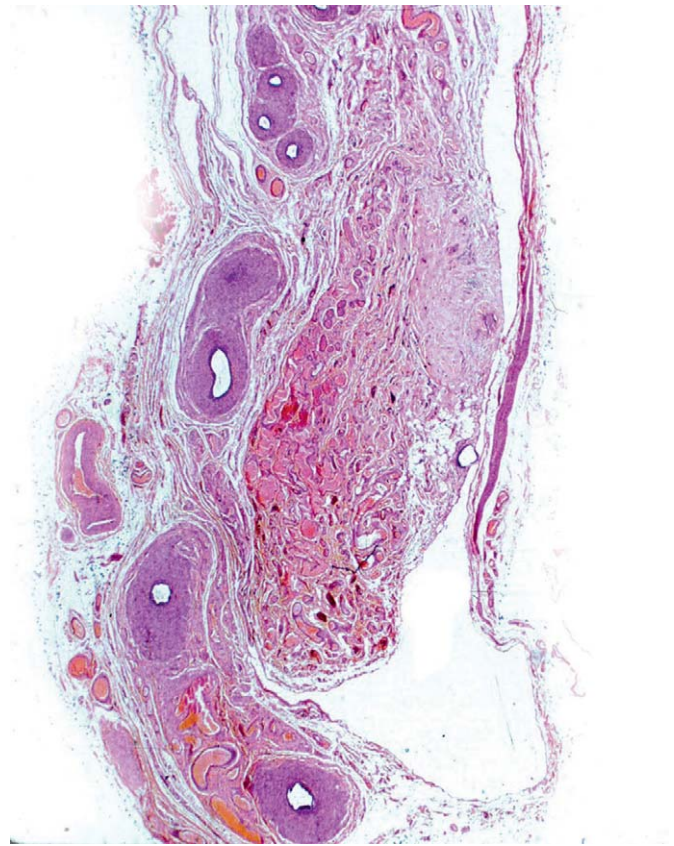


Fig. 12-27 Spermatic cord in anorchidism. Fibrous connective tissue with dystrophic calcification surrounds the distal end of the vas deferens and replaces the testis.

vessels (88%), fat (44%), and nerves that may resemble traumatic neuroma (56%).

The minimal requirement to diagnose vanishing testis is to find either a vascularized fibrous nodule with calcification or hemosiderin, or a fibrous nodule with cord elements.²⁷⁵ It has been proposed that removal of the testicular nubbin in this syndrome may not be required because the percentage of seminiferous tubules is very low and the presence of germ cells low, and thus the probability of a tumor is minimal.^{276,277} The general recommendation is scrotal exploration as a first step, reserving laparoscopy for cases in which either the atrophic remnant cannot be identified during scrotal exploration or has a patent vaginal process.²⁶⁶

Etiology

The histologic findings suggest that most cases of unilateral and bilateral anorchidism are produced during the fetal period after the testis has inhibited the müllerian ducts and induced differentiation of wolffian duct derivatives. Two hypotheses account for the disappearance of the testes: primary anomaly of the gonad; and atrophy secondary to a vascular lesion such as thrombosis or intrauterine torsion. The presence of macrophages with hemosiderin and dystrophic calcification supports the latter. Absence of one testis may be associated with malformations of the urogenital system, such as absence of the kidney, cystic seminal vesicles, and ipsilateral renal dysgenesis.^{278,279}

Micro-orchidism

This clinical term refers to diverse conditions (Klinefelter's syndrome, hypogonadotropic hypogonadism, rudimentary testes syndrome, bilateral cryptorchidism, etc.) that share small testicular size.^{280,281}

A peculiar case is presented by some patients with Kenny–Caffey syndrome: short stature, cortical thickening and medullary stenosis of long bones, delayed closure of anterior fontanelles, hypoparathyroidism, and several ocular alterations. FSH serum levels are elevated, but only in some cases, whereas LH and testosterone are normal. Adult testes are small, with seminiferous tubules showing complete but diminished spermatogenesis. Leydig are hyperplastic. Unlike patients with the rudimentary testes syndrome, micro-orchidism patients have a normal-sized penis and no epididymal or prostatic atrophy.²⁸²

Polyorchidism

Polyorchidism is a rare condition, with approximately 100 reported cases.^{283,284} It was first described in a postmortem study in 1880,²⁸⁵ and the first case treated surgically and confirmed histologically was reported in 1895.²⁸⁶ Although three testes are the most common,²⁸⁷ four testes have been reported in six patients,^{288–292} and five in one case but without histologic confirmation.²⁹³ Age of diagnosis varies from newborn to 74 years, with a mean of 17 years. Testicular duplication is usually an incidental finding during surgery for inguinal hernia, cryptorchidism, or testicular torsion, but has also been detected in patients with infertility or unexplained fertility after bilateral vasectomy.²⁹⁴ The extra testis is often intrascrotal (75%) and less frequently inguinal (20%), abdominal,²⁹⁵ or retroperitoneal (5%).^{296,297} Duplication is three times more frequent on the left than on the right.²⁹⁸ High-resolution ultrasound is the appropriate diagnostic technique.^{284,299} Testicular maldescent (40%), inguinal hernia (30%), hydrocele, varicocele, and contralateral cryptorchidism are the most frequently associated anomalies.^{300–302} Testicular torsion (13%)³⁰³ and testicular cancer (5.4%) are occasional complications. Although the extra testis may be histologically normal,^{304–306} usually it is not,^{300,307} and displays lesions such as Sertoli cell-only tubules, hypospermatogenesis, or maturation arrest. The lack of spermatogenesis has been attributed to the anomalous location of the testis and the absence of communication between the testis and excretory ducts.³⁰⁸

The embryologic origin of polyorchidism remains uncertain, and the following have been proposed to account for the variety of findings in different cases (Fig. 12-28):

- Longitudinal division of all the structures of the genital ridge and mesonephric ducts. Each of the two testes resulting from the duplication has an excretory duct and develops active spermatogenesis.^{286,294,309–311}
- Longitudinal division of the genital ridge. Of the two resulting testes, the medial loses its connection with the mesonephric ducts and undergoes atrophy.
- High transverse division of the genital ridge. The two resulting portions are in continuity with the mesonephric ducts that give rise to the ductuli

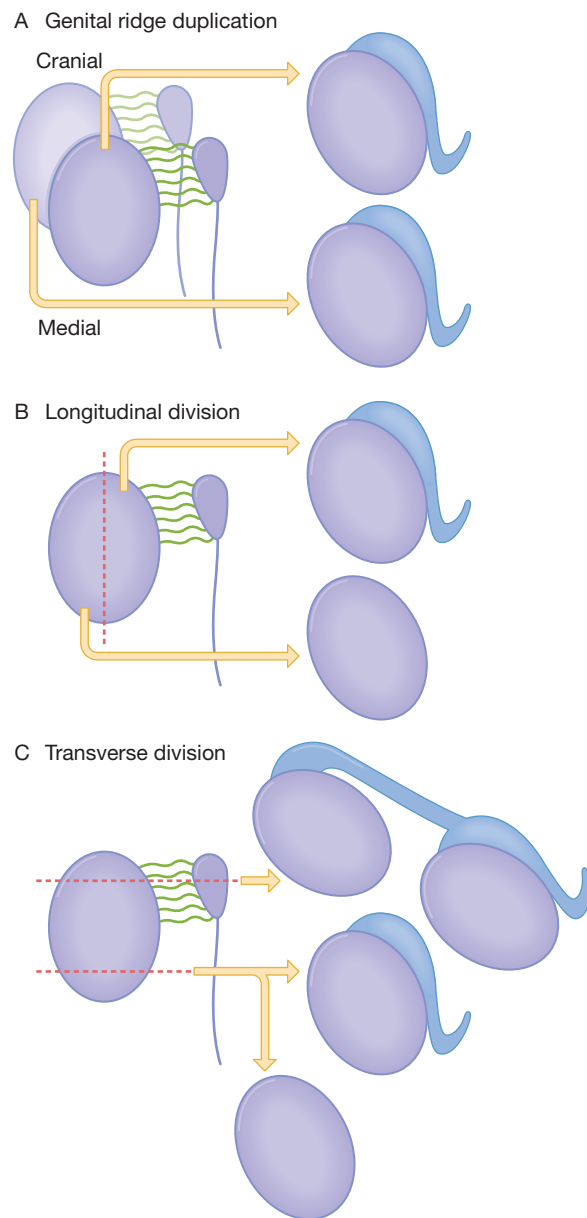


Fig. 12-28 Possible mechanisms of polyorchidism. **(A)** Genital ridge duplication gives rise to two testes with their respective epididymides. **(B)** Longitudinal division of the genital ridge. The testis derived from the medial region has no epididymis. **(C)** Transverse division of the genital ridge. The resulting testes either share a single epididymis or one testis is devoid of epididymis.

efferentes. Each testis has its own ductus epididymidis or shares a common one, but there is a single vas deferens for both.^{302,312}

- Low transverse division of the genital ridge. The more caudal testis has no excretory ducts.³⁰²

The clinical differential diagnosis of polyorchidism includes most of pathologic conditions that enlarge the scrotum and spermatic cords: spermatocele, hydrocele, cysts and tumors of the spermatic cord, crossed testicular ectopia, adrenal cortical ectopia, and splenogonadal fusion. Orchiectomy used to be the treatment of choice for all atrophic

and non-scrotal testes. Today, most surgeons undertake fixation of the testis to the scrotal pouch and the re-creation of a 'simple testis' if it is permitted by the anatomical condition and malignancy has been precluded. This treatment may allow spermatogenesis as well as additional psychologic and cosmetic benefits.³¹³ Intrascrotal rhabdomyosarcoma, testicular teratoma, and seminoma have been reported in patients with polyorchidism.^{314,315}

Testicular hypertrophy (macroorchidism)

Macro-orchidism may be uni- or bilateral and be associated with chromosomal anomalies or endocrine alterations. An increase in the testicular parenchyma occurs in several conditions,³¹⁶ including congenital Leydig cell hyperplasia, compensatory hypertrophy, benign idiopathic macroorchidism, bilateral megalotestes with low gonadotropins, fragile X chromosome, and the testicular hypertrophy observed in juvenile hypothyroidism.

Congenital Leydig cell hyperplasia

Congenital Leydig cell hyperplasia is uncommon and may be diffuse or nodular. The diagnosis of diffuse Leydig cell hyperplasia requires quantification of Leydig cells by morphometry, using normal newborn testes as controls (Fig. 12-29). Nodular Leydig cell hyperplasia is characterized by the presence of non-encapsulated Leydig cell nodules in the mediastinum testis, adjacent testicular parenchyma and connective tissue among the ductuli efferentes (Fig. 12-30).

The differential diagnosis of nodular Leydig cell hyperplasia includes intratesticular adrenal rests and bilateral Leydig cell tumor. Except for patients with adrenogenital syndrome, intratesticular adrenal rests are rare. These rests are encapsulated, with the exception of the adrenogenital tumors, and consist of radially arranged cells with vesicular nuclei and small nucleoli displacing the rete testis or seminiferous tubules. Leydig cell tumors may be bilateral, poorly circumscribed, and surrounded by testicular parenchyma, features making it difficult to distinguish from Leydig cell hyper-

plasia. However, Leydig cell tumors are rarely congenital, whereas those occurring at infancy often induce precocious maturation of the adjacent seminiferous tubules and early macrogenitosomia.

Leydig cell hyperplasia is caused by large quantities of hCG entering the fetal circulation. Diabetic mothers, particularly those with hypertension, may develop hyperplacentosis; the resulting edema in the placental villi alters the vascular permeability and allows the passage of hCG to the fetus. Congenital Leydig cell hyperplasia decreases rapidly during the first months of postnatal life, after maternal human chorionic gonadotropin is gone. Combined diffuse and nodular Leydig cell hyperplasia occurs in several malformative syndromes, such as Beckwith-Wiederman, leprechaunism, triploid fetuses, fetuses with Rh isoimmunization,³¹⁷ and in several complications of pregnancy.

Compensatory hypertrophy of the testis

Compensatory hypertrophy has been observed in monorchidism,³¹⁸ cryptorchidism³¹⁹ (Fig. 12-31), varicocele,³²⁰ and after testicular injury. Hypertrophy persists and may increase during childhood and puberty, but ceases thereafter; the hypertrophied testis then becomes normal or remains slightly enlarged.^{321,322} The degree of hypertrophy is determined by three factors: the volume of the remaining testicular parenchyma, the age at which the injury occurred, and the functional ability of the descended testis.³²³ Compensatory hypertrophy results from an alteration in the hypophyseal hormonal feedback mechanism, followed by an increase in secretion of FSH, evidence that the contralateral testis is normal. In monorchidism, the testis is initially normal.²³⁷ When a 50% reduction of testicular mass occurs (probably before birth), the endocrine feedback changes and the resulting secretion of FSH (before or immediately after birth) causes accelerated growth of the contralateral testis. In cryptorchidism, the reduction in testicular mass is less severe than in monorchidism, and the scrotal testis may also be abnormal, inducing a lesser compensatory hypertrophy. Compen-

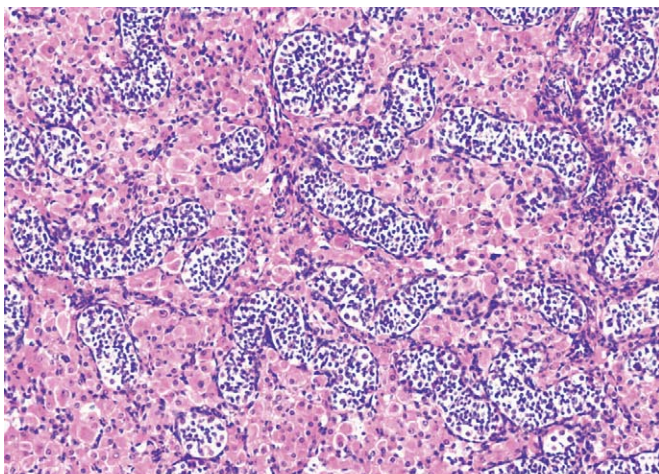


Fig. 12-29 Congenital Leydig cell hyperplasia. Multiple nodules of Leydig cells are present in the mediastinum testis as well as deep in the parenchyma.

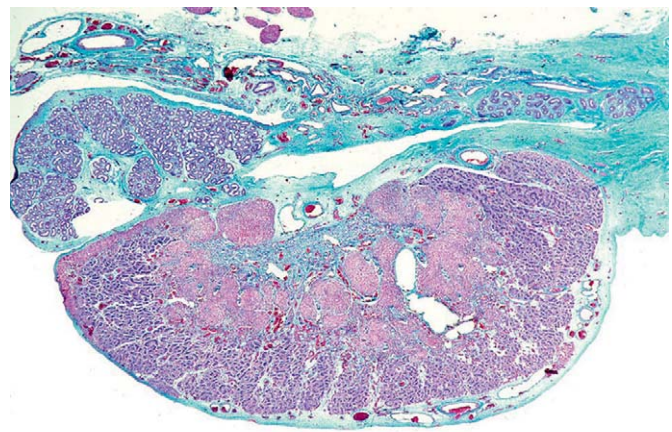


Fig. 12-30 Congenital Leydig cell hyperplasia. Fetal Leydig cells form large clusters surrounding groups of seminiferous tubules.

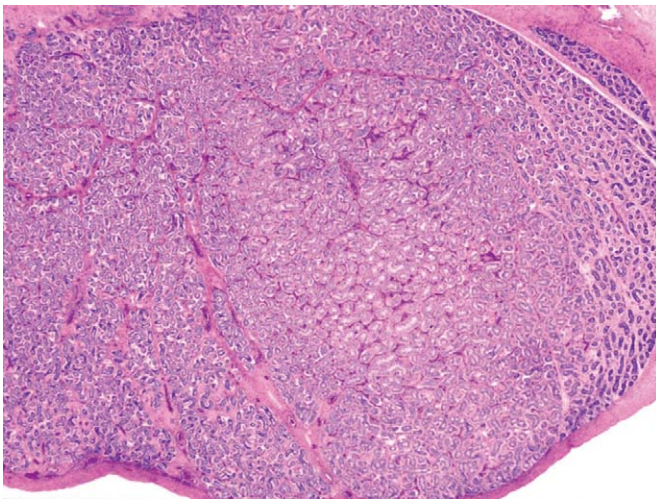


Fig. 12-31 Contralateral scrotal testis from a cryptorchid patient showing a group of large seminiferous tubules that stands out from the surrounding small tubules.

satory hypertrophy develops between birth and 3 years of age, and the testis may reach a volume twice normal when the other testis is absent.²⁴³

Idiopathic benign macroorchidism

Some prepubertal and pubertal patients have pronounced unilateral³²⁴ or bilateral^{325–327} testicular hypertrophy in the absence of other pathologic findings. This probably results from hormonal receptivity in the testicular parenchyma. Morphometric studies have shown that the testicular enlargement is chiefly due to an increase in the length of the seminiferous tubules, although increases in tubular diameter and Sertoli cell numbers have also been observed. Elevated FSH serum levels, reported in some cases, or hyperactive FSH receptors might be the cause of the excessive Sertoli cell proliferation and the lengthening and thickening of seminiferous tubules.^{328–330} In addition, Leydig cell hyperplasia and deficient spermatogenesis are frequent findings in adult life. As the development of the two testes may be asynchronous during puberty, some unilateral macroorchidisms may represent cases in which these differences are unusually exaggerated.

Bilateral megalotestes with low gonadotropins

About 2% of adults with fertility problems have enlarged testes, with volumes over 25 mL, and low levels of FSH, LH, testosterone, prolactin, and estradiol.³³¹ Despite the important hormonal changes, sperm concentrations and total numbers of spermatozoa are higher than normal. Low FSH levels may be attributable to increased inhibin secretion because the number of Sertoli cells is elevated in these testes, but no explanation for the reduction in the other hormone levels has been found.

Fragile X chromosome; Martin–Bell syndrome

Fragile X chromosome is the best-known form of inherited mental retardation, with an incidence of 1 in 1500 males and 1 in 2500 females.³³² In addition to facial dysmorphism (large ears, prognathism, high forehead, and arched palate),

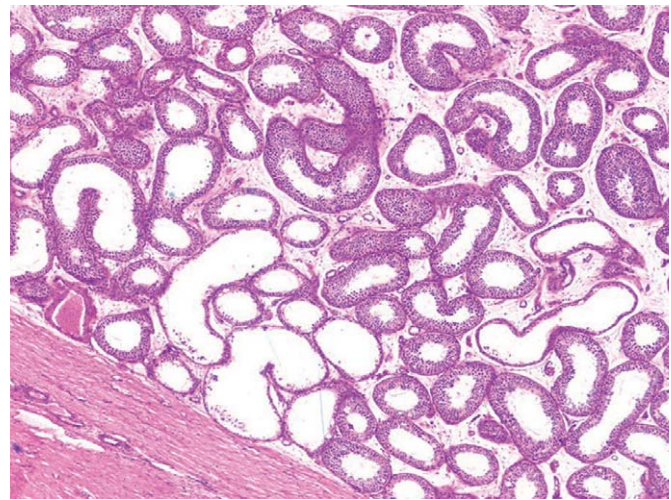


Fig. 12-32 Martin–Bell syndrome (fragile X chromosome). The seminiferous tubules show variable degrees of dilatation and marked hypospermatogenesis.

macroorchidism (Martin–Bell syndrome) is often an associated finding.^{333–337} The impaired gene (FMR1 gene) is mapped to Xq27,3 which is genetically fragile. The gene alteration is due to a lengthening of a trinucleotide CCG repeat that results in FMR1 gene silencing. If the CCG sequence is repeated fewer than 200 times, the disorder is considered a premutation and males show no symptoms; if the number of repetitions exceeds 200, mutation is complete and all show the disorder.^{338–340} In men with this syndrome, the average testicular volume is more than 70 mL (four times greater than normal). The penis also is larger than normal, and both anomalies are apparent in infancy. The scrotum is also enlarged and prematurely pigmented. This precocious genital development is difficult to explain because the hypothalamopituitary axis is normal, but it may be caused by increased sensitivity to stimulation by FSH.³⁴¹

Testicular biopsies from adults may be normal or show interstitial edema and hypospermatogenesis (Fig. 12-32). Usually, there is normal testicular parenchyma with focal reduced spermatogenesis and Sertoli cell hyperplasia (Fig. 12-33) or tubules containing only immature Sertoli cells. Morphometry indicates that testicular enlargement is chiefly the result of lengthening of seminiferous tubules.³²⁸ The low number of spermatids is attributed to atrophy caused by compression of the seminiferous epithelium by marked increase in intratubular fluid.³⁴² Meiotic anomalies have been excluded.³⁴³ The fragile X syndrome is second in frequency only to Down's syndrome as a cause of mental retardation.^{344–346} However, this chromosomal anomaly is not always associated with mental retardation or macroorchidism, and there are men with fragile X syndrome who are otherwise normal.³⁴⁷

The terms 'fragile X-negative Martin–Bell syndrome' or 'mental retardation–macro-orchidism' refer to X-linked (MRMO) or XLMR+MO patients who have the Martin–Bell syndrome phenotype but do not present the fragile X site. The gene responsible for this disorder is mapped to Xq12–q21.³⁴⁸

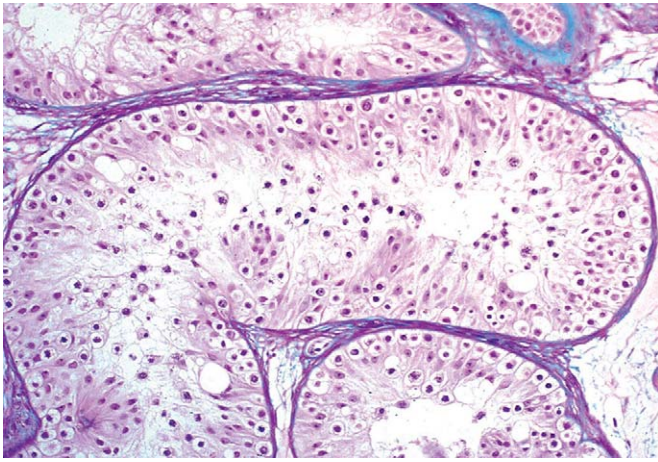


Fig. 12-33 Martin-Bell syndrome (fragile X chromosome). The seminiferous tubules show marked hypospermatogenesis. Several groups of dysgenetic Sertoli cells are seen near the lumen.

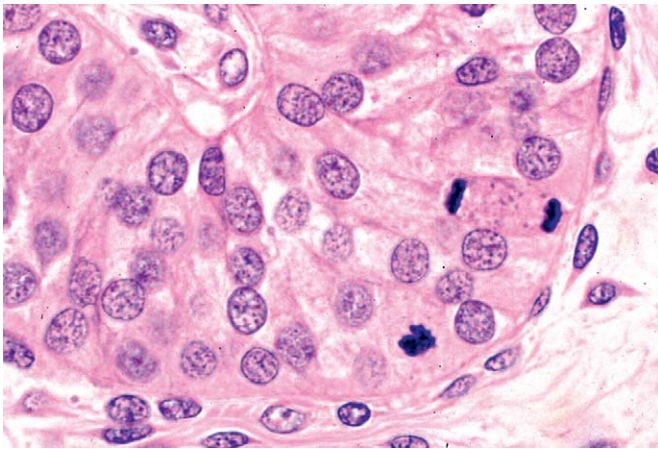


Fig. 12-34 Macroorchidism in a 3-year-old infant with hypothyroidism. The Sertoli cells have spherical nuclei which contain small heterochromatin granules. Two mitotic figures are seen. The testicular interstitium has no Leydig cells.

Other testicular hypertrophies

Testicular hypertrophy appears associated with FSH-secreting pituitary adenoma,³⁴⁹ hyperprolactinemia, hypoprolactinemia, and hypothyroidism.^{350,351} The most frequent association of testicular hypertrophy is with hypothyroidism. Children with hypothyroidism often show testicular enlargement without virilization.³⁵⁰ About 80% have macroorchidism,³⁵² most have elevated FSH levels, and half have increased LH levels.^{353,354} Testosterone levels are normal during infancy. The response of FSH and LH to GnRH is altered and no pulsatile LH release occurs (Fig. 12-34).³⁵⁵

Testicular biopsies before puberty show an accelerated development of the testis with pubertal maturation of seminiferous tubules but not Leydig cells. Testicular biopsies in untreated adults show tubular and interstitial hyalinization with few Leydig cells.^{356,357} Testicular size in this type of macroorchidism diminishes as soon as the substitutive therapy

starts.^{353,358,359} The etiopathogenesis has been explained by three hypotheses: an increase in gonadotropin secretion caused by TRH stimulation of gonadotropic cells,^{360,361} a direct TSH effect on the testis due to the structural similarity between TSH receptors and FSH receptors present in the testis;³⁶² and a lack of steroid hormones that are required for testicular maturation (in their absence, Sertoli cell proliferation is excessive, giving rise to testicular enlargement).³⁶³⁻³⁶⁶

Precocious puberty

Precocious puberty is defined by onset of secondary sex characteristics at a chronologic age that is below the mean middle age for the population. For practical purposes, this is considered to be before 8 years of age in girls and 9 years in boys. The incidence is estimated at between 1 in 5000 and 1 in 10 000, with a female:male ratio higher than 20:1. In boys, the first symptom is rapid testicular enlargement followed by growth of pubic and axillary hair, enlargement of the penis, and acceleration of skeletal growth.³⁶⁷

According to hypothalamopituitary-gonadal axis function, precocious puberty can be classified into three groups: central or gonadotropin-dependent, which results from the activation of this axis; peripheral or gonadotropin-independent, mediated by sex steroid hormones secreted by the testis or adrenal glands; and a mixed group that first appears as peripheral precocious puberty and thereafter, because of the secondary response of the hypothalamus, becomes gonadotropin dependent.

Other possible causes of precocious puberty are hypoprolactinemia, pituitary tumor, and alteration of testicular steroid metabolism.

Central precocious puberty (CPP) Central precocious puberty, also known as true precocious puberty, is isosexual. It is the most common form of precocious puberty in girls and accounts for more than 50% of cases in boys. The age of presentation is between 4 and 10 years.³⁶⁸ The cause is only known in 60% of cases; most are related to lesions in the central nervous system, whereas the others are usually idiopathic.

Lesions in the central nervous system that causes CPP share alterations of specific areas, including the posterior hypothalamus (eminencia media and tuber cinereum), mammillary bodies, the bottom of the third ventricle, or the pineal gland.^{369,370} The most frequent causes are:

- Tumor of the hypothalamus (astrocytoma, ganglioglioma, ganglioglioma, craniopharyngioma, cyst of the third ventricle, and suprasellar cyst of the arachnoid space),³⁷¹⁻³⁷³ hamartoma (gangliocytoma) of the tuber cinereum and mammillary body, tumor of the pineal gland (teratoma and pinealoma), tumor of the optic nerve (glioma), and cerebral and cerebellar astrocytoma.
- Cerebral trauma (including postpartum and accidental trauma) that stimulates the extrahypothalamic areas responsible for hypothalamic activation.³⁷⁴⁻³⁷⁶
- Infections such as meningitis, encephalitis, toxoplasmosis, and syphilis.
- Cerebral malformations, including hydrocephaly, microcephaly, and craniosynostosis.³⁷⁷

- Hereditary diseases as neurofibromatosis and tuberous sclerosis. Children with type I neurofibromatosis often have also optic pathway tumors.
- Cerebral irradiation, as occurs in hypothalamopituitary selective irradiation,³⁷⁸ prophylactic irradiation in children with acute lymphoblastic leukemia,³⁷⁹ and irradiation of cerebral tumor that is far from the hypothalamopituitary region.

The diagnosis of central precocious puberty is easy if the hormonal findings show elevated gonadotropin levels (both basal values and in response to GnRH), associated with high testosterone levels and an increase in either LH/FSH ratio or in LH and FSH values after stimulation with GnRH agonists. However, in some cases it is necessary to measure nocturnal LH secretion to find secretion pulses before a dynamic test can reveal the pubertal pattern.

Knowledge of the etiology in males has improved with the use of CT and MRI.^{380,381} One of the most important contributions of these techniques is the finding of a high number of hamartomas in children with precocious puberty.³⁸²⁻³⁸⁴ These lesions, also known as gangliocytomas, consist of abnormally located neurons and glial cells. Lesions are usually multiple, small, and located on the hypothalamus between the anterior part of the mammillary body and the posterior part of the tuber cinereum. These neurons contain LHRH-positive neurosecretory granules, suggesting that this hormone can be released into the blood draining the hypophyseal portal system and reach the gonadotropic cells.³⁸⁵

Precocious puberty owing to cerebral tumors usually occurs with advanced stage of the tumor, preceded by cerebral symptoms such as hydrocephaly, papillary edema, or psychic alterations. The same occurs when precocious puberty results from cerebral inflammation or cerebral malformation.

Although pineal gland tumor is rare in children, 30% produce precocious puberty, principally in boys. This tumor is usually a teratoma or non-parenchymatous tumor that destroys the pineal gland, hindering its antigonadotropic action and initiating puberty.³⁸⁶ In contrast, pinealocyte-derived tumor secretes great amounts of melatonin that delay the onset of puberty.

Peripheral precocious puberty (PPP) Peripheral precocious puberty is also known as precocious pseudopuberty. It may be caused by a primary testicular disorder, a lesion in other endocrine glands, or hormonal treatment. Primary testicular disorders causing precocious pseudopuberty include familial testotoxicosis, functioning testicular tumor, excessive aromatase activity, or Leydig cell hyperplasia with focal spermatogenesis. The principal secondary anomalies include adrenal cortical anomaly (congenital adrenal hyperplasia, virilizing tumor of the adrenal, and Nelson's syndrome), and lesion secondary to hCG-secreting tumor (hepatoblastoma accounts for half of precocious pseudopuberty cases, and testicular germ cell tumor and the tumors of the retroperitoneum, mediastinum, and pineal gland are responsible for the other half of cases).³⁸⁷

Familial testotoxicosis: gonadotropin-independent precocious puberty (GIPP) or familial male-limited precocious puberty

(FMPP) Familial testotoxicosis is a form of male sexual precocity characterized by early differentiation of Leydig cells and the initiation of spermatogenesis in the absence of stimulation by pituitary gonadotropin. This is a primary testicular abnormality with autosomal dominant inheritance.^{388,389} Ultrastructural studies confirm an adult Leydig cell pattern and complete spermatogenesis, although many spermatids are abnormal.³⁹⁰ The cause of familial testotoxicosis is a constitutive activating mutation of the LH receptor gene.³⁹¹ This gene comprises 11 exons and has been mapped to 2p21. Hormonal measurements show elevated serum levels of testosterone, and low levels of dihydroepiandrosterone sulfate, androstenedione, 17-hydroxyprogesterone, gonadotropin-releasing hormone (GRH), and LH, as well as absence of a pulsatile pattern. In addition, serum levels of inhibin B appear elevated before the normal age of onset of puberty.³⁹² In some patients, a mutation in LH receptor induces Leydig cell adenoma.³⁹³

Precocious puberty secondary to functioning testicular tumor A syndrome of precocious puberty can be the result of different tumors, including Leydig cell tumor, sex cord tumor, adrenal cortex virilizing carcinoma, and extratesticular hCG-secreting germ cell tumor.

Leydig cell tumor may cause precocious puberty. The testis is enlarged owing to tumor growth and maturation of the seminiferous tubules adjacent to the tumor; such maturation results from androgen secretion by tumor cells (Fig. 12-35). In most cases, the contralateral testis is not enlarged.^{394,395}

Sex cord tumor with annular tubules and large cell calcifying Sertoli cell tumor may give rise to precocious pseudopuberty that is isosexual (development of musculature and axillary and pubic hair) and heterosexual (gynecomastia). This precocious testicular maturation and the development of the tumor itself cause testicular enlargement. It has been suggested that tumor cells stimulate Leydig cells to produce androgens that are aromatized to estrogens by the tumor cells themselves, thus accounting for the clinical

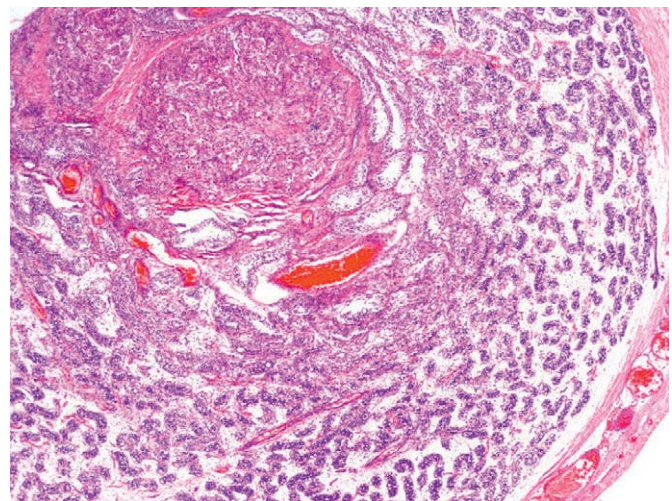


Fig. 12-35 Precocious maturation of seminiferous tubules, which surround a virilizing Leydig cell tumor.

symptoms. These tumors are frequently observed in Peutz-Jeghers syndrome^{396,397} and Carney's complex.³⁹⁸

Most infants with adrenal cortex virilizing tumors have small testes, but some cases of testicular hypertrophy have also been observed.³⁹⁹ Testicular development in these cases is attributed to adrenal androgenic action on seminiferous tubules.⁴⁰⁰ In untreated (or maltreated) congenital adrenal hyperplasia, both testes can be enlarged because they contain growing masses of adrenal cortex-like cells.⁴⁰¹ A similar condition is observed in Nelson's syndrome.

Testicular enlargement is modest in paraneoplastic precocious pseudopuberty secondary to hepatoblastoma⁴⁰² or extratesticular hCG-secreting germ cell tumor, although nodular or diffuse precocious maturation has been occasionally reported.⁴⁰³

Precocious pseudopuberty secondary to excessive aromatase activity Biosynthesis of C18 estrogens from C19 androgens occurs by three consecutive oxidative reactions that are catalyzed by an enzymatic complex known as estrogen synthetase or aromatase.⁴⁰⁴ This complex has two components: P450 arom (a product from the CYP19 gene located on 15p21.1),⁴⁰⁵ which joins C19 substrate and catalyzes the insertion of oxygen in C19 to form C18 estrogens; and NADPH-cytochrome P450 reductase, a ubiquitous flavoprotein that conveys reducing equivalents to any form of cytochrome P450 it meets.

Aromatase is in the endoplasmic reticulum of estrogen-synthesizing cells and expressed in placenta, ovarian granulosa, Sertoli cells, Leydig cells, adipose tissue, and several central nervous system regions, including the hypothalamus, amygdala, and hippocampus. Excessive aromatase causes excessive conversion of androgens to estrogen,⁴⁰⁶ and is a heterogeneous genetic disorder with an autosomal dominant inheritance. The disorder leads to heterosexual precocious pseudopuberty with gynecomastia in males, and to isosexual precocity and macromastia in females. Ultimately, patient stature is short because of the potent ability of androgens to accelerate epiphyseal closure. Most males are fertile and have normal libido.⁴⁰⁷ Generally, the inhibitory estrogenic effect on testicular function is less than that observed with estrogen-producing tumors or in patients treated with exogenous estrogens.

Excessive aromatase caused by P450 mutation induces alterations in both males and females. In females lacking estrogens owing to desmolase deficiency, excessive aromatase leads to pseudohermaphroditism and progressive virilization at puberty; conversely, pubertal development is normal in males. In children, FSH and LH levels and gonadotropin response to GnRH are normal, suggesting that the role of estrogens in pituitary regulation is weak during infancy.⁴⁰⁸ In both genders, epiphyseal closure is delayed and a eunuchoid habitus results. Adult males have small testes, severe oligozoospermia, and complete asthenozoospermia; FSH and LH levels are high, testosterone levels are normal, and serum estrogen levels are very low.

All patients with excessive aromatase have short stature, with continuing linear growth into adulthood, unfused epiphyses, osteoporosis, bilateral genu valgum, and eunuchoid proportions. The testes show macroorchidism with

normal testicular consistency in some cases,⁴⁰⁹ and are small with severe oligozoospermia and 100% immotile spermatozoa in other cases.⁴¹⁰

A syndrome similar to that of excessive aromatase production is found in patients with estrogen resistance caused by disruptive mutations of the ER gene. These patients show macroorchidism, elevated testosterone levels, and increased levels of FSH, LH, estradiol, and estrona.⁴¹¹

Precocious pseudopuberty secondary to Leydig cell hyperplasia with focal spermatogenesis This entity can present with clinical symptoms similar to those of a functioning Leydig cell tumor; this is a precocious pseudopuberty with ipsilateral testicular enlargement.⁴¹² The testes contains hypertrophic Leydig cell nests in association with normal spermatogenesis. No tumoral mass is seen. Leydig cells do not contain Reinke's crystalloids and do not compress the seminiferous tubules. There is a clear delimitation between tubules with spermatogenesis and infantile immature tubules. The differential diagnosis between this entity and Leydig cell tumor with precocious pseudopuberty is based on the histological pattern. Open excisional testicular biopsy is recommended; if there is Leydig cell tumor, or the diagnosis by frozen section is not conclusive, removal is advisable.⁴¹³ There are no data to suggest that this hyperplasia might develop into Leydig cell tumor.

Mixed precocious puberty The best known form is the McCune-Albright syndrome (MAS), characterized by the association of 'coffee and milk' pigmentary lesions in the skin, bone lesions (polyostotic fibrous dysplasia), enlarged testes, prepubertal size of the penis, and absence of pubic and axillary hair. Although testicular enlargement is usually bilateral, unilateral macroorchidism may be the first symptom.⁴¹⁴ An interesting finding is that the onset of testicular maturation is induced by the testis itself, which produces steroid secretion due to autonomous hyperfunction of Sertoli cells without evidence of Leydig cell involvement.⁴¹⁵ This secretion causes early maturation of the hypothalamo-pituitary-testicular axis and, subsequently, true precocious puberty.⁴¹⁶ Serum levels of testosterone are low, but those of inhibin B and AMH are abnormally increased. This syndrome is caused by mutations that activate the GNAS-1 gene, which encodes the α subunit of the trimeric G-protein. Because mutations are lethal in the uterus, those subjects producing AMH bear a mosaicism chromosomal constitution for this deficiency.

Testicular ectopia and testicular fusion

Testicular ectopia

A testis is ectopic when it is in a location outside the normal path of descent. Unlike cryptorchid testes, ectopic testes are nearly normal in size and are accompanied by a spermatic cord that is normal or even longer than normal, and by a normal scrotum.⁴¹⁷

Testicular ectopia is classified according to location;⁴¹⁸⁻⁴²² in decreasing order of frequency, the major types are:

- *Interstitial or inguinal superficial ectopia.* This is the most frequent form and may be confused with inguinal cryptorchidism. After passing through the outer genital opening, the testis ascends to the anterosuperior iliac

spine and remains on the aponeurosis of the major oblique muscle. These testes often are more nearly normal histologically than are cryptorchid testes.

- *Femoral or crural ectopia.* After passing through the inguinal canal, the testis lodges in the high crural cone in Scarpa's triangle.
- *Perineal.* The testis is located between the raphe and the genitocrural fold.
- *Transverse or crossed ectopia.* Both testes descend through the same inguinal canal and lodge in the same scrotal pouch. Each possesses its own vascular supply, epididymis, and vas deferens. In addition, there is ipsilateral hernia.^{423–430} Between 20% and 40% of patients with this ectopia have persistent müllerian duct syndrome^{431–432} and show a high incidence of testicular germ cell tumor.⁴³³
- *Pubopenile ectopia.* The ectopic testis is on the back of the penis near the symphysis pubis.⁴³⁴
- *Pelvic ectopia.* The testis is in the pelvis, usually in the depth of Douglas' cul-de-sac.
- Other unusual testicular ectopias include *retroumbilical, cranio-lateral to the inner inguinal opening* between the outer and inner oblique muscles, and *subumbilical*.⁴³⁵ Rarely, the testis and its spermatic cord may protrude through a defect in the scrotal skin, a condition called *testicular exstrophy*.⁴³⁶

The term *testicular dislocation* refers to testes that secondarily disappear from the scrotum and lodge around the superficial inguinal ring, within the inguinal ring, or inside the abdominal cavity as a result of testicular trauma. The formation of canalicular and intra-abdominal dislocation requires the presence of previous inguinal hernia.⁴³⁷

Testicular fusion

Testicular fusion is a rare anomaly characterized by fusion of the testes to form a single structure, usually in the midline. Each has its own epididymis and vas deferens. This anomaly is often associated with other malformations, such as fusion of the adrenal glands or horseshoe kidney.

Hamartomatous testicular lesions

Cystic dysplasia

Cystic dysplasia of the testis is a congenital lesion characterized by cystic transformation of an excessively developed rete testis that may extend to the tunica albuginea of the opposite pole.⁴³⁸ To date, fewer than 40 cases have been reported.^{439,440} The seminiferous tubules may be dilated and atrophic; this is more evident after puberty. Ultrasound images are characteristic.^{441,442} Cysts arise in the septal and mediastinal rete testis (Fig. 12-36); they are interconnected and contain acellular, eosinophilic, periodic acid–Schiff-positive material. They are lined by cuboidal cells that resemble those of the normal rete testis.^{443–445} The connective tissue between the cysts is scant and histologically similar to the interstitial connective tissue. There may be small groups of cysts limited to the region of the mediastinum testis, or cysts extending throughout the entire testis. In extensive

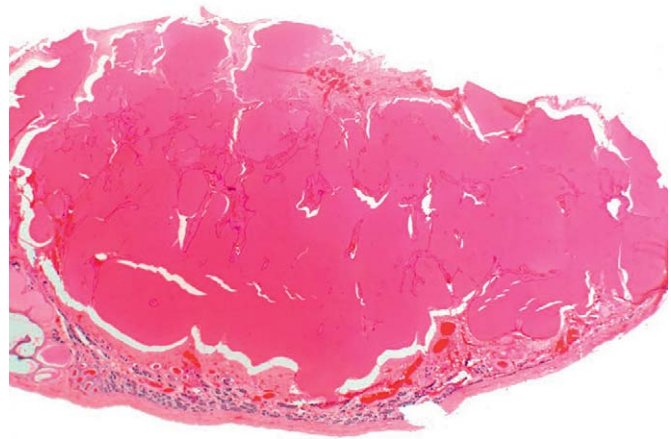


Fig. 12-36 Cystic dysplasia of the testis. There is cystic transformation of the rete testis and adjacent seminiferous tubules.

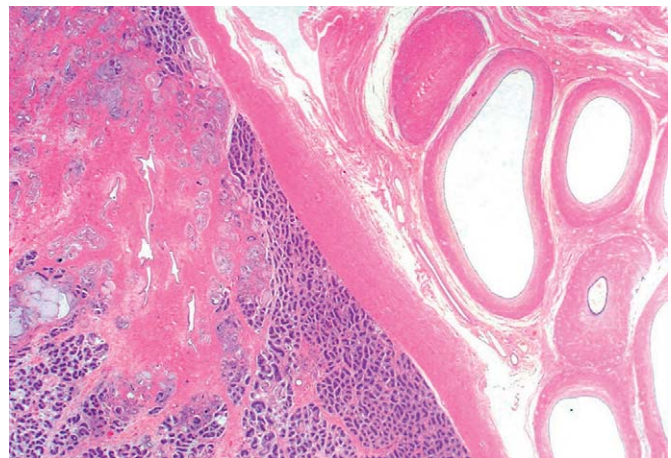


Fig. 12-37 Marked luminal dilation of the ductus epididymidis in an infant with cystic dysplasia of the rete testis.

cases, residual seminiferous tubules occupy only a small crescent beneath the tunica albuginea and the testis is grossly spongy. Cystic dysplasia occurs in normally descended and cryptorchid testes in children and adults, and may affect one or both testes.⁴⁴⁶ In adults, the residual parenchyma often shows complete tubular sclerosis or hypospermatogenesis with intratubular accumulation of spermatozoa and Leydig cell pseudohyperplasia.

In most cases the epididymis is altered.⁴⁴⁷ The head of the epididymis is small and contains few ductuli efferentes with irregular, usually dilated lumina. The ductus epididymidis is dilated, has an atrophic epithelium, and thick connective tissue replaces the muscular layer (Fig. 12-37).

Testicular cystic dysplasia is frequently associated with severe anomalies of the urinary system. Renal agenesis,^{446–449} renal dysplasia,⁴⁴⁶ hydroureter, and urethral stenosis⁴⁵⁰ have been reported ipsilateral to cystic dysplasia. The clinical differential diagnosis should consider all cystic testicular lesions impairing prepubertal testes, including epidermoid cyst,

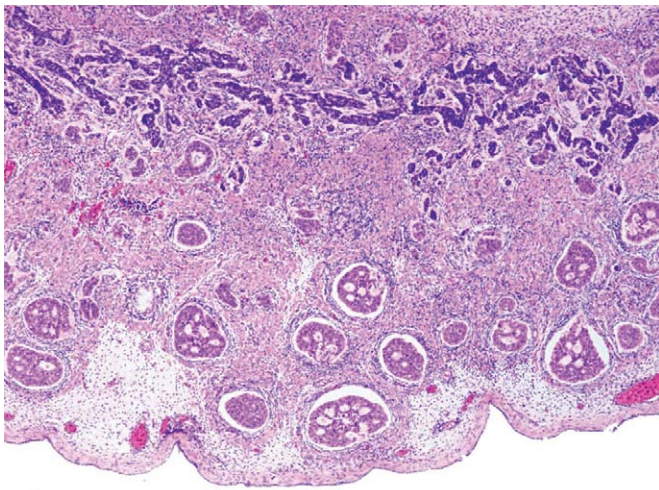


Fig. 12-38 Gonadoblastoid testicular dysplasia. Several nodules are present at the periphery of the testicular parenchyma.

cystic teratoma, juvenile granulosa cell tumor, testicular lymphangiectasis, and simple cyst of the testis.⁴⁵¹ The presence of ipsilateral renal anomalies during ultrasound exploration provides an important diagnostic clue.⁴⁵² Previously, orchidectomy was the treatment of choice, but testis-sparing surgery⁴⁵³ is now recommended.^{454,455}

The etiology and pathogenesis of cystic dysplasia are uncertain. Given that the rete testis is a mesonephric derivative and most of the associated renal malformations are apparently caused by failure in the induction of renal blastema by the mesonephros, cystic dysplasia is considered to be the result of an abnormal mesonephros.

During childhood, the normal rete testis has no lumina, and these form during puberty. The adult rete testis is a conduit for the passage of tubular fluid and spermatozoa and also actively reabsorbs part of this fluid while adding ions, proteins and steroids to it. Malfunction of the rete testis cells may cause the formation of excessive fluid of abnormal composition, resulting in a condition morphologically similar to cystic dysplasia of the rete testis induced in fowl by sodium intoxication or the administration of the salt-retaining hormone deoxycorticosterone acetate.

Gonadoblastoid testicular dysplasia

Gonadoblastoid testicular dysplasia refers to an abnormally differentiated testicular parenchyma beneath the tunica albuginea.⁴⁵⁶ The anomaly consists of large tubular or nodular structures within a dense stroma, reminiscent of ovarian stroma (Fig. 12-38). Each structure is composed of three cell types: cells with vesicular nuclei and vacuolated cytoplasm; cells with hyperchromatic nuclei; and germ cell-like cells. The former two types are arranged at the periphery, forming a pseudostratified epithelium. The third type resembles fetal spermatogonia and are fewer in number. These structures contain eosinophilic, periodic acid–Schiff-positive material, similar to Call–Exner bodies (Fig. 12-39). There may be continuity between these structures and normal seminiferous tubules. The differential diagnosis includes conditions

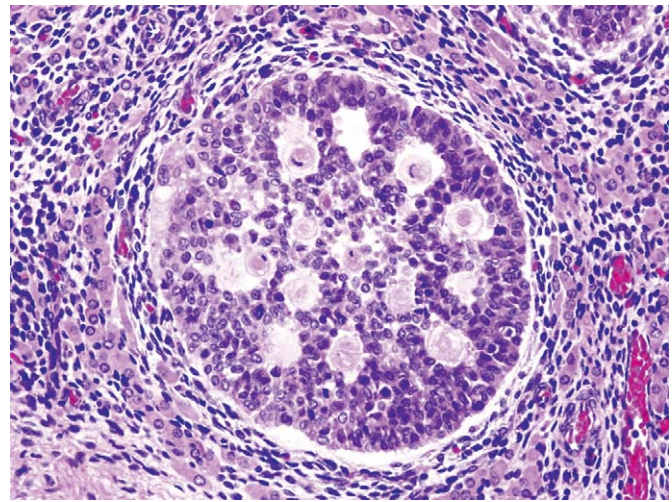


Fig. 12-39 Gonadoblastoid testicular dysplasia. A nodule contains numerous Sertoli-like cells, Call–Exner bodies, and isolated germ cells. The nodule is surrounded by two cell layers: fusiform cells (inner layer) and Leydig cells (outer layer).

showing anomalous seminiferous tubules at the gonadal periphery, including testicular dysgenesis and gonadoblastoma. Testicular dysgenesis also presents tubular or cord-like structures, but these are differentiated (some form true seminiferous tubules) and may also be present within a poorly collagenized tunica albuginea; patients with testicular dysgenesis are male pseudohermaphrodites with müllerian remnants. Gonadoblastoma usually appears in a streak gonad or dysgenetic gonad and contains granulosa–Sertoli cells and germ cells that are similar to those of dysgerminoma or seminoma; these cells are absent in gonadoblastoid testicular dysplasia. Several cases with this disorder have been reported in patients with Walker–Warburg syndrome.^{457,458}

Sertoli cell nodule (hypoplastic zones or dysgenetic tubules)

This disorder refers to the presence, in an adult testis, of one or several foci of infantile (immature) seminiferous tubules. Each group of tubules appears well delimited but unencapsulated. Nodule size varies from microscopic to 5 mm. On section, each nodule is distinguished by its whitish color. Sertoli cell nodule is found in most adult cryptorchid testes, regardless of when the testes descended. It is also present in 22% of normal scrotal testes in some series,⁴⁵⁹ and is an occasional finding in males with idiopathic infertility.

The seminiferous tubules have a prepubertal diameter and may be anastomotic. The epithelium is columnar or pseudostratified, devoid of lumina, and usually consists only of Sertoli cells (Fig. 12-40). The cells have elongated hyperchromatic nuclei with one or several peripherally placed small nucleoli.⁴⁵⁹ The interstitium varies from scant to well collagenized. Leydig cells are usually absent in these areas and, if present, their numbers are low. Study of serial sections reveals continuity between some of these tubules and normal tubules. Sertoli cell nodule changes with advancing age. The Sertoli cells produce large amounts of basal lamina

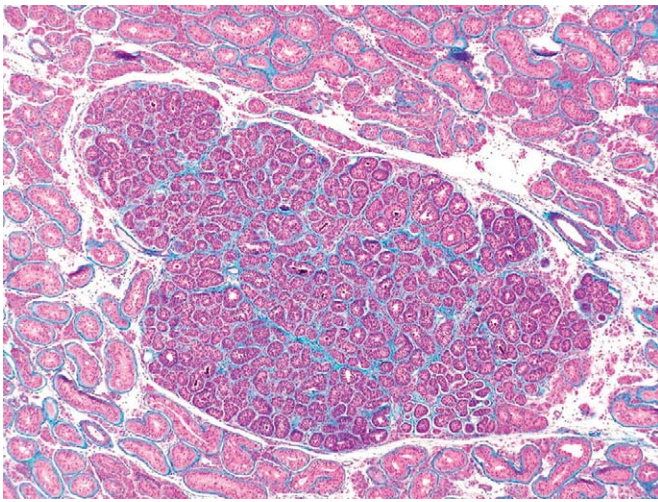


Fig. 12-40 Sertoli cell nodule. This adult cryptorchid testis contains compact groups of small seminiferous tubules with pseudostratified cell layers without lumina.

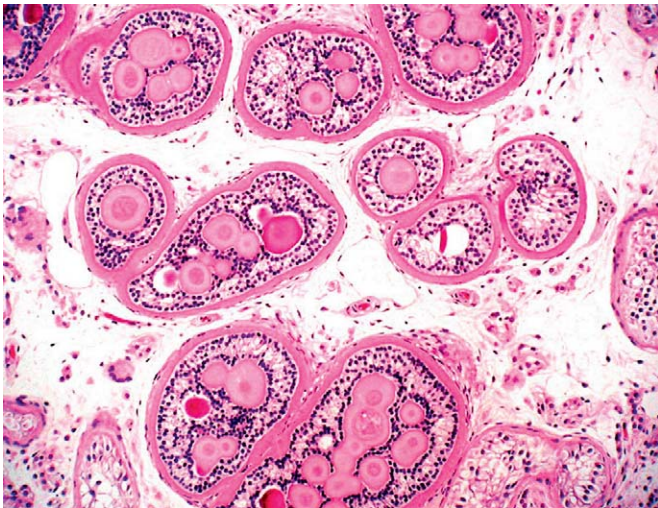


Fig. 12-41 Sertoli cell nodule. Sertoli cell-produced material, similar to the basal lamina material, forms fingerlike protrusions inside the hypoplastic tubules. The Sertoli cells are arranged in a ring around this material.

that protrudes inside the hypoplastic tubules. In transverse and oblique sections, these protrusions might be misinterpreted as intratubular accumulations of basal lamina material (Fig. 12-41). This material can undergo calcification to form microliths. Immunohistochemical study reveals two basic components of the basal lamina (collagen IV and laminin), confirming its extracellular origin; the protrusions consist mainly of laminin, whereas collagen IV delimits the outer profile of the seminiferous tubules. So, while the amount of collagen IV is uniform around the tubules, the depth of laminin varies within the same tubule.

Tubular hypoplasia is assumed to be a primary testicular lesion, and refers to the presence of seminiferous tubules that are unable to undergo pubertal development despite the same hormonal stimuli of adjacent normal tubules. This

dysgenesis includes immature Sertoli cell pattern, low inhibin secretion, absence of androgen receptors,⁴⁶⁰ and lack of maturation of peritubular myoid cells that fail to synthesize elastic fibers. The presence of hypoplastic zones in a testicular biopsy is an adverse prognostic sign for fertility.

The differential diagnosis includes tubular hamartoma in androgen insensitivity syndrome, sex cord tumor with annular tubules, and mixed atrophy of the testis. Tubular hamartoma in androgen insensitivity syndrome is multiple, similar to the hypoplastic zones of tubular hypoplasia; however, the Sertoli-like cells of hamartoma have spherical nuclei (rather of elongated nuclei), form a cuboidal epithelium, and contain numerous Leydig cells among the tubules (see Androgen insensitivity syndrome, below). Sex cord tumor with annular tubules may present with multiple foci of intratubular neoplasia, similar in distribution to that of hypoplastic zones; however, sex cord tumor appears in undescended testes, and in patients with Peutz–Jeghers syndrome, and consists of cuboidal or spherical cells that express cytokeratins that are not expressed in hypoplastic tubules.

It is possible that hypoplastic tubules contain some germ cells that may be spermatogonia or gonocytes. There are scant spermatogonia that fail to display signs of maturation or proliferation. Also, some of the tubules contain intratubular undifferentiated germ cell neoplasia that usually also appears in the adjacent, non-hypoplastic seminiferous tubules. The histologic picture is similar to that of gonadoblastoma, but such a tumor can be easily excluded because it arises in malformed gonads (gonadal dysgenesis and testicular dysgenesis) characteristic of intersex stages, unlike patients with tubular hypoplasia.

Congenital testicular lymphangiectasis

Congenital testicular lymphangiectasis is characterized by abnormal and excessive development of lymphatic vessels in the tunica albuginea, mediastinum testis, interlobular septa, and testicular interstitium.^{461–463} Ultrastructurally these dilated vessels are similar to normal lymphatic capillaries, although some are markedly dilated and the testicular interstitium is slightly edematous (Fig. 12-42). Testicular lymphangiectasis occurs in both cryptorchid and scrotal testes; in one of the latter cases, the patient had Noonan's syndrome. The disease does not seem to affect the seminiferous tubules, and low numbers of spermatogonia and reduced tubular diameters are observed only in cryptorchid testes. The epididymis and spermatic cord are not affected, and congenital testicular lymphangiectasis is not associated with pulmonary, intestinal, or systemic lymphangiectasis. During fetal life, lymphatic vessels are visible only immediately beneath the tunica albuginea and in the interlobular septa.⁴⁶⁴ During childhood, the number and size of the septal lymphatic vessels decreases,⁴⁶⁵ by adulthood they are inconspicuous.⁴⁶⁶ In lymphangiectasis, the septal lymphatic vessels are large and often massively dilated. Testicular lymphangiectasis occurs only in the childhood testis, suggesting that these dilated vessels undergo involution at puberty or that pubertal development of the seminiferous tubules masks the lymphangiectasis. One exceptional case of epididymal lymphangiectasis, with dilated epididymal blood vessels,

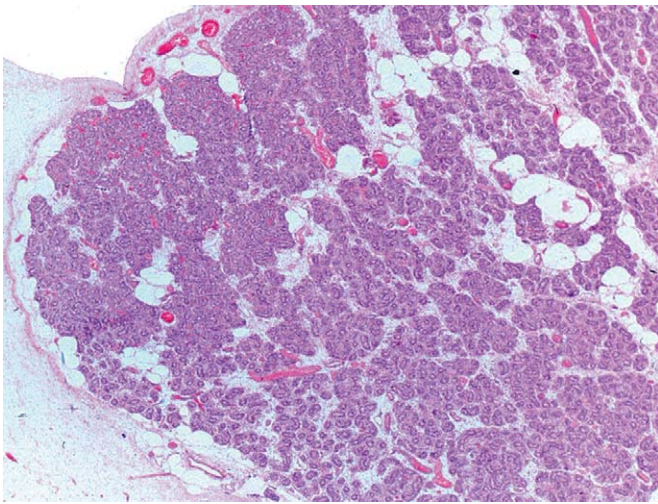


Fig. 12-42 Congenital testicular lymphangiectasis. Ectatic lymphatic vessels are seen in the tunica vasculosa and interlobular septa, as well as among the seminiferous tubules, causing compression.

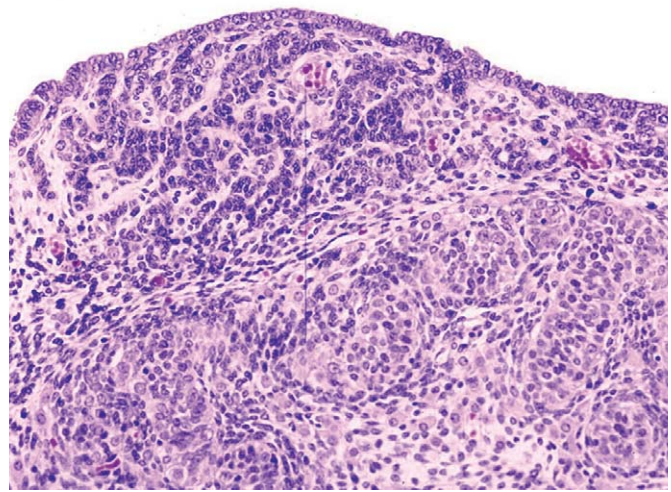


Fig. 12-44 Persistent testicular blastema in a newborn. The blastema forms anastomosing cord-like formations which connect to the superficial cells. Several gonocytes are observed at the periphery of the blastema.

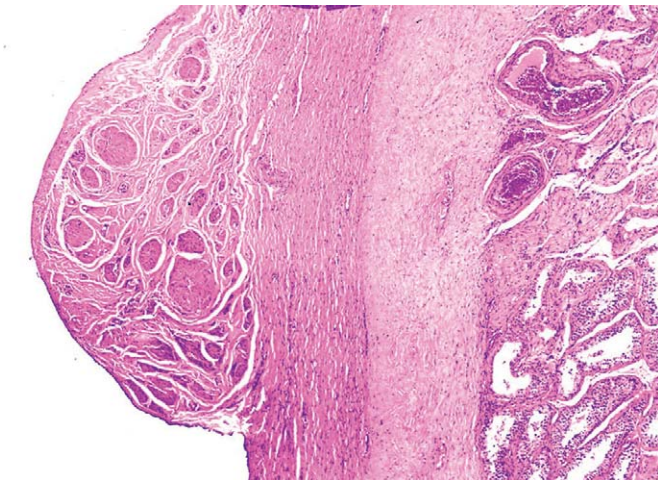


Fig. 12-43 Smooth muscle hamartoma within enlarged tunica albuginea.

was reported in a 59-year-old man.⁴⁶⁷ The vessels distort the architecture of the ductuli efferentes, which in turn become irregularly dilated by mechanical compression.

Other hamartomatous testicular lesions

Other hamartomas of the testis include hamartoma of the rete testis and smooth muscle hamartoma. Hamartoma of the rete testis is a disordered proliferation of tubular structures in a loose connective tissue.⁴⁶⁸ Cystic transformation of the rete testis associated with proliferation of smooth muscle cells and abundant myxoid stroma was reported in a 26-year-old man.⁴⁶⁹

Smooth muscle hamartoma is located in the inferior testicular pole, the cauda of the epididymis, and the proximal segment of the vas deferens (Fig. 12-43),⁴⁷⁰ and is similar to that reported in the digestive and respiratory tracts.^{471,472} Smooth muscle hyperplasia also occurs in the androgen insensitivity syndrome, forming nodules up to 1 cm in

diameter. The muscular proliferation is located in the lower testicular pole, and involves the tunica albuginea and adjacent soft tissues.

Testicular ectopia

Gonadal blastema ectopia

This infrequent finding has been observed in newborns and consists of gonadal blastema in otherwise normal testes. The blastema is located in the vicinity of the upper testicular pole, near the implantation of the caput of the epididymis, displays a crescent shape, and extends throughout the depth of the tunica albuginea and the adjacent testicular parenchyma.

The blastema consists of epithelial cords of cells or solid masses in continuity with the mesothelium (Fig. 12-44). These cells are intermingled with others that are larger, with pale cytoplasm, vesicular nuclei, and prominent nucleoli. The blastematous epithelial cells display immunoreactivity for vimentin, laminin, type IV collagen, and cytokeratin; the expression of the latter in the most superficial cells is similar to that of mesothelial cells and decreases in intensity in the deeper cells. This suggests that these may be pre-Sertoli cells. The cord-like structures are delimited by laminin and type IV collagen. The second larger cell type is immunoreactive for placenta-like alkaline phosphatase (PLAP) on the surface, suggesting that it is related to the gonocyte. Leydig cells have not been observed among the cords of gonadal blastema.

The differential diagnosis of gonadal blastema ectopia is with ovotestes. The small size of the gonocytes distinguishes them from oocytes, which are several times larger. In addition, no intersex condition is observed.

Seminiferous tubule ectopia

The presence of seminiferous tubules within the tunica albuginea is rare and usually an incidental histologic finding.⁴⁷³ Ectopic tubules are present in approximately 0.8% of pediatric autopsies and 0.3% of adult autopsies. The lower inci-

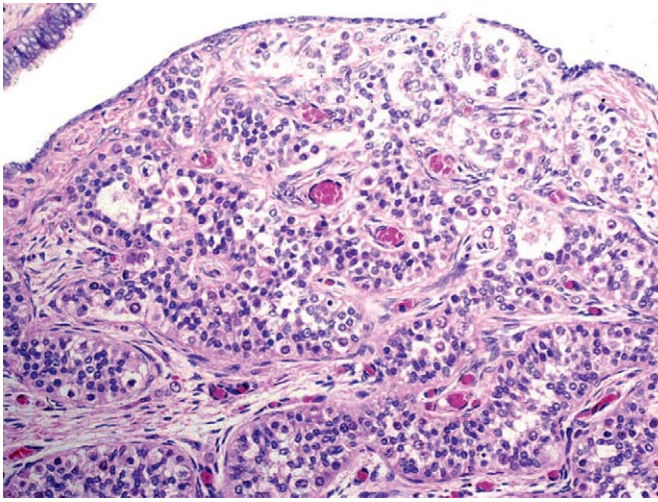


Fig. 12-45 Testis from 2-month-old infant showing ectopic seminiferous tubules within the tunica albuginea in the upper testicular pole.

dence in adults may be explained by proportionally less sampling. The lesion ranges from microscopic size to a few millimeters in diameter, and may be visible as minute bulges in which multiple small vesicles protrude through a thin tunica albuginea.⁴⁷⁴ Histologically there are groups of seminiferous tubules in the tunica albuginea, sometimes accompanied by Leydig cells. In children, the ectopic tubules appear normal (Fig. 12-45), whereas in adults they are usually slightly dilated, although some may be hyalinized. Serial sections reveal continuity with the intraparenchymatous seminiferous tubules.

Ectopia of the seminiferous tubule is probably congenital, although it has been found in elderly men.⁴⁷⁵ It does not appear to be the result of trauma. The malformation probably arises in the sixth week of gestation, when the primordial sex cords have formed and are branching toward the gonadal surface, and the developing testes is covered by only one to three layers of celomic epithelium. Later, the tunica albuginea forms around the sex cords and under the celomic epithelium. Failure of insertion of the tunica albuginea between the sex cords and celomic epithelium may entrap seminiferous tubules.

Ectopia differs from testicular dysgenesis, a distinctive form of male pseudohermaphroditism with müllerian remnants. Numerous features, characteristic of ectopic seminiferous tubules, distinguish it from other conditions, including normal thickness and collagenization of the tunica albuginea, absence of interstitial tissue resembling ovarian stroma (characteristic of testicular dysgenesis), and clear delimitation of the tunica albuginea and testicular parenchyma (see discussion on male pseudohermaphroditism with müllerian remnants, below).

In a unique case, there were multiple clusters of seminiferous tubules in the wall of a hernia sac that accompanied an undescended testis removed from an adult man. The ectopic tubules were not surrounded by tunica albuginea and were similar to those in cryptorchid testicular parenchyma with only dysgenetic Sertoli cells.

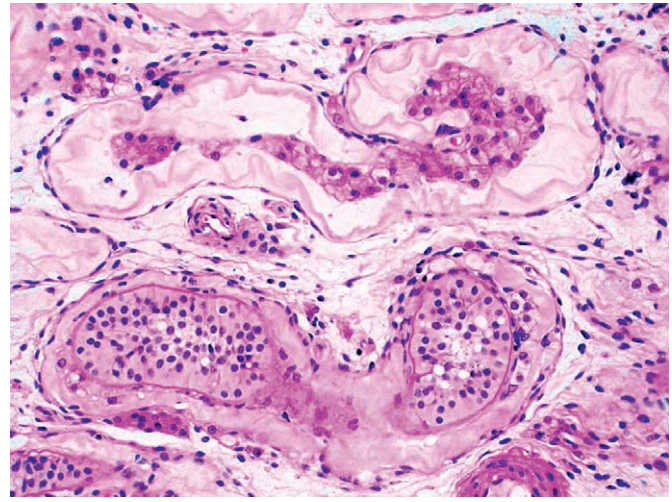


Fig. 12-46 Ectopic Leydig cells inside a hyalinized seminiferous tubule. This picture contrasts with that of dysgenetic Sertoli-cell-only tubule, which shows a patent basal membrane located between the dysgenetic Sertoli cells and the tubular wall.

Leydig cell ectopia

Leydig cells occur normally in the testicular interstitium (interstitial Leydig cells) and in the wall of the seminiferous tubules (peritubular Leydig cells). However, clusters of Leydig cells are often observed in other locations in the testis, or in the epididymis or spermatic cord.⁴⁷⁶

Ectopic Leydig cells may be found in the interlobular septa,⁴⁷⁷⁻⁴⁷⁹ rete testis, tunica albuginea,⁴⁸⁰⁻⁴⁸² or within hyalinized seminiferous tubules.^{478,483-485} Intratubular Leydig cells are found only in tubules with advanced atrophy and marked thickening of the tunica propria, including the tubules in adult cryptorchid testes, those of men with Klinefelter's syndrome, and in some other primary hypogonadisms (Fig. 12-46). Immunohistochemical studies suggest that the endocrine function of these Leydig cells is low.⁴⁸⁶ Several theories have been offered to account for these ectopic cells, including in situ differentiation, migration from the testicular interstitium, and trapping of peritubular Leydig cells in the tunica propria during its thickening.⁴⁸⁷ Leydig cells are commonly found in the epididymis⁴⁸⁷ and spermatic cord;^{488,489} 26 of 64 autopsies had such foci.⁴⁹⁰ Extratesticular Leydig cells usually form small groups within or adjacent to nerves (Fig. 12-47).^{477,490}

The occurrence of ectopic Leydig cells in the albuginea, epididymis, or spermatic cord may account for the rare cases of Leydig cell tumor in these paratesticular structures. Ectopic Leydig cells should not be misinterpreted as tumor cells (infiltration or metastasis) when malignancy of a testicular Leydig cell tumor is suspected.

Other ectopias

Other rare forms of ectopia are found within and outside the testis. Intratesticular ectopia includes adrenal cortical ectopia, osseous and adipose tissue heterotopia, and ectopia of the ductus epididymidis. Extratesticular ectopia includes splenic ectopia (splenogonadal fusion), hepatic ectopia (hepatotes-

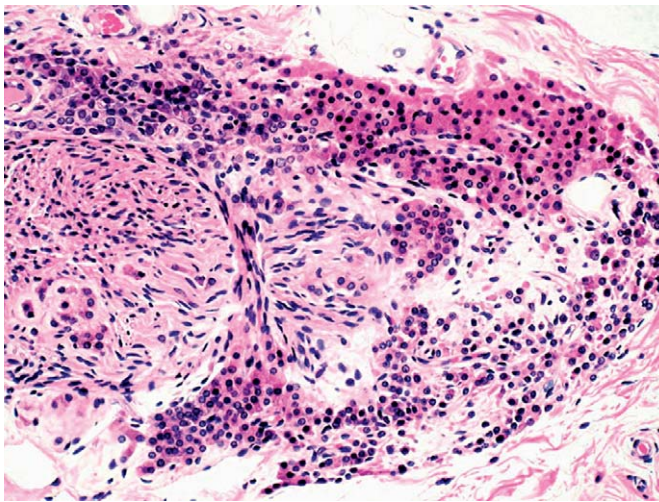


Fig. 12-47 Ectopic Leydig cells around and inside a spermatic cord nerve.

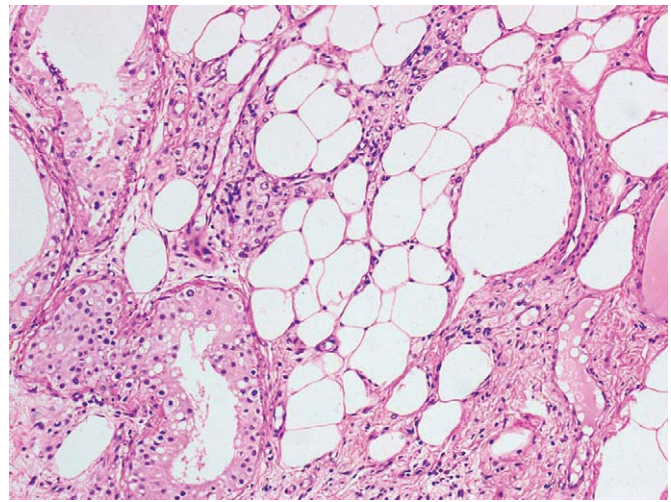


Fig. 12-48 Adult cryptorchid testis showing metaplastic fat cells between the seminiferous tubules and the rete testis.

ticular fusion), and renal blastema ectopia (see discussion in Chapter 12).

Adrenal cortical ectopia may be important in two conditions that develop tumoral masses: adrenogenital syndrome and Nelson's syndrome. Tumors in adrenogenital syndrome appear in 8.2% of patients with congenital adrenal hyperplasia, appearing as bilateral testicular masses of synchronous growth. These tumors consist of well delimited but non-encapsulated yellow nodules, several centimeters long, composed of large microvacuolated cells. The cause seems to be prolonged stimulation by elevated ACTH secretion. The differential diagnosis includes Leydig cell tumor. The diagnosis of tumors in adrenogenital syndrome is supported by a family or personal history of salt-lost syndrome or hypertension, demonstration of 11 β -hydroxysteroids (a specific marker for adrenal cortex) in spermatic vein blood, or a rapid positive response of tumor to corticoid treatment. Nelson's syndrome occurs in patients who, after adrenalectomy for treatment of Cushing's syndrome, develop an ACTH-secreting pituitary adenoma. These patients may develop testicular tumor growth similar to that in adrenogenital syndrome. Most Nelson's syndrome tumors do not respond to dexamethasone treatment.

Cartilaginous heterotopia may be found in the caput of the epididymis and has been attributed to metaplasia of metanephric rests. Osseous heterotopia (testicular osteoma) is a metaplasia occurring in areas of the testicular parenchyma with fibrosis or ischemia.⁴⁹¹ Adipose metaplasia is frequent in undescended testis, elderly men, and those with Cowden's syndrome (Fig. 12-48).⁴⁹² Groups of tubular formations that resembles the epididymis have been reported inside the testicular parenchyma in testes with marked tubular atrophy, and probably represent a rare form of metaplasia.⁴⁹³

Undescended testes

Testicular descent is not always complete at birth, and about 3.2% of full-term newborns have incompletely descended

testes. Most of these descend within 3 months, and only 0.8% of infants have incompletely descended testes 12 months after birth. Spontaneous testicular descent is exceptional after the first year. In recent decades, a significant increase in the incidence of cryptorchidism has been detected.⁴⁹⁴

Only 5% of patients with impalpable testes are actually devoid of testes. Other causes include true cryptorchidism, testicular ectopia, and retractile testes. True cryptorchidism includes abdominal, inguinal, and high scrotal testes that cannot be moved to the scrotum. Ectopic testes are those located out of the normal path of testicular descent; the most frequent site is the superficial inguinal pouch. Other rare locations of ectopia include the abdominal wall, the upper thigh, the perineum, and the base of the penis. Retractable testes may be moved to the scrotum at exploration and account for about one third of undescended testes.

True cryptorchidism

Patients with true cryptorchidism account for about 25% of cases of empty scrotum. These testes most frequently are found in the inguinal canal or upper scrotum; arrest within the abdomen is less frequent. Cryptorchidism is slightly more frequent on the right than the left, and in approximately 18% of cases is bilateral. There is a family history of cryptorchidism in 14% of cases.⁴⁹⁵ The cryptorchid testis is usually smaller than the contralateral one, and this difference is often discernible at 6 months of age.⁴⁹⁶ One-third of cryptorchid testes are soft.

Etiology

Several conditions are predictive of high risk of cryptorchidism, including increased maternal age, maternal obesity, pregnancy toxemia, bleeding during late pregnancy, and smoking, tallness, subfertility antecedents, cesarean birth, low birthweight, preterm newborn, twin birth, hypospadias⁴⁹⁷ and other congenital malformations, and children born from September to November, and in May and

June.^{498,499} Of these associations, low birth weight seems to be the most important.⁵⁰⁰

There are two types of cryptorchidism: congenital and acquired.

Congenital cryptorchidism

This cryptorchidism is caused by anomalies in anatomic development or hormonal mechanisms involved in testicular descent (described above). Impalpable undescended testes are infrequent because the transabdominal phase follows the simple mechanism of relative movement of the testis, whereas displacement of the ovary is more complex.⁵⁰¹ Conversely, palpable undescended testes are more frequent because the second phase of testicular descent is more complex. Unilateral cryptorchidism may be caused by androgen failure, which leads to either an ipsilateral lesion in the development of genitofemoral nerve neurons or a defect in CGRP release that hinders normal migration of the gubernaculum.

Acquired cryptorchidism

A normally descended testis may become cryptorchid and locate even in the abdominal cavity. Two categories of acquired undescended testis have been described.

The *postoperative trapped testis*⁵⁰² is a normally descended testis that leaves the scrotal pouch after surgery owing to an inguinal hernia or hydrocele.^{503–505} This iatrogenic cryptorchidism occurs in 1.2% of children after herniotomy. Adherence of the testis or the cremasteric muscle to the surgical incision causes testicular ascent when the incision heals and undergoes retraction.

Spontaneous ascent from unknown causes. Various mechanisms have been proposed, including inability of the spermatic blood vessels to grow adequately,⁵⁰⁶ anomalous insertion of the gubernaculum,⁵⁰⁷ failure in reabsorption of the vaginal process^{508,509} and failure in postnatal elongation of the spermatic cord.^{510,511} The spermatic cord measures 4–5 cm at birth and reaches 8–10 cm at 10 years of age. This growth does not occur if the peritoneal–vaginal duct has become a fibrous remnant. The cause might be a defect in postnatal CGRP release by the genitofemoral nerve.^{501,512,513}

Pathogenesis

The most frequent findings in congenital and acquired cryptorchidism at infancy are decreased germ cell numbers and diminished tubular diameter.^{514,515} There are multiple causes of testicular maldescent, including anatomical anomalies of the gubernaculum testis, hormonal dysfunction (hypogonadotropic hypogonadism), mechanical impairment (insufficient intra-abdominal pressure, short spermatic cord, underdeveloped processus vaginalis), dysgenetic (primary anomaly of the testis), and heredity.

Most cryptorchidism appears to be caused by either a deficit of fetal androgens or an excess of maternal estrogens. Androgen insufficiency seems to be slight and transient because anomalies other than hypoplasia of the epididymis are not seen. Elevated maternal estrogens level could cause diminution of FSH secretion by the fetal pituitary, inducing low müllerian-inhibiting hormone production that would hinder testicular descent.⁵¹⁶

Three mechanisms seem to be involved in the process:

- *Primary testicular anomaly.* Cryptorchid testes may bear an anomalous germ cell population, as suggested many years ago.⁵¹⁷ More than 40% of cryptorchid patients have a marked decrease in the tubular fertility index,⁵¹⁸ even with nearly normal numbers of spermatogonia; these cells also have abnormal DNA content.⁵¹⁹
- *Lesions secondary to transient perinatal hypogonadotropic hypogonadism.* Cryptorchid patients do not have gonadotropin elevation, which normally occurs between 60 and 90 days after birth, and this deficiency of LH could cause Leydig cell involution. The subsequent androgen deficiency could account for failure of gonocytes to differentiate into spermatogonia.^{520–522}
- *Injury caused by increased temperature.* This was suggested in the past on the basis of experimental studies in laboratory animals. In follow-up biopsies from testes that were descended surgically or with hormonal treatment, the sole parameter that improved during childhood was tubular diameter. Because this depends on Sertoli cells, it may be that temperature is more important for Sertoli cells than for spermatogonia.⁵¹⁸

In the normal testis there is transient formation of spermatocytes at 4–5 years of age. This meiotic attempt is probably an androgenic event that does not occur in cryptorchid testes and agrees with the characteristic low numbers of spermatogonia in the prepubertal age.⁵²³

Histology of cryptorchid testes

Prepubertal testes Undescended testes are usually smaller than the contralateral ones. This difference is already significant at 6 months of age.^{524,525} Although there have been a number of biopsy studies in the first years of life, there is no agreement about the severity of damage or the time of its onset.^{523,526,527} Based on the tubular fertility index (TFI) and mean tubular diameter (MTD), most testicular biopsies from cryptorchid testes of children can be classified into one of three groups:

- *Type I (testes with slight alterations).* The tubular fertility index is higher than 50, and the mean tubular diameter is normal or slightly (<10%) decreased. Approximately 31% of cryptorchid testes are in this group (Fig. 12-49).
- *Type II (testes with marked germinal hypoplasia).* Tubular fertility index is between 30 and 50, and mean tubular diameter is 10–30% lower than normal. The spermatogonia are distributed irregularly and most are in tubular sections that are grouped in the same testicular lobule. These testes comprise approximately 29% of cryptorchid testes (Fig. 12-50).⁵²⁸
- *Type III (testes with severe germinal hypoplasia).* Tubular fertility index is less than 30, and mean tubular diameter less than 30% of normal. Many of the spermatogonia are giant with dark nuclei (Fig. 12-51). These testes often contain ring-shaped tubules,

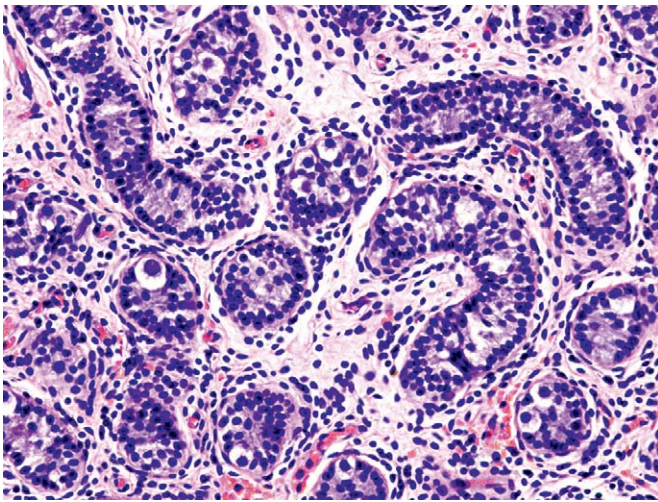


Fig. 12-49 Cryptorchidism. Seminiferous tubules with type I lesions show slightly decreased diameters and a normal tubular fertility index.

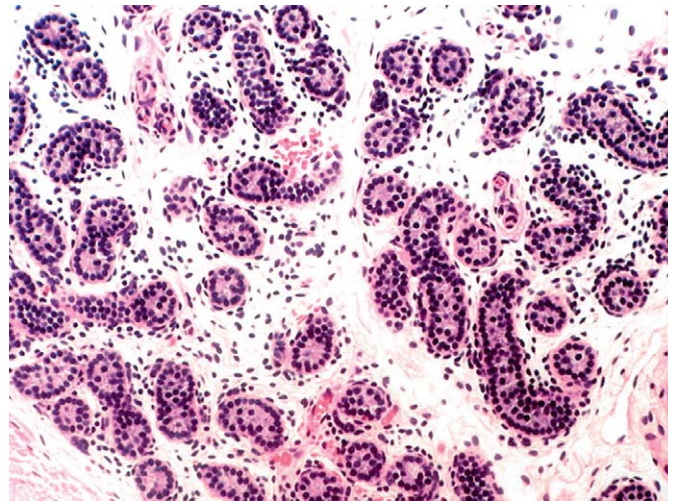


Fig. 12-51 Cryptorchidism. Seminiferous tubules with type III lesions show severe reduction in both tubular diameter and tubular fertility index.

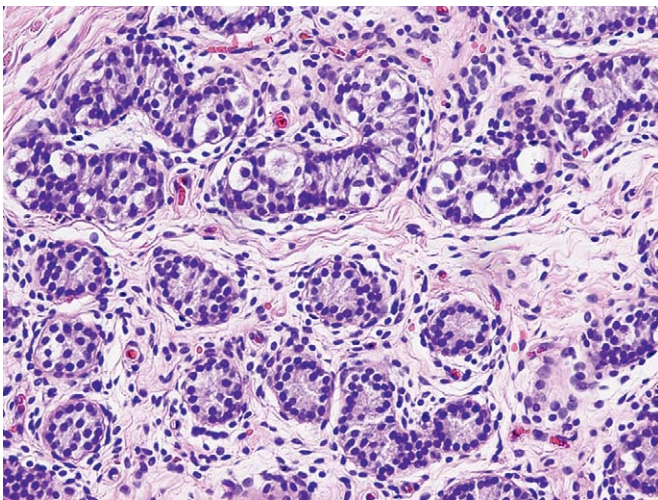


Fig. 12-50 Cryptorchidism. Seminiferous tubules with type II lesions show markedly decreased diameters and an irregular distribution of germ cells.

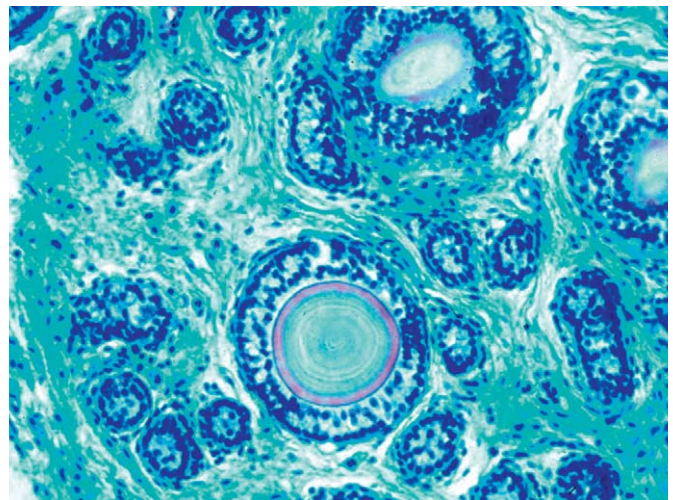


Fig. 12-52 Microlithiasis in an infant cryptorchid testis. The seminiferous tubules show type III lesions and contain numerous microliths.

megatubules (with or without eosinophilic bodies or microliths) (Fig. 12-52), and focal granular changes in the Sertoli cells (Fig. 12-53). The testicular interstitium is wide and edematous. These comprise about 40% of cryptorchid testes.

About 8% of tests with type I lesions show many multinucleated spermatogonia (with three or more nuclei) (Fig. 12-54).⁵²⁹ The seminiferous tubules of testes with types II or III lesions have a thickened lamina propria during childhood and, at puberty, Sertoli cell hyperplasia.⁵²⁶ Patients with bilateral cryptorchidism have a higher incidence of type II and III lesions than those with unilateral cryptorchidism.

Type I lesions are comparable to those seen in experimental cryptorchidism; normal testes in which lesions were

induced by increased temperature.⁵²⁷ Testes with type II or III lesions bear variable degrees of dysgenesis that, in addition to germ cells, involve Sertoli cells, peritubular myofibroblasts, and Leydig cells. The dysgenesis of these other cell types is evident only after puberty. In about 25% of cases the contralateral scrotal testis also has histologic lesions of variable severity. This finding supports the hypothesis of a bilateral defect in many cases of unilateral cryptorchidism. Microdeletions in the long arm of the Y chromosome are present in 27% of patients with corrected unilateral cryptorchidism who present with azoospermia or severe oligospermia.⁵³⁰ These findings are similar to those observed in patients with azoospermia or severe idiopathic oligospermia. Unilateral cryptorchidism with a normal contralateral testis could be due to an end-organ failure.⁵³¹ In cryptorchidism secondary to spontaneous ascent, lesions are similar to

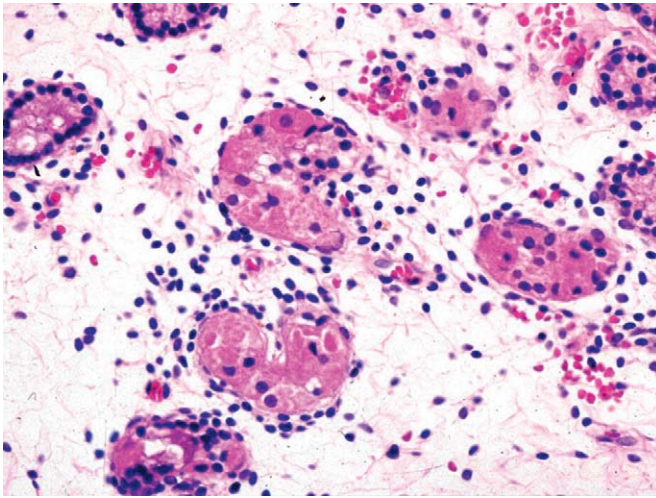


Fig. 12-53 Cryptorchidism. Type III lesions, in which the interstitium is expanded by edema. The cytoplasm of the Sertoli cells contains numerous eosinophilic granules of variable size.

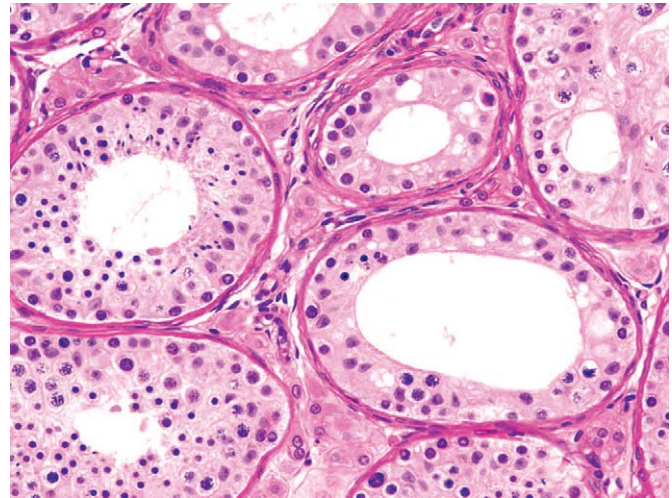


Fig. 12-55 Adult ex-cryptorchid testis which was surgically descended at the age of 2 years. Tubular sections show a pattern varying from spermatogonial maturation arrest to complete, although decreased, spermatogenesis.

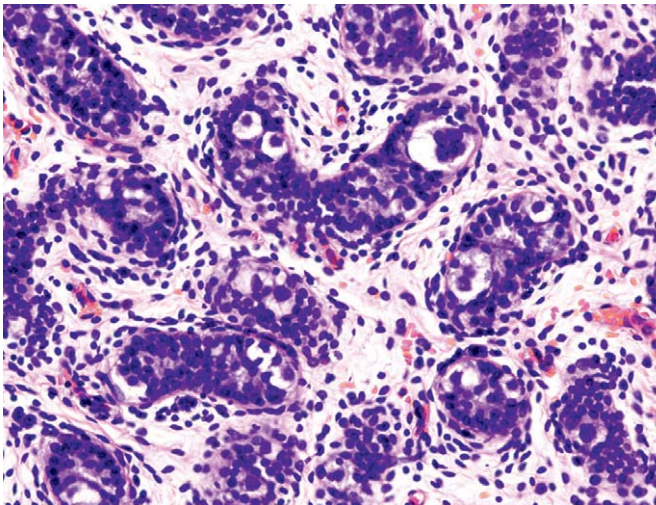


Fig. 12-54 Prepubertal cryptorchid testis. The seminiferous tubules have Sertoli cells with elongated nuclei, pseudostratified growth pattern, and isolated spermatogonia, some of which are multinucleate or contain hypertrophic nuclei.

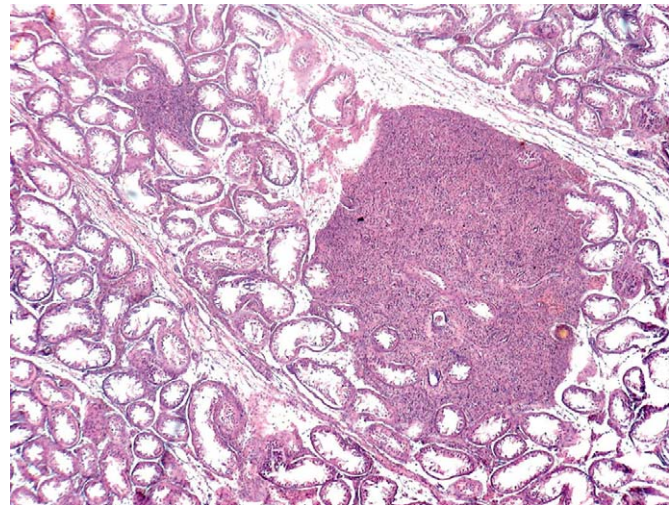


Fig. 12-56 Nodular Leydig cell hyperplasia in an adult ex-cryptorchid testis.

those of congenital cryptorchidism, whereas in cryptorchidism secondary to herniotomy, germ cell depletion is slight⁵³² and becomes important only after 5 years of age.⁵³³

Adult testes Most pubertal and adult cryptorchid testes have anomalies in all testicular structures. The seminiferous tubules have decreased diameters and deficient spermatogenesis. In decreasing order of frequency, the most common germ cell lesions are tubules with Sertoli cell and spermatogonia-only pattern; tubules with Sertoli cells (dysgenetic) only; tubular hyalinization; and mixed atrophy. The lamina propria has scant elastic fibers and increased collagen fibers.⁵³⁴ Sertoli cells are present in increased numbers and do not mature normally except in tubules with germ cells (Fig. 12-55).^{528,535} Often, groups of tubules containing only

Sertoli cells with a prepubertal pattern (very small diameter and total absence of maturation) are present and are considered hypoplastic, dysgenetic, or hamartomatous. Areas of apparent Leydig cell hyperplasia are frequent, and many of these cells contain vacuolated lipid-laden cytoplasm (Fig. 12-56).

The rete testis is hypoplastic in most cases and is lined by columnar epithelium with rare areas of flattened cells. Cystic dilation is common, and adenomatous hyperplasia has been found in some cases. Near the rete testis, the testicular parenchyma frequently contains metaplastic fat. In some cryptorchid testes, several tubular segments are destroyed by inflammation that probably has an autoimmune cause (focal orchitis).⁵³⁶ Epididymal tubules are poorly developed and peritubular tissue is immature.

Blood flow is associated with testicular histology. For example, testicular volume, histologic pattern, and testicular

artery resistive index are lower in undescended testes than in controls, and testicular artery resistive index is inversely proportional to testicular histology score in undescended testes.⁵³⁷ There is also an apparent correlation between testicular size, spermiogram, and hormone levels. Assuming that a significant reduction in testicular size (>12 mL) is only observed in 9.3% of cases, and that serum levels of FSH, LH, and testosterone are normal, an inverse correlation is seen between FSH and testicular volume, sperm concentration, sperm motility, and normally shaped sperm. In addition, there is a direct relation between testicular volume and sperm concentration, sperm motility, and normally shaped sperm. These findings indicate the cause of tubular impairment in young men operated on in childhood for cryptorchidism.⁵³⁸

Obstructed testes

Obstructed testes are located in the superficial inguinal pouch (Denis–Browne pouch) and are considered ectopic by some authors and cryptorchid by others.^{539,540} Histologic studies reveal that most obstructed testes bear the same lesions as true cryptorchid testes. Type I lesions are observed in half, type II in more than one-third, and the remainder show type III lesions. The higher proportion of type I lesions suggests a better prognosis than in true cryptorchid testes.

Retractile testes

Some authors assume that retractile testes are normal and exclude them from studies of cryptorchidism.^{541,542} However, these testes may present important lesions and many consider them to be a form of cryptorchidism.^{543–545} Retractable testes may not always be movable to the lower scrotum (70–75 mm from the pubic tubercle) and in 50% of cases are smaller than scrotal testes. Approximately 50% of retractile testes remain high after age 6 years, when cremasteric activity declines.⁵⁴⁶ Retractable testes have a 32% risk of becoming ascending or acquired undescended testes. The risk is higher in boys younger than 7 years, or when the spermatic cord is tight or inelastic.⁵⁴⁷ During childhood, tubular diameter and tubular fertility index decrease.⁵⁴⁴ Adults with retractile testes that descended spontaneously but late may be fertile⁵⁴⁸ or infertile.⁵⁴⁹ Usually there is germ cell atrophy that varies in severity from lobule to lobule.⁵⁴⁴ Regular examination of retractile testes is advisable during childhood and, if complete testicular descent does not occur, orchidopexy is indicated.

Congenital anomalies associated with undescended testes

Most cryptorchid patients have a patent processus vaginalis, and 65–75% have a hernia sac, although most hernias are not clinically visible. Urologic anomalies are present in 10.5% of patients, the most frequent being hypospadias, complete duplication of the urinary tract, non-obstructive ureteral dilatation, kidney malrotation, and posterior urethral valves. Cryptorchidism is more frequent in patients with microcephaly, myelomeningocele, bifid spine, omphalocele, gastroschisis, micropenis, and imperforate anus.

Cryptorchidism may appear isolated or associated with congenital anomalies, endocrine dysfunction, chromosomal disorders, or intersex conditions. Thus, cryptorchidism is found in the Kallmann, Prader–Willi, Klinefelter, Noonan, Smith–Lemli–Opitz, Aarskog–Scott, Rubinstein–Taybi, prune belly, and caudal regression syndromes, anomalies of the androgen receptor, absence of anti-müllerian hormone, CHARGE association, and trisomies 13, 18, and 21.

Sperm excretory duct anomalies occur in 9–36% of cryptorchid patients,^{550,551} and are classified into three types:⁵⁵²

- *Ductal fusion anomalies* (25% of cases). These consist of anomalous fusion of the caput of the epididymis to the testis or segmental atresia of the epididymis and vas deferens. This is chiefly associated with intra-abdominal or high scrotal cryptorchid testes.
- *Ductal suspension anomalies* (59% of cases). The caput of the epididymis is attached to the testis, whereas the corpus and the cauda of the epididymis are separated from the testis by a mesentery. A variant consists of an excessively long cauda of the epididymis that descends along the inguinal duct to the scrotum.
- Anomalies associated with absent or vanishing testes (16% of cases).

Cryptorchidism is part of the testicular dysgenesis syndrome. This consists of abnormal testicular development that predisposes to cryptorchidism, hypospadias, spermatogenic alterations, and testicular cancer. The association of these disorders with cryptorchidism has been corroborated by numerous clinical, epidemiological and genetic studies. The least severe form of this syndrome is a defect in spermatogenesis; the most severe is testicular cancer. A constellation of histologic lesions is common in the testes of men with testicular dysgenesis; these lesions include Sertoli cell-only pattern, mixed atrophy, hypoplastic tubules (Sertoli cell nodules), microlithiasis, malformed tubules, granular changes in Sertoli cells, nodular Leydig cell hyperplasia, and intratubular germ cell neoplasia. It is assumed that there is a prenatal development of the lesions as a result of several genetic, environmental, or endocrine disruptor factors that would interfere with the estrogen/androgen ratio.^{553–556}

Complications of cryptorchidism

The main complications of cryptorchidism are testicular cancer, infertility, testicular torsion, and psychological problems.

Testicular cancer

Approximately 0.8% of 1-year-old males have cryptorchidism, and about 10% of testicular cancer patients had cryptorchidism. The risk of testicular cancer in cryptorchid males is four to 10 times higher than that of the general population. Testes with elevated number of multinucleated spermatogonia seem to have a higher risk of cancer and adulthood.⁵⁵⁷ About 5% of biopsies in children contain cells similar to those seen in undifferentiated intratubular germ cell neoplasia, and these cells may evolve toward germ cell tumor (Fig. 12-57).⁵⁵⁸ The most frequent tumor in undescended testes is seminoma.^{559,560} Regardless of timing, orchidopexy does not

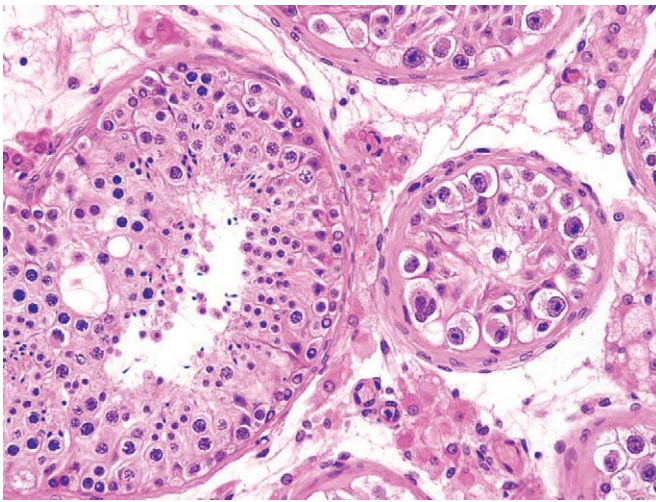


Fig. 12-57 Adult ex-cryptorchid testis which was surgically descended at infancy. The patient was infertile. The smallest seminiferous tubule shows intratubular germ cell neoplasia, undifferentiated type. The relative tumor cell homogeneity contrasts with the variety in shape and size of the cells in the adjacent seminiferous tubule.

reduce the risk of cancer, although it facilitates early detection as the intrascrotal testis is palpable. One in five testicular tumors arises in properly descended testes contralateral to cryptorchid testes, suggesting that there is a primary bilateral testicular anomaly in cryptorchidism. Intra-abdominal testes also have a higher incidence of tumors.⁵⁶⁰

Infertility

Infertility is the most frequent problem caused by cryptorchidism. In a series of patients with infertility, nearly 9% had cryptorchidism.⁵⁶¹ Infertility is influenced by several factors, including bilaterality, number of germ cells, location and size of the testis, and age at time of orchidopexy. The most important risk factors are bilaterality and germ cell number. Only 16%⁵⁶² to 25%⁵⁶³ of men with bilateral cryptorchidism have normal sperm counts (20 million/mL or more). The highest sperm counts occur with testes in the superficial inguinal pouch. Patients with bilaterally impalpable testes are usually azoospermic.⁵⁶³ Fertility rates in unilateral cryptorchidism vary from 25% to 81%.⁵⁶⁴

The number of germ cells per cross-sectioned tubule is the most important prognostic factor. Patients with no increase in inhibin B during the postoperative period usually have a low number of spermatogonia per cross-sectioned tubule and a low tubular fertility index. In unilateral cryptorchidism, fertility depends on the number of spermatogonia in the contralateral testis. However, if the number of germ cells per cross-sectioned tubule in the cryptorchid testis is lower than 1% of normal, the risk of infertility is 33%. In bilateral cryptorchidism the risk of infertility rises from 75% to 100% when one or both testes have less than 1% of germ cells per cross-sectioned tubule. Neither the preoperative location of the testis in patients with unilateral cryptorchidism nor the small size of the testis at the time of orchidopexy is relevant for fertility.^{565–567} An important fertility factor is the permeability of sperm excretory ducts. The age at orchidopexy may

also influence fertility, although this has not been proven. In patients over 4 years of age orchidopexy does not enhance fertility.^{568,569}

Benefit of testicular biopsy in patients with cryptorchidism

Testicular biopsies of infantile testes at orchidopexy are useful for determining baseline germ cell status and whether surgery should be completed with hormonal treatment.⁵⁷⁰ However, even if biopsy supplies important data, it is not considered a routine procedure.

Even in the best cases when the number of spermatogonia is nearly normal, spermatogenesis may never occur owing to deficient spermatogonium development during childhood, failure of spermatogenesis at puberty, and, if complete spermatogenesis occurs, this might be associated with obstruction of sperm excretory ducts.

In childhood, the chance of a biopsy finding an occult cancer or precancer is low because intratubular germ cell neoplasia is not diffusely distributed throughout the testis. Testicular biopsy is recommended in patients with intra-abdominal testes, abnormal external genitalia, or abnormal karyotype.⁵⁷¹ The situation is different in adults because intratubular germ cell neoplasia is present in 2–3% of cases and is diffuse.^{572,573} When intratubular germ cell neoplasia is detected in a child, further examination of the testis and rebiopsy after puberty are recommended.⁵⁷⁴ In adults, if intratubular germ cell neoplasia is unilateral orchidectomy should be performed, but if it is bilateral, radiation may be used to eradicate the neoplasia while maintaining Leydig cell function.⁵⁷⁵

Testicular microlithiasis

Testicular microlithiasis (TM) is characterized by the presence of numerous calcifications diffusely distributed throughout the testicular parenchyma. The number and size of the calcifications often is great enough to be detected radiographically or by ultrasound.⁵⁷⁶ Isolated microliths have been reported in undescended testes, prepubertal Klinefelter's syndrome, male pseudohermaphroditism, and otherwise normal children and patients studied for other diseases.⁵⁷⁷ In adults, microliths are frequently observed in cryptorchid and ex-cryptorchid testes,⁵⁷⁸ seminiferous tubules located at the periphery of germ cell tumor,⁵⁷⁹ infertile patients,^{580–582} and in some patients complaining of orchialgia^{583,584} or testicular asymmetry.⁵⁸⁵

Testicular microlithiasis occurs in 0.3% of cryptorchid testes and is slightly more common in prepubertal than adult testes. In adults, it usually is diagnosed when men seek help for infertility, pain, or testicular asymmetry.⁵⁸¹ Microlithiasis has been observed in 1.4–2% of testicular echographies of different disorders.^{586,587} In infertile patients the incidence is slightly higher. Microlithiasis is present in 35% of testis having a malignant tumor.⁵⁸⁸

Ultrasound studies reveal two types of microlithiasis: classic TM, in which the number of microliths is five or more; and limited TM, when there are fewer than five microliths (Fig. 12-58). The incidences of TM in these studies are lower than 1% in infants, 5.6% in the general population aged between 18 and 35 years (bilateral in 66% of patients

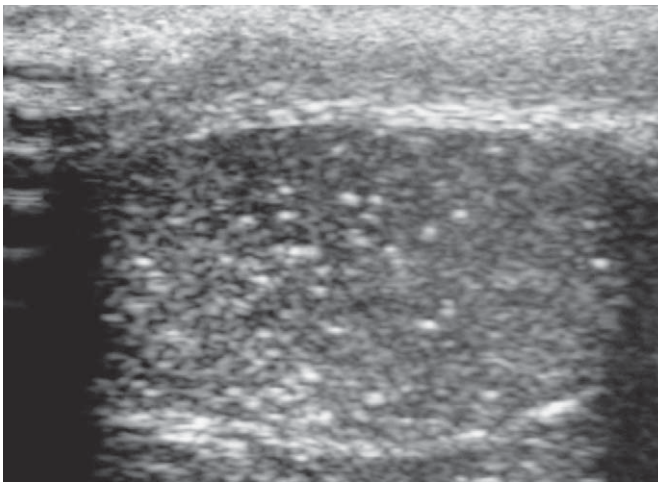


Fig. 12-58 Testicular microlithiasis showing the characteristic 'snowstorm' pattern.

showing microliths,⁵⁸⁹ 0.68–4.1% in patients with other disorders,^{586,587,590–592} from 4.6%⁵⁹³ to 20%⁵⁹⁴ in subfertile patients, 9.52% in ex-cryptorchid testes,⁵⁹⁵ and more than 30% in adult testes with germ cell tumors).^{588,596–599} Several cases of testicular microlithiasis have also been observed in infant testes with germ cell tumor or gonadal stroma tumor.^{600,601} The incidence is higher in whites than in blacks.

Pain is the most common clinical symptom in patients without a palpable testicular mass, and has been attributed to dilation of seminiferous tubules secondary to obstruction by microliths.

Microliths are made by hydroxyapatite, according to X-ray diffraction studies⁶⁰² and Raman spectroscopy.⁶⁰³ In the pre-pubertal testis, microliths are surrounded by a double layer of Sertoli cells and measure up to 300 μm in diameter. When they are very large, the seminiferous epithelium may be destroyed and the microlith is surrounded by peritubular cells (Fig. 12-59). Testes with microliths have subnormal mean tubular diameters and tubular fertility index.⁶⁰⁴ In adult testes with microliths there is incomplete spermatogenesis. Some seminiferous tubules with microliths are cystically dilated (Fig. 12-60). Microliths arise as extratubular eosinophilic bodies that mineralize and pass into the tubular lumina.⁶⁰⁵ Microlithiasis may be a disorder of the tunica propria. Also, testicular microlithiasis is occasionally associated with pulmonary microlithiasis and with calcifications in the parasympathetic nervous system.^{606,607}

The association of microlithiasis and testicular cancer is controversial.^{608,609} Although the development of testicular cancer has been observed in several patients whose testicular microlithiasis had been previously diagnosed by ultrasound studies,^{610–614} it is also thought that patients with testicular microlithiasis not associated with other disorder do not require any follow-up.⁶¹⁵ When microlithiasis is associated with infertility the incidence of cancer varies according to the unilaterality or bilaterality of microlithiasis:⁵⁹⁴ subfertile patients with unilateral microlithiasis show no intratubular germ cell neoplasia, whereas this is present in 20% of those

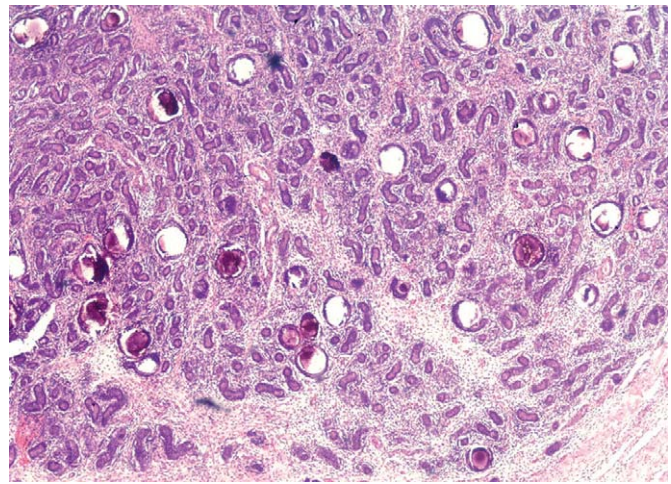


Fig. 12-59 Testicular microlithiasis. Infantile cryptorchid testis with type III lesions and numerous microliths within the seminiferous tubules.

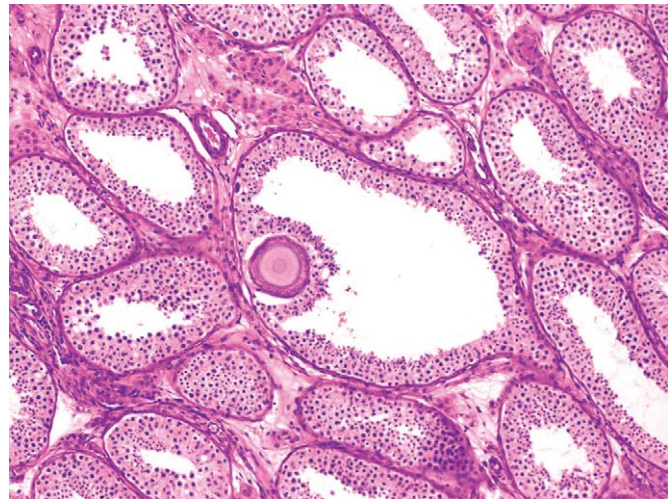


Fig. 12-60 Testicular microlithiasis. Seminiferous tubules with dilated lumina in a patient biopsied for infertility. The central tubule contains a microlith which developed in the tubular wall and protrudes into the lumen.

with bilateral microlithiasis. The risk of malignancy is higher in classic than in limited TM.⁶¹⁶ The nexus between microlithiasis and cancer does not seem to be the predisposition of one disorder towards the other but rather the predisposition of both to develop in abnormal testes. This may also explain the association between microlithiasis and infertility.

Yearly ultrasound examination, perhaps with testicular biopsy, is recommended in those with testicular microlithiasis associated with cryptorchidism, infertility, atrophic testes, or contralateral testis bearing germ cell tumor.⁶¹⁷

Microlithiasis also occurs in the rete testis or sperm excretory ducts. Epididymal rupture and extravasation of microliths into the interductal tissue may cause a histiocytic reaction resembling malakoplakia (Fig. 12-61). The disorder is asymptomatic and not associated with testicular cancer.⁶¹⁸

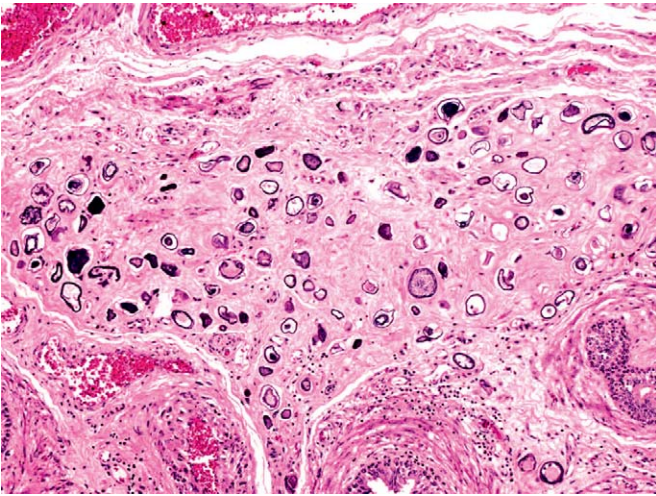


Fig. 12-61 Epididymal microlithiasis. Numerous microliths displaying a psammoma body-like appearance are set in hyalinized stroma.

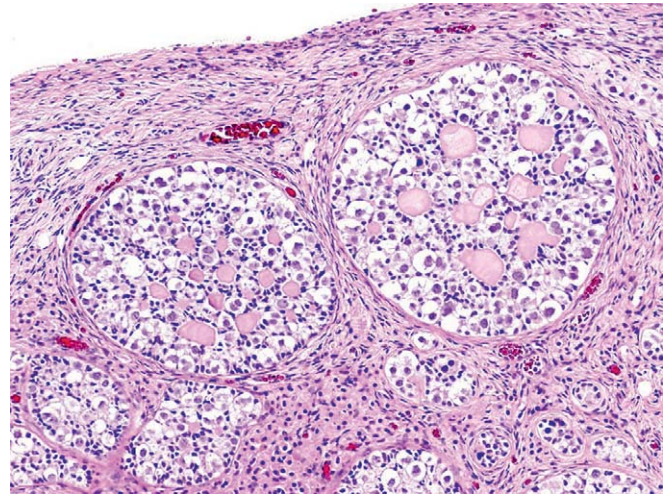


Fig. 12-63 Frasier's syndrome in a 16-year-old patient. The two streak gonads contain gonadoblastoma.

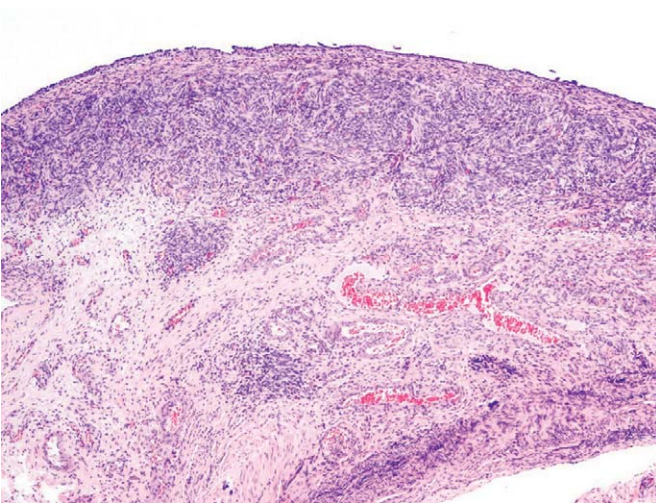


Fig. 12-62 Gonadal dysgenesis. The elongate formation consists of an outer cellular part devoid of ovarian follicles and a central part with numerous blood vessels.

Gonadal dysgenesis

Gonadal dysgenesis refers to disorders characterized by amenorrhea and streak gonads in phenotypically female patients. In adults, streak gonads are elongated masses of fibrous tissue resembling ovarian stroma (Fig. 12-62). They may contain hilar cells and rete or epithelial cords with variable degrees of maturation, and may result from failure in gonad formation, failure of gonadal differentiation to ovary, or failure of gonadal differentiation to testis. Some streak gonads contain a few oocytes or primordial follicles, but all germ cells disappear at puberty. Patients with streak gonads have a hypoplastic uterus and fallopian tubes. Four types of gonadal dysgenesis have been described: 46XY pure, 46XX pure, 45X0, and mixed.

46XY Gonadal dysgenesis

46XY gonadal dysgenesis (Swyer's syndrome) is characterized by female phenotype, absence of Turnerian stigmata, and female external genitalia, sometimes with fused labia majora, a hypertrophic clitoris, and hypospadias. The breasts develop at puberty. Sexual infantilism persists in adulthood, and eunuchoidism and amenorrhea appear. These patients have elevated serum gonadotropin levels and low serum estradiol.

There are two types of gonadal dysgenesis: complete and incomplete. Patients with the complete type have female external genitalia and classic streak gonads, although cases with ovarian tissue have been reported. The cause is unknown in about 80% of cases,⁶¹⁹ and is due to alterations in the SRY gene in the remainder (a mutation in 10–15% of cases, and a SRY deletion as a result of an aberrant X/Y interchange in 10–15%).⁶²⁰ The consequence of failure is very early gonadal alteration (sixth to eighth week of gestation). With the subsequent absence of müllerian inhibiting factor, testosterone, and dihydrotestosterone, a female phenotype develops.

Patients with incomplete 46XY gonadal dysgenesis have ambiguous external genitalia and variable degree of development of the müllerian and wolffian structures. Although they have streak gonads, testicular development is usually observed. This gonadal dysgenesis does not seem to be caused by SRY alterations.⁶²¹ These findings suggest that in the first type ovarian differentiation was canceled, and that in the second type testicular differentiation failed. The first is similar to the gonad of 45X0 Turner's syndrome, whereas the second resembles the gonad of mixed gonadal dysgenesis.⁶²² The clitoromegaly may be caused by androgens secreted by hyperplastic Leydig cells in the streak gonad.

Some patients with 46XY gonadal dysgenesis present with extragonadal anomalies and multiple syndromes, including camptomelic dysplasia and renal disorder,⁶²³ myotonic dystrophy and terminal renal disease,⁶²⁴ progressive renal insufficiency and gonadoblastoma (Frasier's syndrome) (Figs 12-63 and 12-64),^{625–629} mental retardation with⁶³⁰ or

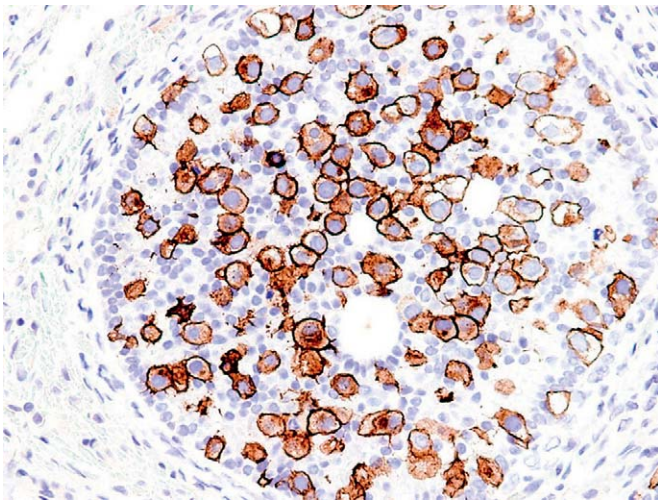


Fig. 12-64 Frasier's syndrome. The cell surface and Golgi zone of the atypical gonadoblastoma germ cells are immunoreactive for *c-kit*.

without⁶³¹ facial anomalies or short stature,⁶³² renal insufficiency and Wilms' tumor (Denys–Drash syndrome), the combination of cleft palate, micrognathia, kyphosis, scoliosis, and clubfoot (Gardner–Silengo–Wachtel syndrome or genitopalatocardiac syndrome),⁶³³ pterygium multiple syndrome,⁶³⁴ Graves' disease,^{635,636} and congenital universalis alopecia, microcephaly, cutis marmorata, and short stature.^{637,638}

Most cases are sporadic,⁶³⁹ although the syndrome has been reported in several members of the same family,^{640–643} and several forms of inheritance (X-linked, autosomal recessive, and male-limited autosomal dominant) have been proposed.⁶⁴⁴ In addition to infertility, patients with 46XY gonadal dysgenesis have a high risk of germ cell tumor. This risk is about 5% in the first decade of life, and 25–30% overall,^{645–648} and, thus, prophylactic gonadectomy is recommended.

46XX Gonadal dysgenesis

Patients with 46XX gonadal dysgenesis have normal stature, female phenotype, well-developed external genitalia, and hypoplastic ovaries rather than streak gonads (Fig. 12-65). The anomaly is usually detected when patients present with primary amenorrhea or infertility. This syndrome is sporadic and familial, and it may be linked to recessive autosomal inheritance.^{649,650} Patients have no predisposition to gonadal neoplasia. Associated somatic anomalies such as neurosensory hearing loss (Perrault's syndrome) are rare.

Some familial cases have shown a balanced translocation of the X chromosome (from the long arm to the short arm)^{651,652} or between chromosomes 1 and 11.⁶⁵³ Because the development of ovarian follicles requires FSH, mutations have been sought in the FSHR gene. Mutations have been detected in familial cases and also in unrelated patients,^{654,655} whereas other patients have shown no mutations in this gene.⁶⁵⁶ The incidence of tumors in these patients is very low, and the most common is dysgerminoma.^{657–659}

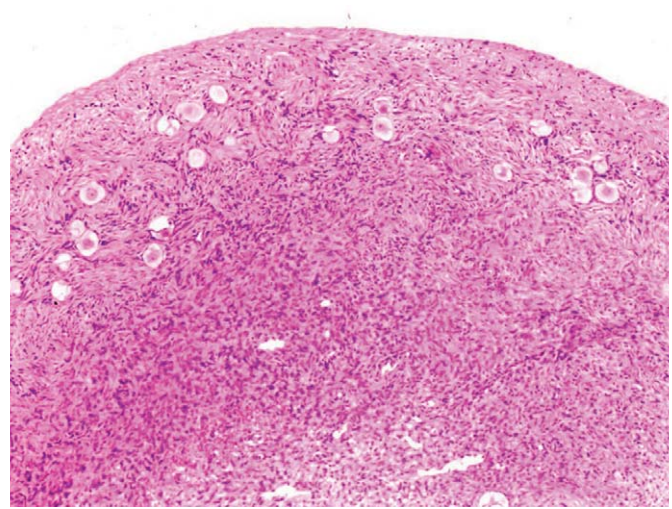


Fig. 12-65 46XX gonadal dysgenesis. The streak gonads contain isolated oocytes.

45XO Gonadal dysgenesis

This is one of the most common chromosomal anomalies (from 1/2500 to 1/5000 in female newborns),⁶⁶⁰ although 99% of zygotes with this karyotype are aborted in the first stages of embryonal development.⁶⁶¹

Patients with 45XO gonadal dysgenesis have characteristic stigmata of Turner's syndrome, including short stature, pterygium coli, lymphedema, and cardiac malformations. The external genitalia are female and infantile; the gonads are typical streak gonads. Today, Turner's syndrome is defined by the combination of physical features and the complete or partial absence of one of both X chromosomes, frequently associated with mosaicism. Turnerian stigmata may be classified into four groups:⁶⁶² skeletal anomalies such as cubitus valgus, shortening of the fourth metacarpal and Madelund's deformity characteristic of Leri–Weill dyschondrosteosis; soft tissue anomalies such as webbed neck, low posterior hair line, and puffy hands and feet; visceral anomalies such as aortic coarctation, horseshoe kidney, polycystic kidney, urethral stenosis and vesicourethral reflux; and miscellaneous anomalies such as nevus pigmentosus.⁶⁶³

During embryonic life, these gonads show normal germ cell numbers up to the third month, when germ cell proliferation ceases.^{665,666} Oogenesis stops in meiosis I, usually before the pachytene stage. The cause seems to be generalized meiotic pairing errors with the start of an apoptotic mechanism to avoid the formation of abnormal gametes.⁶⁶⁷ Massive apoptosis of oocytes occurs between the 15th and the 20th weeks.⁶⁶⁸ Surviving germ cells disappear throughout fetal life, and their numbers at birth are usually low (Fig. 12-66).⁶⁶⁹

Patients with mosaicism have fewer anomalies than pure 45XO individuals; 12% have menstruation (compared to 3% of pure 45XO patients), and 18% have breast development (compared to 5% of pure 45XO patients). In 10–20% of

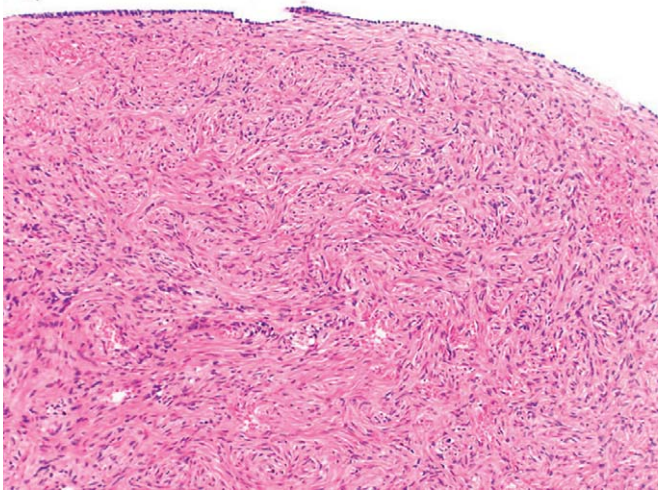


Fig. 12-66 Gonadal dysgenesis. Streak fibroblastic stroma resembling ovarian cortex.

45X0 patients the SRY gene is demonstrable by in-situ hybridization. It has been proposed that patients with SRY expression should undergo gonadectomy, because this gene is also a marker of gonadoblastoma.⁶⁷⁰ These patients may develop gonadoblastoma, dysgerminoma, and mixed germ cell tumor.^{670,671}

Mixed gonadal dysgenesis

Mixed gonadal dysgenesis is characterized by the presence of a streak gonad and a contralateral testis (often cryptorchid) or streak testis (see discussion on male pseudohermaphroditism with müllerian remnants, below).

True hermaphroditism

True hermaphroditism is a disorder of gonadal differentiation characterized by the presence in the same individual of both testicular and ovarian tissue. This condition is rare and usually difficult to diagnose, so only 25% of male hermaphrodites are diagnosed before age 20.⁶⁷² Failure to recognize this disorder may lead to surgical intervention for hernia repair or orchidopexy. Most hermaphrodites raised as males display symptoms for the first time at puberty because of breast development⁶⁷³ (95% of hermaphrodites have some degree of gynecomastia), periodic hematuria⁶⁷⁴ (if they have a uterus ending in the urinary tract), or cryptorchidism.⁶⁷⁵ Hermaphrodites raised as females initially present with irregular menstruation or clitoromegaly. True hermaphroditism should be suspected in all children with ambiguous sex characteristics (Fig. 12-67). The gonads of these patients are ovotestes, ovaries, or testes, with all possible combinations.⁶⁷⁶ True hermaphroditism can be (1) unilateral, if there are both testicular and ovarian tissues (forming one ovotestes or two separated gonads) on one side, and a testis or an ovary in the other side; if there is no gonadal tissue in this latter side, unilateral hermaphroditism is incomplete; (2) bilateral, if testicular and ovarian tissues are present on both sides of the body; and (3) alternate, if there is a testis on one side, and an ovary on the other side.

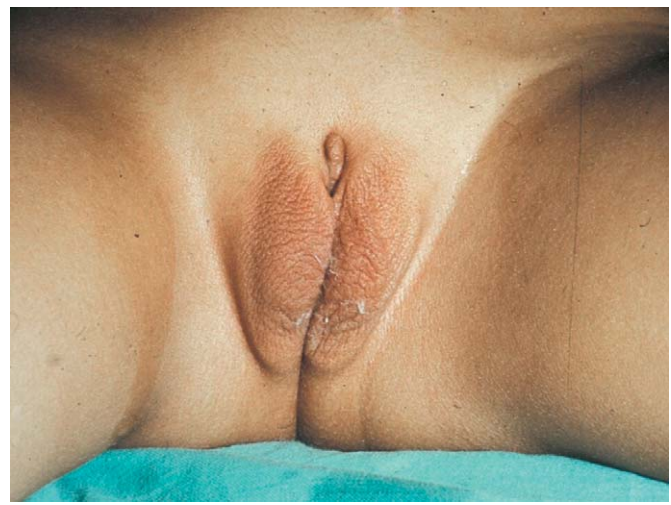

Fig. 12-67 True hermaphrodite showing external genitalia which display transverse folds and a slightly hypertrophic clitoris.

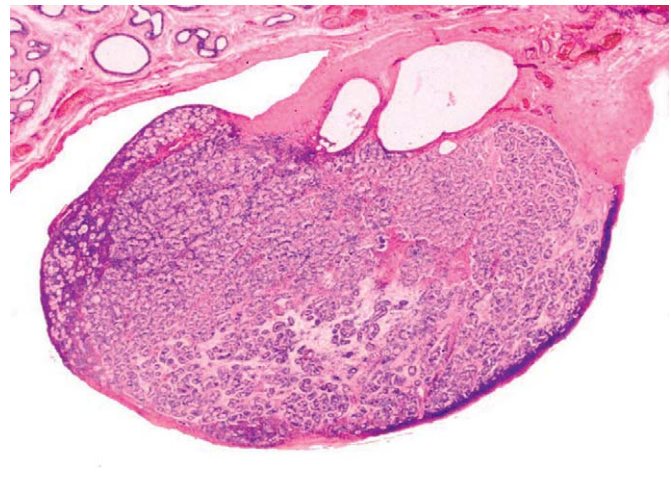


Fig. 12-68 True hermaphroditism. The ovotestis contains ovarian follicles arranged in a crescent. There is cystic transformation of the rete testis. The epididymis is hypoplastic.

Ovotestis is the most frequent gonadal type in true hermaphroditism. It is more frequent on the right side and is located in the abdomen (50% of cases), labioscrotal folds, inguinal canal, or the external inguinal ring. The ovotestis has a bilobated or ovoid shape (Fig. 12-68). In the bilobated ovotestis the testis and ovary are connected by a pedicle, whereas in the ovoid ovotestis the ovarian tissue forms a crescent capping the testicular parenchyma. The proportion of ovary to testis varies widely (Fig. 12-69). At adulthood, the ovarian follicles mature and corpora lutea or corpora albicantia may be seen. The seminiferous tubules rarely develop complete spermatogenesis. The interstitium usually contains Leydig cells. Ovotestis is associated with a fallopian tube in 65% of cases, and with a vas deferens in the remainder. If the patient has ovotestis/ovary, a completely developed uterus is present. If the patient has bilateral ovotestis (13%), uterine agenesis is frequent (Fig. 12-70).⁶⁷⁷

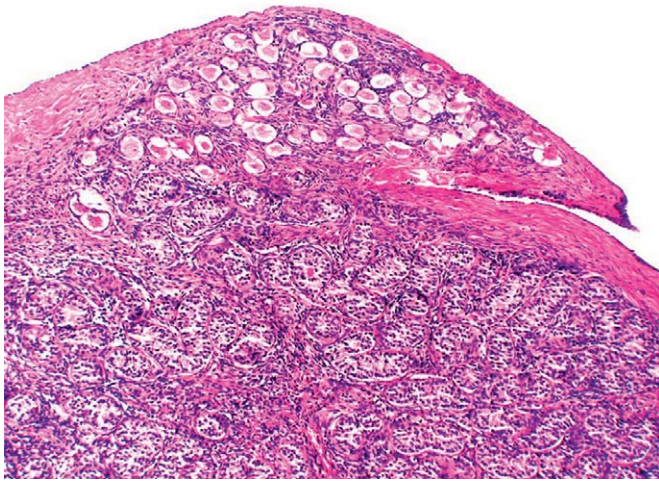


Fig. 12-69 True hermaphroditism. Ovotestis from a 2-year-old. The ovarian and testicular tissues are sharply demarcated.

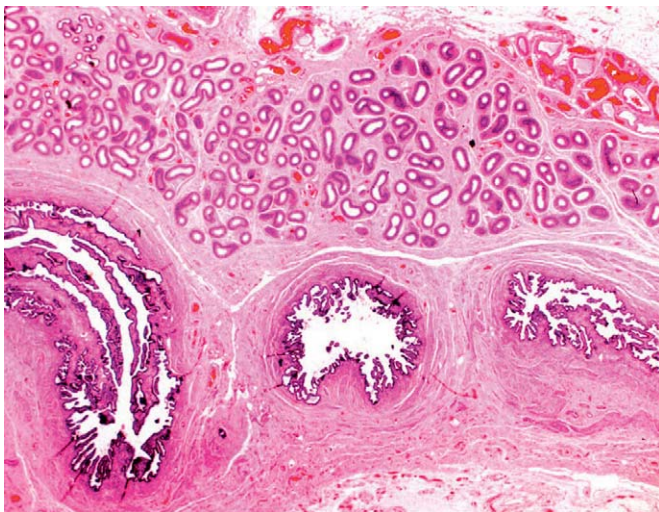


Fig. 12-70 True hermaphroditism. Epididymis and fallopian tube in an adult hermaphrodite raised as a female.

The testis of hermaphrodites is most often on the right side (60%) and is located anywhere from the abdomen to the scrotum. These testes have low tubular fertility indices during childhood. After puberty, the seminiferous tubules remain small, often containing only dysgenetic Sertoli cells, similar to the tubules of cryptorchid testes. Incomplete spermatogenesis has been reported, but complete spermatogenesis is exceptional. The ovary of hermaphrodites is most frequently on the left side (63%) and usually is hypoplastic with few primordial follicles. However, in occasional patients the ovary is histologically and functionally normal.

The most frequent karyotype is 46XX (60%), followed by several mosaicisms (33%) which, in decreasing order of frequency, are 46XX/46XY, 46XY/47XXY, 45X0/46XY, 46XX/47XXY. The 46XY karyotype is the least common (7%). There is variation in the incidence of some karyotypes

around the world. Mosaicism is found in 40.5% of European cases, but in only 21% of North America cases. Conversely, most African true hermaphrodites (97%) have 46XX karyotype. The karyotype 46XY is rare and its frequency is similar in Europe, Asia, and North America.^{678,679} Most cases are sporadic, and families with several affected members also have 46XX males. This finding suggests that both genetic anomalies are alternative forms of a single genetic defect.⁶⁸⁰ The following mechanisms^{681,682} have been proposed to explain the occurrence of testicular parenchyma: true hermaphroditism 46XX, a hidden mosaicism with a cell line having a Y chromosome; transfer from a Y chromosome fragment (including SRY gene) to the X chromosome; autosomal mutation of variable penetrance; and X-linked mutation coupled with rare X inactivation or X mutation that permits testicular differentiation in the absence of SRY. Some 46XX hermaphrodites with SRY-negative leukocytes are positive for this gene in DNA from the testicular parenchyma in the ovotestis.⁶⁸³ Over 22 pregnancies in true hermaphrodites have been reported,⁶⁸⁴ in contrast to the exceptional cases of paternity. Ovules may arise from the ovotestes or the ovary.

Management of true hermaphroditism depends on the patient's age at the time of diagnosis, the nature and location of the gonads, and the developmental stage of the external genitalia. Although bilateral castration may be justified in order to avoid the risk of neoplasia, gonadal preservation may be desirable until adulthood. In this case, if the patient is raised as a girl, puberty will occur spontaneously and there is a small chance of fertility.⁶⁸⁵ However, the high risk of malignancy (estimated at 4.6%) should be taken into account. The most frequent tumors are gonadoblastoma, dysgerminoma, and yolk sac tumor.⁶⁷⁶ The risk of cancer may be reduced if some precautions are taken, including removal of the testis if it has not descended and surveillance of the residual gonad with periodic ultrasound studies, especially in cases of chromosomal mosaicisms.

Male pseudohermaphroditism

Normal male development requires adequate differentiation of the testes in the fetal period, synthesis and secretion of testicular hormones, and proper response of target organs to these hormones. Anti-müllerian hormone produced by Sertoli cells inhibits the development of müllerian derivatives that would otherwise form the uterus and fallopian tubes. Testosterone produced by Leydig cells stimulates differentiation of the wolffian ducts into male genital ducts. The conversion of testosterone into dihydrotestosterone by the enzyme 5 α -reductase ensures the development of male external genitalia. Alterations in these processes may cause male pseudohermaphroditism.

Impaired Leydig cell activity

Androgen synthesis deficiencies

These autosomal recessive syndromes are characterized by an error in testosterone synthesis that results in incomplete or absent virilization. Cholesterol is the source for the synthesis of androgens, estrogens, and other steroid hormones

through multiple steps. First, the steroidogenic acute regulatory protein (StAR) generates cholesterol into mitochondria; StAR gene mutations cause congenital lipid adrenal hyperplasia. Second, within mitochondria, the cholesterol side-chain cleavage enzyme P450_{sc} transforms cholesterol into pregnenolone; a disorder in this enzyme is rare because it is highly lethal in embryonic life. Third, pregnenolone undergoes 17 α -hydroxylation by microsomal P450c17; deficiency in 17 α -hydroxylase causes female sexual infantilism and hypertension. Fourth, 17-OH-pregnenolone is converted into DHEA by 17,20-lyase activity of P450c17. The ratio of 17,20-lyase to 17 α -hydroxylase activity of P450c17 determines the ratio of C21 to C19 steroids produced. The ratio is regulated by at least three factors, including the electron-donating protein P450 oxidoreductase (POR), cytochrome b5, and serine phosphorylation of P450c17. Mutations in POR are present in the Antley-Bixler skeletal dysplasia syndrome as well as a variant of polycystic ovarian syndrome. Figure 12-71 shows the enzymes involved in the abovementioned steps. The enzyme 3 β -hydroxysteroid dehydrogenase transforms DHEA to androstenedione, and the enzymatic complex called aromatase transforms androstenedione into estrone and testosterone into estradiol.

In some patients cholesterol synthesis is also impaired, and congenital adrenal hyperplasia is superimposed on androgen deficiency. Deficient testosterone synthesis may result from abnormalities in the enzymes involved in pregnenolone formation (congenital lipid adrenal hyperplasia), including 3 β hydroxysteroid dehydrogenase, 17 α -hydroxylase, 17,20-desmolase, and 17 β -hydroxysteroid dehydrogenase (Fig. 12-71).

Congenital lipid adrenal hyperplasia Congenital lipid adrenal hyperplasia is the most severe form of congenital adrenal hyperplasia.⁶⁸⁶ The disorder is characterized by a deficit in steroid hormone synthesis in the adrenal cortex and gonads, producing a female phenotype with severe salt-loss syndrome. Conversion of cholesterol to pregnenolone requires the enzymes 20 α -hydroxylase, 20,22-desmolase, and 22 α -hydroxylase. Failure of any of these leads to deficits in cortisol, aldosterone, and testosterone.⁶⁸⁷

The enzymatic defect is usually caused by a deficit in the steroidogenic acute regulatory (StAR) protein; in other cases, the deficit is in P450_{sc}. The mitochondrial protein StAR promotes cholesterol transfer from the outer to inner mitochondrial membrane, where cholesterol serves as a substrate for P450_{sc} and initiates steroidogenesis. More than 35 different mutations in the StAR gene have been identified.⁶⁹⁰ As a result, cholesterol is not converted to pregnenolone, which is required for the synthesis of mineralocorticoids, glucocorticoids, and sex hormones.

The disorder is rare in most countries, but is common in Japan, Korea, and the Arabian countries.^{691,692} Patients usually present with salt-losing crisis in the first 2 months of life.^{693,694} In most cases, males have female or ambiguous external genitalia and a blind-sac vagina, hypoplastic wolffian derivatives, absence of müllerian structures, and cryptorchidism.⁶⁹⁵ The adrenals usually appear enlarged and contain lipid accumulations,^{696,697} but these diminish with age and the adrenals shrink.

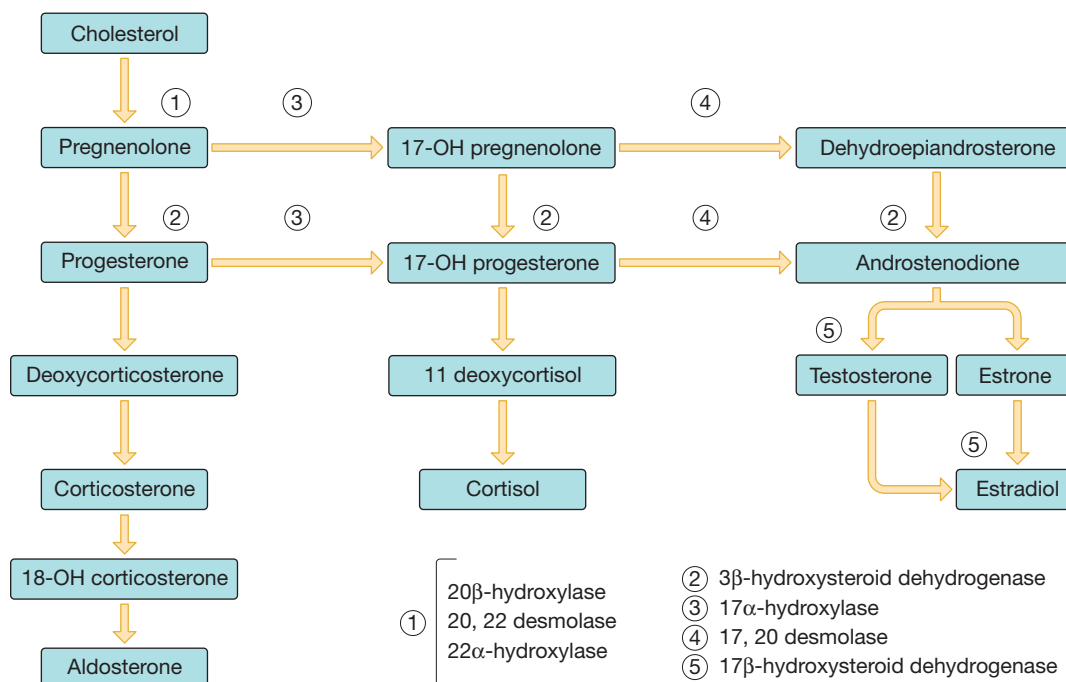


Fig. 12-71 Enzymatic defects in impaired testosterone biosynthesis.

In the testes, lipid accumulations may be present or absent in Leydig cells^{686,696,698-702} or Sertoli cells.⁷⁰³ An 8-year-old child had partially hyalinized seminiferous tubules with Sertoli cell-only pattern.⁷⁰⁴ The testes of pubertal patients are usually normal for age.^{701,702} Intratubular germ cell neoplasia has been reported in one case.⁷⁰⁵

Most patients die from adrenal insufficiency. Survivors have female phenotype⁷⁰⁴ and require the administration of glucocorticoids, mineralocorticoids, and gonadal steroids.⁷⁰³

3 β -Hydroxysteroid dehydrogenase deficiency Patients with this defect have two main problems: salt-loss syndrome produced by reduced aldosterone secretion, and incomplete virilization.⁷⁰⁶ At puberty, virilization increases and gynecomastia develops.^{707,708}

The enzyme 3BHSD catalyzes the conversion of 5-3 β -hydroxysteroids such as pregnenolone, 17-hydroxypregnenolone, and dehydroepiandrosterone into respectively 4-3 β -ketosteroid, progesterone, 17-hydroxyprogesterone, and androstenedione.⁷⁰⁹ There are two 3BHSD genes located on the p11-p13 region of chromosome 1. The type I gene is expressed in the placenta, kidney, and skin, whereas the type II gene 3BHSD is expressed only in the gonads and adrenal glands. Complete absence of the 3BHSD gene is lethal; therefore, most reported cases have only partial 3BHSD deficits.⁷¹⁰⁻⁷¹² It is assumed that these deficits account for 10% of cases of congenital adrenal hyperplasia.

The classic form of salt-losing 3BHSD deficit is diagnosed in the first months of life because of insufficient aldosterone synthesis and subsequent loss of salt. The other 3BHSD deficit, without salt loss, is due to mutations in the type II 3BHSD gene⁷⁰⁸ and its diagnosis may be delayed until puberty.

Severe forms of 3BHSD deficiency are associated with deficits in aldosterone, cortisol, and estradiol. Symptoms may vary widely, as enzymatic activity in the adrenal gland is not the same as in the testis. Most patients show salt loss and adrenal crisis; they have incomplete masculinization and may develop spontaneous puberty and gynecomastia.^{706,707,713} Patients with mild forms have normal genitalia and normal mineralocorticoid levels. Some patients have only hypospadias⁷¹⁴ or micropenis.⁷¹⁵ The testes are smaller and softer than normal.

17 α -Hydroxylase deficiency The cause of deficits in the enzymes 17 α -hydroxylase and 17,20-lyase are mutations of the CYP17 gene that encodes cytochrome P450c17.⁷¹⁶ The CYP17 gene is located on chromosome 10q24-q25,⁷¹⁷ and 50 different mutations have been described.⁷¹⁸ P450c17 catalyzes the 17 α -hydroxylation of pregnenolone to 17OH-pregnenolone and of progesterone to 17 α -OH-progesterone. This enzyme also catalyzes 17,20-lyase activity, transforming 17OH-pregnenolone to DHEA. The classic form of 17 α -hydroxylase deficit is caused by severe deficiencies in CYP17; less severe defects give rise to the isolated 17,20-lyase deficit. 17 α -Hydroxylase deficit impairs the synthesis of both cortisol and testosterone.⁷¹⁹ Low cortisol levels stimulate ACTH secretion, causing hypersecretion of aldosterone precursors and the development of hypokalemic hypertension and male pseudohermaphroditism in males.⁷²⁰ Patients

usually have hypospadias and develop gynecomastia at puberty.⁷²¹

17,20-Desmolase deficiency The enzyme 17,20-desmolase cleaves the side chain of 17-hydroxypregnenolone and 17-hydroxyprogesterone to form dehydroepiandrosterone and androstenedione, respectively. Varying degrees of 17,20-desmolase deficiency are seen, resulting in varied development of external genitalia, ranging from female phenotype to virilization with microphallus, bifid scrotum, and perineal hypospadias. In childhood, the testes contain reduced numbers of spermatogonia (Figs 12-72, 12-73).^{722,723} The cause may be mutations in one of the genetic loci encoding P450c17, flavoprotein OR or b5.⁷²⁴

17 β -Hydroxysteroid dehydrogenase deficiency This enzyme transforms androstenedione into testosterone and also converts estrone into estradiol. The enzymatic defects are sex-linked. Most patients have female phenotype at birth and

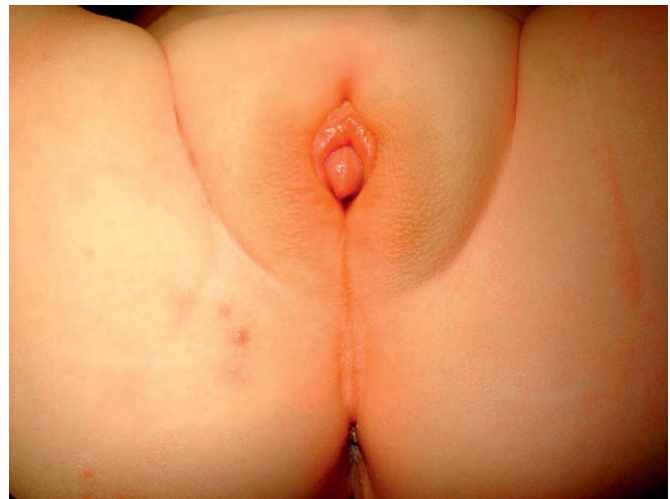

Fig. 12-72 Male pseudohermaphrodite with androgen synthesis deficiency. The external genitalia are ambiguous.

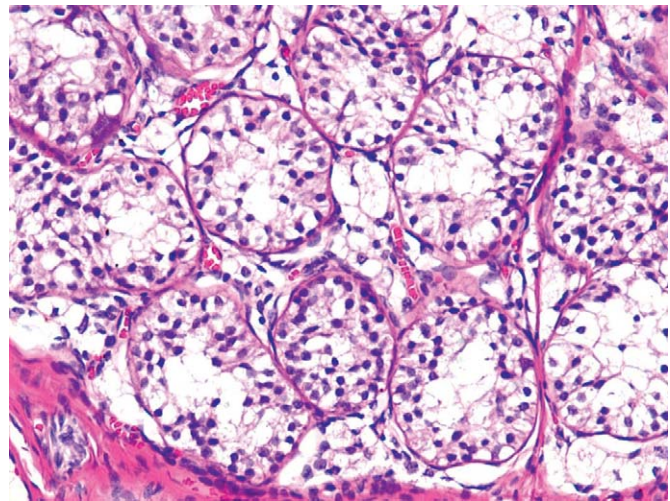


Fig. 12-73 Intense Leydig cell vacuolation in an infant with androgen synthesis deficiency.

are raised as girls, but at puberty undergo virilization.⁷²⁵ One or both testes may be cryptorchid or are located in the labia majora. Normal spermatogenesis has never been observed. The most common testicular patterns are hypoplasia or absence of germ cells and Leydig cell hyperplasia.⁷²⁶ The germ cell injury was initially attributed to cryptorchidism, but it is now thought to be a primary testicular lesion because even very young patients lack germ cells.⁷²⁷ This deficit is due to mutations in the HSD17B3 gene located on 9q22.^{728,729}

Leydig cell hypoplasia

This variant of male pseudohermaphroditism is defined by insufficient testosterone secretion⁴²² and the following characteristics: predominance of female external genitalia; absence of male secondary sex characteristics at puberty; absence of uterus and fallopian tubes and the presence of epididymis and vas deferens; 46XY karyotype; lack of response to human chorionic gonadotropin stimulation; absence of an enzymatic defect in testosterone synthesis; and small undescended testes that are gray and mucous on section.⁷³⁰⁻⁷³³ Age at diagnosis varies from 4 months to 35 years. The syndrome is sporadic and familial.^{734,735}

The best-known cause of Leydig cell hypoplasia is inactivating mutation of the LH receptor in these cells.⁷³⁶⁻⁷³⁸ During fetal life, there is an inadequate response to placental hCG initially and to pituitary LH subsequently. Phenotypes vary widely according to the presence of complete or partial loss of receptor function. These changes range from male pseudohermaphroditism with female external genitalia (type I of Leydig cell hypoplasia) to male phenotype with micropenis, hypospadias, pubertal delay, and primary hypogonadism (type II of Leydig cell hypoplasia).

In type I hypoplasia, the testes contain small seminiferous tubules with Sertoli cells, spermatogonia, and thickened basement membranes. Leydig cells are rare or absent, in contrast to Leydig cell hyperplasia seen in other types of male pseudohermaphroditism, such as those arising from defects in androgen synthesis or androgen action on peripheral tissues.^{739,740} Leydig cell hypoplasia accounts for low serum testosterone levels, lack of virilization, and lack of spermatogenesis. The absence of müllerian derivatives suggests a normal function of Sertoli cells, which synthesize müllerian inhibiting factor. In type II hypoplasia, adult testes show maturation arrest of spermatogonia and a few incompletely differentiated Leydig cells.^{741,742}

Impaired androgen metabolism in peripheral tissues

Androgen insensitivity syndromes

Resistance to androgen stimulation is the cause of several syndromes with phenotypes varying from complete testicular feminization⁷⁴³ to normal male.^{744,745} These syndromes are caused by partial or complete lack of response of the target organs to androgens⁷⁴⁶ due to the absence, diminution, or impairment of androgen receptors or post-receptor anomaly.⁷⁴⁰ The gene for the androgen receptor is located on the X chromosome (Xq11-q12), and X-linked transmission occurs in two-thirds of cases. The karyotype is usually 46XY, but 47XXY and several mosaicisms have been observed.⁷⁴⁷

These syndromes affect 1:20 000–1:40 000 newborns. The diverse phenotypes associated with androgen insensitivity may be classified as: complete androgen insensitivity syndrome (CAIS) or testicular feminization syndrome; partial androgen insensitivity syndrome (PAIS) or partial testicular feminization syndrome, which includes the syndromes of Lubs, Gilbert–Dreyfus, Reifenshtein, and Rossewater; and mild androgen insensitivity syndrome (MAIS), infertile men with light androgen insensitivity, and Kennedy's disease.

Complete androgen insensitivity syndrome (complete testicular feminization syndrome) This form of male pseudohermaphroditism is characterized by female phenotype with testes. Complete testicular feminization syndrome is rarely diagnosed during childhood except in patients who present with hernia, inguinal tumor, or with a family history of pseudohermaphroditism. Primary amenorrhea is the principal presentation in adults.

The testes may be in the abdomen, inguinal canal, or labia majora, and during the first year of life may be normal histologically except for reduced tubular diameter and low tubular fertility index. After the first year, decreased germ cell numbers become evident and the few remaining spermatogonia are concentrated in clusters of seminiferous tubules. The testicular interstitium contains numerous spindle cells arranged in bundles, and during the first year of life has Leydig cells with abundant eosinophilic or vacuolated cytoplasm. At puberty, patients have female external genitalia, a short blind-ended vagina, feminine breast development; and scarce pubic and axillary hair. Serum testosterone is at the normal male level and LH is markedly increased.

In adults, the testes vary in size from small to large, are tan-brown, and contain small seminiferous tubules without lumina which usually contain only Sertoli cells.^{748,749} In one-third of patients both Sertoli cells and spermatogonia are present.⁷⁵⁰ Ultrastructurally, Sertoli cells lack Charcot–Böttcher crystals and annulated lamellae; inter-Sertoli cell specialized junctions are not well developed, and in cryofracture studies the arrangement of membrane particles has an immature pattern.⁷⁵¹ Leydig cells are abundant, but few contain Reinke's crystalloids. Often, there are areas resembling ovarian stroma in the testicular interstitium.

In about two-thirds of cases the testes contain grossly visible white nodules that stand out from the surrounding testicular parenchyma (Figs 12-74, 21-75). Histologically, the nodules consist of clusters of small seminiferous tubules with immature Sertoli cells, hyalinized lamina propria, numerous Leydig cells, and an absence of elastic fibers (Fig. 12-76). These have been referred to as Sertoli–Leydig cell hamartoma. About 25% of testes have Sertoli cell adenoma, sometimes very large, consisting of tubules resembling infantile testis but lacking in germ cells and peritubular myofibroblasts. No Leydig cells are present between the tubules (Figs 12-77, 12-78).⁷⁵² Other benign tumors include Sertoli cell tumor (large cell calcifying Sertoli cell tumor and sex cord tumor with annular tubules), Leydig cell tumor, leiomyoma, and fibroma.⁷⁴⁶

Approximately 60% of cases have small cystic structures closely apposed to the testes, and about 80% of patients have thick bundles of smooth muscle fibers resembling myo-

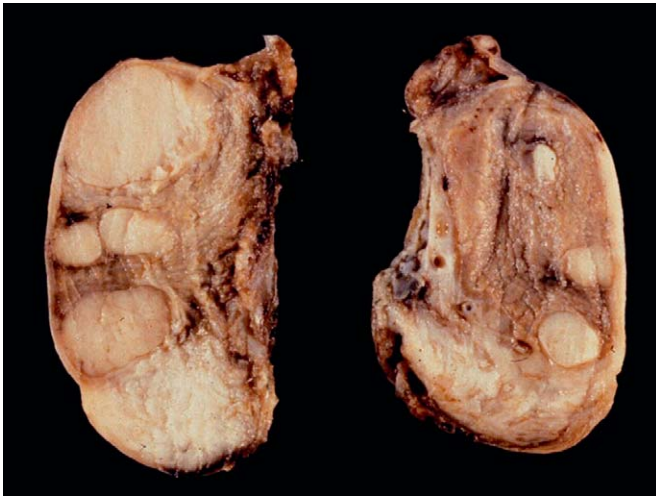


Fig. 12-74 Testicular feminization syndrome. Both testes are enlarged and contain several gray-white nodules.

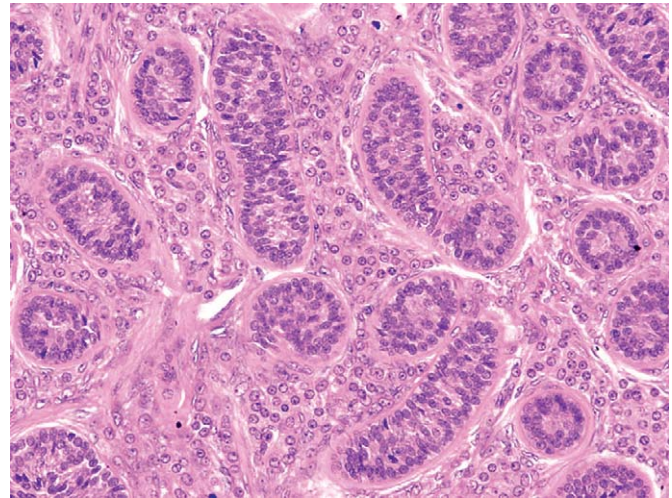


Fig. 12-76 Testicular feminization syndrome. Small seminiferous tubules with immature Sertoli cells surrounded by thick basement membranes and numerous Leydig cells.

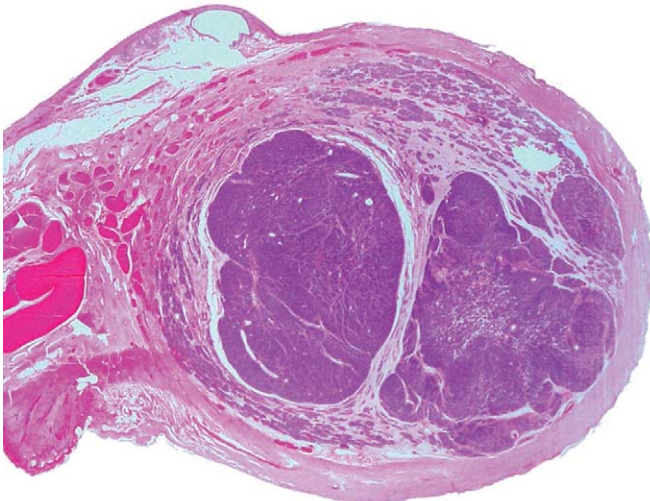


Fig. 12-75 Testicular feminization syndrome. Cross-sectioned testis with multiple well-demarcated nodules.

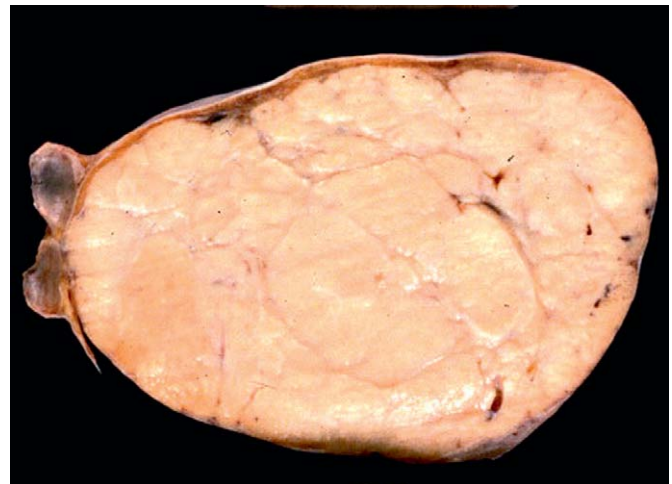

Fig. 12-77 Large Sertoli cell adenoma in an abdominal testis from a 65-year-old patient with testicular feminization syndrome.

metrium near the testis. True myometrium has been demonstrated in only one case. Hypoplastic fallopian tubes are present in about one-third of cases. In about 70% of patients the epididymis and vas deferens are rudimentary; the only explanation for this is residual activity of the mutated androgen receptor.⁷⁵³ Approximately 10% of testes from patients with testicular feminization syndrome develop cancer. The frequency increases with age, but tumors rarely appear before puberty. These tumors include intratubular germ cell neoplasia (Fig. 12-79),⁷⁴⁹ several types of germ cell tumor,^{750,754} and sex cord tumor.⁴⁴¹ Thus, the gonads should be removed immediately after puberty.⁷⁵⁵

Partial androgen insensitivity syndrome (partial testicular feminization syndrome) The phenotype of patients with partial testicular feminization varies from normal female to normal male. The disorder includes four classic syndromes:

Lubs' syndrome,⁷⁵⁶ characterized by partial fusion of labio-scrotal folds, a definitive introitus, clitoromegaly, pubic and axillary hair, and poor breast development;⁷⁵⁷ Gilbert-Dreyfus syndrome, characterized by progressively greater male phenotypic features that include small phallus, hypospadias, incomplete development of wolffian derivatives, and gynecomastia;⁷⁵⁸ Reifenstein's syndrome, characterized by hypospadias, weak or absent virilization, testicular atrophy, gynecomastia, azoospermia, and infertility;⁷⁵⁹ and Rosewater-Gwinup-Hamwi syndrome, characterized by infertile men whose only abnormal feature is gynecomastia.⁷⁶⁰

Mild androgen insensitivity syndrome Spermatogenesis requires high levels of intratesticular testosterone. A minor form of androgen insensitivity may be observed in some patients with male phenotype who present with infertility.⁷⁶¹

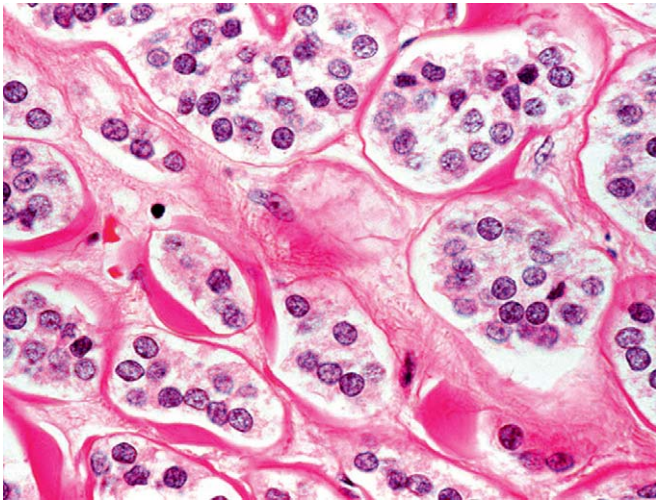


Fig. 12-78 Sertoli cell adenoma showing tubular clusters with a hyalinized wall in a stroma devoid of Leydig cells.

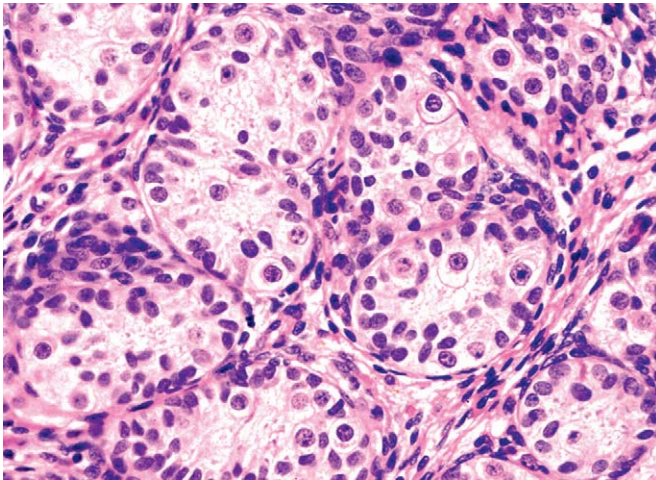


Fig. 12-79 Intratubular germ cell neoplasia, undifferentiated type, in a phenotypically female patient with inguinal testes. The tumor cells stand out by virtue of their large size, pale cytoplasm, and prominent nucleoli.

The frequency of androgen resistance among azoospermic and oligozoospermic men is estimated at about 19%⁷⁶² or lower.^{763,764} Some patients have lost exon 4⁷⁶⁵ or mutated exons 6⁷⁶⁴ or 7.⁷⁶⁶

Kennedy's disease Kennedy's disease (spinal and bulbar muscular atrophy, SBMA) is an X-linked recessive disorder of the adult male^{767,768} characterized by loss of motor neurons in the spinal cord and brain stem and associated with less important loss of sensory neurons and atrophy caused by skeletal muscle denervation.^{767,769} Disease onset around 20 years of age includes muscular weakness, cramps, and fasciculations.⁷⁷⁰ In most cases the male reproductive system is impaired.⁷⁷⁰⁻⁷⁷² The testes may be normal in the initial stages of the disease, and many patients are fertile; however, with progression, there is onset of secondary testicular atrophy and gynecomastia. Testosterone levels are decreased in some cases.

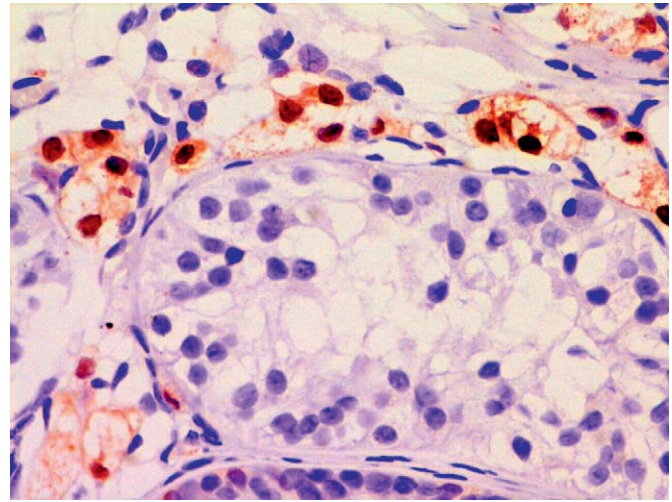


Fig. 12-80 Testis from an infant with 5 α -reductase deficiency showing hyperplastic Leydig cells that have marked cytoplasmic vacuolation and surround a seminiferous tubule lacking germ cells. (Immunostain for calretinin.)

The disease results from mutations in the first exon of the androgen receptor (AR) gene.⁷⁷³ The SMBA gene, located on Xq11-12, has expansion of a repetitive CAG sequence in exon A. The number of CAG repeats is 21 (range, 17–26) in control men and more than 40 in men with Kennedy's disease.^{768,774-777}

5 α -Reductase deficiency

This disorder is a variant of male pseudohermaphroditism caused by a lack of the enzyme 5 α -reductase with failure of conversion of testosterone to dihydrotestosterone.⁷⁷⁸ In patients with the 46XY karyotype there are two isoenzymes: isoenzyme 1 is encoded by the gene SRD5A, located on 5p15, and isoenzyme 2 is encoded by the gene SRD5A2 on 2p23. Most reported cases result from defects in SRD5A2.⁷⁷⁹ Many mutations in different exons have been reported.⁷⁸⁰⁻⁷⁸⁴

During childhood, patients have a clitoriform penis, bifid scrotum, urogenital sinus, and testes in the inguinal canal or labioscrotal folds (Fig. 12-80). Müllerian derivatives are absent. At puberty they acquire the male phenotype, with development of the penis and scrotum. Adults have erections, ejaculations, and normal libido, scant body hair and a thin beard, a very small prostate, and lack of temporal hairline recession (male pattern baldness). Serum levels of FSH, LH, and testosterone are increased, but dihydrotestosterone is decreased.^{785,786}

The disorder is autosomal recessive and has been observed in many consanguineous families from the Dominican Republic.⁷⁸⁷

Defective regression of müllerian ducts

This group of male pseudohermaphrodites is characterized by the presence of müllerian derivatives and unilateral or bilateral testicular dysgenesis. These two features depend on anti-müllerian hormone gene mutations and end-organ insensitivity.⁷⁸⁸⁻⁷⁹¹

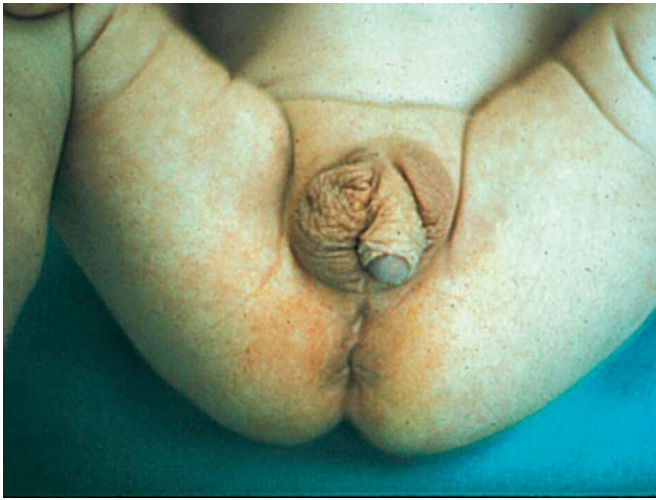


Fig. 12-81 Mixed gonadal dysgenesis in a 3-year-old infant with ambiguous external genitalia, hypoplastic uterus, testicular dysgenesis on the right side, and streak gonad on the left side.

In normal development, anti-müllerian hormone is responsible for inhibition of the ipsilateral müllerian ducts and collagenization of the tunica albuginea. Patients with deficient secretion of this hormone may also have androgen deficiency. Three variants of defective müllerian duct regression have been reported: mixed gonadal dysgenesis, dysgenetic male pseudohermaphroditism, and persistent müllerian duct syndrome.

Mixed gonadal dysgenesis

Mixed gonadal dysgenesis (asymmetric gonadal differentiation) is characterized by the presence of a testis on one side of the body and a streak gonad on the other.⁷⁹² If the gonads are intra-abdominal, the labioscrotal folds may appear as either normal labia or empty scrotal sacs (Fig. 12-81). In the former, the syndrome cannot be recognized in the newborn unless a peniform clitoris is present. If the gonad is descended, it is usually a testis. Müllerian derivatives such as fallopian tubes are usually associated with streak gonad (95% of cases), but may also be associated with testicular tissue (74%). Ipsilateral to the testis there is one epididymis and one vas deferens. On the contralateral side, no gonad or a streak gonad and a fallopian tube are present. A hypoplastic uterus and a poorly developed vagina are frequent findings.

This syndrome accounts for about 15% of intersex conditions. Some patients are raised as males, although their external genitalia are usually ambiguous as a result of fetal virilization. The penis is clitoriform, and the urethra opens in the perineum. Most have cryptorchid testes and are raised as girls, becoming virilized at puberty. Infertility is a common symptom.⁷⁹³ The etiology is heterogeneous:⁷⁹⁴ one-third of patients have turnerian features, in accordance with the presence of the 45X0/46XY karyotype in more than 50% of patients. Other observed karyotypes are 46XY and 45X0/47XYY. Approximately 81% of patients have one Y chromosome. Mutation in the SRY gene has not been found.⁷⁹⁵

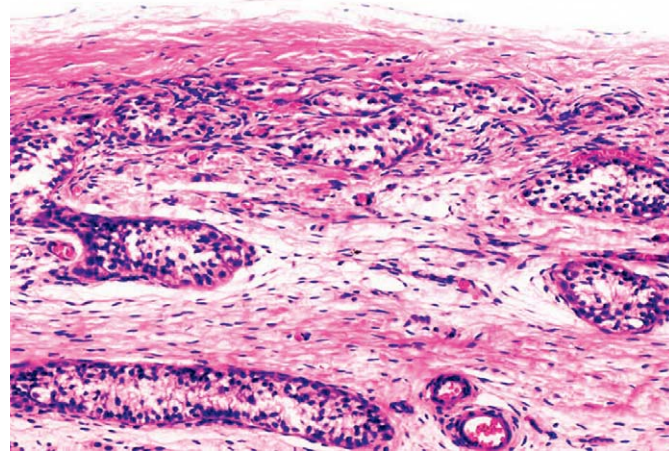


Fig. 12-82 Testicular dysgenesis. Several irregularly shaped seminiferous tubules are observed within a thin, poorly collagenized tunica albuginea.

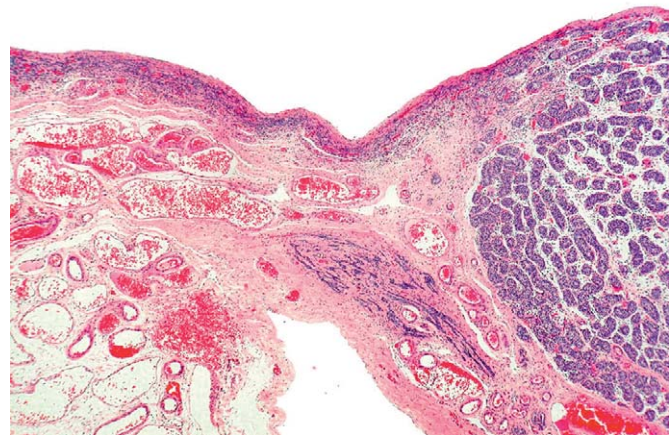


Fig. 12-83 Streak testis consisting of a streak gonad connected to a testis which shows the characteristic lesions of testicular dysgenesis.

The testes can show two different patterns: testicular dysgenesis and streak testis. *Testicular dysgenesis* is characterized by a tunica albuginea that varies in width and is reminiscent of ovarian stroma by the storiform distribution of cells and fibers; there are also malformed seminiferous tubules (Fig. 12-82) that are small, usually lack lumina, and contain only immature Sertoli cells. In adults, spermatogenesis has been observed occasionally. The testicular interstitium contains increased numbers of Leydig cells.

Streak testes are complex gonads in which testicular dysgenesis is associated with a fibrous streak. Most of the gonad consists of a testis showing the characteristic lesions of testicular dysgenesis. In a pole of the gonad, or in continuity with it, there is a fibrous streak whose structure may correspond to any of the varieties mentioned above (Fig. 12-83). This peculiar gonad can also be observed in some dysgenetic male pseudohermaphrodites as well as in the persistent müllerian duct syndrome.

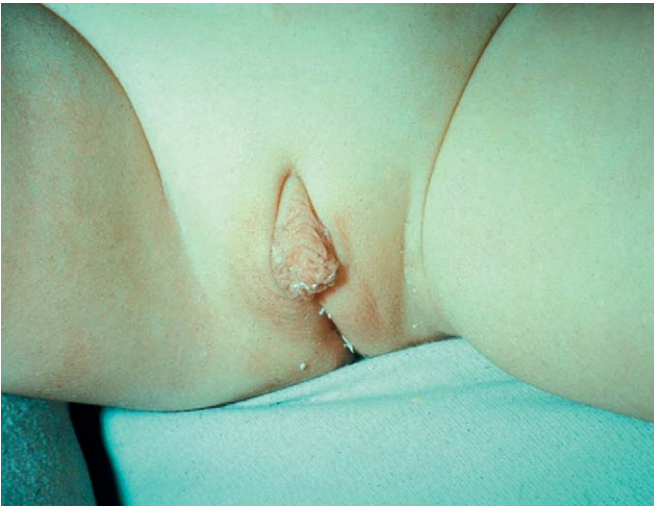

Fig. 12-84 Male pseudohermaphrodite with bilateral testicular dysgenesis.

lerian duct syndrome. In these cases, the streak contains no oocytes. Light microscopy indicates a wide spectrum of testicular lesions, ranging from those of patients with 46XY pure gonadal dysgenesis to true hermaphroditism. Differentiation of the oocyte-containing streak testis and ovotestis remains controversial.^{796,797}

The testes in mixed gonadal dysgenesis are incapable of müllerian duct inhibition and allow complete differentiation of wolffian derivatives, virilization of external genitalia, and, in most cases, testicular descent. The risk of germ cell neoplasia reaches 50% in the third decade of life, usually beginning with gonadoblastoma. The testes should be removed after puberty.

Dysgenetic male pseudohermaphroditism

Dysgenetic male pseudohermaphroditism is a disorder of sexual differentiation characterized by bilateral dysgenetic testes or streak testis, persistent müllerian structures, and cryptorchidism. This syndrome is considered a variant of mixed gonadal dysgenesis (Fig. 12-84).^{791,798} The karyotype may be 46XY or 45X0/46XY, and turnerian stigmata may be present. The uterus and fallopian tubes are present and both are usually hypoplastic (Fig. 12-85).⁷⁹⁹ The testes show lesions characteristic of testicular dysgenesis, with few germ cells during childhood (Fig. 12-85).⁷⁹⁹ In adults, spermatogenesis is poorly developed and the testicular interstitium shows Leydig cell hyperplasia. About 25% of patients develop gonadoblastoma.⁸⁰⁰

Persistent müllerian duct syndrome

Persistent müllerian duct syndrome has many names, including male with uterus, tubular hermaphroditism, persistent oviduct syndrome, and hernia uteri inguinalis.⁸⁰¹ It is a rare form of pseudohermaphroditism, with müllerian derivatives in an otherwise phenotypically normal male, and is the most characteristic form of isolated anti-müllerian hormone deficiency.

The molecular basis of this syndrome is heterogeneous. Three hypotheses have been proposed, including a defect in anti-müllerian hormone synthesis, caused by mutation in the anti-müllerian hormone gene (45% of cases); resistance

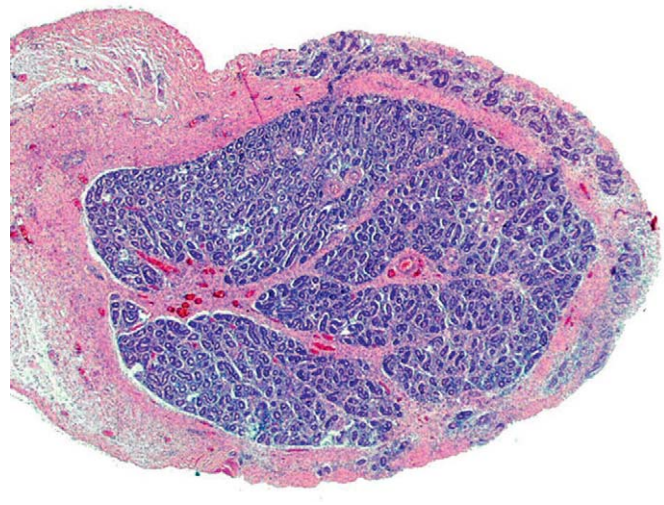


Fig. 12-85 Testicular dysgenesis. The gonad has a central portion showing a testicular pattern and a peripheral band consisting of poorly collagenized connective tissue that contains seminiferous tubules that reach the gonadal surface.

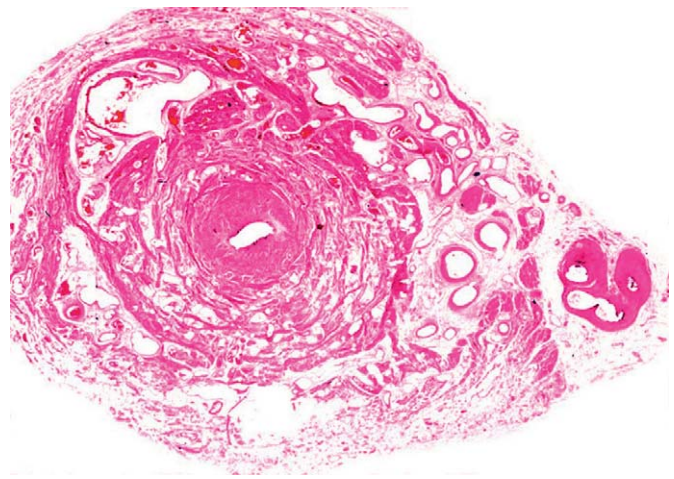


Fig. 12-86 Persistent müllerian duct syndrome. Cross sectioned hypoplastic uterus. In its tunica adventitia and parallel to it, a folded ductus deferens is seen.

of target organs to this hormone, caused by mutation in the receptor II for this hormone (39% of cases); and failure in the action of this hormone immediately before the eighth week of gestation (16% of cases).⁸⁰²

Although the external genitalia are male, one (35% of cases) or both testes (75% of cases) are cryptorchid. The syndrome usually also includes inguinal hernia contralateral to the undescended testis, with a uterus and fallopian tubes within the hernia sac (Figs 12-86, 12-87).⁸⁰³ Several cases with transverse testicular ectopia and persistent müllerian duct structures have been reported.^{804,805} Patients usually have inguinal hernia, but others have cryptorchidism, infertility,⁸⁰⁶ and testicular tumor.⁸⁰⁷

In childhood, the testes have a low tubular fertility index and decreased tubular diameter. In adults, the tunica albu-

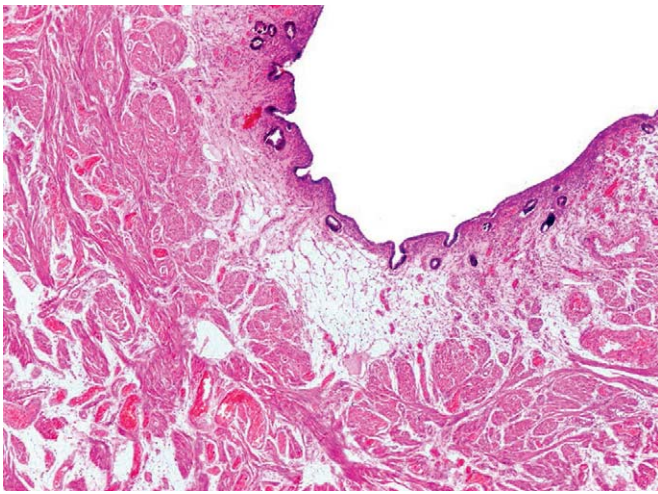


Fig. 12-87 Persistent müllerian duct syndrome. Uterus with atrophic endometrium and hypoplastic myometrium within a hernia sac.

ginea is variably thickened, contains connective tissue resembling ovarian stroma, and may contain tubular structures – alterations typical of testicular dysgenesis. The seminiferous tubules are usually atrophic and hyalinized. Tubules with reduced spermatogenesis or patterns suggesting mixed atrophy (seminiferous tubules with spermatogenesis intermingled with Sertoli cell-only tubules) have also been reported. The Leydig cells appear hyperplastic. Azoospermia or oligozoospermia are common, and paternity is exceptional.⁸⁰⁸

The syndrome is sporadic or familial, with autosomal recessive or X-linked inheritance.^{809,810} These patients have a higher risk of testicular tumor than that attributed to cryptorchidism,⁸¹¹ and all types of germ cell tumor have been observed.^{812,813}

Other forms of male pseudohermaphroditism

Of the dysmorphic syndromes associated with incomplete virilization of external genitalia, the best-known are those of RSH, Denys–Drash, WAGR, Opiz, camptomic dysplasia, ATR-X, Gardner–Silengo–Wachtel, Meckel, branchioskeletal–genital, Down’s, and other trisomies.

RSH (Smith–Lemli–Opitz) syndrome is a malformative recessive autosomal syndrome caused by mutations in the gene encoding for 7-dehydrocholesterol reductase (DHCR7), responsible for the synthesis of cholesterol from its immediate precursor 7-dehydrocholesterol.^{814–816} The disorder is common in Europe and rare in other countries.⁸¹⁷

The most severe form is lethal before birth. Fetuses show postaxial oligodactyly (instead of polydactyly) and sometimes severe hydrops.⁸¹⁸ Non-lethal forms are characterized after birth by severe growth failure; a semi-obtunded state; absence of psychomotor development; microcephaly; congenital cataracts; peculiar facies; broad anteriorly rugose alveolar ridges with cleft palate, edema of the nape of the neck, and unilobulate lungs; male pseudohermaphroditism or female external genitalia in 46,XY patients; postaxial polydactyly of the hands and feet; congenital heart defects; and

renal anomalies.⁸¹⁹ Hepatic and renal insufficiencies are frequent.⁸²⁰

The less severe forms in the male have genital anomalies (70%) varying from normal genitalia to severe hypospadias with or without cryptorchidism, and numerous small anomalies whose collection characterizes the syndrome. Most patients also show mental retardation and severe behavioral problems.⁸²¹

The DHCR7 gene maps to chromosome 11q12-13. Its product is a microsomal, membrane-bound protein. Many different missense, nonsense, and splice-site mutations as well as duplications and deletions have been reported.^{822–827} Prenatal diagnosis is possible by relating ultrasound and cytogenetic studies and carrying out a biochemical analysis in the second trimester in those pregnant women who have low levels or no conjugated estriol.⁸²⁸

In Denys–Drash syndrome, male pseudohermaphroditism is associated with nephroblastoma and renal insufficiency.⁸²⁹ The pseudohermaphroditism is usually either mixed gonadal dysgenesis, dysgenetic male pseudohermaphroditism, 46,XY pure gonadal dysgenesis, or true hermaphroditism.⁸³⁰ The most common nephropathy is diffuse mesangial sclerosis.⁸³¹ Most patients have mutations in the WT-1 gene,⁸³² which is expressed in the genital ridge in the sixth week of gestation and gives rise to either streak gonads or testicular dysgenesis, but, if a delay in testicular determination occurs, normal testes are formed.⁸³³

The term WAGR syndrome refers to Wilms’ tumor, aniridia, genital anomalies, and mental retardation. Prevalence is estimated at between 0.75% and 2% of Wilms’ tumor patients. The syndrome is related to the syndrome of Denys–Drash and that of Frasier (a variety of 46,XY gonadal dysgenesis).^{834,835} All have in common mutations in the WT-1 gene located on chromosome 11 (11p13).

WT-1 product is a transcription factor expressed in different tissues that participates in embryogenesis and cell differentiation. Mutations lead to the production of an anomalous protein that causes alterations in renal function, gonadal anomalies, and the loss of tumor suppressor function. Six variants of alleles have been described: isolated Wilms’ tumor, mesothelioma, isolated diffuse mesangial sclerosis, Denis–Drash syndrome, Frasier syndrome, and WAGR syndrome. Frasier syndrome is caused by mutations in the donor zone of the intron 9 link, with the subsequent loss of the +KTS isoform (the patient has an imbalance in KTS isoforms), whereas large deletions or loss of genetic material that comprises the WT-1 gene and other contiguous genes (PAX6 or AN) lead to the WAGR syndrome.^{836,837}

Patients with Opitz’s syndrome are mainly boys with hypertelorism and, in the severe forms, unilateral or bilateral lip cleft, laryngeal cleft, severe dysphagia with more or less life-threatening aspiration, hypospadias and, occasionally, imperforate anus. The most important internal anomalies are those in the tracheobronchial tree, cardiovascular system (defects in cardiac septation), and gallbladder, with a subjacent defect of the developing embryonal ventral midline. The syndrome is genetically heterogeneous and consists of two entities that were described as different in the past: ADOS, or autosomal dominant Opitz syndrome or G syn-

drome⁸³⁸ with a mutated gene that maps to 22q11.2; and XLOS, or X-linked Opitz syndrome or BBB syndrome⁸³⁹ with a mutated gene that maps to Xp22.3.^{840,841}

Camptomelic dysplasia is an autosomal dominant syndrome with multiple osseous malformations. Patients have 46XY karyotype and external genitalia that are ambiguous or female. Gonadal histology varies from testes to dysgenetic ovaries with primary follicles. The cause is a haploinsufficiency of SOX9, located on 17q.⁸⁴² The incidence of gonadoblastoma is low.

ATR-X syndrome is characterized by mild α -thalassemia, mental retardation, facial dysmorphism, and hypospadias.^{843,844} The disorder is X-linked, and is caused by mutation in the ART-X gene (synonymous XNP, HX2).⁸⁴⁵

Infertility

Testicular biopsy

Testicular biopsy to diagnose infertility began in the 1940s,^{846,847} and most of the diagnostic terms used today were created then.⁸⁴⁸ These terms are usually descriptive and, except for a few (normal testes, Sertoli cell-only tubules, tubular hyalinization, for example), do not specify the degree of tubular abnormality that is evaluated by each pathologist subjectively. The terms maturation arrest and hypospermatogenesis have been applied to biopsies in more than 50% of cases of infertility,^{849–851} but the criteria for these vary widely among pathologists.

Two forms of maturation arrest have been described: spermatogenic arrest, and spermatocytic arrest, or its equivalent, meiotic arrest. True spermatogenic arrest is rare because germ cell maturation usually does not arrest at the level of a defined germ cell type.⁸⁵² To avoid confusion the term irregular hypospermatogenesis has been proposed⁸⁵³ for testicular biopsies with decreased numbers of germ cells, subclassified as slight, moderate, or severe. However, this diagnosis is of little help to clinicians. The reported frequency of spermatocytic (meiotic) arrest in infertile men varies from 12%⁸⁵⁴ to 32.1%⁸⁵⁵ and is present in one or both testes of about 18% of oligozoospermic or azoospermic patients.⁸⁵⁶ If observed in only one testis, the contralateral testis may show histologic changes ranging from normal spermatogenesis to hyalinized tubules.

Disorganization of the seminiferous tubular cell layers is another frequent diagnosis in testicular biopsies,^{848,857,858} but this term is rejected by many pathologists. Actual disorganization of the seminiferous tubular cells is unlikely and has not been demonstrated in ultrastructural studies. In most cases, the apparent disorganization is an artifact induced by handling or fixation.^{859,860}

The term tubular blockage was introduced by Meinhard and co-workers⁸⁵⁸ for testes with at least 50% of seminiferous tubules devoid of a central lumen and showing spatial disorganization of germ cells. This morphology was found in 28% of testicular biopsies from infertile men, mainly those with obstructive azoospermia.⁸⁶¹ Although this appearance can result from improper fixation,⁸⁶² the accumulation

of Sertoli cells and immature germ cells in the centers of tubules suggests a specific lesion, a variant of germ cell sloughing.

Diagnostic confusion decreased the interest and trust of urologists and andrologists in the study of testicular biopsies. Subsequent studies attempted to correlate semen spermatozoa concentration with testicular size and biochemical findings such as serum levels of FSH, and testicular biopsies were undertaken in only a limited number of oligozoospermic and azoospermic patients.^{859,862,863} However, these studies were also discouraging because FSH was found to correlate poorly with numbers of spermatozoa in the semen but better with numbers of spermatogonia in the seminiferous tubules,⁸⁶⁴ and normal numbers of spermatozoa can be produced by relatively small testes whereas some large testes have no spermatogenesis. In recent years, serum levels of inhibin B have been shown to have a positive correlation with spermatozoon numbers and serum FSH level.^{865,866}

The development of morphometry caused a resurgence of interest in biopsies. Many semiquantitative^{853,867–869} and quantitative^{870–875} studies were carried out. The greatest achievements of these studies were enhancement of the reproducibility of results and better evaluation of the reversibility of lesions. Morphometry emerged as the best method to objectively evaluate the seminiferous tubular cells.⁸⁷⁶ The scoring method of Johnsen,⁸⁶⁸ estimation of the germ cell/Sertoli cell ratio for each germ cell type,⁸⁷¹ and calculation of germ cell number per unit length of seminiferous tubules⁸⁷⁰ are reliable and useful.

Several methods are available to evaluate the Leydig cell population, including the mean number of cells per seminiferous tubule and per cell cluster; the mean number of Leydig cell clusters per seminiferous tubule; the ratio of Leydig cell area to seminiferous tubule area;⁸⁷⁷ and the ratio of Leydig cells to Sertoli cells.⁸⁷⁸ These methods have shown that the appearance of Leydig cell hyperplasia described in many conditions is false, and that true Leydig cell hyperplasia is extremely rare.

Optimal interpretation of testicular biopsies depends on the surgical technique by which the tissue sample is taken, the care and delicacy with which the specimen is manipulated, and proper fixation and processing of the tissue. The size of the biopsy should not be greater than a grain of rice: that is, no diameter should be greater than 3 mm. This amounts to about 0.12% of testicular volume (normal volume is approximately 20 mL). The biopsy should be bilateral because in more than 28% of patients the findings differ between the testes. At the time of biopsy, the testicular axes should be measured as the basis of quantitative studies. The tissue should be taken opposite to the rete testis through a 4–5 mm incision in the tunica albuginea. This parenchyma herniates through the incision and can be carefully snipped off. If only light microscopy is to be performed, the specimen should be fixed in Bouin's fluid for 24 hours. If electron microscopy is indicated, a small biopsy fragment should be fixed in glutaraldehyde–osmium tetroxide or a similar fixative. To perform meiotic studies, testicular biopsy should be processed by air-drying or surface-spreading methods. The

examination of testicular biopsies includes qualitative and quantitative evaluation of the testis and correlation between the biopsy and spermogram.

Qualitative and quantitative evaluation of testicular biopsy

Light microscopy immediately reveals whether the lesion is focal or diffuse. If focal, the percentage of tubules showing each lesion (Sertoli cell-only, hyalinization, tubular hypoplasia, etc.) should be calculated. It is useful to evaluate elastic fibers with a special stain because this highlights groups of small tubules that may be missed with hematoxylin and eosin. A minimum of 30 cross-sectioned tubules should be studied (this is usually possible when five or six histological sections are available). The diameter of each tubule should be measured, and the number of spermatogonia, primary spermatocytes, young spermatids (also called round spermatids or $S_a + S_b$ spermatids), mature spermatids (also called elongated or $S_c + S_d$ spermatids), Sertoli cells, and, in some cases, peritubular cells counted. The presence of tubular diverticula,^{879,880} the maturation of Sertoli cells, and morphologic anomalies in germ cells should also be noted. Evaluation of the testicular interstitium should include the number of Leydig cells per tubule (or number of Leydig cell clusters per tubule), the presence of angiectasis (phlebectasis), and the occurrence of peritubular or perivascular inflammation. Normal values are tabulated in Table 12-6. For a clear and rapid understanding of the results, data can be presented using cartesian axes (see Figs 12-96 and 12-103).

Common lesions

The most frequently observed lesions are Sertoli cell-only tubules, tubular hyalinization, alterations in spermatogenesis in either the adluminal or the basal compartments of seminiferous tubules, and mixed tubular atrophy.

Sertoli cell-only syndrome

Sertoli cell-only syndrome includes all azoospermias in which the seminiferous epithelium consists only of Sertoli cells. To better understand this syndrome, it is necessary to consider the morphological and functional changes induced in the Sertoli cell by hypophyseal gonadotropin secretion during puberty. During childhood, Sertoli cells are pseudostratified and their nuclei are dark, small, and round or elongated, with regular outlines and one or two small peripherally placed nucleoli. The cytoplasm lacks specialized organelles.⁸⁸¹ Adult Sertoli cells have characteristically pale, triangular nuclei with irregular, indented outlines. The nucleoli are large and have tripartite structures. The cytoplasm contains abundant smooth endoplasmic reticulum and specialized structures, including annulate lamellae, Charcot-Böttcher crystals, and specialized junctional complexes with other Sertoli cells. The pubertal increase in length and width of the seminiferous tubules replaces the infantile pseudostratified pattern with a simple columnar distribution.

Five variants of the Sertoli cell-only syndrome are identified by Sertoli cell morphology, the degree of development of the seminiferous tubules, and the presence or absence of interstitial lesions.⁸⁸² These variants are designated by the appearance of the predominant Sertoli cell population: immature Sertoli cells, dysgenetic Sertoli cells, adult Sertoli cells, involuting Sertoli cells, and dedifferentiated Sertoli cells (Fig. 12-88). Each type is associated with other tubular and interstitial alterations (Table 12-7).

The most frequent types of Sertoli cell-only syndrome in infertility patients are dysgenetic Sertoli cells, adult Sertoli cells, and involuting Sertoli cells. The clinical manifestations are similar, including normal external genitalia, well-developed secondary male characteristics, azoospermia, elevated serum FSH level, normal or elevated serum LH level, and normal or slightly low testosterone. These clinical and

Table 12-6 Testicular parameters in normal adult testes (means \pm SD)

Values per cross-sectioned tubule	Means \pm SD
Seminiferous Tubules	
Mean tubular diameter (μm)	193 \pm 8
Number of spermatogonia	21 \pm 4
Number of primary spermatocytes	31 \pm 6
Number of young ($S_a + S_b$) spermatids	37 \pm 7
Number of mature ($S_c + S_d$) spermatids	25 \pm 4
Number of Sertoli cells	10.4 \pm 2
Number of Sertoli cell vacuoles	0.8 \pm 0.3
Lamina propria thickness (μm)	5.3 \pm 1
Number of peritubular cells	21 \pm 4
Testicular Interstitium	
Number of Leydig cell clusters per tubule	1.2 \pm 0.3
Number of Leydig cells per tubule	5 \pm 0.2

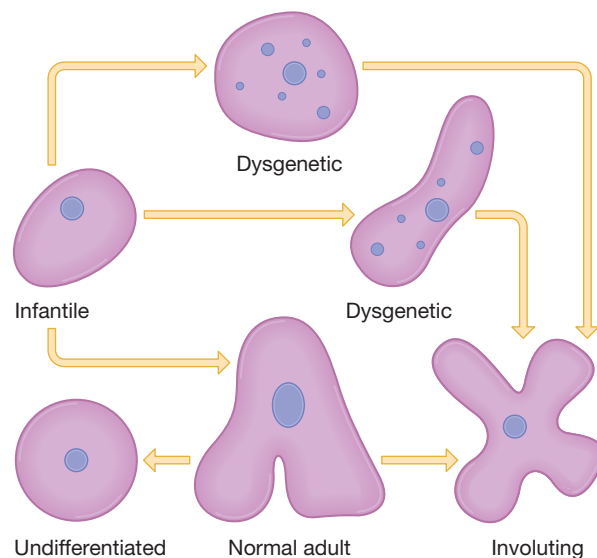


Fig. 12-88 Sertoli cell types.

Table 12-7 Variants of Sertoli cell-only syndrome

Testis pattern	Variants of the Sertoli cell-only syndrome				
	Immature Sertoli cells	Dysgenetic Sertoli cells	Adult Sertoli cells	Involuting Sertoli cells	Dedifferentiated Sertoli cells
Tubular diameter	Very decreased	Decreased	Decreased	Decreased	Decreased
Tubular lumen	Small or absent	Small or absent	Normal	Normal	Normal
Lamina propria thickness	Thin	Enlarged	Normal or enlarged	Normal or enlarged	Enlarged
Elastic fibers in lamina propria	Absent	Decreased	Normal	Normal	Normal
Sertoli cells					
Number	Very increased	Increased	Normal or increase	Normal or increased	Increased
Distribution	Pseudostratified	Pseudostratified	Columnar	Columnar	Columnar or pseudostratified
Nuclear shape	Ovoid	Round or ovoid	Triangular	Lobated	Round
Nuclear outline	Regular	Regular	Few indented	Very indented	Regular
Chromatin	Dark	Pale with granules	Pale	Pale	Pale
Nucleolus	Small, peripheral	Developed, central	Developed, central	Developed, central	Small, central or peripheral
Vacuoles	Absent	Present	Present	Abundant	Abundant
Lipids	Absent	Absent	Decreased	Abundant	Abundant
Vimentin filaments	Basal	Basal	Basal and perinuclear	Basal and perinuclear	Basal
Antimüllerian hormone	Present	Present	Absent	Absent	Absent
Interstitial	Scanty	Increased	Normal	Normal/fibrosis	Fibrosis
Leydig cells	Absent	Pleomorphic, vacuolated, increased or decreased	Normal	Decreased, many lipofuscin granules	Decreased, many lipofuscin granules
Clinical symptoms	Hypogonadotropic hypogonadism	Infertility	Infertility, orchitis	Infertility, hypergonadotropic hypogonadism, chemo- or radiotherapy	Treatment with estrogens, antiandrogens or cisplatin, chronic hepatopathy

histologic features were long thought to constitute a single syndrome, Del Castillo's syndrome, but recent ultrastructural, histochemical, immunohistochemical, and cytogenetic studies have shown that this results from a variety of syndromes that may have primary or secondary causes (Table 12-7).⁸⁸³⁻⁸⁸⁷

Some patients with the adult or dysgenetic Sertoli cell-only syndrome variants have a few spermatozoa in their spermograms. This discrepancy between oligozoospermia and the biopsy histology is caused by the presence of some seminiferous tubules with complete spermatogenesis elsewhere in the testicular parenchyma.

Sertoli cell-only syndrome with immature Sertoli cells Sertoli cells in adult testes with this variant of Sertoli cell-only syndrome have an immature prepubertal appearance with pseudostratification. The number of cells per cross-sectioned tubule is greater than normal. Other tubular and interstitial features suggest immaturity, including small tubular diame-

ters (<80 μm), tubules lacking central lumina, thin lamina propria lacking elastic fibers, and interstitium lacking mature Leydig cells.⁸⁸⁸⁻⁸⁹⁰

This syndrome is caused by a deficiency of both FSH and LH which begins in childhood and is responsible for the lack of maturation of the Sertoli cells, tubular walls, and interstitium. Subsequently, there is no renewal or differentiation of germ cells, and these eventually disappear. When these patients are treated with hormones, the biopsy may show some degree of spermatogenesis or thickening and hyalinization of the tubular basement membrane.

Sertoli cell-only syndrome with dysgenetic Sertoli cells Dysgenetic Sertoli cells begin pubertal differentiation but variably deviate from normal maturation, so that the morphology of dysgenetic Sertoli cells differs among tubules and even among Sertoli cells within the same tubule. Nuclei usually have both mature features (pale chromatin and a centrally located, tripartite nucleolus) and features of immaturity

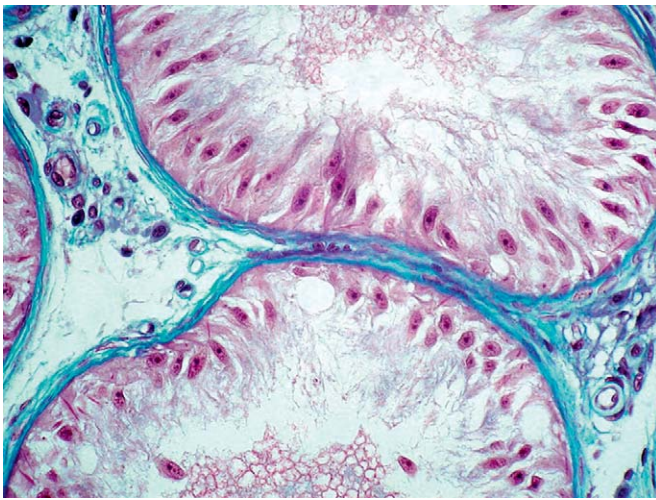


Fig. 12-89 Sertoli cell-only syndrome with dysgenetic Sertoli cells. Seminiferous tubules show slightly thickened tunica propria. The Sertoli cells are increased in number and have elongated nuclei and abundant apical cytoplasm.

(ovoid or round shape; regular outline; and small, dense chromatin granules) (Fig. 12-89).⁸⁹¹ In addition to vimentin, Sertoli cells immunoexpress anti-müllerian hormone (AMH)⁸⁹² and cytokeratin 18.⁸⁹³ Immunoreaction to these two substances is assumed to be a sign of immaturity, as under normal conditions it is not detected after puberty. Other signs of immaturity are poor development of the hematotesticular barrier⁸⁹⁴ and the absence of tubular lumina.

Tubular lumina are very small or absent in most dysgenetic Sertoli cell-containing tubules, because the ability to produce testicular fluid is greatly reduced. Sertoli cell numbers per cross-sectioned tubule are very high, and mean tubular diameter is lower than 120 μm . The tubular walls have few elastic fibers,⁵³⁴ and most tubules show a variable degree of tunica propria hyalinization.

Completely hyalinized tubules are frequent. The testicular interstitium contains a variable number of Leydig cells (normal, decreased, or apparently increased), many of which are pleomorphic with abundant paracrystalline inclusions.^{895,896}

Most patients have normal or slightly subnormal testosterone level and elevated levels of FSH and LH. This syndrome can be observed in men with cryptorchid testes, at the periphery of germ cell tumors, in men with idiopathic infertility,⁸⁹⁷ and in men with Y chromosome anomalies.⁸⁹⁸

Sertoli cell-only syndrome with mature Sertoli cells In this variant, most Sertoli cells appear mature but are present in increased numbers (14 ± 0.8 per cross-sectioned tubule). The seminiferous tubules have small diameters, but are still larger than in the two variants described above, and central lumina are visible. The cytoplasm contains abundant vacuoles that communicate with the tubular lumina (Fig. 12-90). The lateral cell surfaces have many unfolding and extensive specialized junctions with other Sertoli cells (from the basement membrane to the apical cytoplasmic portion). Lipid

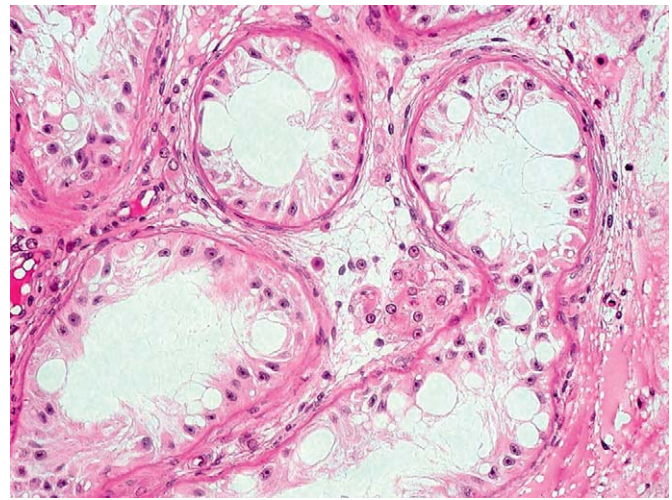


Fig. 12-90 Sertoli cell-only syndrome with mature Sertoli cells. The seminiferous tubules are lined by normal adult Sertoli cells, many with cytoplasmic vacuoles.

droplets, usually derived from phagocytosis of spermatid tubulobulbar complexes and dead germ cells, are scant.⁸⁸⁴ Vimentin filaments are abundant in the basal and perinuclear cytoplasm.⁸⁹⁹ The lamina propria is normal or slightly thickened. Leydig cells are normal.

Serum testosterone level is normal or nearly normal, and FSH and LH levels are elevated.⁹⁰⁰⁻⁹⁰² This syndrome is probably caused by failure of migration of primordial germ cells from the primitive yolk sac to the gonadal ridge.⁹⁰³ This failure may be due to a deletion in the AZFa region in Yq11⁹⁰⁴ or a mutation in the genes that encodes c-KIT or its ligand (stem cell factor), responsible for migration, proliferation, and survival of germ cells.

Sertoli cell-only syndrome with involuting Sertoli cells Testes with this variant of Sertoli cell-only syndrome have numerous changes. Sertoli cell nuclei may have lobulated shapes with irregular outlines, coarse chromatin granules, and inconspicuous nucleoli. Seminiferous tubules have central lumina, decreased diameters, and variable thickening of the basement membrane (Fig. 12-91). Elastic fibers are present in normal or diminished amounts. Leydig cells are variably involuted.

This syndrome may be a primary disorder or secondary to irradiation or cytotoxic therapy, such as cancer chemotherapy or treatment for nephrotic syndrome.⁹⁰⁵ It is not usually possible to determine the etiology from the biopsy findings alone. Changes in the tubular walls are more pronounced in patients with a history of cyclophosphamide treatment, combination chemotherapy, or radiotherapy. The testicular interstitium may be fibrotic in patients treated with cis-platinum or cyclophosphamide.⁹⁰⁶ Some syndromes with involuting Sertoli cells, mainly those associated with decreased number of elastic fibers, probably express a primary testicular anomaly with involuting and dysgenetic Sertoli cells within the same tubule.

Sertoli cell-only syndrome with dedifferentiated Sertoli cells The presence of immature-appearing Sertoli cells in

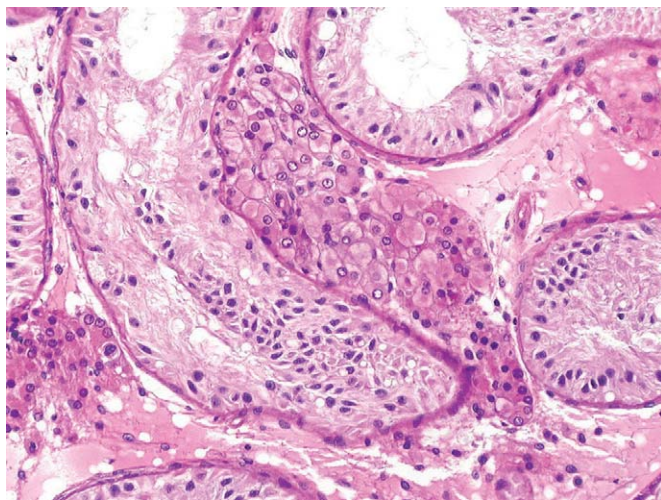


Fig. 12-91 Sertoli cell-only syndrome with involuting Sertoli cells. The Sertoli cell nuclei are hyperchromatic and have irregular outlines.

otherwise mature tubules is the most striking feature of this variant of Sertoli cell-only syndrome. Sertoli cells appear abnormally numerous due to shortening of the tubule, and nuclei are either round or elongated. Round nuclei have single, small, central or peripheral nucleoli, whereas elongated nuclei have dense clumped chromatin and small peripheral nucleoli.

The tubular wall is thickened and contains elastic fibers, increased amounts of collagen fibers, and elevated numbers of peritubular cells as a result of tubular shortening. Mean tubular diameter is markedly decreased to less than 90 μm . The testicular interstitium contains few Leydig cells, and these appear dedifferentiated or contain an increased amount of lipofuscin.

This variant has been observed in surgical specimens from patients receiving androgen deprivation therapy for prostatic cancer, estrogen treatment for transsexuality, and cancer chemotherapy with *cis*-platinum. There is a correlation between the degree of Sertoli cell dedifferentiation and the dose and timing of treatment with estrogens or anti-androgens. Brief treatment induces germ cell loss and inconspicuous Sertoli cell changes; long-term treatment causes pronounced Sertoli cell changes, including initial nuclear rounding followed by nuclear elongation and the development of dark chromatin masses.⁹⁰⁷ Eventually, the nuclei come to resemble those of infantile Sertoli cells, including pseudostratification. At the same time, the tubules become hyalinized and peritubular cells increase whereas Leydig cells disappear.^{908,909}

Estrogens act on the pituitary by inhibiting LH secretion, and on Leydig cells.⁹¹⁰ The action of gonadotropin-releasing hormone agonist analogs is only on the pituitary, whereas *cis*-platinum acts only on the testis.

Tubular hyalinization

A few azoospermic patients have diffuse hyalinization of seminiferous tubules. The incidence of this lesion is difficult to estimate, as these patients usually are not biopsied because their testes are small. Hyalinization of seminiferous tubules

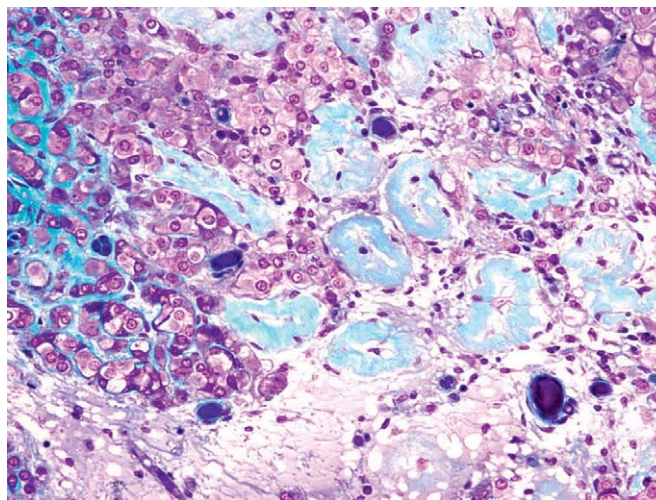


Fig. 12-92 Dysgenetic hyalinization. Fully hyalinized seminiferous tubules and a few peritubular cells among Leydig cell clusters.

is the endpoint of tubular atrophy and includes the absence of both germ cells and Sertoli cells with alterations in the lamina propria and Leydig cells. Etiology can be determined from several histologic features and clinical data, including:

- *General histologic appearance*: extent and topography of the hyalinized tubules and presence of isolated tubules containing germ cells or Sertoli cells only (dysgenetic, adult, involuting, or dedifferentiated).
- *Appearance of atrophic tubules, all showing the same pattern or variable degrees of atrophy*: tubular diameter; trophism of peritubular cells; presence of elastic fibers; degree of collagenization of the lamina propria, and the presence of cell remnants or unusual cells in the tubules.
- *Appearance of the interstitium*: number and morphology of Leydig cells; vascular lesions; and lymphoid infiltrate.
- *Chronology of testicular shrinkage*.

The most common causes of tubular hyalinization include dysgenetic hyalinization, hormonal deficit, ischemia, obstruction, inflammation, and physical or chemical agents. The differential diagnosis is given in Table 12-8.

Dysgenetic hyalinization Dysgenetic hyalinization is a diffuse lesion in which most tubules are uniformly hyalinized (Fig. 12-92). Tubules lack seminiferous tubular cells and have a reduced number of peritubular cells. The few preserved tubules usually contain only Sertoli cells, although rarely a few with spermatogenesis are present. Dysgenetic hyalinization is seen in Klinefelter's syndrome, testes that remain cryptorchid through puberty, and some hypergonadotropic hypogonadisms associated with myopathy. Focal lesions are seen in mixed atrophy of the testis.

Tubular hyalinization is pronounced in Klinefelter's syndrome, and from infancy the seminiferous tubules are small, containing reduced numbers of Sertoli cells and few or no spermatogonia. At puberty, the dysgenetic Sertoli cells fail to

Table 12-8 Differential diagnosis of tubular hyalinization

	Dysgenetic	Hormonal deficit	Ischemia	Excretory duct obstruction	Postinflammatory hyalinization	Physical or chemical agents
Hyalinized tubule size	Minimum	Minimum	Minimum	Very decreased	Minimum	Very decreased
Tubular lumen	Absent	Absent	Absent	Present	Absent	Absent
Peritubular cells	Decreased	Decreased	Decreased	Increased	Decreased or increased	Decreased
Elastic fibers	Decreased	Normal	Normal	Normal	Normal	Normal
Leydig cells	Increased or decreased, pleomorphic	Absent	Absent	Normal	Pseudo-hyperplasia	Decreased
FSH	Increased	Decreased	Increased	Increased	Increased	Increased
LH	Increased	Decreased	Increased	Increased	Increased	Increased
Testosterone	Normal or decreased	Decreased	Normal or decreased	Normal	Normal	Normal or decreased

mature and soon disappear. The tubules collapse, giving the appearance of phantom tubules.⁹¹¹ Peritubular cells fail to differentiate and their number is low.⁹¹² They form a discontinuous ring around the hyalinized tubules and are incapable of synthesizing elastic fibers and other components of the lamina propria. Dysgenesis also involves the interstitium: Leydig cells exhibit a characteristic adenomatous pattern, although their total number is decreased. The morphology of the Leydig cell is not uniform, and there are shrunken, normal, and large forms. Most contain reduced amounts of lipofuscin granules and lipid droplets. Reinke's crystalloids are uncommon, and paracrystalline inclusions are abundant.⁸⁹⁶ In spite of the hyperplastic adenomatous appearance of the Leydig cells, testosterone secretion is markedly decreased, and the resulting hypogonadism is the most important clinical feature of Klinefelter's syndrome.

Tubular hyalinization in the cryptorchid testis is also dysgenetic. However, in contrast to the atrophic collapse seen in Klinefelter's syndrome, cross-sections of the hyalinized tubules in cryptorchidism are targetoid. This results from the arrangement of the peritubular cells into two layers, suggesting an atrophic process that has evolved over a longer period than in Klinefelter's syndrome, or a lower degree of dysgenesis.⁹¹³ Elastic fibers are diminished.⁵³⁴ In the interstitium Leydig cells appear hyperplastic, forming large aggregates, although their absolute numbers are decreased. Leydig cell pleomorphism is less intense than in Klinefelter's syndrome. Many Leydig cells have abundant vacuolated cytoplasm. Whereas tubular hyalinization in Klinefelter's syndrome is secondary to the effect of pubertal gonadotropin secretion on dysgenetic tubules, tubular hyalinization in cryptorchidism probably results from the effect of increased temperature on the dysgenetic tubules. However, other mechanisms are also involved in cryptorchid tubular hyalinization, including obstruction of sperm excretory ducts (anomalies in these ducts are frequent in cryptorchidism) and ischemia (principally in testes that could only be incompletely descended by surgery).

Hyalinization caused by hormonal deficit Hormonal deficit causes diffuse tubular hyalinization, although the tubules

may be recognized for a time as cellular cords surrounded by hyaline material. Sertoli cell, a few spermatogonia, and rare primary spermatocytes may be identified in these cords. When hyalinization is complete, only the elastic fibers in the lamina propria indicate the structure of the previously normal adult testis. Peritubular myofibroblasts decrease in number and form a ring at the periphery of the lamina propria. Leydig cells disappear as hyalinization progresses, and the few that remain have pyknotic nuclei and shrunken cytoplasm with abundant lipofuscin granules.

This process manifests clinically as postpubertal hypogonadotropic hypogonadism and is usually caused by a lesion in or near the pituitary, such as pituitary adenoma, craniopharyngioma, and trauma to the cranial base or sella turcica (see discussion on hypogonadotropic hypogonadism in this chapter).

Ischemic hyalinization Ischemic atrophy is usually caused by torsion of the spermatic cord, vascular injury during inguinal surgery,⁹¹⁴ polyarteritis nodosa, and severe arteriosclerosis.⁹¹⁵ Except for cases caused by torsion of the cord, these patients usually are not referred to infertility clinics.

Torsion of the spermatic cord often is not listed as a cause in large series of infertile patients. However, follow-up of men with torsion reveals marked alteration in their spermograms. Several hypotheses have been offered to explain the low number of sperm produced by the contralateral normal testis; the most promising include response to the release of antigens by the ischemic testis, and primary lesions of the contralateral testis⁹¹⁶ (see discussion on testicular torsion in this chapter).

Testicular anoxia caused by torsion rapidly produces severe lesions that are irreversible without adequate treatment. Eight hours after torsion, there is intense hemorrhagic infarction of the seminiferous tubular cells. Chronic anoxia leads to tubular hyalinization and loss of Leydig cells (Fig. 12-93).

Testicular atrophy secondary to inguinal hernia surgery occurs in 0.03–0.5% of patients in the first repair, and in 0.8–5% in surgery for recurrent hernia. Atrophy is most fre-

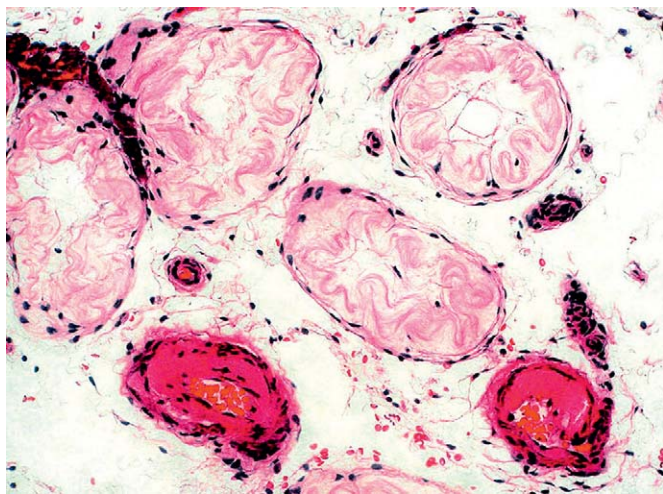


Fig. 12-93 Ischemic tubular hyalinization. Fully hyalinized seminiferous tubules are surrounded by peritubular cells. The testicular interstitium lacks Leydig cells and shows arteriolar hyalinization.

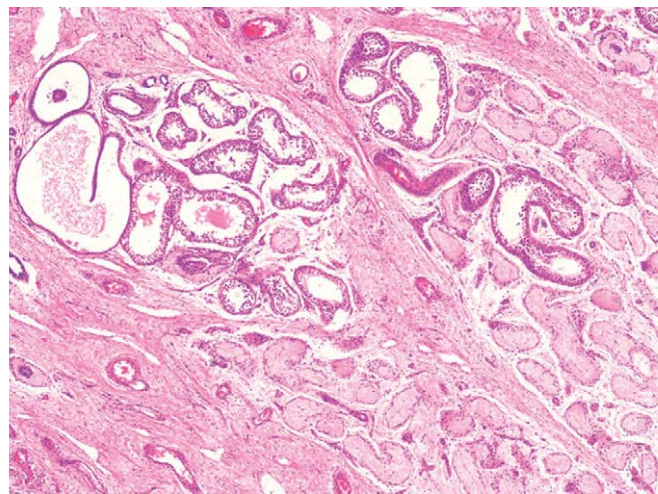


Fig. 12-94 Post-obstructive hyalinization. Seminiferous tubules with marked ectasis with hyalinized tubules. Leydig cell clusters are seen among the hyalinized tubules.

quent in cases that require extensive dissection of the spermatic cord.

Postobstructive hyalinization Obstruction of sperm excretory ducts may cause atrophy of seminiferous tubules. In order to produce tubular hyalinization, the obstruction must be close to the testis because the ductuli efferentes in the caput epididymis absorb about 90% of tubular fluid and protect the testis from excessive intratubular pressure. Obstructive tubular hyalinization is usually focal and secondary to varicocele and other disorders involving dilation of the channels of the rete testis. These may be congenital, as in epididymis–testis dissociation, or acquired, as in rete testis dilation secondary to epididymal atrophy caused by arteritis, arteriosclerosis, or androgen insufficiency. Obstructive tubular hyalinization also occurs in the seminiferous tubules at the periphery of the testis in patients who have had orchitis.⁹¹⁷

Obstructive hyalinization has a mosaic distribution: lobules of completely hyalinized tubules are intermingled with lobules of normal tubules (Fig. 12-94). The diameter of the hyalinized tubules is not as small as in other causes of hyalinization, and the tubules occasionally contain Sertoli cells. In the centers of many of the tubules there is a small lumen or vacuole, the latter in the cytoplasm of a residual Sertoli cell.⁹¹⁸ The lamina propria is thick and contains hypertrophic peritubular cells and abundant extracellular material. Finally, the peritubular cells dedifferentiate and only fibroblasts remain.⁹¹⁹ The interstitium contains a normal number of Leydig cells forming small clusters, some of which are among hyalinized tubules. This is not seen in other patterns such as ischemic hyalinization. In addition, dilated veins with eccentrically hyalinized walls can be seen in testes associated with varicocele. This lobular pattern of tubular atrophy causes a peculiar ultrasound image which has been described as a striated pattern.^{920,921}

Postinflammatory hyalinization Many infections of the testis cause irreversible lesions in the seminiferous tubules. In bacterial infection the epididymis is usually involved, resulting

in obstructive azoospermia. In viral infection the testis is often affected, even without symptoms. Two types of viral orchitis often cause infertility, including mumps orchitis and Coxsackie B orchitis.

Tubular atrophy caused by viral infection has a mosaic topography in which hyalinized and normal tubules are intermingled. In fully hyalinized tubules, the only recognizable cells are peritubular cells that form an incomplete, peripheral ring around the hyalinized material. The presence of elastic fibers in these tubules distinguishes this from dysgenetic hyalinization. Leydig cells form clusters of variable size, but their total number is normal. In bacterial infection the pattern of tubular hyalinization is variable.

Tubular atrophy of unknown etiology may be caused by an autoimmune response. This appears to occur in hypogonadism associated with disorders in other endocrine glands, such as Addison's disease associated with gonadal insufficiency; adrenal–thyroid–gonadal insufficiency; and the association of diabetes, hypogonadism, adrenal insufficiency, and hypothyroidism. The testicular lesions are morphologically similar to those seen in the seminiferous tubules at the periphery of germ cell tumor and in testes with burn-out germinal cancer. In the initial stages of hyalinization associated with germ cell neoplasm, the tubules are small, contain intratubular germ cell neoplasia and dedifferentiating Sertoli cells, and the lamina propria is infiltrated by macrophages, lymphocytes, and plasma cells. In the final stages, the intratubular cells have degenerated, the inflammation has disappeared, and the seminiferous tubules are replaced by areas of hypocellular or acellular fibrosis (Fig. 12-95). It should be noted that autoimmune hyalinization is not the most common type of hyalinization associated with testicular tumors: the obstructive, ischemic, and dysgenetic variants are more common.

Hyalinization caused by physical or chemical agents Radiation and a wide variety of chemicals cause tubular hyalinization. Lengthy cancer chemotherapy combined with

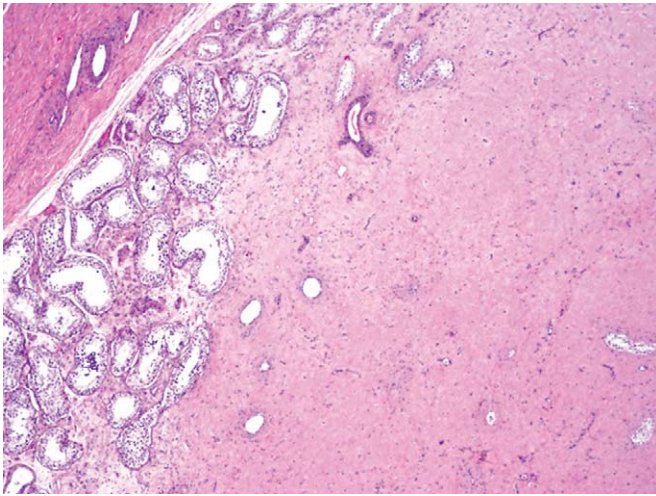


Fig. 12-95 Post-inflammatory hyalinization. Most of the testis consists of cicatricial tissue with no recognizable seminiferous tubules.

radiotherapy invariably causes hyalinization. Children's testes are more sensitive to radiation than those of adults. Radiation for testicular leukemia frequently causes tubular hyalinization. In addition, radiation induces dense interstitial fibrosis and loss of peritubular cells, obscuring the borders between the interstitium and the tubules. This makes the tubules hard to see in hematoxylin–eosin-stained sections. Leydig cells are atrophic and decreased in number. Ischemia secondary to radiation-induced vascular injury also contributes to hyalinization.

In tubular hyalinization associated with cancer chemotherapy, in addition to the direct toxicity of drugs on seminiferous tubular cells (see discussion on Sertoli cell-only syndrome with involuting Sertoli cells in this chapter), nutritional deficiencies cause hypogonadotropic hypogonadism.^{922,923}

Diffuse lesions in spermatogenesis

Histophysiological studies have distinguished two compartments in the seminiferous tubules: basal and adluminal. The blood–testis barrier separates these, and each contains different cell types with diverse hormonal and nutritional requirements. On this basis, lesions may be classified as involving only the adluminal compartment or both the basal and the adluminal compartments. The following discussion of spermatogenic lesions uses this new concept of tubular pathophysiology, conserving as much as possible of the classic terminology.

Lesions in the adluminal compartment of seminiferous tubules This category includes all infertile testes with normal numbers of spermatogonia per cross-sectioned tubule, normal or decreased numbers of spermatocytes and young spermatids, and variable numbers of adult spermatids. A descriptive term for this disorder is immature germ cell sloughing.

A few immature germ cells are normally found in the lumina of the seminiferous tubules,⁹²³ a finding that correlates with their presence in the ejaculates of fertile men.⁹²⁴

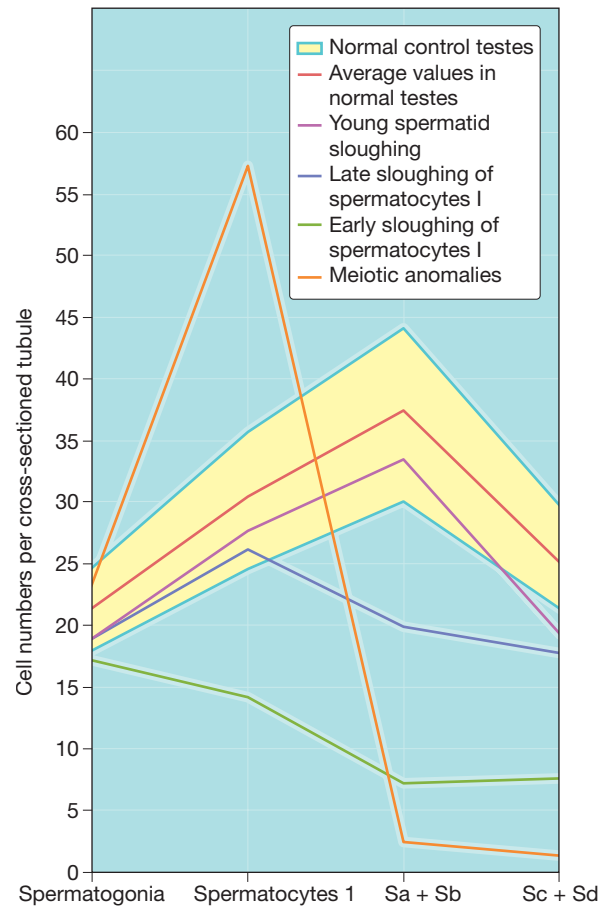


Fig. 12-96 Germ cell number per cross-sectioned tubule in patients with lesions in the adluminal compartment of the seminiferous tubules.

When these cells make up more than 4% of the cells in the ejaculate, it is abnormal and the result of premature sloughing of spermatids and, in some cases, of spermatocytes.^{925,926} Some authors have attempted to establish a correlation between the number of sloughed immature germ cells and the severity of lesions of the seminiferous tubules using light⁹²⁷ and electron⁹²⁸ microscopy.

Lesions in the adluminal compartment are classified according to the most abundant type of germ cell whose maturation is arrested and which then sloughs: young spermatids, late primary spermatocytes, or early primary spermatocytes (Fig. 12-96).

Young spermatid sloughing Young spermatid sloughing is present when the ratio of elongated ($S_c + S_d$) spermatids to round ($S_a + S_b$) spermatids is lower than normal. The implication of this pattern is that many round spermatids are incapable of further differentiation and are sloughed (Fig. 12-97).

Late primary spermatocyte sloughing In this condition, spermatogenesis develops normally up to the level of interphase primary spermatocytes, and these are present in normal numbers. Afterwards, these spermatocytes degenerate without achieving meiosis and slough into the tubular lumen. All types of spermatid are greatly reduced in number.

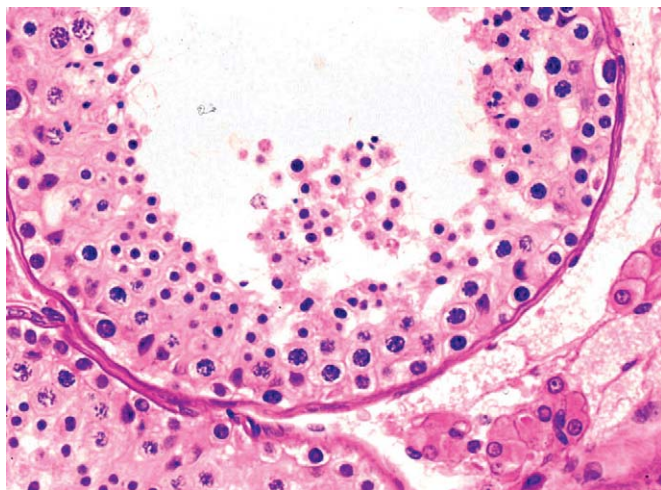


Fig. 12-97 Seminiferous tubule with dilated lumen and moderate young spermatid sloughing.

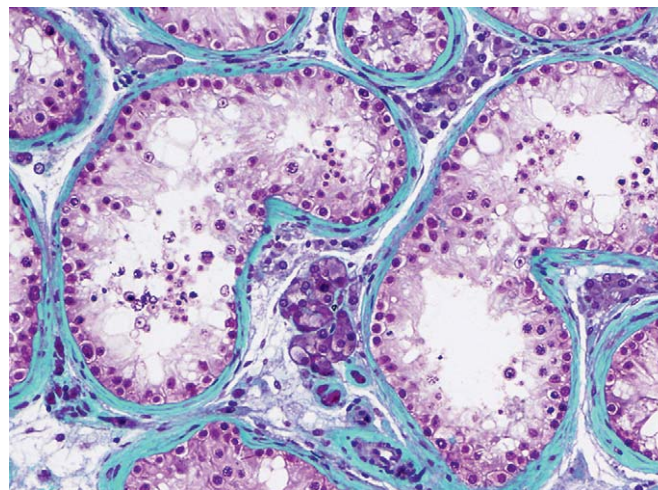


Fig. 12-99 Seminiferous tubule with dilated lumen, apical vacuolation of Sertoli cells, normal number of spermatogonia, and decreased number of other germ cell types.

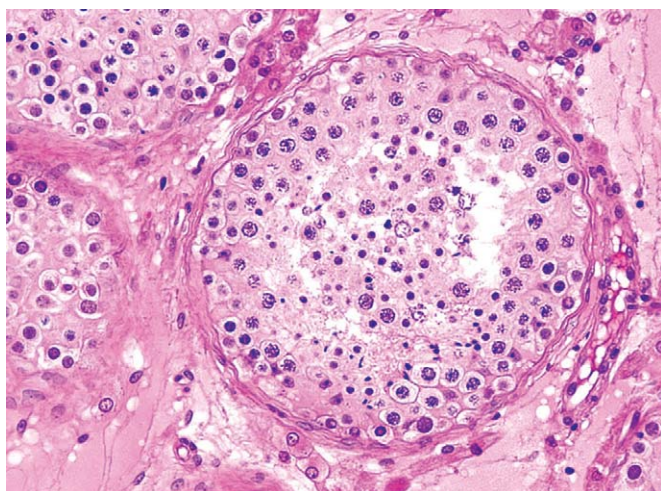


Fig. 12-98 Seminiferous tubule with sloughing of both primary spermatocytes and young spermatids.

When biopsies of these testes are not properly fixed, the seminiferous tubules may have a target-like appearance, with numerous cells in the lumen. This appearance sometimes has been referred to as tubular blockage. Another descriptive term, spermatogenic arrest, also has been applied to this morphology. The latter term is inadequate in most cases, because some spermatids are present, and the number of primary spermatocytes is usually not increased as would occur if the transformation of spermatocyte into spermatid were blocked (Fig. 12-98). Late spermatocyte sloughing is a more accurate term for this condition and is preferred. Primary spermatocyte sloughing occurs at the pachytene or diplotene stage of meiosis.

Early primary spermatocyte sloughing This lesion is characterized by the presence of a normal number of spermatogonia and decreased numbers of primary spermatocytes (Fig. 12-99). The seminiferous tubules may contain a few spermatids.

The term early primary spermatocyte sloughing does not necessarily imply an early meiotic lesion, which is quite rare.^{856,926} Rather, it refers to the sloughing of newly formed spermatocytes. The Sertoli cells may show vacuolation of the apical cytoplasm as an expression of germ cell loss. This lesion is more severe than that in testes with late primary spermatocyte sloughing, and is considered to result from failure of the Sertoli cells to maintain the adluminal compartment.

Etiology The mechanisms causing adluminal compartment lesions can be classified into obstructive and non-obstructive. Obstruction is present in more than 70% of cases, and is characterized by variability of involvement among lobules and the presence of at least two of the following abnormalities: enlargement of tubular diameter and a lumen with remarkable differences among lobules; Sertoli cells with adherens germ cells protruding into the lumen, giving an indented outline; intense apical vacuolation of Sertoli cell cytoplasm; accumulation of spermatozoa in the lumen of some tubules; or number of spermatids $S_c + S_d$ is higher than that of $S_a + S_b$ (see Testicular lesions resulting from obstruction of sperm excretory ducts).⁹²⁹

The three levels of severity of adluminal compartment lesions emphasized by the terms young spermatid sloughing, later primary spermatocytes sloughing, and early primary spermatocyte sloughing, depend on the degree (total or partial) of obstruction and the level of sperm excretory duct obstruction: as the obstruction gets nearer to the testis, the greater the severity. Obstruction may be extratesticular (epididymis, vas deferens, and ejaculatory ducts) or intratesticular (rete testis or any level of the seminiferous tubule length). The most frequent causes of extratesticular excretory duct obstruction are vasectomy, inflammation (epididymitis, prostatitis), mucoviscidosis (congenital bilateral absence of vas deferens), and testis-epididymis dissociation.

Rete testis obstruction. Varicocele is the most frequent cause of obstruction of the rete testis. More than 50% of testes with

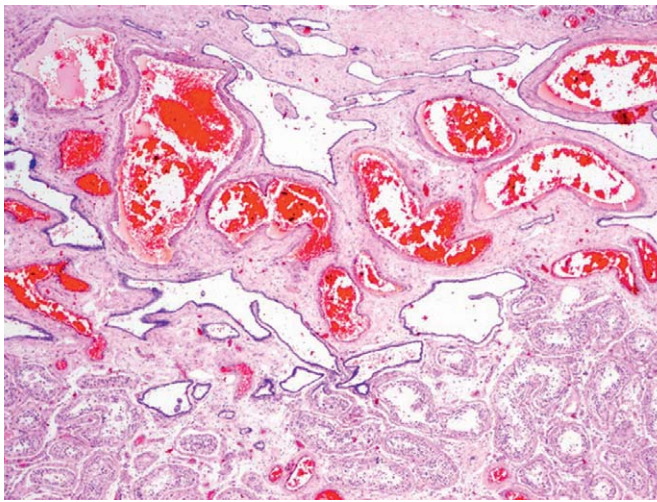


Fig. 12-100 Mediastinum testis from a young man with varicocele. Marked venous dilation (intratesticular varicocele) disrupts and compresses the rete testis cavities, causing partial obstruction of the tubuli recti.

varicocele have a mosaic pattern of tubular lesions, together with marked dilation and eccentric mural fibrosis of intratesticular veins. In normal testes, the walls of veins are extremely thin and the lumina nearly collapsed. Varicocele patients also often have spermatozoa with characteristically elongated heads with thin bases.⁹³⁰ Initially, abnormalities are confined to the testis ipsilateral to the varicocele, but eventually both testes are affected, although abnormalities are more severe in the ipsilateral testis. Elevated pressure in the pampiniform plexus is transmitted to the veins within the testes, principally to the centripetal veins that cross the testicular mediastinum and drain most of the testicular parenchyma (Fig. 12-100).⁹³¹ The dilated centripetal veins compress the intratesticular sperm excretory ducts, explaining the mosaic distribution of the tubular lesions.⁹³²

Seminiferous tubule obstruction. Obstruction at the level of the seminiferous tubules can be dysgenetic or post-orchitic. A dysgenetic cause may be suspected in specimens with a mosaic distribution of lesions and seminiferous tubules with small diameters, thickened lamina propria, and an unusual seminiferous tubular cell layer consisting of cuboidal Sertoli cells and spermatozoa that clog the lumina (Fig. 12-101). The diagnosis is confirmed if study of serial sections demonstrates continuity between these tubules and those with conserved spermatogenesis. The structure of seminiferous tubules has been observed with scanning microscopy at such points of continuity.^{858,933} Tubular stenosis appears to be due to a primary anomaly of Sertoli cells and peritubular cells.

Post-orchitic obstruction should be suspected in cases of tubular atrophy with a mosaic pattern without dysgenetic tubules or varicocele. Some patients have a history of orchitis associated with parotiditis;⁹³⁴ in others the only findings are oligozoospermia and small testes. Testicular biopsy, sampling only the testicular periphery, reveals only the consequences of obstruction, lesions similar to those observed with varicocele. However, some postinflammatory changes

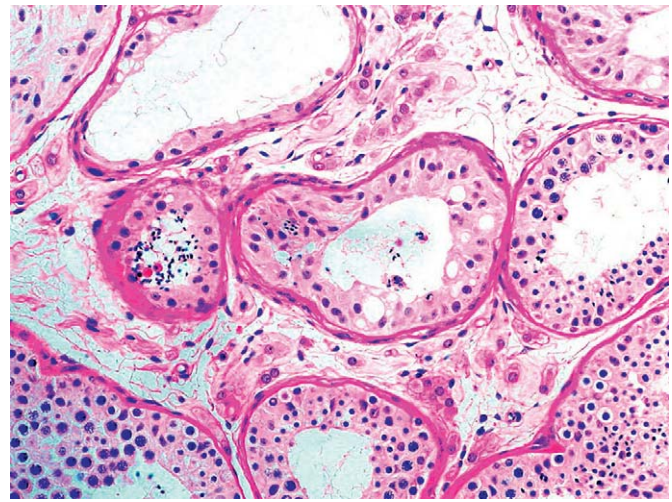


Fig. 12-101 Segmentary dysgenesis of seminiferous tubules. The two central tubules, which only display dysgenetic Sertoli cells, contain numerous spermatozoa from adjacent seminiferous tubules with normal spermatogenesis.

should also be present, including hyalinized tubules, dilated tubules lined by cuboidal Sertoli cells, or complete spermatogenesis. Occasionally, there is modest perivascular or peritubular inflammation and angiectasis.^{935,936}

About 30% of testes with lesions in the adluminal compartment have no obstruction, and most have primary anomalies of germ cells. This claim is supported by the following: pronounced decrease of germ cell type when the preceding type is greatly increased in number; normal correlation between the number of mature spermatids in biopsy and number of spermatozoa in the spermogram; and the presence of numerous malformed germ cells in the adluminal compartment.

Decrease in the number of a germ cell type may be so important that spermatogenesis is arrested, with subsequent azoospermia. In some cases, maturation arrest is only partial and results in severe oligozoospermia. This maturation arrest is observed mainly in primary spermatocytes and young spermatids.

Primary spermatocyte sloughing may also be owing to meiotic anomalies (Fig. 12-102). The observation of increased numbers of spermatocytes arrested in preleptotene–leptotene⁹²⁶ or, more frequently, pachytene⁸⁵⁶ suggests the diagnosis. The lesion is always bilateral. Spermatocytes arrested in pachytene are usually increased in size and later degenerate. In addition, some spermatids have large, diploid, spherical, hyperchromatic nuclei. The anomaly does not always affect all spermatocytes, and then a higher number of spermatids are produced.⁸⁵⁶

Young spermatid sloughing not associated with obstruction may be due to either meiotic anomalies or defective spermiogenesis. The former gives rise to the appearance of many multinucleate, polyploid, hyperchromatic young spermatids. In the second cause, young spermatids are incapable of transforming into mature spermatids, and only round spermatids appear in the ejaculate.

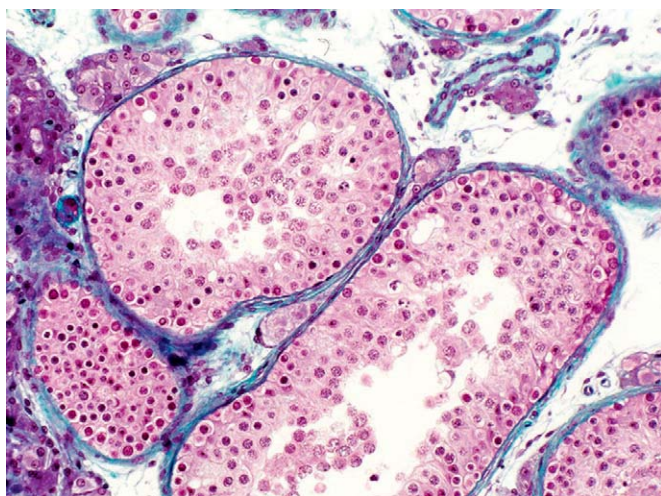


Fig. 12-102 Meiotic abnormalities. The seminiferous tubules contain normal number of spermatogonia and disproportionately high number of primary spermatocytes which do not complete meiosis. No spermatozoa are seen.

Lesions in basal and adluminal compartments of seminiferous tubules Lesions in the basal and adluminal compartments of seminiferous tubules are the most frequent histological findings in testicular biopsies from infertile men. These testes may be classified into two major subgroups: hypospermatogenesis and spermatogonial maturation arrest (Fig. 12-103).

Hypospermatogenesis: Types and etiology Hypospermatogenesis is defined as a reduced number of spermatogonia and primary spermatocytes, with primary spermatocytes outnumbering the spermatogonia. Most seminiferous tubules contain few spermatozoa. About 8% of patients with hypospermatogenesis have focal tubular hyalinization.⁹³⁷ Two variants of hypospermatogenesis have been quantitatively distinguished: pure hypospermatogenesis, and hypospermatogenesis associated with sloughing of primary spermatocytes.

Pure hypospermatogenesis is defined as a proportionate decrease in the number of all types of germ cell. The number of spermatogonia per cross-sectioned tubule is less than 17 and usually more than 10. The number of primary spermatocytes is equal to or higher than that of spermatogonia. The number of round spermatozoa is higher than that of primary spermatocytes, and the number of elongated spermatozoa is similar to that of spermatogonia (Fig. 12-104).

Hypospermatogenesis associated with primary spermatocyte sloughing is characterized by two features: low numbers of spermatogonia and primary spermatocytes (with spermatocytes more numerous than spermatogonia), and degeneration and sloughing of many primary spermatocytes. The remaining spermatozoa give rise to the few spermatozoa observed in the tubules (Fig. 12-105).

Etiology of hypospermatogenesis. Hypospermatogenesis may result from hormonal dysfunction, congenital germ cell deficiency, Sertoli cell dysfunction, Leydig cell dysfunction,

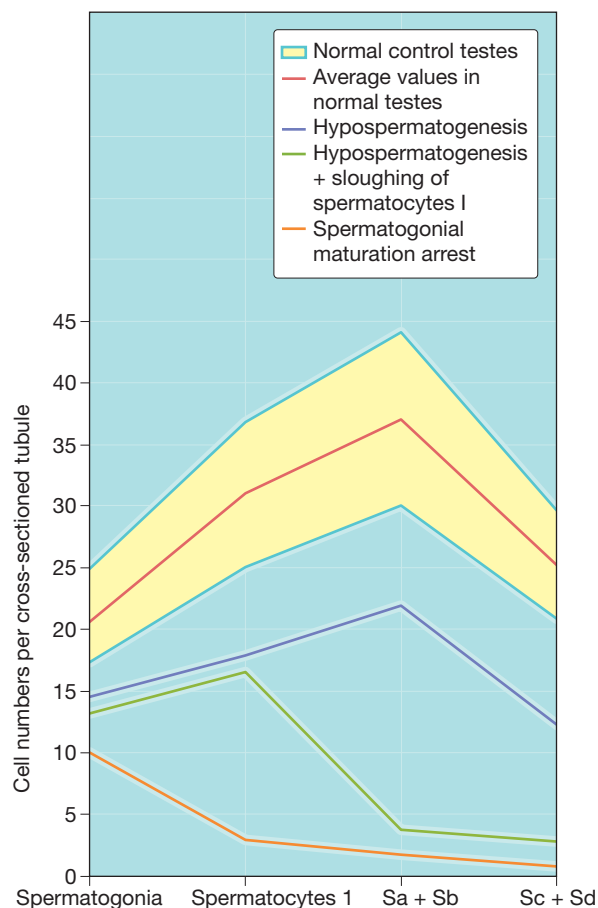


Fig. 12-103 Germ cell number per cross-sectioned tubule in patients with lesions in the basal and adluminal compartments of the seminiferous tubules.

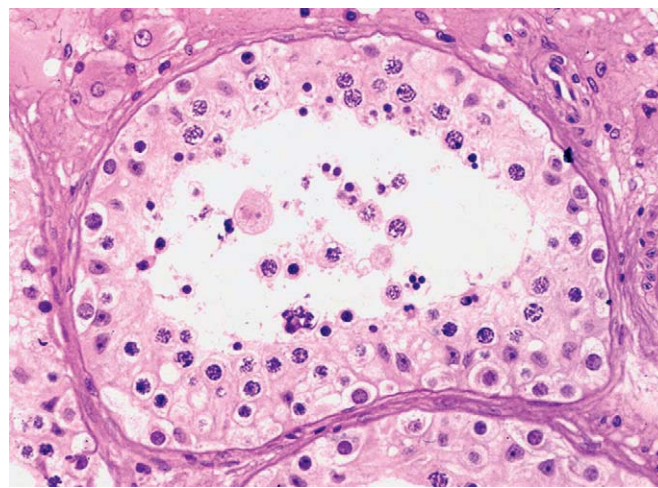


Fig. 12-104 Pure hypospermatogenesis in a patient with severe oligozoospermia. The seminiferous tubule shows slight ectasia and a proportionate decrease of all germ cell types.

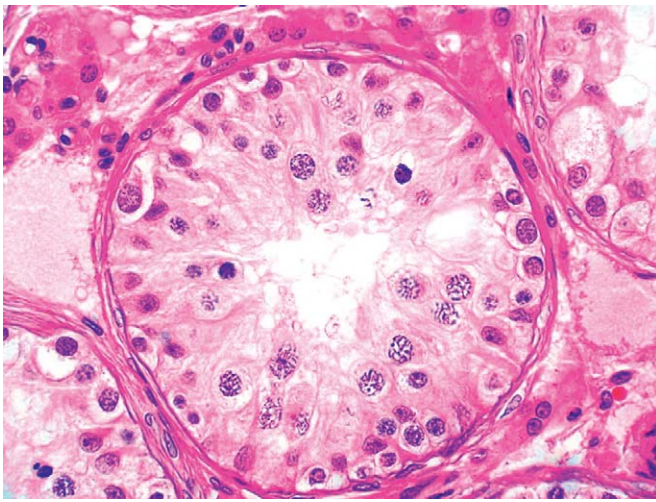


Fig. 12-105 Hypospermatogenesis associated with primary spermatocyte sloughing in an azoospermic patient. Spermatogonia and primary spermatocytes are the sole germ cell types.

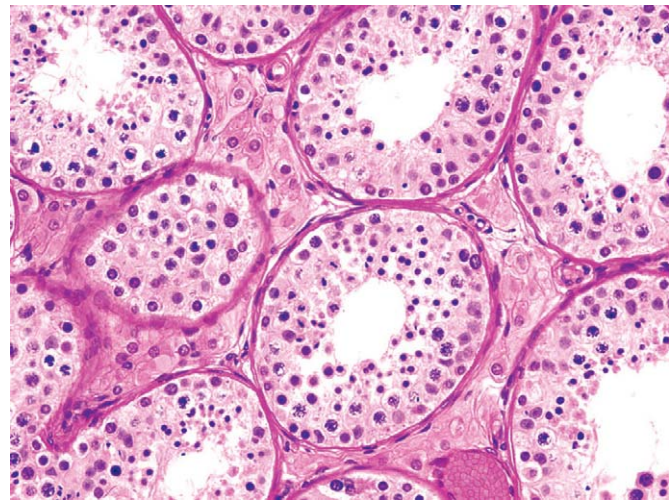


Fig. 12-106 Hypospermatogenesis due to androgen receptor defect. The seminiferous tubules show hypospermatogenesis associated with diffuse Leydig cell hyperplasia.

androgen insensitivity, exposure to chemical or physical agents, and vascular malfunction.

Hormonal dysregulation. Although complete spermatogenesis may be observed in men with low levels of FSH and LH, the production of a normal number of spermatozoa requires normal gonadotropin levels. Hypospermatogenesis has been reported in patients with abnormal pulsatile secretion of FSH and LH,⁹³⁸ low gonadotropin secretion,⁹³⁹ biologically inactive gonadotropins, mutation in the gonadotropin β subunit,⁹⁴⁰ inactivating mutation of FSH receptor gene,⁹⁴¹ hyperprolactinemia, and adrenal and thyroid dysfunction (see discussion on hypogonadisms secondary to endocrine gland dysfunction in this chapter).

Congenital germ cell deficiency. Biopsy of cryptorchid patients after orchidopexy reveals that spermatogonia proliferation is decreased and germ cell development is insufficient in adulthood even if the number of spermatogonia was normal in infancy. Is it likely that this poorly understood primary anomaly of germ cells is present in some cases of hypospermatogenesis.

Sertoli cell dysfunction. For many years, primary germ cell deficiency was considered the most common cause of hypospermatogenesis; today, it is known that Sertoli cell failure is the cause of many cases of germ cell deficiency. This conclusion is based on several findings. Sertoli cells in many infertile patients are markedly abnormal, with an increase in the number of glycogen granules⁹⁴² and acid phosphatase activity;⁸⁸⁴ a decrease in the number of lipid droplets; and alterations in the cytoskeleton,⁹⁴³ the nucleus,⁹⁴⁴ and cytoplasmic organelles.⁹⁴⁵ In some cases Sertoli cells have abnormal maturation, with elongated nuclei containing coarse clumped chromatin instead of triangular-shaped nuclei with pale chromatin. Anomalies in Sertoli cell FSH receptors may be present in idiopathic oligozoospermia associated with elevated levels of FSH.⁹⁴⁶ Serum inhibin B concentration may be used as a marker to estimate Sertoli cell function.⁹⁴⁷

Leydig cell dysfunction. Testosterone synthesis by Leydig cells is necessary for normal spermatogenesis,⁹⁴⁸ and abnormal Leydig cell function is a frequent finding in idiopathic oligozoospermia.^{949–951} Leydig cell dysfunction should be suspected when the cells appear diffusely hyperplastic. Patients have elevated serum LH level with depletion of rapid-release testosterone, revealing a lack of early response of Leydig cells to gonadotropin-releasing hormone stimulation. The ratio of testosterone to LH in the plasma indicates the degree of Leydig cell dysfunction. Decreased ratio with normal testosterone level suggests compensated dysfunction. Patients with a ratio of less than 1:5 and normal other parameters may have complete spermatogenesis.⁹⁵¹

Androgen insensitivity. Some patients with severe oligozoospermia or azoospermia have a defect in androgen receptor responsiveness, similar to that in Reifenstein's syndrome.^{952–954} The abnormality may arise from a genetic defect in the eight exons that code for this receptor, mapped to Xq11-12,⁹⁵⁵ or from post-translational errors.^{956,957} This defect is also referred to as infertile male syndrome and mild androgen insensitivity, and the patients have male phenotype with somatic features of slight androgen deficit.⁹⁵⁸ Histologically, the testis is similar to that observed with Leydig cell dysfunction or mixed atrophy, although the mechanism causing the Leydig cell hyperplasia is quite different (Fig. 12-106). Peripheral resistance to testosterone action alters regulation of the hypothalamohypophyseal–testicular axis, and LH and testosterone levels are elevated. Androgen insensitivity causes between 10%⁹⁵⁹ and 40%⁹⁶⁰ of all cases of severe oligozoospermia or azoospermia. In such cases spermatogenesis improves with the administration of tamoxifen citrate,⁹⁶⁰ clomiphene citrate, or androgen therapy.^{961,962} Calculation of the index of androgen insensitivity can be helpful: plasma LH (mIU/mL) \times plasma testosterone levels (ng/mL). In patients with androgen insensitivity, the index is higher than 200 (normal is about 102).

Physical and chemical agents. The number of chemicals implicated in infertility increases daily. A detailed history is invaluable in evaluating these patients. The same is true of physical agents such as prolonged exposure to heat, ionizing radiation, or microwave radiation.⁹⁶³

Etiology of hypospermatogenesis associated with primary spermatocyte sloughing. Most testes with primary spermatocyte sloughing have varicocele, and this is commonly associated with infertility.⁹⁶⁴⁻⁹⁶⁷ Varicocele is found in 15% of the general population, and is present in 30-40% of infertile men. The mechanism by which varicocele affects fertility is unknown. Clinical varicocele may occur without a testicular lesion (or only phlebectasis), and subclinical varicocele may be associated with severe spermatogenic lesions. Increased testicular temperature^{968,969} and compression of intratesticular sperm excretory ducts by dilated veins⁹³² are the most plausible mechanisms. In other cases, primary spermatocyte sloughing results from anomalies of primary spermatocytes and spermatids, suggesting a meiotic anomaly. Finally, in some patients the cause may be the presence of involuting Sertoli cells.

Spermatogonial maturation arrest Spermatogonial maturation arrest is a disorder defined by the presence of fewer than 17 spermatogonia per cross-sectioned tubule and even fewer primary spermatocytes. Spermatids are usually absent. There have been attempts to correlate the etiology of spermatogonial maturation arrest with the Sertoli cell type present.⁹⁷⁰ Immature Sertoli cells are characteristic of hypogonadotropic hypogonadism and some syndromes with androgen insensitivity (Fig. 12-107). Mature Sertoli cells, if their presence is unilateral, are observed in varicocele, epididymitis, and ipsilateral testicular traumatism, but if they appear in both testes the etiology is unknown. Involuting Sertoli cells are usually present bilaterally; some cases are idiopathic, whereas others are associated with a history of alcoholism or chemotherapy. Dedifferentiated Sertoli cells

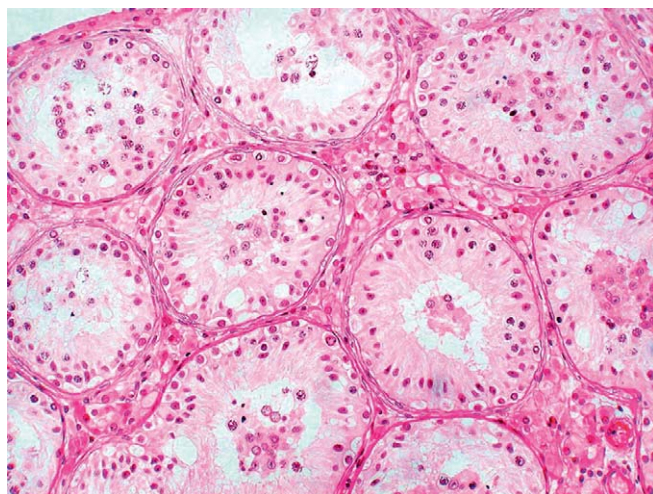


Fig. 12-107 Spermatogonial maturation arrest. The seminiferous tubules have increased numbers of Sertoli cells and nearly normal number of spermatogonia, while the remaining germ cell types are scant. The testicular interstitium shows diffuse Leydig cell hyperplasia.

are found in spermatogonial maturation arrest caused by gonadotropin inhibition in treatment with estrogen, -releasing hormone agonist, or anti-androgen.⁹⁷¹

Focal lesions in spermatogenesis (mixed atrophy)

Mixed atrophy is a descriptive term for the coexistence, in the same testis, of tubules containing only Sertoli cells and tubules with complete or incomplete spermatogenesis.⁹⁷² This disorder includes patchy failure of spermatogenesis and partial del Castillo's syndrome.

The extent of Sertoli cell-only tubules varies widely. Tubules with spermatogenesis may be normal or partially atrophic. Tubular hyalinization is occasionally seen (Fig. 12-108). Mixed atrophy is more common than suggested by the literature, and many cases are included under other diagnoses, such as 'hypospermatogenesis with a severe germ cell depletion in such a way that some Sertoli cell-only tubules are seen,'⁸⁵⁹ and 'Sertoli cell-only syndromes with focal spermatogenesis.'⁹⁷³

Serial sections from testes with mixed atrophy reveal that the two different types of tubule are grouped according to their histologic pattern, suggesting that the distribution is by testicular lobules. In cases of mixed atrophy, the percentage of tubules with spermatogenesis, the degree of spermatogenic development in the tubules, and the type of Sertoli cell present should be reported. Correlation of the first two with the spermiogram gives an indication of prognosis, and the Sertoli cell types identifies the nature (primary or secondary) of the lesion.⁹⁷⁴

Mixed atrophy (probably primary) is observed in idiopathic infertility, cryptorchidism (even if orchidopexy was done at infancy, in both the cryptorchid and the contralateral descended testis), retractile testes, macroorchidism, intravaginal torsion of the spermatic cord (in both twisted and contralateral testis), and chromosomal anomalies such as Down's syndrome, 47/XYY karyotype, 46/XX karyotype,

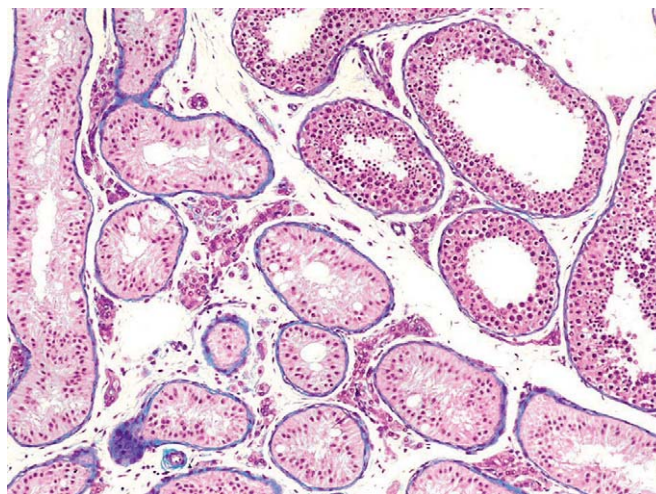


Fig. 12-108 Mixed atrophy. Seminiferous tubules with slight ectasis and complete spermatogenesis adjacent to Sertoli-cell-only pattern. The tubular lesions probably belong to different lobules.

giant Y chromosome, Klinefelter's syndrome with chromosomal mosaicism, partial androgen insensitivity, and some male pseudohermaphrodites. Secondary mixed atrophy may be seen in patients undergoing chemotherapy, corticoid therapy,⁹⁷⁵ or in those with a history of viral orchitis.

Germ cell anomalies in infertile patients

In addition to anomalies in the seminiferous tubules, examination of the biopsy should include a description of the morphology of the germ cells.

Giant spermatogonia

Giant spermatogonia are a normal component of the seminiferous epithelium. These cells may be altered spermatogonia in the S or G₂ phases of the cell cycle. They rest on the basal lamina and have pale cytoplasm and an ovoid nucleus measuring at least 13 μm in diameter. The frequency of these cells in normal and infertile men is about 0.65 cells per 50 cross-sectioned tubules, although their number is usually higher in mixed atrophy. These cells should not be mistaken for intratubular germ cell neoplasia; they are also present in normal numbers in tubules at the periphery of germ cell tumor (Fig. 12-109).⁹⁷⁶

Multinucleate spermatogonia

Multinucleate spermatogonia are a common finding in cryptorchid testes that were surgically corrected, infertile patients, and old men. Nuclei of both Ad and Ap spermatogonial types may be seen within the same cell.

Dislocated spermatogonia

Normally, spermatogonia are present only in the transition zone between the seminiferous tubule basal layer and the tubuli recti. Dislocated spermatogonia have been found throughout the testis in old age,⁹⁷⁷ in infertile patients with a variety of lesions, after long-term estrogen therapy,⁹⁷⁸ and in seminiferous tubules with intratubular germ cell neoplasia.⁹⁷⁹

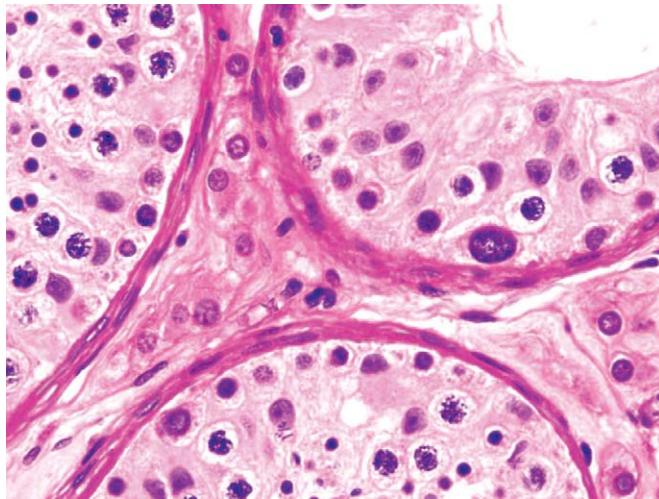


Fig. 12-109 Hypertrophic spermatogonia in a seminiferous tubule showing marked decrease in the number of spermatogenic cells.

Megalospermatocytes

Megalospermatocytes are large primary spermatocytes arrested in the leptotene stage (Fig. 12-110)⁹⁸⁰ that exhibit asynapsis of chromosomes.⁹⁸¹ Joined by cytoplasmic bridges, they form small groups. These cells may be clones of synchronously degenerating spermatocytes.⁹⁸² They are frequently found in elderly men and are a non-specific finding in infertile patients.

Multinucleated spermatids

The presence of spermatids with multiple nuclei (from 2 to 86) is frequent in old age.⁹⁸³ Similar cells with fewer nuclei have also been reported in infertility due to cryptorchidism,⁹⁸⁴ hyperprolactinemia, and idiopathic infertility (Fig. 12-111).

Malformed spermatids

There are at least four teratozoospermic syndromes that may be easily identified by testicular biopsy, although in most

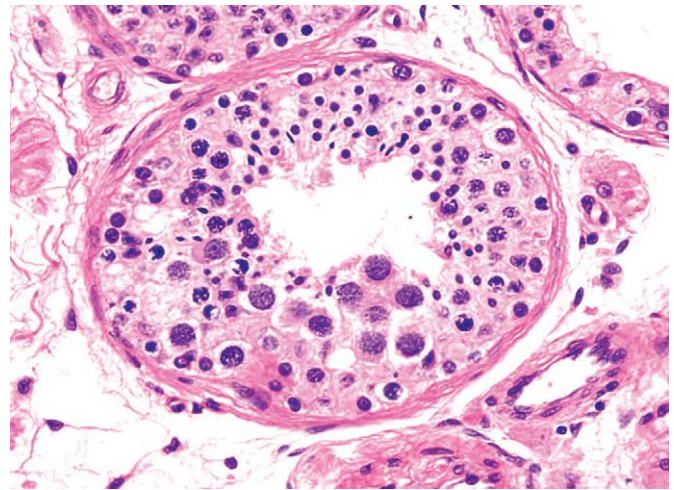


Fig. 12-110 Megalospermatocytes. The seminiferous tubule contains a group of very large primary spermatocytes displaying fine chromatin and eosinophilic cytoplasm.

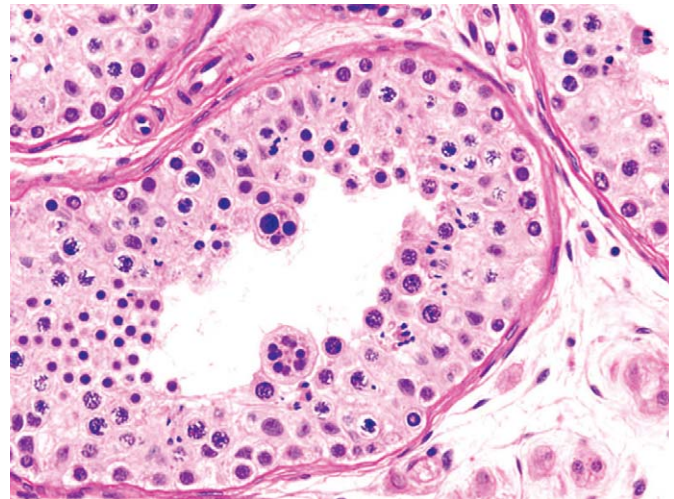


Fig. 12-111 Multinucleation of both spermatids and spermatocytes.

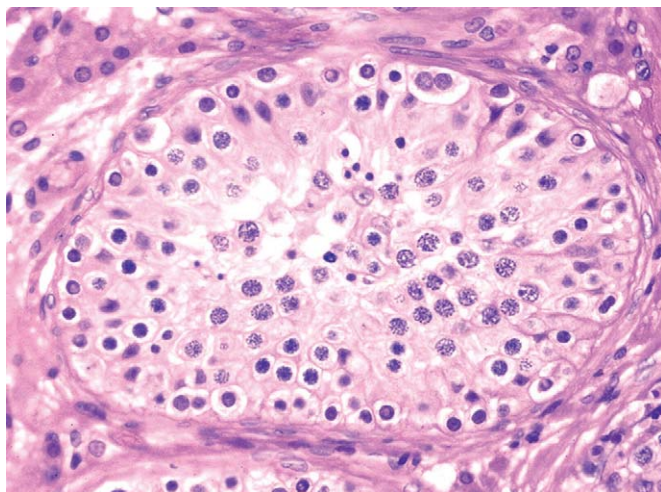


Fig. 12-112 Testicular biopsy showing spermatids with small spherical nuclei, a finding characteristic of round spermatozoa lacking acrosomes. The remaining germ cells are morphologically normal.

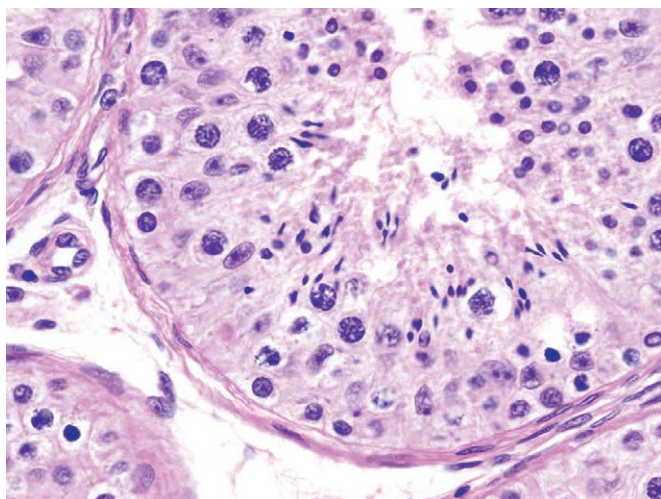


Fig. 12-113 Elongated spermatids showing bell-clapper nuclei in a patient with varicocele.

the diagnosis previously relied on morphologic study of the spermiogram: (1) round-headed spermatids (characteristic of spermatozoa lacking acrosomes) (Fig. 12-112), (2) $S_c + S_d$ spermatids with a very elongated head (characteristic of varicocele) (Fig. 12-113), (3) macrocephalic $S_c + S_d$ spermatids whose DNA content suggests an anomaly in the first meiotic division, and (4) $S_c + S_d$ spermatids with voluminous eosinophilic cytoplasmic droplets (syndrome of spermatozoa with short thick flagella⁹⁸⁵ or fibrous sheath dysplasia).

In some patients, $S_a + S_b$ spermatids rest in these initial phases of spermiogenesis and eventually become sloughed in the tubular lumina.⁹⁸⁶ In other testes there are macrocephalic S_c and S_d spermatids with anomalous DNA content, suggesting an anomaly in the first meiotic division.

Morphologically abnormal spermatozoa

Ultrastructural study of spermatozoa is sometimes necessary to determine the cause of male infertility. A number of mor-

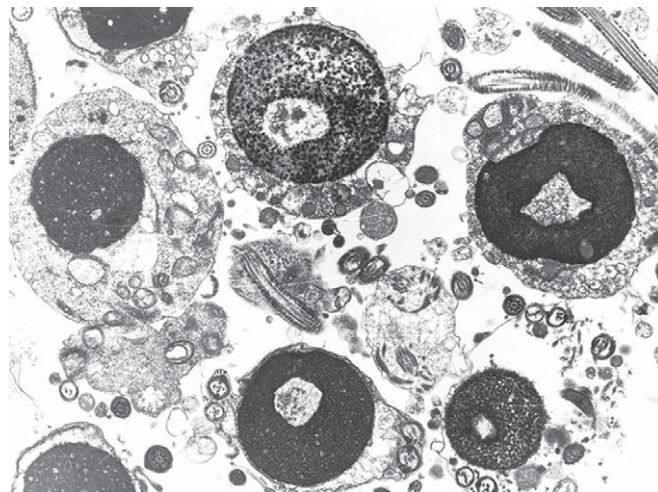


Fig. 12-114 Microcephalic spermatozoa with a spherical nucleus lacking an acrosome and poorly condensed chromatin. Ultrastructural anomalies are observed.

phologically abnormal spermatozoa are present in all semen samples, including those from fertile men, but abnormal spermatozoa are very numerous in infertile patients. Ultrastructural study is advised in all cases of asthenozoospermia, in teratozoospermia when the number of spermatozoa showing the same morphological anomaly is high, and in cases with apparently normal spermatozoa that fail to fertilize in vitro.⁹⁸⁷ The classification of ultrastructural anomalies in spermatozoa is based on light microscopy findings⁹⁸⁸ of lesions in the head and tail.

Anomalies of the spermatozoal head These are defined by changes in the shape of the head, and usually involve both the nucleus and the acrosome. Some anomalies, such as pear-shaped, candle-shaped, or egg-shaped heads,^{989,990} are regarded as minor variants of normal. More significant abnormalities are the elongated, microcephalic, macrocephalic, and crater-defect forms.

The most frequent abnormal head shape is elongated with a narrow base (tapered head spermatozoa). This anomaly is frequently associated with varicocele.⁹⁹¹

Microcephalic spermatozoa have spherical (globozoospermia) or irregularly shaped heads. The former have spherical nuclei with poorly condensed chromatin and lack acrosomes, postacrosomal sheaths, and a nuclear ring (Fig. 12-114). Most cases are sporadic, but this lesion was also reported in two pairs of infertile brothers.^{992,993} Microcephalic spermatozoa with irregularly shaped heads have small and irregularly shaped acrosomes that usually are not in contact with the nucleus. This anomaly may be congenital, as in Aarskog-Scott syndrome,⁹⁹⁴ or secondary to heat exposure or hashish smoking. In both types of microcephaly loss of connection between the acrosomal vesicle and the spermatozoal head is attributed to a deficiency in basic proteins of the sperm perinuclear theca that promotes nuclear envelope organization and adhesion of the acrosomal vesicle.⁹⁹⁵ Acrosin is reduced or absent in spermatozoa lacking acrosomes and those with small acrosomes.⁹⁹⁶ Motility may be

normal. The occurrence of aneuploidy⁹⁹⁷ and disomy of sex chromosomes^{998,999} in some cases should be evaluated before performing intracytoplasmic sperm injection (ICSI).

The cause of round-headed spermatozoa might be the lack of Golgi-associated protein known in male mice as Golgi-associated PDZ- and coiled-coil motif-containing protein (GOPC). This protein is principally localized in the *trans*-Golgi region in round spermatids, and its loss produces globozoospermia. The primary defect consists of an inability of acrosomal vesicles to fuse to each other to create the acrosome.¹⁰⁰⁰

Macrocephalic spermatozoa (macronuclear spermatozoa) have enlarged, irregularly shaped heads and deficient chromatin condensation. There are two types (multiple tails^{1001,1002} and aflagellate), both of which have abnormal DNA content (many are tetraploid), suggesting a meiotic anomaly.^{1003,1004}

Irregularly shaped spermatozoa are characterized by irregularity in the shape of the nucleus or acrosome.¹⁰⁰⁵ In the crater defect syndrome, there is invagination of the nuclear envelope in which the acrosome penetrates. The tail is morphologically normal, and motility is only slightly reduced. In spermatozoa with spoon-shaped nuclei, the defect is probably genetic. Other anomalies include double-headed spermatozoa with two nuclei sharing a single acrosome.¹⁰⁰⁶

Anomalies in the spermatozoal tail Spermatozoal tail anomalies are classified as generalized anomalies of the tail or anomalies in defined tail components, such as the connecting piece, the axoneme, or the periaxonemal structure.¹⁰⁰⁷

Generalized anomalies in the tail *Cytoplasmic remnants.* The presence of cytoplasmic droplets is normal during spermiogenesis. An elevated number of spermatozoa with cytoplasmic droplets in semen is associated with premature sloughing of spermatozoa, as occurs in varicocele, and should not be misinterpreted as spermatozoa with excess residual cytoplasm.¹⁰⁰⁸ These spermatozoa are very often abnormal and the residual cytoplasm may be located around the intermediate piece or surrounding the head. These spermatozoa also have other flagellar anomalies.

Bent tail. A bend in the tail may occur at the level of the connecting piece or the intermediate piece. In bends of the connecting piece, the tail is laterally implanted and forms an angle with a nucleus that displays a thin base. Bends of the intermediate piece are associated with cytoplasmic droplets, malposition of mitochondria, and loss of the parallel arrangement of the dense outer fibers.

Coiled tail. Spermatozoa with a coiled tail are a frequent finding in centrifuged semen, but they may also be a true abnormality. These spermatozoa have a perinuclear cytoplasmic remnant containing a flagellum that is coiled around the nucleus and along the middle or principal pieces (Fig. 12-115). This is frequently associated with abnormalities of the periaxonemal structures.

Tail stump (short-tail spermatozoa). The presence of many spermatozoa with short, thick tails in semen represents a well-defined teratozoospermic syndrome.¹⁰⁰⁹ Ultrastructural examination reveals hypertrophy and hyperplasia of the fibrous sheath,¹⁰¹⁰ hence this syndrome has also been termed 'fibrous sheath dysplasia.'¹⁰¹¹ Additional axonemal malformations, including absence of the central pair of microtu-

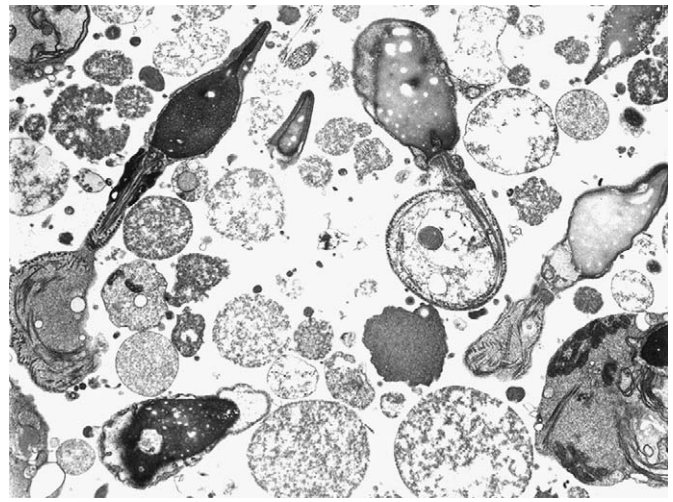


Fig. 12-115 Spermatozoa with coiled tails. The anomaly occurs in the principal pieces. The intermediate pieces show variable lengths, absence of parallelism in the outer dense fibers, and large cytoplasmic droplets. This teratozoospermia was found in two infertile brothers.

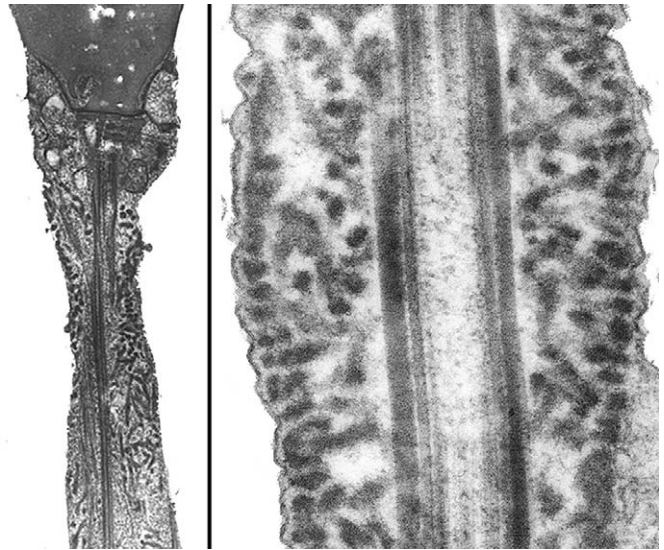


Fig. 12-116 Tail-stump spermatozoal malformation. Longitudinal section of two spermatozoa showing a marked thickening of the principal piece with both hypertrophy and hyperplasia of the fibrous sheath. One of them also shows a very short intermediate piece.

bules (Fig. 12-116)¹⁰¹² and, less frequently, lack of dynein arms, are observed in 50% of cases. About 24% of patients have respiratory disease, such as rhinosinusitis, bronchitis, and bronchiectasis from an early age. Similar findings have been reported in the cilia of the upper respiratory tract, and thus a relationship between fibrous sheath dysplasia and immotile cilia syndrome has been assumed. Clinical presentation may be sporadic or familial. The cause of fibrous sheath dysplasia and the subsequent lack of motility in these spermatozoa is probably related to the occurrence of deletions in *Akap3* and *Akap4* genes, as well as the absence of *Akap4* protein in the fibrous sheath.¹⁰¹³

Multiple tails. The presence of more than two tails is associated with macrocephalic spermatozoa.¹⁰¹⁴

Sperm tail agenesis. Teratozoospermia with 100% sperm tail agenesis has been reported in patients with a high degree of consanguinity. These spermatozoa also have defects in chromatin condensation and residual cytoplasmic droplets.¹⁰¹⁵

Anomalies of the connecting piece Anomalies of the connecting piece are classified as acephalic spermatozoa, deficient organization of the connecting piece, and separation between the head and the tail.

Acephalic spermatozoa are known as 'pin-headed,' although they lack a true head; the small cephalic knob-like thickening is actually a cytoplasmic droplet with a variable degree of mitochondrial organization giving rise to a variable degree of motility.¹⁰¹⁶ This anomaly is due to an early failure in spermiogenesis. It may be familial in some cases.^{1017,1018} Spermatozoa with deficient organization of the connecting piece have narrowing at this level, with loss of alignment of the head and flagellum axes. Spermatozoa with a separated head and flagellum, known as decapitated and decaudated spermatozoa, are also the result of an anomaly in spermiogenesis, but the separation between heads and tails can occur during spermiation or at any level of the sperm excretory ducts.^{1019,1020}

Anomalies in axoneme Abnormalities of the axoneme are classified as numerical anomalies, microtubular ectopia, and immotile cilia syndrome.

The most common numerical anomalies are the absence of one or both microtubules of the central pair and complete lack of the axoneme. Spermatozoa lacking the central microtubule pair also lack the central sheath and are immotile, although they are normal by light microscopy. Familial cases have been reported.¹⁰²¹ This anomaly may be associated with ciliary dyskinesia.¹⁰²²

Immotile cilia syndrome (primary ciliary dyskinesia)¹⁰²³ refers to patients having low mucociliary clearance associated with otitis, sinusitis, bronchitis, bronchiectasis, and immotile spermatozoa. Most patients have the same defect in the axoneme and cilia of the respiratory mucosa. The frequency of this syndrome is estimated at between 1 in 20 000 and 1 in 60 000 men. Clinical symptoms consist of reduced clearance of ciliary mucus in the airway, with onset at infancy. In order to prevent the later development of bronchiectasis, ultrastructural study of the respiratory mucosa is advisable if other disorders have been excluded, including cystic fibrosis, allergy and other immune disorders, α_1 -antitrypsin deficiency, and cardiovascular and metabolic diseases.¹⁰²⁴ The most frequent anomalies of this syndrome are the absence of microtubule doublets and peripheral junctions, the central microtubule pair, the outer dynein arms, the central junctions, the two dynein arms, and the inner dynein arm plus the peripheral junctions (Fig. 12-117). Spermatozoa lacking the two dynein arms or the peripheral junctions are immotile. Reduced motility is seen in spermatozoa with only one dynein arm. Kartagener's syndrome is a variant of the immotile cilia syndrome characterized by the classic triad of situs inversus, bronchiectasis, and chronic sinusitis. The syndrome has autosomal recessive

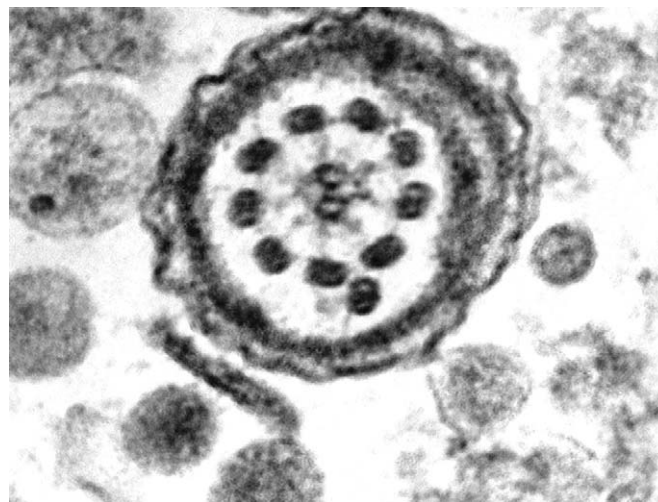


Fig. 12-117 Cross-section of the intermediate piece from a spermatozoon lacking dynein arms and showing a supernumerary microtubule doublet.

inheritance¹⁰²⁵ and is found in 20–25% of patients with situs inversus.¹⁰²⁶

Anomalies in periaxonemal structures Periaxonemal abnormalities include mitochondrial sheath defects,¹⁰²⁷ malposition of the annulus, alteration in number, shape, or length of the outer dense fibers, and absence, thickening, or disruption of the fibrous sheath.^{1011,1028}

Many cases of asthenozoospermia, present in 30% of infertile men, may be attributable to deficient mitochondrial function, possibly caused by mutations in their DNA.¹⁰²⁹ Abnormalities of the dense fibers are associated with deficient motility. Abnormalities of the fibrous sheath include, in addition to the abovementioned dysplasia of the fibrous sheath, absence of the fibrous sheath, and redundant fibrous sheath material associated with a deficit or lack of mitochondria.¹⁰³⁰ The three defects are probably inherited.

Presence of intratubular germ cell neoplasia

The incidence of intratubular germ cell neoplasia (IGCN) in infertile patient is 0.4% in England,¹⁰³¹ 0.7% in Spain,¹⁹³² 0.73% in Germany,¹⁰³³ and 1.1% in Denmark.¹⁰³⁴ A higher risk occurs in patients with severe oligozoospermia (fewer than 10 million spermatozoa per milliliter), azoospermia associated with unilaterally or bilaterally diminished testicular volume,¹⁰³⁵ a history of testicular maldescent,^{1036,1037} or unilateral testicular cancer.¹⁰³⁸

The cells of IGCN are located in seminiferous tubules with decreased tubular diameter and lacking spermatogenesis. These cells are large and have pale cytoplasm and large and irregularly outlined nuclei, with one or several prominent nucleoli. They stain intensely with periodic acid–Schiff and express placenta-like alkaline phosphatase, *c-kit*, and the cell adhesion molecule CD44.¹⁰³⁹

Anomalies in Leydig cells

A reduction in the number or absence of Leydig cells is infrequent in infertility, and only occurs in hypogonadotropic hypogonadism secondary to LH deficit and in patients

with biologically inactive LH. Leydig cell hyperplasia is very common,¹⁰⁴⁰ and has been observed in Klinefelter's syndrome, cryptorchidism, male pseudohermaphroditism, minor androgen insensitivity, infertility secondary to Leydig cell dysfunction, varicocele, after treatment with 5 α -reductase inhibitors or non-steroidal anti-androgens, and in some elderly men. Such hyperplasia may give rise to hypoechoic or hyperechoic images that may be misdiagnosed as tumor.¹⁰⁴¹

Mast cells

There is a close relationship between testicular dysfunction and elevated mast cell numbers in the testis. An increase in interstitial and peritubular mast cells occasionally occurs in infertile patients.^{1042,1043} This increase is higher than that observed in inflammatory or neoplastic process.¹⁰⁴⁴ Daily administration of ketotifen, an antihistamine-like drug with a mast cell-stabilizing effect, significantly improves the spermogram parameters in some patients.¹⁰⁴⁵

Correlation between testicular biopsy and spermogram

For effective therapy, it is important to know whether or not the azoospermia or oligozoospermia is the result of obstruction.^{863,1046}

Obstructive azoospermia and oligozoospermia

Azoospermia caused by obstruction is usually easily diagnosed, but this determination is more difficult with oligozoospermia. Obstruction of the ductal system should be suspected when there are more than 20 mature spermatids ($S_c + S_d$) per cross-sectioned tubule and fewer than 10 million spermatozoa in the spermogram (Fig. 12-118).^{1047,1048} Obstructive azoospermia is implicated in 7.4–14.3% of cases of male infertility.

Classification of obstructive azoospermia by location Obstruction is classified as proximal, distal, and mixed, according to the distance from the testis to the point of obstruction in the ductal system.

Proximal obstruction Obstruction is considered proximal when the lesion lies between the seminiferous tubules and the distal end of the ampulla of the vas deferens. Epididymal obstruction, principally of the caput-corporis transition zone, accounts for 66% of cases. Rarely, there is a defective connection between the rete testis and epididymal ductuli efferentes. Because the seminal vesicles are normal, men with proximal obstruction have a normal volume of semen (the testicular contribution to semen is about 5% of the total volume). When obstruction is in the cauda of the epididymis, epididymal markers, including carnitine, glycerophosphorylcholine and α -glycosidase are low.¹⁰⁴⁹ The nearer the obstruction is to the caput of the epididymis, the higher the level of these markers.

Distal obstruction Distal obstruction is located between the ampulla of the vas deferens and the junction of the ejaculatory ducts and urethra. These patients present with sacral, perineal, or scrotal pain on ejaculation. Rectal examination often reveals enlarged seminal vesicles. The volume of semen is low and consists of watery fluid that fails to

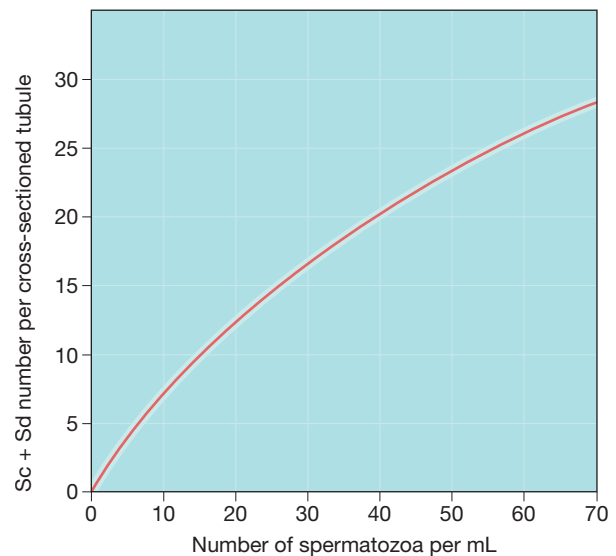


Fig. 12-118 Power curve showing the correlation between the number of spermatozoa in the spermogram and the number of mature spermatids ($S_c + S_d$) per cross-sectioned tubule. If the number of mature spermatids is correlated to that of spermatozoa in spermogram, the oligozoospermia is of the pure secretory type. If the number of mature spermatids is higher than that of spermatozoa in spermogram, the disorder is either an obstructive azoospermia with 'normal' testicular biopsy or a mixed obstructive secretory oligozoospermia.

coagulate. Seminal vesicle secretions are lacking. The concentration of prostatic secretions, such as acid phosphatase and citric acid, is increased owing to the lack of semen dilution. Vasography may help in diagnosis, as higher segments fail to fill.¹⁰⁵⁰ Transrectal ultrasonography is the most accurate imaging modality for the diagnosis of ejaculatory duct obstruction. Needle aspiration of seminal vesicle fluid may show spermatozoa that have entered the seminal vesicles by reflux.

Mixed obstruction Mixed obstruction refers to lack of patency of the vas deferens or the epididymis and alterations in the ejaculatory ducts or seminal vesicles (low ejaculate volume, and absence of fructose). The most frequent cause is mucoviscidosis. One-third of patients with congenital bilateral absence of the vas deferens have agenesis or hypoplasia of the seminal vesicles. The cause of epididymal obstruction in patients with anomalies of the prostate-vesiculo-deferential junctions is difficult to determine.

Etiology of obstructive azoospermia Obstructive azoospermia may be caused by congenital or acquired lesions.

Congenital azoospermia The most frequent anomalies associated with congenital azoospermia are testis-epididymis dissociation, epididymal malformation in cryptorchidism, bilateral absence of the vas deferens, congenital unilateral absence of the vas deferens associated with pathology of the contralateral testis or its sperm excretory ducts, seminal vesicle agenesis, and ejaculatory duct obstruction (Table 12-9).

Agenesis of all mesonephric duct derivatives. Agenesis of all mesonephric duct derivatives is a rare disorder that gives rise to varied anatomical anomalies, depending on the stage of

Table 12-9 Congenital anomalies of the male mesonephric ducts

I. Agenesis of all mesonephric duct derivatives
II. Epididymis
Agenesis of the epididymis
Testis–epididymis dissociation
Failure in the connection between ductuli efferentes and ductus epididymidis
Cysts of the epididymis
Anomalies in epididymal configuration
Elongated epididymis
Angulated epididymis
Free epididymis
III. Vas deferens
Agenesis of the vas deferens
Persistent mesonephric duct
IV. Seminal vesicle
Agenesis of the seminal vesicle
Cysts of the seminal vesicle
Opening of the ureter into the seminal vesicle
V. Ejaculatory duct
Agenesis of the ejaculatory duct

embryonic development at which the mesonephric duct derivatives disappear. If failure occurs before the fourth week the ipsilateral kidney and ureter are absent, although the testis may be present, or there may be other renal anomalies. If failure occurs in the fourth week, and the ureteral bud is already formed, the ureter and kidney may develop normally. If failure occurs between the fourth and the 13th weeks, there is a variable constellation of anomalies that most frequently include normal development of the testis and globus major and hypoplasia of the other excretory duct segments, or agenesis of an excretory duct segment (epididymis, vas deferens, or seminal vesicle).

Epididymal anomalies. The most frequent epididymal anomalies are absence of the epididymis, testis–epididymis dissociation, defective connection of the vas deferens and epididymis, epididymal cyst, and anatomical abnormalities of the epididymis.

Complete absence of the epididymis is frequent in monorchidism and anorchidism. The epididymis is replaced by a small mass of cellular connective tissue with abundant blood vessels at the blind end of the vas deferens.

Partial absence of the epididymis is more frequent than complete absence. Absence of the corpus of the epididymis gives rise to a characteristic malformation called bilobated epididymis. This varies from simple strangulation to complete separation of the caput and cauda. These anomalies are often associated with absence of the vas deferens.

Testis–epididymis dissociation is found in 1% of cases of obstructive azoospermia and is usually associated with cryptorchidism.

Defects in connection between the ductuli efferentes and the ductus epididymidis are rarely complete. In the incomplete form, some of the five to 30 ductuli efferentes in the epididymis are short and end blindly.

Epididymal cysts usually arise from blind-ended ductuli efferentes and contain spermatozoa. These spermatoceles

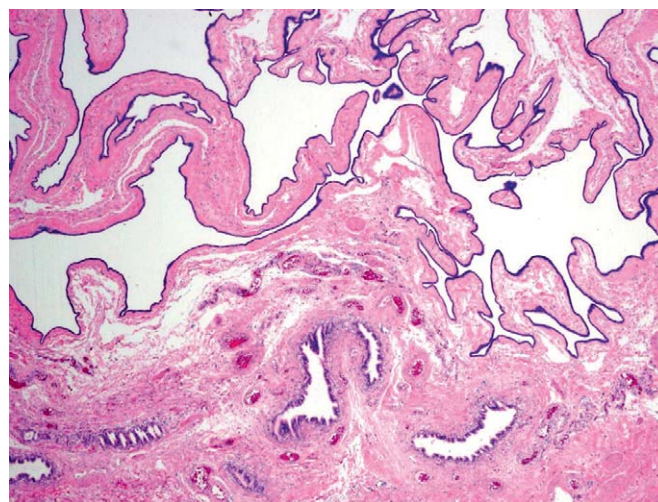


Fig. 12-119 Infertile patient with bilateral epididymal cysts. The cystic wall appears collapsed and folded on the epididymis.

retain their epithelial lining, although it becomes atrophic (Fig. 12-119). Spermatozoa may be obtained from these cysts. Some epididymal cysts arise from embryonic remnants, do not contain spermatozoa, and are lined by columnar or pseudostratified epithelium. Wolffian cyst, unlike müllerian cyst, is immunoreactive in the apical border of epithelial cells with CD10.¹⁰⁵¹ Cyst lined by clear cells with or without papillae raises concern for von Hippel–Lindau disease.¹⁰⁵² Large epididymal cyst requires removal and must be excised with great care to avoid damaging the ductuli efferentes and resulting in obstruction. Epididymal cyst is present in about 5% of males, and the incidence is high (21%) in those exposed to diethylstilbestrol during gestation. The incidence of epididymal cyst in those with hepatorenal polycystosis is similar to that in the general population.¹⁰⁵³

Anomalies in epididymal configuration, altering its shape and location, are frequent in men with cryptorchidism and uncommon with descended testes. The most common malformations are elongated epididymis, angulated epididymis, and free epididymis. Elongated epididymis is found in approximately 68% of undescended testes. The length of the epididymis may be several times that of the testis, and, in abdominal or inguinal cryptorchidism, the epididymis extends several centimeters below the testis. Angulated epididymis is characterized by a long epididymis that has a sharp bend in the corpus with or without stenosis. With free epididymis, all or part of the epididymis is unattached to the testis. The most common variant is epididymis with free cauda.

Vas deferens anomalies. The most frequent anomalies are of the vas deferens are congenital absence, segmental aplasia, ectopia, duplication, diverticula, and crossed dystopia.¹⁰⁵⁴

Congenital absence is defined as unilateral or bilateral absence of either the whole vas deferens or only a segment. Obviously, azoospermia occurs with bilateral absence. The frequency of this malformation varies among populations. At autopsy, the prevalence is 0.5%, but the clinical incidence

is 1–1.3% in infertile men¹⁰⁵⁵ and 10–25% in patients with obstructive azoospermia. Unilateral complete absence is three times more frequent than bilateral absence, and absence of only a segment is even more frequent. The affected segment may be absent or reduced to a fibrous cord. Absence of the vas deferens may be associated with other malformations of the sperm excretory ducts or urinary system. The most frequent malformations of the excretory ducts are absence of the ejaculatory ducts (33% of cases) and, less frequently, absence of the seminal vesicles. About 71% of patients with bilateral absence of the vas deferens have partial aplasia of the epididymis. The most frequent malformations of the urinary system are absence of the ipsilateral kidney and other renal anomalies. Complete or partial absence of the vas deferens occurs frequently in patients with cystic fibrosis.

Persistent mesonephric duct consists of the ureter joined to the vas deferens, forming a single duct that opens in an ectopic orifice between the trigone and the verumontanum. This malformation may be associated with cystic transformation or absence of the seminal vesicle. The kidney may be normal or dysplastic.

Anomalies of seminal vesicle and ejaculatory duct. The most frequent anomalies are agenesis of the seminal vesicles or ejaculatory ducts, cyst of the seminal vesicle, and ectopic opening of the ureter into the seminal vesicle. The last is the most common and often is associated with ipsilateral renal dysplasia.

Acquired azoospermia Inflammation and trauma are the main causes of acquired azoospermia. Epididymitis is a frequent cause; *Chlamydia trachomatis*^{1056,1057} and *Escherichia coli* are the most common infectious causes in developed countries.¹⁹⁵⁸ Infections with *Neisseria gonorrhoeae* and mycobacteria are also implicated, and non-specific epididymitis is important.¹⁰⁵⁹ Apart from elective vasectomy, the most frequent traumatic causes of azoospermia are surgical accidents during herniorrhaphy in children,¹⁰⁶⁰ orchidopexy, varicocelelectomy, hydrocelectomy, deferentography,¹⁰⁶¹ and removal of epididymal cyst. Obstructive azoospermia may also result from blockage of the ejaculatory ducts following transurethral resection, or as a result of chronic urethral catheterization.

Testicular and epididymal lesions resulting from obstruction of sperm excretory ducts Lesions of the testis and epididymis may result from obstructed sperm excretory ducts, depending on the location, origin (congenital or acquired), and duration of the obstruction.

Location of obstruction Obstruction at the level of the ampulla of the vas deferens, seminal vesicles, or ejaculatory ducts does not usually cause significant lesions in the testis or epididymis. More proximal obstruction at the level of the vas deferens, epididymis, or testis–epididymis junction usually causes severe lesions in both the sperm excretory ducts and the testicular parenchyma. Obstruction of the vas deferens causes increased pressure within the ductus epididymis. As a result, epididymal lumina dilate, the epithelium atrophies, and fluid containing few spermatozoa and some spermophages accumulates in the lumen (Fig. 12-120). The most dilated epididymal segment is the caput. The

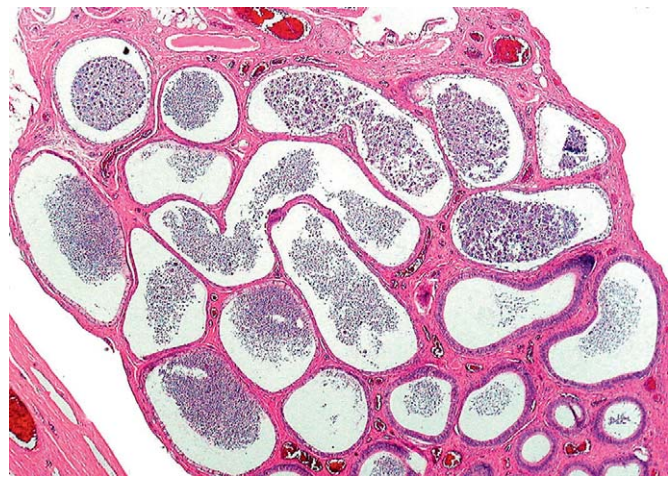

Fig. 12-120 Obstructive azoospermia in a patient with history of epididymitis. The caput epididymidis shows marked dilation of the ductuli efferentes with numerous spermatozoa.

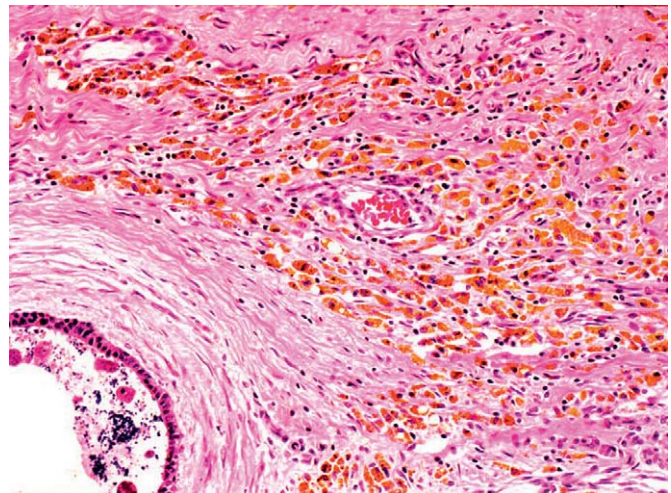


Fig. 12-121 Ceroid granuloma in a patient with history of sperm excretory duct obstruction.

ductuli efferentes often become cystically dilated and filled with spermatozoa and macrophages. From reabsorption and lysosomal degradation of this protein-rich fluid, the epithelium accumulates lipofuscin granules or acquires apical eosinophilic granules (Paneth cell-like change).¹⁰⁶² Rupture of the vas deferens gives rise to microgranulomas and ceroid granuloma (Fig. 12-121). Macrophages and lymphocytes are often present in the intertubular connective tissue.¹⁰⁶³

The most frequent testicular lesions in proximal obstruction involve the adluminal compartment, and are the result of the negative effect of hydrostatic pressure on the seminiferous tubular cell layers and, in particular, on the Sertoli cell (Figs 12-122–12-124).

Etiology of obstruction Obstruction secondary to congenital absence of the vas deferens usually causes little testicular injury, mainly dilation of the seminiferous tubules and an increase in the number of mature ($S_c + S_d$) spermatids.¹⁰⁶⁴

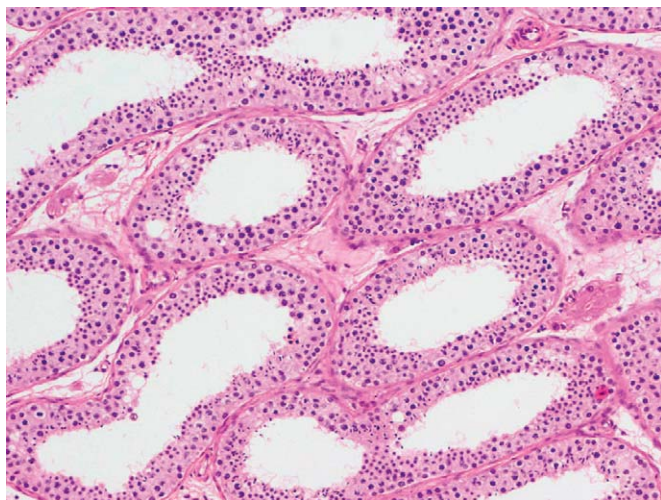


Fig. 12-122 Seminiferous tubules with marked luminal dilation, moderate decrease in cellularity, and occasional vacuolation of Sertoli cell cytoplasm.

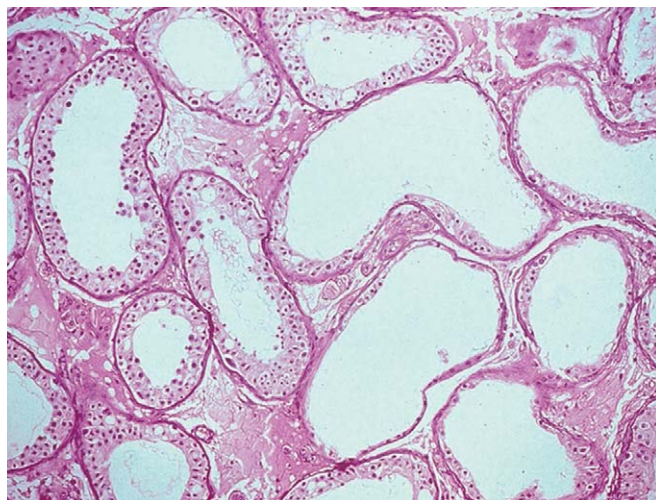


Fig. 12-124 Seminiferous tubules with marked ectasia and atrophy of the seminiferous epithelium in a patient with epididymal obstruction.

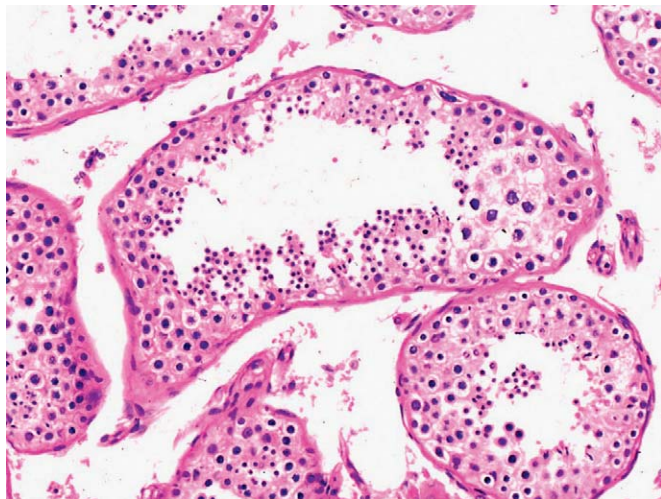


Fig. 12-123 Seminiferous tubules with slight luminal dilation. The seminiferous tubular cell layers have a 'toothed' pattern. Degenerating megalospermatocytes can be seen in the seminiferous epithelium.

Lesions resulting from vasectomy are more important. Increased intraluminal pressure in the epididymis¹⁰⁶⁵ may give rise to pain (late post-vasectomy syndrome).¹⁰⁶⁶ Testicular lesions depend on the surgical technique used: they are slight if the proximal end of the vas deferens is not ligated or sperm granuloma forms at the site of vasectomy. The spermatogenic rhythm in the testis is slower than before vasectomy, and lesions characteristic of testicular obstruction develop, including thickening of the lamina propria and fibrosis of the interstitium.^{1067,1068} In testicular obstruction secondary to herniorrhaphy in infancy, testicular lesions are mild. Testicular lesions may be important if the epididymis is damaged by hydrocelectomy, and consist mainly of primary spermatocyte sloughing. In addition to these lesions, hyalinized tubules may be observed when obstruction is caused by inflammation.

Duration of obstruction In acquired obstruction the testicular lesions worsen with time. Obstruction in the caput of the epididymis leads to disappearance of all germ cells in the adluminal compartment of seminiferous tubules. The tubules become dilated and Sertoli cells appear vacuolated. Testicular alterations after vasectomy may not be related to the duration of the obstruction but rather to the initial injury, and may disappear with time as the intraluminal pressure decreases.¹⁰⁶⁹ However, if a significant amount of time has elapsed after vasectomy, the possibility of attaining a normal spermogram with vasovasostomy is very low. Vasal patency is restored in most cases of reanastomosis, but paternity rates are markedly lower (25–51%)¹⁰⁶⁹ than normal (85%).¹⁰⁷⁰

Functional azoospermia and oligozoospermia

Some azoospermic patients have testicular biopsy with minimal histologic abnormality or minor tubular dilation without detectable excretory duct obstruction. These findings are characteristic of two main conditions: Young's syndrome, and alterations in spermatozoal transport.

Young's syndrome Young's syndrome is defined by the following constellation of findings: azoospermia, sinusitis, bronchitis or bronchiectasis, and normal spermatozoal flagella.¹⁰⁷¹ The incidence is probably higher than that recorded in the literature, and Young's syndrome should be suspected in all patients with obstructive azoospermia without a history of epididymitis or scrotal trauma. These patients have a lesion at the junction of the caput and corpus of the epididymis that gives the epididymis a characteristic gross appearance. The caput of the epididymis is distended, the ductuli efferentes contain yellowish fluid and numerous spermatozoa, and the remaining epididymal segments are normal. The ductus epididymidis is blocked by thick fluid.¹⁰⁷² Young's syndrome should be distinguished from other causes of infertility also associated with chronic sinusitis and pulmonary infections, including ciliary dyskinesia and cystic fibrosis. Ciliary dyskinesia consists of morphological, biochemical, and functional alterations in cilia and flagella, and includes

several diseases such as the immotile cilia syndrome, Kartagener's syndrome, and miscellaneous syndromes characterized by imperfectly defined abnormalities of cilia and flagella.¹⁰⁷³ In Young's syndrome, sinusitis and pulmonary infections develop in childhood and stabilize or improve in adolescence; in other conditions, the pulmonary damage increases with age and the cilia and flagella are ultrastructurally abnormal.¹⁰⁷⁴

Alterations in spermatozoon transport Normally, spermatozoa detach from the Sertoli cells and are transported through the intratesticular and extratesticular excretory ducts, where they are stored, mainly in the cauda of the epididymis, and finally released from the corpus by ejaculation or eliminated by phagocytosis. Only about 50% of spermatozoa are ejaculated. Whereas the release of spermatozoa from the corpus is intermittent, their transport through the sperm excretory ducts is continuous. Transport is accomplished by the myofibroblasts in the wall of the seminiferous tubules and ductuli efferentes and the smooth muscle cells in the wall of the ductus epididymidis and vas deferens. These cells cause peristaltic contraction, propelling spermatozoa along the length of the epididymis in a mean of 12 days (range, 1–21 days). The walls of the seminiferous tubules and extratesticular excretory ducts are under hormonal and neural control. The myofibroblasts in the seminiferous tubules have oxytocinic, α_1 - β -adrenergic, and muscarinic receptors. Unmyelinated nerve fibers penetrate the tubular lamina propria, pass among the myofibroblasts, and end near the Sertoli cells.¹⁰⁷⁵ Along their length these nerve fibers have varicosities containing sympathetic vesicles.

The ductus epididymis is innervated by sympathetic adrenergic nerve fibers that end among the smooth muscle cells. Several hormones, including oxytocin, endothelin-1, vasopressin, and prostaglandins, act on the musculature of the ductus epididymis. The peristaltic contractions begin in the caput and propagate toward the cauda. The frequency and amplitude of contractions vary from region to region, being higher in frequency near the caput and of maximal amplitude in the initial portion of the cauda. The progressive increase in amplitude parallels the progressive increase in thickness of the muscular wall and the requirement for greater force to propel the fluid as it becomes progressively more viscous with a higher concentration of spermatozoa. The distal portion of the cauda is unusually at rest because it is the main reservoir of spermatozoa between ejaculations. Several times daily, vigorous contractions of the distal cauda impel the spermatozoa from the cauda toward the vas deferens.¹⁰⁷⁶

Several drugs that favor contraction of the muscular wall (α_1 blocking and $F_{2\alpha}$ prostaglandins) have been successfully used in the treatment of alterations in the spermatozoon transport.¹⁰⁷⁷

Infertility and chromosomal anomalies

Knowledge of the incidence of chromosomal abnormalities in male infertility has progressed in parallel with advances in technology: karyotypic studies in peripheral blood, meiotic and chromosomal studies of testicular biopsies,

analysis of chromosomes in spermatozoa, and analysis of DNA in blood and spermatozoa for the detection of chromosome Y deletions.¹⁰⁷⁸ The incidence of chromosomal anomalies in infertile men is 2.2–6.6%, whereas in the general population it is lower than 0.5%. The frequency of chromosomal abnormalities increases with the decrease in number of spermatozoa in the ejaculate.¹⁰⁷⁹

Abnormalities of sex chromosomes

Klinefelter's syndrome

Genetic and clinical aspects Klinefelter's syndrome is characterized by an abnormal number of X chromosomes and primary gonadal insufficiency. The original description was of a man with eunuchoidism, gynecomastia, small testes, mental retardation, and elevated level of serum gonadotropins.¹⁰⁸⁰ The frequency of this syndrome varies according to the population studied: 1 in 1000 to 1 in 1400 surviving newborns; 1 in 100 patients in mental institution; 3.4 in 100 infertile men; and 11% of patients who are azoospermic.¹⁰⁸¹

In 80% of cases, the karyotype is 47XXY. The remaining 20% have chromosomal mosaicism with at least two X chromosomes. The most common are XY/XXY, XY/XXX, XX/XXY, XXY/XX/XY, XY/XO/XXY, XX/XXY/XXX, and XXXY/XXXXY. The 47XXY lesion is due to non-disjunction in sex chromosome migration during the first or second meiotic division of the spermatocyte or ovule, or during the first meiotic division of the zygote.¹⁰⁸² Study of the Xg antigen in blood revealed that the extra X chromosome is from the mother in 73% of cases. Advanced maternal age increases the incidence of children with the 47XXY karyotype.

In 47XXY patients, the most common clinical findings are:¹⁰⁸³

- Eunuchoid phenotype with increased stature. The increased height is due to a disproportionate lengthening of the lower extremities. The ratio of span to height is less than 1.
- Incomplete virilization. This is variable and ranges from normal development to absence of secondary sex characteristics.
- Gynecomastia, usually bilateral, present in 50% of patients.
- Mental retardation.

Other commonly associated conditions include chronic bronchitis; varicose veins; cervical rib; kyphosis; scoliosis or pectus excavatum; and a high incidence of hypothalamic, hypophyseal, thyroid, and pancreatic dysfunction.¹⁰⁸⁴

The external genitalia usually are normally developed. The testes are usually less than 2.5 cm long, although in some cases of chromosomal mosaicism they are of normal size.¹⁰⁸⁵ The incidence of cryptorchidism is low in 47XXY patients but increased in mosaicism.¹⁰⁸⁶

Supernumerary X-chromosome material is associated with a reduction of gray matter in the left temporal lobe, a finding correlated with verbal and language deficits.¹⁰⁸⁷

Histologically, the testes show the classic picture of tubular dysgenesis with small hyalinized seminiferous tubules

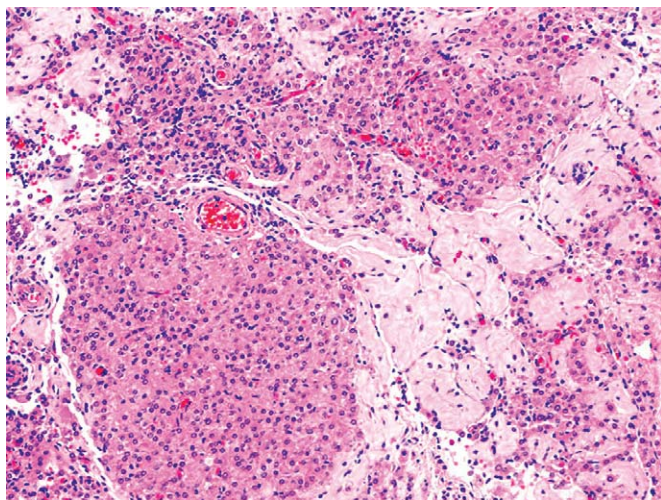


Fig. 12-125 Klinefelter's syndrome. Leydig cell nodules mingle with hyalinized tubules.

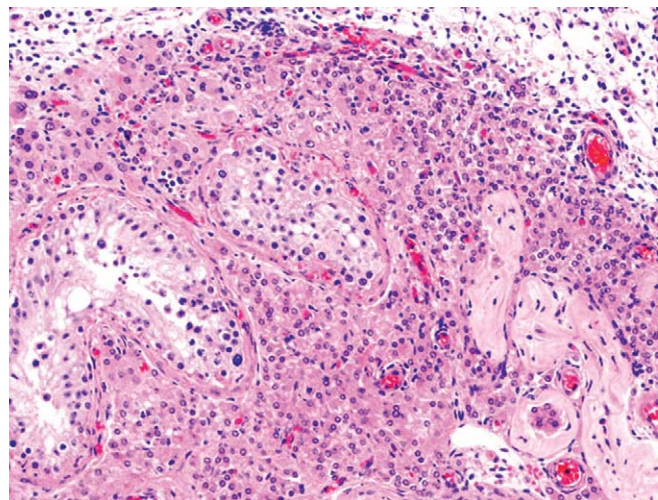


Fig. 12-127 Klinefelter's syndrome mosaicism showing focal spermatogenesis in two seminiferous tubules located within a Leydig cell nodule.

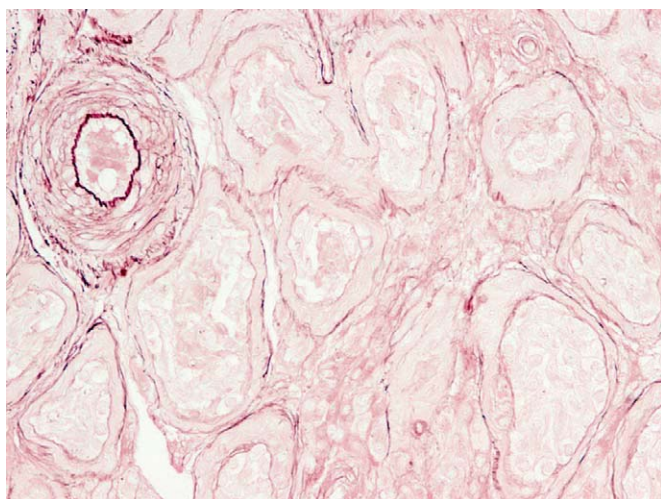


Fig. 12-126 Klinefelter's syndrome. Most seminiferous tubules, even those with Sertoli cell only, have scant elastic fibers that can be demonstrated with orcein stain. The intense staining observed in the inner elastic lamina of arterioles provides a positive control.

lacking elastic fibers and pseudoadenomatous clustering of Leydig cells (Figs 12-125, 12-126).¹⁰⁸⁰ Most biopsies show some tubules with a few Sertoli cells.¹⁰⁸⁸ These cells may be dysgenetic (pseudostratified distribution of nuclei that are dark and elongate and contain small peripherally placed nucleoli in tubules without apparent lumina). Sex chromatin may only be observed in dysgenetic Sertoli cells.¹⁰⁸⁹ This suggests that either there is testicular mosaicism of the X chromosome, or that both X chromosomes are heterochromatinized. In mosaicism, Sertoli cell-only tubules may be more numerous than hyalinized ones.

The reduced testicular volume gives an appearance of Leydig cell hyperplasia,¹⁰⁹⁰ although quantitative studies have shown that the total number of Leydig cells is lower than normal.¹⁰⁹¹ Many of the Leydig cells are pleomorphic

and some are multivacuolated. Immature fibroblast-like Leydig cells may be present. The abnormally differentiated Leydig cells have nuclei with coarse masses of dense chromatin, deep unfolding of the nuclear envelope, multiple paracrystalline inclusions instead of Reinke's crystalloids, multilayered concentric cisternae of smooth endoplasmic reticulum, large masses of microfilaments, and scant lipid droplets.¹⁰⁹² Sex chromatin is apparent in 40–70% of Leydig cells. Leydig cell function is insufficient and androgen levels are less than 50% of normal. Basal FSH and LH are markedly increased.^{1084,1093,1094} In a few patients the testicular damage is less severe, with some tubules showing spermatogenesis and less prominence of Leydig cells.¹⁰⁹⁵ Exceptionally, complete spermatogenesis and even paternity have been reported.¹⁰⁹⁶

The XY/XXY karyotype is the most frequent variant of Klinefelter's syndrome with chromosomal mosaicism. In this condition, the clinical abnormalities may be attenuated. Gynecomastia is present in 33% of cases, compared to a frequency of 55% in men with the 47XXY karyotype. Azoospermia is found in 50% of cases (93% in XXY men). The testes are larger and spermatogenesis is more developed in men with XXY (Fig. 12-127). Patients with the 47XXY karyotype who have spermatozoa in seminiferous tubules are bearers of 46XY spermatogonia and also of 47XXY spermatogonia, whereas those who have no spermatozoa have 47XXY spermatogonia only; these 47XXY spermatogonia may include some spermatozoa with 23X or 23Y chromosomal complement, elevated numbers of both 24XY and 24XX spermatozoa, and also a high frequency of spermatozoa with 21 disomy; this could be an important risk for gonosomy¹⁰⁹⁷ and also for trisomy 21.¹⁰⁹⁸ Genetic counseling is advisable in patients seeking intracytoplasmic sperm injection therapy. Genetic diagnosis before implantation of the zygote or prenatal diagnosis have been recommended, except for parents who assume the risk of gonosomy.

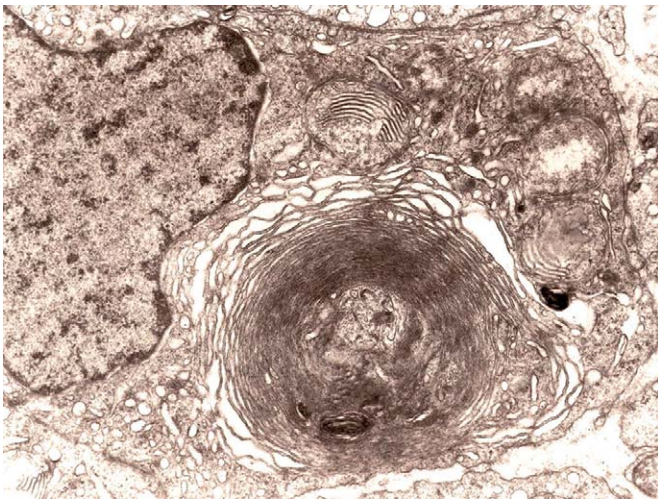


Fig. 12-128 48XXYY Klinefelter's syndrome showing a Leydig cell that contains giant mitochondria and a wheel of smooth endoplasmic reticulum.

The incidence of the 48XXYY karyotype is estimated to be 0.04 per 1000 live births.¹⁰⁹⁹⁻¹¹⁰² This karyotype may be associated with aggressive character, antisocial behavior, more severe mental retardation, and a higher frequency of congenital malformations than the 47XXY karyotype. Men with the 48XXYY karyotype also have characteristic dermatoglyphics with an increase in arches, a decrease in total finger ridge count, and ulnar triradiuses associated with changes in the hypothenar region.¹¹⁰³ Concentric lamellae of smooth endoplasmic reticulum in Leydig cells are a characteristic finding (Fig. 12-128).¹¹⁰⁴ Men with the 48XXYY or 49XXXXYY karyotype often have skeletal malformations, principally radioulnar synostosis, and cryptorchidism.¹¹⁰⁵ In addition to the characteristic symptoms of 47XXY Klinefelter's syndrome,¹¹⁰⁶ men with the 49XXXXYY karyotype have other abnormalities, including severe mental retardation, hypoplasia of external genitalia, cardiac malformations, radioulnar synostosis, microcephaly, and a high arched palate.¹¹⁰⁷

Association of Klinefelter's syndrome with malignancy Patients with Klinefelter's syndrome have a higher incidence of malignancy than the general population. The association was first discovered with breast carcinoma,¹¹⁰⁸ which had an incidence 20 times greater than in the general male population,¹¹⁰⁹ and is related to hormonal stimulation.¹¹¹⁰ Although testicular germ cell tumor is rare in these patients,¹¹¹¹ extragonadal germ cell tumor is 30–40 times more frequent than in the general population. Most occur in the mediastinum (about 71%) and are less frequent in the pineal gland, central nervous system, and retroperitoneum. The most frequent types are teratoma and choriocarcinoma; embryonal carcinoma and seminoma are rare.¹¹¹²⁻¹¹¹⁴ The extragonadal origin of germ cell tumors has been attributed to abnormal germ cell migration from the yolk sac. The high incidence has been attributed to elevated hormone levels and chromosomal anomaly.¹¹¹⁵ In a patient with the XY/XXY chromosomal mosaic and bronchogenic carcinoma, cultured XXY fibroblasts transformed three times more frequently when

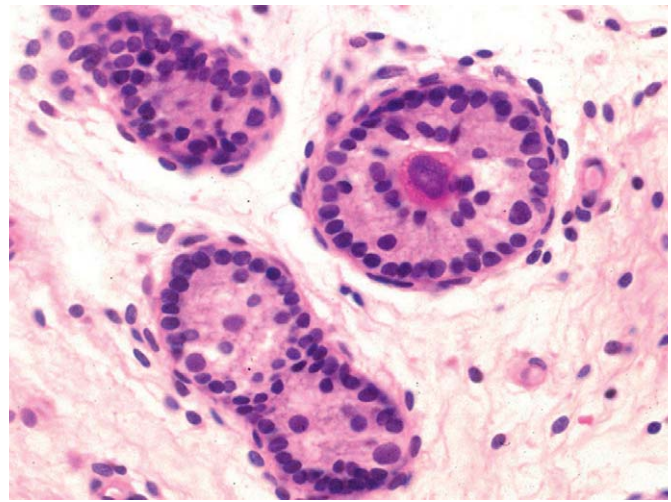


Fig. 12-129 Klinefelter's syndrome at infancy. Seminiferous tubules showing decreased diameters, isolated germ cells, and a ring-shaped tubule that contains a microlith.

exposed to SV40 virus than did fibroblasts from normal men.¹¹¹⁶

Other tumors reported in patients with Klinefelter's syndrome (lymphoma, leukemia, bronchogenic carcinoma, urothelial carcinoma of the bladder, adrenal carcinoma, prostatic adenocarcinoma, testicular Leydig cell tumor, and epidermoid cyst) do not appear to have a higher incidence than in the general population.¹¹¹⁷⁻¹¹²⁰

Occurrence of Klinefelter's syndrome in childhood Early identification of this syndrome is possible with systematic cytogenetic study of newborns with positive sex chromatin or mental retardation.¹¹²¹ Several clinical symptoms suggest Klinefelter's syndrome. Initial symptoms include decreased muscle tone, delayed speech, and poor language skills with an increased incidence of reading difficulties and dyslexia.¹¹²² Later, there may be recognition of mental retardation,¹¹²³ psychiatric problems, excessive stature for age, disproportionately long legs, micropenis, and small testes.¹¹²⁴⁻¹¹²⁷ Androgen deficiency is an early finding.¹¹²⁸ Testicular biopsy reveals scant or absent germ cells. Quantitative studies indicate that the number of germ cells in 47XXY fetuses is significantly lower than in normal 46XY fetuses. The seminiferous tubules have reduced diameter, particularly those devoid of germ cells. The number of Sertoli cells per cross-sectioned tubule is reduced. Megatubules, ring-shaped tubules, and intratubular eosinophilic bodies are common (Fig. 12-129). In some cases of Klinefelter's syndrome associated with Down's syndrome, tubular hyalinization is observed in childhood.¹¹²⁹ The interstitium is wide and contains few Leydig cell precursors. If one testis is undescended, its histology does not differ from that of the contralateral testis. The testicular pattern remains constant through childhood.¹¹³⁰ At puberty, before maturation of the tunica propria occurs, the seminiferous tubules rapidly hyalinize and Leydig cell precursors differentiate into Leydig cells.¹¹³¹

Association of Klinefelter's syndrome with precocious puberty Although precocious puberty is not a characteristic finding in Klinefelter's syndrome, karyotyping in older boys

with mental retardation, gynecomastia, small testes, and precocious puberty is advisable. In most cases, the cause of precocious puberty is a hCG-secreting germ cell tumor in the mediastinum.¹¹³² Infrequently, precocious puberty is idiopathic, and only in isolated cases is there a hamartoma in the third ventricle.¹¹³³

Association of Klinefelter's syndrome with hypogonadotropic hypogonadism Klinefelter's syndrome is often associated with pituitary disorders such as panhypopituitarism¹¹³⁴ or incomplete hypopituitarism.¹¹³⁵ Deficits in FSH,¹¹³⁶ LH,¹¹³⁷ or both^{1138,1139} have been reported. The cause of this association is unknown, and diverse etiologies such as trauma, immunologic disorders, and genetic deficiencies have been postulated. Alternatively, it may be due to exhaustion of pituitary gonadotropin-secreting cells after years of gonadotropin-releasing hormone stimulation.¹¹³⁵

In patients deficient in both gonadotropins, testicular biopsy shows diffuse tubular hyalinization and a marked reduction in or absence of Leydig cells. The histological picture is similar to that of hypogonadotropic hypogonadism occurring after puberty, except for the presence of isolated tubules containing only dysgenetic Sertoli cells and absence of elastic fibers in the hyalinized tubular wall (Fig. 12-130).¹¹³⁹ Biopsy of patients with a deficit only in FSH is similar to that of the dysgenetic Sertoli cell variant of the Sertoli cell-only syndrome, although some hyalinized tubules are present. The testicular biopsy of patients deficient only in LH resembles that of men with classic 47XXY Klinefelter's syndrome.

46XX males The 46XX karyotype may be present in three phenotypes: male phenotype, including normal external genitalia; male pseudohermaphrodites, with a variable degree of ambiguity in external genitalia, ranging from hypospadias to micropenis; and true male hermaphrodites.

46XX males with male phenotype and normal external genitalia Men with the 46XX karyotype having male phenotype and normal external genitalia have clinical features similar

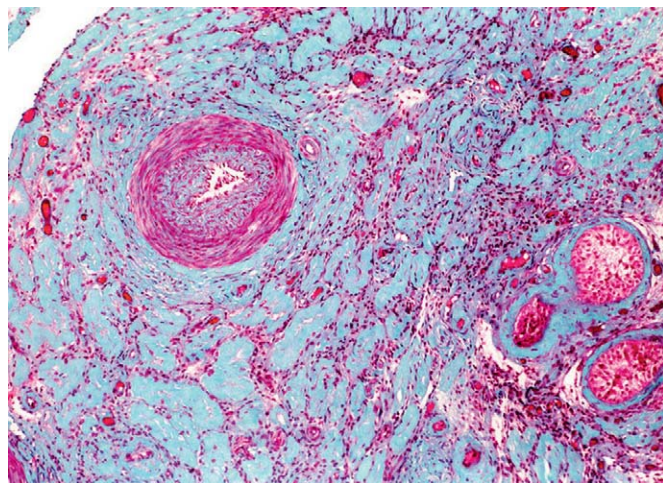


Fig. 12-130 Klinefelter's syndrome with hypogonadotropic hypogonadism showing diffuse tubular hyalinization associated with absence of Leydig cells. Only tubules with dysgenetic Sertoli cells are present.

to those of Klinefelter's syndrome, including small testes, small or normal penis, azoospermia, gynecomastia, and minimal development of secondary sex characteristics. However, these men have harmonious body proportions, normal or slightly low stature, and normal intelligence.¹¹⁴⁰ The incidence of 46XX males varies from 1:10 000 to 1:25 000 live births, accounting for about 0.2% of infertile men.^{1141,1142} Males with 46XX karyotype have hypergonadotropic hypogonadism with elevated serum levels of FSH and, to a lesser degree, elevated LH, with normal or slightly decreased testosterone. Familial cases have been reported.¹¹⁴³

During childhood, biopsy of 46XX males reveals decreased numbers of germ cells.^{1144,1145} Biopsies from adults show one of three patterns: histology similar to that of 47XXY men, including diffuse tubular hyalinization with prominent Leydig cells,¹¹⁴⁶ Sertoli cell-only tubules,^{1147,1148} and both patterns intermingled with less prominent Leydig cells. The last is the most frequent (Fig. 12-131). Ultrastructural studies reveal an increase in intermediate filaments, absence of annulate lamellae in Sertoli cells,¹¹⁴⁹ absence of Reinke's crystalloids, and abundance of intracytoplasmic and intranuclear paracrystalline inclusions in Leydig cells.¹¹⁴⁷

46XX males with ambiguous external genitalia Some patients with the 46XX karyotype have ambiguous external genitalia or hypospadias and are assumed to have a variation of male pseudohermaphroditism.¹¹⁵⁰ These males, together with true hermaphrodites, may be found in the same family, suggesting that both disorders are different manifestations of the same genetic defect.

Etiology of 46XX males The origin of 46XX males may be difficult to determine. However, as testicular differentiation requires genes located on the Y chromosome, 46XX males have been classified by cytogenetics as those having the SRY gene, those lacking the SRY gene, and XX/XY mosaicism. Males with the SRY gene comprise 80% of 46XX males.¹¹⁵¹ It is likely that this occurs when the genetic material from

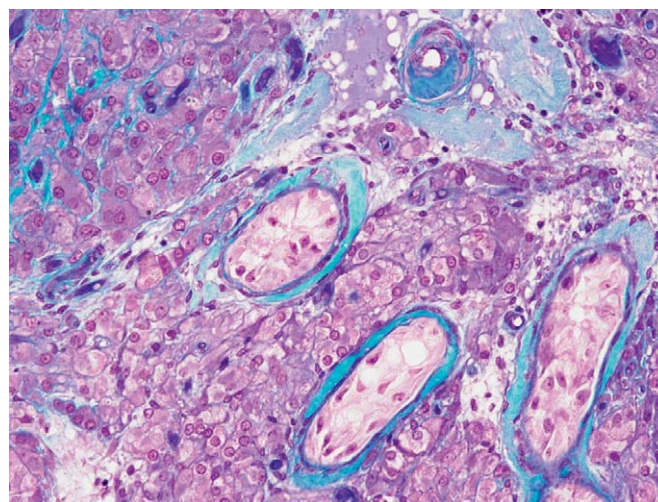


Fig. 12-131 Testis from a 46XX male showing Sertoli-cell-only tubules together with hyalinized tubules, and nodular and diffuse Leydig cell hyperplasia.

the short arm of the Y chromosome is translocated to the X chromosome.¹¹⁵² During paternal meiosis, the homolog pseudoautosomal regions of chromosomes X and Y interchange the terminal portions of their short arms, giving rise to an X chromosome with the SRY gene but lacking the azoospermia factor.¹¹⁵³⁻¹¹⁵⁸ Alternatively, the SRY region may be inserted in an autosome.¹¹⁵⁹ Most 46XX patients who are SRY positive have a normal male phenotype. About 10% of 46XX males are SRY negative and most have ambiguous genitalia. Some patients have a normal male phenotype¹¹⁶¹ and only infertility.¹¹⁶² Although SRY is assumed to be the most important regulator factor of testicular determination, these patients may have mutation of one of the downstream non-Y testis-determining genes.¹¹⁶³⁻¹¹⁶⁶ About 10% of 46XX males have XX/XY mosaicism or other karyotype with the chromosomal complement Y. In these cases, detection of the specific DNA sequences of Y chromosome may be difficult because this chromosome may be only in some tissues and in a small number of cells.¹¹⁶⁰

47XYY syndrome The 47XYY syndrome was first described in 1961 in the father of a girl with Down's syndrome.¹¹⁶⁷ The only clinical findings were excessive height and pustular acne. Study of other cases suggests that these men are predisposed to a psychopathic personality and antisocial behavior, although most have a normal personality and are socially adapted. The incidence of 47XYY patients is estimated to be 0.01% of the general population, 0.7-0.9% of men in prison, and 1.8% of sexual homicide criminals.¹¹⁶⁸ The extra Y chromosome originates from non-disjunction during the paternal second meiotic division.

In the past decade, many cases have been diagnosed prenatally. From birth, the patients have weight, stature and cephalic circumference above mean values and a higher risk for delayed language and/or motor development. About 50% of children have psychological and psychiatric problems such as autism; although their intelligence is normal, many patients are referred to special education programs.¹¹⁶⁹ As adults, they have normal external genitalia and secondary sex characteristics. Fertility is reduced,¹¹⁷⁰ although many have been fathers. Usually, testicular biopsy reveals mixed atrophy characterized by tubules with spermatogenesis associated with Sertoli cell-only tubules (Fig. 12-132).^{1171,1172} Those tubules with spermatogenesis may show normal spermatogenesis or have lesions in the adluminal or basal compartments. In these tubules, many XXY spermatocytes degenerate during meiosis. About 64 % of pachytene cells have three sex chromosomes.¹¹⁷³ The number of normal spermatozoa in the ejaculate is low. There is a high incidence of both YY and XY spermatozoa and disomy 18.

The variability in germ cell development is apparently due to elimination of germ cells that could not pair their sex chromosomes during the first or second meiotic divisions¹¹⁷⁴ or, later, during the round spermatid stage.¹¹⁷⁵ Spermatocytes that succeed in forming trivalent chromosomes are initially viable.¹¹⁷⁶ The ultimate trivalent chromosome segregation yields aneuploid and euploid cells in equal numbers. Sertoli cell-only tubules are attributed to either spermatogonial damage by substances released from degenerated spermatocytes¹¹⁷⁷ or absence of testicular colonization

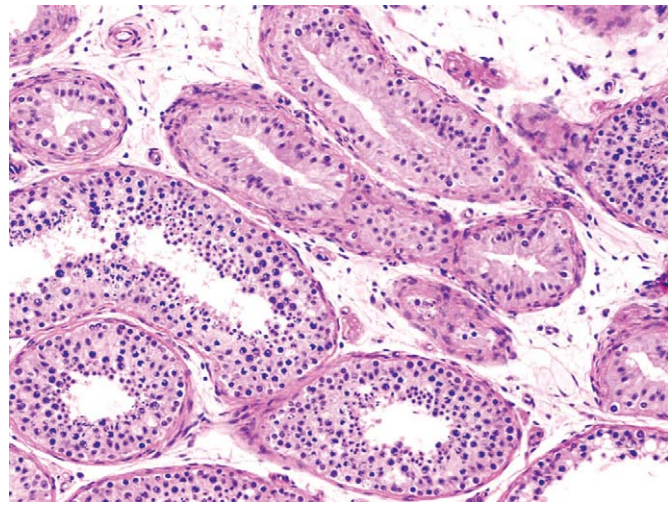


Fig. 12-132 47/XYY syndrome. The testis show tubules with complete spermatogenesis, Sertoli-cell-only tubules, and tubules with spermatogonial maturation arrest.

by primordial germ cells. These men have normal serum levels of testosterone and LH. The latter may be slightly increased in 47XYY men with severe spermatogenic alterations.¹¹⁷⁸

47XYY men with mosaicism (47XYY/46XY) have a higher risk of fathering children with hyperdiploid chromosomal constitution, and spermatozoa should be studied genetically to evaluate the risk of intracytoplasmic sperm injection.¹¹⁷⁹

Men with three and four Y chromosomes have been reported. Men with the 48XYYY karyotype are tall and have normal male phenotype, slight mental retardation, azoospermia and, during childhood, frequent infections of the upper respiratory tract.¹¹⁸⁰ Testicular biopsy shows Sertoli cell-only tubules, severe hyalinization of tubular basement membrane, and diffuse Leydig cell hyperplasia. The chromosomal complement of parents can be normal.¹¹⁸¹ Men with 49XYYYY also have no significant phenotypic abnormalities (except for cases of chromosomal mosaicism). Slight mental retardation, infertility, and antisocial behavior are the most significant clinical findings.¹¹⁸² Rarely patients have facial dysmorphism and various skeletal abnormalities.¹¹⁸³

Structural anomalies of the Y chromosome

The Y chromosome is essential for gender determination and spermatogenesis, and abnormalities often lead to infertility. The relationship between Y chromosome abnormalities and infertility is best understood in azoospermic men with alterations in Yq11, the distal region of the euchromatic part of the long Y arm, the location of a male fertility gene complex called azoospermia factor. Infertility may result from deletion of any of four subregions in which the azoospermia factor has been divided (AZFa, AZFb, AZFc and AZFd).^{1184,1185} The best-known Y chromosome genes involved in spermatogenesis are RBM, DAZ, DFFRY, CDY, SMCY, and ZFY. Six different partial deletions of this region have been found in azoospermic patients (Table 12-10). Other genes related to spermatogenesis are BPY2, PRY, TTY1, TTY2, and VCY.¹¹⁸⁶

Table 12-10 Pathologic findings in infertile men with Y chromosome anomalies in the Y_q11 region

Karyotype	External genitalia	Testicular lesions	Associated anomalies
46XY _q	Small testes	Tubular hyalinization, Sertoli cell-only, spermatogenetic maturation arrest	Low stature, mental retardation, gynecomastia
46XY _{nf} 45X0	Small and soft testes, small penis, ambiguous genitalia, cryptorchidism, hypospadias	Tubular hyalinization, Sertoli cell-only, Leydig cell hyperplasia, decreased spermatid number	Low stature, gynecomastia
46Xr(Y) 45X0	Small testes, cryptorchidism, hypospadias	Sertoli cell-only, spermatogenetic arrest in premeiotic spermatocytes	Low stature
46Xt(Y _p 11,Y _q 11) 45X0	Small and soft testes, hypospadias	Spermatogenetic arrest in premeiotic spermatocytes, decreased spermatid number	Low stature
46Yt(X _p 22,Y _q 11)	Small testes, small penis	Spermatogenetic arrest in premeiotic spermatocytes	Mental retardation, digital anomalies, facial dysmorphism
46XY _q t(Y _q 11-qter,A)	Normal or small testes	Spermatogenetic arrest in premeiotic spermatocytes	
46Xt(Y _q 11-pter,A)	Normal or hypoplastic testes, cryptorchidism, hypospadias	Sertoli cell-only, immature seminiferous tubules	

Monocentric deleted Yq chromosome Partial deletion of the distal portion of the Yq11 euchromatic region is associated with azoospermia owing to loss of the azoospermia factor. These men have normal external genitalia except for small testes,¹¹⁸⁷ normal testosterone and LH serum levels, and increased FSH serum level. The most frequent histological finding is Sertoli cell-only pattern, although many other patterns have been reported.¹¹⁸⁸ The number of Leydig cells is normal or increased. These findings suggest that the azoospermia factor is required for early spermatogenesis.¹¹⁸⁹ If the breakpoint of Yq11 is proximal to the centromere, patients are short because the gene that controls stature is close to that for the azoospermia factor.¹¹⁹⁰

Dicentric Yq isochromosomes Sterility is frequent in men with dicentric Yq isochromosomes.¹¹⁹¹ This anomaly is usually associated with a 45X cell line. The proportion of this line varies between patients and between cell types (fibroblasts or lymphocytes). When the point of breakage and fusion of the two Y chromosomes is in the distal region Yq11, and the second centromere is inactivated, the Y isochromosome is normal in size but does not stain with quinacrine, and thus is called non-fluorescent Y chromosome (Ynf). As the breakpoint is in the Yq11 region, the azoospermia factor function is altered. Development of external genitalia varies from ambiguous to normal, and is probably related to the extent of XO present.¹¹⁹² Testicular biopsies are similar to those of men with monocentric deleted Yq chromosomes (Fig. 12-133).^{1193,1194}

Ring Y chromosome Men with ring Y chromosomes have normal male phenotype, azoospermia, and, in some cases, short stature. Most have mosaic karyotype with a 45X line. In some cases, testicular biopsy resembles that of men with monocentric deleted Yq chromosome, but in others there is premeiotic arrest of spermatocyte maturation.¹¹⁹⁵ This is attributed to difficulty in pairing the X and Y chromosomes during meiosis. Many patients have deletion of some AZF regions.^{1196,1197}

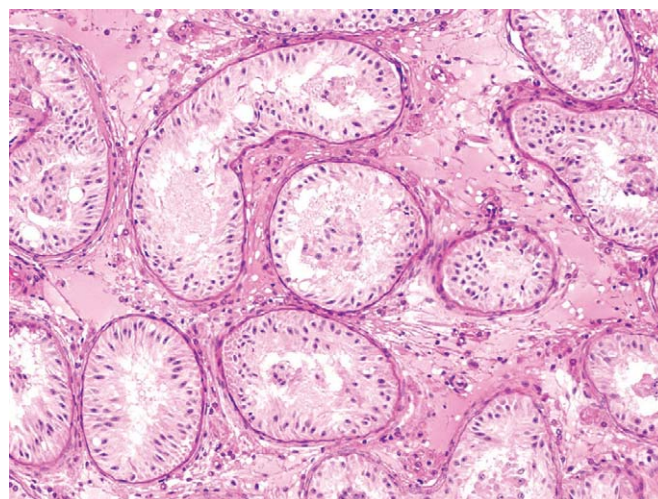


Fig. 12-133 Testis from a male with dicentric Yq isochromosome showing seminiferous tubules with Sertoli cell-only pattern and slight Leydig cell hyperplasia.

Y/Y translocation chromosome Patients with this anomaly have small soft testes and primary spermatocyte maturation arrest owing to defective pairing of the X and Y chromosomes. The karyotype may be mosaic with a 45X line.¹¹⁹⁸

Translocation of Y chromosome to X chromosome Most frequently this translocation is cytogenetically undetectable, and patients present with infertility and are found to have 46XX karyotype.¹¹⁹⁹ The phenotype is similar to that of men with Klinefelter's syndrome except for shorter stature, absence of mental retardation, and smaller teeth. Testicular biopsy shows Sertoli cell-only pattern. Men with cytogenetically detectable translocations have short stature, small testes, tubular hyalinization, and prominent clustered Leydig cells similar to Klinefelter's syndrome.

Autosomal translocation of Y chromosome Translocation of the distal heterochromatic portion of the Y chromosome to the short arm of an acrocentric chromosome occurs occasionally. The most frequent are translocations to chromosomes 5, 18, 13, 15, and 22. The fertility of these men depends on the point of breakage.^{1200,1201} If this occurs in the Yq12 heterochromatic region, the patient has a male phenotype and is fertile. If the point of breakage is in the Yq11 region, the patient is infertile and has small testes. Seminiferous tubules may show only Sertoli cells, spermatogenetic arrest in early stages of meiosis, or an infantile pattern.^{1202,1203}

Interstitial microdeletion in Yq11 Yq11 microdeletion is the most frequent congenital cause of infertility. The frequency of Y chromosome microdeletion in infertile patients varies widely (1–35%).¹²⁰⁴ In azoospermic men, the frequency is between 18%¹²⁰⁵ and 37%.¹²⁰⁶ In oligozoospermic males the incidence drops. Most microdeletions are in the AZFc sub-region.^{1207,1208} Testicular biopsy shows only Sertoli cells, maturation arrest, or mixed atrophy. There is no correlation between site of AZF subregion alteration and histological pattern.¹²⁰⁹ There is no exact correlation between genotype and phenotype,¹²⁰⁹ but most microdeletions in AZFa are associated with azoospermia, most microdeletions in AZFb are associated with maturation arrest, and most microdeletions of AZFc are associated with spermatid maturation arrest or mixed testicular atrophy. Partial deletion of AZFc has a mild effect on fertility.¹²¹⁰

Structural anomalies of the X chromosome

External genitalia in 46XY patients with duplication of distal Xp vary from male, ambiguous, to female, and gonadal dysgenesis is frequent. If the patient has male genitalia, these are usually hypoplastic with hypogonadotropic hypogonadism and, frequently, multiple congenital anomalies and mental retardation.¹²¹¹

Males with translocation of the X chromosome to an autosome may have disturbed spermatogenesis with subfertility or infertility.^{1212,1213} 47XXX males show mental retardation, gynecomastia, normal stature, hypoplastic scrotum, a well-configured but small penis, small testes, and poorly developed pubic hair. Serum testosterone levels are very low. Seminiferous tubules appear severely hyalinized. 47XXX males result from an abnormal X–Y interchange during paternal meiosis and X–X non-disjunction during maternal meiosis.¹²¹⁴

Anomalies in autosomes

There have been many reports on the relationship between autosomal anomalies and infertility, although the causes are not fully understood because the same anomaly is associated with infertility in some patients but not in others.

Chromosomal translocations and inversions

Robertsonian translocations are found in 0.7% of infertile men (8.5% higher than in the normal population) and are more frequent in oligozoospermic than in azoospermic men. The most frequent translocations are 13;14 and 14;21.

The incidence of reciprocal translocations in infertile patients is 0.5% (0.1% in the general population) and

increases to 0.8% in patients with azoospermia or severe oligozoospermia.¹²¹⁵ The most frequent in infertile men are 11;22 and 17;21.

Paracentric and pericentric inversions (except for the pericentric inversion of the heterochromatic region in chromosome 9) are eight times greater in infertile patients (0.16%) than in the general population. The highest risk for infertility occurs in the pericentric inversion of chromosome 1.^{1216,1217}

The most common testicular lesions in men with autosomal anomalies are spermatogonial maturation arrest, primary spermatocyte sloughing sometimes associated with hypospermatogenesis, and Sertoli cell-only pattern.¹²¹⁸

Down's syndrome

The only autosomal anomaly with prolonged survival is Down's syndrome. In addition to trisomy of chromosome 21 and the characteristic appearance, patients with Down's syndrome usually have cryptorchidism, small testes, hypoplasia of the penis and scrotum, and hypospadias.¹²¹⁹ Adults have oligozoospermia or azoospermia secondary to primary testicular deficiency. Levels of FSH and LH are elevated, but testosterone is normal or slightly diminished.¹²²⁰ Isolated cases of paternity have been reported.^{1221,1222}

In utero, there is marked delay in germ cell development.¹²²³ Histologic studies of prepubertal testes at autopsy reveal decreased tubular diameter and tubular fertility index. Eosinophilic bodies or microliths may be present in some tubules (Fig. 12-134). Adult testes have deficient spermatogenesis and mixed atrophy, with some tubules showing complete spermatogenesis and others containing Sertoli cell-only pattern.¹²²⁴

Other syndromes associated with hypergonadotropic hypogonadism

Hypergonadotropic hypogonadism is found in several myopathies (myotonic dystrophy and progressive muscular

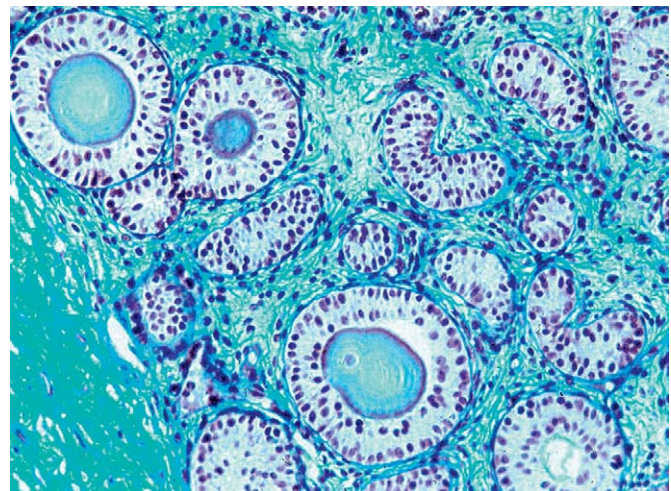


Fig. 12-134 Prepubertal testis in Down's syndrome. There are megatubules, ring-shaped tubules, and small tubules. Germ cell number is very low in all these tubules. Eosinophilic bodies or microliths are present in some tubules.

dystrophy) and dermatopathies (Bloom's, Rothmund–Thomson, Werner's, Cockayne's, and Tay's syndromes), with testicular histology that resembles that of Klinefelter's syndrome. Hypogonadism is also observed in Noonan's syndrome, cerebellar ataxia (with milder testicular lesions), and a miscellaneous group of syndromes with variable histological findings.¹²²⁵

Myotonic dystrophy accounts for approximately 30% of men with muscular disorders, and about 80% have testicular atrophy. The estimated incidence is 1 in 8000 live births. The abnormality involves the distal muscles of the extremities. In addition, patients may have premature baldness, posterior subcapsular cataracts, cardiac conduction defects, impotence, gynecomastia (rarely), and dementia (at later stages). Myotonic dystrophy is an autosomal dominant inherited disease with variable penetrance. Two loci are associated with the disease phenotype: DM1 in 19q13.3, and DM2 in chromosome 3. Mutation in DM1 results in a serine/threonine protein kinase deficiency that causes expansion of a CTG repeat (from 50 to several hundred repeats) located on the 3'-untranslated region of the dystrophy myotonic-protein kinase gene. The number of repeats is positively correlated to severity of the disease and negatively correlated to age of clinical onset.^{1226–1228} DM2 is caused by a mutation in 3q21.3 of the ZNF9 gene and accounts for CCTG-repeat expansion (from 75 to 11 000 repeats) in intron 1 of this gene. The common clinical symptoms are due to gain of function of RNA mechanism in CUG and CCUG repeats altering cellular function, including alternative splicing of various genes.¹²²⁹ The severity of the disease increases in the successive generations.¹²³⁰ The number of CTG repeats is not associated with male subfertility.¹²³¹

Hypogonadism is hypergonadotropic in most cases and is not related to the number of CTG repeats.¹²³² Testicular lesions probably begin late because 65% of patients are fathers. Testicular biopsy shows different degrees of severity, ranging from nearly normal to fully hyalinized seminiferous tubules, with the number of Leydig cells varying from increased to decreased. In some patients the hypogonadism is hypogonadotropic, and the testes show an infantile pattern. Infertility may be the first symptom of myotonic dystrophy.¹²³³

Progressive muscular dystrophy is a multisystemic X-linked disease. It is usually associated with gonadal atrophy caused by a defective locus in chromosome 19. Patients rarely live more than 20 years. The incidence is approximately 1 in 4000 live births. In both Duchenne and Becker forms the cause is a defect in the dystrophin gene.^{1234,1235}

Bloom's, Rothmund–Thomson, and Werner's syndromes are caused by a homozygous defect in human RECEQ helicases in chromosome 15. Of the five members of this gene family (RECQ1, BLM, WRN, RECQ4, and RECQ5), three produce autosomal recessive inherited diseases. Mutations of BLM have been identified in patients with Bloom's syndrome, WRN has been shown to be mutated in Werner's syndrome, and mutations of RecQ4 have been associated with Rothmund–Thomson syndrome.^{1236,1237} Despite the close genetic origin of the three syndromes, symptoms are very different. *Bloom's syndrome* is characterized by short

stature, narrow face with prominent nose, facial 'patchy' skin color changes that become more marked with sun light exposure, and increased susceptibility to respiratory diseases, cancer and leukemia. Severe oligozoospermia and azoospermia are common. Leydig cell function is conserved.¹²³⁸ *Rothmund–Thomson syndrome* presents with poikiloderma, juvenile cataracts, sparse hair, short stature, skeletal defects, dystrophic teeth and nails, and hypogonadism. These patients are predisposed to cancer and osteogenic sarcoma.¹²³⁹ *Werner's syndrome (progeria)* is characterized by short stature, prematurely graying hair, baldness, cataracts, atrophy and calcification of muscle and fat, wrinkling of the skin, keratosis, osteoporosis, telangiectasis, atheroma, diabetes mellitus, gynecomastia, and hypergonadotropic hypogonadism. The lifespan of fibroblasts and other cells is shortened in this syndrome. The mutation is in the RECQ3 helicase gene.

Cockayne's syndrome is a rare autosomal recessive neurodegenerative disorder. Signs and symptoms include infantile failure to thrive, short stature, poorly developed trunk, premature aging, neurological alterations, retinitis pigmentosa, optic atrophy, cataract, deafness, microcephaly, micrognathia, photosensitivity, delayed eruption of primary teeth, congenital absence of some permanent teeth, partial macrodontia, atrophy of the alveolar process and caries, limited articular movements in elbows, knees, and fingers,¹²⁴⁰ abnormally small eccrine glands,¹²⁴¹ and hypergonadotropic hypogonadism. It may be caused by two gene mutations: CNK1 (ERCC8) and ERCC6, located respectively on chromosomes 5 and 10, and causing two variations of Cockayne's syndrome, including CS-A, secondary to a ERCC8 mutation, and CS-B with ERCC6 mutation. CS-B patients have hypersensitivity to ultraviolet light secondary to a DNA repair defect.¹²⁴²

Tay's syndrome (trichothiodystrophy) has two presentations: IBSD (ichthyosis, brittle hair, impaired intelligence, short stature) and IBISD (photosensitivity, ichthyosis, brittle hair, impaired intelligence, short stature). In both forms, patients have decreased fertility. One case of hypergonadotropic hypogonadism has been reported.¹²⁴³

Noonan's syndrome is characterized by multiple malformations reminiscent of Turner's syndrome, including short stature, pterygium coli, and cubitus valgus, although there is normal male karyotype. The disease has an incidence of 1 in 1000 to 1 in 2500 live births and autosomal dominant inheritance, with sporadic occurrence in about 50% of cases. A locus for dominant forms has been mapped to 12q24.1.¹²⁴⁴ Mutation in PTPN11 (protein-tyrosine phosphatase, non-receptor-type 11) accounts for half of cases, although similar germline mutations also cause Leopard's syndrome and certain pediatric hematopoietic malignancies.¹²⁴⁵ Cryptorchidism is present in about 70% of cases and is usually bilateral. During childhood, testicular biopsy shows a low tubular fertility index. Puberty is often delayed, and, at adulthood, hypogonadotropic or hypergonadotropic hypogonadism occurs. Ultrastructural studies reveal morphologic anomalies in germ cells.¹²⁴⁶ Although spermatogenesis is generally impaired, some patients have been fertile (Fig. 12-135).

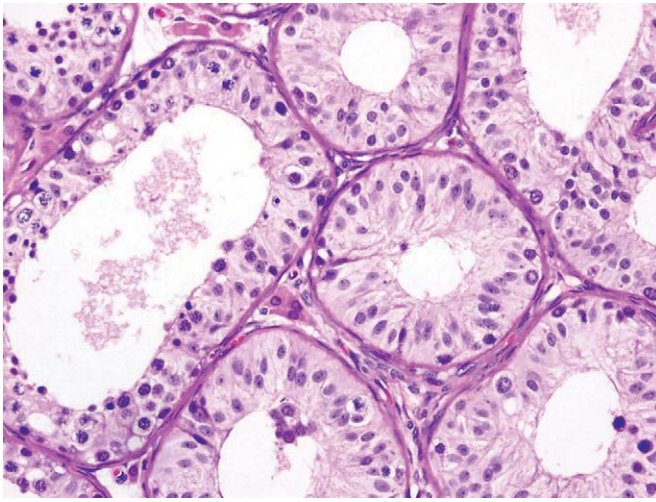


Fig. 12-135 Testis from a 15-year-old boy with Noonan's syndrome. Most seminiferous tubules are small and contain Sertoli cells and isolated spermatogonia. The most dilated tubules have complete although quantitatively decreased spermatogenesis.

Cerebellar atrophy may be associated with hypogonadism. Patients are infertile and have moderate ataxia without endocrine disorder. Infertility is due to morphological abnormalities of spermatozoa caused by decreased expression of MAP2 (the most important microtubule-associated protein), and a defect in erythroid ankyrin.^{1247,1248}

Many other syndromes also present with primary hypogonadism. The best known are Alström's, Weinstein's, Borjesson–Forssman–Lehmann, Marinesco–Sjögren, Richards–Rundle, Robinow's, and Silver–Russell syndromes.

Secondary idiopathic hypogonadism

Hypogonadotropic hypogonadism or hypogonadism of hypothalamo–hypophyseal origin is classified according to whether the hypothalamo–hypophyseal failure occurs before or after puberty. Eunuchoidism, present only in the former group, is the basis of the distinction. The most frequent types of hypogonadism caused by hypothalamo–hypophyseal failure are those caused by a deficit of gonadotropin-releasing hormone, bioinactive FSH and LH, deficit in growth hormone, those associated with Prader–Willi syndrome, and Laurence–Moon–Rozabal–Bardet–Biedl syndrome.

GnRH deficit

The onset and maintenance of the hypothalamo–hypophyseal–gonadal axis is due to pulsatile gonadotropin-releasing hormone (GnRH) secretion by neurons of the nucleus arcuatus hypothalamus, with release into the pituitary portal system and subsequent stimulation of gonadotropin-releasing hormone receptors on the surface of gonadotropin-secreting cells. The GnRH gene is located on 4q13.¹²⁴⁹

Patients with GnRH deficit have partial or complete absence of GnRH-induced pulsatile LH secretion, and normalization of pituitary and gonadal secretions after exogenous GnRH administration. Imaging studies of the hypothalamo–hypophyseal region are normal. Clinical

symptoms vary with age at presentation (congenital or acquired) and severity (complete or partial deficit). Clinical presentations include delayed puberty, idiopathic hypogonadotropic hypogonadism (isolated gonadotropin deficit), Kallmann's syndrome, isolated FSH deficit, and isolated LH deficit (fertile eunuch syndrome).

Constitutional delayed puberty

Constitutional delayed puberty is assumed to be a minor form of GnRH deficit,¹²⁵⁰ and is characterized by delayed sexual maturation in otherwise healthy males. Patients are short and usually have a family history of delayed puberty. Puberty usually begins at 13–14 years of age and progresses over 2 years. If a 14-year-old boy has not begun pubertal changes (testicular enlargement, growth in height, and development of secondary sex characteristics), delayed puberty should be suspected.¹²⁵¹ Simple pubertal delay that is overcome naturally in a short time without treatment must be distinguished from hypogonadotropic hypogonadism. The latter should be suspected when any of the following symptoms are present in the patient or his family: a midline defect, anosmia, or pubic hair without testicular development. Hormone assays may also assist in diagnosis. If a patient between 16 and 18 years old has prepubertal gonadotropin levels, he probably has hypogonadotropic hypogonadism.

Isolated gonadotropin deficit

A variant of hypogonadotropic hypogonadism, isolated gonadotropin deficit is characterized by defects in the synthesis or release of FSH and LH; other hypophyseal functions are normal. Patients have eunuchoid phenotype, with small testes and penis, scanty body hair and beard, a high-pitched voice, and poorly developed muscles. Presentation may be sporadic, autosomal dominant, autosomal recessive, or X-linked. The cause might be a mutation in the GnRH receptor gene.¹²⁵² Patients have very low levels of FSH, LH, testosterone, and estrogen. Clomiphene citrate treatment fails to stimulate hormonal secretion.¹²⁵³ Pulsatile administration of GnRH is useful to promote both androgen production and spermatogenesis. The LH–Leydig cell–testosterone axis is normal in most cases, but normalization of the FSH–Sertoli cell–inhibin axis is not achieved in all cases. Basal inhibin levels higher than 60 pg/mL and absence of cryptorchidism are favorable predictor factors for the acquisition of normal testicular size and acceptable spermatogenesis.¹²⁵⁴

Testicular biopsy reveals an immature pattern. The seminiferous tubules have neither lumina nor elastic fibers (Fig. 12-136). Sertoli cells are immature, and no differentiated Leydig cells are seen. Spermatogonia are rare. In some patients the pattern is similar to that of Sertoli cell-only testes with immature Sertoli cells.¹²⁵⁵

Hypogonadism associated with anosmia

Hypogonadism associated with anosmia is also known as Maestre de San Juan,¹²⁵⁶ Kallman,¹²⁵⁷ or De Morsier¹²⁵⁸ syndromes. The two most important features are hypogonadotropic hypogonadism and anosmia. Members of affected families may have both features or only one. Associated

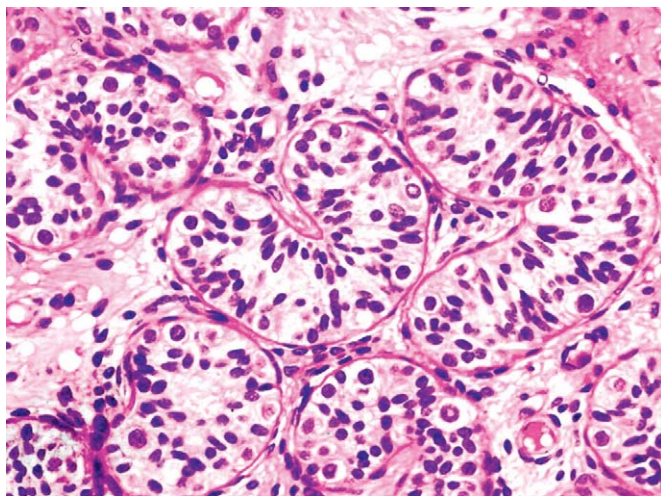


Fig. 12-136 Isolated gonadotropin deficit. The seminiferous tubules have prepubertal diameter, pseudostratified distribution of the Sertoli cells, and several spermatogonia per tubular section.

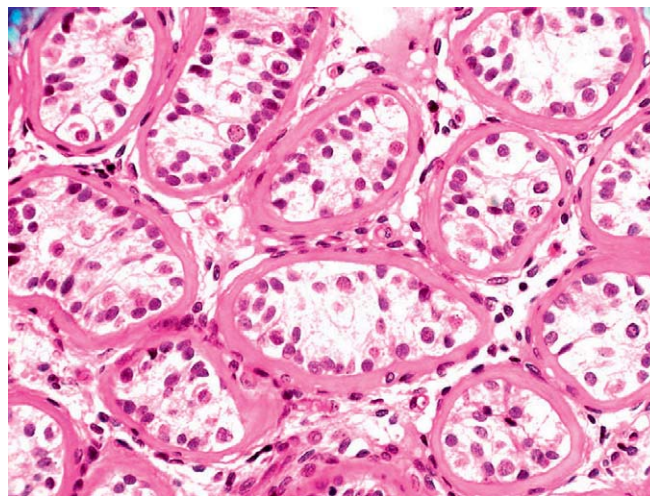


Fig. 12-137 Hypogonadism associated with anosmia in a previously treated patient. The testis shows marked hyalinization of the tubular wall. Some spermatogonia can be observed among the Sertoli cells. The testicular interstitium lacks Leydig cells.

abnormalities include olfactory bulb agenesis, cryptorchidism, mental retardation, color blindness, facial asymmetry, nerve deafness, epilepsy, shortening of the fourth metacarpal, tarsal navicular fibrous dysplasia, familial cerebellar ataxia, diabetes mellitus, hyperlipidemia, gynecomastia, cleft lip, maxillary or palate, unilateral renal aplasia, and cardiovascular abnormalities. The syndrome may be X-linked or autosomal. The gene for the X-linked form is mapped to Xp22.3 and may have different mutations (termed Kal-X, KALIG-1, and ADMLX), complete deletion, and point mutations. This gene encodes the protein anosmina-1, which is similar to other nerve cell adhesion molecules and is involved in axonal growth and development. KAL protein, secreted by mitral cells, permits the passage of olfactory neurons into the olfactory bulbs and is lacking in Kallmann's syndrome. This failure also inhibits migration of neuroblasts from the olfactory epithelium to the hypothalamus to form GnRH-secreting neurons.¹²⁵⁹ The autosomal dominant presentation (occurring in 10% of cases) is due to loss of function of fibroblastic growth factor receptor 1 (FGFR1).¹²⁶⁰ Interaction between KAL1 and FGFR1 is required for neuronal migration.¹²⁶¹

Patients are classified into two groups according to the partial or complete absence of GnRH. Partial absence of GnRH is diagnosed by the presence of spontaneous pulses of LH, FSH, and testosterone during a 24-hour period. Complete absence is diagnosed by the absence of spontaneous pulses of LH, FSH, and testosterone during a 24-hour period. These patients show an increase in FSH only after GnRH administration.¹²⁶² Testes are histologically infantile; the tubules have a small diameter, lack lumina, and contain immature Sertoli cells and isolated spermatogonia.¹²⁶³ The interstitium is wide and consists of acellular connective tissue with no recognizable Leydig cell precursors (Fig. 12-137).¹²⁶⁴

Autopsy studies in patients with anosmia and hypogonadism reveal agenesis of the olfactory bulbs that may be

partial or complete and unilateral or bilateral, together with an apparently normal hypophysis and normal or hypoplastic hypothalamus. This syndrome is the least severe form of holoprosencephaly-hypopituitarism complex, a spectrum of developmental anomalies associated with impaired midline cleavage of the embryonic forebrain, aplasia of the olfactory bulbs and tracts, and midline dysplasia of the face. Testicular seminoma has been reported in a patient with anosmia with hypogonadotropic hypogonadism.¹²⁶⁵

Isolated FSH deficiency

This rare syndrome is characterized by azoospermia or oligozoospermia in normally virilized patients with normal sexual potency. Serum levels of LH and testosterone are normal, but FSH levels are very low or undetectable. The clomiphene stimulation test gives variable results. The GnRH test induces a normal response only of LH. Mutations in the FSH- β gene are exceptional.^{1266,1267}

Testicular biopsy shows maturation arrest at the spermatocyte level, hypospermatogenesis, or partial Sertoli cell-only pattern.¹²⁶⁸ Gonadotropin treatment increases spermatozoal numbers in most cases, and fertility may be induced.

Isolated LH deficiency

Isolated LH deficiency, also known as Pasqualini's or fertile eunuch syndrome,^{1269,1270} is characterized by hypogonadism secondary to LH deficit with preservation of spermatogenesis. Patients have eunuchoid habitus, small testes, decreased libido, female distribution of pubic hair, and a high-pitched voice. Other frequent findings include gynecomastia, anosmia, ocular lesions, and pituitary tumor.¹²⁷¹ FSH level is normal, but LH and testosterone levels are very low. Mutations in the LH- β subunit gene¹²⁷² and the GnRH receptor have been reported.¹²⁷³

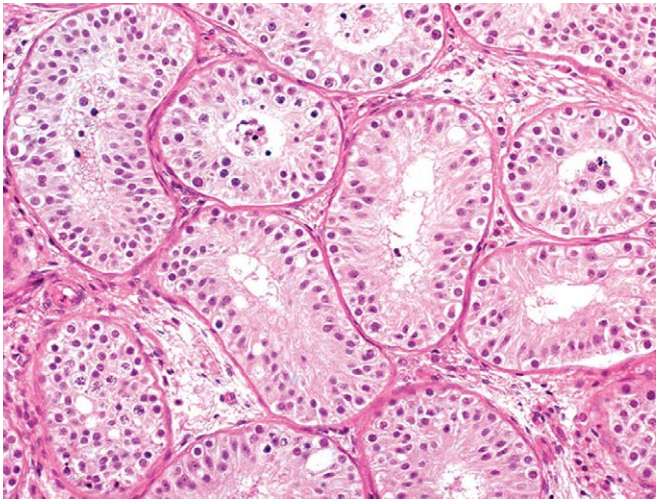


Fig. 12-138 Isolated deficiency of luteinizing hormone. Most seminiferous tubules have a central lumen, numerous spermatogonia, and increased number of Sertoli cells. Spermatocytes and spermatids are observed only in isolated tubules. The testicular interstitium lacks Leydig cells.

The clomiphene test is usually negative, and GnRH stimulation increases LH and, to a lesser degree, FSH. Testicular biopsy shows seminiferous tubules with normal or slightly decreased diameters and complete spermatogenesis; however, the number of all germ cell types is below normal. Leydig cells are rare or absent (Fig. 12-138). Maintenance of spermatogenesis in the absence of Leydig cells and serum testosterone can only be explained by assuming the occurrence of testosterone secretion sufficient for spermatogenesis but not to be detectable in the blood.

Bioinactive FSH and LH

In addition to adequate hypothalamic function, spermatogenesis requires that FSH and LH are biologically active. LH is a heterodimer, composed of two subunits: α (common to FSH and LH) and β (specific for LH). The genes for the β subunit are on 19q13.32. If both alleles are mutated for this subunit, the LH produced is biologically inactive although it may be detectable in standard hormone assay. Homozygous patients have elevated serum level of LH and low testosterone levels, lack of puberty, and infantile testes. Heterozygous patients are only infertile.¹²⁷⁴ Patients with mutation in the β subunit of the FSH gene are oligozoospermic or azoospermic.¹²⁷⁵

Mutations in gonadotropin receptor genes

Activating and inactivating mutations of gonadotropin receptor genes have been reported. Activating mutation of the LH/human chorionic gonadotropin receptor gene causes familial precocious puberty (see discussion on familial testotoxicosis, below). Inactivating mutation of this gene causes male pseudohermaphroditism (see discussion on Leydig cell hypoplasia in this chapter).

Inactivating mutation of the FSH receptor gene produces only mild spermatogenic lesions, emphasizing the relative value assumed for FSH in spermatogenesis. Activating muta-

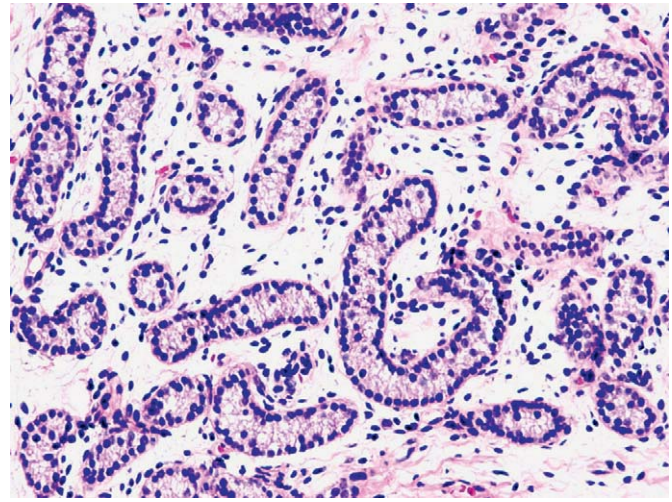


Fig. 12-139 Testis from a 7-year-old child with Prader-Willi syndrome. The seminiferous tubules have a reduced diameter and lack germ cells.

tion of this gene gives rise to spermatogenesis even in the absence of pituitary function.

Growth hormone deficit

Patients with isolated growth hormone deficit and those with resistance to growth hormone action may have delayed puberty and hypogonadotropic hypogonadism.¹²⁷⁶ Some patients with spermatogenetic maturation arrest or idiopathic oligozoospermia have a relative deficit of growth hormone. This hormone probably acts on the testis by stimulating local secretion of insulin-like growth factor-1, which cooperates with testosterone.

Prader-Willi syndrome

Prader-Willi syndrome is characterized by hypogonadism, obesity, muscular hypotonia, mental and physical retardation, and acromicria.¹²⁷⁷ Other frequent findings include strabismus and non-insulin-dependent diabetes mellitus. The incidence is estimated at between 1 in 12 000 and 1 in 15 000 newborns in 25 000 live births, and is higher in males. Patients have low serum levels of LH, testosterone, estradiol, and inhibin B, and high levels of FSH. These hormonal findings suggest the occurrence of a mixed form of central (low LH) and peripheral (low inhibin B and high FSH) hypogonadism.¹²⁷⁸

The penis and testes are hypoplastic, and cryptorchidism is present in about 70% of cases (bilateral in 45% of cases) (Fig. 12-139).¹²⁷⁹ During infancy and childhood, the testes have reduced tubular diameters; adults have an infantile pattern.¹²⁸⁰ This syndrome is caused by an anomaly of chromosome 15, usually in the 15p11-12 band. Other chromosomal anomalies include Robertsonian translocations, reciprocal translocations, small supernumerary metacentric chromosomes, and partial deletion of the long arm of chromosome 15.

Bardet-Biedl syndrome

This syndrome is a pleiotropic disorder characterized by obesity, infantilism, short stature, diabetes insipidus, mental

retardation, retinitis pigmentosa, polydactyly, and syndactyly. It is more frequent in males than in females. Men with this syndrome are infertile, and about 74% show hypogonadism. The testes are prepubertal, the scrotum is hypoplastic or bifid, and the penis is small. Cryptorchidism is found in 42% of males, and is bilateral in 28%. At least 11 genes responsible for this syndrome have been cloned, and it is probable that additional genes are involved. The function of the products of these gene is to mediate and regulate microtubule-based transport processes.^{1281,1282}

Hypogonadotropic hypogonadism associated with dermatologic diseases

Several dermatopathies are associated with hypogonadotropic hypogonadism, including ichthyosis and Johnson's neuroectodermic syndrome. Most cases of ichthyosis associated with hypogonadism are X-linked. About 15% of these patients have cryptorchidism, small testes, micropenis, and high risk of testicular cancer. The cause is a defective microsomal enzyme, steroid sulfatase, causing the accumulation of cholesterol sulfate that hinders sloughing of the cornified layer of the epidermis. The gene responsible for this enzyme is mapped to Xp22.3. Some of these patients also have anosmia or hyposmia owing to involvement of the neighboring genes, causing a contiguous gene defect.¹²⁸³

Johnson-McMillin neuroectodermic syndrome is a rare autosomal dominant disorder characterized by alopecia, hypogonadotropic hypogonadism, anosmia or hyposmia, deafness, prominent ears, microtia and/or atresia of the external auditory meatus, and a pronounced tendency to dental caries.¹²⁸⁴

Hypogonadotropic hypogonadism associated with ataxia

Hypogonadism associated with ataxia is rare. Most patients are the offspring of a consanguineous marriage. Inheritance is autosomal recessive. The most frequent syndromes are Louis-Bar's syndrome (ataxia-telangiectasia) and Friedreich's ataxia.

Ataxia-telangiectasia is the most common inherited ataxia and is characterized by cerebellar ataxia that starts in infancy and develops progressively; mucocutaneous telangiectasis; anomalies of the immune system that cause pulmonary infection; hypersensitivity to ionizing radiation owing to impairment of DNA repair; and a high risk of lymphoid neoplasia. The gene responsible is on 11q22-q23.1.¹²⁸⁵ This ataxia results from inactivation of the A-T mutated (ATM) kinase, a critical protein kinase that regulates the response to DNA double-strand breaks by selective phosphorylation of a variety of substrates.¹²⁸⁶

Friedreich's ataxia is a neurodegenerative disorder characterized by degeneration of dorsal root ganglia and spinocerebellar tracts. Hypertrophic cardiomyopathy is also observed in many of these patients. The incidence is estimated at 1 in 40 000 children. It is caused by defects in the gene encoding frataxin, a protein required for vesicular traffic in cell and synaptic transmission.¹²⁸⁷ About 95% of patients are homozygous for an unstable trinucleoid (GAA) expansion in intron 18 of STM7 on 9q13. The normal gene has up to 35

or 40 triplet repeats, whereas patients with this ataxia carry 70 to more than 1000 GAA triplets.¹²⁸⁸ The normal gene has seven to 22 GAA repeats, whereas the mutated gene has over 120 repeats. The extent of the expanded allele is directly proportional to the severity of disease, early onset of disease, and development of cardiac abnormalities.

Other ataxias associated with hypogonadism are Kearns-Sayre, Boucher-Neuhauser, and Gordon-Holmes syndromes.

Other forms of hypogonadotropic hypogonadism

Hypogonadotropic hypogonadism may also be present in Carpenter's, Biemond's, Fraser's, and Moebius' syndromes, and in patients with mental retardation.

Hypogonadism secondary to endocrine gland dysfunction and other disorders

Maintenance of spermatogenesis requires the harmonious cooperation of several endocrine glands and proper functioning of other tissues. Symptomatic endocrinopathy is present in only 1.7% of infertile men, but over 9% of infertile patients have abnormalities in their endocrine studies.¹²⁸⁹ Hypogonadism may be present in disorders involving the hypothalamus-hypophysis, thyroid, adrenals, pancreas, liver, kidney, and gastrointestinal tract, and may be associated with AIDS, chronic anemia, obesity, lysosomal and peroxisomal diseases, and neoplasia. Hypogonadotropic hypogonadism can also be found in some (usually women) who perform rigorous sports (long-distance runners, swimmers, dancers, and rhythmic gymnasts).¹²⁹⁰

Hypothalamus-hypophysis

Hypopituitarism

Hypogonadism may result from destruction of the hypothalamus or hypophysis by primary or secondary hypothalamic tumor; granulomatous disease (Fig. 12-140); fracture

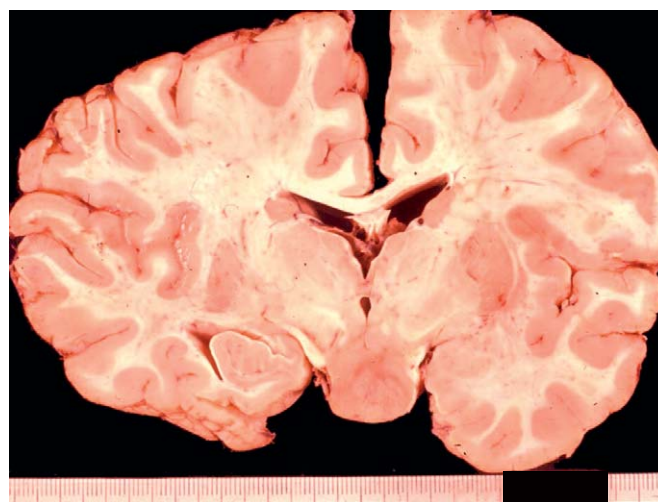


Fig. 12-140 Frontal section from an 18-year-old patient showing destruction of the hypothalamus caused by Langerhans' cell granulomatosis.

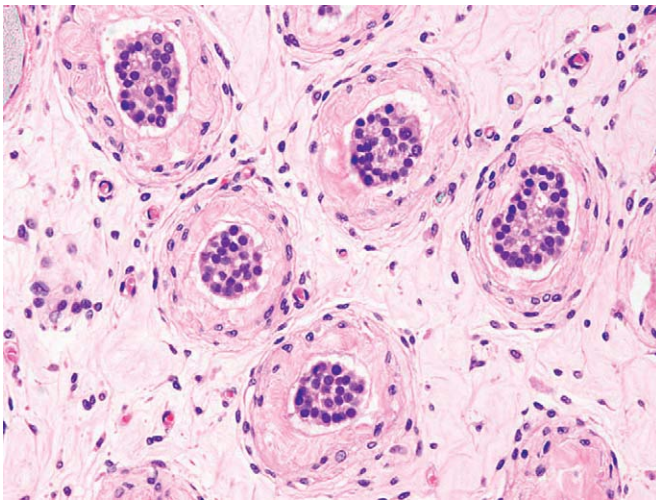


Fig. 12-141 Tubular hyalinization caused by hormonal deprivation and decreased Leydig cell number in a 28-year-old patient who underwent surgery owing to pituitary adenoma. The seminiferous tubules contain dedifferentiated Sertoli cells and isolated spermatozoa.

of the cranial base; radiotherapy for malignancy of the nasopharynx, central nervous system, or the eye orbit; pituitary adenoma and cyst; aneurysm of the inner carotid artery; and chronic and nutritional disease. Many of these processes cause panhypopituitarism with varied symptoms.¹²⁹¹

Clinical manifestations of hypogonadism in patients with pituitary lesions vary according to time of onset (childhood, or after puberty). In prepubertal hypopituitarism the testes retain an infantile appearance into adulthood, and there is rarely proliferation of spermatogonia and the development of primary spermatocytes. Biopsy shows variable hyalinization of tubules. In postpubertal hypopituitarism the appearance ranges from complete spermatogenesis to tubular hyalinization (Fig. 12-141). The presence of elastic fibers in tubular walls indicates that pubertal maturation occurred before the development of hypopituitarism. Leydig cells have pyknotic nuclei and retracted cytoplasm with abundant lipofuscin. In some patients, recovery of spermatogenesis occurs after administration of human chorionic gonadotropin.¹²⁹²

There are cases in which pituitary adenoma secretes both FSH and LH, inducing testosterone hypersecretion and an elevated sperm count.¹²⁹³ FSH-secreting pituitary adenoma associated with large testes and increased serum inhibin concentration has been reported.¹²⁹⁴

Hyperprolactinemia

Prolactin inhibits GnRH secretion and hence FSH and LH secretion. In addition, prolactin has a direct inhibitory effect on androgens in target tissues. In men, hyperprolactinemia causes impairment of spermatogenesis, impotence, loss of libido, and depressed serum testosterone.¹²⁹⁵ Some patients seek treatment because of oligozoospermia and infertility. Hyperprolactinemia is also associated with dysfunction of prolactin receptors.¹²⁹⁶ Spermograms usually show oligozoospermia and an elevated level of fructose,¹²⁸⁷ although

not all males with hyperprolactinemia have subnormal testicular function.¹²⁹⁸

Testicular biopsy reveals variable testicular atrophy. The most frequent lesion is in the tubular adluminal compartment, with degenerative changes in the apical cytoplasm of Sertoli cells, sloughing of young spermatids,¹²⁹⁷ and increased lipid droplets in Leydig cells.¹²⁹⁹ In boys, two different conditions associated with abnormal prolactin secretion have been reported: hyperprolactinemia, testicular enlargement, and primary hypothyroidism; and prolactin deficiency, obesity, and enlarged testes.

Thyroid gland

Infertility caused by thyroid gland malfunction is rare but reversible. It accounts for about 0.5% of male infertility. Testicular function is impaired more by hypo- than by hyperthyroidism. Patients with hyperthyroidism may have gynecostasia, impotence, and infertility. Levels of FSH and LH serum are normal or increased, with elevated sex hormone-binding globulin, increased testosterone concentration, reduced non-sex hormone-binding globulin-bound testosterone, and little or no change in free testosterone.^{1300,1301} In Graves' disease there is a pronounced inhibition of gonadal steroidogenesis.¹³⁰² In patients with hyperthyroidism, spermatozoa may be normal or reduced in number, and in both cases progressive motility is low.

Prepubertal hypothyroidism may impair testicular function by causing precocious or delayed puberty. In delayed puberty, hypothyroidism leads to hypogonadotropic hypogonadism, with testes showing incomplete maturation arrest and, in severe myxedematous hypothyroidism, hydrocele.¹³⁰³ In experimental hypothyroidism, testicular enlargement is frequently associated with increased spermatid production.¹³⁰⁴ Primary hypothyroidism in adults causes hypergonadotropic, hypogonadotropic, or normogonadotropic hypogonadism,¹³⁰⁵ but testicular function is rarely impaired and patients are usually infertile.¹³⁰⁶ The cause of testicular damage is decreased gonadotropins or hyperprolactinemia.¹³⁰⁷ Children with hypothyroidism usually have precocious pseudopuberty.¹³⁰⁸

Adrenals

About 11% of infertile patients reportedly have subclinical adrenal dysfunction, but the true incidence is probably lower. Adrenal disorders most frequently associated with infertility are adrenal hypoplasia, adrenal hyperplasia, and adrenal carcinoma.

Congenital adrenal hypoplasia

Congenital adrenal hypoplasia with hypogonadotropic hypogonadism is an X-linked recessive disorder that gives rise to adrenal insufficiency in the first months of life. In later presentations, patients have cryptorchidism and delayed puberty.¹³⁰⁹ The responsible gene, DAX1 on Xp21, is expressed in the adrenals, testes, pituitary, and hypothalamus. The resulting hypogonadism may be either pure or mixed (hypophyseal and testicular). In the last case, hypogonadism is partial.¹³¹⁰ Testicular biopsy from one adult with adrenal hypoplasia showed an apparent primary lesion,

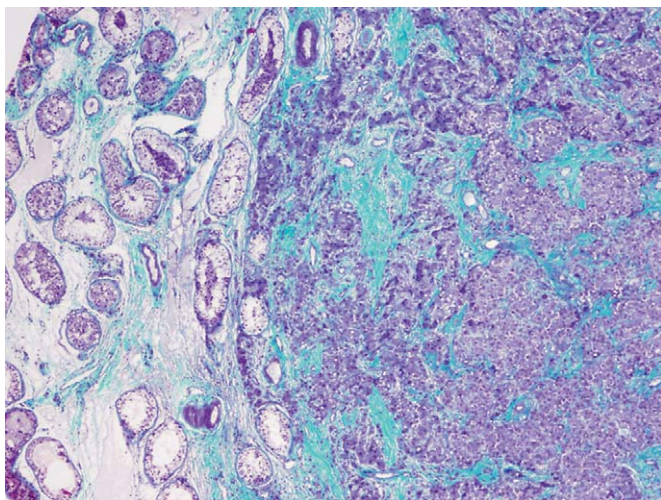


Fig. 12-142 Intratesticular adrenal choristoma near the rete testis from a newborn. The seminiferous tubules are rejected by the mass. The adrenal cortex cells show bizarre nuclei and eosinophilic cytoplasm.

including tubules with dysgenetic Sertoli cells and others with spermatogonial maturation arrest in associated with hypertrophy and hyperplasia of Leydig cells.¹³¹¹

Congenital adrenal hyperplasia

Infertility is frequent in patients with minor forms of congenital adrenal hyperplasia. Those with deficiency of 21-hydroxylase¹³¹² or 11 β -hydroxylase usually have complete spermatogenesis but with reduced numbers of all germ cells. The characteristic histologic finding is decreased numbers of Leydig cells.^{1313–1316} In untreated patients, the testes become enlarged by ‘tumors’ of the adrenogenital syndrome that consist of cells similar to adrenal cortical cells (Fig. 12-142).^{1316–1319}

Adrenal cortical carcinoma

Adrenal carcinoma is often associated with excessive secretion of several hormones, causing hyperaldosteronism, Cushing’s syndrome, virilization, or feminization. Virilizing tumors in infancy have their own characteristics, which differ from those of the same adult tumors as the infantile form may be associated with other disorders, such as hemihypertrophy and Beckwith–Wiederman syndrome, may be included in the spectrum of ‘families with cancer predisposition’ (mutations in p53 gene), and produce precocious pseudopuberty syndrome. In adults, adrenal carcinoma may cause marked spermatogenic depletion owing to the conversion of large amounts of dehydroepiandrosterone produced by the tumor into estrogen. Feminizing tumor in infancy causes gynecomastia and pubic hair development.¹³²⁰ Feminizing tumor presents more striking clinical characteristics, including progressive loss of secondary sex characteristics and feminization due to elevated estrogen. Testicular atrophy results from the inhibitory effect of estrogen on pituitary gonadotropins. Similar symptoms may be observed in patients with prostatic carcinoma treated with estrogens (Fig. 12-143) and in other conditions with excessive estrogen production, such as Sertoli cell or Leydig cell tumor.

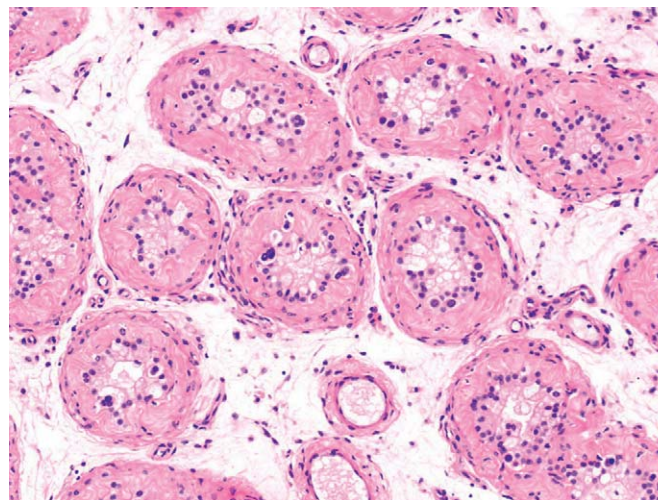


Fig. 12-143 Hypogonadism caused by estrogen therapy for prostate cancer. The seminiferous tubules contain isolated spermatogonia and dedifferentiated Sertoli cells with spherical nuclei, small nucleoli, and pseudostratified infantile distribution. The interstitium contains scattered Leydig cells.

Cushing’s syndrome

Patients with Cushing’s syndrome or diseases that require long-term corticoid therapy, such as ulcerous colitis, rheumatoid arthritis, or asthma, have reversible reduction of fertility. The explanation for this is that most testicular receptors for corticoids are in Leydig cells, and thus glucocorticoids are powerful inhibitors of testosterone synthesis.

Pancreas

Diabetes mellitus

Alterations in the carbohydrate, lipid and protein metabolism characteristic of diabetes mellitus involve the genital system, although most diabetic patients are fertile. Gonadal impairment depends on the type of diabetes and the time of disease onset (infancy and childhood, puberty, or adulthood).^{1321,1322} Testicular lesions in newborns with diabetic mothers are discussed in the section on congenital anomalies of the testis.³¹⁷

Puberty may be delayed in diabetic patients, although the cause is unknown. Other gonadal alterations appear at puberty, and diabetic men who have not been adequately treated may be infertile and have sexual dysfunction. Serum levels of FSH, LH, and testosterone are decreased.¹³²³ Spermograms reveal low numbers and poor motility of spermatozoa.¹³²⁴ Prolactin levels are increased and testosterone levels low or near normal.

The seminiferous tubules have reduced diameters, thickening of the lamina propria, and alterations in the adluminal compartment. These consist of degenerative changes in the Sertoli cell apical cytoplasm and sloughing of immature germ cells. The major lesion is in the interstitial connective tissue and Leydig cells. Small interstitial blood vessels show diabetic microangiopathy characterized by enlargement and duplication of the basal lamina, pericyte degeneration, and endothelial cell alterations. The number of fibroblasts

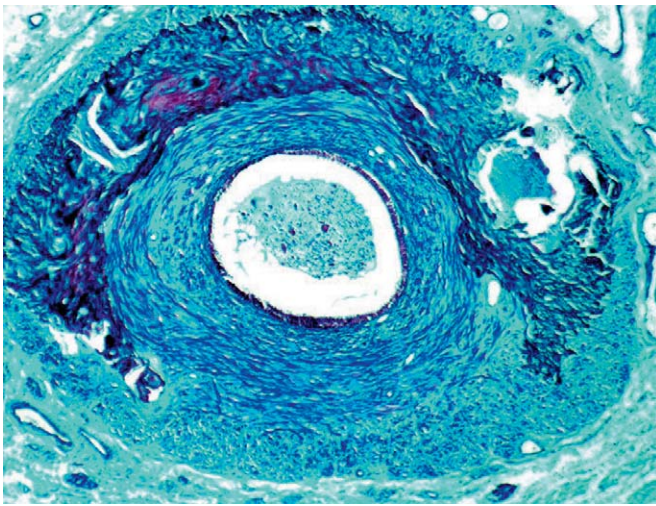


Fig. 12-144 Diabetic patient with dystrophic calcification in the ductus deferens muscular wall.

and the amount of collagen and ground substance in the interstitial connective tissue are increased.¹³²⁵ Leydig cells are decreased in number and show increased amounts of lipid droplets and lysosomes, accounting for the reduced function of these cells.

The tubular lesions are attributed to low serum testosterone, probably owing to deficient Leydig cell stimulation by insulin (or a decrease in insulin-dependent FSH) and abnormal carbohydrate metabolism of Sertoli cells. Sexual dysfunction is present in more than half of patients and consists of impotence, decreased libido, disorders of intercourse, and retrograde ejaculation. The causes of impotence are multiple, including microangiopathy and macroangiopathy, hormonal deficiencies, psychological factors, and autonomic neuropathy affecting the parasympathetic system. Neuropathy is probably chiefly responsible for erectile failure in diabetic men.¹³²⁶ Alterations in sperm excretory ducts may be associated with diabetes. The most frequent are enlarged seminal vesicles and calcification of both seminal vesicles and vasa deferentia. Calcifications are found in the muscular layers and display a concentric arrangement (Fig. 12-144).¹³²⁷

Mucoviscidosis

Although cystic fibrosis (mucoviscidosis) was recognized as a disease prior to 1940, its effects on the male genital system were not recognized until the 1970s. This may be explained by improvements in medical care during childhood, allowing the survival of many patients to adulthood, and the recognition of cystic fibrosis in patients who had been diagnosed with chronic bronchitis and hepatic or digestive dysfunction. In the US, cystic fibrosis is the most lethal congenital disease, with a prevalence of 1 in 2500 children, and a carrier status of 1 in 25 white men.¹³²⁸ Lesions in sperm excretory ducts involve (in decreasing order of frequency) the vas deferens (congenital bilateral absence, unilateral absence), ejaculatory ducts (bilateral obstruction), epididymis (diffuse or segmental hypoplasia), and seminal vesicles (incomplete

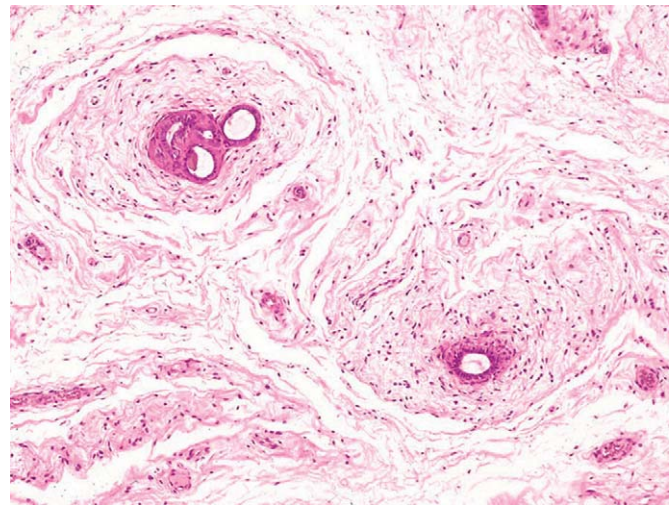


Fig. 12-145 Epididymis in cystic fibrosis. Sections of the ductus epididymidis show decreased lumen diameter with surrounding concentric rings of loose connective tissue.

development). Thus, it appears that most patients with cystic fibrosis have infertility due to obstruction.^{1329,1330}

Histologic studies in children, even at an early age, reveal that the vas deferens and ductus epididymidis are absent or reduced to small ductuli with reduced or absent lumina and thin, poorly muscular walls (Fig. 12-145). The testes are normal during childhood, but show hypospermatogenesis and spermatid malformations by adulthood. The spermogram is characteristic of obstructive azoospermia, with acid pH, decreased semen volume and fructose concentration, and increased citric acid and acid phosphatase.¹³³¹

The disease is a genetic disorder with autosomal recessive inheritance. The impaired gene (cystic fibrosis gene) is on chromosome 7 (7q31),¹³³² and encodes a protein termed cystic fibrosis transmembrane regulator (CFTR). Alterations in this protein cause cystic fibrosis. Although more than 800 mutations of this gene have been identified,¹³³³ the most frequent mutation in Caucasians is D-F508, responsible for 70% of cases. Congenital bilateral obstructive azoospermia secondary to bilateral absence of the vas deferens, even in the absence of other symptoms, is often a *forme fruste* of cystic fibrosis.¹³³⁴ Before initiating treatment for infertility, the possibility that the patient is a carrier of the cystic fibrosis gene should be evaluated.¹³³⁵

Malformation of the genital system plays the most important role in infertility in cystic fibrosis.¹³³⁶ The lesions begin in the 10th week of gestation, when the wolffian duct forms the sperm excretory ducts.¹³³⁷ Variable penetrance of the cystic fibrosis gene accounts for the diversity of malformations affecting different regions of the male genital system.

Liver

The liver has a primary role in metabolism, detoxification, and excretion of sex steroid hormones. Chronic hepatic failure damages the hypothalamo-hypophyseal-testicular axis, and subsequently all related endocrine glands. Hypogonadism is frequent in the final stages of severe chronic

liver diseases, including alcoholism, non-alcoholic liver disease, and hemochromatosis.

Hypogonadism, liver disease, and excessive alcohol consumption

The association of testicular atrophy with gynecomastia and hepatic cirrhosis is well known and is referred to as Silvestrini–Corda syndrome.^{1338,1339}

Alcohol has a direct toxic effect on Leydig cells. Acute alcoholic intoxication suppresses serum testosterone in voluntary non-alcoholic men and laboratory animals. Chronic alcohol ingestion, even in the absence of cirrhosis, causes hypogonadism, with symptoms of Leydig cell failure, including testicular atrophy, infertility, decreased libido, impotence, and reduced size of the prostate and seminal vesicles.¹³⁴⁰ Chronic alcoholic patients with cirrhosis also have symptoms of hyperestrogenism, including gynecomastia, female escutcheon, and female fat distribution pattern.

Most chronic alcoholic men, with or without cirrhosis, have significant testicular lesions. The seminiferous tubules have reduced diameters, thickened lamina propria, and decreased or absent germ cells. Leydig cells are reduced in number and contain abundant lipofuscin granules (Fig. 12-146). The epididymis becomes atrophic, mainly in the ductuli efferentes, owing to androgen deprivation. The epithelium of the rete testis becomes cuboidal or columnar due to estrogens. The spermiogram correlates with the variability of histologic findings, usually showing a marked reduction in the number and motility of spermatozoa and an increase in the percentage of morphologically abnormal spermatozoa.^{1341,1342} About 20% of patients initially have an increase in serum testosterone; with advanced disease, testosterone level decreases. The initial increase is due to an elevation in sex hormone-binding globulin concentration and reduced testosterone metabolism by the liver.¹³⁴³ Serum estrogen level also increases owing to increased conversion of testos-

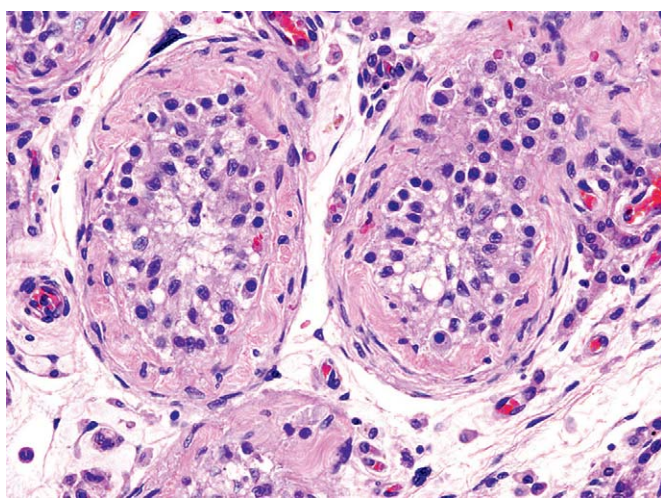


Fig. 12-146 Testis from a patient with alcoholic cirrhosis. The seminiferous tubules show decreased diameter, thickening of the tubular wall, and spermatogonia, isolated spermatocytes, and Sertoli cells exhibiting intense vacuolation of the adluminal compartment. The testicular interstitium shows marked Leydig cell atrophy and numerous macrophages.

terone into estrogen in peripheral adipose and muscular tissue.¹³⁴⁴

Non-alcoholic hepatic disease and infertility

Non-alcoholic liver disease impairs gonadal function according to the severity of the disease.¹³⁴⁵ Patients have decreased levels of total and biologically active free testosterone. Hormonal alterations are not as severe as in alcoholic patients, emphasizing the direct action of alcohol on Leydig cells. In α_1 -antitrypsin deficiency testicular function and fertility are conserved; only in advanced stages of the disease do minor biochemical alterations occur.¹³⁴⁶ In Alagille's syndrome (intrahepatic biliary duct hypoplasia), hypogonadism is associated with cholestasis, frequent vertebral, cardiac, and facial malformations, and mental retardation. Hypogonadism is manifest by small testes, delayed puberty, and, in adults, lack of germ cell development.

Hemochromatosis and infertility

Hereditary hemochromatosis is the most frequent genetic disease in the northern hemisphere and results from excessive iron absorption and accumulation in multiple tissue and organs, leading to cirrhosis, diabetes, hypogonadism, and arthralgia. Four types of hereditary hemochromatosis have been reported.¹³⁴⁷ Type 1, the most frequent, is caused by mutation in the HFE gene (C282Y), leading to increased intestinal absorption of iron, supersaturation of iron deposits, and damage in multiples organs. The type 1 hereditary hemochromatosis gene (HFE) is located on the short arm of chromosome 6,^{1348,1349} is present in 85–100% of hemochromatosis patients with northern European ancestry, and its protein product is mainly expressed in the epithelium of Lieberkühn crypts. This protein interacts with the transferrin receptor, reducing its affinity for iron-bound transferrin; therefore, HFE becomes a negative regulator of transferrin-bound iron uptake. Type 2 gene is a juvenile form that expresses before the age of 30 years in both sexes, and is associated with severe cardiomyopathy and hypogonadism.¹³⁵⁰ The type 2 hemochromatosis locus is on chromosome 1q21, but this gene has not yet been isolated.^{1351,1352} Type 3 is on chromosome 7q22, impairs the transferrin 2 receptor, and its consequences are similar to those of type 1 receptor defect. Type 4 is autosomal dominant, on 2q32, and affects the basolateral iron carrier ferroportin 1, resulting in iron deposition in macrophages. Types 1, 2, and 3 have recessive autosomal inheritance and show a similar distribution pattern of iron deposits. In these three types, alteration of gonadal function has also been reported.

Iron homeostasis depends on many genes that act in a coordinated manner, and their exact function is not well known. It is assumed that normal individuals absorb 1–2 mg/day of iron, whereas homozygous patients with hereditary hemochromatosis absorb up to 3–4 mg/day. Once iron deposits become saturated (cells of liver, pancreas, hypophysis, heart, adrenals, and gastric mucosa), the toxic effects of iron cause dysfunction of the liver (cirrhosis and cancer in 5–10% of patients), the pancreas (diabetes in 80% of patients), the heart (myocardiopathy), musculoskeletal system (arthritis), and hypophysis (hypogonadism) (Fig. 12-147).

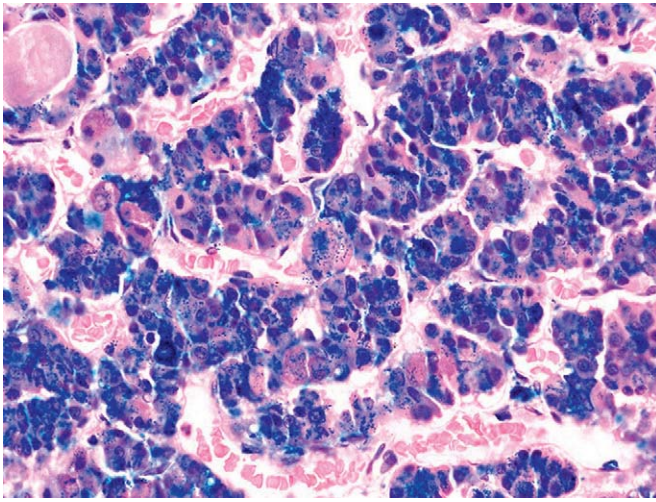


Fig. 12-147 Perl stains decorates the voluminous iron deposits in cells of the anterior pituitary in a patient with hemochromatosis.

Hypogonadism may be the first sign of disease when it starts in adult life.¹³⁵³ With age, hypogonadism becomes hypogonadotropic, with low serum levels of testosterone, LH, and FSH in more than 40% of patients,¹³⁵⁴ except if early treatment is initiated.¹³⁵⁵ The most frequent findings are testicular atrophy with diminished tubular diameter, tubular wall thickening, a progressive decrease in spermatogenesis, and increased lipofuscin granules in Leydig cells. The cause of these testicular disorders might be preferential deposition of iron in gonadotropic cells.¹³⁵⁶ Iron deposits are not observed in the testis. Hypogonadism decreases after aggressive therapy.¹³⁵⁷

Kidney

Polycystic renal disease

Polycystic renal disease in adults is a dominant autosomal disorder that appears with 1 in 1000 frequency in the general population. Patients with this disease comprise 10% of end-stage renal failure cases.¹³⁵⁸ Infertility is common, even before the beginning of renal insufficiency. Oligoteratozoospermia and necrospermia are frequent findings.^{1359,1360} Serum levels of FSH, LH, prolactin, testosterone, and estradiol remain normal for a long time before the onset of renal insufficiency. The causes of spermogram alterations have been related to partial obstruction of ejaculatory ducts (based on finding cystic dilations in seminal vesicles in 60% of patients) or seminal vesicle cyst.¹³⁶¹ The incidence of these two disorders in patients with polycystic renal disease is very high compared to andrological patients without this disease (5.2%).¹³⁶²

Chronic renal insufficiency

Chronic renal insufficiency is associated with disturbed endocrine function in the pituitary, thyroid, parathyroids, and testes. The associated sexual dysfunction consists of erectile impotence, diminution of libido and semen volume, oligozoospermia or azoospermia, and infertility. In children, skeletal development and puberty are delayed.¹³⁶³

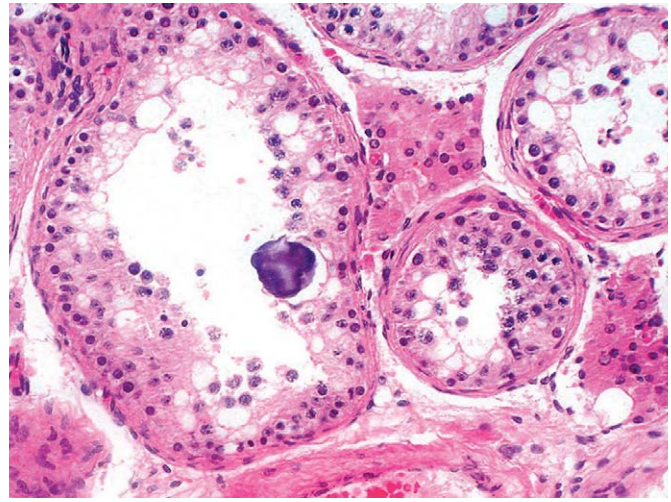


Fig. 12-148 Testis from a patient with chronic renal insufficiency. The seminiferous tubules show premature sloughing of primary spermatocytes. An intraepithelial microlith is present.

Hormonal studies reveal elevated levels of FSH, LH, and prolactin, but testosterone levels are low.¹³⁶⁴ Testicular biopsy shows seminiferous tubules with reduced diameters and reduced or absent germ cells (Fig. 12-148).^{1365,1366} The interstitium contains a normal number of Leydig cells and increased numbers of macrophages. Additionally, patients with chronic renal insufficiency due to glomerulonephritis have thickening of the tubular lamina propria and decreased number of Leydig cells. Patients with end-stage renal disease who undergo dialysis show calcifications in several organs and tissues, including the male genital system (epididymidis, tunica albuginea, and cavernous tissue) in 87% of cases, and, in isolated cases, calcification of the testicular parenchyma and microlithiasis.¹³⁶⁷ Elevated serum levels of phosphorus, increased calcium-phosphorus product, severe hyperparathyroidism secondary to other disorders, older age, and prolonged time on dialysis contribute to this disorder. Uremic calcification is a cell-mediated process in which elevated levels of TGF, vitamin K-dependent proteins such as osteocalcin and atherocalcin, and defects in calcium-regulatory proteins such as fetuin are implicated.¹³⁶⁸ When these patients are dialyzed, accumulations of urate and oxalate crystals are deposited in the rete testes and ductuli efferentes. These crystals are deposited beneath the epithelium and often sloughed into the lumen. Reactive changes in the rete testis, including cystic transformation, are frequent (see Disorders of the rete testis).¹³⁶⁹

The cause of gonadal dysfunction is unclear and probably involves several factors, including impaired testicular steroidogenesis,¹³⁷⁰ reduced clearance of pituitary hormones,¹³⁷¹ and secretory defects of the pituitary and hypothalamus.¹³⁷² Dialysis does not improve testicular function. The response to renal transplantation is not immediate and is related to the glomerular filtration rate. Patients with rates lower than 50 mL/min develop atrophy of the seminiferous tubular cells.¹³⁷⁰

Chronic inflammatory bowel disease

Hypogonadism is a frequent finding in men with celiac disease, and results in clinical symptoms in 5–10% of untreated patients. Celiac disease causes infertility in some cases. Spermograms show reduced motility and numerous morphologic anomalies in spermatozoa. Hormonal studies show elevated serum FSH levels in more than 25% of men with celiac disease. LH also is increased in more than 50% of these men. The response of FSH and LH to GnRH stimulation is excessive. The cause of this pituitary derangement is unknown. Sperm anomalies are not always corrected by a gluten-free diet. Studies in patients with ulcerative colitis and regional enteritis reveal a low sperm count, impaired motility, and ultrastructural alterations, including nuclear pleomorphism and chromatin malcondensation and decondensation. Zinc deficit may be responsible for these alterations in Crohn's disease.¹³⁷³ The alterations apparently are related to the extent of the intestinal lesions and the severity of symptoms.¹³⁷⁴ Patients with ulcerative colitis treated with salazopyrine,¹³⁷⁵ mesalazine¹³⁷⁶ or fasalazine¹³⁷⁷ present with significant impairment of spermatogenesis and subfertility. Spermogram parameters improve when treatment ceases.

Acquired immunodeficiency syndrome (AIDS)

More than 17% of HIV-infected men have hypogonadism,¹³⁷⁸ which can be observed even in those whose viral replication is under control and show normal numbers of CD4 lymphocytes. Patients frequently develop 'early andropause,' marked by dysregulation of the hypothalamopituitary-testicular axis.¹³⁷⁹

Hypogonadism is more frequent in HIV-infected men with wasting syndrome, and therefore these patients should undergo screening for hypogonadism and, if necessary, physiologic androgen replacement therapy.^{1380–1383}

The incidence of hypogonadism in males with AIDS is estimated to be 50%.^{1384,1385} According to autopsy studies this increases to 100% in the 3–24 months prior to death.¹³⁸⁶ Histological studies reveal that 28% have complete but quantitatively abnormal spermatogenesis, and the remainder have spermatocytic arrest or Sertoli cell-only pattern.

Chronic anemia

Patients with chronic anemia requiring multiple transfusions develop iron deposits in the pituitary and polyglandular insufficiency, with atrophy of the thyroid, adrenals, and testes (Fig. 12-149). The most frequent conditions are β -thalassemia and sickle cell anemia (see Fig. 12-119).

β -Thalassemia is an autosomal dominant disease with three types: thalassemia trait (heterozygous β -thalassemia), intermediate thalassemia, and major β -thalassemia. The cause is mutation in the β -globin gene resulting in ineffective erythropoiesis, hemolysis, and anemia. Nearly 20% of patients with major thalassemia have delayed puberty,^{1387–1389} and 69% have hypogonadotropic hypogonadism.¹³⁹⁰ Gonadal dysfunction persists in most patients after healing of the thalassemia.¹³⁹¹

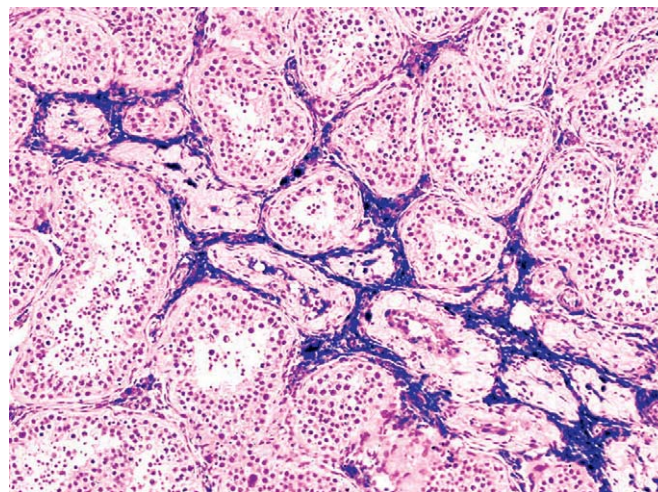


Fig. 12-149 Major thalassemia in a patient who underwent multiple blood transfusions. The testicular interstitium and atrophic tubules show Perl's stain-positive iron deposits.

Sickle cell anemia is an autosomal recessive disorder with a constellation of findings resulting from abnormal synthesis of hemoglobin, with over 90% of hemoglobin being type A. Most patients have hypogonadotropic hypogonadism.¹³⁹²

Obesity

The majority of people in developed countries are currently overweight, and the incidence of obesity seems to be increasing. Infertility is frequently associated with obesity. Very obese males have increased levels of serum estradiol and decreased levels of free testosterone and inhibin B.¹³⁹³ Testosterone reduction is not followed by a compensatory increase in gonadotropins, resulting in hypogonadotropic hypogonadism.^{1394,1395} Testicular abnormalities begin with the adluminal compartment and later involve the basal compartment; also, there are Leydig cell atrophy, cuboidal metaplasia of the rete testis, and epididymal atrophy.

Autoimmune polyglandular syndrome

There are three types of autoimmune polyglandular insufficiency syndrome. Type I is defined by the presence of at least two of three characteristic features: Addison's disease, hypoparathyroidism, and chronic mucocutaneous candidiasis. The AIRE gene (autoimmune regulator), responsible for type I disease, is on 21q22.3,^{1396,1397} and the disorder is recessive autosomal. Hypergonadotropic hypogonadism is frequent.¹³⁹⁸ Patients with type I syndrome have antibodies against many autoantigens, intracellular enzymes including the P450 side-chain cleavage enzyme, 17 α -hydroxylase^{1399,1400} and 21-hydroxylase, glutamic acid decarboxylase 65, aromatic L-amino acid decarboxylase, tyrosine phosphatase-like protein IA-2, tryptophan hydroxylase (TPH), tyrosine hydroxylase, and cytochrome P450 1A2.¹⁴⁰¹

Type II autoimmune polyglandular syndrome is characterized by the presence of diabetes mellitus, hyperthyroid-

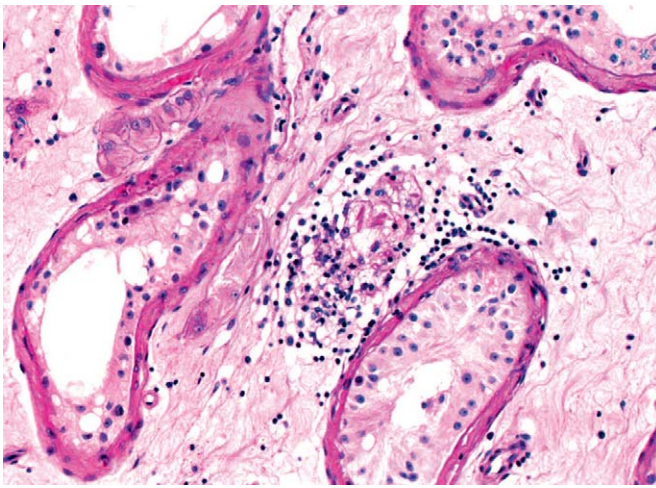


Fig. 12-150 Testis from a man with autoimmune polyglandular syndrome showing selective lymphoid infiltrates in a Leydig cell cluster. Reinke's crystalloid can be recognized. The seminiferous tubules contain Sertoli cells and isolated spermatogonia.

ism, Hashimoto's thyroiditis, Addison's disease, vitiligo, alopecia, pernicious anemia, and hypogonadism (listed in decreasing order of frequency). Type III syndrome includes thyroiditis, diabetes mellitus, pernicious anemia, and vitiligo or alopecia. About 14% of patients have hypogonadism owing to autoimmune destruction of the testis or pituitary gonadotropin-secreting cells (Fig. 12-150).^{1402,1403}

Lysosomal and peroxisomal diseases

There are at least four diseases caused by metabolic deposits in lysosomes or peroxisomes associated with testicular alterations, including Fabry's disease, adrenal leukodystrophy, Wolman's disease, and cystinosis.

Fabry's disease

Fabry's disease is an X-linked metabolic disorder characterized by intralysosomal deposits of globotriaosylceramide (Gb3) owing to α -galactosidase deficiency. Clinical symptoms begin with painful neuropathy and progressive renal, cardiovascular, and cerebrovascular dysfunction. All endocrine glands may accumulate Gb3 as a result of well-developed vasculature and low rate of cell proliferation.¹⁴⁰⁴ Testes and sperm excretory ducts are always damaged. Some alterations, including those of endothelial cells, smooth muscle cells, and fibroblasts, are non-specific; others, such as those of myofibroblasts, Leydig cells, and epididymal epithelium, are specific (Figs 12-151, 12-152). Spermatogenesis is deficient.¹⁴⁰⁵ Enzyme replacement therapy with recombinant human α -galactosidase eliminates existing glycosphingolipid deposits and blocks new ones, and is thus recommended for implementation as soon as possible after diagnosis.¹⁴⁰⁶⁻¹⁴⁰⁸

Adrenoleukodystrophy (adrenal testicular myeloneuropathy)

This disorder is caused by mutation in the adrenoleukodystrophy gene on Xq28.¹⁴⁰⁹ Mutation at this site produces three peroxisomal diseases: adrenoleukodystrophy, adrenomyeloneuropathy, and Addison's disease.

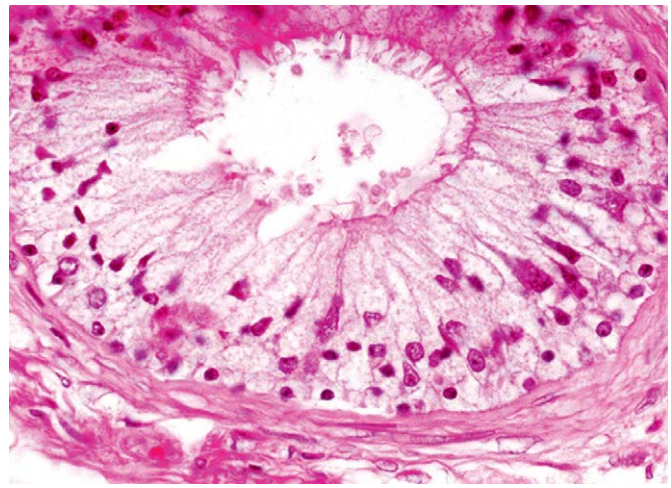


Fig. 12-151 Fabry's disease. Both basal and principal cells of the epididymis show pale and vacuolated cytoplasm, due to lipid deposits.



Fig. 12-152 Fabry's disease. The deposits observed in the ductus epididymidis epithelium consist of multiple, parallelly arranged laminae.

Adrenoleukodystrophy is characterized by progressive demyelination of the central nervous system, usually in children and young adults, often with adrenal insufficiency and testicular failure. Peroxisomal β -oxidation is deficient and, as a result, very long-chain fatty acids accumulate inside peroxisomes in many tissues, causing the signs and symptoms of the disease.^{1410,1411}

Adrenomyeloneuropathy begins at a later age (about 30 years) with progressive paraparesis, peripheral neuropathy, and adrenal cortical failure. Males usually have gonadal dysfunction with oligozoospermia or azoospermia and hypergonadotropic hypogonadism.¹⁴¹² Testicular atrophy develops slowly, the seminiferous epithelium disappear, and Leydig cells contain characteristic cytoplasmic lamellar inclusions, with similar inclusions in adrenal cortical cells and cerebral cells.¹⁴¹³

Wolman's disease

Wolman's disease is a rare inherited lysosomal disease characterized by a deficit in acid lipase/cholesterol ester hydrolase. The genetic mutation has been mapped to 10q23.2-q23.3.¹⁴¹⁴ Complete enzymatic deficiency (Wolman's disease) causes death in infancy as a result of the accumulation of cholesterol esters and triglycerides in numerous organs such as the liver, adrenal cortex, and intestines.¹⁴¹⁵ Partial deficiency is known as cholesterol ester storage disease, and the testis accumulates triglycerides and cholesterol in Leydig cells and, to a lesser degree, in interstitial macrophages. Delayed disruption of spermatogenesis by this storage disease probably accounts for the frequent lack of fertility problems in men with this disease.¹⁴¹⁶ Early treatment of children with Wolman's disease by transplantation of umbilical cord blood-derived stem cells may successfully restore acid lipase level in some.¹⁴¹⁷

Cystinosis

Cystinosis is an autosomal recessive metabolopathy characterized by alterations in cystine transport from the lysosomes to the cytosol that results in intralysosomal accumulation of cystine. There are several genes responsible, all on chromosome 17p13. Cystine storage occurs in all body tissues. Deposits in the renal parenchyma cause the main complication of cystinosis, namely renal insufficiency (nephropathic cystinosis). Patients also develop hypergonadotropic hypogonadism. Testicular involvement may be massive, with interstitial macrophages filled with cystine crystals that are visible by polarized light.¹⁴¹⁸

Niemann–Pick disease

Niemann–Pick disease consists of a heterogeneous group of inherited recessive autosomal diseases characterized by deposition of lipids in macrophages and other tissues. There are four reported types (A, B, C, D). The most common, type A, results from excessive storage of sphingomyelin owing to a mutation in the acid sphingomyelin gene that encodes a lysosomal hydrolase, located on 11p15.1-4 region.¹⁴¹⁹

Interstitial macrophages in the testes have wide eosinophilic, granular cytoplasm. Ultrastructural studies reveal a large number of lysosomes filled with laminate bodies.

Infertility secondary to physical and chemical agents

Physical and chemical agents may impair testicular function by direct action on the pituitary, the testis, or the sperm excretory ducts. In the pituitary, damage to gonadotropic cells may be caused by estrogen. In the testes, gonadotoxic agents may selectively impair a select cell type, but later, global dysfunction occurs. For example, there is direct toxicity to Sertoli cells by phthalates used as plasticizers, nitroaromatic compounds intermediate in the production of dyes and explosives, and γ -diketones used as solvents. Direct toxicity on spermatogenesis is seen with ionizing radiation. Many drugs that impair epididymal fluid or spermatozoon transport damage sperm excretory ducts, with subsequent loss of fertility.¹⁴²⁰

Occupational exposure

The relationship between infertility or subfertility and certain professions or exposures to environmental agents is well known.¹⁴²¹ Adverse effects of the following agents on spermatogenesis has been demonstrated: organic solvents such as chlorinated solvents, aromatic solvents and varnishes, degreasers, thinners, and adhesives; this is also the case with carbon disulfide exposure; pesticides such as DDT, linuron, and polychlorinated biphenyls;¹⁴²² heavy metals such as lead, cadmium, mercury, and copper; industrial wastes such as dioxins and ethylene dibromide; phthalates and polyvinyl chloride; oral contraceptives; exposure to radiation or high temperature; and recreational drugs and doping. There is also a long list of potentially harmful agents that disrupt testicular function.¹⁴²³

Carbon disulfide

Carbon disulfide is used as a solvent in the production of rayon. Continuous exposure is toxic to the nervous system, and causes a decrease in spermatogenesis and libido and an increase in FSH and LH serum levels.^{1424,1425}

Dibromochloropropane

Dibromochloropropane is used as a soil fumigant to control nematodes. Lengthy exposure causes oligozoospermia, azoospermia, increased FSH and LH levels, and Y-chromosome non-dysjunction.¹⁴²⁶

Lead

Of the two natural forms of lead, organic and inorganic, the inorganic form is more dangerous. Exposure to inorganic lead by workers in smelting, battery, and stained-glass plants causes direct spermatogenic damage.¹⁴²⁷ Patients have asthenospermia, teratozoospermia, and oligozoospermia.^{1428,1429}

Oral contraceptive manufacture

Workers in pharmaceutical plants using synthetic estrogens and progestins develop hyperestrogenism with gynecomastia, decreased libido, and impotence.¹⁴³⁰

Neonatal exposure of males to diethylstilbestrol may induce cryptorchidism, testicular hypoplasia, epididymal cyst, and severe anomalies in semen production.¹⁴³¹

Endocrine-disrupting compounds

There is increasing evidence to suggest that estrogen-like effects are produced by a variety of naturally occurring estrogens (so-called phytoestrogens) and numerous synthetic compounds such as phthalates,¹⁴³² pesticides,¹⁴³³ and polychlorinated biphenyls.¹⁴³⁴ The principal methods of contact with potential endocrine-disrupting compounds is dietary ingestion of milk, fish, meat, fruits and vegetables, or environmental exposure.¹⁴³⁵ The increasing incidence of cryptorchidism, hypospadias, testicular cancer, and poor semen quality may be related to the negative influence of environmental factors on the testis during fetal life. The term 'testicular dysgenesis syndrome' has been proposed to designate this constellation of putative syndromes.¹⁴³⁶

Estrogen exposure in utero may disrupt development of the testes and the entire male reproductive tract. Estrogen may hinder FSH secretion by the fetal pituitary, and also interfere with subsequent Sertoli cell proliferation, and

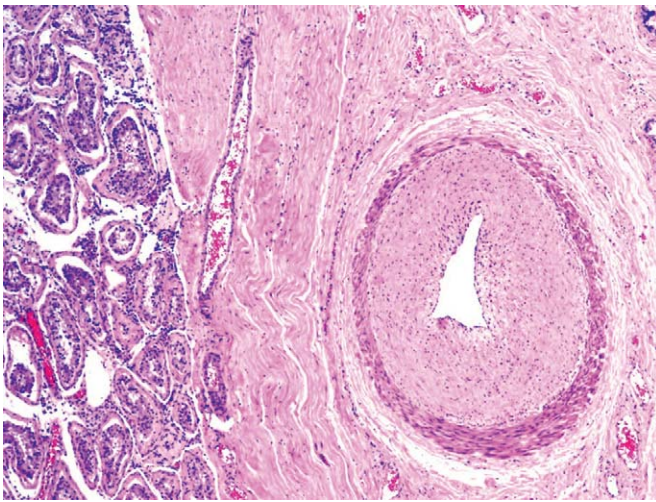


Fig. 12-153 Testis from a 40-year-old patient who consumed cocaine from the age of 16 years. In the tunica albuginea, a branch of the testicular artery shows intense fibrosis in the tunica intima. The seminiferous tubules have marked germ cell atrophy.

hence the secretion of AMH required for the regression of müllerian ducts. Persistence of müllerian derivatives is associated with lack of testicular descent. Changes in AMH secretion may also account for altered germ cell proliferation during fetal life. Exposure to high concentrations of estrogen might compromise testosterone production as well as masculinization of external genitalia (hypospadias) and inguinal descent of the testis (cryptorchidism). Abnormal development of Sertoli cells and low germ cell numbers could cause diminished spermatozoon production and infertility.¹⁴³⁷

Recreational drugs and doping

Marijuana decreases sperm density and motility and increases the number of morphologically abnormal spermatozoa.¹⁴³⁸ Cocaine induces apoptosis in the rat testis (Fig. 12-153).¹⁴³⁹ About 20% of injection drug users have low serum testosterone levels. Consumption of more than 80 g alcohol per day adversely affects spermatogenesis in two-thirds of patients.¹⁴⁴⁰ Women smoking more than 20 cigarettes per day have fertility problems, neonatal and perinatal mortality, miscarriage, and congenital malformations.¹⁴⁴¹ Abuse of anabolic steroids by athletes causes hypogonadotropic hypogonadism and transient azoospermia.¹⁴⁴²

Radiation

Ionizing radiation causes alterations in spermatogenesis and hormonal regulation of the testes. Some patients recover fertility a few years after exposure.¹⁴⁴³ The effects of non-ionizing radiation are less severe; however, reduced libido and reduced numbers of spermatozoa have been reported in men exposed to microwaves.¹⁴⁴⁴

Heat

Normal intratesticular temperature is 31–33°C, about 4–6°C lower than core body temperature. Conditions causing higher testicular temperature, such as varicocele and cryptorchidism, also cause testicular damage, with decreased numbers of spermatozoa and an elevated percentage of sper-

matozoa with abnormal forms and low motility.^{1445,1446} Primary spermatocytes at the end of the pachytene stage are most sensitive to heat. The mechanism by which heat produces testicular lesions is unknown; hyperthermia affects the activity of enzymes such as ornithine decarboxylase¹⁴⁴⁷ and carnitine acetyl transferase,¹⁴⁴⁸ both necessary for metabolism and proliferation of the seminiferous tubular cells.¹⁴⁴⁹ The synthesis of DNA and RNA by germ cells also depends on temperature. DNA synthesis by spermatogonia and preleptotene primary spermatocytes is higher at 31°C than at 37°C. RNA and protein synthesis are normal at temperatures between 28°C and 37°C, but decrease markedly at 40°C.¹⁴⁵⁰

Testicular trauma

Testicular trauma is especially frequent among athletes. Trauma results in a wide variety of lesions, including contusion with or without hematocele, rupture, dislocation, and eventually spermatogenetic alteration that may lead to infertility. Dislocation involves the displacement of one or both testes to a non-scrotal location^{1451,1452} such as the inguinal canal, abdominal cavity, acetabular area, or distant locations such as the perineum, subcutaneous tissues, or superficial to the outer oblique fascia.^{1453,1454} Spermatogenetic recovery by orchidopexy has been successfully performed up to 13 years after bilateral traumatic dislocation.¹⁴⁵⁵

Cancer therapy

Sexual dysfunction is found in 25–50% of patients who are treated for cancer.¹⁴⁵⁶ Testicular cancer, Hodgkin's disease, and leukemia are the most frequent malignancies during the reproductive years. Therefore, preservation of fertility requires careful selection of less gonadotoxic therapeutic regimens; if paternity is planned, cryopreservation of semen before treatment may be considered. The most destructive treatments for gonadal function are radiation therapy and alkylating agents.¹⁴⁵⁷

Radiation therapy

The testicular parenchyma is one of the most radiosensitive tissues of the body, and the germ cells are the most radiosensitive cells of the testis. Experimental irradiation of volunteers with a single dose revealed that late spermatogonia (Ap and B) are more radiosensitive than early (Ad) spermatogonia. Ap and B spermatogonia may be destroyed with doses as low as 0.3 Gy (1 Gy = 100 rad), whereas Ad spermatogonia tolerate doses higher than 4 Gy. Type A spermatogonia, spermatids, and spermatozoa are respectively 100, 200, and 10 000 times less radiosensitive than B spermatogonia. Doses higher than 6 Gy produce a Sertoli cell-only pattern. Leydig cells tolerate up to 8 Gy and Sertoli cells up to 60 Gy, although Sertoli cells show ultrastructural alterations and increased phagocytosis of germ cell remnants after low doses of radiation.

Even with optimal protection, the contralateral testis absorbs from 0.2 to 1.4 Gy in adjuvant therapy for rectal cancer¹⁴⁵⁸ or when the opposite testis is irradiated,¹⁴⁵⁹ a dose sufficient to cause temporary azoospermia. Likewise, irradiation of iliac or inguinal lymph nodes for Hodgkin's disease

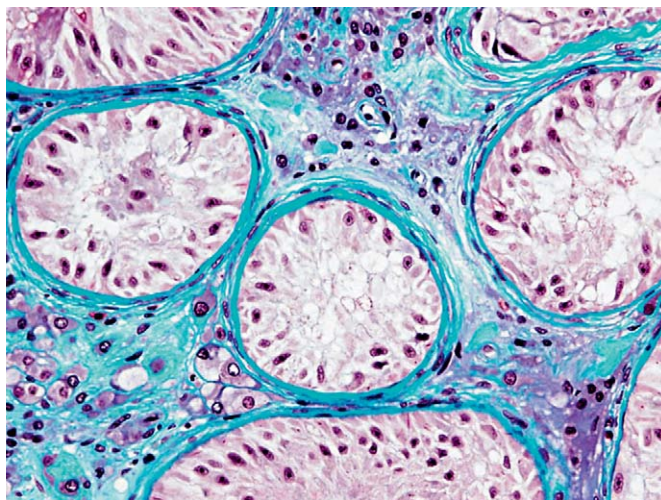


Fig. 12-154 Testis from a 26-year-old patient who, at the age of 9 years, underwent surgery followed by radiotherapy for paratesticular rhabdomyosarcoma. The testicular biopsy shows post-irradiation lesions, including germ cell aplasia and peritubular and interstitial fibrosis.

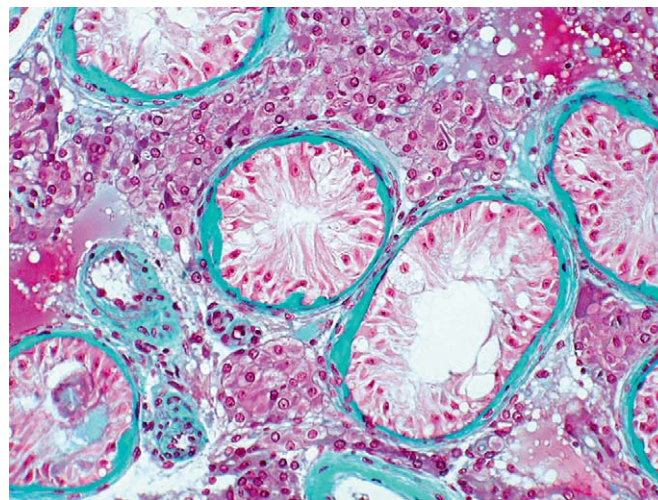


Fig. 12-155 Testis from a patient with Hodgkin's disease after chemotherapy. The seminiferous tubules are small and contain only vacuolated Sertoli cells. The testicular interstitium has pseudohyperplasia of Leydig cells.

or other forms of lymphoma exposes the testes to about 5 Gy.¹⁴⁶⁰ Restoration of testicular function is time-dependent,¹⁴⁶¹ requiring at least 2 years.¹⁴⁶² Fertility in thyroid cancer patients who received radioiodine-131 (¹³¹I) therapy decreases briefly, but infertility is not permanent.¹⁴⁶³ Electromagnetic radiation from cell phones impairs spermatozoon motility according to one study.¹⁴⁶⁴

Prepubertal testes also are sensitive to radiation therapy. Patients treated for Wilms' tumor may have delayed puberty and, at adulthood, oligospermia or azospermia with elevated levels of FSH; this finding suggests that Leydig cells are also damaged. A special case is that of children with acute lymphoblastic leukemia involving the testis. Radiotherapy with doses of 20–25 Gy, either alone or with chemotherapy, causes irreversible damage to the seminiferous tubules and Leydig cells. These patients develop azospermia and hypogonadotropic hypogonadism with low serum testosterone (Fig. 12-154).

Chemotherapy

Widespread use of cytotoxic chemotherapy has created a number of adverse side effects, including gonadotoxicity. Combination chemotherapy makes it difficult to ascertain which specific agent is responsible for azospermia and Leydig cell dysfunction. Comparative studies of chemotherapy for acute lymphoblastic leukemia,¹⁴⁶⁵ extragonadal solid tumors,¹⁴⁶⁶ Hodgkin's disease,¹⁴⁶⁷ Ewing's sarcoma, and other soft tissue sarcomas¹⁴⁶⁸ in children and pubertal boys have shown that alkylating agents cause the most severe testicular damage. Alkylating agents destroy the seminiferous tubular cells and induce tubular atrophy, shrinking the testis and increasing FSH serum concentration.¹⁴⁶⁹ These agents also impair Leydig cell function, causing low testosterone, normal or elevated serum levels of LH, and an exaggerated response of LH to GnRH administration.¹⁴⁷⁰ Testicular damage may be increased by combination with other agents (Fig. 12-155).

Cyclophosphamide appears to be responsible for the greatest number of permanent or temporary cases of azospermia after chemotherapy. This agent acts directly on the spermatogenic stem cells,¹⁴⁶⁸ and recovery depends on the number of surviving cells. In children, cyclophosphamide reduces seminiferous tubule diameter and germ cell numbers; in the residual spermatogonia nuclei are enlarged. Puberty may progress, even during treatment, and the adult testis may show a Sertoli cell-only pattern.¹⁴⁶⁵ In adults, cyclophosphamide treatment may cause irreversible testicular damage. Administered alone, a dose of 20 000 mg/m² produces permanent azospermia in 50% of men. If cyclophosphamide is administered with doxorubicin, vincristine, dacarbazine, or dactinomycin (drugs that alone do not cause azospermia), doses of 7500 mg/m² cause azospermia in 50% of patients. Fludarabine, used for the treatment of chronic lymphocytic leukemia, produces testicular damage with diminution of ejaculate volume, oligozoospermia, increase in serum levels of FSH and LH, and decreased testosterone level. DNA in spermatozoa is markedly abnormal, an effect that persists for several months.¹⁴⁷¹

Procarbazine, used to treat Hodgkin's disease, causes permanent azospermia in 30% of patients, even when not combined with alkylating agents.¹⁴⁷² Patients treated with a combination of cyclophosphamide and procarbazine in the COPP protocol (cyclophosphamide, vincristine, procarbazine, and prednisone) do not recover spermatogenesis even if the cyclophosphamide dose does not exceed 4800 mg/m².

Chemotherapy without both alkylating agents and procarbazine, such as the ABVD (doxorubicin, bleomycin, vinblastine and dacarbazine) or VBM (vinblastine, bleomycin and methotrexate) regimens, produces reversible azospermia in 36% of patients. The alternating use of MOPP (mechlorethamine, vincristine, procarbazine and prednisone) and

ABVD treatments causes testicular dysfunction in 87% of patients, but spermatogenesis recovers in 40%.¹⁴⁷³

Patients with germ cell cancer who received chemotherapy with BEP regimens (cisplatin, etoposide, and bleomycin) become azoospermic 7–8 weeks after starting treatment. When the total doses reaches 600 mg/m², infertility is irreversible; at lower dosages, fertility might be recovered over a period of about 2 (50% of patients) to 5 (80%) years,¹⁴⁷⁴ although a high percentage of spermatozoa with DNA abnormalities persists.¹⁴⁷⁵

An important consideration in patients with testicular cancer or Hodgkin's disease is the existence of testicular dysfunction before treatment. In some series¹⁴⁷⁶ dysfunction is present at diagnosis in more than 50% of patients; its cause is unknown. Proposed mechanisms include primary germ cell deficiency, release of toxic substances by tumor cells, and alteration in the hypothalamo–hypophyseal–testicular axis.

Surgery

Sexual function is often lost in patients who undergo bilateral retroperitoneal lymph node dissection for non-seminomatous testicular cancer. Up to 90% lose antegrade ejaculation, although libido, erection, and orgasm are normal. Loss of antegrade ejaculation results from the removal of or injury to sympathetic ganglia and the hypogastric nervous plexus during surgery. Unilateral surgery, especially if the left side is not operated on, reduces this complication.^{1477,1478} Hypospermatogenesis sometimes occurs after surgery for rectal cancer, perhaps due to vascular compromise.

Infertility in patients with spinal cord injury

Spinal cord injury is a frequent finding, with more than 10 000 cases annually in the US, mostly in young adults.¹⁴⁷⁹ Fertility is impaired in 90% of males with spinal cord injury. The major sexual dysfunctions in these patients are the lack of erection and ejaculation and poor semen quality.^{1480–1485} Failure of ejaculation occurs in 95% of patients. Semen may be obtained by means of vibratory stimulation of the penis or electroejaculation in more than 90%, but its quality is low, with increased numbers of dead spermatozoa, markedly low motility, and reduced fertilization rate.^{1486–1488} Possible explanations include genitourinary tract infection, endocrine anomaly, and impaired spermatogenesis. Recurrent infection occurs in 60–70% of patients. Compared to controls, a significant increase in the numbers of neutrophils and macrophages occurs, with a marked increase in the production of reactive oxygen species.^{1489,1490} This finding and the presence of elevated cytokine levels¹⁴⁹¹ are assumed to be involved in pathogenesis. Endocrine anomalies are transient, and hormonal levels return to normal after a few months. More than 50% of patients have abnormalities of the adluminal compartment of the seminiferous tubules, with variable degrees of immature germ cell sloughing;¹⁴⁸² in 50% of patients the number of mature spermatids per cross-sectioned tubule is less than 10 (normal >21).

Possible etiologies include an increase in testicular temperature due to vascular dilation, or an alteration in scrotal

thermoregulation secondary to impaired sympathetic innervation from prolonged wheelchair restraint; alteration in sperm transport secondary to nerve injury, resulting in sperm stagnation in seminal vesicles, a hostile environment that normally is devoid of spermatozoa;¹⁴⁹³ and abnormal composition of seminal fluid, causing deterioration of spermatozoa that in the epididymis and ductus deferens had good motility.¹⁴⁹⁴

More than 25% of patients with spinal cord injury have brown-tinged semen in some ejaculations.¹⁴⁹⁵ Although the cause is unknown, it might be related to seminal vesicle dysfunction.

When spermatozoa cannot be obtained by electroejaculation or vibratory stimulation, vasal aspiration or testicular biopsy are recommended. Most patients have at least a few mature spermatids in some seminiferous tubules; therefore, testicular sperm extraction followed by intracytoplasmic sperm injection is a reasonable consideration in azoospermic patients.¹⁴⁹²

Inflammation and infection

Infectious agents may reach the testis and epididymis through blood vessels, lymphatics, sperm excretory ducts, or directly from a superficial wound. Infection transmitted through the blood mainly affects the testis and causes orchitis, whereas infection ascending through the sperm excretory ducts usually causes epididymitis. Acute inflammation is accompanied by enlargement of the testis or epididymis. The tunica albuginea is covered by a fibrinous exudate, and the testicular parenchyma is yellow or brown. Bacterial infection may cause abscess. In some cases the infection begins to heal, with the deposition of granulation tissue and fibrosis; in others, the infection may persist as an active process for a long time, resulting in chronic orchidoepididymitis.

Orchitis

Viral orchitis

The most frequent causes of viral orchidoepididymitis are mumps virus and Coxsackie B virus. Other viral infections that occasionally cause acute orchitis include influenza, infectious mononucleosis, echovirus, lymphocytic choriomeningitis, adenovirus, coronavirus, bat salivary gland virus, smallpox, varicella, vaccinia, rubella, dengue, and phlebotomous fever. Subclinical orchitis probably occurs during other viral infections (Fig. 12-156).

Before vaccination was commonly used, mumps orchidoepididymitis complicated 14–35% of adult mumps cases and was bilateral in 20–25% of cases. Nevertheless, mini-epidemics still occasionally occur.^{1496,1497} As expected, the incidence remains high in countries where vaccination is not obligatory.¹⁴⁹⁸ In about 85% of cases of mumps orchitis the epididymis is also involved, but epididymal involvement alone is rare.¹⁴⁹⁹ Clinical symptoms of orchitis usually appear 4–6 days after symptoms of parotiditis, but orchitis may also appear without parotid involvement.¹⁵⁰⁰ Testicular involvement is multifocal, and consists of acute inflammation of

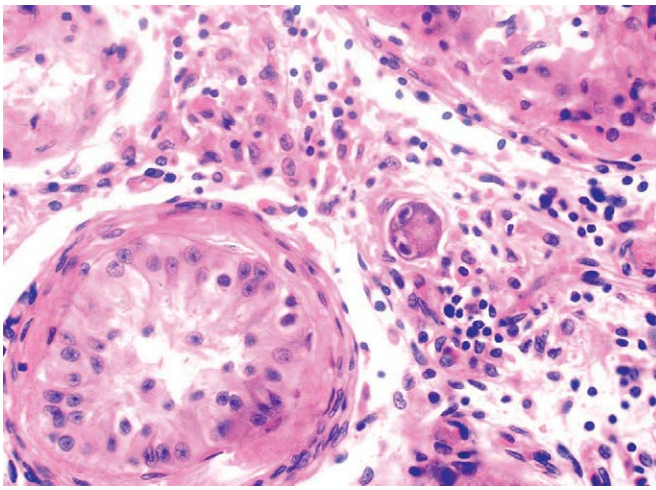


Fig. 12-156 Orchitis caused by cytomegalovirus in a patient with HIV. The inflammatory infiltrate of the testicular interstitium has two characteristic intranuclear inclusions.

the interstitium and seminiferous tubules. The tubular lining is destroyed, and eventually only hyalinized tubules and clusters of Leydig cells remain.¹⁵⁰¹ With time, the testes shrink and become soft. If the infection is bilateral the patient is usually infertile, with severe oligozoospermia or azoospermia, although biopsy may reveal the presence of mature spermatids in some tubules, allowing sperm extraction for paternity.¹⁵⁰² If only one testis was affected, the sperm concentration may be normal or slightly decreased and fertility is maintained. Occasionally the testicular damage is so severe that testicular endocrine function is impaired, causing hypergonadotropic hypogonadism, with low testosterone levels and regression of secondary sex characteristics. Mumps orchidoepididymitis is infrequent in childhood.

Bacterial orchitis

Most bacterial orchitis is associated with bacterial epididymitis. Orchitis secondary to suppurative epididymitis caused by *Escherichia coli* is most common.¹⁵⁰³ On light microscopy, the tubules are effaced by intense acute inflammation. Chronic orchitis with microabscesses is caused by *E. coli*, streptococci, staphylococci, pneumococci, *Salmonella enteritidis*,¹⁵⁰⁴ and *Actinomyces israeli*.^{1505,1506} In some cases of chronic bacterial orchitis, the testis contains an inflammatory infiltrate consisting of numerous histiocytes with foamy cytoplasm (xanthogranulomatous orchitis) (Fig. 12-157),¹⁵⁰⁷ similar to that of idiopathic granulomatous orchitis but lacking intratubular giant cells. Rarely, as in Whipple's disease, large numbers of bacilli are present in histiocytes in the interstitium, vascular walls, and seminiferous tubules.

The most frequent complications of pyogenic bacterial orchidoepididymitis are scrotal pyocele and chronic draining scrotal sinus. Small fragments of testicular parenchyma may be eliminated through the scrotal skin, known clinically as fungus testis. Another complication is testicular infarct, resulting from compression or thrombosis of the veins of

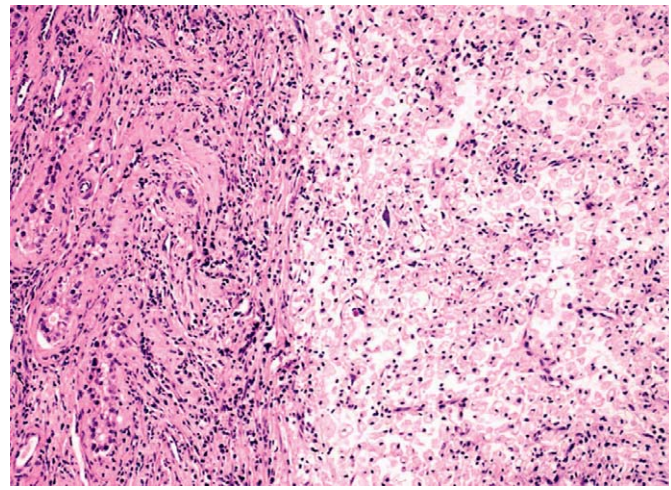


Fig. 12-157 Xanthogranulomatous orchitis showing a dense infiltrate of macrophages with vacuolated cytoplasm surrounded by atrophic seminiferous tubules.

the spermatic cord, in the scrotal neck, or the superficial inguinal ring.

Granulomatous orchidoepididymitis

Most cases of chronic orchidoepididymitis are associated with granulomas in the testis. Specific causes may require special stains, cultures, or serologic tests, and include tuberculosis, syphilis, leprosy, brucellosis, mycoses, and parasitic diseases. In sarcoidosis and idiopathic granulomatous orchitis, the agent is unknown.

Tuberculosis

The incidence of tuberculous orchidoepididymitis declined after the development of effective antibiotics, but it has recently undergone a resurgence among people who have emigrated from countries with a high incidence of the disease and the increasing population of immunologically compromised patients.

Most cases of tuberculous orchidoepididymitis are associated with involvement elsewhere in the genitourinary system.¹⁵⁰⁸ Tuberculous epididymitis is usually the result of ascent from tuberculous prostatitis, which in turn is often secondary to renal or pulmonary tuberculosis. The pattern of spread is different in children: more than half have advanced pulmonary tuberculosis, and the testis is infected through the blood.¹⁵⁰⁹ More than 50% of patients with renal tuberculosis develop tuberculous epididymitis, and orchitis occurs in approximately 3% of patients with genital tuberculosis, usually secondary to epididymal tuberculosis. It has been suggested that some cases of tuberculous orchidoepididymitis are sexually transmitted.¹⁵¹⁰ Tuberculous orchidoepididymitis occurs mainly in adults: 72% of patients are older than 35 years, and 18% are over 65 years. The signs and symptoms may be mild, consisting only of testicular enlargement and scrotal pain. In such cases, fever is infrequent and constitutional symptoms may be absent.¹⁵¹¹

Histologically, there are typical caseating and non-caseating granulomas that destroy the seminiferous tubules

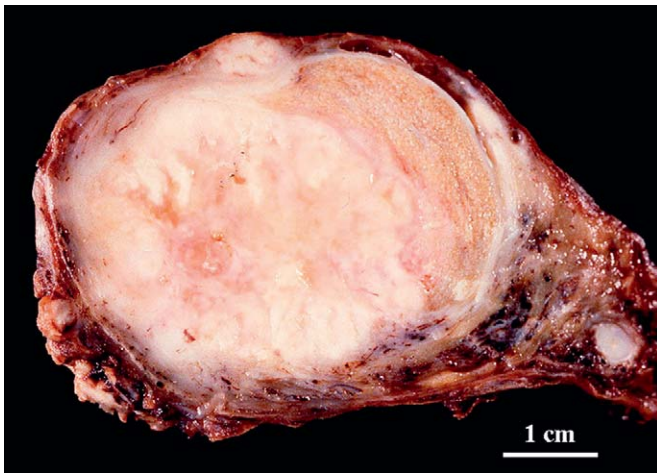


Fig. 12-158 Tuberculous orchitis in a 38-year-old patient with a white-gray nodule which has a pseudotumoral pattern and caused testicular enlargement.

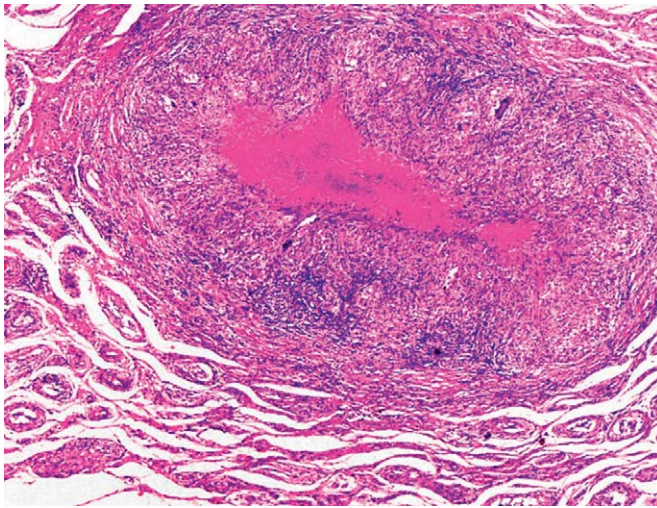


Fig. 12-159 Tuberculous orchitis showing central necrosis surrounded by numerous granulomas, some of which contain giant cells in their centers.

and interstitium (Figs 12-158, 12-159). In immunosuppressed patients, the granulomas consist of epithelioid histiocytes and a few lymphocytes with rare giant cells. Acid-fast bacilli tend to be more numerous in immunosuppressed patients. Similar lesions may be observed in orchidopididymitis caused by bacillus Calmette–Guérin, which is usually used for intravesical instillation in patients with vesicular urothelial carcinoma.¹⁵¹²

Syphilis

Syphilitic orchitis may be congenital or acquired. In congenital orchitis, both testes are enlarged at birth. The histological findings are similar to those of the interstitial orchitis of acquired syphilis. If diagnosis is delayed until puberty, the testis often shows retraction and fibrosis. In adults, acquired orchitis is a complication of the tertiary stage of syphilis and

has two characteristic histologic patterns: interstitial inflammation and gumma.

Early in the disease, patients with interstitial orchitis have painless enlargement. Grossly, the parenchyma is gray with translucent areas. Histologically, plasma cells are abundant. The inflammation begins in the mediastinum testis and testicular septa, later extending through the parenchyma as the seminiferous tubules lose their cellular lining and undergo sclerosis. Initially, the arteries show an obliterans type of endarteritis. Small gummas may be observed. Eventually, the inflammation subsides and is replaced by fibrosis. The epididymis is usually not affected.

Gummatous orchitis is characterized by the presence of one or several well-delineated grossly gray-yellow zones of necrosis.¹⁵¹³ Histologically, ghostly silhouettes of seminiferous tubules are visible within the gumma, surrounded by inflammation consisting of lymphocytes, plasma cells, and scattered giant cells. In most cases spirochetes may be demonstrated histochemically with Warthin–Starry silver stain, but the most specific diagnostic technique is genetic testing.

Leprosy

The testis may be infected in patients with lepromatous or borderline leprosy. Frequent involvement of the testis in lepromatous leprosy results from the low intrascrotal temperature that promotes growth of the bacilli. Orchitis is usually bilateral, although the degree of involvement may differ between the testes. Occasionally, testicular involvement may be the sole indication of the infection, and the diagnosis may be made by testicular biopsy.¹⁵¹⁴

The histologic findings in the testis vary with the duration of the infection. Initially, there is perivascular lymphocytic inflammation and interstitial macrophages that contain numerous acid-fast bacilli. Later, the seminiferous tubules undergo atrophy, the Leydig cells cluster, and blood vessels show endarteritis obliterans. Finally, the testis is replaced by fibrous tissue with a few lymphocytes and macrophages containing acid-fast bacilli. Most patients with lepromatous leprosy are infertile, even if the orchitis was clinically mild.^{1515,1516}

Brucellosis

Brucellosis is common in some parts of the world, including the Middle East.^{1517,1518} Orchitis occurs in some patients and may be the first sign of disease. Brucellosis should be suspected when testicular enlargement occurs in patients with undulating fever, malaise, sweats, weight loss, and headache.¹⁵¹⁹ Occasionally this may mimic testicular tumor. Histologically, there is a dense lymphohistiocytic inflammation with occasional non-caseating granulomas in the interstitium. The seminiferous tubules are infiltrated by inflammatory cells and undergo atrophy. Diagnosis is made by clinical and laboratory findings, including blood culture, the Bengal rose test, and high brucella agglutination titers,^{1520,1521} or by real-time polymerase chain reaction assay of urine.¹⁵²²

Sarcoidosis

Sarcoidosis is a systemic granulomatous disease of unknown etiology that preferentially affects young black adults. The

genitourinary tract is involved in only 0.5% of clinical cases and 5% of autopsy cases. Fewer than 30 cases of primary epididymal involvement have been reported, and about 12 of these also involved the testis.^{1523,1524} Isolated testicular involvement is exceptional.^{1523,1525,1526} Testicular sarcoidosis is usually unilateral and nodular.⁹⁴⁷ It is often asymptomatic and found at autopsy.¹⁵²⁷ The testis contains non-caseating granulomas similar to sarcoid granulomas at other locations. Before diagnosing testicular sarcoidosis, other granulomatous lesions should be excluded, including tuberculosis, sperm granuloma, granulomatous orchitis, and seminoma. Seminoma often has an intense sarcoid-like reaction, and examination of multiple histologic sections may be necessary to find diagnostic foci of seminoma. An association of mediastinal sarcoidosis and testicular cancer has been reported.¹⁵²⁸ Genital involvement of sarcoidosis may be the cause of intermittent azoospermia that benefits from corticoid therapy.¹⁵²⁹

Malakoplakia

Malakoplakia is a chronic inflammatory disease that was initially described in the bladder¹⁵³⁰ and subsequently in many other organs. The testes (alone or together with the epididymis) are involved in 12% of cases involving the urogenital system.^{1531,1532} Grossly, the testes are enlarged and have a brown-yellow parenchymous discoloration,¹⁵³³ often with abscesses. Malakoplakia causes tubular destruction that is associated with a dense infiltrate of macrophages with granular eosinophilic cytoplasm that often contains Michaelis–Gutmann bodies (Fig. 12-160).^{1534,1535}

The differential diagnosis includes idiopathic granulomatous orchitis and Leydig cell tumor. Inflammation in idiopathic granulomatous orchitis includes intratubular multinucleate giant cells; in malakoplakia it is difficult to identify the tubular outlines, and giant cells are usually absent. Leydig cell tumor is not usually associated with

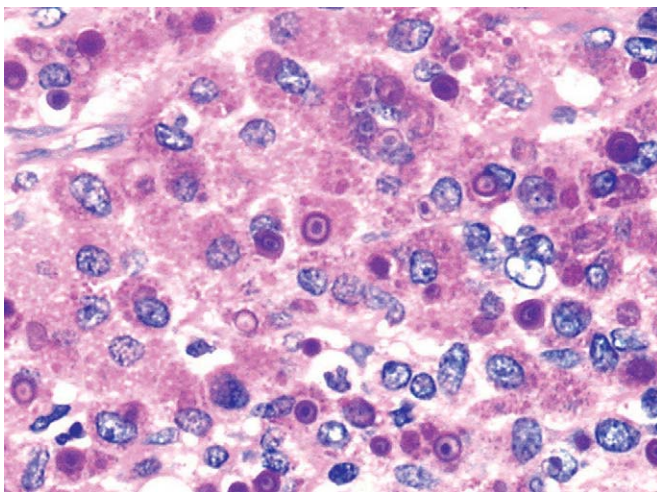


Fig. 12-160 Malakoplakia of the testis showing macrophages with granular and eosinophilic cytoplasm that contains several Michaelis–Gutmann bodies.

inflammation, but may contain mononucleated or binucleated cells with abundant eosinophilic cytoplasm. Reinke's crystalloids are identified in up to 40% of cases of Leydig cell tumor but absent in malakoplakia, and Michaelis–Gutmann bodies are absent.

Orchidoepididymitis caused by fungi and parasites

Fungal orchitis is rare; most cases are associated with blastomycosis, coccidiomycosis, histoplasmosis, and cryptococcosis.¹⁵³⁶ The genital tract may be involved in widespread blastomycosis. In decreasing order, the organs most frequently affected are the prostate, epididymis, testis, and seminal vesicles. Grossly, there often are small abscesses that may have caseous centers. Fungi measuring 8–15 μm in diameter with double refringent contours are present in the giant cells in granulomas and stain positively with periodic acid–Schiff and methenamine silver stains.

Coccidioidomycosis is endemic in California, the southwestern United States, and Mexico, and may present as epididymal disease after remission of systemic symptoms.¹⁵³⁷ The granulomas are similar to those of tuberculosis and contain 30–60 μm sporangia with endospores that stain with periodic acid–Schiff. Dissemination of histoplasmosis and cryptococcosis frequently occurs after steroid therapy and may give rise to granulomatous orchitis with extensive necrosis.¹⁵³⁸ *Histoplasma capsulatum* measures 1–5 μm in diameter and may be demonstrated with silver stain. *Cryptococcus* is identified by its thick wall that stains with mucicarmine.

Most parasites that reach the genital tract, such as *Phyllaria* and *Schistosoma*, are in the spermatic cord, and testicular lesions are secondary to vascular injury.¹⁵³⁹ Testicular infection has also been reported in patients with visceral leishmaniasis, congenital and acquired toxoplasmosis (Fig. 12-161),¹⁵⁴⁰ *Echinococcus* infection,¹⁵⁴¹ and orchitis due to *Trichomonas vaginalis*.

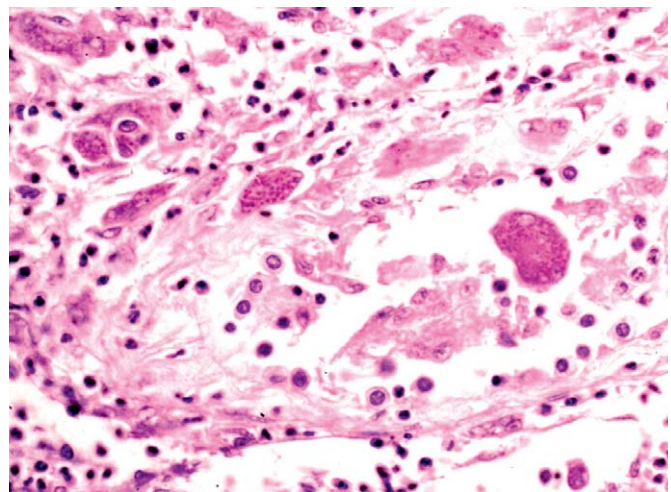


Fig. 12-161 Orchitis caused by toxoplasmosis. The giant cells in the testicular interstitium and those in the seminiferous tubules or walls contain numerous organisms.

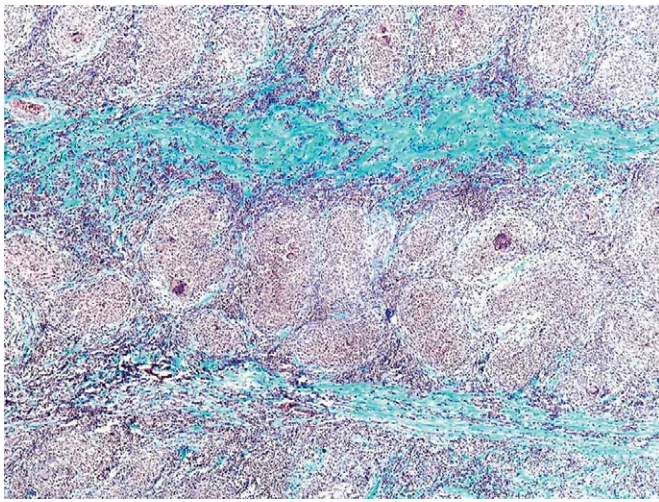


Fig. 12-162 Idiopathic granulomatous orchitis showing seminiferous tubules with peritubular fibrosis. Numerous lymphocytes and macrophages are present in the interstitium and within seminiferous tubules. Multinucleated giant cells are present in some tubules.

Idiopathic granulomatous orchitis

Idiopathic granulomatous orchitis is a chronic inflammatory condition of older adults (mean, 59.2 years). The most prominent clinical symptom is testicular enlargement, suggesting malignancy.¹⁵⁴² Most patients have a history of scrotal trauma, 66% have symptoms of urinary tract infection with negative cultures, and 40% have sperm granuloma in the epididymis. An autoimmune etiology has been suggested.

The testis is enlarged, with a nodular cut surface and areas of necrosis or infarction. There are two histologic forms, according to whether the lesion is predominantly in the tubules (tubular orchitis) or the interstitium (interstitial orchitis). In tubular orchitis, germ cells degenerate and the Sertoli cells have vacuolated cytoplasm and vesicular nuclei. Plasma cells and lymphocytes infiltrate the walls of the seminiferous tubules, forming concentric rings. Multinucleated giant cells are present in the tubular lumina and sometimes in the interstitium (Fig. 12-162). Vascular thrombosis and arteritis are common. In interstitial orchitis, the inflammation is predominantly interstitial. Ultimately, tubular atrophy and interstitial fibrosis prevail in both forms, which may arise from different immune mechanisms.¹⁵⁴³ Tubular orchitis histologically resembles experimental orchitis caused by injection of serum from animals with orchitis, whereas interstitial orchitis resembles orchitis produced by the transfer of cells from immunized animals.

The differential diagnosis of idiopathic granulomatous orchitis is infectious orchitis caused by bacteria, spirochetes, fungi, or parasites. A useful clue in the tubular form is the presence of giant cells within seminiferous tubules.

Focal orchitis

The occurrence of focal lymphoid cell infiltrates in the testicular interstitium is common in infertile patients,^{1544,1545} patients who have undergone surgery for bilateral inguinal hernia,¹⁵⁴⁶ vasectomized patients who developed post-

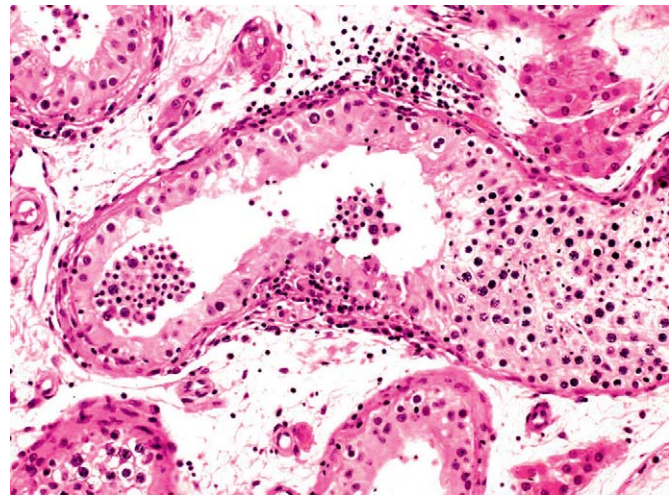


Fig. 12-163 Focal orchitis showing infiltrates of lymphoid cells and macrophages within a seminiferous tubule. There is persistence of Sertoli cells and isolated spermatogonia.

infection obstruction,¹⁵⁴⁷ after testicular piercing,¹⁵⁴⁸ and cryptorchidism.¹⁵⁴⁹ Inflammatory infiltrates usually involve the seminiferous tubules, and this suggests the disorder is due to an immunologic response (Fig. 12-163).

Testicular pseudolymphoma

Pseudolymphoma is a benign reactive process with a lymphoid cell proliferation so intense that it may be mistaken for lymphoma. Testicular pseudolymphoma consists of inflammatory infiltrates with numerous lymphocytes and plasma cells that partially or totally destroy testicular parenchyma.^{1550,1551}

The differential diagnosis includes lymphoma, various forms of orchitis, and seminoma. The diagnosis of lymphoma may be excluded by the lack of atypia and polyclonal nature of the inflammation. Syphilitic orchitis also contains a plasma cell-rich inflammatory infiltrate, but pseudolymphoma does not have other characteristic features of syphilitic orchitis, such as endarteritis obliterans; spirochetes cannot be demonstrated by special stains. The lack of granulomas or significant numbers of macrophages, together with the negative results of specific histochemical stains, also helps to exclude idiopathic granulomatous orchitis, tuberculosis, leprosy, sarcoidosis, and fungal infection. Finally, although the presence of a prominent inflammatory infiltrate and, in many cases, numerous lymphoid follicles, may suggest the diagnosis of seminoma, the presence of seminoma cells should be easily demonstrated with Best's carmine stain, periodic acid-Schiff, or placenta-like alkaline phosphatase. The term plasma cell granuloma¹¹⁵² refers to a reactive process characterized by the presence of polyclonal adult plasma cells that are absent in testicular plasmacytoma.¹⁵⁵³

Histiocytosis with testicular involvement

Sinus histiocytosis with massive lymphadenopathy (Rosai-Dorfman disease) is a benign proliferation of macrophages

that uniquely contain numerous lymphocytes in their cytoplasm. The disease was reported in a kidney and testis of a patient in remission from malignant lymphoma in association with monoclonal IgA gammopathy,¹⁵⁵⁴ and in a second patient with diabetes mellitus who had been previously treated for pulmonary tuberculosis.¹⁵⁵⁵

Increased numbers of interstitial macrophages may also be observed in more than two-thirds of autopsies from adult patients, but the cause is unknown. One condition associated with this disorder is treatment with hydroxyethylstarch plasma expander. In this lesion, the interstitial macrophages stand out by virtue of their large size and multivacuolated cytoplasm, suggesting thesaurosis. There is no evidence of mucin glycoproteins, proteoglycans, starch, lipids, glycogen, or foreign body material. Most patients have no clinical symptoms other than pruritus and persistent erythema.¹⁵⁵⁶

Other testicular and epididymal lesions

Epididymitis nodosa

Epididymitis nodosa is a proliferation of small irregular ducts whose epithelium lacks the characteristic features of the epididymal epithelium. The disorder is associated with inflammation and fibrosis, similar to vasitis nodosa.¹⁵⁵⁷

Epididymitis induced by amiodarone

In several tissues, including the testis, amiodarone is concentrated up to 300 times its plasma level,¹⁵⁵⁸ causing testicular atrophy and increased serum levels of FSH and LH in some patients.¹⁵⁵⁹ The incidence of epididymitis during amiodarone therapy varies from 3% to 11%,^{1560,1561} and more than 35 cases (in several cases involvement was bilateral) have been reported, although there are probably many others.^{1562,1563} The disorder may occur at any age.¹⁵⁶⁴ When amiodarone dosage is reduced to 300 mg/day the epididymitis heals within a few weeks.¹⁵⁶⁵ Autopsy studies show focal areas of fibrosis and lymphoid cell infiltrates not related to infection. Recognition is important to avoid unnecessary antibiotics or aggressive surgery.

Ischemic granulomatous epididymitis

This term describes a lesion located in the epididymal head characterized by non-infectious necrosis with polypoid masses of inflamed granulation tissue in peripheral ductal structures. Granulomas containing multinucleated giant cells present within efferent ductuli or form sperm microgranulomas with ductal neof ormation similar to that of epididymitis nodosa. The cause is unknown, but may result from ischemia.¹⁵⁶⁶

Calculus (stone in the testis)

The terms 'testicular calculus' and 'stone in the testis' have been used to describe a lesion characterized by the presence of nodular testicular calcification that is not related to ischemia, orchitis, vasculitis, hematoma, or tumor.^{1567,1568}

Polyarteritis nodosa

The testicular arteries may be affected by systemic disorders such as Schönlein–Henoch purpura,¹⁵⁶⁹ Wegener's disease,^{1570,1571} Kogan's disease,¹⁵⁷² Behçet's disease,¹⁵⁷³ relapsing polychondritis, rheumatoid arthritis, and dermatomyositis, but the most frequent involvement is with polyarteritis nodosa.¹⁵⁷⁴ Approximately 80% of patients with polyarteritis nodosa have testicular or epididymal involvement,¹⁵⁷⁵ but only 2–18% are diagnosed during life. Rarely, testicular or epididymal polyarteritis nodosa is the first manifestation of the disease. In these cases the symptoms may suggest orchitis, epididymitis, testicular torsion, or tumor.^{1576–1578}

The testis usually shows arterial lesions in different stages of evolution, including fibrinoid necrosis, inflammatory reaction, thrombosis, or aneurysm. The parenchyma initially has zones of infarction (Fig. 12-164). Histologic and immunohistochemical findings similar to those of polyarteritis nodosa may occasionally be observed in the testis or the epididymis without lesions elsewhere; this condition is referred to as isolated arteritis of the testis and epididymis,¹⁵⁷⁹ and differs from classic polyarteritis by a lack of vascular thrombosis, aneurysm, or infarct. The etiology of isolated arteritis is unknown, but the prognosis is excellent.¹⁵⁸⁰ The histologic findings of necrotizing arteritis in the testis or epididymis should be followed by clinical, hematologic, and biochemical studies to exclude systemic arteritis.^{1581,1582}

Testicular infarct

Torsion of the spermatic cord is the most frequent cause of testicular infarct, followed by trauma, incarcerated inguinal hernia, epididymitis, and vasculitis.

Spermatic cord torsion

Spermatic cord torsion is a surgical emergency. If repair is delayed more than 8 hours, testicular viability is usually compromised. This disorder may appear at any age, but the

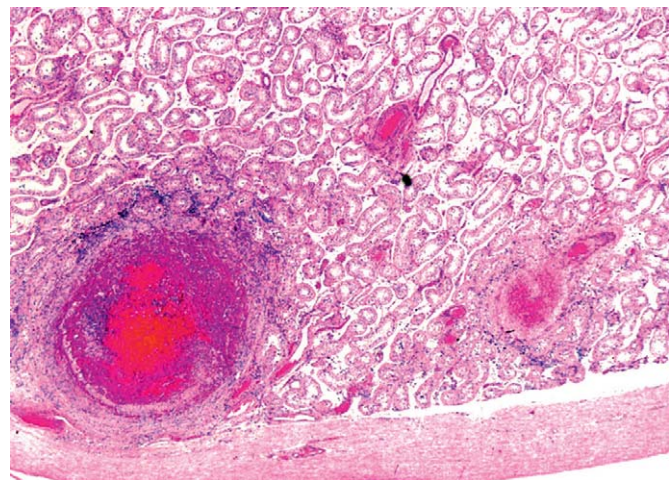


Fig. 12-164 Polyarteritis nodosa involving several intraparenchymal arteries.

peaks of maximal incidence are the perinatal period and puberty.¹⁵⁸³

Factors that predispose to testicular torsion are anatomical anomalies in testicular suspension and abnormal position of the testis. Many men with testicular torsion have an abnormally high reflection of the tunica vaginalis, giving rise to the deformity known as 'bell-clapper.' Other anomalies include elongated mesorchium, separation between the epididymis and testis, and absent or very elongated gubernaculum. The frequency of testicular torsion is higher in cryptorchid and retractile testes than in normal testes.

There are two classic anatomic forms of testicular torsion: high (supravaginal or extravaginal) and low (intravaginal). Each appears at a different age. Extravaginal torsion typically occurs in infancy and childhood, whereas intravaginal torsion is more frequent at puberty and adulthood.

Neonatal torsion is bilateral in 12–21% of cases.¹⁵⁸⁴ Most torsion observed on the first of life is intrauterine.¹⁵⁸⁵ Pubertal and adult torsion causes testicular pain that may radiate to the abdomen or other sites. About 36% of patients have a previous history of pain or swelling in one or both testes. The differential diagnosis includes all causes of acute scrotum.^{1586,1587}

Torsion causes hemorrhagic infarction of the testis (Fig. 12-165). In old neonatal torsion, the histological findings are so advanced that only collagenized tissue containing calcium and hemosiderin deposits is seen. In adults, three degrees of histological lesion may be distinguished.¹⁵⁸⁸ Degree I (26.5% of adult twisted testes) is characterized by edema, vascular congestion, and focal hemorrhage. Seminiferous tubules are dilated, with sloughed immature germ cells, apical vacuolation of Sertoli cells, and dilated lymphatic vessels.¹⁵⁸⁹ Degree II (26.5% of testes) has pronounced interstitial hemorrhage and sloughing of all germ cell types

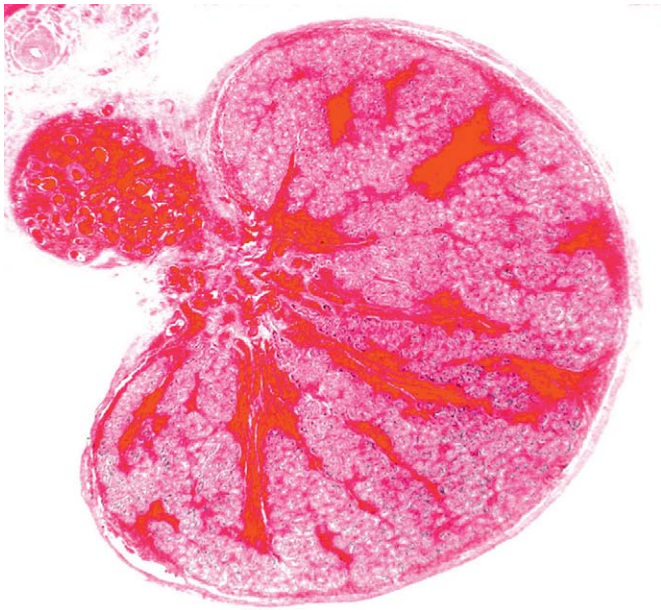

Fig. 12-165 Hemorrhagic infarct in a newborn testis. The hemorrhagic areas are near the rete testis and follow the course of the centripetal veins.

in the seminiferous tubules. The lesion is more severe in the center of the testis, and thus biopsy might provide erroneous information (Fig. 12-166). Degree III lesions (45% of testes) are characterized by necrosis of the seminiferous tubular cell layers. There is often a correlation between the time interval of torsion and the degree of the histologic lesion.¹⁵⁹⁰ Degree I appears in torsion of less than 4 hours' duration, degree II in torsion of between 4 and 8 hours, and degree III in torsion of more than 12 hours. Nevertheless, there are some exceptions that could probably be related, among other factors, to the number of twists in the torsed spermatic cord (degrees of testicular rotation). The testicular salvage rate, defined as testicular growth and development that reflects the age of the patient and the contralateral testis, is around 50% in all cases of testicular torsion.¹⁵⁹¹ Testes that do not bleed into the albuginea incision within 10 minutes are assumed to be non-viable and should be removed.¹⁵⁹²

Little attention has been paid to intermittent testicular torsion. Early orchiopexy may save these testes, but after surgery, the testis becomes small and excessively mobile, and most have the bell-clapper deformity.¹⁵⁹³ Seminiferous tubules are devoid of germ cells and have hyalinized walls.

Some adults with untreated testicular torsion develop lipomembranous fat necrosis of the spermatic cord.¹⁵⁹⁴ Patients seek help for pain in the high scrotum. At this level, there is a small nodule that corresponds to remnants of the twisted testis. The epididymis and proximal spermatic cord characteristically contain fat necrosis (Fig. 12-167).

Adults with prior spermatic cord torsion often consult for infertility. The mechanism causing spermiogram alteration is controversial, and three hypotheses have been proposed:

- *Autoimmune process.* It has been suggested that the ischemic injury breaks the blood–testis barrier, and antigens released from the necrotic germ cells activate

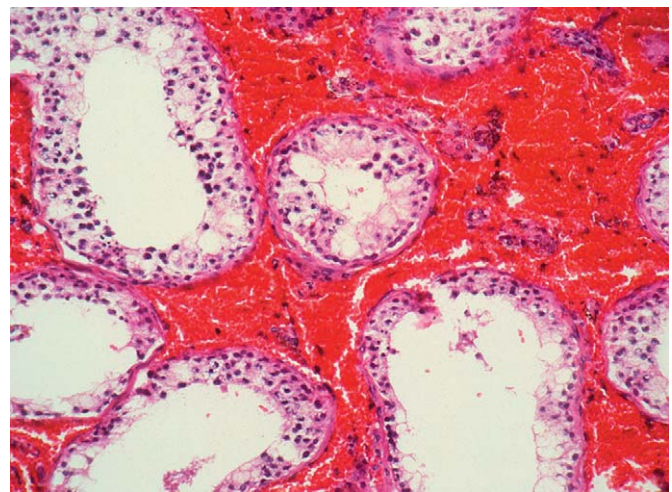


Fig. 12-166 Hemorrhagic infarct grade II in a 13-year-old boy. There is interstitial hemorrhage, focal sloughing of the seminiferous tubular cells, and intense Sertoli cell vacuolation.

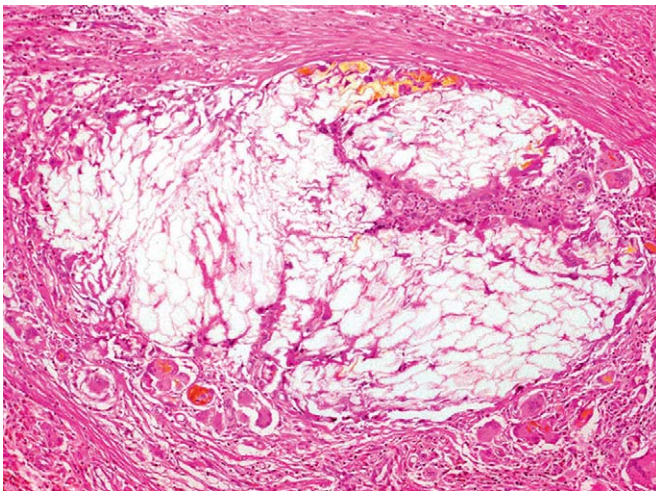


Fig. 12-167 Lipomembranous fat necrosis in a 14-year-old boy who presented with a history of several weeks of intense scrotal pain. Giant cell granulomatous reaction around the membranes had developed.

macrophages and lymphocytes in the interstitium, stimulating the formation of antibodies against these antigens. These antibodies that enter in the blood circulation may presumably damage the contralateral testis.¹⁵⁹⁵

- *Alterations in microcirculation.* After testicular torsion, blood flow decreases in the contralateral testis, causing an increase in the characteristic products of hypoxia, such as lactic acid and hypoxanthine.¹⁵⁹⁶ Intense apoptosis involving mainly spermatocytes I and II has been observed.¹⁵⁹⁷ Long-term effects are yet unknown.
- *Primary testicular lesions.* Many twisted testes have lesions that cannot be formed in a few hours, such as hypoplastic tubules, microlithiasis, and focal spermatogenesis. In addition, more than half of biopsies of the contralateral testis show marked spermatogenetic lesions.¹⁵⁹⁸ These findings suggest that torsion occurs in testes with congenital lesions.

Other causes of testicular infarct

Trauma¹⁵⁹⁹ and lesions of the vessels of the spermatic cord may also cause testicular infarct. Ischemic atrophy is a risk of inguinal surgery, including herniorrhaphy, varicocelectomy, hydrocelectomy, and descent of cryptorchid testis (Fig. 12-168). The incidence of atrophy after inguinal herniorrhaphy varies from 0.06% in primary herniorrhaphy¹⁶⁰⁰ to 7.9% after surgery for recurrent herna,¹⁶⁰¹ depending on the difficulty and extent of the hernia. Atrophy occurs in some cases of thrombosis of the vena cava or spermatic artery.¹⁶⁰² Focal infarction of the testis is associated with polycythemia, sickle cell disease, trauma,^{1603,1604} and laparoscopic inguinal hernia repair.

Focal infarction may also be spontaneous. Clinical symptoms of testicular infarct mimic testicular tumor. Color Doppler ultrasound reveals the diagnosis in most cases.¹⁶⁰⁵

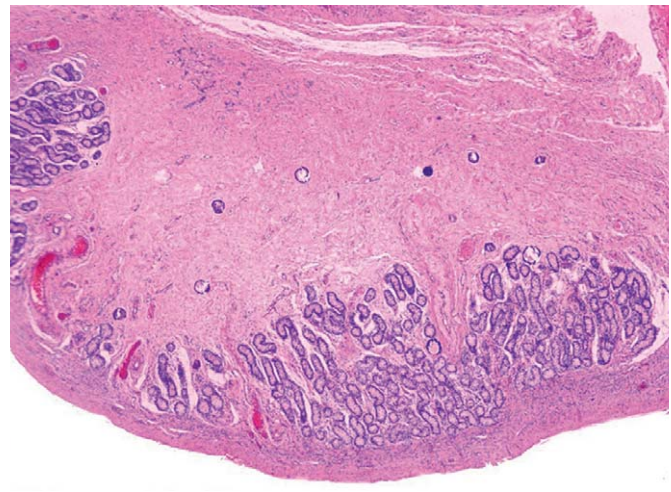


Fig. 12-168 Longitudinally sectioned testis from a 4-year-old infant who had previously undergone orchidopexy. The testis shows marked fibrosis and numerous calcifications except for the periphery of the testicular parenchyma.

Other testicular diseases

Cystic malformation

Cystic malformation of the tunica albuginea and testicular parenchyma was first described in the 19th century,¹⁶⁰⁶ and was long considered rare and mainly present in the tunica albuginea.^{1607,1608} With the systematic use of ultrasonography, the incidence of cysts has been found to be much higher:¹⁶⁰⁹ non-neoplastic cysts are found in 2.1%¹⁶¹⁰ to 9.8%¹⁶¹¹ of testes.^{1612,1613}

Cyst of the tunica albuginea is usually an incidental finding in patients in the fifth or sixth decade of life. It is located in the anterolateral aspect of the testis and may be unilocular or multilocular,¹⁶¹⁴ ranging from 2 to 4 mm and containing clear fluid without spermatozoa. The cyst may be embedded within the connective tissue of the tunica albuginea, protrude from the inner surface of the tunica albuginea into the testicular parenchyma, or protrude from the outer surface forming a blue lump in the tunica albuginea. The epithelium lining the cyst may be simple columnar or stratified cuboidal, and is supported by a thin layer of collagenized connective tissue. The columnar epithelium usually includes some ciliated cells,¹⁶¹⁵ and the cuboidal epithelium is composed of two layers of non-ciliated cells (Fig. 12-169).

Cyst of the rete testis is identified by a distinctive epithelial lining of areas of flattened cells intermingled with areas of tall columnar cells. Spermatozoa are frequently found within the cyst,¹⁶¹⁶ and hence the cyst is also called intratesticular spermatocele.¹⁶¹⁷ It may be associated with cystic transformation of the rete testis and multiple epididymal cysts. Rete testis cyst is not always attached to the rete and may be found at a distance.

Simple cyst of the testis constitutes the remaining intraparenchymal cyst. It is usually lined by cuboidal epithelium and contains no spermatozoa.^{1618,1619} Simple cyst ranges

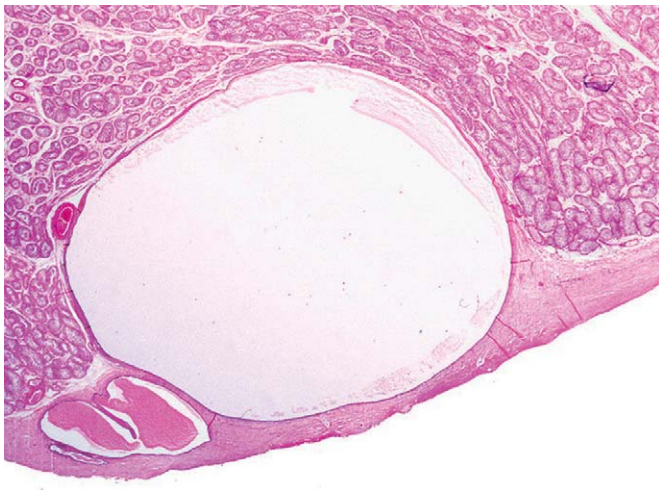

Fig. 12-169 Multilocular cyst in the tunica albuginea. The largest cavity protrudes into the testicular parenchyma.

from 2 nm to 18 mm in diameter.^{1620,1621} The disorders occurs at any age, from 5 months to 80 years, with a bimodal distribution with peaks at 8 month and 60 years.¹⁶²² It may occur bilaterally,¹⁶²³ and may present as two cysts in the same testis.¹⁶²⁴

Origin of the three types of testicular cyst is uncertain. Previously, traumatic¹⁶²⁵ and inflammatory¹⁶²⁶ origins were attributed to tunica albuginea cyst, but most now believe that they are derived from embryonal remnants of the mesonephric ducts^{1615,1627} or mesothelial cells embedded in the tunica albuginea during embryogenesis.^{1614,1628,1629} Simple cyst of the testis may also have a mesothelial origin, but it is possible that some arise from ectopic rete testis epithelium. These cysts are unrelated to epidermoid cyst, differing in the ultrasonographic^{1630,1631} and histologic features (see discussion on cystic dysplasia and testicular tumors in the section on hamartomatous testicular lesions). Ultrasound studies indicate that testicular cyst has little potential for growth.^{1630,1632} Currently, excision is recommended only in children when the cyst may impair testicular development.¹⁶³³

Disorders of the rete testis

Dysgenesis

Dysgenesis of the rete testis is characterized by inadequate maturation and persistence of infantile or pubertal characteristics in adults.¹⁶³⁴ This disorder is frequent in undescended adult testes. The lesion involves the rete testis segments referred to as septal, mediastinal, and extratesticular. There is poor development of the cavities and their epithelial lining, which becomes cuboidal or columnar instead of flattened with areas of columnar cells. The lumina of the rete testis cavities may be completely absent (simple hypoplasia) or, conversely, undergo microcystic dilation (cystic hypoplasia). In a few cases, the rete testis develops papillary, cribriform, or tubular formations (adenomatous hyperplasia).

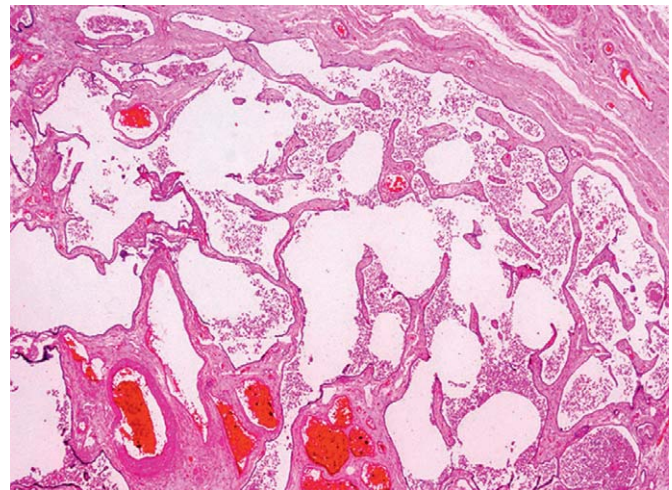


Fig. 12-170 Cystic transformation of the rete testis secondary to a lesion in the caput epididymidis in a patient with chronic epididymitis.

Metaplasia

The epithelium of the rete testis is usually flattened, with scattered areas of columnar cells. In estrogen-treated patients, those with chronic hepatic insufficiency, functioning tumor that secretes estrogens or human chorionic gonadotropin, and other disorders that are described as hyperplasia of the rete testis it may undergo diffuse transformation into tall columnar epithelium. Except for the latter group, metaplasia of the rete testis seems to be an estrogen-dependent process, and estrogen receptors are present in the rete testis epithelium.¹⁶³⁵

Cystic ectasia of the rete testis (acquired cystic transformation)

Acquired cystic transformation of the rete testis is common, and its incidence increases with age and associated disorders.¹⁶³⁶ Ultrasound^{1637,1638} and magnetic resonance¹⁶³⁹ studies reveal characteristic images that may suggest malignancy. The lesion has three forms: simple, associated with epithelial metaplasia, and with crystalline deposits.

Simple cystic transformation consists of dilated cavities with normal epithelium. It results from obstruction of the epididymis or the initial portion of the vas deferens due to ischemia (aging men); compression by epididymal and spermatic cord tumor, or by congestive veins in varicocele; inflammation in patients with previous epididymitis; malformation (testis–epididymis dissociation, malformed epididymis and absence of the vas deferens);¹⁶⁴⁰ or iatrogenic causes (surgery for epididymoectomy or removal of epididymal cyst) (Fig. 12-170).¹⁶⁴¹

Cystic transformation with epithelial metaplasia is a frequent finding at autopsy.¹³⁶⁹ Its development is probably due to the concurrence of sperm excretory duct obstruction and conditions involved in increased serum estrogen levels, such as chronic liver insufficiency. Another possible cause is inflammation involving the rete testis.

Cystic transformation with crystalline deposits has also been called cystic transformation of the rete testis secondary

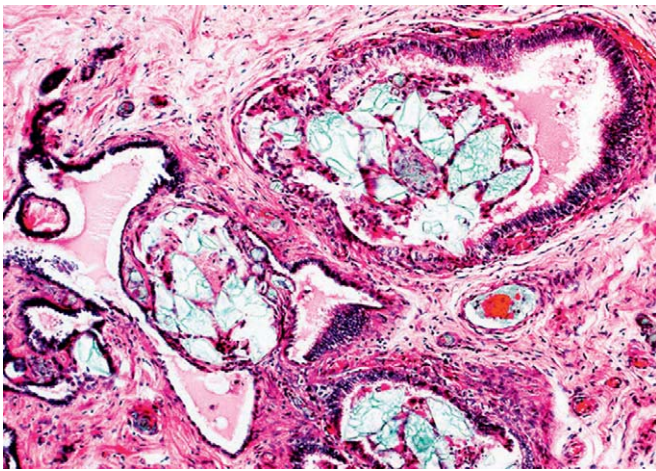


Fig. 12-171 Changes in the rete testis associated with dialysis. Dilation of the rete testis and initial portion of the ductuli efferentes can be observed. Crystalline structures, mainly rhomboidal in shape, accumulate inside and outside the tubules.

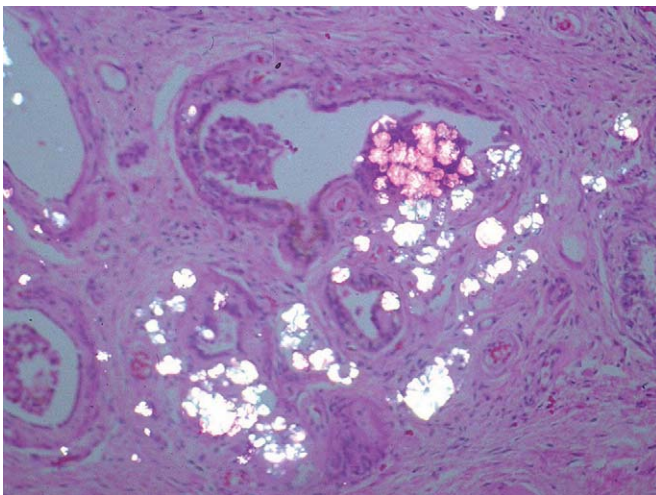


Fig. 12-172 Renal dialysis-associated cystic transformation of the rete testis with oxalate crystals demonstrated by polarized light.

to renal insufficiency.¹⁶⁴² It is a bilateral lesion of adult testes characterized by the concurrence of three findings: cystic transformation of the rete testis, cuboidal or columnar metaplasia of its epithelium, and the presence of urate and oxalate crystalline deposits that may be recognized by polarized light. The lesion is pathognomonic of dialyzed patients with chronic renal insufficiency. Crystalline deposits are initially formed beneath the epithelia of the rete testis and ductuli efferentes; later they protrude into the lumina, where they are finally released. Inflammation is absent or slight, although a few giant cells and small fibrotic areas are often seen (Figs 12-171, 12-172).

Adenomatous hyperplasia

This lesion is characterized by diffuse or nodular proliferation of tubular or papillary structures that are derived from the rete testis¹⁶⁴³ and are observed in cryptorchid or normally

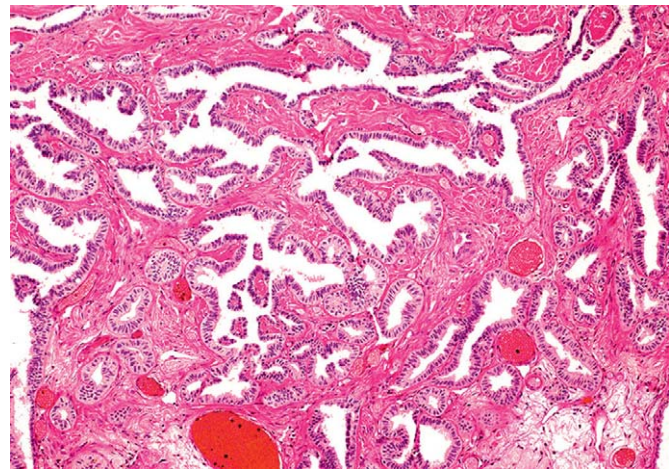


Fig. 12-173 Adenomatous hyperplasia of the rete testis. The epithelium is columnar and supported by a well-collagenized stroma.

descended testes. Cases have been reported in newborns, children, and adults.¹⁶⁴⁴

Adenomatous hyperplasia in newborn and infantile testes consists of enlargement of the mediastinum testis by cord-like or tubular structures derived from the rete testis. The lesion may extend up to one-third of testicular volume. Despite excessive development of the rete testis, the normal connections with seminiferous tubules and efferent ductuli remain. Presentation may be unilateral or bilateral. Unilateral presentation is associated with cryptorchidism or vanishing testis. Bilateral cases may also present with bilateral renal dysplasia. Efferent ductuli may show luminal dilation and irregular outlines. The etiopathogenesis might be similar to that of cystic dysplasia of the testis.¹⁶⁴⁴

Adenomatous hyperplasia in adults is usually an incidental finding at autopsy,¹⁶⁴⁵ in cryptorchid testes,¹⁶⁴⁶ or in testes with germ cell tumor. The rete testis epithelium forms non-encapsulated nodular outgrowths or a diffuse pattern. Nodule size may be large enough to suggest tumor. The epithelium consists of cuboidal cells with ovoid nuclei, deep nuclear folds, and peripheral nucleoli. Atypias and mitotic figures are lacking (Fig. 12-173). The ultrastructure and immunophenotype of the epithelium are similar to those of the normal rete testis. Spermatozoa may be seen inside the cavities in some cases, suggesting that such a proliferation is connected with the seminiferous tubules. Most of the testes show a certain degree of seminiferous tubular atrophy.

In incidental autopsy cases the etiology is unknown, although it may be related to hormonal or chemical agent effects.¹⁶⁴⁷⁻¹⁶⁴⁹ In cryptorchid testes and with many testicular tumors, the most probable cause is a primary anomaly that is part of the testicular dysgenesis syndrome.¹⁶⁵⁰

Adenomatous hyperplasia should be distinguished from three entities: rete testis pseudohyperplasia, which appears in atrophic testes; primary rete testis tumor; and metastasis of adenocarcinoma. In pseudohyperplasia, lesions are focal, microscopic, and usually located in the septal rete, although the mediastinal rete shows few or no alterations. Benign rete testis tumor such as adenoma (solid and papillary variants)

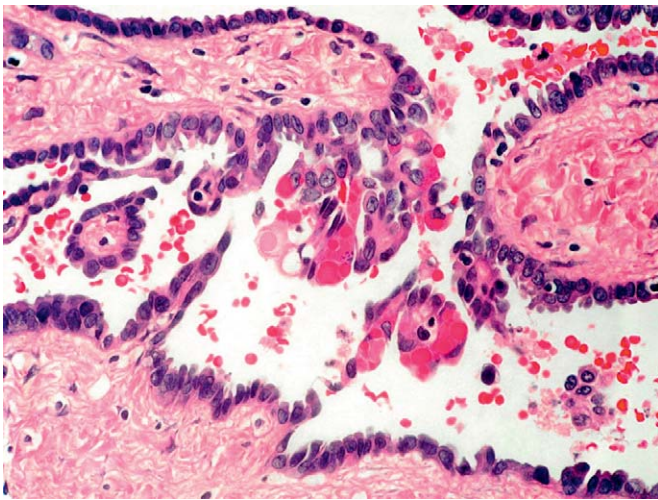


Fig. 12-174 Rete testis hyperplasia with hyaline globules. The globule-containing cells protrude into the lumina of the rete testis channels.

and cystadenoma are isolated and focal,¹⁶⁵¹ whereas rete testis hyperplasia is diffuse. Adenocarcinoma of the rete testis is a tumor that displays numerous mitotic figures and infiltrates adjacent structures.¹⁶⁵² Metastasis of prostatic adenocarcinoma may be excluded because these metastases alter the rete testis architecture and are immunoreactive for prostatic acid phosphatase and PSA.

Hyperplasia with hyaline globule formation

This reactive lesion is characterized by the presence of intracytoplasmic accumulation of hyaline eosinophilic globules in the epithelial cells of the rete testis. The epithelium may be hyperplastic, but does not contain mitotic figures or nuclear atypia. The globules are up to 15 μm in diameter (Fig. 12-174). This lesion is associated with tumor and inflammatory processes occurring near the mediastinum testis, and can be observed in association with 75% of mixed testicular germ cell tumors, 47% of seminomas, and 20% of non-germ cell testicular tumors, such as epididymal tumor that infiltrates the testis (adenomatoid tumor).¹⁶⁵³ Yolk sac tumor infiltrating the rete testis may closely resemble this type of rete testis hyperplasia. Positive immunoreactions for α -fetoprotein and placenta-like alkaline phosphatase, as

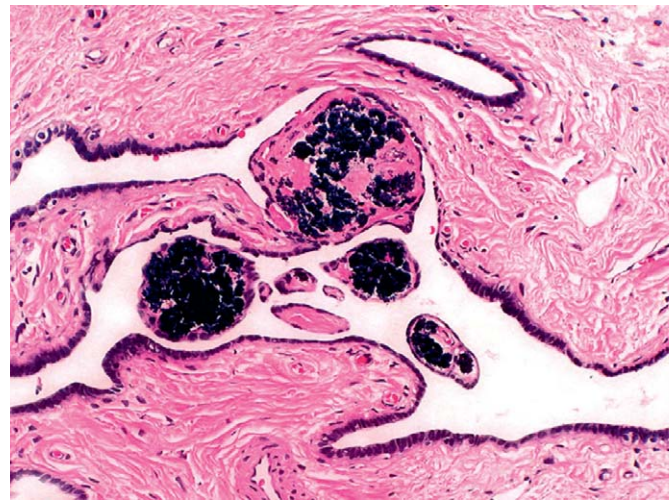


Fig. 12-175 Nodular proliferation of calcifying connective tissue in the rete testis with large calcium deposits.

well as nuclear atypia, are helpful to distinguish germ cell neoplasia from this rete testis hyperplasia.¹⁶⁵⁴

Intracavitary polypoid nodular proliferation

This lesion, described as nodular proliferation of calcifying connective tissue in the rete testis, is characterized by the presence of multiple nodules that originate from the rete testis lining and subjacent connective tissue, protruding into the channels of the rete testis. These consist of cellular connective tissue covered by several layers of a fibrin-like material, which in turn is covered by rete testis epithelium. The nodules may be totally or partially calcified (Fig. 12-175).¹⁶⁵⁵ The lesion is an incidental finding at autopsy in patients with impaired peripheral perfusion.

Selective location of the lesion in the walls of the cavities and chordae rete testis is probably related to poor vascularization of these structures. The etiopathogenetic mechanism may be anoxia, necrosis, fibrin deposition, proliferation of connective tissue, or dystrophic calcification. The intracavitary growth of the lesion might be due to the lower intracavitary pressure and also to the stiff structure of the mediastinum testis.

REFERENCES

- Hiort O, Holterhus PM. The molecular basis of male sexual differentiation. *Eur J Endocrinol* 2000; 142: 101–110.
- Gessler M, Poustka A, Cavenee W, et al. Homozygous deletions in Wilms' tumours of a zinc-finger gene identified by chromosome jumping. *Nature* 1990; 343: 774–778.
- Call KM, Glaser T, Ito CY, et al. Isolation and characterization of a zinc finger polypeptide gene at the human chromosome 11 Wilms' tumor locus. *Cell* 1990; 60: 509–520.
- Kreidberg JA, Sariola H, Loring JM, et al. WT-1 is required for early kidney development. *Cell* 1993; 74: 679–691.
- Pelletier J, Bruening W, Kashtan CE, et al. Germline mutations in the Wilms' tumor suppressor gene are associated with abnormal urogenital development in Denys-Drash syndrome. *Cell* 1991; 67: 437–447.
- Barboux S, Niaudet P, Gubler MC, et al. Donor splice-site mutations in WT1 are responsible for Frasier syndrome. *Nature Genet* 1997; 17: 467–470.
- Hanley NA, Ball SG, Clement-Jones M, et al. Expression of steroidogenic factor 1 and Wilms' tumour 1 during early human gonadal development and sex determination. *Mech Dev* 1999; 87: 175–180.
- Achermann JC, Ito M, Hindmarsh PC, et al. A mutation in the gene encoding steroidogenic factor-1 causes XY sex reversal and adrenal failure in humans. *Nature Genet* 1999; 22: 125–126.

9. Biason-Lauber A, Schoenle EJ. Apparently normal ovarian differentiation in a prepubertal girl with transcriptionally inactive steroidogenic factor 1 (NR5A1/SF-1) and adrenal cortical insufficiency. *Am J Hum Genet* 2000; 67: 1563–1568.
10. Lim HN, Hawkins JR. Genetic control of gonadal differentiation, *Baillière's Clin Endocrinol Metab* 1998; 12: 1–16.
11. Bishop CE, Guellaen G, Gelowert D, et al. Single-copy DNA sequences specific for the human Y chromosome. *Nature* 1984; 309: 253–255.
12. McElreavey K, Fellous M. Sex determination and the Y chromosome. *Am J Med Genet* 1999; 89: 176–185.
13. Blyth B, Duckett JW. Gonadal differentiation: a review of the physiological process and influencing factors based on recent experimental evidence. *J Urol* 1991; 145: 689–694.
14. Salas-Cortes L, Jaubert F, Barbaux S, et al. The human SRY protein is present in fetal and adult Sertoli cells and germ cells. *Int J Dev Biol* 1999; 43: 135–140.
15. Haqq CM, King CY, Ukiyama E, et al. Molecular basis of mammalian sexual determination: activation of Müllerian inhibiting substance gene expression by SRY. *Science* 1999; 266: 1494–1500.
16. Huang B, Wang S, Ning Y, et al. Autosomal XX sex reversal caused by duplication of SOX-9. *Am J Med Genet* 1999; 87: 349–353.
17. Foster JW, Dominguez-Steglich MA, Guioli S, et al. Campomelic dysplasia and autosomal sex reversal caused by mutations in an SRY-related gene. *Nature* 1994; 372: 525–530.
18. Chaboissier MC, Kobayashi A, Vidal VI, et al. Functional analysis of Sox8 and Sox9 during sex determination in the mouse. *Development* 2004; 131: 1891–1901.
19. Wagner T, Wirth J, Meyer J, et al. Autosomal sex reversal and campomelic dysplasia are caused by mutations in and around the SRY-related gene SOX9. *Cell* 1994; 79: 1111–1120.
20. Zhou R, Liu L, Guo Y, et al. Similar gene structure of two Sox9a genes and their expression patterns during gonadal differentiation in a teleost fish, rice field eel (*Monopterus albus*). *Mol Reprod Dev* 2003; 66: 211–217.
21. Koopman P. Sex determination: a tale of two Sox genes. *Trends Genet* 2005; 21: 367–370.
22. Wolf U. The molecular genetics of human sex determination. *J Mol Med* 1995; 73: 325–331.
23. Baumstark A, Barbi G, Djalali M, et al. X-p duplications with and without sex reversal. *Hum Genet* 1996; 97: 79–86.
24. Bennett CP, Docherty Z, Robb SA, et al. Deletion 9p and sex reversal. *J Med Genet* 1993; 30: 518–520.
25. Wilkie AOM, Campbell FM, Daubeney P. Complete and partial XY sex reversal associated with terminal deletion of 10q: report of 2 cases and literature review. *Am J Med Genet* 1993; 46: 597–600.
26. Merchant-Larios H, Moreno-Mendoza N, Buehr M. The role of the mesonephros in cell differentiation and morphogenesis of the mouse fetal testis. *Int J Dev Biol* 1993; 37: 407–415.
27. Moreno-Mendoza N, Herrera-Muñoz J, Merchant-Larios H. Limb bud mesenchyme permits seminiferous cord formation in the mouse fetal testis but subsequent testosterone output is markedly affected by the sex of the donor stromal tissue. *Dev Biol* 1995; 169: 51–56.
28. Tilmann C, Capel B. Mesonephric cell migration induces testis cord formation and Sertoli cell differentiation in the mammalian gonad. *Development* 1999; 126: 2883–2890.
29. Capel B, Albrecht K, Washburn LL, et al. Migration of mesonephric cells into the mammalian gonad depends on Sry. *Mech Dev* 1999; 84: 127–131.
30. Karl J, Capel B. Sertoli cells of the mouse testis originate from the coelomic epithelium. *Dev Biol* 1998; 203: 323–333.
31. Magre S, Jost A. Sertoli cells and testicular differentiation in the rat fetus. *J Electron Microscop Tech* 1991; 19: 172–188.
32. Wartenberg H, Kinsky I, Viebahn C, Schmolke C. Fine structural characteristics of testicular cord formation in the developing rabbit gonad. *J Electron Microscop Tech* 1991; 19: 133–157.
33. Satoh M. Histogenesis and organogenesis of the gonad in human embryos. *J Anat* 1991; 177: 85–107.
34. Merchant-Larios H, Moreno-Mendoza N. Mesonephric stromal cells differentiate into Leydig cells in the mouse fetal testis. *Exp Cell Res* 1998; 244: 230–238.
35. Merchant-Larios H, Taketo T. Testicular differentiation in mammals under normal and experimental conditions. *J Electron Microscop Tech* 1991; 19: 158–171.
36. Taketo T. Production of müllerian-inhibiting substance (MIS) and sulfated glycoprotein-2 (SGP-2) associated with testicular differentiation in the XX mouse gonadal graft. In: Robaire B, ed. *The male germ cell*. Ann NY Acad Sci 1991; 637: 74–89.
37. Byskov AG. Differentiation of the mammalian embryonic gonad. *Physiol Rev* 1986; 66: 71–117.
38. Haider SC, Laue D, Schwochau G, Hilscher B. Morphological studies on the origin of adult-type Leydig cells in rat testis. *Ital J Anat Embryol* 1995; 100: 535–541.
39. Lee MM, Donahoe PK. Müllerian inhibiting substance: a gonadal hormone with multiple functions. *Endocrinol Rev* 1993; 14: 152–164.
40. Picard JY, Josso N. Purification of testicular anti-müllerian hormone allowing direct visualization of the pure glycoprotein and determination of yield and purification factor. *Mol Cell Endocrinol* 1984; 34: 23–29.
41. Josso N, Picard JY. Anti-müllerian hormone. *Physiol Rev* 1986; 66: 1038–1090.
42. Behringer RR, Finegold MJ, Cate RL. Müllerian-inhibiting substance function during mammalian sexual development. *Cell* 1994; 79: 415–425.
43. Tran D, Muesy-Dessole N, Josso N. Anti-müllerian hormone is a functional marker of foetal Sertoli cells. *Nature* 1977; 269: 411–412.
44. Josso N, Cate RL, Picard JY, et al. Anti-Müllerian hormone, the Jost factor. *Recent Prog Hormone Res* 1993; 48: 1–59.
45. Schwindt B, Doyle LW, Hutson JM. Serum levels of müllerian inhibiting substance in preterm and term male neonates. *J Urol* 1997; 158: 610–612.
46. Shen WH, Moore CC, Ikeda Y, et al. Nuclear receptor steroidogenic factor 1 regulates the müllerian inhibiting substance gene: a link to the sex determination cascade. *Cell* 1994; 77: 651–661.
47. Barbara PS, Moniot B, Poulat F, et al. Steroidogenic factor-1 regulates transcription of the human anti-müllerian hormone receptor. *J Biol Chem* 1998; 273: 29654–29660.
48. Rey R, Josso N. Regulation of testicular anti-Müllerian hormone secretion. *Eur J Endocrinol* 1996; 135: 144–152.
49. Jirasek JE. Development of the genital system and male pseudohermaphroditism. Baltimore: Johns Hopkins, 1971.
50. Musnsterberg A, Lovell-Badge R. Expression of the mouse anti-müllerian hormone gene suggests a role in both male and female sexual differentiation. *Development* 1991; 113: 613–624.
51. Catlin EA, Powell SM, Manganaro TF, et al. Sex-specific fetal lung development and Müllerian inhibiting substance. *Am Rev Respir Dis* 1990; 141: 466–470.
52. Cunha GR, Alarid ET, Turner T, et al. Normal and abnormal development of the male urogenital tract. Role of androgens, mesenchymal-epithelial interactions, and growth factors. *J Androl* 1992; 13: 465–475.
53. Larsen WJ. *Human embryology*. London: Churchill Livingstone, 1993; 247.

54. Orth JM. The role of follicle-stimulating hormone in controlling Sertoli cell proliferation in testes of fetal rats. *Endocrinology* 1984; 115: 1248–1255.
55. Eskola V, Nikula H, Huhtaniemi I. Age-related variation of follicle-stimulating hormone stimulated cAMP production, protein kinase C activity and their interactions on the rat testis. *Mol Cell Endocrinol* 1993; 93: 143–148.
56. Wensing CJ. The embryology of testicular descent. *Hormone Res* 1988; 30: 144–152.
57. Heyns CF, De Klerk DP. The gubernaculum during testicular descent in the pig fetus. *J Urol* 1985; 133: 694–699.
58. Heyns CF. The gubernaculum during testicular descent in the human fetus. *J Anat* 1987; 153: 93–112.
59. Heyns CF, Human HJ, De Klerk DP. Hyperplasia and hypertrophy of the gubernaculum during testicular descent in the fetus. *J Urol* 1986; 135: 1043–1047.
60. Frey HL, Rajfer J. Incidence of cryptorchidism. *Urol Clin North Am* 1982; 9: 327–329.
61. Baumans V, Dijkstra G, Wensing CJ. The role of a non-androgenic testicular factor in the process of testicular descent in the dog. *Int J Androl* 1983; 6: 541–552.
62. Backhouse KM. Mechanism of testicular descent. *Karger Prog Reprod Biol Med* 1984; 10: 16–23.
63. Backhouse KM. The gubernaculum testis Hunteri, testicular descent and maldescent. *Ann Roy Coll Surg Engl* 1964; 35: 227–233.
64. Frey HL, Rajfer J. Role of the gubernaculum and intraabdominal pressure in the process of testicular descent. *J Urol* 1984; 131: 574–579.
65. Hutson JM, Hasthorpe S. Testicular descent and cryptorchidism: the state of the art in 2004. *J Pediatr Surg* 2005; 40: 297–302.
66. Baker LA, Nef S, Nguyen MT, et al. The insulin-3 Gene: Lack of a genetic basis for human cryptorchidism. *J Urol* 2002; 167: 2534–2537.
67. Tomiyama H, Hutson JM, Truong A, Agoulnik AI. Transabdominal testicular descent is disrupted in mice with deletion of insulinlike factor 3 receptor. *J Pediatr Surg* 2003; 38: 1793–1798.
68. Foresta C, Bettella A, Vinanzi C, et al. A novel circulating hormone of testis origin in humans. *J Clin Endocrinol Metab* 2004; 89: 5952–5958.
69. Yamanaka J, Metcalf SA, Hutson JM, Mendelsohn FA. Testicular descent II. Ontogeny and response to denervation of calcitonin gene-related peptide receptors in neonatal rat gubernaculum. *Endocrinology* 1993; 132: 280–284.
70. Hutson JM, Beasley SW. The mechanism of testicular descent. *Aust Paediatr J* 1987; 23: 215–216.
71. Goh DW, Middlesworth W, Farmer PJ, Hutson JM. Prenatal androgen blockade with flutamide inhibits masculinization of the genitofemoral nerve and testicular descent. *J Pediatr Surg* 1994; 29: 836–838.
72. Tanyel FC, Erdem S, Büyükpamukcu N, Tan E. Cremaster muscles obtained from boys with an undescended testis show significant neurological changes. *BJU Int* 2000; 85: 116–119.
73. Bernstein L, Pike MC, Depue RH, et al. Maternal hormone levels in early gestation of cryptorchid males: a case-control study. *Br J Cancer* 1988; 58: 379–381.
74. Spencer JR. The endocrinology of testicular descent. *AUA Update Series Lesson* 1994; 12: 94–99.
75. Staub C, Rauch M, Ferriere F, et al. Expression of estrogen receptor ESR1 and its 46-kDa variant in the gubernaculum testis. *Biol Reprod* 2005; 73: 703–707.
76. Cain MP, Kramer SA, Tindall DJ, Husmann DA. Expression of androgen receptor protein within the lumbar spinal cord during ontologic development and following antiandrogen induced cryptorchidism. *J Urol* 1994; 152: 766–769.
77. Belman AB. Acquired undescended (ascended) testis: Effects of human chorionic gonadotropin. *J Urol* 1988; 140: 1189–1190.
78. Vilar O. Histology of the human testis from neonatal period to adolescence. *Adv Exp Med Biol* 1970; 10: 95–111.
79. Müller J, Skakkebaek NE. Fluctuations in the number of germ cells during late foetal and early postnatal periods in boys. *Acta Endocrinol* 1984; 105: 271–274.
80. Müller J, Skakkebaek NE. Quantification of germ cells and seminiferous tubules by stereological examination of testicles of 50 boys who suffered from sudden death. *Int J Androl* 1983; 6: 143–156.
81. Cortes D, Müller J, Skakkebaek NE. Proliferation of Sertoli cells during development of the human testis assessed by stereological methods. *Int J Androl* 1987; 10: 589–596.
82. Nistal M, Abaurrea MA, Paniagua R. Morphological and histometric study of human Sertoli cells from birth to the onset of puberty. *J Anat* 1982; 134: 351–363.
83. Lin LH, DePhilip RM. Differential expression of placental (P)-cadherin in Sertoli cells and peritubular myoid cells during postnatal development of the mouse testis. *Anat Rec* 1996; 244: 155–164.
84. Prince FP. Ultrastructural evidence of mature Leydig cells and Leydig cell regression in the neonatal human testis. *Anat Rec* 1990; 228: 405–417.
85. Hadziselimovic F. Ultrastructure of normal and cryptorchid testis development. *Adv Anat Embryol Cell Biol* 1977; 53: 47–50.
86. Nistal M, Santamaría L, Paniagua R. Mast cells in the human testis and epididymis from birth to adulthood. *Acta Anat* 1984; 139: 535–552.
87. Faiman C, Reyes FI, Winter JSD. Serum gonadotropin patterns during the perinatal period in man and in the chimpanzee. *INSERM* 1974; 32: 281–298.
88. Forest mg, Sizonenko PC, Cathiard AM, et al. Hypophyso-gonadal function in humans during the first year of life. 1. Evidence for testicular activity in early infancy. *J Clin Invest* 1974; 53: 819–824.
89. Bidlingmaier F, Dörr HG, Eisenmenger W, et al. Testosterone and androstenedione concentrations in human testis and epididymis during the first two years of live. *J Clin Endocrinol Metabol* 1983; 57: 311–315.
90. Pelliniemi LK, Kuopio T, Fröjdman K. The cell biology and function of the fetal Leydig cell. In: Payne A., Hardy M, Russel L, eds. *The Leydig cell*. Vienna, FL: Cache River Press, 1996; 141–174.
91. Codesal J, Regadera J, Nistal M, et al. Involution of human fetal Leydig cells. An immunohistochemical, ultrastructural and quantitative study. *J Anat* 1990; 172: 103–114.
92. Nistal M. Paraganglios del epidídimo humano. *An Anat* 1977; 1: 307–316.
93. Müller J, Skakkebaek NE. Quantification of germ cells and seminiferous tubules by stereological examination of testicles from 50 boys who suffered from sudden death. *Int J Androl* 1983; 6: 143–156.
94. Paniagua R, Nistal M. Morphological and histometric study of human spermatogonia from birth to the onset of puberty. *J Anat* 1984; 139: 535–552.
95. Codesal J, Santamaría L, Paniagua R, et al. Proliferative activity of human spermatogonia from fetal period to senility measured by cytophotometric DNA quantification. *Arch Androl* 1989; 22: 209–215.
96. Rey R. Assessment of seminiferous tubule function (anti-müllerian hormone). *Baillière's Best Pract Res Clin Endocrinol Metab* 2000; 14: 399–408.
97. Andersson AM, Toppari J, Haavisto AM, et al. Longitudinal reproductive hormone profiles in infants: Peak of inhibin B levels in infant boys exceeds levels in adult men. *J Clin Endocrinol Metab* 1998; 83: 675–681.
98. Racine C, Rey R, Forest MG, et al. Receptors for anti-Müllerian hormone on Leydig cell are responsible for its effects on steroidogenesis and cell differentiation. *Proc Natl Acad Sci USA* 1998; 95: 594–599.
99. Frasier SD, Horton R. Androgens in the peripheral plasma of prepubertal

- children and adults. *Steroids* 1966; 8: 777–784.
100. Forti G, Santoro S, Andrea-Grisolia G, et al. Spermatic and peripheral plasma concentration of testosterone and androstenedione in prepubertal boys. *J Clin Endocrinol Metab* 1981; 53: 883–886.
 101. Lee VMK, Burger HG. Pituitary testicular axis during puberal development. In: De Kretser DM, Burger HG, Hudson B, eds. *The pituitary and testis: Clinical and experimental studies*. Heidelberg: Springer Verlag, 1983; 44–70.
 102. Mancini RE, Vilar O, Lavieri JC, et al. Development of Leydig cells in the normal human testis. A cytological, cytochemical and quantitative study. *Am J Anat* 1963; 112: 203–214.
 103. Nistal M, Paniagua R, Regadera J, et al. A quantitative morphology study of human Leydig cells from birth to adulthood. *Cell Tissue Res* 1986; 246: 229–236.
 104. Zachmann M, Kind HP, Häfliger H, et al. Testicular volume during adolescence. Cross-sectional and longitudinal studies. *Helv Paediatr Acta* 1974; 29: 61–72.
 105. Daniel WA, Feinstein RA, Howard-Peebles P, et al. Testicular volumes of adolescent. *J Pediatr* 1982; 101: 1010–1012.
 106. Hansen P, With TH. Clinical measurement of the testes in boys and men. *Acta Med Scand* 1952; 226: 457–465.
 107. Orvis BR, Bottle SK, Kogan BA. Testicular histology in fetuses with the prune belly syndrome and posterior urethral valves. *J Urol* 1988; 139: 335–337.
 108. Cortes D, Müller J, Skakkebaek NE. Proliferation of Sertoli cells during development of the human testis assessed by stereological methods. *Int J Androl* 1987; 10: 589–596.
 109. Nistal M, Paniagua R, Aburrea MA, et al. Hyperplasia and the immature appearance of Sertoli cells in primary testicular disorders. *Hum Pathol* 1982; 13: 3–12.
 110. Nistal M, Garcia-Rodeja E, Paniagua R. Granular transformation of Sertoli cells in testicular disorders. *Hum Pathol* 1991; 22: 131–137.
 111. Nistal M, Paniagua R, Regadera J, et al. A quantitative morphological study of human Leydig cells from birth to adulthood. *Cell Tissue Res* 1986; 246: 229–236.
 112. Nistal M, González-Peramato P, Paniagua R. Congenital Leydig cell hyperplasia. *Histopathology* 1988; 12: 307–317.
 113. Doshi N, Surti UI, Szulman AE. Morphologic anomalies in triploid liveborn fetuses. *Hum Pathol* 1983; 14: 716–723.
 114. Behre HM, Nashan D, Nieschlag E. Objective measurement of testicular volume by ultrasonography: evaluation of the technique and comparison with orchidometer estimates. *J Androl* 1989; 12: 395–403.
 115. Diamond JM. Ethnic differences. Variation in human testis size. *Nature* 1986; 320: 488–489.
 116. Handelsman DJ, Stara S. Testicular size: The effects of ageing, malnutrition, and illness. *J Androl* 1985; 6: 144–151.
 117. Prader A. Testicular size: assesment and clinical importance. *Triangle* 1966; 7: 240–243.
 118. Sosnik H. Studies of the participation of the tunica albuginea and rete testis (TA and RT) in the quantitative structure of human testis. *Gegenbaurs Morphol Jahrb* 1985; 131: 347–356.
 119. Leeson CR, Forman DE. Postnatal development and differentiation of contractile cells within the rabbit testis. *J Anat* 1981; 132: 491–511.
 120. Middendorff R, Muller D, Mewe M, et al. The tunica albuginea of the human testis is characterized by complex contraction and relaxation activities regulated by cyclic GMP. *J Clin Endocrinol Metab* 2002; 87: 3486–3499.
 121. Trainer TD. Histology of the normal testis. *Am J Surg Pathol* 1987; 11: 107–171.
 122. Lennox B, Ahmad RN, Mack WS. A method for determining the relative total length of the tubules in the testis. *J Pathol* 1970; 102: 229–238.
 123. Fawcett DW, Burgos MH. The fine structure of Sertoli cells in the human testis. *Anat Res* 1956; 124: 401–402.
 124. Nagano T. Some observations on the fine structure of the Sertoli cell in the human testis. *Zeitschr Zellforsch* 1966; 73: 89–106.
 125. Schulze C. On the morphology of the human Sertoli cell. *Cell Tissue Res* 1974; 153: 339–355.
 126. Schulze W, Rehder V. Organization and morphogenesis of the human seminiferous epithelium. *Cell Tissue Res* 1984; 237: 395–407.
 127. Fawcett DW. The mammalian spermatozoon. *Dev Biol* 1975; 44: 394–436.
 128. Paniagua R, Nistal M, Amat P, et al. Ultrastructural observations on nucleoli and related structures during human spermatogenesis. *Anat Embryol* 1986; 174: 301–306.
 129. Bustos-Obregón E, Esponda P. Ultrastructure of the nucleus of human Sertoli cells in normal and pathological testes. *Cell Tissue Res* 1974; 152: 467–475.
 130. Sáez JM, Avallet O, Lejeune H, et al. Cell–cell communication in the testis. *Hormone Res* 1991; 36: 104–115.
 131. Dym M. The fine structure of the monkey (*Macaca*) Sertoli cell and its role in maintaining the blood–testis barrier. *Anat Rec* 1973; 175: 639–656.
 132. Fawcett DW, Leak LV, Heidger PM. Electron microscopic observations on the structural components of the blood testis barrier. *J Reprod Fertil* 1979; 22: 105–122.
 133. Russell LD, Peterson RN. Sertoli cell junctions: morphological and functional correlates. *Int Rev Cytol* 1985; 94: 177–211.
 134. Russell LD: Morphological and functional evidence for Sertoli-germ cell relationship. In: Russell LD, Griswold MD, eds. *The Sertoli cell*. Clearwater, FL: Cache River Press, 1993; 365–390.
 135. Ritzen EM, Hansson V, French FS. The Sertoli cell. In: Burger H, De Kretser DM, eds. *The testis*. New York: Raven Press, 1981; 171–194.
 136. Pfeiffer DC, Vogl AW. Evidence that vinculin is codistributed with actin bundles in ectoplasmic ('junctional') specializations of mammalian Sertoli cells. *Anat Rec* 1991; 231: 89–100.
 137. Paniagua R, Rodríguez MC, Nistal M, et al. Changes in the lipid inclusion/Sertoli cell cytoplasm area ratio during the cycle of the human seminiferous epithelium. *J Reprod Fertil* 1987; 80: 335–341.
 138. Bawa SR. Fine structure of the Sertoli cell of the human testis. *J Ultrastruct Res* 1963; 9: 459–474.
 139. Paniagua R, Martín A, Nistal A, et al. Testicular involution in elderly men: comparison of histologic quantitative studies with hormone patterns. *Fertil Steril* 1987; 47: 671–679.
 140. Schulze W, Schulze C. Multinucleate Sertoli cells in aged human testes. *Cell Tissue Res* 1981; 217: 259–266.
 141. Johnson L, Petty CS, Neaves WB. Influence of age on sperm production and testicular weights in men. *J Reprod Fertil* 1984; 70: 211–218.
 142. Bockers TM, Nieschlag E, Kreutz MR, et al. Localization of follicle-stimulating hormone (FSH) immunoreactivity and hormone receptor mRNA in testicular tissue of infertile men. *Cell Tissue Res* 1994; 278: 595–600.
 143. Simoni M, Weinbauer GF, Gromoll J, et al. Role of FSH in male gonadal function. *Ann Endocrinol* 1999; 60: 102–106.
 144. Suarez-Quian CA, Martínez-García F, Nistal M, et al. Androgen receptor distribution in adult human testis. *J Clin Endocrinol Metab* 1999; 84: 350–358.
 145. Lejeune H, Skalli M, Chatelain PG, et al. The paracrine role of Sertoli cells on Leydig cell function. *Cell Biol Toxicol* 1992; 8: 73–83.
 146. Petrie RG, Morales CR. Receptor-mediated endocytosis of testicular transferrin by germinal cells of the rat testis. *Cell Tissue Res* 1992; 267: 45–55.
 147. Anderson RA, Sharpe RM. Regulation of inhibin production in the human male and its clinical applications. *Int J Androl* 2000; 23: 136–144.
 148. Khan SA, Schmidt K, Hallin P, et al. Human testis cytosol an ovarian

- follicular fluid contain high amounts of interleukin-1-like factor(s). *Mol Cell Endocrinol* 1988; 58: 221–230.
149. Parvinen M, Vihko KK, Toppari J. Cell interactions during the seminiferous epithelial cycle. *Int Rev Cytol* 1986; 104: 115–151.
 150. Paniagua R, Nistal M, Amat P, et al. Quantitative differences between variants of A spermatogonia in man. *J Reprod Fertil* 1986; 77: 669–673.
 151. Rowley MJ, Berlin JD, Heller CG. The ultrastructure of the four types of human spermatogonia. *Zeitschr Zellforsch* 1971; 112: 139–157.
 152. Nistal M, Codesal J, Paniagua R, et al. Decrease in the number of Ap and Ad spermatogonia and the Ap/Ad ratio with advancing age. *J Androl* 1987; 8: 64–68.
 153. Paniagua R, Codesal J, Nistal M, et al. Quantification of cell types throughout the cycle of the human seminiferous epithelium and their DNA content. *Anat Embryol* 1987; 176: 225–230.
 154. Schulze W. Normal and abnormal spermatogonia in the human testis. *Fortschr Androl* 1981; 7: 33–45.
 155. Nistal M, Paniagua R, Esponda E. Development of the endoplasmic reticulum during human spermatogenesis. *Acta Anat* 1980; 108: 238–249.
 156. Heller CG, Clermont Y. Kinetics of the germinal epithelium in man. *Recent Prog Hormone Res* 1964; 20: 545–571.
 157. Holstein AF, Roosen-Runge EC. Atlas of human spermatogenesis. Berlin: Grosse-Verlag, 1981.
 158. De Kretser DM. Ultrastructural features of human spermiogenesis. *Zeitschr Zellforsch* 1969; 98: 477–505.
 159. Fawcett DW, Anderson WA, Phillips DM. Morphogenetic factors influencing the shape of the sperm head. *Dev Biol* 1971; 26: 220–251.
 160. Fawcett DW, Phillips DM. The fine structure and development of the neck region of the mammalian spermatozoon. *Anat Rec* 1969; 165: 153–184.
 161. Bruecker H, Shafe E, Holstein AF. Morphogenesis and fate of the residual body in human spermiogenesis. *Cell Tissue Res* 1985; 240: 303–309.
 162. Chemes M. The phagocytic function of Sertoli cells. A morphological, biochemical, and endocrinological study of lysosomes and acid phosphatase localization in the rat testis. *Endocrinology* 1986; 119: 1673–1686.
 163. Clermont Y. Renewal of spermatogonia in man. *Am J Anat* 1966; 118: 509–524.
 164. Holstein AF. Ultrastructural observations on the differentiation of spermatids in man. *Andrologia* 1976; 8: 157–165.
 165. Dym M, Fawcett DW. Further observations on the numbers of spermatogonia, spermatocytes and spermatids connected by intercellular bridges in the mammalian testis. *Biol Reprod* 1971; 4: 195–215.
 166. Schulze W. Evidence of a wave of spermatogenesis in the human testis. *Andrologia* 1982; 14: 200–207.
 167. Schulze W, Reimer M, Rehder V, et al. Computeraided three-dimensional reconstructions of the arrangement of primary spermatocytes in human seminiferous tubules. *Cell Tissue Res* 1986; 244: 1–8.
 168. Clermont Y. The cycle of the seminiferous epithelium in man. *Am J Anat* 1963; 2: 35–51.
 169. Ueno H, Mori H. Morphometrical analysis of Sertoli cell ultrastructure during the seminiferous epithelial cycle in rats. *Biol Reprod* 1990; 43: 769–776.
 170. Grandjean V, Sage J, Ranc F, et al. Stage-specific signals in germ line differentiation control of Sertoli cell phagocytic activity by spermatogenic cells. *Dev Biol* 1997; 184: 165–174.
 171. Paniagua R, Rodriguez MC, Nistal M, et al. Changes in the lipid inclusions/Sertoli cell cytoplasm area ratio during the cycle of the Sertoli cell of the human seminiferous epithelium. *J Reprod Fertil* 1987; 80: 335–341.
 172. Griswold MD. Interaction between germ cells and Sertoli cells in the testis. *Biol Reprod* 1995; 52: 211–216.
 173. Bartke A. Apoptosis of male germ cells, a generalized or a cell type-specific phenomenon? *Endocrinology* 1995; 136: 3–4.
 174. Bustos-Obrégón E. Ultrastructure and function of the lamina propria of mammalian seminiferous tubules. *Andrologia* 1976; 8: 179–185.
 175. De Kretser DM, Kerr JB, Paulsen CA. The peritubular tissue in the normal and pathological human testis: an ultrastructural study. *Biol Reprod* 1975; 12: 317–324.
 176. Dym M. Basement membrane regulation of Sertoli cells. *Endocrinol Rev* 1994; 15: 102–115.
 177. Christl HW. The lamina propria of vertebrate seminiferous tubules: A comparative light and electron microscopic investigation. *Andrologia* 1990; 22: 85–94.
 178. Ross MH, Long IR. Contractile cells in human seminiferous tubules. *Science* 1986; 153: 1271–1273.
 179. Virtanen I, Kalliojoki M, Narvanen O. Peritubular myoid cells of human and rat testis are smooth muscle cells that contain desmin-type intermediate filaments. *Anat Rec* 1986; 215: 10–20.
 180. De Menezes AP. Elastic tissue in the limiting membrane of the human seminiferous tubules. *Am J Anat* 1977; 150: 349–374.
 181. Gabbiani G. The biology of myofibroblasts. *Kidney Int* 1992; 41: 530–532.
 182. Miyake K, Yamamoto M, Narita H, et al. Evidence for contractility of the human seminiferous tubule confirmed by its response to noradrenaline and acetylcholine. *Fertil Steril* 1986; 46: 734–737.
 183. Johnson L, Petty CS, Neaves WB. Age-related variations in seminiferous tubules in men. A stereologic evaluation. *J Androl* 1986; 7: 316–322.
 184. Kuroda N, Nakayama H, Miyazaki E, et al. Distribution and role of CD34-positive stromal cells and myofibroblasts in human normal testicular stroma. *Histol Histopathol* 2004; 19: 743–751.
 185. Nelson AA. Giant interstitial cells and extraparenchymal interstitial cells of the human testis. *Am J Pathol* 1938; 14: 831–841.
 186. Okkels M, Sand K. Morphological relationship between testicular nerves and Leydig cells in man. *J Endocrinol* 1940; 2: 38–49.
 187. Schulze C. Sertoli cells and Leydig cells in man. *Adv Anat Embryol Cell Biol* 1984; 88: 1–104.
 188. Paniagua R, Amat P, Nistal M, et al. Ultrastructure of Leydig cells in human ageins testes. *J Anat* 1986; 146: 173–183.
 189. Schulze W, Davidoff MS, Ivell R, et al. Neuron-specific enolase-like immunoreactivity in human Leydig cells. *Andrologia* 1991; 23: 279–283.
 190. Ivell R, Balvers M, Domagalski R, et al. Relaxin-like factor: a highly specific and constitutive new marker for Leydig cells in the human testis. *Mol Hum Reprod* 1997; 3: 459–466.
 191. Barreiro ML, Tena-Sempere M. Ghrelin and reproduction: a novel signal linking energy status and fertility. *Mol Cell Endocrinol* 2004; 226: 1–9.
 192. Foresta C, Bettella A, Vinanzi C, et al. A novel circulating hormone of testis origin in humans. *J Clin Endocrinol Metab* 2004; 89: 5952–5958.
 193. Strauss KI, Isaacs KR, Ha QN, Jacobowitz DM. Calretinin is expressed in the Leydig cells of rat testis. *Biochim Biophys Acta* 1994; 1219: 435–440.
 194. Movahedi-Lankarani S, Kurman RJ. Calretinin, a more sensitive but less specific marker than α -inhibin for ovarian sex cord-stromal neoplasms: an immunohistochemical study of 215 cases. *Am J Surg Pathol* 2002; 26: 1477–1483.
 195. Holash JA, Harik SI, Perry G, Stewart PA. Barrier properties of testis microvessels. *Proc Natl Acad Sci USA* 1993; 90: 11069–11073.
 196. Davidoff MS, Schulze W, Middendorff R, et al. The Leydig cell of the human testis – a new member of the diffuse neuroendocrine system. *Cell Tissue Res* 1993; 271: 429–439.

197. Davidoff MS, Middendorff R, Pusch W, et al. Sertoli and Leydig cells of the human testis express neurofilament triplet proteins. *Histochem Cell Biol* 1999; 111: 173–187.
198. Chemes H, Cigorruga S, Bergada C, et al. Isolation of human Leydig cell mesenchymal precursors from patients with the androgen insensitivity syndrome: testosterone production and response to human chorionic gonadotropin stimulation in culture. *Biol Reprod* 1992; 46: 793–801.
199. Davidoff MS, Middendorff R, Enikolopov G, et al. Progenitor cells of the testosterone-producing Leydig cells revealed. *Cell Biol* 2004; 167: 935–944.
200. Kaler LW, Neaves WB. Attrition of the human Leydig cell population with advancing age. *Anat Rec* 1978; 192: 513–518.
201. Kothari LK, Gupta AS. Effect of ageing on the volume, structure and total Leydig cell content of human testis. *Int J Fertil* 1974; 19: 140–146.
202. Mori H, Hiromoto N, Nakahara M, et al. Stereological analysis of Leydig cell ultrastructure in aged humans. *J Clin Endocrinol Metab* 1982; 55: 634–641.
203. Nistal M, Santamaría L, Paniagua R, et al. Multinucleate Leydig cells in normal human testes. *Andrologia* 1986; 18: 268–272.
204. Amat P, Paniagua R, Nistal M, et al. Mitosis in adult human Leydig cells. *Cell Tissue Res* 1986; 243: 219–221.
205. Neaves WB, Johnson L, Porter JC, et al. Leydig cell numbers, daily sperm production and serum gonadotropin levels in ageing men. *J Clin Endocrinol Metab* 1984; 55: 756–763.
206. Neaves WB, Johnson L, Petty CS. Age-related change in numbers of other interstitial cells in testes of adult men: evidence bearing on the fate of Leydig cells lost with increasing age. *Biol Reprod* 1985; 33: 259–269.
207. Sharpe RM, Maddocks S, Millar M, et al. Testosterone and spermatogenesis. Identification of stage-specific, androgen-regulated proteins secreted by adult rat seminiferous tubules. *J Androl* 1992; 13: 172–184.
208. Parvinen M. Regulation of the seminiferous epithelium. *Endocrinol Rev* 1982; 3: 404–417.
209. Paniagua R, Rodríguez MC, Nistal M, et al. Changes in surface area and number of Leydig cells in relation to the 6 stages of the cycle of the human seminiferous epithelium. *Anat Embryol* 1988; 178: 423–427.
210. Anthony CT, Rosselli M, Skinner MK. Actions of the testicular paracrine factor (P-Mod-S) on Sertoli cell transferrin secretion throughout pubertal development. *Endocrinology* 1991; 129: 353–360.
211. Norton JN, Skinner MK. Regulation of Sertoli cell function and differentiation through the actions of a testicular paracrine factor P-Mod-S. *Endocrinology* 1989; 124: 2711–2719.
212. Skinner MK. Cell–cell interactions in the testis. *Endocrinol Rev* 1991; 12: 45–77.
213. Middendorff R, Müller D, Wichers S, et al. Evidence for production and functional activity of nitric oxide in seminiferous tubules and blood vessels of the human testis. *J Clin Endocrinol Metab* 1997; 82: 4154–4161.
214. Prince FP. Ultrastructural evidence of indirect and direct autonomic innervation of human Leydig cells. Comparison of neonatal, childhood and pubertal ages. *Cell Tissue Res* 1992; 269: 383–390.
215. Nistal M, Paniagua R. Leydig cell differentiation induced by stimulation with HCG and HMG in two patients affected with hypogonadotropic hypogonadism. *Andrologia* 1979; 11: 211–222.
216. Miller SC, Bowman BM, Rowland HG. Structure, cytochemistry, endocytic activity, and immunoglobulin (Fc) receptors of rat testicular interstitial-tissue macrophages. *Am J Anat* 1983; 168: 1–13.
217. Hutson JC. Changes in the concentration and size of testicular macrophages during development. *Biol Reprod* 1990; 43: 885–890.
218. Hutson JC. Testicular macrophages. *Int Rev Cytol* 1994; 149: 99–143.
219. Jonsson CK, Setchell BP, Martinelle N, et al. Endotoxin-induced interleukin 1 expression in testicular macrophages is accompanied by downregulation of the constitutive expression in Sertoli cells. *Cytokine* 2001; 14: 283–288.
220. Gaytan F, Romero JL, Morales C, et al. Response of testicular macrophages to EDS-induced Leydig cell death. *Andrologia* 1995; 27: 259–65.
221. Afane M, Dubost J-J, Sauvezie B, et al. Modulation of Leydig cell testosterone production by secretory products of macrophages. *Andrologia* 1998; 30: 71–78.
222. Lukyanenko Y, Chen JJ, Hutson JC. Testosterone regulates 25-hydroxycholesterol production in testicular macrophages. *Biol Reprod* 2002; 67: 1435–1438.
223. Mayerhofer A, Frungieri MB, Fritz S, et al. Evidence for catecholaminergic, neuron-like cells in the adult human testis: changes associated with testicular pathologies. *J Androl* 1999; 20: 341–347.
224. Maseki Y, Mikaye K, Mitsuya H, et al. Mastocytosis occurring in testes from patients with idiopathic male infertility. *Fertil Steril* 1981; 36: 814–817.
225. Jarow JP, Ogle A, Kaspar J, Hopkins M. Testicular artery ramification within the inguinal canal. *J Urol* 1992; 147: 1290–1292.
226. Kormano M, Suoranta H. Microvascular organization of the adult human testes. *Anat Rec* 1971; 170: 31–40.
227. Suoranta M. Changes in the small blood vessels of the adult human testis in relation to age and to some pathological conditions. *Virchows Arch A [Pathol Anat]* 1971; 352: 165–181.
228. Takayama H, Tomoyoshi T. Microvascular architecture of rat and human testes. *Invest Urol* 1981; 18: 341–344.
229. Suzuki F, Nagano T. Microvasculature of the human testis and excurrent duct system. Resin-casting and scanning electron-microscopic studies. *Cell Tissue Res* 1986; 243: 79–89.
230. Ergun S, Davidoff M, Holstein AF. Capillaries in the lamina propria of human seminiferous tubules are partly fenestrated. *Cell Tissue Res* 1996; 286: 93–102.
231. Holstein AF, Orlandini GE, Moller R. Distribution and fine structure of the lymphatic system in the human testis. *Cell Tissue Res* 1979; 200: 15–27.
232. Nistal M, Paniagua R, Abaurrea MA. Varicose axons bearing ‘synaptic’ vesicles on the basal lamina of the human seminiferous tubules. *Cell Tissue Res* 1982; 226: 75–82.
233. Santamaría L, Reoyo A, Regadera J, et al. Histochemistry and ultrastructure of nerve fibres and contractile cells in the tunica albuginea of the rat testis. *Acta Anat* 1990; 139: 126–133.
234. Jonte G, Holstein AF. On the morphology of the transitional zones from the rete testis into the ductuli efferentes and from the ductuli efferentes into the ductus epididymidis investigations on the human testis and epididymis. *Andrologia* 1978; 19: 398–412.
235. Dinges HP, Zatloukal K, Schmid C, et al. Co-expression of cytokeratin and vimentin filaments in rete testis and epididymis. An immunohistochemical study. *Virchows Archiv A [Pathol Anat]* 1991; 418: 119–127.
236. Kogan SJ. Cryptorchidism. In: Kelalis PP, King LR, Belman AB, eds. *Clinical pediatric urology*, 2nd edn. Vol 2. Philadelphia: WB Saunders, 1985; 864.
237. Oesch I, Ransley PG. Unilaterally palpable testis. *Eur Urol* 1987; 13: 324–325.
238. Levitt SB, Kogan SJ, Schnider KM, et al. Endocrine tests in phenotypic children with bilateral palpable testes can reliably predict ‘congenital’ anorchism. *Urology* 1978; 11: 11–17.
239. Aynsley-Green A, Zachmann M, Illig R, Prader A. Congenital bilateral anorchia in childhood: a clinical

- endocrine and therapeutic evaluation of twenty-one cases. *Clin Endocrinol* 1976; 5: 381–391.
240. Rivarola MA, Bergada C, Cullen M. HCG stimulation test in prepubertal boys with cryptorchidism, in bilateral anorchia and in male pseudohermaphroditism. *J Clin Endocrinol Metab* 1970; 31: 526–530.
241. Jarow JP, Berkovitz GD, Migeon CJ, et al. Elevation of serum gonadotropins establishes the diagnosis of anorchism in prepubertal boys with bilateral cryptorchidism. *J Urol* 1986; 136: 277–279.
242. Koff SA. Does compensatory testicular enlargement predict monorchism? *J Urol* 1991; 146: 632–633.
243. Huff DS, Snyder HM, Hadziselimovic F, et al. An absent testis is associated with contralateral testicular hypertrophy. *J Urol* 1992; 148: 627–628.
244. Brothers LR, Weber CH, Ball TP. Anorchismus versus cryptorchidism; the importance of a diligent search for intra-abdominal testes. *J Urol* 1971; 119: 207–209.
245. Plotzker ED, Rushton HG, Belman AB, et al. Laparoscopy for nonpalpable testes in childhood: Is inguinal exploration also necessary when vas and vessels exit the inguinal ring? *J Urol* 1992; 148: 635–638.
246. Edman CD, Winter AJ, Porter JC, et al. Embryonic testicular regression: a clinical spectrum of XY agonalad individuals. *Obstet Gynecol* 1977; 2: 208–217.
247. Coulam CB. Testicular regression syndrome. *Obstet Gynecol* 1979; 53: 44–49.
248. Maciel-Guerra AT, Farah SB, Garmes HM, et al. True agonaladism: report of a case analyzed with Y-specific DNA probes. *Am J Med Genet* 1991; 41: 444–445.
249. Devriendt K, Deloof E, Moerman P, et al. Diaphragmatic hernia in Denys-Drash syndrome. *Am J Med Genet* 1995; 57: 97–101.
250. Manouvrier-Hanu S, Besson R, Cousin L, et al. Sex reversal and diaphragmatic hernia in phenotypically female sibs with normal XY chromosomes. *J Med Genet* 2000; 37: 315–318.
251. Zenteno JC, Jimenez AL, Canto P, et al. Clinical expression and SRY gene analysis in XY subjects lacking gonadal tissue. *Am J Med Genet* 2001; 99: 244–247.
252. Macayran JF, Doroshov RW, Phillips J, et al. PAGOD syndrome: eighth case and comparison to animal models of congenital vitamin A deficiency. *Am J Med Genet* 2002; 108: 229–234.
253. Kennerknecht I, Sorgo W, Oberhoffer R, et al. Familial occurrence of agonaladism and multiple internal malformations in phenotypically normal girls with 46,XY and 46,XX karyotypes, respectively: a new autosomal recessive syndrome. *Am J Med Genet* 1993; 47: 1166–1170.
254. Silengo M, Del Monaco A, Linari A, Lala R. Low birth-weight, microcephalic malformation syndrome in a 46,XX girl and her 46,XY sister with agonaladism: third report of the Kennerknecht syndrome or autosomal recessive Seckel-like syndrome with previously undescribed genital anomalies. *Am J Med Genet* 2001; 101: 275–278.
255. Kushnick T, Wiley JE, Palmer SM. Agonaladism in a 46,XY patient with CHARGE association. *Am J Med Genet* 1992; 42: 96–99.
256. Najjar SS, Takla RJ, Nassar VH. The syndrome of rudimentary testes: occurrence in live siblings. *J Pediatr* 1974; 84: 119–122.
257. Glass AR. Identical twins discordant for the 'rudimentary testes' syndrome. *J Urol* 1982; 127: 140–141.
258. Acquafredda A, Vassal J, Job JC. Rudimentary testes syndrome revisited. *Paediatrics* 1987; 2: 209–214.
259. Tzvetkov D, Tzvetkova P, Kanchev L. Congenital anorchism: diagnostic and therapeutic aspects. *Arch Androl* 1994; 32: 243–249.
260. De Rosa M, Lupoli G, Mennitti M, et al. Congenital bilateral anorchia: clinical, hormonal and imaging study in 12 cases. *Andrologia* 1996; 28: 281–285.
261. Lobaccaro JM, Medlej R, Berta P, et al. PCR analysis and sequencing of the SRY sex determining gene in four patients with bilateral congenital anorchia. *Clin Endocrinol* 1993; 38: 197–201.
262. Parigi GB, Bardoni B, Avoltini V, et al. Is bilateral congenital anorchia genetically determined? *Eur J Pediatr Surg* 1999; 9: 312–315.
263. Tosi SE, Morin LS. The vanishing testis syndrome. Indications for conservative therapy. *J Urol* 1976; 115: 758.
264. Sparnon A, Guiney EJ, Puri P. The vanishing testis. *Pediatr Surg Int* 1986; 1: 227–228.
265. Abeyaratne MR, Aherne WA, Scott JES. The vanishing testis. *Lancet* 1969; 2: 822–824.
266. Belman AB, Rushton HG. Is the vanished testis always a scrotal event? *BJU Int* 2001; 87: 480–483.
267. Simpson JL, Horwith M, Morrillo-Cucci G. Bilateral anorchia: discordance in monozygotic twins. *Birth Defects* 1971; 7: 196–200.
268. Vinci G, Anjot MN, Trivin C, et al. An analysis of the genetic factors involved in testicular descent in a cohort of 14 male patients with anorchia. *J Clin Endocrinol Metab* 2004; 89: 6282–6285.
269. Amelar RD. Anorchism without eunuchoidism. *J Urol* 1956; 76: 174.
270. Honoré M. Unilateral anorchism. Report of 11 cases with discussion of etiology and pathogenesis. *Urology* 1978; 11: 251–254.
271. Nistal M, Paniagua R, Regadera J, et al. Hyperplasia of spermatic cord nerves: a sign of testicular absence. *Urology* 1987; 29: 411–415.
272. Salle B, Hedinger C, Nicole R. Significance of testicular biopsies in cryptorchidism in children. *Acta Endocrinol* 1968; 58: 67–76.
273. Kogan SJ, Gill B, Bennett B, et al. Human monorchism: A clinicopathological study of unilateral absent testes in 65 boys. *J Urol* 1986; 135: 758–761.
274. Smith NM, Byard RW, Bourne AJ. Testicular regression syndrome a pathological study of 77 cases. *Histopathology* 1991; 19: 269–272.
275. Spires SE, Woolums CS, Pulito AR, Spires SM. Testicular regression syndrome: a clinical and pathologic study of 11 cases. *Arch Pathol Lab Med* 2000; 124: 694–698.
276. Grady RW, Mitchell ME, Carr MC. Laparoscopic and histologic evaluation of the inguinal vanishing testis. *Urology* 1998; 52: 866–869.
277. Cendron M, Schned AR, Ellsworth PL. Histological evaluation of the testicular nubbin in the vanishing testis syndrome. *J Urol* 1998; 160: 1161–1163.
278. Das S, Amar AD. Ureteral ectopia into cystic seminal vesicle with ipsilateral renal dysgenesis and monorchia. *J Urol* 1980; 124: 574–575.
279. Matsuoka LY, Wortsman J, McConnachie P. Renal and testicular agenesis in a patient with Darier's disease. *Am J Med* 1985; 78: 873–877.
280. König MP. Findings: small testicles. *Schweiz Med Wschr* 1987; 117: 731–735.
281. Margery J, Le Berre JP, Bredin C, et al. Klinefelter's syndrome diagnosed three years after surgery for mediastinal teratoma. *Presse Med* 2005; 34: 1078–1079.
282. Hoffman WH, Kovacs K, Li S, et al. Kenny-Caffey syndrome and microorchidism. *Am J Med Genet* 1998; 80: 107–111.
283. Thum G. Polyorchidism: case report and review of literature. *J Urol* 1991; 145: 370–372.
284. Oner AY, Sahin C, Poca S, Kizilkaya E. Polyorchidism: sonographic and magnetic resonance image findings. *Acta Radiol* 2005; 46: 769–771.
285. Ahlfeld F. Die Missbildungen des Menschen. Leipzig: Grunow, 1880; 126–127.
286. Lane WA. A case of supernumerary testis. *Trans Clin Soc Lond* 1895; 28: 59–60.

287. Khetan N, Torkington J, Jamison MH. Polyorchidism presenting as retractile testes. *BJU Int* 1999; 83: 524.
288. Baker LL, Hajek PC, Burkhard TK, et al. Polyorchidism: evaluation by MR. *AJR Am J Roentgenol* 1987; 148: 305–307.
289. Singh A, Sobti MK. Polyorchidism. *Br J Urol* 1988; 61: 458–459.
290. Snow BW, Tarry WF, Duckett JW. Polyorchidism: An unusual case. *J Urol* 1985; 133: 483–484.
291. Spranger R, Gunst M, Kühn M. Polyorchidism: a strange anomaly with unsuspected properties. *J Urol* 2002; 168: 198.
292. Deveci S, Aygun C, Agildere AM, Ozkardes H. Bilateral double by testis: evaluation magnetic resonance imaging. *Int J Urol* 2004; 11: 813–815.
293. Day GH. One man with five testes: report of case. *JAMA* 1918; 71: 2055–2057.
294. Hakami M, Mosavy SH. Triorchidism with normal spermatogenesis: an unusual cause for failure of vasectomy. *Br J Surg* 1975; 62: 633.
295. Yenyol CO, Nergiz N, Tuna A. Abdominal polyorchidism: a case report and review of the literature. *Int Urol Nephrol* 2004; 36: 407–408.
296. Giyanani VL, McCarthy J, Venable DD, et al. Ultrasound of polyorchidism: Case report and literature review. *J Urol* 1987; 138: 863–864.
297. Hancock RA, Hodgins TE. Polyorchidism. *Urology* 1984; 24: 303–307.
298. Abbasoglu L, Salman FF, Gun F, Asicioglu C. Polyorchidism presenting with undescended testis. *Eur J Pediatr Surg* 2004; 14: 355–357.
299. Chung T-J, Yao W-J. Sonographic features of polyorchidism. *J Clin Ultrasound* 2002; 30: 106–108.
300. Pelander WM, Luna G, Lilly JR. Polyorchidism: Case report and literature review. *J Urol* 1978; 119: 705–706.
301. Gandia VM, Arrizabalaga M, Leiva O, et al. Polyorchidism discovered as testicular torsion associated with undescended atrophic contralateral testis. A surgical solution. *J Urol* 1987; 137: 743–744.
302. Verdú TF, Pérez-Bustamante I, Jiménez CM. Poliorquia. Revisión y aportación de un nuevo caso. *Actas Urol Esp* 1986; 10: 277–278.
303. Feldman S, Drach GW. Polyorchidism discovered as testicular torsion. *J Urol* 1983; 130: 976–977.
304. Khan C. Polyorchidism with normal spermatogenesis. *Br J Urol* 1988; 61: 100–103.
305. Smart RH. Polyorchidism with normal spermatogenesis. *J Urol* 1972; 107: 278.
306. Nocks BN. Polyorchidism with normal spermatogenesis and equal sized testes. A theory of embryonal development. *J Urol* 1978; 120: 638–640.
307. Garat JM, Marina S, Sole-Balcells F, et al. Polyorchidie. *J d'Urol* 1981; 87: 175–176.
308. Mallafré JM, Janeiro MR, Corominas S, et al. Testículo supernumerario. Comunicación de un caso y revisión de la literatura. *Arch Esp Urol* 1989; 42: 166–168.
309. Al-Hibbal Z, Izzidien AY. Polyorchidism: case report and review of the literature. *J Pediatr Surg* 1984; 19: 212–214.
310. Darrow RP, Humes JJ. Polyorchidism: a case report. *J Urol* 1954; 72: 53–54.
311. Thiessen NW. Polyorchidism: report of a case. *J Urol* 1943; 49: 710–711.
312. Nistal M, Paniagua R, Martín-Lopez R. Polyorchidism in a newborn: case report and review of the literature. *Pediatr Pathol* 1990; 10: 601–607.
313. Holland AJ. Polyorchidism: A case report and review of the literature. *J Pediatr Surg* 2005; 40: 1219.
314. Grechi G, Zampi GC, Selli C, et al. Polyorchidism and seminoma in a child. *J Urol* 1980; 123: 291–292.
315. Scott KW. A case of polyorchidism with testicular teratoma. *J Urol* 1980; 124: 930–932.
316. Takihara H, Consentino MJ, Sakatoku J, et al. Significance of testicular size measurement in andrology. II Correlation of testicular size with testicular function. *J Urol* 1987; 137: 416–418.
317. Nistal M, González-Peramato P, Paniagua R. Congenital Leydig cell hyperplasia. *Histopathology* 1988; 12: 307–317.
318. Huff DS, Wu HY, Snyder H, et al. Evidence in favor of the mechanical (intrauterine torsion) theory over the endocrinopathy (cryptorchidism) theory in the pathogenesis of testicular agenesis. *J Urol* 1991; 146: 630–631.
319. Laron Z, Zilka E. Compensatory hypertrophy of testicle in unilateral cryptorchidism. *J Clin Endocrinol Metab* 1969; 29: 1409–1413.
320. Ku JH, Son H, Kwak C, et al. Impact of varicocele on testicular volume in young men: significance of compensatory hypertrophy of contralateral testis. *J Urol* 2002; 168: 1541–1544.
321. Laron Z, Dickerman Z, Prager-Lewin R, et al. Plasma LH and FSH response to LRH in boys with compensatory testicular hypertrophy. *J Clin Endocrinol Metab* 1975; 40: 977–981.
322. Laron Z, Dickerman Z, Ritterman I, et al. Followup of boys with unilateral compensatory testicular hypertrophy. *Fertil Steril* 1980; 33: 297–300.
323. Zachman M, Prader A, Kind HP, et al. Testicular volume during adolescence. *Helv Paediatr Acta* 1974; 29: 61–72.
324. Lee PA, Marshall FF, Greco JM, et al. Unilateral testicular hypertrophy: An apparently benign occurrence without cryptorchidism. *J Urol* 1982; 127: 329–331.
325. Nisula BC, Loriaux DL, Sherins RJ, et al. Benign bilateral testicular enlargement. *J Clin Endocrinol Metab* 1974; 38: 440–445.
326. Breen DH, Braunstein GD, Neufeld N, et al. Benign macroorchidism in a pubescent boy. *J Urol* 1981; 125: 589–591.
327. Truwit CHL, Jackson M, Thompson IM. Idiopathic macroorchidism. *J Clin Ultrasound* 1989; 17: 200–205.
328. Nistal M, Martínez-García F, Regadera J, et al. Macro-orchidism: light and electron microscopic study of four cases. *Hum Pathol* 1992; 23: 1011–1018.
329. Somuncu S, Cakmak M, Caglayan F, et al. Idiopathic benign bilateral testicular enlargement in a pubertal boy: a case report and review of literature. *J Pediatr Surg* 2005; 40: 23–25.
330. Alvarez-Acevedo Garcia M, Molina Rodriguez MA, Gonzalez Casado I, et al. Macroorchidism: a case report. *An Pediatr* 2006; 64: 89–92.
331. Meschede D, Behre HM, Nieschlag E. Endocrine and spermatological characteristics of 135 patients with bilateral megalotestis. *Andrologia* 1995; 27: 207–212.
332. Van Esch H. The Fragile X premutation: new insights and clinical consequences. *Eur J Med Genet* 2006; 49: 1–8.
333. Lubs HA. A marker X chromosome. *A J Hum Genet* 1969; 21: 231–234.
334. Martin JP, Bell J. A pedigree of mental defect showing sex-linkage. *J Neurol Psychiatr* 1943; 6: 154–157.
335. Turner G, Eastman C, Casey J, et al. X-linked mental retardation associated with macroorchidism. *J Med Genet* 1975; 12: 367–371.
336. Cantú JM, Scaglia HE, González-Didi M, et al. Inherited congenital normofunctional testicular hyperplasia and mental deficiency. A corroborative study. *Hum Genet* 1975; 12: 367–371.
337. Ruvalcaba RHA, Myhre SA, Roosen-Runge EC, et al. X-linked mental deficiency megalotestis syndrome. *JAMA* 1977; 238: 1646–1650.
338. Sutherland GR, Ashforth PLC. X-linked mental retardation with macroorchidism and the fragile site at Xq 27 or 28. *Hum Genet* 1979; 48: 117–120.
339. Howard-Peebles PN, Stoddard GR. Familial-X-linked mental retardation with a marker X chromosome and its relationship to macroorchidism. *Clin Genet* 1980; 17: 125–128.
340. Hecht JT, Moore CM, Scott CI. A recognizable syndrome of sex-linked mental retardation, large testes and

- marker X chromosome. *South Med J* 1981; 74: 1493–1495.
341. Berkowitz GD, Wilson DP, Carpenter NJ, et al. Gonadal function in men with the Martin-Bell (fragile X) syndrome. *Am J Med Genet* 1986; 23: 227–239.
342. Johannisson R, Rehder H, Wendt V, et al. Spermatogenesis in two patients with the fragile X syndrome. I. Histology: light and electron microscopy. *Hum Genet* 1987; 76: 141–147.
343. Johannisson R, Froster-Iskenius U, Saadallah N, et al. Spermatogenesis in two patients with the fragile X syndrome. *Hum Genet* 1988; 79: 231–234.
344. Gerald PS. X-linked mental retardation and an X-chromosome marker. *N Engl J Med* 1980; 303: 696–697.
345. Webb TP, Bunday SE, Thake AI, et al. Population incidence and segregation ratios in Martin-Bell syndrome. *Am J Hum Genet* 1986; 23: 573–580.
346. Vuelckel MA, Philip N, Piquet C, et al. Study of a family with a fragile site of the X chromosome at Xq 27–28 without mental retardation. *Hum Genet* 1989; 81: 353–357.
347. Rudelli RD, Jenkins EC, Wisniewski K, et al. Testicular size in fetal fragile X syndrome. *Lancet* 1983; 1: 1221–1222.
348. Johnson JP, Nelson R, Schwartz CE. A family with mental retardation, variable macrocephaly and macroorchidism, and linkage to Xq12-q21. *J Med Genet* 1998; 35: 1026–1030.
349. Heseltine D, White MC, Kendall-Taylor P, et al. Testicular enlargement and elevated serum inhibin concentrations occur in patients with pituitary macroadenomas secreting follicle stimulating hormone. *Clin Endocrinol* 1989; 31: 411–423.
350. Laron Z, Karp M, Dolberg L. Juvenile hypothyroidism with testicular enlargement. *Acta Paediatr Scand* 1970; 59: 317–322.
351. Cordero GL, Gracia R, Nistal M, et al. Hipotiroidismo y maduración testicular precoz. *Rev Clin Esp* 1973; 128: 83–88.
352. Hannini EA, Ulisse S, D'Armiendo M. Thyroid hormone and male gonadal function. *Endocrinol Rev* 1995; 16: 443–459.
353. Barnes ND, Hayles AB, Ryan RJ. Sexual maturation in juvenile hypothyroidism. *Mayo Clin Proc* 1973; 48: 849–856.
354. Castro-Magana M, Angulo M, Canas A, et al. Hypothalamic-pituitary gonadal axis in boys with primary hypothyroidism and macroorchidism. *J Pediatr* 1988; 112: 397–402.
355. Maran RR. Thyroid hormones: their role in testicular steroidogenesis. *Arch Androl* 2003; 49: 375–388.
356. De La Balze F, Arrillaga F, Mancini RE, et al. Male hypogonadism in hypothyroidism: A study of six cases. *J Clin Endocrinol Metab* 1962; 22: 212–222.
357. Hoffman WH, Kovacs KT, Gala RR, et al. Macroorchidism and testicular fibrosis associated with autoimmune thyroiditis. *J Endocrinol Invest* 1991; 14: 609–616.
358. Franks RC, Stempfel RS. Juvenile hypothyroidism and precocious testicular maturation. *J Clin Endocrinol Metab* 1963; 23: 805–810.
359. Hopwood NJ, Lockhart LH, Bryan GT. Acquired hypothyroidism with muscular hypertrophy and precocious testicular enlargement. *J Pediatr* 1974; 85: 233–236.
360. Wierman ME, Bruder JM, Kepa JK. Regulation of gonadotropin-releasing hormone (GnRH) gene expression in hypothalamic neuronal cells. *Cell Mol Neurobiol* 1995; 15: 79–88.
361. Bruder JM, Samuels MH, Bremner WJ, et al. Hypothyroidism-induced macroorchidism: Use of a gonadotropin-hormone agonist to understand its mechanism and augment adult stature. *J Clin Endocrinol* 1995; *Metab* 80: 11–16.
362. Anasti JN, Flack MR, Froehlich J, et al. A potential novel mechanism for precocious puberty in juvenile hypothyroidism. *J Clin Endocrinol Metab* 1995; 80: 276–279.
363. Van Haaster LH, De Jong FH, Docter R, De Rooij DG. High neonatal triiodothyronine levels reduce the period of Sertoli cell proliferation and accelerate tubular lumen formation in the rat testis, and increase serum inhibin levels. *Endocrinology* 1993; 133: 755–760.
364. Simorangkir DR, De Kretser DM, Wreford NG. Increased numbers of Sertoli and germ cells in adult rat testes induced by synergistic action of transient neonatal hypothyroidism and neonatal hemicaststration. *J Reprod Fertil* 1995; 104: 207–213.
365. Palmero S, Prati M, Bolla F, Fugassa E. Tri-iodothyronine directly affects rat Sertoli cell proliferation and differentiation. *J Endocrinol* 1995; 145: 355–362.
366. De Franca LR, Hess RA, Cooke PS, Russell LD. Neonatal hypothyroidism causes delayed Sertoli cell maturation in rats treated with propylthiouracil: evidence that the Sertoli cell controls testis growth. *Anat Rec* 1995; 242: 57–69.
367. Lee PA. Central precocious puberty. An overview of diagnosis, treatment, and outcome. *Endocrinol Metab Clin North Am* 1999; 28: 901–918.
368. Colaco P. Precocious puberty. *Indian J Pediatr* 1997; 64: 165–175.
369. Cloutier MD, Hayles AB. Precocious puberty. *Adv Pediatr* 1970; 17: 125–138.
370. Bierich JR. Sexual precocity. *Clin Endocrinol Metab* 1975; 4: 107–142.
371. Brauner R, Pierre-Kahn A, Nemedysandor E, et al. Precocious puberty caused by a suprasellar arachnoid cyst. Analysis of 6 cases. *Arch Fr Pediatr* 1987; 44: 489–493.
372. Mohn A, Schoof E, Fahlbusch R, et al. The endocrine spectrum of arachnoid cysts in childhood. *Pediatr Neurosurg* 1999; 31: 316–321.
373. Adan L, Bussieres L, Dinand V, et al. Growth, puberty and hypothalamic-pituitary function in children with suprasellar arachnoid cyst. *Eur J Pediatr* 2000; 159: 348–355.
374. Bovier-Lapierre M, Sempe M, David M. Aspects étiologiques cliniques et biologiques des pubertés précoces d'origine centrale. *Pediatric* 1972; 27: 587–609.
375. Shaul PW, Towbin RB, Chernausek SD. Precocious puberty following severe head trauma. *Am J Dis Child* 1985; 139: 467–469.
376. Sockalosky JJ, Kriel RL, Krach LE, Sheehan M. Precocious puberty after traumatic brain injury. *J Pediatr* 110: 373–377, 1987.
377. Morello A, Porcaro S, Lima J, Impallaria P. Endocrine disorder as the only sign of chronic 'non-hypertensive' hydrocephalus. *J Neurosurg Sci* 2002; 46: 81–84.
378. Brauner R, Czernichow P, Rappaport R. Precocious puberty after hypothalamic and pituitary irradiation in young children. *N Engl J Med* 1984; 311: 920.
379. Leiper AD, Stanhope R, Kitching P, Chessells JM. Precocious and premature puberty associated with treatment of acute lymphoblastic leukaemia. *Arch Dis Child* 1987; 62: 1107–1112.
380. Cacciari E, Zucchini S, Carla G, et al. Endocrine function and morphological findings in patients with disorders of the hypothalamo-pituitary area: a study with magnetic resonance. *Arch Dis Child* 1990; 65: 1191–1202.
381. Fahmy JL, Kaminsky CK, Kaufman F, et al. The radiological approach to precocious puberty. *Br J Radiol* 2000; 73: 560–567.
382. Shah P, Patkar D, Patankar T, et al. MR imaging features in hypothalamic hamartoma: a report of three cases and review of literature. *J Postgrad Med* 1999; 45: 84–86.
383. Feuillan PP, Jones JV, Barnes KM, et al. Boys with precocious puberty due to hypothalamic hamartoma: reproductive axis after discontinuation of gonadotropin-releasing hormone analog therapy. *J Clin Endocrinol Metab* 2000; 85: 4036–4038.
384. De Sanctis V, Corrias A, Rizzo V, et al. Etiology of central precocious puberty in males: the results of the Italian Study Group for Physiopathology of Puberty. *J Pediatr Endocrinol Metab* 2000; 13: 687–693.
385. Judge DM, Kulin HE, Page R, et al. Hypothalamic hamartoma: a source

- of luteinizing-hormone-releasing factor in precocious puberty. *N Engl J Med* 1977; 296: 7–10.
386. Tandon N, Chopra R, Ghoshal S, et al. Mixed germ cell tumour of the pineal region: a case report. *Neurol India* 1999; 47: 321–323.
387. Nogueira K, Liberman B, Pimentel-Filho FR, et al. hCG-secreting pineal teratoma causing precocious puberty: report of two patients and review of the literature. *J Pediatr Endocrinol Metab* 2002; 15: 1195–1201.
388. Wierman ME, Beardsworth DE, Mansfield MJ. Puberty without gonadotropins: A unique mechanism of sexual development. *N Engl J Med* 1985; 312: 65–72.
389. Rosenthal SM, Grumbach MM, Kaplan SL. Gonadotropin-independent familial sexual precocity with premature Leydig and germinal cell maturation (familial testotoxicosis): Effects of a patent luteinizing hormone-releasing factor agonist and metoxyprogesterone acetate therapy in four cases. *J Clin Endocrinol Metab* 1983; 57: 571–579.
390. Gondos B, Egli CA, Rosenthal SM, Grumbach MM. Testicular changes in gonadotropin-independent familial male sexual precocity. Familial testotoxicosis. *Arch Pathol Lab Med* 1985; 109: 990–995.
391. Latronico AC, Shinozaki H, Guerra G Jr, et al. Gonadotropin-independent precocious puberty due to luteinizing hormone receptor mutations in Brazilian boys: A novel constitutively activating mutation in the first transmembrane helix. *J Clin Endocrinol Metab* 2000; 85: 4799–4805.
392. Soriano-Guillen L, Mitchell V, Carel JC, et al. Activating mutations in the LH receptor gene: a human model of non FSH-dependent inhibin production and germ cell maturation. *J Clin Endocrinol Metab* 2006; 91: 3041–3047.
393. Canto P, Soderlund D, Ramon G, et al. Mutational analysis of the luteinizing hormone receptor gene in two individuals with Leydig cell tumors. *Am J Med Genet* 2002; 108: 148–152.
394. Gracia R, Nistal M, Gallego ME, et al. Tumor de células de Leydig con pseudopubertad precoz. *An Esp Pediatr* 1980; 13: 593–598.
395. Polepalle SK, Shabaik A, Alagiri M. Leydig cell tumor in a child with spermatocyte maturation and no pseudoprecocious puberty. *Urology* 2003; 62: 55 1–55, vii.
396. Coen P, Kulin H, Ballantine T, et al. An aromatase-producing sex-cord tumor resulting in prepubertal gynecomastia. *N Engl J Med* 1991; 324: 317–322.
397. Ros P, Nistal M, Alonso M, et al. Sertoli cell tumour in a boy with Peutz–Jeghers syndrome. *Histopathology* 1999; 34: 84–86.
398. Carney JA. Carney complex: the complex of mixomas, spotty pigmentation, endocrine overactivity, and schwannomas. *Semin Dermatol* 1995; 14: 90–98.
399. Bonfig W, Bittmann I, Bechtold S, et al. Virilising adrenal cortical tumours in children. *Eur J Pediatr* 2003; 162: 623–628.
400. Drago JR, Olstein JS, Tesluk H, et al. Virilizing adrenal cortical carcinoma with hypertrophy of spermatic tubules in childhood. *Urology* 1979; 14: 70–75.
401. Cunnah D, Perry L, Dacie JA, et al. Bilateral testicular tumours in congenital adrenal hyperplasia: A continuing diagnostic and therapeutic dilemma. *Clin Endocrinol* 1989; 30: 141–147.
402. Heimann A, White PF, Riely CA, et al. Hepatoblastoma presenting as isosexual precocity. The clinical importance of histologic and serologic parameters. *J Clin Gastroenterol* 1987; 9: 105–110.
403. Cohgen AR, Wilson JA, Sadeghi-Nejad A. Gonadotropin-secreting pineal teratoma causing precocious puberty. *Neurosurgery* 1991; 28: 597–602.
404. Nebert DW, Nelson DR, Adesnik M, et al. The P450 gene superfamily: updated listing of all genes and recommended nomenclature for the chromosomal loci. *DNA* 1989; 8: 1–13.
405. Chen SA, Besman MJ, Sparkes RS, et al. Human aromatase: cDNA cloning, Southern blot analysis, and assignment of the gene to chromosome 15. *DNA* 1988; 7: 27–38.
406. Martin RM, Lin CJ, Nishi MY, et al. Familial hyperestrogenism in both sexes: clinical, hormonal, and molecular studies of two siblings. *J Clin Endocrinol Metab* 2003; 88: 3027–3034.
407. Stratakis CA, Vottero A, Brodie A, et al. The aromatase excess syndrome is associated with feminization of both sexes and autosomal dominant transmission of aberrant P450 aromatase gene transcription. *J Clin Endocrinol Metab* 1998; 83: 1348–1357.
408. Deladoëy J, Flück C, Bex M, et al. Aromatase deficiency caused by a novel P450arom gene mutation: impact of absent estrogen production on serum gonadotropin concentration in a boy. *J Clin Endocrinol Metab* 1999; 84: 4050–4054.
409. Morishima A, Grumbach MM, Simpson ER, et al. Aromatase deficiency in male and female siblings caused by a novel mutation and the physiological role of estrogens. *J Clin Endocrinol Metab* 1995; 80: 3689–3698.
410. Carani C, Qin K, Simoni M, et al. Effect of testosterone and estradiol in a man with aromatase deficiency. *N Engl J Med* 1997; 337: 91–95.
411. Grumbach MM, Auchus RJ. Estrogen: consequences and implications of human mutations in synthesis and action. *J Clin Endocrinol Metab* 1999; 84: 4677–4694.
412. Wilson BE, Netzloff ML. Primary testicular abnormalities causing precocious puberty Leydig cell tumor, Leydig cell hyperplasia, and adrenal rest tumor. *Ann Clin Lab Sci* 1983; 13: 315–320.
413. Leung AC, Kogan SJ. Focal lobular spermatogenesis and pubertal acceleration associated with ipsilateral Leydig cell hyperplasia. *Urology* 2000; 56: 508–509.
414. Arrigo T, Pirazzoli P, De Sanctis L, et al. McCune–Albright syndrome in a boy may present with a monolateral macroorchidism as an early and isolated clinical manifestation. *Hormone Res* 2006; 65: 114–119.
415. Coutant R, Lumbroso S, Rey R, et al. Macroorchidism due to autonomous hyperfunction of Sertoli cells and G(s)alpha gene mutation: an unusual expression of McCune–Albright syndrome in a prepubertal boy. *J Clin Endocrinol Metab* 2001; 86: 1778–1781.
416. Giovannelli G, Bernasconi S, Banchini G. McCune–Albright syndrome in a male child: A clinical and endocrinologic enigma. *J Pediatr* 1978; 92: 220–226.
417. Campbell MF. Anomalies of the testicle. In: Campbell MF, Harrison JH, eds. *Urology*, 3rd edn. Philadelphia: WB Saunders, 1970; 1632.
418. Dieckmann KP, Düe W, Fiedler U. Perineale Hodenektomie. *Urologe (A)* 1988; 27: 358–362.
419. Murphy DM, Butler MR. Preperitoneal ectopic testis: a case report. *J Pediatr Surg* 1985; 20: 93–94.
420. Paramo PG, Nacarino L, Polo G. Ectopia epidídimo-perineal. *Arch Esp Urol* 1971; 24: 61–63.
421. Tramoyeres A, Esteve J, Fernández A, et al. Testículo ectópico perineal. *Arch Esp Urol* 1980; 33: 357.
422. Wattenberg CA, Rape MG, Beare JB. Perineal testicle. *J Urol* 1949; 62: 858–861.
423. Oludiran OO, Sakpa CL. Crossed ectopic testis: a case report and review of the literature. *Pediatr Surg Int* 2005; 21: 672–673.
424. Doraiswamy NV. Crossed ectopic testis. Case report and review. *Zeitschr Kinder Chir* 1983; 38: 264–268.
425. Fujita J. Transverse testicular ectopia. *Urology* 16: 400–402, 1980.
426. Miura T, Takahashi G. Crossed ectopic testis with common vas deferens. *J Urol* 1985; 134: 1206–1208.

427. Gornall PG, Pender DJ. Crossed testicular ectopia detected by laparoscopy. *Br J Urol* 1987; 59: 283.
428. Peters JH, Sing S. Transverse testicular ectopia: a case report. *Del Med* 1987; J 59: 333-335.
429. Beasley SW, Auldust AW. Crossed testicular ectopia in association with double incomplete testicular descent. *Aust NZ J Surg* 1985; 55: 301-303.
430. Dogruyol H, Özcan M, Balkan E. Two rare genital abnormalities: Crossed testicular and scrototesticular ectopia. *Br J Urol* 1992; 70: 201-203.
431. Tiryaki T, Hucumenoglu S, Atayurt H. Transverse testicular ectopia associated with persistent Müllerian duct syndrome. A case report. *Urol Int* 2005; 74: 190-192.
432. Josso N, Picard JY, Imbeaud S, et al. The persistent müllerian duct syndrome: a rare cause of cryptorchidism. *Eur J Pediatr* 1993; 152: S76-S78.
433. Manassero F, Cuttano MG, Morelli G, et al. Mixed germ cell tumor after bilateral orchidopexy in persistent Müllerian duct syndrome with transverse testicular ectopia. *Urol Int* 2004; 73: 81-83.
434. Middleton GW, Beamon CR, Guillenwater JY. Two rare cases of ectopic testes. *J Urol* 1976; 115: 445-446.
435. Gaur DD, Purohit KC, Joshi AS, et al. Subumbilical ectopic testis, *BJU Int* 1999; 84: 887.
436. Heyns CF. Exstrophy of the testis. *J Urol* 1990; 144: 724-725.
437. O'Donnell C, Kumar U, Kiely EA. Testicular dislocation after scrotal trauma. *Br J Urol* 1998; 82: 768.
438. Leissring JC, Oppenheimer ROF. Cystic dysplasia of the testis: a unique anomaly studied by microdissection. *J Urol* 1973; 110: 362-363.
439. Kajo K, Matoska J, Javorka K, et al. Cystic dysplasia of the rete testis. Case report. *APMIS* 2005; 113: 720-723.
440. Nanni L, Buonuomo V, Gessi M, et al. Cystic dysplasia of the rete testis associated to cryptorchidism: a case report. *Arch Ital Urol Androl* 2005; 77: 199-201.
441. Cho CS, Kosek J. Cystic dysplasia of the testis: sonographic and pathologic findings. *Radiology* 1985; 156: 777-778.
442. Garrett JE, Cartwright PC, Snow BW, et al. Cystic testicular lesions in the pediatric population. *J Urol* 2000; 163: 928-936.
443. Roosen-Runge EC, Holstein AF. The human rete testis. *Cell Tissue Res* 1978; 189: 409-433.
444. Bustos-Obregón E, Holstein AF. The rete testis in man: Ultrastructural aspects. *Cell Tissue Res* 1976; 175: 1-15.
445. Dym M. The mammalian rete testis. A morphological examination. *Anat Rec* 1976; 186: 493-524.
446. Nistal M, Regadera J, Paniagua R. Cystic displasia of the testis: light and electron microscopic study of three cases. *Arch Pathol Lab Med* 1984; 108: 579-583.
447. Robson WL, Thomason MA, Minette LJ. Cystic dysplasia of the testis associated with multicystic dysplasia of the kidney. *Urology* 1998; 51: 477-479.
448. Fischer JE, Jewett TC, Nelson ST, et al. Ectasia of the rete testis with ipsilateral renal agenesis. *J Urol* 1982; 128: 1040-1043.
449. Glantz I, Hansen K, Caldamone A, et al. Cystic dysplasia of the testis. *Hum Pathol* 1993; 24: 1141-1145.
450. Tesluk H, Blankenberg TA. Cystic dysplasia of testis. *Urology* 1987; 29: 47-49.
451. Garrett JE, Cartwright PC, Snow BW, Coffin CM. Cystic testicular lesions in the pediatric population. *J Urol* 2000; 163: 928-936.
452. Bonnet JP, Aigrain Y, Ferkadji L. Cystic dysplasia of the testis with ipsilateral renal agenesis. A case report and review of the literature. *Eur J Pediatr Surg* 1997; 7: 57-59.
453. Noh PH, Cooper CS, Snyder HM III. Conservative management of cystic dysplasia of the testis. *J Urol* 1999; 162: 2145.
454. Toffolutti T, Gamba PG, Cecchetto G, et al. Testicular cystic dysplasia: evaluation of 3 new cases treated without surgery. *J Urol* 1999; 162: 2146-2148.
455. Cimador M, Rosone G, Castagnetti M, et al. Cystic dysplasia of rete testis associated with ipsilateral renal agenesis. Case report. *Minerva Pediatr* 2003; 55: 175-179.
456. Spear GS, Martin CG. Fetal gonadoblastoid testicular dysplasia. *Hum Pathol* 1986; 17: 531-533.
457. Hung NA, Silver MM, Chitayat D, et al. Gonadoblastoid testicular dysplasia in Walker-Warburg syndrome. *Pediatr Dev Pathol* 1998; 1: 393-404.
458. Nistal M, Rodriguez JI, García-Fernandez E, et al. Fetal gonadoblastoid testicular dysplasia: a focal failure of testicular development. *Pediatr Dev Pathol* 2007 (in press).
459. Hedinger CE, Huber R, Weber E. Frequency of so-called hypoplastic or dysgenetic zones in scrotal and otherwise normal testes. *Virchows Arch [Pathol Anat Physiol Klin Med]* 1967; 342: 165-168.
460. Regadera J, Martínez-García F, González-Peramato P, et al. Androgen receptor expression in Sertoli cells as a function of seminiferous tubule maturation in the human cryptorchid testis. *J Clin Endocrinol Metab* 2001; 86: 413-421.
461. Nistal M, Paniagua R. Congenital testicular lymphangiectasis. *Virchows Arch A [Pathol Anat Histol]* 1977; 377: 79-84.
462. Nistal M, Paniagua R, Bravo MP. Congenital testicular lymphangiectasis in Noonan's syndrome. *J Urol* 1984; 131: 759-761.
463. Nistal M, Garcia-Rojo M, Paniagua R. Congenital testicular lymphangiectasis in children with otherwise normal testes. *Histopathology* 1990; 17: 335-338.
464. Ostroverkhova V G. Macro-microscopischeskoe is sledavanie vnutriorgannoi limfaticheskoi sistemy muzhskoi polovozi zhelezy [Macro/microscopic study of intraorgan lymphatic system of male gonad in man]. *Arch Anat Gist Embriol* 1960; 39: 59-65.
465. Holstein AF, Orlandini GE, Moller R. Distribution and fine structure of the lymphatic system in the human testis. *Cell Tissue Res* 1979; 200: 15-27.
466. Fawcett DW, Heidger PM, Leak LV. Lymph vascular system of the interstitial tissue of the testis as revealed by electron microscopy. *J Reprod Fertil* 1969; 19: 109-119.
467. Kaido M, Iwai S, Ide Y, et al. Epididymal lymphangiectasis. *J Urol* 1993; 150: 1251-1252.
468. Srigley JR, Hartwick RWJ. Tumors and cysts of the paratesticular region. *Pathol Annu* 1990; 25: 51-108.
469. Fridman E, Skarda J, Ofek-Moravsky E, Cordoba M. Complex multilocular cystic lesion of rete testis, accompanied by smooth muscle hyperplasia, mimicking intratesticular Leydig cell neoplasm. *Virchows Arch* 2005; 447: 768-771.
470. Barton JH, Davis CJ Jr, Sesterhenn IA, et al. Smooth muscle hyperplasia of the testicular adnexa clinically mimicking neoplasia. Clinicopathologic study of sixteen cases. *Am J Surg Pathol* 1999; 23: 903-909.
471. Tanaka N, Seya T, Onda M, et al. Myoepithelial hamartoma of the small bowel: report of a case. *Surg Today* 1996; 26: 1010-1013.
472. Benisch BM, Wood WG, Kroeger GB, et al. Focal muscular hyperplasia of the trachea. *Arch Otolaryngol* 1974; 99: 226-227.
473. Nistal M, Paniagua R, León L, et al. Ectopic seminiferous tubules in the tunica albuginea of normal and dysgenetic testes. *Appl Pathol* 1985; 3: 123-128.
474. Schmidt SS, Minckler TM. Pseudocysts of the tunica albuginea: Benign invasion by testicular tubules. *J Urol* 1987; 138: 151.
475. Nistal M, Paniagua R. Development of the testis from birth to puberty. In: Nistal M, Paniagua R, eds. *Testicular and epididymal pathology*. New York: Thieme-Stratton, 1984; 14-25.

476. Regadera J, Cobo O, Martínez-García C, et al. Testosterone immunoexpression in human Leydig cells of the tunica albuginea testis and spermatic cord. A quantitative study in normal fetuses, young adults, elderly men and patients with cryptorchidism. *Andrologia* 1993; 25: 115–122.
477. Nelson AA. Giant interstitial cells and extraparenchymal interstitial cells of the human testis. *Am J Pathol* 1938; 14: 831–841.
478. Halley JBW. The infiltrative activity of Leydig cells. *J Pathol Bacteriol* 1961; 81: 347–353.
479. Halley JBW. Relation of Leydig cells in the human testicle to the tubules and testicular function. *Nature* 1960; 185: 865–866.
480. McDonald JH, Calams JA. A histological study of extraparenchymal Leydig-like cells. *J Urol* 1958; 79: 850–858.
481. Berbingler H. Über die Zwischenzellen des Hodens. *Verh D Path Ges* 1921; 18: 186–197.
482. Brack E. Zur pathologischen Anatomie der Leydig Zelle. *Virchows Arch [Pathol Anat Physiol]* 1923; 240: 127–143.
483. Schulze C, Holstein AF. Leydig cells within the lamina propria of seminiferous tubules in four patients with azoospermia. *Andrologia* 1978; 10: 444–452.
484. Mori H, Shiraishi T, Matsumoto K. Ectopic Leydig cells in seminiferous tubules of an infertile human male with a chromosomal aberration. *Andrologia* 1978; 10: 434–443.
485. Mori H, Tamai M, Fushimi H, et al. Leydig cells within the spermatogenic seminiferous tubules. *Hum Pathol* 1987; 18: 1227–1231.
486. Regadera J, Codesal J, Paniagua R, et al. Immunohistochemical and quantitative study of interstitial and intratubular Leydig cells in normal men, cryptorchidism, and Klinefelter's syndrome. *J Pathol* 1991; 164: 299–306.
487. Priesel A. Über das Verhalten von Hoden und Nebenhoden bei angeborenem Fehlen des Ductus deferens, zugleich zur Frage des Vorkommens von Zwischenzellen in menschliche Nebenhoden. *Virchows Arch [Pathol Anat Physiol]* 1924; 249: 246–304.
488. Berger L. Sur l'existence de glands sympathicotropes dans l'ovaire et le testicule humains; leur rapport avec la glande interstitielle du testicule. *Compt Rend Acad Sci Paris* 1922; 175: 907–909.
489. Peters KH. Zur Ultrastruktur der Leydigzellen im Funiculus spermaticus des Menschen. *Verh Anat Ges* 1977; 71: 555–559.
490. Nistal M, Paniagua R. Histogenesis of human extraparenchymal Leydig cells. *Acta Anat* 1979; 105: 188–197.
491. Lespi PJ, Gregorini SD, De Lasa AT, D'Orazio O. Osteoma testicular. Presentación de un caso y revisión de la literatura. *Patologia* 1999; 37: 289–290.
492. Woodhouse JB, Delahunt B, English SF, et al. Testicular lipomatosis in Cowden's syndrome. *Mod Pathol* 2005; 18: 1151–1156.
493. Nistal M, Garcia-Cabezas MA, Castello MC, et al. Age-related epididymis-like intratesticular structures: benign lesions of Wolffian origin that can be misdiagnosed as testicular tumors. *J Androl* 2006; 27: 79–85.
494. Storgaard L, Bonde JP, Olsen J. Male reproductive disorders in humans and prenatal indicators of estrogen exposure. A review of published epidemiological studies. *Reprod Toxicol* 2006; 21: 4–15.
495. Suetomi T, Kawai K, Sekido N, et al. Testicular cancers occurring in brothers with cryptorchism. *Int J Urol* 2002; 9: 67–70.
496. Cendron M, Huff DS, Keating MA, et al. Anatomical, morphological and volumetric analysis: a review of 759 cases of testicular maldescent. *J Urol* 1993; 149: 570–573.
497. Akre O, Lipworth L, Cnattingius S, et al. Risk factor patterns for cryptorchidism and hypospadias. *Epidemiology* 1999; 10: 364–369.
498. Hjertkvist M, Dauber JE, Berhg A. Cryptorchidism: a registry based study in Sweden on some factors of some possible etiological importance. *J Epidemiol Commun Health* 1989; 43: 324–329.
499. Berkowitz GS, Lapinski RH, Godbold JH, et al. Maternal and neonatal risk factors for cryptorchidism. *Epidemiology* 1995; 6: 127–131.
500. Weidner IS, Moller H, Jensen TK, Skakkebaek NE. Risk factors for cryptorchidism and hypospadias. *J Urol* 1999; 161: 1606–1609.
501. Hutson JM, Hasthorpe S. Abnormalities of testicular descent. *Cell Tissue Res* 2005; 322: 155–158.
502. Eardley KC, Saw KC, Whitaker RH. Surgical outcome of orchidopexy II. Trapped and ascending testes. *Br J Urol* 1994; 73: 204–206.
503. Kaplan GW. Iatrogenic cryptorchidism resulting from hernia repair. *Surg Gynecol Obstet* 1976; 142: 671–672.
504. Surana R, Puri P. Iatrogenic ascent of the testis: an under-recognized complication of inguinal hernia operation in children. *Br J Urol* 1994; 73: 580–581.
505. Colodny AH. Iatrogenic ascent of the testis: an underrecognized complication of inguinal hernia operation in children. *Br J Urol* 1994; 74: 531–532.
506. Docimo SG. Testicular descent and ascent in the first year of life. *Urology* 1996; 48: 458–460.
507. Rabinowitz R, Hulbert WC Jr. Late presentation of cryptorchidism: The etiology of testicular re-ascent. *J Urol* 1997; 157: 1892–1894.
508. Atwell JD. Ascent of the testis: fact or fiction. *Br J Urol* 1985; 57: 474–477.
509. Clarnette TD, Rowe D, Hasthorpe S, Hutson JM. Incomplete disappearance of the processus vaginalis as a cause of ascending testis. *J Urol* 1997; 157: 1889–1891.
510. Myers NA, Officer CB. Undescended testis: congenital or acquired? *Aust Paediatr J* 1975; 11: 76–80.
511. Gracia J, Navarro E, Guirado F, et al. Spontaneous ascent of the testis. *Br J Urol* 1997; 79: 113–115.
512. Schiffer KA, Kogan SJ, Reda EF, et al. Acquired undescended testis. *Am J Dis Child* 1987; 141: 106–107.
513. Shono T, Zakaria O, Imajima T, et al. Does proximal genitofemoral nerve division induce testicular maldescent or ascent in the rat? *BJU Int* 1999; 83: 323–326.
514. Konstantinos S, Alevizos A, Anargiros M, et al. Association between testicular microlithiasis, testicular cancer, cryptorchidism and history of ascending testis. *Int Braz J Urol* 2006; 32: 434–438.
515. Rusnack SL, Wu H-Y, Huff DS, et al. The ascending testis and the testis undescended since birth share the same histopathology. *J Urol* 2002; 168: 2590–2591.
516. Hadziselimovic F, Geneto R, Emmons LR. Elevated placental estradiol: a possible etiological factor of human cryptorchidism. *J Urol* 2000; 164: 1694–1695.
517. Farrington GH. Histologic observations in cryptorchidism: the congenital germinal-cell deficiency of the undescended testis. *J Pediatr Surg* 1969; 4: 606–613.
518. Nistal M, Paniagua R, Díez-Pardo JA. Histologic classification of undescended testes. *Hum Pathol* 1980; 11: 666–673.
519. Codesal J, Paniagua R, Queizán A, et al. Cytophotometric DNA quantification in human spermatogonia of cryptorchid testes. *J Urol* 1993; 149: 382–385.
520. Huff DS, Hadziselimovic F, Snyder HMC, et al. Early postnatal testicular maldevelopment in cryptorchidism. *J Urol* 1991; 146: 624–626.
521. Christiansen P, Müller J, Buhl S, et al. Hormonal treatment of cryptorchidism – hCG or GnRH – a multicentre study. *Acta Paediatr* 1992; 81: 605–608.
522. Bica DTG, Hadziselimovic F. Busereline treatment of cryptorchidism: a randomized, double-blind, placebo-controlled study. *J Urol* 1992; 148: 617–621.
523. Huff DS, Fenig DM, Canning DA, et al. Abnormal germ cell development in cryptorchidism. *Hormone Res* 2001; 55: 11–17.

524. Cendron M, Huff DS, Keating MA, et al. Anatomical, morphological and volumetric analysis: A review of 759 cases of testicular maldescent. *J Urol* 1993; 149: 570–573.
525. Nagar H, Haddad R. Impact of early orchidopexy on testicular growth. *Br J Urol* 1997; 80: 334–335.
526. Kogan S, Tennenbaum S, Gill B, et al. Efficacy of orchidopexy by patient age 1 year for cryptorchidism. *J Urol* 1990; 144: 508–509.
527. Thorup J, Cortes D, Nielsen H. Clinical and histopathologic evaluation of operated maldescented testes after luteinizing hormone-releasing hormone treatment. *Pediatr Surg Int* 1993; 8: 419–422.
528. Nistal M, Paniagua R, Riestra ML, et al. Bilateral prepubertal testicular biopsias predict significance of cryptorchidism-associated mixed testicular atrophy, and allow assessment of fertility. *Am J Surg Pathol* 2007 (in press).
529. Cortes D, Thorup J, Visfeldt J. Multinucleated spermatogonia in cryptorchid boys: a possible association with an increased risk of testicular malignancy. *APMIS* 2003; 111: 25–30.
530. Foresta C, Moro E, Garolla A, et al. Y chromosome microdeletions in cryptorchidism and idiopathic infertility. *J Clin Endocrinol Metab* 1999; 84: 3660–3665.
531. Hadziselimovic F, Snyder HM, Huff DS. An unusual subset of cryptorchidism: possible end organ failure. *J Urol* 1999; 162: 983–985.
532. Mayr J, Rune GM, Holas A, et al. Ascent of the testis in children. *Eur J Pediatr* 1995; 154: 893–895.
533. Imthurn T, Hadziselimovic F, Herzog B. Impaired germ cells in secondary cryptorchid testis after herniotomy. *J Urol* 1995; 153: 780–781.
534. Gotoh M, Miyake K, Mitsuya H. Elastic fibers in tunica propria of undescended and contralateral scrotal testes from cryptorchid patients. *Urology* 1987; 30: 359–363.
535. Nistal M, Paniagua R, Abaurrea MA, Santamaria L. Hyperplasia and the immature appearance of Sertoli cells in primary testicular disorders. *Hum Pathol* 1982; 13: 3–12.
536. Nistal M, Riestra ML, Paniagua R. Focal orchitis in undescended testes: discussion of pathogenetic mechanisms of tubular atrophy. *Arch Pathol Lab Med* 2002; 126: 64–69.
537. Atilla MK, Sargin H, Yilmaz Y, et al. Undescended testes in adults: clinical significance of resistive index values of the testicular artery measured by Doppler ultrasound as a predictor of testicular histology. *J Urol* 1997; 158: 841–843.
538. Vinardi S, Magro P, Manenti M, et al. Testicular function in men treated in childhood for undescended testes. *J Pediatr Surg* 2001; 36: 385–388.
539. Nistal M, Paniagua R, Queizán A. Histologic lesions in undescended ectopic obstructed testes. *Fertil Steril* 1985; 43: 455–462.
540. Herzog B, Steigert M, Hadziselimovic F. Is a testis located at the superficial inguinal pouch (Denis Browne pouch) comparable to a true cryptorchid testis? *J Urol* 1992; 148: 622–623.
541. Huff DS, Hadziselimovic F, Snyder HM III, et al. Histologic maldevelopment of unilaterally cryptorchid testes and their descended partners. *Eur J Pediatr* 1993; 152: S10–14.
542. Cendron M, Huff DS, Keating MA, et al. Anatomical, morphological and volumetric analysis: a review of 759 cases of testicular maldescent. *J Urol* 1993; 149: 570–573.
543. Alexandre C. Les testicules oscillants. forme dégradée de cryptorchidie? *JGynecol Obstet Biol Reprod (Paris)* 1977; 6: 71–74.
544. Nistal M, Paniagua R. Infertility in adult males with retractile testes. *Fertil Steril* 1984; 41: 395–403.
545. Ito H, Katauni Z, Kuwamura K, et al. Changes in the volume and histology of retractile testes in prepubertal boys. *Int J Androl* 1986; 9: 161–169.
546. Wyllie GW. The retractile testis. *Med J Aust* 1984; 140: 403–405.
547. Agarwal PK, Diaz M, Elder JS. Retractable testis – is it really a normal variant? *J Urol* 2006; 175: 1496–1499.
548. Puri P, Nixon HH. Bilateral retractile testes – subsequent effects on fertility. *J Pediatr Surg* 1967; 12: 563–566.
549. Caroppo E, Niederberger C, Elhanbly S, et al. Effect of cryptorchidism and retractile testes on male factor infertility: a multicenter, retrospective, chart review. *Fertil Steril* 2005; 83: 1581–1584.
550. Elder JS. Epididymal anomalies associated with hydrocele/hernia and cryptorchidism: implications regarding testicular descent. *J Urol* 1992; 148: 624–626.
551. Scorer CG, Farrington GH. Congenital deformities of the testis and epididymis, p 136. New York: Appleton-Century-Crofts, 1971.
552. Mollaeian M, Nehrabi V, Elahi V. Significance of epididymal and ductal anomalies associated with undescended testis. *Urology* 1994; 43: 857–860.
553. Ferlin A, Bogatcheva NV, Giancesello L, et al. Insulin-like factor 3 gene mutations in testicular dysgenesis syndrome: clinical and functional characterization. *Mol Hum Reprod* 2006; 12: 401–406.
554. Bay K, Asklund C, Skakkebaek NE, Andersson AM. Testicular dysgenesis syndrome: possible role of endocrine disrupters. *Best Pract Res Clin Endocrinol Metab* 2006; 20: 77–90.
555. Giwercman A, Rylander L, Hagmar L, Giwercman YL. Ethnic differences in occurrence of TDS – genetics and/or environment? *Int J Androl* 2006; 29: 291–297.
556. Nistal M, Regadera J, Winitzky P, et al. Granular changes in Sertoli cells in children and pubertal patients. *Fertil Steril* 2005; 83: 1489–99.
557. Cortes D, Visfeldt J, Thorup JM. Erythropoietin may reduce the risk of germ cell loss in boys with cryptorchidism. *Hormone Res* 2001; 55: 41–45.
558. Engeler DS, Hösli PO, John H, et al. Early orchidopexy: prepubertal intratubular germ cell neoplasia and fertility outcome. *Urology* 2000; 56: 144–148.
559. Abrat RP, Reddi VB, Sarembock LA. Testicular cancer and cryptorchidism. *Br J Urol* 1992; 70: 656–659.
560. Giwercman A, Müller J, Skakkebaek NE. Cryptorchidism and testicular neoplasia. *Hormone Res* 1988; 30: 157–163.
561. Larizza C, Antiba A, Palazzi J, et al. Testicular maldescent and infertility. *Andrologia* 1990; 22: 285–288.
562. Cortes D, Thorup J. Histology of testicular biopsies taken at operation for bilateral maldescented testes in relation to fertility in adulthood. *Brit J Urol* 68: 285–291, 1991.
563. Puri P, O'Donnell B. Semen analysis in patients operated on for impalpable testes. *Br J Urol* 1990; 66: 646–647.
564. Kogan SJ. Fertility in cryptorchidism: an overview in 1987. *Eur J Pediatr* 1987; 146: S21.
565. Lee PA, Coughlin MT, Bellinger MF. Paternity and hormone levels after unilateral cryptorchidism: association with pretreatment testicular location. *J Urol* 2000; 164: 1697–1701.
566. Lee PA, Coughlin MT, Bellinger MF. No relationship of testicular size at orchidopexy with fertility in men who previously had unilateral cryptorchidism. *J Urol* 2001; 166: 236–239.
567. Wilkerson ML, Bartone FF, Fox L, Hadziselimovic F. Fertility potential: a comparison of intra-abdominal and intracranial testes by age groups in children. *Hormone Res* 2001; 55: 18–20.
568. Okuyama A, Nonomure N, Nakamura M, et al. Surgical management of undescended testis: retrospective study of potential fertility in 274 cases. *J Urol* 1989; 142: 749–751.
569. Cendron M, Keating MA, Huff DS, et al. Cryptorchidism, orchidopexy and infertility: a critical long-term retrospective analysis. *J Urol* 1989; 142: 559–562.
570. Hadziselimovic F, Zivkovic D, Bica DT, Emmons LR. The importance of mini-puberty for fertility in cryptorchidism. *J Urol* 2005; 174: 1536–1539.
571. Cortes D, Thorup JM, Visfeldt J. Cryptorchidism: aspects of fertility

- and neoplasms. A study including data of 1,335 consecutive boys who underwent testicular biopsy simultaneously with surgery for cryptorchidism. *Hormone Res* 2001; 55: 21–27.
572. Pedersen KV, Boisen P, Zetterlund CG. Experience of screening for carcinoma-in-situ of the testis among young men with surgically corrected maldescended testes. *Int J Androl* 1987; 10: 181–185.
573. Berthelsen JC, Sakakkebaek NE. Distribution of carcinoma-in-situ in testes from infertile men. *Int J Androl* 1981; 4: 172–184.
574. Giwercman A, Clausen OPE, Skakkebaek NE. Carcinoma-in-situ of the testis: aneuploid cells in semen. *Br Med J* 1988; 296: 1762–1764.
575. Giwercman A, Müller J, Skakkebaek NE. Cryptorchidism and testicular neoplasia. *Hormone Res* 1988; 30: 157–163.
576. Smith SW, Brammer HM, Henry M, et al. Testicular microlithiasis: sonographic features with pathologic correlation. *AJR Am J Roentgenol* 1991; 157: 1003–1004.
577. Kwan DJ, Kirsch AJ, Chang DT, et al. Testicular microlithiasis in a child with torsion of the appendix testis. *J Urol* 1995; 153: 183–184.
578. Mullins TL, Sant GR, Ucci AA Jr, Doherty JF. Testicular microlithiasis occurring in a postorchidopexy testis. *Urology* 1986; 27: 144–146.
579. Ikinge U, Wuster K, Terwey B, Mohring K. Microcalcifications in testicular malignancy: diagnostic tool in occult tumor? *Urology* 1982; 19: 525–528.
580. Schantz A, Milsten R. Testicular microlithiasis with sterility. *Fertil Steril* 1976; 27: 801–805.
581. Sasagawa I, Nakada T, Kazama T, et al. Testicular microlithiasis in male infertility. *Urol Int* 1988; 43: 368–369.
582. Gonzalez Sanchez FJ, Encinas Gaspar MB, Napal Lecumberri S. Microlithiasis testicular asociada a infertilidad. *Arch Esp Urol* 1997; 50: 71–74.
583. Duchek M, Bergh A, Oberg L. Painful testicular lithiasis. *Scand J Urol Nephrol* 1991; 138: 231–233.
584. Jara Rascon J, Escribano Patino G, Herranz Amo F, et al. Testicular microlithiasis: diagnosis associated with orchialgia. *Arch Esp Urol* 1998; 51: 82–85.
585. Moran JM, Moreno F, Climent V, Nistal M. Idiopathic testicular microlithiasis. Ultrastructural study. *Br J Urol* 1993; 72: 252–253.
586. Skyrme RJ, Fenn NJ, Jones AR, et al. Testicular microlithiasis in a UK population: its incidence, associations and follow-up. *BJU Int* 2000; 86: 482–485.
587. Ganem JP, Workman KR, Shaban SF. Testicular microlithiasis is associated with testicular pathology. *Urology* 1999; 53: 209–213.
588. Berger A, Brabrand K. Testicular microlithiasis – a possibly premalignant condition. Report of five cases and a review of the literature. *Acta Radiol* 1998; 39: 583–586.
589. Peterson AC, Bauman JM, Light DE, et al. The prevalence of testicular microlithiasis in an asymptomatic population of men 18 to 35 years old. *J Urol* 2001; 166: 2061–2064.
590. Cast JE, Nelson WM, Early AS, et al. Testicular microlithiasis: prevalence and tumor risk in a population referred for scrotal sonography. *Am J Roentgenol* 2000; 175: 1703–1706.
591. Miller FN, Rosairo S, Clarke JL, et al. Testicular calcification and microlithiasis: association with primary intra-testicular malignancy in 3,477 patients. *Eur Radiol* 2007; 17: 363–369.
592. Derogee M, Bevers RF, Prins HJ, et al. Testicular microlithiasis, a premalignant condition: prevalence, histopathologic findings, and relation to testicular tumor. *Urology* 2001; 57: 1133–1137.
593. Mazzilli F, Delfino M, Imbrogno N, et al. Seminal profile of subjects with testicular microlithiasis and testicular calcifications. *Fertil Steril* 2005; 84: 243–245.
594. De Gouveia Brazao CA, Pierik FH, Oosterhuis JW, et al. Bilateral testicular microlithiasis predicts the presence of the precursor of testicular germ cell tumors in subfertile men. *J Urol* 2004; 171: 158–160.
595. Nicolas F, Dubois R, Laboure S, et al. Testicular microlithiasis and cryptorchidism: ultrasound analysis after orchidopexy. *Prog Urol* 2001; 11: 357–361.
596. Miller RL, Wissman R, White S, Ragosin R. Testicular microlithiasis. a benign condition with a malignant association. *J Clin Ultrasound* 1996; 24: 197–202.
597. Rashid HH, Cos LR, Weinberg E, et al. Testicular microlithiasis: a review and its association with testicular cancer. *Urol Oncol* 2004; 22: 285–289.
598. Arrigo T, Messina MF, Valenzise M, et al. Testicular microlithiasis heralding mixed germ cell tumor of the testis in a boy. *J Endocrinol Invest* 2006; 29: 82–85.
599. Zastrow S, Hakenberg OW, Wirth MP. Significance of testicular microlithiasis. *Urol Int* 2005; 75: 3–7.
600. Drut R. Yolk sac tumor and testicular microlithiasis. *Pediatr Pathol Mol Med* 2003; 22: 343–347.
601. Leenen AS, Riebel TW. Testicular microlithiasis in children: sonographic features and clinical implications. *Pediatr Radiol* 2002; 32: 575–579.
602. Smith GD, Steele I, Barnes RB, Levine LA. Identification of seminiferous tubule aberrations and a low incidence of testicular microliths associated with the development of azoospermia. *Fertil Steril* 1999; 72: 467–471.
603. De Jong BW, De Gouveia Brazao CA, Stoop H, et al. Raman spectroscopic analysis identifies testicular microlithiasis as intratubular hydroxyapatite. *J Urol* 2004; 171: 92–96.
604. Priebe CJ, Garret R. Testicular calcification in a 4-year-old boy. *Pediatrics* 1970; 46: 785–789.
605. Nistal M, Martinez-Garcia C, Paniagua R. The origin of testicular microliths. *Int J Androl* 1995; 18: 221–229.
606. Nistal M, Paniagua R, Díez-Pardo JA. Testicular microlithiasis in 2 children with bilateral cryptorchidism. *J Urol* 1979; 121: 535–537.
607. Coetzee T. Pulmonary alveolar microlithiasis with involvement of the sympathetic nervous system and gonads. *Thorax* 1970; 25: 637–642.
608. Wegner HE, Hubotter A, Andresen R, Miller K. Testicular microlithiasis and concomitant testicular intraepithelial neoplasia. *Int Urol Nephrol* 1998; 30: 313–315.
609. Holm M, Høi-Hansen CE, Rajpert-De Meyts E, Skakkebaek NE. Increased risk of carcinoma in situ in patients with testicular germ cell cancer with ultrasonic microlithiasis in the contralateral testicle. *J Urol* 2003; 170: 1163–1167.
610. Winter TC III, Zunkel DE, Mack LA. Testicular carcinoma in a patient with previously demonstrated testicular microlithiasis. *J Urol* 1996; 155: 648.
611. Frush DP, Kliever MA, Madden JF. Testicular microlithiasis and subsequent development of metastatic germ cell tumor. *Am J Roentgenol* 1996; 167: 889–890.
612. Gooding GAW. Detection of testicular microlithiasis by sonography. *Am J Roentgenol* 1997; 168: 281–282.
613. Golash A, Parker J, Ennis O, et al. The interval of development of testicular carcinoma in a patient with previously demonstrated testicular microlithiasis. *J Urol* 2000; 163: 239.
614. Høi-Hansen CE, Sommer P, Meyts ER, et al. A rare diagnosis: testicular dysgenesis with carcinoma in situ detected in a patient with ultrasonic microlithiasis. *Asian J Androl* 2005; 7: 445–447.
615. Ravichandran S, Smith R, Cornford PA, Fordham MV. Surveillance of testicular microlithiasis? Results of an UK based national questionnaire survey. *BMC Urol* 2006; 6: 8.
616. Bennett HF, Middleton WD, Bullock AD, Teefey SA. Testicular microlithiasis: US follow-up. *Radiology* 2001; 218: 359–363.
617. Parra BL, Venable DD, Gonzalez E, et al. Testicular microlithiasis as a predictor of intratubular germ cell

- neoplasia. *Urology* 1996; 48: 797–799.
618. Nistal M, García-Cabezas MA, Regadera J, Castillo MC. Microlithiasis of the epididymis and the rete testis. *Am J Surg Pathol* 2004; 28: 514–522.
619. Scherer G, Held M, Erde L M, et al. Three novel SRY mutations in XY gonadal dysgenesis and the enigma of XY dysgenesis cases without SRY mutations. *Cytogenetic Cell Genet* 1998; 80: 188–192.
620. Bilbao JR, Loidan L, Castaño J. A novel postzygotic nonsense mutation in SRY in familial XY gonadal dysgenesis. *Hum Genet* 1996; 97: 537–539.
621. Tagliarini EB, Assumpcao JG, Scolfaro MR, et al. Mutations in SRY and WT1 genes required for gonadal development are not responsible for XY partial gonadal dysgenesis. *Braz J Med Res* 2005; 38: 17–25.
622. Vilain E, Jaubert F, Fellous M, et al. Pathology of 46,XY pure gonadal dysgenesis: absence of testis differentiation associated with mutations in the testis-determining factor. *Differentiation* 1993; 52: 151–159.
623. Simpson JL, Blagowidow N, Martin AO. XY gonadal dysgenesis: Genetic heterogeneity based upon clinical observations, H-Y antigen status and segregations analysis. *Hum Genet* 1981; 58: 91–97.
624. Simpson JL, Chaganti RSK, Mouradian J, German J. Chronic renal disease, myotonic dystrophy, and gonadoblastoma in XY gonadal dysgenesis. *J Med Genet* 1982; 19: 73–76.
625. Harkins PG, Haning RV Jr, Shapiro SS. Renal failure with XY gonadal dysgenesis: Report of the second case. *Obstet Gynecol* 1980; 56: 751–752.
626. Haning RV, Chesney RW, Moorthy AV, Gilbert EF. A syndrome of chronic renal failure and XY gonadal dysgenesis in young phenotypic females without genital ambiguity. *Am J Kidney Dis* 1985; 6: 40–48.
627. Machin GA. Atypical presentation of Denys-Drash syndrome in a female with a novel WT1 gene mutation. *Birth Defects* 1996; 30: 269–286.
628. Perez de Nanclares G, Castaño L, Bilbao JR, et al. Molecular analysis of Frasier syndrome: mutation in the WT1 gene in a girl with gonadal dysgenesis and nephronophthisis. *J Pediatr Endocrinol Metab* 2002; 15: 1047–1050.
629. Zugor V, Zenker M, Schrott KM, Schott GE. Frasier syndrome: a rare syndrome with WT1 gene mutation in pediatric urology. *Aktuelle Urol* 2006; 37: 64–66.
630. Hoffman RP, Steele MW, Lee PA, et al. 46,XY siblings with inadequate virilization and CNS deficiency. *Hormone Res* 1988; 29: 207–210.
631. Schipper JA, Delemarre-vd Waal HA, Hansen M, Sprangers MAJ. Testicular dysgenesis and mental retardation in two incompletely masculinized XY-siblings. *Acta Paediatr Scand* 1991; 80: 125–128.
632. Tsutsumi O, Iida T, Nakahori Y, Taketani Y. Analysis of the testis-determining gene SRY in patients with XY gonadal dysgenesis. *Hormone Res* 46 1996; 46 (Suppl 1): 6–10.
633. Greenberg F, Gresik MV, Carpenter RJ, et al. The Gardner–Silengo–Wachtel or genitor–palato–cardiac syndrome: Male pseudohermaphroditism with micrognathia, cleft palate, and conotruncal cardiac defects. *Am J Med Genet* 1987; 26: 59–64.
634. Angle B, Hersh JH, Yen F, Verdi GD. XY gonadal dysgenesis associated with a multiple pterygium syndrome phenotype. *Am J Med Genet* 1997; 68: 7–11.
635. Kawamura M, Owada M, Kimura Y, et al. 46,XY pure gonadal dysgenesis: a case with Graves' disease. *Intern Med* 2001; 40: 740–743.
636. Tanwani LK, Chudgar D, Murphree SS, et al. A case of gonadal dysgenesis, breast development, Graves' disease, and low bone mass. *Endocrinol Pract* 2003; 9: 220–224.
637. El-Shanti H, Ahmad M, Ajlouni K. Alopecia universalis congenita, XY gonadal dysgenesis and laryngomalacia: a novel malformation syndrome. *Eur J Pediatr* 2003; 162: 36–40.
638. Teebi AS, Dupuis L, Wherrett D, et al. Alopecia congenita universalis, microcephaly, cutis marmorata, short stature and XY gonadal dysgenesis: variable expression of El-Shanti syndrome. *Eur J Pediatr* 2004; 163: 170–172.
639. Neri G, Opitz J. Syndromal (and nonsyndromal) forms of male pseudohermaphroditism. *Am J Med Genet* 1999; 89: 201–209.
640. Kempe A, Engels H, Schubert R, et al. Familial ovarian dysgerminomas (Swyer syndrome) in females associated with 46 XY-karyotype. *Gynecol Endocrinol* 2002; 6: 107–111.
641. Brosnan PG, Lewandowski RC, Toguri AG, et al. A new familial syndrome of 46 XY gonadal dysgenesis with anomalies of ectodermal and mesodermal structural. *J Pediatr* 1980; 97: 586–590.
642. Sternberg WH, Barclay DL, Klopfer HW. Familial XY gonadal dysgenesis. *N Engl J Med* 1968; 278: 695–700.
643. Chemke J, Carmichael R, Stewart JM, et al. Familial XY gonadal dysgenesis. *J Med Genet* 1970; 7: 105–111.
644. Simpson JL, Blagowidow N, Martin AO. XY gonadal dysgenesis: Genetic heterogeneity based upon clinical observations, H-Y antigen status and segregations analysis. *Hum Genet* 1981; 58: 91–97.
645. Mann JR, Corkery JJ, Fisher HJW, et al. The X linked recessive form of XY gonadal dysgenesis with high incidence of gonadal cell tumors: Clinical and genetic studies. *J Med Genet* 1983; 20: 264–270.
646. Simpson JL, Photopoulos G. The relationship of neoplasia to disorders of abnormal sexual differentiation. *Birth Defects* 1976; 12: 15–50.
647. Le Caignec C, Baron S, McElreavey K, et al. 46,XY gonadal dysgenesis: evidence for autosomal dominant transmission in a large kindred. *Am J Med Genet* 2003; 116A: 37–43.
648. Hoepffner W, Horn LC, Simon E, et al. Gonadoblastomas in 5 patients with 46XY gonadal dysgenesis. *Exp Clin Endocrinol Diabetes* 2005; 113: 231–235.
649. Portuondo JA, Neyro JL, Benito JA, et al. Familial 46,XX gonadal dysgenesis. *Int J Fertil* 1987; 32: 56–58.
650. Marrakchi A, Belhaj L, Boussouf H, et al. Pure gonadal dysgenesis XX and XY: observations in fifteen patients. *Ann Endocrinol (Paris)* 2005; 66: 553–556.
651. Carpenter NJ, Say B, Browning D. Gonadal dysgenesis in a patient with an X; 3 translocation: case report and review. *J Med Genet* 1980; 17: 216–221.
652. Grass FS, Schwartz RP, Deal JO, Parke JC Jr. Gonadal dysgenesis, intra-X chromosomal insertion, and possible position effect in an otherwise normal female. *Clin Genet* 1981; 20: 28–35.
653. Tullu MS, Arora P, Parmar RC, et al. Ovarian dysgenesis with balanced autosomal translocation. *J Postgrad Med* 2001; 47: 113–115.
654. Doherty E, Pakarinen P, Tiitinen A, et al. A novel mutation in the FSH receptor inhibiting signal transduction and causing primary ovarian failure. *J Clin Endocrinol Metab* 2002; 87: 1151–1155.
655. Allen LA, Achermann JC, Pakarinen P, et al. A novel loss of function mutation in exon 10 of the FSH receptor gene causing hypergonadotropic hypogonadism: clinical and molecular characteristics. *Hum Reprod* 2003; 18: 251–256.
656. De la Chesnaye E, Canto P, Ulloa-Aguirre A, Mendez JP. No evidence of mutations in the follicle-stimulating hormone receptor gene in Mexican women with 46,XX pure gonadal dysgenesis. *Am J Med Genet* 2001; 98: 125–128.
657. Letterie GS, Page DC. Dysgerminoma and gonadal dysgenesis in a 46,XX female with no evidence of Y chromosomal DNA. *Gynecol Oncol* 1995; 57: 423–425.
658. Norimura Y, Nishiyama H, Yanagida K, Sato A. Dysgerminoma with syncytiotrophoblastic giant cells

- arising from 46,XX pure gonadal dysgenesis. *Obstet Gynecol* 1998; 92: 654–656.
659. Namavar-Jahromi B, Mohit M, Kumar PV. Familial dysgerminoma associated with 46, XX pure gonadal dysgenesis. *Saudi Med J* 2005; 26: 872–874.
660. Gravholt CH, Juul S, Naeraa R, Hansen J. Prenatal and postnatal prevalence of Turner's syndrome: a registry study. *Br Med J* 1996; 312: 16–21.
661. Hook EB, Warburton D. The distribution of chromosomal genotypes associated with Turner's syndrome: livebirth prevalence and evidence for dismissed fetal mortality and severity in genotypes associated with structural X abnormalities or mosaicism. *Hum Genet* 1983; 64: 24–27.
662. Lippe BM. Primary ovarian failure. In: Kaplan SA, ed. *Clinical pediatric endocrinology*. Philadelphia: WB Saunders, 1990; 325–366.
663. Ogata T, Matsuo N. Turner syndrome and female sex chromosome aberrations: deduction of the principal factors involved in the development of clinical features. *Hum Genet* 1995; 95: 607–629.
664. Ranke MB, Saenger P. Turner's syndrome. *Lancet* 2001; 358: 309–314.
665. Singh RP, Carr DH. The anatomy and histology of XO human embryos and fetuses. *Anat Rec* 1966; 155: 369–383.
666. Jirasek J. Principles of reproductive embryology. In: Simpson JL, ed. *Disorders of sexual differentiation*. New York: Academic Press, 1976; 51–111.
667. Edelmann W, Cohen PE, Kneitz B, et al. Mammalian MutS homologue 5 is required for chromosome pairing in meiosis. *Nature Genet* 1999; 21: 123–127.
668. Modi DN, Sane S, Bhartiya D. Accelerated germ cell apoptosis in sex chromosome aneuploid fetal human gonads. *Mol Hum Reprod* 2003; 9: 219–225.
669. Ohno S. *Sex chromosomes and sex-linked genes*. Berlin: Springer-Verlag, 1967.
670. Tanaka Y, Sasaki Y, Tachibana K, et al. Gonadal mixed germ cell tumor combined with a large hemangiomas lesion in a patient with Turner's syndrome and 45,X/46,X, + mar karyotype. *Arch Pathol Lab Med* 1994; 118: 1135–1138.
671. Brant WO, Rajimwale A, Lovell MA, et al. Gonadoblastoma and Turner syndrome. *J Urol* 2006; 175: 1858–60.
672. Aaronson IA. True hermaphroditism. A review of 41 cases with observations on testicular histology and function. *Br J Urol* 1985; 57: 775–779.
673. Ouhilal S, Turco J, Nangia A, et al. True hermaphroditism presenting as bilateral gynecomastia in an adolescent phenotypic male. *Fertil Steril* 2005; 83: 1041.
674. Osorio Acosta VA, Alonso Dominguez FJ. True hermaphroditism. *Arch Esp Urol* 2004; 57: 856–860.
675. Morel Y, Rey R, Teinturier C, et al. Aetiological diagnosis of male sex ambiguity: a collaborative study. *Eur J Pediatr* 2002; 161: 49–59.
676. Nichter LS. Seminoma in a 46 XX true hermaphrodite with positive H-Y antigen. A case report. *Cancer* 1984; 53: 1181–1184.
677. Van Niekert WA, Retief AE. The gonads of human true hermaphrodites. *Hum Genet* 1981; 58: 117–122.
678. Van Niekert WA. True hermaphroditism. Clinical morphological and cytogenetic aspects. New York: Harper & Row, 1974.
679. Krob G, Braun A, Kuhnle U. True hermaphroditism: geographical distribution, clinical findings, chromosomes and gonadal histology. *Eur J Pediatr* 1994; 153: 2–10.
680. Yordam N, Alikasifoglu N, Caglar M, et al. True hermaphroditism: clinical features, genetic variants and gonadal histology. *J Pediatr Endocrinol Metab* 2001; 14: 421–427.
681. Toubanc JE, Boucekkine C, Abbas N, et al. Hormonal and molecular genetic findings in 46, XX subjects with sexual ambiguity and testicular differentiation. *Eur J Pediatr* 1993; 152: S70–S75.
682. Greenfield SP. Familial 46XX males coexisting with familial 46,XX true hermaphrodites in same pedigree. *J Pediatr* 1987; 110: 244–248.
683. Jimenez AL, Kofman-Alfaro S, Berumen J, et al. Partially deleted SRY gene confined to testicular tissue in a 46,XX true hermaphrodite without SRY in leukocytic DNA. *Am J Med Genet* 2000; 93: 417–420.
684. Tanaka Y, Fujiwara K, Yamauchi H, et al. Pregnancy in a woman with a Y chromosome after removal of an ovarian dysgerminoma. *Gynecol Oncol* 2000; 79: 519–521.
685. Nihoul-Fekete C, Lortat-Jacob S, Cachin O, et al. Preservation of gonadal function in true hermaphroditism. *J Pediatr Surg* 1984; 19: 50–55.
686. Prader A, Gurtner HP. Das syndrom des Pseudohermaphroditismus masculinus bei kongenitaler Nebenniereninsiden-Hyperplasie ohne Androgenüberproduktion. *Helvet Pediatr Acta* 1955; 10: 397–412.
687. Kirkland RT, Kirkland JL, Johnson CM, et al. Congenital lipid adrenal hyperplasia in an eight-year-old phenotypic female. *J Clin Endocrinol* 1973; 36: 488–496.
688. Katsumata N, Kawada Y, Yamamoto Y, et al. A novel compound heterozygous mutation in the steroidogenic acute regulatory protein gene in a patient with congenital lipid adrenal hyperplasia. *J Clin Endocrinol Metab* 1999; 84: 3983–3987.
689. Achermann JC, Meeks JJ, Heffs B, et al. Molecular and structural analysis of two novel StAR mutation in patients with lipid congenital adrenal hyperplasia. *Mol Genet Metab* 2001; 73: 354–357.
690. Fluck CE, Maret A, Mallet D, et al. A novel mutation L260P of the steroidogenic acute regulatory protein gene in three unrelated patients of Swiss ancestry with congenital lipid adrenal hyperplasia. *J Clin Endocrinol Metab* 2005; 90: 5304–5308.
691. Bose HS, Sato S, Aisenberg J, et al. Mutations in the steroidogenic acute regulatory protein (StAR) in six patients with congenital lipid adrenal hyperplasia. *J Clin Endocrinol Metab* 2000; 85: 3636–3639.
692. Miller WL. Disorders of androgen synthesis – from cholesterol to dehydroepiandrosterone. *Med Princ Pract* 2005; 14: 58–68.
693. Chen X, Baker BY, Abduljabbar MA, Miller WL. A genetic isolate of congenital lipid adrenal hyperplasia with atypical clinical findings. *J Clin Endocrinol Metab* 2005; 90: 835–840.
694. Bhangoo A, Anhalt H, Ten S, King SR. Phenotypic variations in lipid congenital adrenal hyperplasia. *Pediatr Endocrinol Rev* 2006; 3: 258–271.
695. Saenger P. Abnormal sex differentiation. *J Pediatr* 104: 1–17, 1984.
696. Saenger P, Klonari Z, Black SM, et al. Prenatal diagnosis of congenital lipid adrenal hyperplasia. *J Clin Endocrinol Metab* 1995; 80: 200–205.
697. Caron KM, Soo SC, Wetsel WC, et al. Targeted disruption of the mouse gene encoding steroidogenic acute regulatory protein provides insights into congenital lipid adrenal hyperplasia. *Proc Natl Acad Sci USA* 1997; 94: 11540–11545.
698. Tsutsui Y, Hirabayashi N, Ito G. An autopsy case of congenital lipid hyperplasia of the adrenal cortex. *Acta Pathol Jpn* 20: 227–237, 1970.
699. Müller J, Torsson A, Damkjaer Nielsen M, et al. Gonadal development and grown in 46,XX and 46,XY individuals with P450scc deficiency (congenital lipid adrenal hyperplasia). *Hormone Res* 1991; 36: 203–208.
700. Saenger P. New developments in congenital lipid adrenal hyperplasia and steroidogenic acute regulatory

- protein. *Pediatr Clin North Am* 1997; 44: 397–421.
701. Dhom G. Zur Morphologie und Genese der kongenitalen Nebennierenrindenhypertrophie beim männlichen Scheinzwitter. *Zeitschr Allg Pathol Anat* 1958; 97: 346–357.
702. Ogata T, Matsuo N, Saito M, Prader A. The testicular lesion and sexual differentiation in congenital lipoid adrenal hyperplasia. *Helv Paediatr Acta* 1989; 43: 531–538.
703. Hauffa BP, Miller WL, Grumbach MM, et al. Congenital adrenal lipoid hyperplasia due to deficient cholesterol side-chain cleavage activity (20,22-desmolase) in a patient treated for 18 years. *Clin Endocrinol* 1985; 23: 481–493.
704. Kirkland RT, Kirkland JL, Johnson CM, et al. Congenital lipoid adrenal hyperplasia in a eight-year-old phenotype female. *J Clin Endocrinol* 1973; 36: 488–496.
705. Korsch E, Peter M, Hiort O, et al. Gonadal histology with testicular carcinoma in situ in a 15-year old 46,XY female patient with a premature termination in the steroidogenic acute regulatory protein causing congenital lipoid adrenal hyperplasia. *J Clin Endocrinol Metab* 1999; 84: 1628–1632.
706. Bongiovanni AM. Unusual steroid pattern in congenital adrenal hyperplasia: deficiency of 3 β -hydroxydehydrogenase. *J Clin Endocrinol* 1961; 21: 860–862.
707. Parks GA, Bermudez JA, Anast CS, et al. Pubertal boy with the 3 β -hydroxysteroid dehydrogenase defect. *J Clin Endocrinol* 1971; 33: 269–278.
708. Zhang L, Mason JL, Naiki Y, et al. Characterization of two novel homozygous missense mutations involving codon 6 and 259 of type II 3 β -hydroxysteroid dehydrogenase (3 β HSD) gene causing, respectively, nonsalt-wasting and salt-wasting 3 β HSD deficiency disorder. *J Clin Endocrinol Metab* 2000; 85: 1678–1685.
709. Griffin JE, Wilson JD. Disorders of sexual differentiation. In: Walsh PC, Retik AB, Stamey TA, et al., eds. *Campbell's urology*. Vol. 2. Philadelphia: WB Saunders, 1992; 1496–1542.
710. Rheaume E, Simard J, Morel Y, et al. Congenital adrenal hyperplasia due to point mutations in the type II 3 β -hydroxysteroid dehydrogenase gene. *Nature Genet* 1992; 1: 239–45.
711. Simard J, Rheaume E, Sanchez R, et al. Molecular basis of congenital adrenal hyperplasia due to 3 β -hydroxysteroid dehydrogenase deficiency. *Mol Endocrinol* 1993; 7: 716–28.
712. Sanchez R, Rheaume E, Laflamme N, et al. Detection and functional characterization of the novel missense mutation Y254D in type II 3 β -hydroxysteroid dehydrogenase (3 β HSD) gene of a female patient with nonsalt-losing 3 β HSD deficiency. *J Clin Endocrinol Metab* 1994; 78: 561–567.
713. Pang S, Levine LS, Stoner E, et al. Nonsalt-losing congenital adrenal hyperplasia due to 3 β -hydroxysteroid dehydrogenase deficiency with normal glomerulosa function. *J Clin Endocrinol Metab* 1983; 56: 808–818.
714. Aaronson IA, Carkmak MA, Key LL. Defects of the testosterone biosynthetic pathway in boys with hypospadias. *J Urol* 1997; 157: 1884–1888.
715. Sapunar J, Vidal T, Bauer K. Abnormalities of adrenal steroidogenesis in Chilean boys with micropenis. *Rev Med Chile* 2003; 131: 46–54.
716. Lam CW, Arlt W, Chan CK, et al. Mutation of proline 409 to arginine in the meander region of cytochrome p450c17 causes severe 17 alpha-hydroxylase deficiency. *Mol Genet Metab* 2001; 72: 254–259.
717. Fan YS, Sasi R, Lee C, et al. Localization of the human CYP17 gene (cytochrome P450 (17 alpha)) to 10q24.3 by fluorescence 'in situ' hybridization and simultaneous chromosome banding. *Genomics* 1992; 14: 1110–1111.
718. Brooke AM, Taylor NF, Shepherd JH, et al. A novel point mutation in P450c17 (CYP17) causing combined 17alpha-hydroxylase/17,20-lyase deficiency. *J Clin Endocrinol Metab* 2006; 91: 2428–2431.
719. Auchus RJ, Gupta MK. Towards a unifying mechanism for CYP17 mutations that cause isolated 17,20-lyase deficiency. *Endocrinol Res* 2002; 28: 443–447.
720. Biglieri EG, Herron MA, Brust N. 17 alpha-hydroxylation deficiency in man. *J Clin Invest* 1966; 45: 1946–1954.
721. Sabage MO, Chausain JL, Evain D, et al. Endocrine studies in male pseudohermaphroditism in childhood and adolescence. *Clin Endocrinol* 1978; 8: 219–231.
722. Zachmann M, Vollman JA, Hamilton W, et al. Steroid 17,20 desmolase deficiency. *Clin Endocrinol* 1972; 1: 369–385.
723. Goebelsmann U, Davajan V, Isreal R, et al. Male pseudohermaphroditism consistent with 17–20 desmolase deficiency. *Gynecol Invest* 1974; 5: 60–64.
724. Gupta MK, Geller DH, Auchus RJ. Pitfalls in characterizing P450c17 mutations associated with isolated 17,20-lyase deficiency. *J Clin Endocrinol Metab* 2001; 86: 4416–4423.
725. Twosten W, Johannisson R, Holterhus PM, Hiort O. Severe 46,XY virilization deficit due to 17 β -hydroxysteroid dehydrogenase deficiency. *Klin Paediatr* 2002; 214: 314–315.
726. Millan M, Audi L, Martinez-Mora J, et al. 17 ketosteroid reductase deficiency in an adult patient without gynecomastia but with female psychosexual orientation. *Acta Endocrinol* 1983; 102: 633–640.
727. Dunic M, Plavsic V, Fattorini I, et al. Absent spermatogenesis despite early bilateral orchidopexy in 17-ketoreductase deficiency. *Hormone Res* 1985; 22: 100–106.
728. Lindqvist A, Hughes IA, Andersson S. Substitution mutation C268Y causes 17 β -hydroxysteroid dehydrogenase 3 deficiency. *J Clin Endocrinol Metab* 2001; 86: 921–923.
729. Richter-Unruh A, Korsch E, Hiort O, et al. Novel insertion frameshift mutation of the LH receptor gene: problematic clinical distinction of Leydig cell hypoplasia from enzyme defects primarily affecting testosterone biosynthesis. *Eur J Endocrinol* 2005; 152: 255–259.
730. Brown DM, Markland C, Dehner LP. Leydig cell hypoplasia: A cause of male pseudohermaphroditism. *J Clin Endocrinol Metab* 1978; 46: 1–7.
731. Eil C, Austin RM, Sesterhenn I, Dunn JF, et al. Leydig cell hypoplasia causing male pseudohermaphroditism: diagnosis 13 year after prepubertal castration. *J Clin Endocrinol Metab* 1984; 58: 441–448.
732. Lee PA, Rock JA, Brown TR, et al. Leydig cell hypofunction resulting in male pseudohermaphroditism. *Fertil Steril* 1982; 37: 675–679.
733. Park JJ, Burnett LS, Jones HW, et al. A case of male pseudohermaphroditism associated with elevated LH, normal FSH and low testosterone possibly due to the secretion of an abnormal LH molecule. *Acta Endocrinol* 1976; 83: 173–181.
734. Pérez-Palacios G, Scaglia HE, Kofman-Alpharo S, et al. Inherited male pseudohermaphroditism due to gonadotropin irresponsiveness. *Acta Endocrinol* 1981; 98: 148–155.
735. Saldanha PH, Arnhold IJP, Mendonça BB, et al. A clinico-genetic investigation of Leydig cell hypoplasia. *Am J Med Genet* 1987; 26: 337–344.
736. Latronico AC. Naturally occurring mutations of the luteinizing hormone receptor gene affecting reproduction. *Semin Reprod Med* 2000; 18: 17–20.
737. Salameh W, Choucair M, Guo TB, et al. Leydig cell hypoplasia due to inactivation of luteinizing hormone receptor by a novel homozygous nonsense truncation mutation in the seventh transmembrane domain. *Mol Cell Endocrinol* 2005; 229: 57–64.
738. Leung MY, Steinbach PJ, Bear D, et al. Biological effect of a novel mutation in the third leucine-rich repeat of human luteinizing hormone

- receptor. *Mol Endocrinol* 2006; 20: 2493–2503.
739. Wilson JD, Harrod MJ, Goldstein JL, et al. Familial incomplete male pseudohermaphroditism, type I. Evidence for androgen resistance and variable clinical manifestations in a family with the Reifenstein syndrome. *N Engl J Med* 1974; 290: 1097–1103.
740. Griffin JE, Durrant JL. Quantitative receptor defects in families with androgen resistance; failure of stabilization of the fibroblast cytosol androgen receptor. *J Clin Endocrinol Metab* 1982; 55: 465–474.
741. Toledo SPA, Arnhold IJP, Luthold W, et al. Leydig cell hypoplasia determining familial hypergonadotropic hypogonadism. *Prog Clin Biol Res* 1985; 200: 311–314.
742. Arnhold IJP, Mendonça BB, Bloise W, et al. Male pseudohermaphroditism resulting from Leydig cell hypoplasia. *J Pediatr* 1985; 106: 1057–1060.
743. Morris JM. The syndrome of testicular feminization in male pseudohermaphrodites. *Am J Obstet Gynecol* 1953; 65: 1192–1211.
744. Nitsche EM, Hiort O. The molecular bases of androgen insensitivity. *Hormone Res* 2000; 54: 327–333.
745. Brinkmann AO. Molecular basis of androgen insensitivity. *Mol Cell Endocrinol* 2001; 179: 105–109.
746. Rutgers JL, Scully RE. The androgen insensitivity syndrome (testicular feminization). A clinicopathologic study of 43 cases. *Int J Gynecol Pathol* 1991; 10: 126–145.
747. Gerli M, Migliorini G, Bocchini V, et al. A case of complete testicular feminization and 47 XXY karyotype. *J Med Genet* 1979; 16: 480–483.
748. Müller J. Morphometry and histology of gonads from twelve children and adolescents with the androgen insensitivity (testicular feminization) syndrome. *J Clin Endocrinol Metab* 1984; 59: 485–789.
749. Müller J, Skakkebaek NE. Testicular carcinoma in situ in children with the androgen insensitivity (testicular feminization) syndrome. *Br Med J* 1984; 288: 1419–1420.
750. Nistal M, De la Roza C, Cano J. Síndrome de feminización testicular completa. *Patología* 1979; 12: 119–125.
751. Aumuller G, Peter ST. Immunohistochemical and ultrastructural study of Sertoli cells in androgen insensitivity. *Int J Androl* 1986; 9: 99–108.
752. Ko HM, Chung JH, Jung IS, et al. Androgen receptor gene mutation associated with complete androgen insensitivity syndrome and Sertoli cell adenoma. *Int J Gynecol Pathol* 2001; 20: 196–199.
753. Hannema SE, Scott IS, Hodapp J, et al. Residual activity of mutant androgen receptors explains wolffian duct development in the complete androgen insensitivity syndrome. *J Clin Endocrinol Metab* 2004; 89: 5815–5822.
754. Sakai N, Yamada T, Asao T, et al. Bilateral testicular tumors in androgen insensitivity syndrome. *Int J Urol* 2000; 7: 390–392.
755. Papadimitriou DT, Linglart A, Morel Y, Chaussain JL. Puberty in subjects with complete androgen insensitivity syndrome. *Hormone Res* 2006; 65: 126–131.
756. Lubs HA Jr, Vilar O, Bergenstal DM. Familial male pseudohermaphroditism with labial testes and partial feminization: endocrine studies and genetic aspects. *J Clin Endocrinol Metab* 1959; 19: 1110–1120.
757. Gunasegaram R, Loganath A, Peh KL, et al. Altered hypothalamic–pituitary–testicular function in incomplete testicular feminization syndrome. *Aust NZ J Obstet Gynecol* 1984; 24: 288–292.
758. Gilbert-Dreyfus S, Sebaoum CIA, Belaisch J. Etude d'un cas familial d'androgynoidisme avec hypospadias grave, gynécomastie et hyperoestrogénie. *Ann Endocrinol* 1957; 18: 93–101.
759. Reifenstein EC Jr. Hereditary familial hypogonadism. *Clin Res* 1947; 3: 86–89.
760. Rosewater S, Gwinup G, Hamwi GJ. Familial gynecomastia. *Ann Intern Med* 1965; 63: 377–385.
761. Lombardo F, Sgro P, Salacone P, et al. Androgens and fertility. *J Endocrinol Invest* 2005; 28: 51–55.
762. Morrow AG, Gyorki S, Warne GL, et al. Variable androgen receptor levels in infertile men. *J Clin Endocrinol Metab* 1987; 64: 1115–1121.
763. Schulster A, Ross L, Scommegna A. Frequency of androgen insensitivity in infertile phenotypically normal men. *J Urol* 1983; 130: 699–701.
764. Wang Q, Ghadessy FJ, Yong EL. Analysis of the transactivation domain of the androgen receptor in patients with male infertility. *Clin Genet* 1998; 54: 185–192.
765. Akin JW, Behzadian A, Tho SPT, McDonough PG. Evidence for partial deletion in the androgen receptor gene in a phenotypic male with azoospermia. *Am J Obstet Gynecol* 1991; 165: 1891–1894.
766. Giwercman A, Kledal T, Schwartz M, et al. Preserved male fertility despite decreased androgen sensitivity caused by a mutation in the ligand-binding domain of the androgen receptor gene. *J Clin Endocrinol Metab* 2000; 85: 2253–2259.
767. Kennedy WR, Alter M, Sung JH. Progressive proximal spinal and bulbar muscular atrophy of late onset. A sex-linked recessive trait. *Neurology* 1968; 18: 671–680.
768. Tanaka F, Doyu M, Ito Y, et al. Founder effect in spinal and bulbar muscular atrophy (SBMA). *Hum Mol Genet* 1996; 5: 1253–1257.
769. Sobue G, Hashizume Y, Mukai E, et al. X-linked recessive bulbospinal neuronopathy: a clinicopathological study. *Brain* 1989; 112: 209–232.
770. Harding AE, Thomas PK, Baraitser M, et al. X-linked recessive bulbospinal neuronopathy: a report of ten cases. *J Neurol Neurosurg Psychiatry* 1982; 45: 1012–1019.
771. Stefanis C, Papapetropoulos T, Scarpalezos S, et al. X-Linked spinal and bulbar muscular atrophy of late onset. A separate type of motor neuron disease? *J Neurol Sci* 1975; 24: 493–503.
772. Arbizu T, Santamaria J, Gomez JM, et al. A family with adult spinal and bulbar muscular atrophy, X-linked inheritance and associated testicular failure. *J Neurol Sci* 1983; 59: 371–382.
773. La Spada AR, Wilson EM, Lubahn DB, et al. Androgen receptor gene mutations in X-linked spinal and bulbar muscular atrophy. *Nature* 1991; 352: 77–79.
774. La Spada AR, Roling DB, Harding AE, et al. Meiotic stability and genotype-phenotype correlation of the tricleotide repeat in X-linked spinal and bulbar muscular atrophy. *Nature Genet* 1992; 2: 301–304.
775. Chamberlain NL, Driver ED, Miesfeld RL. The length and location of CAG trinucleotide repeats in the androgen receptor N-terminal domain affect transactivation function. *Nucleic Acids Res* 1994; 22: 3181–3186.
776. MacLean HE, Choi WT, Rekaris G, et al. Abnormal androgen receptor binding affinity in subjects with Kennedy's disease (spinal and bulbar muscular atrophy). *J Clin Endocrinol Metab* 1995; 80: 508–516.
777. Gottlieb B, Lombroso R, Beitel LK, Trifiro MA. Molecular pathology of the androgen receptor in male (in)fertility. *Reprod Biomed Online* 2005; 10: 42–48.
778. Imperato-McGinley J, Guerrero J, Gautier T, Peterson RE. Steroid 5 alpha-reductase deficiency in man. An inherited form of male pseudohermaphroditism. *Science* 1974; 186: 1213–1215.
779. Vilchis F, Mendez JP, Canto P, et al. Identification of missense mutations in the SRD5A2 gene from patients with steroid 5alpha-reductase 2 deficiency. *Clin Endocrinol* 2000; 52: 383–387.
780. Andersson S, Berman DM, Jenkins EP, Russell DW. Deletion of steroid 5 alpha reductase 2 gene in male pseudohermaphroditism. *Nature* 1991; 354: 159–161.
781. Wilson JD, Griffin JE, Russell DW. Steroid 5 alpha-reductase 2 deficiency. *Endocrinol Rev* 1993; 14: 577–593.
782. Boudon C, Lumbroso S, Lobaccaro JM, et al. Molecular study of the 5

- alpha-reductase type 2 gene in three european families with 5 alpha-reductase deficiency. *J Clin Endocrinol Metab* 1995; 80: 2149–2153.
783. Skordis N, Patsalis PC, Bacopoulou I, et al. 5alpha-reductase 2 gene mutations in three unrelated patients of Greek Cypriot origin: identification of an ancestral founder effect. *J Pediatr Endocrinol Metab* 2005; 18: 241–246.
784. Kim SH, Kim KS, Kim GH, et al. A novel frameshift mutation in the 5alpha-reductase type 2 gene in Korean sisters with male pseudohermaphroditism. *Fertil Steril* 2006; 85: 750; e9–750.e12.
785. Schmidt JA, Schweikert, HU. Testosterone and epitestosterone metabolism of single hairs in 5 patients with 5 alpha-reductase-deficiency. *Acta Endocrinol* 1986; 113: 588–592.
786. Okon E, Livni N, Rösler A, et al. Male pseudohermaphroditism due to 5 alpha-reductase deficiency. *Arch Pathol Lab Med* 1980; 104: 363–367.
787. Peterson RE, Imperato-Mcginley J, Gautier T, et al. Male pseudohermaphroditism due to steroid 5 alpha-reductase deficiency. *Am J Med* 1977; 62: 170–191.
788. Josso N, Fekete C, Cachin O, et al. Persistence of müllerian ducts in male pseudohermaphroditism, and its relationship to cryptorchidism. *Clin Endocrinol* 1983; 19: 247–258.
789. Josso N, Boussin L, Knebelmann B, et al. Anti-Müllerian hormone and intersex states. *Trends Endocrinol Metab* 1991; 2: 227–233.
790. Josso N, Cate RL, Picard JY, et al. Anti-Müllerian hormone, the Jost factor. *Rec Progr Hormone Res* 1993; 48: 1–59.
791. Josso N, Picard JY, Imbeaud S, et al. The persistent müllerian duct syndrome: a rare cause of cryptorchidism. *Eur J Pediatr* 1993; 152: S76–S78.
792. Sohval AR. Hermaphroditism with atypical or 'mixed' gonadal dysgenesis. Relationship to gonadal neoplasm. *Am J Med* 1964; 36: 281–292.
793. Záh W, Kalderon AE, Tucci JR. Mixed gonadal dysgenesis. *Acta Endocrinol* 1975; 197: 3–39.
794. Konrad D, Sossay R, Winklehner HL, et al. Penoscrotal hypospadias and coarctation of the aorta with mixed gonadal dysgenesis. *Pediatr Surg Int* 2000; 16: 226–228.
795. Alvarez-Nava F, Soto M, Borjas L, et al. Molecular analysis of SRY gene in patients with mixed gonadal dysgenesis. *Ann Genet* 2001; 44: 155–159.
796. Robboy SJ, Miller T, Donahoe PK, et al. Dysgenesis of testicular and streak gonads in the syndrome of mixed gonadal dysgenesis. Perspective derived from a clinicopathologic analysis of twenty-one cases. *Hum Pathol* 1982; 13: 700–716.
797. Berkovitz GD, Fechner PY, Zacur HW, et al. Clinical and pathologic spectrum of 46,XY gonadal dysgenesis: its relevance to the understanding of sex differentiation. *Medicine (Baltimore)* 1991; 70: 375–383.
798. Rajfer J, Mendelsohn G, Arnheim J, et al. Dysgenetic male pseudohermaphroditism. *J Urol* 1978; 119: 525–527.
799. Ribeiro-Scolforo M, Aparecida-Cardinali I, Gabas-Stuchi-Perez E, et al. Morphometry and histology of gonads from 13 children with dysgenetic male pseudohermaphroditism. *Arch Pathol Lab Med* 2001; 125: 652–656.
800. Slowikoska-Hilczler J, Szarras-Czapnik M, et al. Testicular pathology in 46,XY dysgenetic male pseudohermaphroditism: an approach to pathogenesis of testis cancer. *J Androl* 2001; 22: 781–792.
801. Nilson O. Hernia uteri inguinalis beim Manne. *Acta Chirurg Scand* 1939; 83: 231–240.
802. Belville C, Josso N, Picard JY. Persistence of müllerian derivatives in males. *Am J Med Genet* 1999; 89: 218–223.
803. Sheehan SJ, Tobbia IN, Ismail MA, et al. Persistent müllerian duct syndrome. Review and report of 3 cases. *Br J Urol* 1985; 57: 548–551.
804. Beheshti M, Churchill BM, Hardy BE, et al. Familial persistent müllerian duct syndrome. *J Urol* 1984; 131: 968–969.
805. Mouli K, McCarthy P, Ray P, et al. Persistent müllerian duct syndrome in a man with transverse testicular ectopia. *J Urol* 1988; 139: 373–375.
806. Hershlag A, Spitz IM, Hochner-Celnikier D, et al. Persistent müllerian structures in infertile male. *Urology* 1986; 28: 138–141.
807. Malayaman D, Armiger G, D'Arcangues C, et al. Male pseudohermaphroditism with persistent müllerian and wolffian structures complicated by intra-abdominal seminoma. *Urology* 1984; 24: 67–69.
808. Belville C, Josso N, Picard J-Y. Persistence of müllerian derivatives in males. *Am J Med Genet* 1999; 89: 218–223.
809. Sloan WR, Walsh PC. Familial persistent müllerian duct syndrome. *J Urol* 1976; 115: 459–461.
810. Carré-Eusèbe D, Imbeaud S, Harbison M, et al. Variants of the anti-müllerian hormone gene in a compound heterozygote with the persistent müllerian duct syndrome and his family. *Hum Genet* 1992; 90: 389–394.
811. Nistal M, Paniagua R, Isorna S, et al. Diffuse intratubular undifferentiated germ cell tumor in both testes of a male subject with a uterus and ipsilateral testicular dysgenesis. *J Urol* 1980; 124: 286–289.
812. Snow BW, Rowland RG, Seal GM, et al. Testicular tumor in patient with persistent müllerian duct syndrome. *Urology* 1985; 26: 495–497.
813. Dueñas A, Saldívar C, Castellero C, et al. A case of bilateral seminoma in the setting of persistent müllerian duct syndrome. *Rev Invest Clin* 2001; 53: 193–196.
814. Kelley RI. RSH/Smith-Lemli-Opitz syndrome: mutations and metabolic morphogenesis. *Am J Med Genet* 1998; 63: 322–326.
815. Angle B, Tint GS, Yacoub OA, Clark AL. Atypical case of Smith-Lemli-Opitz syndrome: implications for diagnosis. *Am J Med Genet* 1998; 80: 322–326.
816. Nwokoro NA, Wassif CA, Porter FD. Genetic disorders of cholesterol biosynthesis in mice and humans. *Mol Genet Metab* 2001; 74: 105–119.
817. Witsch-Baumgartner M, Ciara E, Loffer J, et al. Frequency gradients of DHCR7 mutations in patients with Smith-Lemli-Opitz syndrome in Europe: evidence for different origins of common mutations. *Eur J Hum Genet* 2001; 9: 45–50.
818. Putnam AR, Szakacs JG, Opitz JM, Byrne JL. Prenatal death in Smith-Lemli-Opitz/RSH syndrome. *Am J Med Genet A* 2005; 138: 61–65.
819. Goldenberg A, Wolf C, Chevy F, et al. Antenatal manifestations of Smith-Lemli-Opitz (RSH) syndrome: a retrospective survey of 30 cases. *Am J Med Genet A* 2004; 124: 423–426.
820. Bradley LA, Palomaki GE Knight GJ, et al. Levels of unconjugated estriol and other maternal serum markers in pregnancies with Smith-Lemli-Opitz (RSH) syndrome fetuses. *Am J Med Genet* 1999; 82: 355–358.
821. Neri G, Opitz J. Syndromal (and nonsyndromal) forms of male pseudohermaphroditism. *Am J Med Genet* 1999; 89: 201–209.
822. Fitzky BU, Witsch-Baumgartner M, Erdel M, et al. Mutations in the delta7-steroid reductase gene in patients with the Smith-Lemli-Opitz syndrome. *Proc Natl Acad Sci USA* 1998; 95: 8181–8186.
823. Moebius FF, Fitzky BU, Lee JN, et al. Molecular cloning and expression of the human delta7-sterol reductase. *Proc Natl Acad Sci USA* 1998; 95: 1899–1902.
824. Wassif CA, Maslen C, Kachilele-Linjewile S, et al. Mutations in the human sterol delta7 reductase gene at 11q12-13 cause Smith-Lemli-Opitz syndrome. *Am J Hum Genet* 1998; 63: 55–62.
825. Waterham HR, Wijburg FA, Hennekam RC, et al. Smith-Lemli-Opitz syndrome is caused by mutations in the 7-dehydrocholesterol reductase gene. *Am J Hum Genet* 1998; 63: 329–338.

826. Porter FD. RSH/Smith–Lemli–Opitz syndrome: a multiple congenital anomaly/mental retardation syndrome due to an inborn error of cholesterol biosynthesis. *Mol Genet Metab* 2000; 71: 163–174.
827. Krakowiak PA, Nwokoro NA, Wassif CA, et al. Mutation analysis and description of sixteen RSH/Smith–Lemli–Opitz syndrome patients: polymerase chain reaction-based assays to simplify genotyping. *Am J Med Genet* 2000; 94: 214–227.
828. Shinawi M, Szabo S, Popek E, et al. Recognition of Smith–Lemli–Opitz syndrome (RSH) in the fetus: utility of ultrasonography and biochemical analysis in pregnancies with low maternal serum estradiol. *Am J Med Genet A* 2005; 138: 56–60.
829. Drash A, Sherman F, Hartmann WH, et al. A syndrome of pseudohermaphroditism, Wilms' tumor, hypertension and degenerative renal disease. *J Pediatr* 1970; 76: 585–593.
830. Rajfer J. Association between Wilms' tumor and gonadal dysgenesis. *J Urol* 1981; 125: 388–390.
831. McCoy FE, Franklin WA, Aronson AJ, et al. Glomerulonephritis associated with male pseudohermaphroditism and nephroblastoma. *Am J Surg Pathol* 1983; 7: 387–395.
832. Royer-Pokora B, Beier M, Henzler M, et al. Twenty-four new cases of WT1 germline mutations and review of the literature: genotype/phenotype correlations for Wilms' tumor development. *Am J Med Genet* 2004; A 27: 249–257.
833. Heppe RK, Koyle MA, Beckwith JB. Nephrogenic rests in Wilms' tumor patients with the Drash syndrome. *J Urol* 1991; 145: 1225–1228.
834. Koziell A, Charmandari E, Hindmarsh PC, et al. Frasier syndrome, part of the Denys Drash continuum or simply a WT1 gene associated disorder of intersex and nephropathy? *Clin Endocrinol* 2000; 52: 519–524.
835. Zugor V, Zenker M, Schrott KM, Schott GE. Frasier syndrome: a rare syndrome with WT1 gene mutation in pediatric urology. *Aktuelle Urol* 2006; 37: 64–66.
836. Chao LY, Huff V, Strong LC, Saunders GF. Mutation in the PAX6 gene in twenty patients with aniridia. *Hum Mutat* 15: 332–339, 2000.
837. Fischbach BV, Trout KL, Lewis J, et al. WAGR syndrome: a clinical review of 54 cases. *Pediatrics* 2005; 116: 984–988.
838. Opitz JM, Frías JL, Gutenberger JE, Pellett JR. The G syndrome of multiple congenital anomalies. *Birth Defects* 1969; 5: 95–101.
839. Opitz JM, Summitt RL, Smith DW. The BBB syndrome: familial telecanthus with associated congenital anomalies. *Birth Defects* 1969; 5: 95–101.
840. Berti C, Fontanella B, Ferrentino R, Meroni G. Mig12, a novel Opitz syndrome gene product partner, is expressed in the embryonic ventral midline and co-operates with Mid1 to bundle and stabilize microtubules. *BMC Cell Biol* 2004; 5: 9.
841. Cho HJ, Shin MY, Ahn KM, et al. X-linked Opitz G/BBB syndrome: identification of a novel mutation and prenatal diagnosis in a Korean family. *J Korean Med Sci* 2006; 21: 790–793.
842. Giordano J, Prior HM, Bamforth JS, et al. Genetic study of SOX9 in a case of campomelic dysplasia. *Am J Med Genet* 2001; 98: 176–181.
843. Gibbons RJ, Higgs DR. Molecular-clinical spectrum of the ATR-X syndrome. *Am J Med Genet* 2000; 97: 204–212.
844. Wada T, Fukushima Y, Saitoh S. A new detection method for ATRX gene mutations using a mismatch-specific endonuclease. *Am J Med Genet A* 2006; 140: 1519–1523.
845. Fichera M, Silengo M, Spalletta A, et al. Prenatal diagnosis of ATR-X syndrome in a fetus with a new G>T splicing mutation in the XNP/ATR-X gene. *Prenat Diagn* 2001; 21: 747–751.
846. Charny CW. Testicular biopsy, its value in male sterility. *JAMA* 1940; 115: 1429–1432.
847. Charny CW, Meranze DR. Testicular biopsy. Further studies in male infertility. *Surg Gynecol Obstet* 1942; 74: 836–842.
848. Nelson WO. Interpretation of testicular biopsy. *JAMA* 1953; 151: 449–452.
849. Pesce C. Testicular biopsy in the evolution of male infertility. *Semin Diagn Pathol* 1987; 4: 264–274.
850. Wong TW, Straus FH II, Warner NE. Testicular causes of infertility. *Arch Pathol* 1973; 95: 151–159.
851. Wong TW, Straus FH II, Warner NE. Pretesticular causes of infertility. *Arch Pathol* 1974; 98: 1–8.
852. Guarch R, Pesce C, Puras A, et al. A quantitative approach to the classification of hypospermatogenesis in testicular biopsies for infertility. *Hum Pathol* 1992; 23: 1032–1037.
853. Honoré LJ. Testicular biopsy for infertility: a review of sixty-eight cases with a simplified histologic classification of lesions. *Int J Fertil* 1979; 24: 49–52.
854. Girgis SM, Etriby A, Ibrahim AA, et al. Testicular biopsy in azoospermia: a review of the last ten years. Experience of over 800 cases. *Fertil Steril* 1969; 20: 467–477.
855. Wong TW, Straus FH II, Warner NE. Posttesticular causes of infertility. *Arch Pathol* 1973; 95: 160–164.
856. Söderstrom KO, Suominen J. Histopathology and ultrastructure of meiotic arrest in human spermatogenesis. *Arch Pathol Lab Med* 1980; 198: 476–482.
857. Charny CW. Reflections on testicular biopsy. *Fertil Steril* 1963; 14: 610–616.
858. Meinhard E, McRae CU, Chisholm GD. Testicular biopsy in evaluation of male infertility. *Br Med J* 1973; 3: 577–581.
859. Levin HS. Testicular biopsy in the study of male infertility. Its current usefulness, histologic techniques, and prospects for the future. *Hum Pathol* 1979; 10: 569–584.
860. Bairati A, Della Morte E, Giarola A, et al. Testicular biopsy of azoospermic men with vas deferens malformation using two different techniques. *Arch Androl* 1986; 17: 67–78.
861. Narbaitz R, Tolnai G, Jolly E, et al. Ultrastructural studies on testicular biopsies from eighteen cases of hypospermatogenesis. *Fertil Steril* 1978; 30: 679–686.
862. Fossati P, Asfour M, Blacker C, et al. Serum and seminal gonadotropins in normal and infertile men: correlations with sperm count, prolactinemia, and seminal prolactin. *Arch Androl* 1979; 2: 247–252.
863. Johnson L, Petty CS, Neaves WB. The relationship of biopsy evaluations and testicular measurements to overall daily sperm production in human testes. *Fertil Steril* 1980; 34: 36–40.
864. De Kretser DM, Burger HG, Hudson B. The relationship between germinal cells and serum FSH levels in males with infertility. *J Clin Endocrinol Metab* 1974; 38: 787–793.
865. Jensen TK, Andersson AM, Hjollund NH, et al. Inhibin B as a serum marker of spermatogenesis: correlation to differences in sperm concentration and follicle-stimulating hormone levels. A study of 349 Danish men. *J Clin Endocrinol Metab* 1997; 82: 4059–4063.
866. Kumanov P, Nandipati K, Tomova A, Agarwal A. Inhibin B is a better marker of spermatogenesis than other hormones in the evaluation of male factor infertility. *Fertil Steril* 2006; 86: 332–338.
867. Makler A, Abramovici H. The correlation between sperm count and testicular biopsy using a new scoring system. *Int J Fertil* 1978; 23: 300–304.
868. Johnsen SG. Testicular biopsy score count – a method for registration of spermatogenesis in human testes: Normal values and results in 335 hypogonadal males. *Hormones* 1970; 1: 2–25.
869. Meyer JM, Roos M, Rumpel Y. Statistical study of a semiquantitative evaluation of testicular biopsies. *Arch Androl* 1988; 20: 71–71.
870. Steinberger E, Tjioe DY. A method for quantitative analysis of human seminiferous epithelium. *Fertil Steril* 1968; 19: 960–970.
871. Rowley MJ, Heller CG. Quantitation of the cells of the seminiferous

- epithelium of human testis employing Sertoli cells as a constant. *Zeitschr Zellforsch* 1971; 115: 461–472.
872. Skakkebaek NE, Hammen R, Philip J, et al. Quantification of human seminiferous epithelium. III Histological studies in 44 infertile men with normal chromosome complements. *Acta Pathol Microbiol Scand (A)* 1973; 81: 97–111.
873. Skakkebaek NE, Hulten M, Philip J. Quantification of human seminiferous epithelium. 4. Histological studies in 17 men with numerical and structural autosomal aberrations. *Acta Pathol Microbiol Scand (A)* 1973; 81: 112–124.
874. Skakkebaek NE, Heller CG. Quantification of human seminiferous epithelium. I Histological studies in twenty-one fertile men with normal chromosome complements. *J Reprod Fertil* 1983; 32: 179–189.
875. Zuckerman Z, Rodriguez-Rigau LJ, Weiss DB, et al. Quantitative analysis of the seminiferous epithelium in human testicular biopsies, and the relation of spermatogenesis to sperm density. *Fertil Steril* 1978; 30: 448–455.
876. Johnson L, Zane RS, Petty CS, et al. Quantification of the human Sertoli cell population: its distribution, relation to germ cell numbers, and age related decline. *Biol Reprod* 1984; 31: 785–795.
877. Weiss DB, Rodriguez-Rigau L, Smith KD, et al. Quantitation of Leydig cells in testicular biopsies of oligospermic men with varicocele. *Fertil Steril* 1978; 30: 305–312.
878. Heller CG, Lalli MF, Pearson JE, et al. A method for the quantification of Leydig cells in man. *J Reprod Fertil* 1971; 25: 177–184.
879. Averback P, Wight DGD. Seminiferous tubule hypercurvature: a newly recognized common syndrome of human male infertility. *Lancet* 1979; 1: 181–183.
880. Averback P. Branching of seminiferous tubules associated with hypofertility and chronic respiratory infection. *Arch Pathol Lab Med* 1980; 104: 361–362.
881. Nistal M, Abaurrea MA, Paniagua R. Morphological and histometric study on the human Sertoli cells from birth to the onset of puberty. *J Anat* 1982; 134: 351–363.
882. Nistal M, Jiménez F, Paniagua R. Sertoli cell types in Sertoli-cell-only syndrome: relationships between Sertoli cell morphology and aetiology. *Histopathology* 1990; 16: 173–180.
883. Schulze C, Holstein AF, Schirden C, et al. On the morphology of the human Sertoli cells under normal conditions and in patients with impaired fertility. *Andrologia* 1976; 8: 167–178.
884. Chemes HE, Dym M, Fawcett DW, et al. Pathophysiological observations of Sertoli cells in patients with germinal aplasia or severe germ cell depletion. Ultrastructural findings and hormone levels. *Biol Reprod* 1977; 17: 108–128.
885. Terada T, Hatakeyama S. Morphological evidence for two types of idiopathic 'Sertoli-cell-only' syndrome. *Int J Androl* 1991; 14: 117–126.
886. Goslar HG, Hilscher B, Haider SG, et al. Enzyme histochemical studies on the pathological changes in human Sertoli cells. *J Histochem Cytochem* 1982; 30: 1268–1274.
887. Fabbri A, Re M, Spera G. Behaviour of glycogen and related enzymes in the Sertoli cell syndrome. *Experientia* 1969; 25: 647–651.
888. Nistal M. Testículo humano. Hipoplasia túbulo intersticial difusa (hipogonadismo hipogonadotrópico). *Arch Esp Urol* 1973; 3: 252–280.
889. Nistal M, Paniagua R. Leydig cell differentiation induced by stimulation with HCG and HMG in two patients affected with hypogonadotropic hypogonadism. *Andrologia* 1979; 11: 211–222.
890. De Kretser DM. The fine structure of the immature human testis in hypogonadotrophic hypogonadism. *Virchows Arch [Cell Pathol]* 1968; 1: 283–296.
891. Nistal M, Paniagua R, Abaurrea MA, et al. Hyperplasia and the immature appearance of Sertoli cells in primary testicular disorders. *Hum Pathol* 1982; 13: 3–12.
892. Steger K, Rey R, Kliesch S, et al. Immunohistochemical detection of immature Sertoli cell markers in testicular tissue of infertile adult men: a preliminary study. *Int J Androl* 1996; 19: 122–128.
893. Bar-Shira Maymon B, Paz G, Elliott DJ, et al. Maturation phenotype of Sertoli cells in testicular biopsies of azoospermic men. *Hum Reprod* 2000; 15: 1537–1542.
894. Cavicchia JC, Sacerdote FL, Ortiz L. The human blood–testis barrier in impaired spermatogenesis. *Ultrastruct Pathol* 1996; 20: 211–218.
895. Steger K, Rey R, Louis F, et al. Reversion of the differentiated phenotype and maturation block in Sertoli cells in pathological human testis. *Hum Reprod* 1999; 14: 136–143.
896. Paniagua R, Nistal M, Bravo MP. Leydig cell types in primary testicular disorders. *Hum Pathol* 1984; 15: 181–190.
897. Mack WS, Scott LS, Ferguson-Smith MA, et al. Ectopic testis and the undescended testis: a histological comparison. *J Pathol Bacteriol* 1961; 82: 439–443.
898. Taniuchi I, Mizutani S, Namiki M, et al. Short arm dicentric Y chromosome in a sterile man: a case report. *J Urol* 1991; 146: 415–416.
899. Aumuller G, Schulze C, Viebahn C. Intermediate filaments in Sertoli cells. *Microsc Res Tech* 1992; 20: 50–72.
900. Christiansen P. Urinary gonadotropins in the Sertoli-cell-only syndrome. *Acta Endocrinol* 1975; 78: 180–191.
901. Hammar M, Berg AA. Impaired Leydig cell function in vitro in testicular tissue from human males with 'Sertoli cell only' syndrome. *Andrologia* 1985; 17: 37–41.
902. Okuyama A, Nonomura N, Koh E, et al. Testicular FSH and HCG receptors in Sertoli-cell-only syndrome. *Arch Androl* 1989; 23: 119–124.
903. Del Castillo EB, Trabucco A, De la Balze FA. Syndrome produced by absence of the germinal epithelium without impairment of the Sertoli or Leydig cells. *J Clin Endocrinol Metab* 1947; 7: 493–497.
904. Blagosklonova O, Fellmann F, Clavequin MC, et al. AZFa deletions in Sertoli cell-only syndrome: a retrospective study. *Mol Hum Reprod* 2000; 6: 795–799.
905. Rothman MC, Sims SA, Stotts CI. Sertoli cell only syndrome in 1982. *Fertil Steril* 1982; 38: 388–390.
906. Buchanan JD, Fairley KF, Barrie JU. Return of spermatogenesis after stopping cyclophosphamide therapy. *Lancet* 1975; 2: 156–157.
907. Decensi AU, Guarneri D, Marroni P, et al. Evidence for testicular impairment after long-term treatment with a luteinizing hormone-releasing hormone agonist in elderly men. *J Urol* 1989; 142: 1235–1238.
908. Sapino A, Pagani A, Godano A, et al. Effects of estrogens on the testis of transsexuals: a pathological and immunocytochemical study. *Virchows Arch A* 1987; 411: 409–414.
909. Schulze C. Response of the human testis to long-term estrogen treatment: Morphology of Sertoli cells, Leydig cells and spermatogonial stem cells. *Cell Tissue Res* 1988; 251: 31–43.
910. Daehlin L, Tomic R, Damber JE. Depressed testosterone release from testicular tissue in vitro after withdrawal of oestrogen treatment in patients with prostatic carcinoma. *Scand J Urol Nephrol* 1988; 22: 11–13.
911. Söderstrom KD. Tubular hyalinization in human testes. *Andrologia* 1986; 18: 97–103.
912. Martín R, Santamaría L, Nistal M, et al. The peritubular myofibroblasts in the testes from normal men and men with Klinefelter's syndrome. A quantitative, ultrastructural, and immunohistochemical study. *J Pathol* 1992; 168: 59–66.
913. Santamaría L, Martínez-Onsurbe P, Paniagua R, et al. Laminin, type IV collagen, and fibronectin in normal

- and cryptorchid human testes. An immunohistochemical study. *Int J Androl* 1990; 13: 470–487.
914. Wantz GI. Testicular atrophy as a sequela of inguinal herniorrhaphy. *Int Surg* 1986; 71: 159–163.
915. Regadera J, Nistal M, Paniagua R. Testis epididymis, and spermatic cord in elderly men. Correlation of angiographic and histologic studies with systemic arteriosclerosis. *Arch Pathol Lab Med* 1985; 109: 663–667.
916. Nistal M, Martínez C, Paniagua R. Primary testicular lesions in the twisted testis. *Fertil Steril* 1992; 57: 381–386.
917. Morgan AD. Inflammation and infestation of the testis and paratesticular structures. In: Puch RCB ed. *Pathology of the testis*. Oxford: Blackwell, 1976; 79–138.
918. Mirsch IH, Choi H. Quantitative testicular biopsy in congenital and acquired genital obstruction. *J Urol* 1990; 143: 311–312.
919. Santamaría L, Martín R, Nistal M, et al. The peritubular myoid cells in the testes from men with varicocele. An ultrastructural, immunohistochemical and quantitative study. *Histopathology* 1992; 21: 423–433.
920. Cohn EL, Watson L, Older R, Moran R. Striated pattern of the testicle on ultrasound: an appearance of testicular fibrosis. *J Urol* 1996; 156: 180–181.
921. Casalino DD, Kim R. Clinical importance of a unilateral striated pattern seen on sonography of the testicle. *AJR Am J Roentgenol* 2002; 178: 927–930.
922. Potashnic G, Ben-Aderet N, Israeli R, et al. Suppressive effects of 1,2-dibromo-3-3-chloropropane on human spermatogenesis. *Fertil Steril* 1978; 30: 444–447.
923. Barton M, Wiesner BP. Significance of testicular exfoliation in male infertility. *Br Med J* 1952; 1: 958–962.
924. Belsey MAR, Eliasson AJ, Gallegos KS, et al. Laboratory manual for the examination of human semen and semen–cervical mucus interaction. In: Paulsen CA, Prasac MNR, eds. *VHO special program in human reproduction*. Singapore: Press Concern, 1980; 74–94.
925. Sigg C, Hornstein OP. Zytologische Klassifikation in reifer Keimzellen im Luftgetrockneten Ejakulatanstrich beim spermatologische Syndrom der vermehrten Desquamation von Zellen der Spermatogenese (VDZS). *Andrologia* 1987; 19: 378–391.
926. Breucker H, Hofmann N, Holstein AF. Transformed spermatocytes constituting the ejaculate of an infertile man. *Andrologia* 1988; 20: 526–535.
927. Riedel HH, Schirren C. Studies on the differentiation of round cells in the human ejaculate. *Zeitschr Hautkr* 1978; 53: 255–267.
928. Holstein C. Morphologie freier unreifer Keimzellen im menschlichen Hoden, Nebenhoden und Ejaculat. *Andrologia* 1983; 15: 7–25.
929. Nistal M, Gonzalez-Peramato P, Paniagua R. Diagnostic value of differential quantification of spermatids in obstructive azoospermia. *J Androl* 2003; 24: 721–726.
930. MacLeod J. Seminal cytology in the presence of varicocele. *Fertil Steril* 1965; 16: 735–757.
931. Takihara M, Sakatoku J, Cockett ATK. The pathophysiology of varicocele in male infertility. *Fertil Steril* 1991; 55: 861–868.
932. Nistal M, Paniagua R, Regadera J, et al. Obstruction of the tubuli recti and ductuli efferentes by dilated veins in the testes of men with varicocele and its possible role in causing atrophy of the seminiferous tubules. *Int J Androl* 1984; 7: 309–323.
933. Yamamoto M, Hashimoto J, Takaba H, et al. Scanning electron microscopic study on the shape of infertile seminiferous tubules: A hypothesis of pathogenesis of idiopathic male infertility. *Int J Fertil* 1988; 33: 265–272.
934. Gall EA. The histopathology of acute mumps orchitis. *Am J Pathol* 1947; 23: 637–651.
935. Sciarano RB, Rahn MI, Pigozzi MI, et al. An azoospermic man with a double-strand DNA break-processing deficiency in the spermatocyte nuclei: case report. *Hum Reprod* 2006; 21: 1194–1203.
936. Kostova E, Yeung CH, Luetjens cm, et al. Association of three isoforms of the meiotic BOULE gene with spermatogenic failure in infertile men. *Mol Hum Reprod* 2007; 13: 85–93.
937. Gulizia S, Vicari E, Aleffi A, et al. Abnormal germ cell exfoliation in semen of hypogonadotrophic patients during a hCG treatment. *Andrologia* 1981; 13: 74–77.
938. Scaglia HE, Timossi cm, Carrere CA, et al. Altered luteinizing hormone pulsatility in infertile patients with idiopathic oligoasthenozoospermia. *Hum Reprod* 1998; 13: 2782–2786.
939. Dony JM, Smals AG, Rolland R, et al. Differential effect of luteinizing hormone-releasing hormone infusion on testicular steroids in normal men and patients with idiopathic oligospermia. *Fertil Steril* 1984; 42: 274–280.
940. Harsch IA, Simoni M, Nieschlag E. Molecular heterogeneity of serum follicle-stimulating hormone in hypogonadal patients before and during androgen replacement therapy and in normal men. *Clin Endocrinol* 1993; 39: 173–180.
941. Tapanainen JS, Aittomaki K, Min J, et al. Men homozygous for an inactivating mutation of the follicle-stimulating-hormone (FSH) receptor gene present variable suppression of spermatogenesis and fertility. *Nature Genet* 1997; 15: 205–206.
942. Sigg S. Klassifizierung tubulärer Hodenatrophien bei Sterilitätabklärungen. *Schweiz Med Wschr* 1979; 35: 1284–1293.
943. Martinova Y, Kantcheva L, Tzvetkov D. Testicular ultrastructure in infertile men. *Arch Androl* 1989; 22: 103–122.
944. Bustos-Obregón E, Esponda P. Ultrastructure of the nucleus of human Sertoli cells in normal and pathological testes. *Cell Tissue Res* 1974; 152: 467–475.
945. De Kretser DM, Kerr JB, Paulsen CA. Evaluation of the ultrastructural changes in the human Sertoli cell in testicular disorders and the relationship of the changes to the levels of serum FSH. *Int J Androl* 1981; 4: 129–144.
946. Namiki M, Koide T, Okuyama A, et al. Abnormality of testicular FSH receptors in infertile men. *Acta Endocrinol* 1984; 106: 548–555.
947. Kumanov P, Nandipati KC, Tomova A, et al. Significance of inhibin in reproductive pathophysiology and current clinical applications. *Reprod Biomed Online* 2005; 10: 786–812.
948. Gerris J, Comhaire F, Hellemans P. Placebo-controlled trial of high-dose mesterolone treatment of idiopathic male infertility. *Fertil Steril* 1991; 55: 603–607.
949. Andersson AM, Jorgensen N, Frydelund-Larsen L, et al. Impaired Leydig cell function in infertile men: a study of 357 idiopathic infertile men and 318 proven fertile controls. *J Clin Endocrinol Metab* 2004; 89: 3161–3167.
950. Stecker JF, Lloyd JW. Leydig and Sertoli cell function in normal and oligospermic males: a preliminary report. *Fertil Steril* 1978; 29: 204–208.
951. Giagulli VA, Vermeulen A. Leydig cell function in infertile men with idiopathic oligospermic infertility. *J Clin Endocrinol Metab* 1988; 66: 62–67.
952. Aiman J, Griffin JE, Gazak JM, et al. Androgen insensitivity as a cause of infertility in otherwise normal men. *N Engl J Med* 1979; 300: 223–227.
953. Aiman J, Griffin JE. The frequency of androgen receptor deficiency in infertile men. *J Clin Endocrinol Metab* 1982; 54: 725–732.
954. O'Dowd J, Gaffney EF, Young RH. Malignant sex cord stromal tumor in a patient with the androgen insensitivity syndrome. *Histopathology* 1990; 16: 279–282.
955. Knoke Y, Jakubiczka S, Lehnert H, et al. A new point mutation of the androgen receptor gene in a patient with partial androgen resistance and severe oligozoospermia. *Andrologia* 1999; 31: 199–201.

956. Akin JW. The use of clomiphene citrate in the treatment of azoospermia secondary to incomplete androgen resistance. *Fertil Steril* 1993; 59: 223–224.
957. Akin JW, Behzadian A, Tho, SPT, et al. Evidence for a partial deletion in the androgen receptor gene in a phenotypic male with azoospermia. *Am J Obstet Gynecol* 1991; 165: 1891–1894.
958. Hiort O, Holterhus PM. Androgen insensitivity and male infertility. *Int J Androl* 2003; 26: 16–20.
959. Schulster A, Ross L, Scommegna A. Frequency of androgen insensitivity infertile phenotypically normal men. *J Urol* 1983; 130: 699–701.
960. Gooren L. Improvement of spermatogenesis after treatment with the antiestrogen tamoxifen in a man with the incomplete androgen insensitivity syndrome. *J Clin Endocrinol Metab* 1989; 68: 1207–1210.
961. Sokol RZ, Steiner BS, Bustillo M, et al. A controlled comparison of the efficacy of clomiphene citrate in male infertility. *Fertil Steril* 1988; 49: 865–870.
962. Yong EL, Ng SC, Roy AC, et al. Pregnancy after hormonal correction of severe spermatogenic defect due to a mutation in androgen receptor gene. *Lancet* 1994; 344: 826–827.
963. Schrag SD, Dixon RL. Occupational exposures associated with male reproductive dysfunction. *Ann Rev Pharmacol Toxicol* 1985; 25: 567–592.
964. Cameron DT, Snyder FE. Ultrastructural surface characteristics of seminiferous tubules from men with varicocele. *Andrologia* 1982; 14: 425–433.
965. Takihara H, Cosentino MJ, Sakaratoku J, et al. Significance of testicular size measurement in andrology. II. Correlation of testicular size with testicular function. *J Urol* 1987; 137: 416–419.
966. Chehval MJ, Purcell MH. Deterioration of semen parameters over time in men with untreated varicocele: evidence of progressive testicular damage. *Fertil Steril* 1992; 57: 174–177.
967. Agger P, Johnsen S. Quantitative evaluation of testicular biopsies in varicocele. *Fertil Steril* 1978; 29: 52–57.
968. Dubin L, Hotchkiss RS. Testis biopsy in subfertile men with varicocele. *Fertil Steril* 1969; 20: 50–57.
969. Etriby A, Girgis SM, Hefnawy H, et al. Testicular changes in subfertile males with varicocele. *Fertil Steril* 1967; 18: 666–671.
970. Nistal M, De Mora JC, Paniagua R. Classification of several types of maturational arrest of spermatogonia according to Sertoli cell morphology: an approach to aetiology. *Int J Androl* 1998; 21: 317–326.
971. Denis L. Prostate cancer. Primary hormonal treatment. *Cancer* 1993; 71: 1050–1058.
972. Hatakeyama S, Takizawa T, Kawara Y. Focal atrophy of the seminiferous tubule in the human testis. *Acta Pathol Jpn* 1979; 29: 901–905.
973. Sigg C, Hedinger C. Quantitative and ultrastructural study on germinal epithelium in testicular biopsies with 'mixed atrophy.' *Andrologia* 1981; 13: 412–424.
974. Sharpe RM, McKinnell C, Kivlin C, Fisher JS. Proliferation and functional maturation of Sertoli cells, and their relevance to disorders of testis function in adulthood. *Reproduction* 2003; 125: 769–784.
975. Buchanan JD, Fairley KF, Barrie JU. Return of spermatogenesis after stopping cyclophosphamide therapy. *Lancet* 1975; 2: 156–157.
976. Sigg C, Hedinger C. The frequency and morphology of 'giant spermatogonia' in the human testis. *Virchows Arch B [Cell Pathol]* 1983; 44: 115–134.
977. Paniagua R, Nistal M, Amat P, et al. Seminiferous tubule involution in elderly men. *Biol Reprod* 1987; 36: 939–947.
978. Bergmann M, Nashan D, Nieschlag E. Pattern of compartmentation in human seminiferous tubules showing dislocation of spermatogonia. *Cell Tissue Res* 1989; 256: 183–190.
979. Holstein AF, Bustos-Obregon E, Hartmann M. Dislocated type-A spermatogonia in human seminiferous tubules. *Cell Tissue Res* 1984; 236: 35–40.
980. Miething A. Intercellular bridges between megalospermatocytes in the human testis. *Andrologia* 1991; 23: 91–97.
981. Johannisson R, Schulze W, Holstein AF. Megalospermatocytes in the human testis exhibit asynapsis of chromosomes. *Andrologia* 2003; 35: 146–151.
982. Holstein AF, Eckmann C. Megalospermatocytes: indicators of disturbed meiosis in man. *Andrologia* 1986; 18: 601–609.
983. Nistal M, Codesal J, Paniagua R. Multinucleate spermatids in aging human testes. *Arch Androl* 1986; 16: 125–129.
984. Vegni-Talluri M, Bigliardi E, Soldani P. Unusual incidence of binucleate spermatids in human cryptorchidism. *J Submicrosc Cytol* 1978; 10: 357–361.
985. Nistal M, Paniagua R. Testicular and epididymal pathology. New York: Thieme-Stratton, 1984; 227–240.
986. Aumüller G, Fuhrmann W, Krause W. Spermatogenetic arrest with inhibition of acrosome and sperm tail development. *Andrologia* 1987; 19: 9–17.
987. Baccetti B, Capitani S, Collodel G, et al. Recent advances in human sperm pathology. *Contraception* 2002; 65: 283–287.
988. David G, Bisson JP, Czyglik F, et al. Anomalies morphologiques du spermatozoïde humain. Propositions pour un système de classification. *J Gynecol Obstet Biol Reprod* 1975; 4: 17–36.
989. Holstein AF. Morphologische Studien an abnormen Spermatoïden und Spermatozoen des Menschen. *Virchows Arch [Pathol Anat Histol]* 1975; 367: 92–112.
990. Holstein AF, Schirren C. Classification of abnormalities in human spermatids based on recent advances in ultrastructural research on spermatid differentiation. In: Fawcett DW, Bedford JM, eds. *The spermatozoon. Maturation, mobility, surface properties and comparative aspects*. Baltimore: Urban and Schwarzenberg, 1979; 341–353.
991. Portuondo JA, Calabozo M, Echanojauregui AD. Morphology of spermatozoa in fertile man with and without varicocele. *J Androl* 1983; 4: 312–315.
992. Kullander S, Rausing A. On round headed human spermatozoa. *Int J Fertil* 1975; 2: 33–40.
993. Nistal M, Paniagua R. Morphogenesis of round headed human spermatozoa lacking acrosomes in a case of severe teratozoospermia. *Andrologia* 1978; 10: 49–51.
994. Meschede D, Rolf C, Neugebauer D-C, et al. Sperm acrosome defects in a patient with Aarskog-Scott syndrome. *Am J Med Genet* 1996; 66: 340–342.
995. Escalier D. Failure of differentiation of the nuclear-perinuclear skeletal complex in the round-headed human spermatozoa. *Int J Dev Biol* 1990; 34: 287–297.
996. Reichart M, Lederman H, Har-Even D, et al. Human sperm acrosin activity with relation to semen parameters and acrosomal ultrastructure. *Andrologia* 1993; 25: 59–66.
997. Morel F, Douet-Guilbert N, Moerman A, et al. Chromosome aneuploidy in the spermatozoa of two men with globozoospermia. *Mol Hum Reprod* 2004; 10: 835–838.
998. Martin RH, Greene C, Rademaker AW. Sperm chromosome aneuploidy analysis in a man with globozoospermia. *Fertil Steril* 2003; 79: 1662–1664.
999. Moretti E, Collodel G, Scapigliati G, et al. 'Round head' sperm defect. Ultrastructural and meiotic segregation study. *J Submicrosc Cytol Pathol* 2005; 37: 297–303.
1000. Yao R, Ito C, Natsume Y, et al. Lack of acrosome formation in mice lacking a Golgi protein, GOPC. *Proc Natl Acad Sci USA* 2002; 99: 11211–11216.
1001. German J, Rasch EM, Huang CY, et al. Human infertility due to production of multiple-tailed

- spermatozoa with excessive amounts of DNA. *Am J Hum Genet* 1981; 33: 64–74.
1002. Nistal M, Paniagua R, Herruzo A. Multi-tailed spermatozoa in a case with asthenospermia and teratospermia. *Virchows Arch B [Cell Pathol]* 1977; 26: 111–118.
1003. Escalier D. Human spermatozoa with large heads and multiple flagella: a quantitative ultrastructural study of 6 cases. *Biol Cell* 1983; 48: 65–74.
1004. Guthauser B, Vialard F, Dakouane M, et al. Chromosomal analysis of spermatozoa with normal-sized heads in two infertile patients with macrocephalic sperm head syndrome. *Fertil Steril* 2006; 85: 750. e5.
1005. Baccetti B, Burrini AG, Collodel G, et al. Crater defect in human spermatozoa. *Gamete Res* 1989; 22: 249–255.
1006. Matano Y. Ultrastructural study of human binucleate spermatids. *J Ultrastruct Res* 1971; 34: 123–134.
1007. Dadoune JP. Ultrastructural abnormalities of human spermatozoa. *Hum Reprod* 1988; 3: 311–318.
1008. Cooper TG. Cytoplasmic droplets: the good, the bad or just confusing? *Hum Reprod* 2005; 20: 9–11.
1009. Nistal M, Paniagua R, Herruzo A. Absence de la paire centrale du complexe axonémique dans une tératospermie avec flagelles courts et épais. *J Gynecol Obstet Biol Reprod* 1979; 8: 47–50.
1010. Alexandre C, Bisson JP, David G. Asthenozoospermie totale avec anomalie ultrastructurale du flagelle dans deux frères stériles. *J Gynecol Obstet Biol Reprod* 1978; 7: 31–38.
1011. Chemes HE, Brugo Olmedo S, et al. Dysplasia of the fibrous sheath. An ultrastructural defect of human spermatozoa associated with sperm immotility and primary sterility. *Fertil Steril* 1987; 48: 664–669.
1012. Barthelemy C, Tharanne MJ, Lebos C, et al. Tail stump spermatozoa: morphogenesis of the defect. An ultrastructural study of sperm and testicular biopsy. *Andrologia* 1990; 22: 417–425.
1013. Baccetti B, Collodel G, Estenoz M, et al. Gene deletions in an infertile man with sperm fibrous sheath dysplasia. *Hum Reprod* 2005; 20: 2790–2794.
1014. Nistal M, Paniagua R, Herruzo A. Multi-tailed spermatozoa in a case with asthenospermia and teratospermia. *Virchows Arch B [Cell Pathol]* 1977; 26: 111–118.
1015. Latini M, Gandini L, Lenzi A, Romanelli F. Sperm tail agenesis in a case of consanguinity. *Fertil Steril* 2004; 81: 1688–1691.
1016. Perotti ME, Giarola A, Gioria M. Ultrastructural study of the decapitated sperm defect in a infertile man. *J Reprod Fertil* 1981; 63: 543–549.
1017. Baccetti B, Burrini AG, Collodel G, et al. Morphogenesis of the decapitated and decaudated sperm defect in two brothers. *Gamete Res* 1989; 23: 181–188.
1018. Chemes HE, Puigdomenech ET, Carizza C, et al. Acephalic spermatozoa and abnormal development of the head–neck attachment: a human syndrome of genetic origin. *Hum Reprod* 1999; 14: 1811–1818.
1019. Zamboni L. Sperm structure and its relevance to infertility. *Arch Pathol Lab Med* 1992; 116: 325–344.
1020. Toyama Y, Iwamoto T, Yajima M, et al. Decapitated and decaudated spermatozoa in man, and pathogenesis based on the ultrastructure. *Int J Androl* 2000; 23: 109–115.
1021. Okada H, Fujioka H, Tatsumi N, et al. Assisted reproduction for infertile patients with 9 + 0 immotile spermatozoa associated with autosomal dominant polycystic kidney disease. *Hum Reprod* 1999; 14: 110–113.
1022. Baccetti B, Burrini AG, Pallini V. Spermatozoa and cilia lacking axoneme in an infertile man. *Andrologia* 1980; 12: 525–532.
1023. Afzelius BA, Eliasson R, Hoh O, Lindholmer C. Lack of dynein arms in immotile human spermatozoa. *J Cell Biol* 1975; 66: 225–232.
1024. Holzmann D, Ott PM, Felix H. Diagnostic approach to primary ciliary dyskinesia: a review. *Eur J Pediatr* 2000; 159: 95–98.
1025. Carlen B, Stenram U. Primary ciliary dyskinesia: a review. *Ultrastruct Pathol* 2005; 29: 217–220.
1026. Douard R, Feldman A, Bargy F, et al. Anomalies of lateralization in man: a case of total situs inversus. *Surg Radiol Anat* 2000; 22: 293–297.
1027. Schieferstein G, Wolburg H, Adam W. Stiff-tail-oder Mittelstück-Syndrom. *Andrologia* 1987; 1: 5–8.
1028. Haidl G, Becker A, Henkel R. Pour development of outer dense fibres as a mayor cause of tail abnormalities in the spermatozoa of asthenoteratozoospermic men. *Hum Reprod* 1991; 6: 1431–1438.
1029. Ruiz-Pesini E, Lapeña A-C, Díez-Sanchez C, et al. Human mtDNA haplogroups associated with high or reduced spermatozoa motility. *Am J Hum Genet* 2000; 67: 682–696.
1030. Carra E, Sangiorgi D, Gattuccio F, Rinaldi AM. Male infertility and mitochondrial DNA. *Biochem Biophys Res Commun* 2004; 322: 333–339.
1031. Pryor JP, Cameron KM, Chilton CP, et al. Carcinoma in situ in testicular biopsies from men presenting with infertility. *Br J Urol* 1983; 55: 780–784.
1032. Nistal M, Codesal J, Paniagua R. Carcinoma in situ of the testis in infertile men. A histological, immunocytochemical and cytophotometric study of DNA content. *J Pathol* 1989; 159: 205–210.
1033. Schütte B. Early testicular cancer in severe oligozoospermia. In: Holstein AF, Leindenberger F, Hölzer KH, Bettendorf G, eds. *Carl Schirren Symposium. Advances in andrology*. Berlin: Diesbach Verlag, 1988; 188–190.
1034. Skakkebaek NE, Berthelsen JG, Giwercman A, et al. Carcinoma-in-situ of the testis: possible origin from gonocytes and precursor of all types of germ cell tumours except spermatocytoma. *Int J Androl* 1987; 10: 19–28.
1035. Schutte B. Male subfertility. Continuing diagnostic and therapeutic measures. *Ther Umsch* 1980; 37: 487–493.
1036. Giwercman A, Grindsted J, Hansen B, et al. Testicular cancer risk in boys with maldescended testis: A cohort study. *J Urol* 1987; 138: 1214–1216.
1037. Novero V Jr, Goossens A, Tournaye H, et al. Seminoma discovered in two males undergoing successful testicular sperm extraction for intracytoplasmic sperm injection. *Fertil Steril* 1996; 65: 1051–1054.
1038. Berthelsen JC, Skakkebaek NE, Von Der Maase H, et al. Screening for carcinoma in situ of the contralateral testis in patients with germinal testicular cancer. *Br Med J* 1982; 285: 1683–1686.
1039. Hadziselimovic F, Herzog B, Emmons LR. The incidence of seminoma and expression of cell adhesion CD44 in cryptorchid boys and infertile men. *J Urol* 1997; 157: 1895–1897.
1040. Singh R, Shastry PK, Rasalkar AA, et al. A novel androgen receptor mutation resulting in complete androgen insensitivity syndrome and bilateral Leydig cell hyperplasia. *J Androl* 2006; 27: 510–516.
1041. Olumi AF, Garnick MB, Renshaw AA, et al. Leydig cell hyperplasia mimicking testicular neoplasm. *Urology* 1996; 48: 647–649.
1042. Hashimoto J, Nagay T, Takaba H, et al. Increased mast cells in the limiting membrane of seminiferous tubules in the testes of patients with idiopathic infertility. *Urol Int* 1988; 43: 129–132.
1043. Nagai T, Takaba H, Miyake K, et al. Testicular mast cell heterogeneity in idiopathic male infertility. *Fertil Steril* 1992; 57: 1331–1336.
1044. Kollur SM, Pattankar VL, El Hag IA. Mast cells in testicular lesions. *Ups J Med Sci* 2004; 109: 239–245.
1045. Oliva A, Multigner L. Ketotifen improves sperm motility and sperm morphology in male patients with leukocytospermia and unexplained infertility. *Fertil Steril* 2006; 85: 240–243.
1046. Makler A, Geresh I. An attempt to explain occurrence of patent

- reproductive tract in azoospermic males with tubular spermatogenesis. *Int J Fertil* 1979; 24: 246–250.
1047. Silber SJ, Rodriguez-Rigau LJ. Quantitative analysis of testicular biopsy: determination of partial obstruction and prediction of sperm count after surgery for obstruction. *Fertil Steril* 1981; 36: 480–485.
1048. Nistal M, Codesal J, Santamaría L, Paniagua R. Correlation between spermatozoon numbers in spermogram and seminiferous epithelium histology in testicular biopsies from subfertile men. *Fertil Steril* 1987; 48: 507–509.
1049. Sandoval L, Diaz M, Rivas F. Alpha-1,4-glucosidase activity and the presence of germinal epithelium cells in the semen for differential diagnosis of obstructive and nonobstructive azoospermia. *Arch Androl* 1995; 35: 155–158.
1050. Pryor JP, Hendry WF. Ejaculatory duct obstruction in subfertile males: analysis of 87 patients. *Fertil Steril* 1991; 56: 725–730.
1051. Nistal M, Gonzalez-Peramato P, Serrano A, et al. Paratesticular cysts with benign epithelial proliferations of wolffian origin. *Am J Clin Pathol* 2005; 124: 245–251.
1052. Sano T, Horiguchi H. Von Hippel-Lindau disease. *Microsc Res Tech* 2003; 60: 159–164.
1053. Belet U, Danaci M, Sarikaya S, et al. Prevalence of epididymal, seminal vesicle, prostate, and testicular cysts in autosomal dominant polycystic kidney disease. *Urology* 2002; 60: 138–141.
1054. Vohra S, Morgentaler A. Congenital anomalies of the vas deferens, epididymis, and seminal vesicles. *Urology* 1997; 49: 313–321.
1055. Dubin L, Amelar RD. Etiologic factors in 1294 consecutive cases of male infertility. *Fertil Steril* 1971; 22: 469–474.
1056. Auroux M, De Mouy DM, Acar JF. Male fertility and positive chlamydial serology. A study of 61 fertile and 82 subfertile men. *J Androl* 1987; 8: 197–200.
1057. Hillier SL, Rabe LK, Muller CH, et al. Relationship of bacteriologic characteristics to semen indices in men attending an infertility clinic. *Obstet Gynecol* 1990; 75: 800–804.
1058. Wagenlehner FM, Naber KG. Treatment of bacterial urinary tract infections: presence and future. *Eur Urol* 2006; 49: 235–244.
1059. Delavierre D. Orchi-epididymitis. *Ann Urol* 2003; 37: 322–338.
1060. Sandhu DPS, Osborn DE, Munson KW. Relationship of azoospermia to inguinal surgery. *Int J Androl* 1992; 15: 504–506.
1061. Ross LS, Flom LS. Azoospermia. A complication of hydrocele repair in a fertile population. *J Urol* 1991; 146: 852–853.
1062. Schned AR, Memoll VA. Coarse granular cytoplasmic change of the epididymis. An immunohistochemical and ultrastructural study. *J Urol Pathol* 1994; 2: 213–222.
1063. Rajalakshmi M, Kumar BV, Ramakrishnan PR, Kapur MM. Histology of the epididymis in men with obstructive infertility. *Andrologia* 1990; 22: 319–326.
1064. Hirsch IH, McCue P, Allen J, et al. Quantitative testicular biopsy in spinal cord injured men: comparison to fertile controls. *J Urol* 1991; 146: 337–341.
1065. Pardanani DS, Patil NG, Pawar HN. Some gross observations of the epididymides following vasectomy: a clinical study. *Fertil Steril* 1976; 27: 267–270.
1066. McMahon AJ, Buckley J, Taylor A, et al. Chronic testicular pain following vasectomy. *Br J Urol* 1992; 69: 188–191.
1067. Jarow JP, Budin RE, Dym M, et al. Quantitative pathologic changes in the human testis after vasectomy. A controlled study. *N Engl J Med* 1985; 313: 1252–1256.
1068. Jenkins IL, Muir VY, Blacklock NJ, et al. Consequences of vasectomy: an immunological and histological study related to subsequent fertility. *Br J Urol* 1979; 51: 406–410.
1069. Marmar JL. The status of vasectomy reversals. *Int J Fertil* 1991; 36: 352–357.
1070. Urry RL, Heaton JB, Moore M, et al. A fifteen-year study of alterations in semen quality occurring after vasectomy reversal. *Fertil Steril* 1990; 53: 341–345.
1071. Young D. Surgical treatment of male infertility. *J Reprod Fertil* 1970; 23: 541–542.
1072. Handelsman DJ, Conway AJ, Boylan LM, Turtle JR. Young's syndrome: obstructive azoospermia and chronic sinopulmonary infections. *N Engl J Med* 1984; 310: 3–4.
1073. Neville E, Brewis RAL, Yeates WK, et al. Respiratory tract disease and obstructive azoospermia. *Thorax* 1983; 38: 929–930.
1074. Hendry WF, Knight RK, Whitfield HN. Obstructive azoospermia: respiratory function tests, electron microscopy and the results of surgery. *Br J Urol* 1978; 50: 598–604.
1075. Nistal M, Paniagua R, Abaurrea MA. Varicose axon bearing 'synaptic' vesicles on the basal lamina of the human seminiferous tubules. *Cell Tissue Res* 1982; 226: 75–82.
1076. Filippi S, Morelli A, Vignozzi L, et al. Oxytocin mediates the estrogen-dependent contractile activity of endothelin-1 in human and rabbit epididymis. *Endocrinology* 2005; 146: 3506–3517.
1077. Yamamoto M, Hibi H, Miyake K. Comparison of the effectiveness of placebo and alpha-blocker therapy for the treatment of idiopathic oligozoospermia. *Fertil Steril* 1995; 63: 396–400.
1078. Aran B, Blanco J, Vidal F, et al. Screening for abnormalities of chromosomes X, Y, and 18 and for diploidy in spermatozoa from infertile men participating in an vitro fertilization-intracytoplasmic sperm injection program. *Fertil Steril* 1999; 72: 696–701.
1079. Bertini V, Simi P, Valetto A. Cytogenetic study of 435 subfertile men: incidence and clinical features. *J Reprod Med* 2006; 51: 15–20.
1080. Klinefelter HF, Reifenstein EC, Albright F. Syndrome characterized by gynecomastia, aspermatogenesis without aleydigism and increased excretion of follicle-stimulating hormone. *J Clin Endocrinol* 1942; 2: 615–627.
1081. Glander HJ. Infertility in the Klinefelter syndrome. *MMW Fortschr Med* 2005; 147: 39–41.
1082. Ohno S. Control of meiotic process. In: Troen P, Nankin HR, eds. *The testis in normal and infertile men*. New York: Raven Press, 1977; 1–8.
1083. Smyth CM, Bremner WJ. Klinefelter syndrome. *Arch Intern Med* 1998; 158: 1309–1314.
1084. Hsueh WA, Hsu TH, Federman DD. Endocrine features of Klinefelter's syndrome. *Medicine* 1978; 57: 447–461.
1085. Kamischke A, Baumgardt A, Horst J, Nieschlag E. Clinical and diagnostic features of patients with suspected Klinefelter syndrome. *J Androl* 2003; 24: 41–48.
1086. Becker KL. Clinical and therapeutic experiences with Klinefelter's syndrome. *Fertil Steril* 1972; 23: 568–578.
1087. Patwardhan AJ, Eliez S, Bender B, et al. Brain morphology in Klinefelter syndrome: extra X chromosome and testosterone supplementation. *Neurology* 2000; 54: 2218–2223.
1088. Mor C, Ben-Bassat M, Leiba S. Leydig and Sertoli cells. Their fine structure in three cases of Klinefelter's syndrome. *Arch Pathol Lab Med* 1982; 106: 228–230.
1089. Frohland A, Skakkebaek NE. Dimorphism in sex chromatin pattern of Sertoli cells in adults with Klinefelter's syndrome: correlation with two types of 'Sertoli-cell-only' tubes. *J Clin Endocrinol Metab* 1971; 33: 683–687.
1090. Ahmad KW, Dykes JRW, Ferguson-Smith MA, et al. Leydig cell counts in chromatin-positive Klinefelter's syndrome. *J Clin Endocrinol Metab* 1971; 33: 517–520.
1091. Nistal M, Santamaría L, Paniagua R. Quantitative and ultrastructural study of Leydig cells in Klinefelter's syndrome. *J Pathol* 1985; 146: 323–331.
1092. Rubin P, Mattei A, Cesarini JP, et al. Etude en microscopie électronique de

- la cellule de Leydig dans la maladie de Klinefelter en périodes pre, per et postpubertaires. *Ann Endocrinol* 1971; 32: 671-681.
1093. Gabrilove JC, Freiberg EK, Nicolis GC. Testicular function in Klinefelter's syndrome. *J Urol* 1980; 124: 825-828.
1094. Wellen JJ, Smals AGH, Rijken JCW, et al. Testosterone and δ 4 androstenedione in the saliva of patients with Klinefelter's syndrome. *Clin Endocrinol* 1983; 18: 51-59.
1095. Gómez-Acebo J, Parrilla R, Abrisqueta JA, et al. Fine structure of spermatogenesis in Klinefelter's syndrome. *J Clin Endocrinol Metab* 1968; 28: 1287-1292.
1096. Steinberger E, Smith KD, Perloff WH. Spermatogenesis in Klinefelter's syndrome. *J Clin Endocrinol Metab* 1965; 25: 1325-1330.
1097. Staessen C, Tournaye H, Van Assche E, et al. PDG in 47,XXY Klinefelter's syndrome patients. *Hum Reprod Update* 2003; 9: 319-330.
1098. Hennebicq S, Pelletier R, Bergues U, Rousseaux S. Risk of trisomy 21 in offspring of patients with Klinefelter's syndrome. *Lancet* 2001; 357: 2104-2105.
1099. Mudal S, Ockey CH. The 'double male.' A new chromosome constitution in Klinefelter's syndrome. *Lancet* 1960; 2: 492-493.
1100. Ellis JR, Miller OJ, Penrose LS, et al. A male with XXYY chromosomes. *Ann Hum Genet* 1961; 25: 145-152.
1101. Borgeonkar DS, Muler E, Char F. Do the 48 XXYY males have a characteristic phenotype? *Clin Genet* 1970; 1: 272-277.
1102. Bloomgarden ZI, Delozier CD, Cohen MP, et al. Genetics and endocrine findings in a 48 XXYY male. *J Clin Endocrinol Metab* 1980; 50: 740-743.
1103. Uchida IA, Miller JR, Soltan HC. Dermatoglyphics associated with the XXYY chromosome complement. *Ann J Hum Genet* 1964; 16: 284-289.
1104. Nistal M, Paniagua R, López-Pajares I. Ultrastructure of Leydig cells in Klinefelter's syndrome with 48 XXYY karyotype. *Virchows Arch B [Cell Pathol]* 1978; 28: 39-46.
1105. Ferguson-Smith MA, Johnston AW, Handmaker S. Primary amentia and microorchidism associated with an XXXY sex-chromosome constitution. *Lancet* 1960; 2: 184-187.
1106. Kim HJ, Kim D, Shin JM, et al. 49,XXXXY syndrome with diabetes mellitus. *Hormone Res* 2006; 65: 14-17.
1107. Fraccaro M, Kaijser K, Lindsten J. A child with 49 chromosomes. *Lancet* 1960; 2: 899-902.
1108. Jackson AW, Mudal S, Ockey CH, et al. Carcinoma of the male breast in association with Klinefelter's syndrome. *Br Med J* 1965; 1: 223-225.
1109. Scheike O. Male breast cancer. *Acta Pathol Microbiol Scand* 1975; 251: 13-35.
1110. Mies R, Fischer H, Pfeiff B, et al. Klinefelter's syndrome and breast cancer. *Andrologia* 1982; 14: 317-321.
1111. Isurugi K, Imao S, Hirose K, et al. Seminoma in Klinefelter's syndrome with 47 XXY, 15s+ karyotype. *Cancer* 1977; 39: 2041-2047.
1112. Vanfleteren E, Steeno O. Klinefelter's syndrome and mediastinal teratoma. *Andrologia* 1981; 13: 573-577.
1113. Gohji K, Goto A, Takenaka A, et al. Extragonadal germ cell tumor in the retrovesical region associated with Klinefelter's syndrome: A case report and review of literature. *J Urol* 1989; 141: 133-136.
1114. McNeil MM, Leong A, Sage RE. Primary mediastinal embryonal carcinoma in association with Klinefelter's syndrome. *Cancer* 1981; 47: 343-345.
1115. Sogge MR, McDonald SDM, Cofold PB. The malignant potential of the dysgenetic germ cell in Klinefelter's syndrome. *Am J Med* 1979; 66: 515-518.
1116. Mukerjee D, Bowen J, Anderson DE. Simian papovavirus 40 transformation of cells from cancer patient with XY/XXY mosaic Klinefelter's syndrome. *Cancer Res* 1970; 30: 1769-1772.
1117. Pascual J, Liaño F, García-Villanueva A, et al. Isolated primary aldosteronism in a patient with adrenal carcinoma and XY/XXY Klinefelter's syndrome. *J Urol* 1990; 144: 1454-1456.
1118. PENCHANSKY L, Krause JR. Acute leukemia following a malignant teratoma in a child with Klinefelter's syndrome. *Cancer* 1982; 50: 684-689.
1119. Keung YK, Buss D, Chauvenet A, Pettenati M. Hematologic malignancies and Klinefelter syndrome. A chance association? *Cancer Genet Cytogenet* 2002; 139: 9-13.
1120. Hwang JJ, Dharmawardana PG, Uchio EM, et al. Prostate cancer in Klinefelter syndrome during hormonal replacement therapy. *Urology* 2003; 62: 941.
1121. Ferguson-Smith MA. The prepubertal testicular lesion in chromatin-positive Klinefelter's syndrome (primary micro-orchidism). As seen in mentally handicapped children. *Lancet* 1959; 1: 219-222.
1122. Samango-Sprouse C. Mental development in polysomy X Klinefelter syndrome (47,XXY; 48,XXXXY): effects of incomplete X inactivation. *Semin Reprod Med* 2001; 19: 193-202.
1123. Khalifa M, Struthers J. Klinefelter syndrome is a common cause for mental retardation of unknown etiology among prepubertal males. *Clin Genet* 2002; 61: 49-53.
1124. Schibler D, Brook CG, Kind HP, et al. Growth and body proportions in 54 boys and men with Klinefelter's syndrome. *Helv Paediatr Acta* 1974; 29: 325-333.
1125. Grumbach MM, Conte FA. Disorders of sex differentiation. In: Wilson JD, Foster DW, eds. *Williams' textbook of endocrinology*, 8th edn. Philadelphia: WB Saunders, 1992; 853-951.
1126. Smyth CM, Bremner WJ. Klinefelter syndrome. *Arch Intern Med* 1998; 158: 1309-1314.
1127. Visootsak J, Aylstock M, Graham JM Jr. Klinefelter syndrome and its variants: an update and review for the primary pediatrician. *Clin Pediatr* 2001; 40: 639-651.
1128. Ross JL, Samango-Sprouse C, Lahlou N, et al. Early androgen deficiency in infants and young boys with 47,XXY Klinefelter syndrome. *Hormone Res* 2005; 64: 39-45.
1129. Lanman JT, Skalarin BS, Cooper HL, et al. Klinefelter's syndrome in a ten month old mongolian idiot. *N Engl J Med* 1960; 263: 887-888.
1130. Gracia R, Martín-Álvarez L, Figols J, et al. Síndrome de Klinefelter's XXY en el periodo prepuberal. Estudio de ocho observaciones. *An Esp Pediatr* 1974; 7: 510-523.
1131. Akglaede L, Wikstrom AM, Rajpert-De Meyts E, et al. Natural history of seminiferous tubule degeneration in Klinefelter syndrome. *Hum Reprod Update* 2006; 12: 39-48.
1132. Volkl TM, Langer T, Aigner T, et al. Klinefelter syndrome and mediastinal germ cell tumors. *Am J Med Genet A* 2006; 140: 471-481.
1133. Bertelloni S, Battini R, Baroncelli GL, et al. Central precocious puberty in 48,XXYY Klinefelter syndrome variant. *J Pediatr Endocrinol Metab* 1999; 12: 459-465.
1134. Maisey DN, Mills IH, Middleton H, et al. A case of Klinefelter's syndrome with acquired hypopituitarism. *Acta Endocrinol* 1984; 105: 126-129.
1135. Smals AGH, Kloppenborg PWC. Klinefelter's syndrome with hypogonadotropic hypogonadism. *Br Med J* 1977; 1: 839-839.
1136. Rabinowitz D, Cohen MM, Rosenmann E, et al. Chromatin-positive Klinefelter's syndrome with undetectable peripheral FSH levels. *Am J Med* 1975; 59: 584-590.
1137. Shirai M, Matsuda S, Mitsukawa S. A case of hypogonadotropic hypogonadism with an XY/XXY chromosome mosaicism. *Tohoku J Exp Med* 1974; 114: 131-139.
1138. Carter JN, Wiseman DGH, Lee HB. Klinefelter's syndrome with hypogonadotropic hypogonadism. *Br Med J* 1977; 1: 212-212.
1139. Nistal M, Paniagua R, Abaurrea MA, et al. 47,XXY Klinefelter's syndrome with low FSH and LH levels and

- absence of Leydig cells. *Andrologia* 1980; 12: 426–433.
1140. Fuse H, Ito H, Minagawa H, et al. A case of XX-male syndrome. *Jpn J Fertil Steril* 1982; 27: 77–82.
1141. Maeda O, Nakamura M, Namiki M, et al. 45X/46XX boy with hypospadias: case report. *J Urol* 1986; 135: 1249–1251.
1142. De la Chapelle A, Hortling H, Niemi M, et al. XX sex chromosomes in a human male. First case. *Acta Med Scand* 1964; 175: 25–38.
1143. Radi O, Parma P, Imbeaud S, et al. XX sex reversal, palmoplantar keratoderma, and predisposition to squamous cell carcinoma: genetic analysis in one family. *Am J Med Genet A* 2005; 138: 241–246.
1144. De la Chapelle A. Analytic review: Nature and origin of males with XX sex chromosomes. *Am J Hum Genet* 1972; 24: 71–105.
1145. Kovacs K, Singer W, Casal G. Leydig cell ultrastructure in an XX male. *J Urol* 1974; 112: 651–654.
1146. Nistal M, Barreiro E, Herruzo A, et al. Varón con cariotipo 46 XX. *Arch Esp Urol* 1975; 28: 263–272.
1147. Nistal M, Paniagua R. Ultrastructure of testicular biopsy from an XX male. *Virchows Arch B [Cell Pathol]* 1979; 31: 45–55.
1148. Romani F, Terquem A, Dadoune JP. Le testicule chez l'homme 46, XX: A propos d'une observation ultrastructural. *J Gynecol Obstet Biol Rep* 1977; 6: 1049–1059.
1149. Sasagawa I, Terada T, Katayama T, et al. Ultrastructure of the testis in an XX male with normal plasma testosterone. *Andrologia* 1986; 18: 361–367.
1150. Mittwoch U. Sex determination and sex reversal: genotype, phenotype, dogma and semantics. *Hum Genet* 1992; 89: 467–479.
1151. Marquet F, Verloes A, Beckers A. Clinical case of the month. A male with 46,XX karyotype. *Rev Méd Liège* 1998; 53: 515–517.
1152. Ferguson-Smith MA. X-Y chromosomal interchange in the etiology of true hermaphroditism and of XX Klinefelter's syndrome. *Lancet* 1966; 27: 475–476.
1153. Butler MG, Walzak MP, Sanger WG, et al. A possible etiology of the infertile 46 XX male subject. *J Urol* 1983; 130: 154–156.
1154. Muller U, Donlon T, Schmid M, et al. Deletion mapping of the testis determining locus with DNA probes in 46 XX males and 46 XY and 46 X dic (Y) females. *Nucleic Acids Res* 1986; 14: 6489–6505.
1155. Fuse H, Satomi S, Kazama T, et al. DNA hybridization study using Y-specific probes in an XX-male. *Andrologia* 1991; 23: 237–239.
1156. Suzuki Y, Sasagawa I, Yazawa H, et al. Localization of the sex-determining region-Y gene in XX males. *Arch Androl* 2000; 44: 133–136.
1157. Castineyra G, Copelli S, Levalle O. 46,XX male: clinical, hormonal/genetic findings. *Arch Androl* 2002; 48: 251–257.
1158. Rigola MA, Carrera S, Ribas I, et al. A comparative genomic hybridization study in a 46,XX male. *Fertil Steril* 2002; 78: 186–188.
1159. Dauwse JG, Hansson KB, Brouwers AA, et al. An XX male with the sex-determining region Y gene inserted in the long arm of chromosome 16. *Fertil Steril* 2006; 86: 463; e1–5.
1160. Yoshida M, Kakizawa Y, Moriyama N, et al. Deoxyribonucleic acid and cytological detection of Y-containing cells in a XX hypospadiac boy with polyorchidism. *J Urol* 1991; 146: 1356–1358.
1161. Abusheikha N, Lass A, Brinsden P. XX males without SRY gene and with infertility. *Hum Reprod* 2001; 16: 717–718.
1162. Rajender S, Rajani V, Gupta NJ, et al. SRY-negative 46,XX male with normal genitals, complete masculinization and infertility. *Mol Hum Reprod* 2006; 12: 341–346.
1163. Ferguson-Smith MA, Cooke A, Affara NA, et al. Genotype-phenotype correlations in XX males and their bearing on current theories of sex determination. *Hum Genet* 1990; 84: 198–202.
1164. McElreavey K, Vilain E, Abbas N, et al. A regulatory cascade hypothesis for mammalian sex determination: SRY represses a negative regulator of male development. *Proc Natl Acad Sci USA* 1993; 90: 3368–3372.
1165. Seeherunvong T, Perera EM, Bao Y, et al. 46,XX sex reversal with partial duplication of chromosome arm 22q. *Am J Med Genet A* 2004; 127: 149–151.
1166. Ergun-Longmire B, Vinci G, Alonso L, et al. Clinical, hormonal and cytogenetic evaluation of 46,XX males and review of the literature. *J Pediatr Endocrinol Metab* 2005; 18: 739–748.
1167. Sanberg AA, Koepf GF, Ishihara T, et al. XYY human male. *Lancet* 1961; 2: 888.
1168. Briken P, Habermann N, Berner W, Hill A. XYY chromosome abnormality in sexual homicide perpetrators. *Am J Med Genet B Neuropsychiatr Genet* 2006; 141: 198–200.
1169. Geerts M, Steyaert J, Fryns JP. The XYY syndrome: a follow-up study on 38 boys. *Genet Couns* 2003; 14: 267–279.
1170. Baghdassarian A, Bayard F, Borgaonkar DS, et al. Testicular function in XYY men. *Johns Hopkins Med J* 1975; 136: 15–24.
1171. Skakkebaek NE, Hulten M, Jacobsen P, et al. Quantification of human seminiferous epithelium. II. Histological studies in eight 47, XYY men. *J Reprod Fertil* 1973; 32: 391–401.
1172. Speed RM, Faed MJ, Batstone PJ, et al. Persistence of two Y chromosomes through meiotic prophase and metaphase I in an XYY man. *Hum Genet* 1991; 87: 416–420.
1173. Rives N, Milazzo JP, Miraux L, et al. From spermatocytes to spermatozoa in an infertile XYY male. *Int J Androl* 2005; 28: 304–310.
1174. Miklos GL. Sex chromosome pairing and male fertility. *Cytogenet Cell Genet* 1974; 13: 558–577.
1175. Burgoyne PS, Sutcliffe MJ, Mahadevaiah SK. The role of unpaired sex chromosomes in spermatogenic failure. *Andrologia* 1992; 24: 17–20.
1176. Burgoyne PS. Evidence for an association between univalent Y chromosomes and spermatocyte loss in XYY mice and men. *Cytogenet Cell Genet* 1979; 23: 84–89.
1177. Hulten M. Meiosis in XYY men. *Lancet* 1970; 1: 717–718.
1178. Nielsen J, Johnsen SG. Pituitary gonadotrophins and 17-ketosteroids in patients with the XYY syndrome. *Acta Endocrinol* 1973; 72: 191–196.
1179. Lim AST, Fong Y, Yu SL. Analysis of the sex chromosome constitution of sperm in men with a 47,XYY mosaic karyotype by fluorescence in situ hybridization. *Fertil Steril* 1999; 72: 121–123.
1180. Hori N, Kato T, Sugimura Y, et al. A male subject with 3 Y chromosomes (48,XYYY): A case report. *J Urol* 1988; 139: 1059–1061.
1181. Venkataraman G, Craft I. Triple-Y syndrome following ICSI treatment in a couple with normal chromosomes: case report. *Hum Reprod* 2002; 17: 2560–2563.
1182. Sirota L, Zlotogora Y, Shabtai F, et al. 49 XYYYY. A case report. *Clin Genet* 1981; 19: 87–93.
1183. DesGroseilliers M, Lemyre E, Dallaire L, Lemieux N. Tetrasomy Y by structural rearrangement: clinical report. *Am J Med Genet* 2002; 111: 401–404.
1184. Vogt PH. Human Y chromosome function in male germ cell development (review). *Adv Dev Biol* 1996; 4: 191–257.
1185. Kent-First M, Muallem A, Shultz J, et al. Defining regions of the Y-chromosome responsible for male infertility and identification of a fourth AZF region (AZFd) by Y-chromosome microdeletion. *Mol Reprod Dev* 1999; 53: 27–41.
1186. Stuppia L, Gatta V, Fogh I, et al. Characterization of novel genes in AZF regions. *J Endocrinol Invest* 2000; 23: 659–663.
1187. Tiepolo L, Zuffardi O. Localization of factors controlling spermatogenesis in the nonfluorescent portion of the human Y chromosome long arm. *Hum Genet* 1976; 34: 119–124.
1188. Reijo R, Alagappan RK, Patrizio P, et al. Severe oligozoospermia resulting from deletions of

- azoospermia factor gene on Y chromosome. *Lancet* 1996; 347: 1290–1293.
1189. Hartung M, Devictor M, Codaccioni JL, et al. Yq deletion and failure of spermatogenesis. *Ann Genet* 1988; 31: 21–26.
1190. Kosztolanyi G, Trixler M. Yq deletion with short stature, abnormal male development, and schizoid character disorder. *J Med Genet* 1983; 20: 393–394.
1191. Codina-Pascual M, Oliver-Bonet M, Navarro J, et al. FISH characterization of a dicentric Yq (p11.32) isochromosome in an azoospermic male. *Am J Med Genet A* 2004; 127: 302–306.
1192. Daniel A. Y isochromosomes and rings. In: Sandber AA, ed. *The Y chromosome, Part B. Clinical aspects of Y chromosome abnormalities*. New York: Alan R Liss, 1985; 105–135.
1193. Chandley AC, Ambros P, McBeach S, et al. Short arm dicentric Y chromosome with associated statural defect in a sterile man. *Hum Genet* 1986; 73: 350–353.
1194. Giraud F, Mattei JF, Lucas C, et al. Four new cases of dicentric Y chromosomes. *Hum Genet* 1977; 36: 249–260.
1195. Chandley AC, Edmond P. Meiotic studies on a subfertile patient with a ring Y chromosome. *Cytogenetics* 1971; 10: 295–304.
1196. Bertini V, Canale D, Bicocchi MP, et al. Mosaic ring Y chromosome in two normal healthy men with azoospermia. *Fertil Steril* 2005; 84: 1744.
1197. Lin YH, Lin YM, Lin YH, et al. Ring (Y) in two azoospermic men. *Am J Med Genet A* 2004; 128: 209–213.
1198. Wahlström J. Y/Y translocations and their cytologic and clinical manifestation. In: Sandberg AA, ed. *The Y chromosome Part B: Clinical aspects of Y chromosome abnormalities*. New York: Alan R Liss, 1985; 207–212.
1199. Petit C, De la Chapelle A, Levilliers J, et al. An abnormal terminal X-Y interchange accounts for most but not all cases of human XX maleness. *Cell* 1987; 49: 595–602.
1200. Brisset S, Izard V, Misrahi M, et al. Cytogenetic, molecular and testicular tissue studies in an infertile 45,X male carrying an unbalanced (Y; 22) translocation: case report. *Hum Reprod* 2005; 20: 2168–2172.
1201. Pinho MJ, Neves R, Costa P, et al. Unique t(Y; 1)(q12; q12) reciprocal translocation with loss of the heterochromatic region of chromosome 1 in a male with azoospermia due to meiotic arrest: a case report. *Hum Reprod* 2005; 20: 689–696.
1202. Andersson M, Page DC, Pettay D, et al. Y; autosome translocations and mosaicism in the aetiology of 45,X maleness: assignment of fertility factor to distal Yq II. *Hum Genet* 1988; 79: 2–7.
1203. Andersson M, Page DC, Brown LG, et al. Characterization of a (Y; 4) translocation by DNA hybridization. *Hum Genet* 1988; 78: 377–381.
1204. Vogt P, Keil R, Kohler M, et al. Genome analysis: From sequence to function. *Adv Mol Genet* 1991; 4: 277–280.
1205. Girardi SK, Mielnik A, Schlegel PN. Submicroscopic deletions in the Y chromosome of infertile men. *Hum Reprod* 1997; 12: 1635–1641.
1206. Foresta C, Ferlin A, Garolla A, et al. Y-chromosome deletions in idiopathic severe testiculopathies. *J Clin Endocrinol Metab* 1997; 82: 1075–1080.
1207. Oliva R, Margarit E, Ballesta JL, et al. Prevalence of Y chromosome microdeletions in oligospermic and azoospermic candidates for intracytoplasmic sperm injection. *Fertil Steril* 1998; 70: 506–510.
1208. Dewan S, Puscheck EE, Coulam CB, et al. Y-chromosome microdeletions and recurrent pregnancy loss. *Fertil Steril* 2006; 85: 441–445.
1209. Johnson MD, Tho SPT, Behzadian A, et al. Molecular scanning of Yq 11 (interval 6) in men with Sertoli-cell-only syndrome. *Am J Obstet Gynecol* 1989; 161: 1732–1737.
1210. McElreavey K, Ravel C, Chantot-Bastaraud S, Siffroi JP. Y chromosome variants and male reproductive function. *Int J Androl* 2006; 29: 298–303.
1211. Telvi LT, Ion A, Carel J-C, et al. A duplication of distal Xp associated with hypogonadotropic hypogonadism, hypoplastic external genitalia, mental retardation, and multiple congenital abnormalities. *Med Genet* 1996; 33: 767–771.
1212. Solari AJ, Rahn IM, Ferreyra ME, Carballo MA. The behavior of sex chromosomes in two human X-autosome translocations: failure of extensive -inactivation spreading. *Biocell* 2001; 25: 155–166.
1213. Ma S, Yuen BH, Penaherrera M, et al. ICSI and the transmission of X-autosomal translocation: a three-generation evaluation of X; 20 translocation: case report. *Hum Reprod* 2003; 18: 1377–1382.
1214. Ogata T, Matsuo M, Muroya K, et al. 47,XXX male: a clinical and molecular study. *Am J Med Genet* 2001; 98: 353–356.
1215. Martin RH, Hulten M. Chromosome complements in 695 sperm from three men heterozygous for reciprocal translocations and a review of the literature. *Hereditas* 1993; 118: 165–175.
1216. Martin RH, Chernos JE, Lowry RB, et al. Analysis of sperm chromosome complements from a man heterozygous for a pericentric inversion of chromosome 1. *Hum Genet* 1994; 93: 135–138.
1217. Bache I, Assche EV, Cingoz S, et al. An excess of chromosome 1 breakpoints in male infertility. *Eur J Hum Genet* 2004; 12: 993–1000.
1218. Shapiro CE. Unbalanced chromosomal translocation associated with Sertoli-cell-only histology. *J Urol* 1991; 145: 563–564.
1219. Mercer ES, Broecker B, Smith EA, et al. Urological manifestations of Down syndrome. *J Urol* 2004; 171: 1250–1253.
1220. Sasagawa I, Nakada T, Hasihimoto T, et al. Hormone profiles and contralateral testicular histology in Down's syndrome with unilateral testicular tumor. *Arch Androl* 1993; 30: 93–98.
1221. Zuhlke C, Thies U, Braulke I, et al. Down syndrome and male fertility: PCR-derived fingerprinting, serological and andrological investigations. *Clin Genet* 1994; 46: 324–326.
1222. Kim ST, Cha YB, Park JM, Gye MC. Successful pregnancy and delivery from frozen-thawed embryos after intracytoplasmic sperm injection using round-headed spermatozoa and assisted oocyte activation in a globozoospermic patient with mosaic Down syndrome. *Fertil Steril* 2001; 75: 445–447.
1223. Cools M, Honecker F, Stoop H, et al. Maturation delay of germ cells in fetuses with trisomy 21 results in increased risk for the development of testicular germ cell tumors. *Hum Pathol* 2006; 37: 101–111.
1224. Johannisson R, Gropp A, Winking H, et al. Down syndrome in the male. Reproductive pathology and meiotic studies. *Hum Genet* 1983; 63: 132–138.
1225. Nistal M, Paniagua R. Hypogonadism due to primary testicular failure. In: Nistal M, Paniagua R, eds. *Testicular and epididymal pathology*. New York: Thieme-Stratton, 1984; 145–167.
1226. Tsilfidis C, MacKenzie AE, Mettler G, et al. Correlation between CTG trinucleotide repeat length and frequency of severe congenital myotonic dystrophy. *Nature Genet* 1992; 1: 192–195.
1227. Harley HG, Rundle SA, MacMillan JC, et al. Size of the unstable CTG repeat sequence in relation to phenotype and prenatal transmission in myotonic dystrophy. *Am J Hum Genet* 1993; 52: 1164–1174.
1228. Redman JB, Fenwick RG Jr, Fu YH, et al. Relationship between parenteral trinucleotide CTG repeat length and severity of myotonic dystrophy in offspring. *JAMA* 1993; 269: 1960–1965.
1229. Ranum LP, Day JW. Myotonic dystrophy: clinical and molecular parallels between myotonic

- dystrophy type 1 and type 2. *Curr Neurol Neurosci Rep* 2002; 2: 465–470.
1230. Brunner HG, Brüggerwirth HT, Nillesen W, et al. Influence of sex of the transmitting parent as well as of parental allele size on the CTG expansion in myotonic dystrophy (DM). *Am J Hum Genet* 1993; 53: 1016–1023.
1231. Kunej T, Teran N, Zorn B, Peterlin B. CTG amplification in the DM1PK gene is not associated with idiopathic male subfertility. *Hum Reprod* 2004; 19: 2084–2087.
1232. Marchini C, Lonigro R, Verriello L, et al. Correlations between individual clinical manifestations and CTG repeat amplification in myotonic dystrophy. *Clin Genet* 2000; 57: 74–82.
1233. Hauser W, Aulitzky W, Baltaci S, Frick J. Increasing infertility in myotonia dystrophica Curschmann–Steinert. A case report. *Eur Urol* 1991; 20: 341–342.
1234. Hoffman EP, Fischbeck KH, Brown RH, et al. Dystrophin characterization in muscle biopsies from Duchenne and Becker muscular dystrophy patients. *N Engl J Med* 1988; 318: 1363–1368.
1235. Ervasti JM. Dystrophin, its interactions with other proteins, and implications for muscular dystrophy. *Biochim Biophys Acta* 2007; 1772: 108–117.
1236. Kitao S, Ohsugi I, Ichikawa K, et al. Cloning of two new human helicase genes of the RECQ family: biological significance of multiple species in higher eukaryotes. *Genomics* 1998; 54: 443–452.
1237. Yu CE, Oshima J, Fu YM, et al. Positional cloning of the Werner's syndrome gene. *Science* 1996; 272: 258–262.
1238. Martin RH, Kademak A, German J. Chromosomal breakage in human spermatozoa, a heterozygous effect of the Bloom syndrome mutation. *Am J Hum Genet* 1994; 55: 1242–1246.
1239. Werner SR, Prahald AK, Yang J, Hock JM. RECQL4-deficient cells are hypersensitive to oxidative stress/damage: Insights for osteosarcoma prevalence and heterogeneity in Rothmund–Thomson syndrome. *Biochem Biophys Res Commun* 2006; 345: 403–409.
1240. Hamdani M, El Kettani A, Rais L, et al. Cockayne's syndrome with unusual retinal involvement (report of one family). *J Fr Ophtalmol* 2000; 23: 52–56.
1241. Landing BH, Sugarman G, Dixon LG. Eccrine sweat gland anatomy in cockayne syndrome: a possible diagnostic aid. *Pediatr Pathol* 1983; 1: 349–353.
1242. Arenas-Sordo M de L, Hernandez-Zamora E, Montoya-Perez LA, Aldape-Barrios BC. Cockayne's syndrome: a case report. Literature review. *Med Oral Patol Oral Cir Bucal* 2006; 11: e236–238.
1243. McCuaig C, Marcoux D, Rasmussen JE, et al. Trichothiodystrophy associated with photosensitivity, gonadal failure, and striking osteosclerosis. *J Am Acad Dermatol* 1993; 28: 820–826.
1244. Jamieson CR, Van der Burgt I, Brady AF, et al. Mapping a gene for Noonan syndrome to the long arm of chromosome 12. *Nature Genet* 1994; 8: 357–360.
1245. Tartaglia M, Gelb BD. Noonan syndrome and related disorders: genetics and pathogenesis. *Annu Rev Genomics Hum Genet* 2005; 6: 45–68.
1246. Nistal M, Paniagua R, Pallardo LF. Testicular biopsy and hormonal study in a male with Noonan's Syndrome. *Andrologia* 1983; 15: 415–425.
1247. Peters LL, Birkenmeier CS, Bronson RT, et al. Purkinje cell degeneration associated with erythroid ankyrin deficiency in nb/nb mice. *J Cell Biol* 1991; 114: 1233–1241.
1248. Harada T, Pineda LL, Nakano A, et al. Ataxia and male sterility (AMS) mouse. A new genetic variant exhibiting degeneration and loss of cerebellar Purkinje cells and spermatogenic cells. *Pathol Int* 2003; 53: 382–389.
1249. Kakar SS. Molecular structure of the human gonadotropin-releasing hormone receptor gene. *Eur J Endocrinol* 1997; 137: 183–192.
1250. Seminara SB, Hayes FJ, Crowley WF Jr. Gonadotropin-Releasing hormone deficiency in the human (idiopathic hypogonadotropic hypogonadism and Kallmann's syndrome): pathophysiological and genetic considerations. *Endocrinol Rev* 1998; 19: 521–539.
1251. Pallardo LF, Santiago M, Cerdán A, et al. Algunos aspectos del eunucoidismo hipogonadotrópico. *Med Clin* 1972; 59: 390–396.
1252. Pralong FP, Gomez F, Castillo E, et al. Complete hypogonadotropic hypogonadism associated with a novel inactivating mutation of the gonadotropin-releasing hormone receptor. *J Clin Endocrinol Metab* 1999; 84: 3811–3816.
1253. Boyar R, Finkelstein J, Roffwang H, et al. Synchronization of augmented luteinizing hormone secretion with sleep during puberty. *N Engl J Med* 1972; 287: 582–586.
1254. Pitteloud N, Hayes FD, Dwyer A, et al. Predictors of outcome of long-term GnRH therapy in men with idiopathic hypogonadotropic hypogonadism. *J Clin Endocrinol Metab* 2002; 87: 4128–4136.
1255. Nistal M, Paniagua R. Hypogonadism due to secondary testicular failure. In: Nistal M, Paniagua R, eds. *Testicular and epididymal pathology*. New York: Thieme-Stratton, 1984; 169–177.
1256. Maestre de San Juan A. Falta total de nervios olfatorios con anosmia en un individuo en quien existía una atrofia congénita de los testículos y miembro viril. *Siglo Médico* 1856; 131: 211–214.
1257. Kallmann FJ, Shoenfeld WA, Barrera SE. The genetic aspects of primary eunuchoidism. *Am J Ment Defic* 1944; 48: 203–236.
1258. De Morsier G, Gauthier G. La dysplasie olfacto-génitale. *Pathol Biol* 1963; 11: 1267–1271.
1259. Yoshida K, Rutishauser U, Crandall JE, et al. Polysialic acid facilitates migration of luteinizing hormone-releasing hormone neurons on vomeronasal axons. *J Neurosci* 1999; 19: 794–801.
1260. Tsai PS, Gill JC. Mechanisms of disease: Insights into X-linked and autosomal-dominant Kallmann syndrome. *Nature Clin Pract Endocrinol Metab* 2006; 2: 160–171.
1261. Pitteloud N, Meysing A, Quinton R, et al. Mutations in fibroblast growth factor receptor 1 cause Kallmann syndrome with a wide spectrum of reproductive phenotypes. *Mol Cell Endocrinol* 2006; 254–255: 60–69.
1262. Happ J, Ditscheid W, Krause U. Pulsatile gonadotropin-releasing therapy in male patients with Kallmann's syndrome or constitutional delay of puberty. *Fertil Steril* 1985; 43: 599–608.
1263. Enríquez L, Díaz-Rubio M, Zamarrón A, et al. Hipogonadismo hipogonadotrópico con anosmia. *Rev Clin Esp* 1973; 131: 383–392.
1264. Pervaiz N, Hagedoorn J, Mininberg DT. Electron microscopic studies of testes in Kallmann syndrome. *Urology* 1979; 14: 267–269.
1265. Albers DD, Males JL. Seminoma in hypogonadotropic hypogonadism associated with anosmia (Kallmann's syndrome). *J Urol* 1981; 126: 57–58.
1266. Berger K, Souza H, Brito VN, et al. Clinical and hormonal features of selective follicle-stimulating hormone (FSH) deficiency due to FSH β -subunit gene mutations in both sexes. *Fertil Steril* 2005; 83: 466–470.
1267. Lamminen T, Jokinen P, Jiang M, et al. Human FSH β subunit gene is highly conserved. *Mol Hum Reprod* 2005; 11: 601–605.
1268. Al-Ansari AAK, Khalil TH, Kelani Y, Mortimer CH. Isolated follicle-stimulating hormone deficiency in men: successful long-term gonadotropin therapy. *Fertil Steril* 1984; 42: 618–626.
1269. Pasqualini RQ, Bur GE. Síndrome hipoandrogénico con gametogénesis conservada: clasificación de la insuficiencia testicular. *Rev Asoc Med Argent* 1950; 64: 6–10.
1270. Pasqualini RQ, Bur GE. Hypoandrogenic syndrome with spermatogenesis. *Fertil Steril* 1955; 6: 144–157.

1271. McCullagh EP, Beck JC, Schaffenburg CA. A syndrome of eunuchoidism with spermatogenesis, normal urinary FSH, and low-normal ICSH ('fertile eunuchs'). *J Clin Endocrinol Metab* 1953; 13: 489–509.
1272. Shiraishi K, Naito K. Fertile eunuch syndrome with the mutations (Trp8Arg and Ile15Thr) in the β subunit of luteinizing hormone. *Endocrinol J* 2003; 50: 733–737.
1273. Pitteloud N, Boepple PA, DeCruz S, et al. The fertile eunuch variant of idiopathic hypogonadotropic hypogonadism: spontaneous reversal associated with a homozygous mutation in the gonadotropin-releasing hormone receptor. *J Clin Endocrinol Metab* 2001; 86: 2470–2475.
1274. Weiss J, Axelrod L, Whitcomb RW, et al. Hypogonadism caused by a single amino acid substitution in the β subunit of luteinizing hormone. *N Engl J Med* 1992; 326: 179–183.
1275. Layman LC, Porto AL, Xie J, et al. FSH β gene mutations in a female with partial breast development and a male sibling with normal puberty and azoospermia. *J Clin Endocrinol Metab* 2002; 87: 3702–3707.
1276. Tato L, Zamboni G, Antoniazzi F, et al. Gonadal function and response to growth hormone (GH) in boys with isolated GH deficiency and to GH and gonadotropins in boys with multiple pituitary hormone deficiencies. *Fertil Steril* 1996; 65: 830–834.
1277. Prader A, Labhart A, Willi H. Ein syndrom von Adipositas, Kleinwuchs, Kryptorchismus, und Oligophrenie nach myotonieartigen Zustand in Neugeborenenalter. *Schweiz Med Wschr* 1956; 86: 1260–1261.
1278. Eiholzer U, l'Allemand D, Rousson V, et al. Hypothalamic and gonadal components of hypogonadism in boys with Prader–Labhart–Willi syndrome. *J Clin Endocrinol Metab* 2006; 91: 892–898.
1279. Uehling D. Cryptorchidism in the Prader–Willi syndrome. *J Urol* 1980; 124: 103–104.
1280. Martín-Zurro A, Sánchez-Franco F, Cerdán-Vallejo A, et al. Síndrome de Prader–Willi. *Rev Clin Esp* 1972; 125: 5–15.
1281. Young TL, Penney L, Woods MO, et al. A fifth locus for Bardet–Biedl syndrome maps to chromosome 2q31. *Am J Hum Genet* 1999; 64: 900–904.
1282. Blacque OE, Leroux MR. Bardet–Biedl syndrome: an emerging pathomechanism of intracellular transport. *Cell Mol Life Sci* 2006; 63: 2145–2161.
1283. Maya-Núñez G, Torres L, Ulloa-Aguirre A, et al. An atypical contiguous gene syndrome: molecular studies in a family with X-linked Kallmann's syndrome and X-linked ichthyosis. *Clin Endocrinol* 1999; 50: 157–162.
1284. Cushman LJ, Torres-Martinez W, Weaver DD, Johnson–McMillin syndrome: report of a new case with novel features. *Birth Defects Res A Clin Mol Teratol* 2005; 73: 638–641.
1285. Savitsky K, Bar-Shira A, Gilad S, et al. A single ataxia telangiectasia gene with a product similar to PI-3 kinase. *Science* 1995; 268: 1749–1753.
1286. Frappart PO, McKinnon PJ. Ataxia-telangiectasia and related diseases. *Neuromol Med* 2006; 8: 495–512.
1287. Carvajal JJ, Pook MA, Dos Santos M, et al. The Friedreich's ataxia gene encodes a novel phosphatidylinositol-4-phosphatase 5-kinase. *Nature Genet* 1996; 14: 157–162.
1288. Pandolfo M. Friedreich ataxia: Detection of GAA repeat expansions and frataxin point mutations. *Meth Mol Med* 2006; 126: 197–216.
1289. Sigman M, Jarow JP. Endocrine evaluation of infertile men. *Urology* 1997; 50: 659–664.
1290. Burge MR, Lanzi RA, Skarda ST, et al. Idiopathic hypogonadotropic hypogonadism in a male runner is reversed by clomiphene citrate. *Fertil Steril* 1997; 67: 783–785.
1291. Veldhuis JB, Hammond JM. Endocrine function after spontaneous infarction of the human pituitary. Report, review and reappraisal. *Endocrinol Rev* 1980; 1: 100–107.
1292. Tash J, McGovern JH, Schlegel PN. Acquired hypogonadotropic hypogonadism presenting as decreased seminal volume. *Urology* 2000; 56: 669.
1293. Zárate A, Fonseca ME, Mason M, et al. Gonadotropin-secreting pituitary adenoma with concomitant hypersecretion of testosterone and elevated sperm count. Treatment with LRH agonists. *Acta Endocrinol* 1986; 113: 29–34.
1294. Heseltine D, White MC, Kendall-Taylor P, et al. Testicular enlargement and elevated serum inhibin concentrations occur in patients with pituitary macroadenomas secreting follicle stimulating hormone. *Clin Endocrinol* 1989; 31: 411–423.
1295. Corona G, Petrone L, Mannucci E, et al. The impotent couple: low desire. *Int J Androl* 2005; 28: 46–52.
1296. Bouhdiba M, Leroy-Martin B, Peyrat JP, et al. Immunohistochemical detection of prolactin and its receptors in human testis. *Andrologia* 1989; 21: 223–228.
1297. Cameron DF, Murray FT, Drylie D. Ultrastructural lesions in testes from hyperprolactinemic men. *J Androl* 1984; 5: 285–293.
1298. Eggert-Kruse W, Schwalbach B, Gerhard I, et al. Influence of serum prolactin on semen characteristics and sperm function. *Int J Fertil* 1991; 36: 243–251.
1299. Murray FT, Cameron DF, Ketchum C. Return of gonadal function in men with prolactin-secreting tumors. *J Clin Endocrinol Metab* 1984; 59: 79–85.
1300. Ford HC, Cooke RR, Keightley EA, et al. Serum levels of free and bound testosterone in hyperthyroidism. *Clin Endocrinol* 1992; 36: 187–192.
1301. Hudson RW, Edwards AL. Testicular function in hyperthyroidism. *J Androl* 1992; 13: 117–124.
1302. Willey KP, Hunt N, Castel MA, et al. Graves' autoimmune serum inhibits gonadal steroidogenesis. Development of a Leydig cell bioassay to identify broad spectrum anti-endocrine autoantibodies. *J Reprod Immunol* 1993; 24: 45–63.
1303. De La Balze F, Arillaga F, Mancini RE, et al. Male hypogonadism in hypothyroidism: A study of six cases. *J Clin Endocrinol Metab* 1962; 22: 212–222.
1304. Krassas GE, Pontikides N. Male reproductive function in relation with thyroid alterations. *Best Pract Res Clin Endocrinol Metab* 2004; 18: 183–95.
1305. Donnelly P, White C. Testicular dysfunction in men with primary hypothyroidism; reversal of hypogonadotropic hypogonadism with replacement thyroxine. *Clin Endocrinol* 2000; 52: 197–201.
1306. Corrales-Hernández JJ, Miralles García JM, García-Díez LC. Primary hypothyroidism and human spermatogenesis. *Arch Androl* 1990; 25: 21–27.
1307. Buitrago JM, Garía-Díez LC. Serum hormones and seminal parameters in males with thyroid disturbance. *Andrologia* 1987; 19: 37–41.
1308. Weber G, Vigone MC, Stroppa L, et al. Thyroid function and puberty. *J Pediatr Endocrinol Metab* 2003; 16: 253–257.
1309. Loke KY, Larry KS, Lee YS, et al. Prepubertal diagnosis of X-linked congenital adrenal hypoplasia presenting after infancy. *Eur J Pediatr* 2000; 159: 671–675.
1310. Calvari V, Alpigliani mg, Poggi E, et al. X-linked adrenal hypoplasia congenita and hypogonadotropic hypogonadism: report on new mutation of the DAX-1 gene in two siblings. *J Endocrinol Invest* 2006; 29: 41–47.
1311. Seminara SB, Achermann JC, Gene LM, et al. X-linked adrenal hypoplasia congenita: a mutation in DAX1 expands the phenotypic spectrum in males and females. *J Clin Endocrinol Metab* 1999; 84: 4501–4509.
1312. Sugino Y, Usui T, Okubo K, et al. Genotyping of congenital adrenal hyperplasia due to 21-hydroxylase deficiency presenting as male infertility: Case report and literature review. *J Assist Reprod Genet* 2006; 23: 377–380.
1313. Bonaccorsi AC, Adler I, Figueiredo JG. Male infertility due to congenital

- adrenal hyperplasia: testicular biopsy findings, hormonal evaluation, and therapeutic results in three patients. *Fertil Steril* 1987; 47: 664–670.
1314. Burke EF, Gilbert E, Uehling DT. Adrenal rest tumors of the testes. *J Urol* 1973; 109: 649–652.
1315. Oberman AS, Flatau E, Luboshitzki R. Bilateral testicular adrenal rests in a patient with 11-hydroxylase deficient congenital adrenal hyperplasia. *J Urol* 1993; 149: 350–352.
1316. Cutfield RG, Bateman JM, Odell WD. Infertility caused by bilateral testicular masses secondary to congenital adrenal hyperplasia (21-hydroxylase deficiency). *Fertil Steril* 1983; 40: 809–814.
1317. Cara JF, Moshang T Jr, Bongiovanni AM, et al. Elevated 17-hydroxyprogesterone and testosterone in a newborn with 3 β -hydroxysteroid dehydrogenase deficiency. *N Eng J Med* 1985; 313: 618–621.
1318. Sasano H, Masuda T, Ojima M, et al. Congenital 17 α -hydroxylase deficiency: A clinico-pathologic study. *Hum Pathol* 1987; 18: 1002–1007.
1319. Battaglia M, Ditunno P, Palazzo S, et al. Bilateral tumors of the testis in 21-alpha hydroxylase deficiency without adrenal hyperplasia. *Urol Oncol* 2005; 23: 178–180.
1320. Watanabe T, Yasuda T, Noda H, et al. Estrogen secreting adrenal adenocarcinoma in an 18-month-old boy: aromatase activity, protein expression, mRNA and utilization of gonadal type promoter. *Endocrinol J* 2000; 47: 723–730.
1321. Dinulovic D, Radonjic G. Diabetes mellitus/male infertility. *Arch Androl* 1990; 25: 277–293.
1322. Elamin A, Hussein O, Tuvemo T. Growth, puberty, and final height in children with type 1 diabetes. *J Diabetes Complications* 2006; 20: 252–256.
1323. Ballester J, Munoz MC, Dominguez J, et al. Insulin-dependent diabetes affects testicular function by FSH- and LH-linked mechanisms. *J Androl* 2004; 25: 706–719.
1324. García-Díez LC, Corrales-Hernández J, Hernández-Díaz J, et al. Semen characteristics and diabetes mellitus: significance of insulin in male infertility. *Arch Androl* 1991; 26: 219–227.
1325. Cameron DF, Murray FT, Drylie DD. Interstitial compartment pathology and spermatogenic disruption in testes from impotent diabetic men. *Anat Rec* 1985; 213: 53–62.
1326. Quadri R, Veglio M, Flecchia D, et al. Autonomic neuropathy and sexual impotence in diabetic patients: Analysis of cardiovascular reflexes. *Andrologia* 1989; 21: 346–352.
1327. Regadera J, Nistal M, Paniagua R. Idiopathic vas deferens calcification. *Morfol Normal Patol B* 1983; 8: 219–223.
1328. Lemna WK, Feldman GL, Kerem B, et al. Mutation analysis for heterozygote detection and the prenatal diagnosis of cystic fibrosis. *N Engl J Med* 1990; 322: 291–296.
1329. Stuhmann M, Dork T. CFTR gene mutations and male infertility. *Andrologia* 2000; 32: 71–83.
1330. Denning CR, Sommers SC, Herbert J, et al. Infertility in male patients with cystic fibrosis. *Pediatrics* 1968; 41: 7–17.
1331. Feigelson J, Pecau Y. Anomalies du sperme, des deferents et de l'epididyme dans la mucoviscidose. *Presse Med* 1986; 15: 523–525.
1332. Osborne L, Knight RA, Santis G, et al. A mutation in the second nucleotide binding fold of the cystic fibrosis gene. *Am J Hum Genet* 1991; 48: 608–612.
1333. Lewis-Jones DI, Gazvani MR, Mountford R. Cystic fibrosis in infertility: screening before assisted reproduction: opinion. *Hum Reprod* 2000; 15: 2415–2417.
1334. Schellen TM, Van Straatten A. Autosomal recessive hereditary congenital aplasia of the vasa deferentia in four siblings. *Fertil Steril* 1980; 34: 401–404.
1335. Anguiano A, Oates RD, Amos JA, et al. Congenital bilateral absence of the vas deferens. A primary genital form of cystic fibrosis. *JAMA* 1992; 267: 1794–1797.
1336. Olson JR, Weaver DK. Congenital mesonephric defects in male infants with mucoviscidosis. *J Clin Pathol* 1969; 22: 725–730.
1337. Holsclaw DS, Perlmutter AD, Jockin H, et al. Genital abnormalities in male patients with cystic fibrosis. *J Urol* 1971; 106: 568–574.
1338. Silvestrini R. La reviviscenza mammaria nell'uomo affetto da cirrosi del Laennec. *Riforma Med* 1926; 42: 701–704.
1339. Corda L. Sulla c.d. reviviscenza della mammella maschile nella cirrosi epatica (nota preventiva). *Minerva Medica* 5: 1064–1067, 1925.
1340. Van Thiel DH, Lester R, Sherins RJ. Hypogonadism in alcoholic liver disease: evidence for a double defect. *Gastroenterology* 1974; 67: 1188–1199.
1341. Comathi C, Balasubramanian K, Vijayabhanu N, et al. Effect of chronic alcoholism on semen – studies on lipid profiles. *Int J Androl* 1993; 16: 175–181.
1342. Galvao-Teles A, Goncalves L, Carvalho H, Monteiro E. Alterations of testicular morphology in alcoholic disease. *Alcohol Clin Exp Res* 1983; 7: 144–149.
1343. Terasaki T, Nowlin DM, Partridge WM. Differential binding of testosterone and oestradiol to isoforms of sex hormone binding globulin: selective alteration of estradiol binding in cirrhosis. *J Clin Endocrinol Metab* 1988; 67: 639–643.
1344. Gluud, C and the Copenhagen Study Group for Liver Diseases. Serum testosterone concentration in men with alcoholic cirrhosis: background for variation. *Metabolism* 1987; 36: 373–378.
1345. Zifroni A, Schiavi RC, Schaffner F. Sexual function and testosterone levels in men with nonalcoholic liver disease. *Hepatology* 1991; 14: 479–482.
1346. Handelsman DJ, Conway AJ, Boylan LM, et al. Testicular function and fertility in men with homozygous alpha-1 antitrypsin deficiency. *Andrologia* 1986; 18: 406–412.
1347. Niederau C. Hereditary hemochromatosis. *Internist* 2003; 44: 191–205.
1348. Jazwinska EC, Cullen LM, Busfield F, et al. Haemochromatosis and HLA-H. *Nature Genet* 1996; 14: 249–251.
1349. Feder JN, Gnirke A, Thomas W, et al. A novel MHC class 1-like gene is mutated in patients with hereditary haemochromatosis. *Nature Genet* 1996; 13: 399–408.
1350. Rivard SR, Mura C, Simard H, et al. Clinical and molecular aspects of juvenile hemochromatosis in Saguenay-Lac-Saint-Jean (Quebec, Canada). *Blood Cells Mol Dis* 2000; 26: 10–14.
1351. Roetto A, Totaro A, Cazzola M, et al. Juvenile hemochromatosis locus maps to chromosome 1q. *Am J Hum Genet* 1999; 64: 1388–1393.
1352. Camaschella C, Roetto A, De Gobbi M. Juvenile hemochromatosis. *Semin Hematol* 2002; 39: 242–248.
1353. Berent R, Allinger S, Hobling W, et al. A 24-year-old patient with decreased libido and erectile dysfunction as initial manifestations of hemochromatosis. *Dtsch Med Wochenschr* 2000; 125: 1466–1468.
1354. Paris I, Hermans M, Buysschaert M. Endocrine complications of genetic hemochromatosis. *Acta Clin Belg* 54: 334–345, 1999.
1355. McDermott JH, Walsh CH. Hypogonadism in hereditary hemochromatosis. *J Clin Endocrinol Metab* 2005; 90: 2451–2455.
1356. Kontogeorgos G, Handy S, Kovacs K, et al. The anterior pituitary in hemochromatosis. *Endocrinol Pathol* 1996; 7: 159–164.
1357. Angelopoulos NG, Goula A, Dimitriou E, et al. Reversibility of hypogonadotropic hypogonadism in a patient with the juvenile form of hemochromatosis. *Fertil Steril* 2005; 84: 1744.
1358. Manno M, Marchesan E, Tomei F, et al. Polycystic kidney disease and infertility: case report and literature review. *Arch Ital Urol Androl* 2005; 77: 25–28.
1359. Li Vecchi M, Cianfrone P, Damiano R, et al. Infertility in adults with

- polycystic kidney disease. *Nephrol Dial Transplant* 2003; 18: 190–191.
1360. Fang S, Baker HW. Male infertility and adult polycystic kidney disease are associated with necrospemia. *Fertil Steril* 2003; 79: 643–644.
1361. Peces R, Venegas JL. Seminal vesicle cysts and infertility in autosomal dominant polycystic kidney disease. *Nefrologia* 2005; 25: 78–80.
1362. Behre HM, Kliesch S, Schadel F, et al. Clinical relevance of scrotal and transrectal ultrasonography in andrological patients. *Int J Androl* 1995; 2: 27–31.
1363. Van Steenbergen MW, Wit JM, Donckerwolcke RA. Testosterone esters advance skeletal maturation more than growth in short boys with chronic renal failure and delayed puberty. *Eur J Pediatr* 1991; 150: 676–680.
1364. Blackman MR, Weintraub BD, Kourides IA, et al. Discordant elevation of the common alpha subunit of the glycoprotein hormones compared to β subunits in serum of uremic patients. *J Clin Endocrinol Metab* 1981; 53: 39–48.
1365. Holsdsworth S, Atkins RC, De Kretser DM. The pituitary testicular axis in men with chronic renal failure. *N Engl J Med* 1977; 296: 1245–1249.
1366. Elias AN, Vaziri ND, Farooqui S, et al. Pathology of endocrine organs in chronic renal failure. An autopsy analysis of 66 patients. *Int J Artif Organs* 1984; 7: 251–256.
1367. Guvel S, Pourbagher MA, Torun D, et al. Calcification of the epididymis and the tunica albuginea of the corpora cavernosa in patients on maintenance hemodialysis. *J Androl* 2004; 25: 752–756.
1368. Ketteler M, Vermeer C, Wanner C, et al. Novel insights into uremic vascular calcification: role of matrix Gla protein and alpha-2-heremans Schmid glycoprotein/fetuin. *Blood Purif* 2002; 20: 473–476.
1369. Nistal M, Jimenez-Hefferman JA, Garcia-Viera M, et al. Cystic transformation and calcium oxalate deposits in rete testis and efferent ducts in dialysis patients. *Hum Pathol* 1996; 27: 336–341.
1370. Lim VS, Fang VS. Gonadal dysfunction in uremic men. A study of the hypothalamo-pituitary-testicular axis before and after renal transplantation. *Am J Med* 1975; 58: 655–662.
1371. Enmanouel DS, Lindheimer MD, Katz AI. Pathogenesis of endocrine abnormalities in uremia. *Endocrinol Rev* 1980; 1: 28–44.
1372. Cowden EA, Ratcliffe WA, Ratcliffe JG, et al. Hypothalamic-pituitary function in uremia. *Acta Endocrinol* 1981; 98: 488–495.
1373. El-Tawil AM. Zinc deficiency in men with Crohn's disease may contribute to poor sperm function and male infertility. *Andrologia* 2003; 35: 337–341.
1374. Hrudka F, Singh A. Sperm nucleomalacia in men with inflammatory bowel disease. *Arch Androl* 1984; 13: 37–57.
1375. Cosentino MJ, Chey WY, Takihara H, et al. The effects of sulphasalazine on human male fertility potential and seminal prostaglandins. *J Urol* 1984; 132: 682–686.
1376. Chermesh I, Eliakim R. Mesalazine-induced reversible infertility in a young male. *Dig Liver Dis* 2004; 36: 551–552.
1377. Di Paolo MC, Paoluzi OA, Pica R, et al. Sulphasalazine and 5-aminosalicylic acid in long-term treatment of ulcerative colitis: report on tolerance and side-effects. *Dig Liver Dis* 2001; 33: 563–569.
1378. Hengge UR. Testosterone replacement for hypogonadism: clinical findings and best practices. *AIDS Read* 2003; 13: S15–21.
1379. Cohan GR. HIV-associated hypogonadism. *AIDS Read* 2006; 16: 341–345.
1380. Berger D, Muurahainen N, Wittert H, et al. Hypogonadism and wasting in the era of HAART in HIV-infected patients. Twelfth World AIDS Conference, Geneva, Switzerland, 1998 [Abstract 32174].
1381. Rietschel P, Corcoran C, Stanley T, et al. Prevalence of hypogonadism among men with weight loss related to human immunodeficiency virus infection who are receiving highly active antiretroviral therapy. *Clin Infect Dis* 2000; 31: 1240–1244.
1382. Grinspoon S, Corcoran C, Lee K, et al. Loss of lean body mass and muscle mass correlates with androgen levels in hypogonadal men with acquired immunodeficiency syndrome and wasting. *J Clin Endocrinol Metab* 1996; 81: 4051–4058.
1383. Grinspoon S, Corcoran C, Stanley T, et al. Effects of hypogonadism and testosterone administration on depression indices in HIV-infected men. *J Clin Endocrinol Metab* 2000; 85: 60–65.
1384. Wahlstrom JT, Tang A, Cofrancesco J, et al. Gonadal hormone levels in injection drug users. *Drug Alcohol Depend* 2000; 60: 311–313.
1385. Dobs S, Dempsey MA, Ladenson PW, et al. Endocrine disorders in men infected with human immunodeficiency virus. *Am J Med* 1988; 84: 611–616.
1386. Salehian B, Jacobson D, Swerdloff RS, et al. Testicular pathologic changes and the pituitary-testicular axis during human immunodeficiency virus infection. *Endocrinol Pract* 1999; 5: 1–9.
1387. Pintor C, Loche S, Puggioni R, et al. Adrenal and testicular function in boys affected by thalassemia. *J Endocrinol Invest* 1984; 7: 147–149.
1388. De Sanctis V, Roos M, Gasser T, et al. Italian Working Group on Endocrine Complications in Non-Endocrine Diseases. Impact of long-term iron chelation therapy on growth and endocrine functions in thalassaemia. *J Pediatr Endocrinol Metab* 2006; 19: 471–480.
1389. Al-Rimawi HS, Jallad MF, Amarín ZO, et al. Pubertal evaluation of adolescent boys with β -thalassaemia major and delayed puberty. *Fertil Steril* 2006; 86: 886–890.
1390. Moayeri H, Oloomi Z. Prevalence of growth and puberty failure with respect to growth hormone and gonadotropins secretion in β -thalassaemia major. *Arch Iran Med* 2006; 9: 329–334.
1391. De Sanctis V. Growth and puberty and its management in thalassaemia. *Hormone Res* 2002; 58: 72–79.
1392. Soliman AT, El-Zalabany MM, Ragab M, et al. Spontaneous and GnRH-provoked gonadotropin secretion and testosterone response to human chorionic gonadotropin in adolescent boys with thalassaemia major and delayed puberty. *J Trop Pediatr* 2000; 46: 79–85.
1393. Globerman H, Shen-Orr Z, Karnieli E, et al. Inhibin B in men with severe obesity and after weight reduction following gastroplasty. *Endocrinol Res* 2005; 31: 17–26.
1394. Norman RJ, Clark AM. Obesity and reproductive disorders: a review. *Reprod Fertil Dev* 1998; 10: 55–63.
1395. Pasquali R. Obesity, fat distribution and infertility. *Maturitas* 2006; 20: 363–371.
1396. Boe AS, Knappskog PM, Myhre AG, et al. Mutational analysis of the autoimmune regulator (AIRE) gene in sporadic autoimmune Addison's disease can reveal patients with unidentified autoimmune polyendocrine syndrome type I. *Eur J Endocrinol* 2002; 146: 519–522.
1397. Meyer G, Badenhop K. Autoimmune regulator (AIRE) gene on chromosome 21: implications for autoimmune polyendocrinopathy-candidiasis-ectodermal dystrophy (APECED) any more common manifestations of endocrine autoimmunity. *J Endocrinol Invest* 2002; 25: 804–811.
1398. Smith BR, Furmaniak J. Adrenal and gonadal autoimmune diseases. *J Clin Endocrinol Metab* 1995; 80: 1502–1505.
1399. Krohn K, Uiibo R, Aavik E, et al. Identification by molecular cloning of an autoantigen associated with Addison's disease as steroid 17 alpha-hydroxylase. *Lancet* 1992; 339: 770–773.
1400. Winqvist O, Gustafsson J, Rorsman F, et al. Two different cytochrome p450 enzymes are the adrenal antigens in autoimmune polyendocrine syndrome type I and Addison's

- disease. *J Clin Invest* 1993; 92: 2377–2385.
1401. Soderbergh A, Myhre AG, Ekwall O, et al. Prevalence and clinical associations of 10 defined autoantibodies in autoimmune polyendocrine syndrome type I. *Clin Endocrinol Metab* 2004; 89: 557–562.
1402. Trencé DL, Morley JE, Handwerker BS. Polyglandular autoimmune syndromes. *Am J Med* 1984; 77: 107–116.
1403. Barkan AL, Kelch RP, Marshall JC. Isolated gonadotrope failure in the polyglandular autoimmune syndrome. *N Engl J Med* 1985; 312: 1535–1540.
1404. Faggiano A, Pisani A, Milone F, et al. Endocrine dysfunction in patients with Fabry disease. *J Clin Endocrinol Metab* 2006; 91: 4319–4325.
1405. Nistal M, Paniagua R, Picazo ML. Testicular and epididymal involvement in Fabry's disease. *J Pathol* 141: 113–124, 1983.
1406. Eng C, Guffon N, Wilcox WR, et al. Safety and efficacy of recombinant human alpha-galactosidase A replacement therapy in Fabry's disease. *N Engl J Med* 2001; 345: 9–16.
1407. Desnick RJ, Brady R, Barranger J, et al. Fabry disease, an under-recognized multisystemic disorder: expert recommendations for diagnosis, management, and enzyme replacement therapy. *Ann Intern Med* 2003; 138: 338–346.
1408. Schwarting A, Dehout F, Feriozzi S, et al. Enzyme replacement therapy and renal function in 201 patients with Fabry disease. *Clin Nephrol* 2006; 66: 77–84.
1409. Mosser J, Douar AM, Sarde CO, et al. Putative X-linked adrenoleukodystrophy gene shares unexpected homology with ABC transporters. *Nature* 1993; 361: 726–730.
1410. Graham GE, MacLeod PM, Lillicrap DP, et al. Gonadal mosaicism in a family with adrenoleukodystrophy. Molecular diagnosis of carrier status among daughters of a gonadal mosaic when direct detection of the mutation is not possible. *J Inherit Metab Dis* 1992; 15: 68–74.
1411. Jia Z, Pei Z, Li Y, et al. X-linked adrenoleukodystrophy: role of very long-chain acyl-CoA synthetases. *Mol Genet Metab* 2004; 83: 117–127.
1412. Libber SM, Migeon CJ, Brown FR, et al. Adrenal and testicular function in 14 patients with adrenoleukodystrophy or adrenomyeloneuropathy. *Hormone Res* 1986; 24: 1–8.
1413. Powers JM, Schaumburg HH. The testis in adrenoleukodystrophy. *Am J Pathol* 1981; 102: 90–98.
1414. Anderson RA, Rao N, Byrum RS, et al. In situ localization of the genetic locus encoding the lysosomal acid lipase/cholesterol esterase (LIPA) deficient in Wolman disease to chromosome 10q23.2-q23.3. *Genomics* 1993; 15: 245–247.
1415. Contreras F, Alvarez I, Nistal M, et al. Enfermedad de Wolman. Estudio anatomopatológico de dos observaciones. *Patología* 1974; 7: 189–200.
1416. Elleder M, Chlumská A, Ledvinová J, et al. Testis – a novel storage site in human cholesterol ester storage disease. Autopsy report of an adult case with a long-standing subclinical course complicated by accelerated atherosclerosis and liver carcinoma. *Virchows Arch* 2000; 436: 82–87.
1417. Stein J, Garty BZ, Dror Y, et al. Successful treatment of Wolman disease by unrelated umbilical cord blood transplantation. *Eur J Pediatr* 2007; 166: 663–665.
1418. Chik CL, Friedman A, Merriam GR, et al. Pituitary–testicular function in nephropathic cystinosis. *Ann Intern Med* 1993; 119: 568–575.
1419. Suzuki K, Suzuki K. Lysosomal diseases. In: Graham DI, Lantos PL, eds. *Greenfield's neuropathology*, 7th edn. Oxford: Arnold, 2002; 673–712.
1420. Brinkworth MH, Handelsman DJ. Environmental influences on male reproductive health. In: Nieschlag S, Behre HM, eds. *Andrology. Male reproductive health and dysfunction*, 2nd edn. Berlin: Springer Verlag, 2000; 253–270.
1421. Schrag SD, Dixon RL. Occupational exposures associated with male reproductive dysfunction. *Annu Rev Pharmacol Toxicol* 1985; 25: 567–592.
1422. Swan SH. Semen quality in fertile US men in relation to geographical area and pesticide exposure. *Int J Androl* 2006; 29: 62–68.
1423. De Celis R, FERIA-Velasco A, González-Unzaga M, et al. Semen quality of workers occupationally exposed to hydrocarbons. *Fertil Steril* 2000; 73: 221–228.
1424. Meyer CR. Semen quality in workers exposed to carbon disulfide compared to a control group from the same plant. *J Occup Med* 1981; 23: 435–439.
1425. Wagar G, Tolonen M, Stenman UH, Helpio E. Endocrinologic studies in men exposed occupationally to carbon disulfide. *J Toxicol Environ Health* 1981; 7: 363–371.
1426. Kapp RW Jr, Picciano DJ, Jacobson CB. Y-chromosomal nondysjunction in dibromochloropropane exposed workmen. *Mutat Res* 1979; 64: 47–51.
1427. Naha N, Chowdhury AR. Inorganic lead exposure in battery and paint factory: effect on human sperm structure and functional activity. *J UOEH* 2006; 28: 157–171.
1428. Lancranjan I, Popescu HI, Gavanescu O, et al. Reproductive ability of workmen occupationally exposed to lead. *Arch Environ Health* 1975; 30: 396–401.
1429. Cullen MR, Kayne RD, Robins JM. Endocrine and reproductive dysfunction in men associated with occupational inorganic lead intoxication. *Arch Environ Health* 1984; 39: 431–440.
1430. Harrington JM. Occupational exposure to synthetic estrogens: some methodological problems. *Scand J Work Environ Health* 1992; 8: 167–171.
1431. Gill WB, Schumacher GFB, Bibbo M, et al. Association of diethylstilbestrol exposure in utero with cryptorchidism, testicular hypoplasia and semen abnormalities. *J Urol* 1979; 122: 36–39.
1432. Hauser R, Meeker JD, Duty S, et al. Altered semen quality in relation to urinary concentrations of phthalate monoester and oxidative metabolites. *Epidemiology* 2006; 17: 682–691.
1433. Jurewicz J, Hanke W, Sobala W, et al. Current use of pesticides in Poland and the risk of reproductive disorders. *Med Pr* 2004; 55: 275–281.
1434. Hauser R. The environment and male fertility: recent research on emerging chemicals and semen quality. *Semin Reprod Med* 2006; 24: 156–167.
1435. Andersson A-M, Skakkebaek NE. Exposure to exogenous estrogens in food: possible impact on human development and health. *Eur J Endocrinol* 1999; 140: 477–485.
1436. Skakkebaek NS, Rajpert-De Meyts E, Main KM. Testicular dysgenesis syndrome: an increasingly common developmental disorder with environmental aspects. *Hum Reprod* 2001; 16: 972–978.
1437. Weber RF, Pierik FH, Dohle GR, Burdorf A. Environmental influences on male reproduction. *BJU Int* 2002; 89: 143–148.
1438. Whan LB, West MC, McClure N, Lewis SE. Effects of delta-9-tetrahydrocannabinol, the primary psychoactive cannabinoid in marijuana, on human sperm function in vitro. *Fertil Steril* 2006; 85: 653–660.
1439. Yang GS, Wang W, Wang YM, et al. Effect of cocaine on germ cell apoptosis in rats at different ages. *Asian J Androl* 2006; 8: 569–575.
1440. Muthusami KR, Chinnaswamy P. Effect of chronic alcoholism on male fertility hormones and semen quality. *Fertil Steril* 2005; 84: 919–924.
1441. Hassa H, Yildirim A, Can C, et al. Effect of smoking on semen parameters of men attending an infertility clinic. *Clin Exp Obstet Gynecol* 2006; 33: 19–22.
1442. Karila T, Hovatta O, Seppala T. Concomitant abuse of anabolic androgenic steroids and human chorionic gonadotrophin impairs spermatogenesis in power athletes. *Int J Sports Med* 2004; 25: 257–263.

1443. Ash P. The influence of radiation on fertility in man. *Br J Radiol* 1980; 53: 271–278.
1444. Lancrajan I, Maicanescu M, Rafaila E, et al. Gonadal function in workmen with long term exposure to microwaves. *Health Phys* 1975; 29: 381–383.
1445. Mieusset R, Bujan L, Mansat A, et al. Effects of artificial cryptorchidism on sperm morphology. *Fertil Steril* 1987; 47: 150–155.
1446. Dada R, Gupta NP, Kucheria K. Spermatogenic arrest in men with testicular hyperthermia. *Teratog Carcinog Mutagen* 2003; Suppl 1: 235–243.
1447. Peñafiel R, Solano F, Gramdes A. The effect of hyperthermia on ornithine decarboxylase activity in different rat tissue. *Biochem Pharmacol* 1988; 37: 497–502.
1448. Amendola R, Cordelli E, Mauro F, et al. Effects of L-acetylcarnitine (LAC) on the post-injury recovery of mouse spermatogenesis monitored by flow cytometry. Recovery after hyperthermic treatment. *Andrologia* 1991; 23: 135–140.
1449. Casillas ER, Erickson BJ. The role of carnitine in spermatozoa metabolism. Substrate induced elevations in the acetylation state of carnitine and coenzyme A in bovine and monkey spermatozoa. *Biol Reprod* 1975; 12: 275–283.
1450. Okuyama A, Koh E, Kondoh N, et al. In vitro temperature sensitivity of DNA, RNA, and protein synthesis throughout puberty in human testis. *Arch Androl* 1991; 26: 7–13.
1451. Lee JY, Cass AS, Streitz JM. Traumatic dislocation of testes and bladder rupture. *Urology* 1992; 40: 506–508.
1452. Lopez Alcina E, Martin JC, Fuster A, et al. Testicular dislocation. Report of 2 new cases and review of the literature. *Actas Urol Esp* 2001; 25: 299–302.
1453. Nagarajan VP, Pranikoff K, Imahori SC, et al. Traumatic dislocation of testis. *Urology* 1983; 22: 521–524.
1454. Kochakarn W, Choonhaklai V, Hotrapawanond P, et al. Traumatic testicular dislocation a review of 36 cases. *J Med Assoc Thai* 2000; 83: 208–212.
1455. Yoshimura K, Okubo K, Ichioka K, et al. Restoration of spermatogenesis by orchiopexy 13 years after bilateral traumatic testicular dislocation. *J Urol* 2002; 167: 649–650.
1456. Arai Y, Kawakita M, Okada Y, et al. Sexuality and fertility in long-term survivors of testicular cancer. *J Clin Oncol* 1997; 15: 1444–1448.
1457. Nicholson HS, Beyrre J. Fertility and pregnancy after treatment for cancer during childhood or adolescence. *Cancer* 1993; 71: 3392–3399.
1458. Piroth MD, Hensley F, Wannemacher M, et al. Male gonadal dose in adjuvant 3-d-pelvic irradiation after anterior resection of rectal cancer. Influence to fertility. *Strahlenther Onkol* 2003; 179: 754–759.
1459. Hahn EW, Feingold SM, Simpson L, et al. Recovery from aspermia induced by low-dose radiation in seminoma patients. *Cancer* 1982; 50: 337–340.
1460. Speiser B, Rubin P, Casarett G. Aspermia following lower truncal irradiation in Hodgkin's disease. *Cancer* 1973; 32: 692–698.
1461. Freund I, Zenzes MA, Muller RP, et al. Testicular function in eight patients with seminoma after unilateral orchidectomy and radiotherapy. *Int J Androl* 1987; 10: 447–455.
1462. Fossa SD, Almaas B, Jetne V, et al. Paternity after irradiation for testicular cancer. *Acta Radiol Oncol* 1986; 25: 33–36.
1463. Esfahani AF, Eftekhari M, Zenooz N, Saghari M. Gonadal function in patients with differentiated thyroid cancer treated with (131)I. *Hell J Nucl Med* 2004; 7: 52–55.
1464. Erogul O, Oztas E, Yildirim I, et al. Effects of electromagnetic radiation from a cellular phone on human sperm motility: an in vitro study. *Arch Med Res* 2006; 37: 840–843.
1465. Müller J, Hertz H, Skakkebaek NE. Development of the seminiferous epithelium during and after treatment for acute lymphoblastic leukemia in childhood. *Hormone Res* 1988; 30: 115–120.
1466. Matus-Ridley M, Nicosia SV, Meadows AT. Gonadal effects of cancer therapy in boys. *Cancer* 1985; 55: 2353–2363.
1467. Brämswig JH, Heimes U, Heiermann E, et al. The effects of different cumulative doses of chemotherapy on testicular function. *Cancer* 1990; 65: 1298–1302.
1468. Meistrich ML, Wilson G, Brown BW, et al. Impact of cyclophosphamide on long-term reduction in sperm count in men treated with combination chemotherapy for Ewing and soft tissue sarcomas. *Cancer* 1992; 70: 2703–2712.
1469. Bar-Shira Maymon B, Yogev L, Marks A, et al. Sertoli cell inactivation by cytotoxic damage to the human testis after cancer chemotherapy. *Fertil Steril* 2004; 81: 1391–1394.
1470. Friedman NM, Plymate SR. Leydig cell dysfunction and gynaecomastia in adult males treated with alkylating agents. *Clin Endocrinol* 1980; 12: 553–556.
1471. Chatterjee R, Haines GA, Perera DM, et al. Testicular and sperm DNA damage after treatment with fludarabine for chronic lymphocytic leukaemia. *Hum Reprod* 2000; 15: 762–766.
1472. Howell SJ, Shalet SM. Spermatogenesis after cancer treatment: damage and recovery. *J Natl Cancer Inst Monogr* 2005; 34: 12–17.
1473. van den Berg H, Furstner F, van den Bos C, Behrendt H. Decreasing the number of MOPP courses reduces gonadal damage in survivors of childhood Hodgkin disease. *Pediatr Blood Cancer* 2004; 42: 210–215.
1474. Delbes G, Hales BF, Robaire B. Effects of the chemotherapy cocktail used to treat testicular cancer on sperm chromatin integrity. *J Androl* 2007; 28: 241–249.
1475. Spermon JR, Ramos L, Wetzels AM, et al. Sperm integrity pre- and post-chemotherapy in men with testicular germ cell cancer. *Hum Reprod* 2006; 21: 1781–1786.
1476. Viviani S, Ragni G, Santoro A, et al. Testicular dysfunction in Hodgkin's disease before and after treatment. *Eur J Cancer* 1991; 27: 1389–1392.
1477. Fossa SD, Ous S, Byholm T, et al. Posttreatment fertility in patients with testicular cancer. Part 1. *Br J Urol* 1985; 57: 204–209.
1478. Nijman JM, Schraffordt Koops H, et al. Sexual function after bilateral retroperitoneal lymph node dissection for nonseminomatous testicular cancer. *Arch Androl* 1987; 18: 255–267.
1479. Bennett CJ, Seager SW, Vasher EA, et al. Sexual dysfunction and electroejaculation in men with spinal cord injury: review. *J Urol* 1988; 139: 453–457.
1480. Murphy JB, Lipschultz LI, Vervoort SM. Infertility in the spinal cord injured male. *World J Urol* 1986; 4: 83–87.
1481. Perkash I, Martin DE, Warner H, et al. Reproductive biology of paraplegics: Results of semen collection, testicular biopsy and serum hormone evaluation. *J Urol* 1985; 134: 284–288.
1482. Siösteen A, Steen Y, Forssman L, et al. Auto-immunity to spermatozoa and quality of semen in men with spinal cord injury. *Int J Fertil* 1993; 38: 117–122.
1483. Leriche A, Berard E, Vauzelle JL, et al. Histological and hormonal testicular changes in spinal cord patients. *Paraplegia* 1977–1978; 15: 274–279.
1484. Brown DJ, Hill ST, Baker HW. Male fertility and sexual function after spinal cord injury. *Prog Brain Res* 2006; 152: 427–439.
1485. Kafetsoulis A, Brackett NL, Ibrahim E, et al. Current trends in the treatment of infertility in men with spinal cord injury. *Fertil Steril* 2006; 86: 781–789.
1486. Holstein AF, Sauerwein D, Schirren U. Spermatogenesis bei Patienten mit traumatischer Querschnittlähmung. *Urologe A* 1985; 24: 208–215.
1487. Brindley GS. Deep scrotal temperature and the effect on it of clothing, air, temperature, activity, posture and paraplegia. *Br J Urol* 1982; 54: 49–55.

1488. Chappelle PA, Roby-Brami A, Yakovleff A, et al. Neurological correlations of ejaculation and testicular size in men with a complete spinal cord section. *J Neurol Neurosurg Psychiatry* 1988; 51: 197–202.
1489. Aird IA, Vince GS, Bates MD, et al. Leukocytes in semen from men with spinal cord injuries. *Fertil Steril* 1999; 72: 97–103.
1490. Trabulsi EJ, Shupp-Byrne D, Sedor J, Hirsch IH. Leukocyte subtypes in electroejaculates of spinal cord injured men. *Arch Phys Med Rehab* 2002; 83: 31–34.
1491. Basu S, Aballa TC, Ferrel SM, et al. Inflammatory cytokine concentrations are elevated in seminal plasma of men with spinal cord injuries. *J Androl* 2004; 25: 250–254.
1492. Elliott SP, Orejuela F, Hirsch IH, et al. Testis biopsy findings in the spinal cord injured patient. *J Urol* 2000; 163: 792–795.
1493. Ohl DA, Menge AC, Jarow JP. Seminal vesicle aspiration in spinal cord injured men: insight into poor sperm quality. *J Urol* 1999; 162: 2048–2051.
1494. Brackett NL, Lynne CM, Aballa TC, et al. Sperm motility from the vas deferens of spinal cord injured men is higher than from the ejaculate. *J Urol* 2000; 164: 712–715.
1495. Wieder JA, Lynne cm, Ferrell SM, et al. Brown-colored semen in men with spinal cord injury. *J Androl* 1999; 20: 594–600.
1496. Casella R, Leibundgut B, Lehmann K, et al. Mumps orchitis: report of a mini-epidemic. *J Urol* 1997; 158: 2158–2161.
1497. Masarani M, Wazait H, Dinneen M. Mumps orchitis. *J Roy Soc Med* 2006; 99: 573–575.
1498. Duszczuk E, Krynicka-Czech B, Talarek E, Popielska J. Mumps – an underestimated disease. *Przegl Epidemiol* 2006; 60: 99–104.
1499. Shulman A, Shohat B, Gillis D, et al. Mumps orchitis among soldiers: frequency, effect on sperm quality, and sperm antibodies. *Fertil Steril* 1992; 57: 1344–1346.
1500. Diehl K, Hondl H. Mumps orchitis: symptoms and treatment possibilities. *Zeitschr Urol Nephrol* 1990; 83: 243–247.
1501. Charny CW, Meranze DR. Pathology of mumps orchitis. *J Urol* 1948; 60: 140–146.
1502. Lin YM, Hsu CC, Lin JS. Successful testicular sperm extraction and fertilization in an azoospermic man with postpubertal mumps orchitis. *BJU Int* 1999; 83: 526–527.
1503. Mikuz G, Damjanov I. Inflammation of the testis, epididymis, peritesticular membranes and scrotum. *Pathol Annu* 1982; 1: 101–128.
1504. Ejlersen T, Jensen HK. Orchitis and testicular abscess formation caused by non-typhoid salmonellosis. *APMIS* 1990; 98: 294–298.
1505. Jani AN, Casibang V, Mufarrij W. Disseminated actinomycosis presenting as a testicular mass. A case report. *J Urol* 1990; 143: 1012–1014.
1506. Lin CY, Jwo SC, Lin CC. Primary testicular actinomycosis mimicking metastatic tumor. *Int J Urol* 2005; 12: 519–521.
1507. Nistal M, Gonzalez-Peramato P, Serrano A, Regadera J. Xanthogranulomatous funiculitis and orchiepididymitis: report of 2 cases with immunohistochemical study and literature review. *Arch Pathol Lab Med* 2004; 128: 911–914.
1508. Almagro UA, Tresp M, Sheth NK. Tuberculous epididymitis occurring 35 years after renal tuberculosis. *J Urol* 1989; 141: 1204–1205.
1509. Cabral DA, Johnson HW, Coleman GU, et al. Tuberculous epididymitis as a cause of testicular pseudomalignancy in two young children. *Pediatr Infect Dis* 1985; 4: 59–62.
1510. Wolf JS Jr, McAninch JW. Tuberculous epididymo-orchitis. Diagnosis by fine needle aspiration. *J Urol* 1991; 145: 836–838.
1511. Stein AL, Miller DB. Tuberculous epididymo-orchitis. A case report. *J Urol* 1983; 129: 613.
1512. Harada H, Seki M, Shinojima H, et al. Epididymo-orchitis caused by intravesically instilled bacillus Calmette–Guérin: genetically proven using a multiplex polymerase chain reaction method. *Int J Urol* 2006; 13: 183–185.
1513. Persaud V, Rao A. Gumma of testis. *Br J Urol* 1977; 49: 142–143.
1514. Akhtar M, Alli MA, Mackey DM. Lepromatous leprosy presenting as orchitis. *Am J Clin Pathol* 1980; 73: 712–715.
1515. Kumar B, Raina A, Kraur S, et al. Clinicopathological study of testicular involvement in leprosy. *Indian J Lepr* 1982; 54: 48–55.
1516. Richens J. Genital manifestations of tropical diseases. *Sex Transm Infect* 2004; 80: 12–17.
1517. Fallatah SM, Oduloju AJ, Al-Dusari SN, Fakunle YM. Human brucellosis in Northern Saudi Arabia. *Saudi Med J* 2005; 26: 1562–1566.
1518. Yetkin MA, Erdinc FS, Bulut C, Tulek N. Epididymoorchitis due to brucellosis in central Anatolia, Turkey. *Urol Int* 2005; 75: 235–238.
1519. Romero-Perez P, Navarro-Ibañez V, Amat-Cecilia M, et al. Brucellar orchiepididymitis in acute brucellosis. *Actas Urol Esp* 1995; 19: 330–332.
1520. Reisman EM, Colquitt LA, Childers J, et al. Brucella orchitis: a rare cause of testicular enlargement. *J Urol* 1990; 143: 821–822.
1521. Perez Fentes D, Blanco Parra M, Alende Sixto M, et al. Orquioepididimitis brucelosa: A propósito de un caso. *Arch Esp Urol* 2005; 58: 674–677.
1522. Queipo-Ortuno MI, Colmenero JD, Munoz N, et al. Rapid diagnosis of Brucella epididymo-orchitis by real-time polymerase chain reaction assay in urine samples. *J Urol* 2006; 176: 2290–2293.
1523. Ryan DM, Lesser BA, Crumley LA, et al. Epididymal sarcoidosis. *J Urol* 1993; 149: 134–136.
1524. Handa T, Nagai S, Hamada K, et al. Sarcoidosis with bilateral epididymal and testicular lesions. *Intern Med* 2003; 42: 92–97.
1525. Metcalfe MS, Rees Y, Morgan P, et al. Sarcoidosis presenting as a testicular mass. *Br J Urol* 1998; 82: 769–770.
1526. Wong JA, Grantmyre J. Sarcoid of the testis. *Can J Urol* 2006; 13: 3201–3203.
1527. Singer AJ, Gavrill GJ, Leidich RB, et al. Genitourinary involvement of systemic sarcoidosis confined to testicle. *Urology* 1990; 35: 422–444.
1528. Blacher EJ, Maynard JF. Seminoma and sarcoidosis: an unusual association. *Urology* 1985; 26: 288–289.
1529. Svetec DA, Waguespack RL, Sabanegh ES Jr. Intermittent azoospermia associated with epididymal sarcoidosis. *Fertil Steril* 1998; 70: 777–779.
1530. Michaelis L, Gutmann C. Ueber Einschlüsse in Blastumoren. *Ztschr Klin Med* 1902; 47: 208–215.
1531. McClure J. A case of malacoplakia of the epididymis associated with trauma. *J Urol* 1980; 124: 934–935.
1532. Kusuma V, Niveditha SR, Krishnamurthy, Ramdev K. Epididymo-testicular malacoplakia – a case report. *Indian J Pathol Microbiol* 2006; 49: 413–415.
1533. Saraf P, Disant’Agnese P, Valvo J, et al. An unusual case of malacoplakia involving the testis and prostate. *J Urol* 1983; 129: 149–151.
1534. Díaz-González R, Leiva D, Navas-Palacios JJ, et al. Testicular malacoplakia. *J Urol* 1982; 127: 325–328.
1535. Nistal M, Rodríguez Echandía EL, Paniagua R. Septate junctions between digestive vacuoles in human malacoplakia. *Tissue Cell* 1978; 10: 137–142.
1536. Orr WA, Mulholland SG, Walzak Jr MP. Genitourinary tract involvement with systemic mycosis. *J Urol* 1972; 107: 1047–1150.
1537. Dykes TM, Stone AB, Canby-Hagino ED. Coccidioidomycosis of the epididymis and testis. *AJR Am J Roentgenol* 2005; 84: 552–553.
1538. James CL, Lomax-Smith JD. Cryptococcal epididymoorchitis complicating steroid therapy for releasing polychondritis. *Pathology* 1991; 23: 256–258.
1539. Alves LS, Assis BP, Rezende MM. Schistosomal epididymitis. *Int Braz J Urol* 2004; 30: 413–415.

1540. Nistal M, Santana A, Paniagua R, et al. Testicular toxoplasmosis in two men with the acquired immunodeficiency syndrome (AIDS). *Arch Pathol Lab Med* 1986; 110: 744-746.
1541. Strohmaier WL, Bichler KH, Wilbert DM, et al. Alveolar echinococcosis with involvement of the ureter and testes. *J Urol* 1990; 144: 733-734.
1542. Martinez-Rodriguez M, Navarro Fos S, Soriano Sarrío P, et al. Idiopathic granulomatous orchitis: pathologic study of one case. *Arch Esp Urol* 2006; 59: 725-727.
1543. Sato K, Hirokawa K, Hatakeyana S. Experimental allergic orchitis in mice. Histopathological and immunological studies. *Virchows Arch [Pathol Anat]* 1981; 392: 147-158.
1544. Lehmann D, Emmons LR. Immunological phenomena observed in the testis and their possible role in infertility. *Am J Reprod Immunol* 1989; 19: 43-52.
1545. El-Demiry MI, Hargreave TB, Bussuttil A. Immunocompetent cells in human testis in health and disease. *Fertil Steril* 1987; 48: 470-479.
1546. Suominen JJ. Sympathetic auto-immune orchitis. *Andrologia* 1995; 27: 213-216.
1547. Hendry WF, Levison DA, Parkinson MC, et al. Testicular obstruction: clinicopathological studies. *Ann Roy Coll Surg Engl* 1990; 72: 396-407.
1548. Lehmann J, Jancke C, Retz M, et al. Hypoechoic Lesion found on testicular ultrasound after testicular piercing. *J Urol* 2000; 164: 1651.
1549. Nistal M, Riestra ML, Paniagua R. Focal orchitis in undescended testes: discussion of pathogenetic mechanisms of tubular atrophy. *Arch Pathol Lab Med* 2002; 126: 64-69.
1550. Jass JR, Farrell MA, Ellis H. Pseudolymphoma of the testis. *Br J Urol* 1984; 56: 102-103.
1551. Algaba F, Santaularia JM, Garat JM, Cubells J. Testicular pseudolymphoma. *Eur Urol* 1986; 12: 362-363.
1552. Aksoy PK, Ozdemir BH, Aygun C, Agildere M. Plasma cell granuloma of the testis: unusual localization. *J Urol* 2001; 166: 1000.
1553. Anghel G, Petti N, Remotti D, et al. Testicular plasmacytoma: report of a case and review of the literature. *Am J Hematol* 2002; 71: 98-104.
1554. Lossos IS, Okon E, Bogomolski-Yahalom V, et al. Sinus histiocytosis with massive lymphadenopathy (Rosai-Dorfman disease): report of a patient with isolated renotesticular involvement after cure of non-Hodgkin's lymphoma. *Ann Hematol* 1997; 74: 41-44.
1555. Fernandopulle SM, Hwang JS, Kuick CH, et al. Rosai-Dorfman disease of the testis: an unusual entity that mimics testicular malignancy. *J Clin Pathol* 2006; 59: 325-327.
1556. Cox NH, Popple AW. Persistent erythema and pruritus, with a confluent histiocytic skin infiltrate, following the use of a hydroxyethylstarch plasma expander. *Br J Dermatol* 1996; 134: 353-357.
1557. Schned AR, Selikowitz SM. Epididymitis nodosa. An epididymal lesion analogous to vasitis nodosa. *Arch Pathol Lab Med* 1986; 110: 61-64.
1558. Adams PC, Holt P, Holt DW. Amiodarone in testis and semen. *Lancet* 1985; 1: 341.
1559. Dobs AS, Sarma PS, Guarnieri T, Griffith L. Testicular dysfunction with amiodarone use. *J Am Coll Cardiol* 1991; 18: 1328-1332.
1560. Gasparich JP, Mason JT, Green HL, et al. Non-infectious epididymitis associated with amiodarone therapy. *Lancet* 2: 1211-1212, 1984.
1561. Sadek I, Biron P, Kus T. Amiodarone-induced epididymitis: report of a new case and literature review of 12 cases. *Can J Cardiol* 1993; 9: 833-836.
1562. Kirkali Z. Amiodarone-induced sterile epididymitis. *Urol Int* 43: 372-373, 1988.
1563. Gabal-Shehab LL, Monga M. Recurrent bilateral amiodarone induced epididymitis. *J Urol* 1999; 161: 921.
1564. Hutchison J, Peters CA, Diamond DA. Amiodarone induced epididymitis in children. *J Urol* 1998; 160: 515-517.
1565. Hamoud Kaneti J, Smailowitz Z, Lissmer L. Amiodarone-induced epididymitis. Report of 2 cases. *Eur Urol* 1996; 29: 497-498.
1566. Nistal M, Mate A, Paniagua R. Granulomatous epididymal lesion of possible ischemic origin. *Am J Surg Pathol* 1997; 21: 951-956.
1567. Ellis H, Hutton PA. A stone in the testicle. *Br J Urol* 1983; 55: 449.
1568. Dayanc M, Kilciler M, Kibar Y, et al. Testicular calculus. *J Urol* 2000; 163: 1253-1254.
1569. O'Regan S, Robitaille P. Orchitis mimicking testicular torsion in Henoch-Schönlein's purpura. *J Urol* 1981; 126: 834-835.
1570. Davenport A, Downey SE, Goel S, et al. Wegener's granulomatosis involving the urogenital tract. *Br J Urol* 1996; 78: 354-357.
1571. Barber TD, Al-Omar O, Poulik J, McLoirie GA. Testicular infarction in a 12-year-old boy with Wegener's granulomatosis. *Urology* 2006; 67: 846.e9-10.
1572. Vollerten RS, McDonald TJ, Younge BR, et al. Cogan's syndrome: 18 cases and a review of the literature. *Mayo Clin Proc* 1986; 61: 344-361.
1573. Karlamani VG, Vaiopoulos G, Markomichelakis N, et al. Recurrent epididymo-orchitis in patients with Behçet's disease. *J Urol* 2000; 163: 487-489.
1574. Nigro KG, Abdul-Karim FW, MacLennan GT. Testicular vasculitis. *J Urol* 2006; 176: 2682.
1575. Persellin ST, Menke DM. Isolated polyarteritis nodosa of the male reproductive system. *J Rheumatol* 1992; 19: 985-988.
1576. Mukamel E, Abarbanel J, Savion M, et al. Testicular mass as presenting symptom of isolated polyarteritis nodosa. *Am J Clin Pathol* 1995; 103: 215-217.
1577. Dahl EV, Baggenstoss AH, DeWeerd JH. Testicular lesions of periarteritis nodosa, with special reference to diagnosis. *Am J Med* 1960; 28: 222-226.
1778. Teichman JM, Mattrey RF, Demby AM, Schmidt JD. Polyarteritis nodosa presenting as acute orchitis: A case report and review of the literature. *J Urol* 1993; 149: 1139-1140.
1579. Kessel A, Toubi E, Golan, TD, et al. Isolated epididymal vasculitis. *Isr Med Assoc J* 2001; 3: 65-66.
1580. Fraenkel-Rubin M, Ergas D, Sthoeger ZM. Limited polyarteritis nodosa of the male and female reproductive systems: diagnostic and therapeutic approach. *Ann Rheum Dis* 2002; 61: 362-364.
1581. Huisman TK, Collins WT, Voulgarakis GR. Polyarteritis nodosa masquerading as a primary testicular neoplasm. A case report and review of the literature. *J Urol* 1990; 114: 1236-1238.
1582. Shurbaji MS, Epstein JI. Testicular vasculitis: Implication for systemic disease. *Hum Pathol* 1988; 19: 186-189.
1583. Nistal M, Alcoba M, Contreras F. Torsión del cordón espermático. A propósito de 87 nuevos casos. Revisión de la literatura. *Arch Esp Urol* 1971; 24: 385-398.
1584. Das S, Singer D. Controversies of perinatal torsion of the spermatic cord: a review, survey and recommendations. *J Urol* 1990; 143: 231-233.
1585. Arena F, Nicotina PA, Romeo C, et al. Prenatal testicular torsion: ultrasonographic features, management and histopathological findings. *Int J Urol* 2006; 13: 135-141.
1586. Cuckow PM, Frank JD. Torsion of the testis. *BJU Int* 2000; 86: 349-353.
1587. Davol P, Simmons J. Testicular torsion in a 68-year-old man. *Urology* 2005; 66: 195.
1588. Mikuz G. Testicular torsion: simple grading for histological evaluation of tissues damage. *Appl Pathol* 1985; 3: 134-139.
1589. Nistal M, Martinez C, Paniagua R. Primary testicular lesions in the twisted testis. *Fertil Steril* 1992; 57: 381-386.
1590. Granados EA, Caicedo P, Garat JM. Torsión testicular antes de 6 horas. I. *Arch Esp Urol* 1998; 51: 971-974.

1591. Tryfonas G, Violaki A, Tsikopoulos G, et al. Late postoperative results in males treated for testicular torsion during childhood. *J Pediatr Surg* 1994; 29: 553–556.
1592. Arda IS, Ozyaylali L. Testicular tissue bleeding as an indicator of gonadal salvageability in testicular torsion surgery. *BJU Int* 2001; 87: 89–92.
1593. Johnston BI, Wiener JS. Intermittent testicular torsion. *BJU Int* 2005; 95: 933–934.
1594. Nistal M, Gonzalez-Peramato P, Paniagua R. Lipomembranous fat necrosis in three cases of testicular torsion. *Histopathology* 2001; 38: 443–447.
1595. Kosar A, Küpeli B, Alcigir G, et al. Immunologic aspects of testicular torsion: detection of antisperm antibodies in contralateral testicle. *Eur Urol* 1999; 36: 640–644.
1596. Akgür FM, Kilinç K, Tanyel FC, et al. Ipsilateral and contralateral testicular biochemical acute changes after unilateral testicular torsion and detorsion. *Urology* 1994; 44: 413–418.
1597. Hadziselimovic F, Geneto R, Emmons LR. Increased apoptosis in the contralateral testes of patients with testicular torsion as a factor for infertility. *J Urol* 1998; 160: 1158–1160.
1598. Laor E, Fisch S, Tennenbaum S, et al. Unilateral testicular torsion: abnormal histological findings in the contralateral testis. Cause or effect? *Br J Urol* 1990; 65: 520–523.
1599. Tomomasa H, Oshio S, Ameniya H, et al. Testicular injury. Late results of semen analyses after orchietomy. *Arch Androl* 1992; 29: 59–63.
1600. Wantz GE. Testicular atrophy as a sequela of inguinal hernioplasty. *Int Surg* 1986; 71: 159–163.
1601. Rutledge RH. Cooper's ligament repair for adult growing hernias. *Surgery* 1980; 87: 601–610.
1602. Roach R, Messing E, Starling J. Spontaneous thrombosis of left spermatic vein: Report of 2 cases. *J Urol* 1985; 134: 369–373.
1603. Nistal M, Palacios J, Regadera J, et al. Postsurgical focal testicular infarct. *Urol Int* 1986; 41: 149–151.
1604. Nawrocki JD, Cook AJ. Localised infarction of the testis. *Br J Urol* 1992; 69: 541.
1605. Sriprasad S, Kooiman GG, Muir GH, Sidhu PS. Acute segmental testicular infarction: differentiation from tumour using high frequency colour Doppler ultrasound. *Br J Radiol* 2001; 74: 965–967.
1606. Cooper AP. Observations on the structure and diseases of the testis. London: S McDowall, 1930; 79.
1607. Jenkins RH, Deming CL. Cysts of the testicle. *N Engl J Med* 1935; 213: 57–59.
1608. Sethney HT, Albers DD. Tunica albuginea cyst: rare testicular mass. *Urology* 1980; 15: 285–286.
1609. Leung ML, Gooding GAW, Williams RD. High-resolution sonography of scrotal contents in asymptomatic subjects. *AJR Am J Roentgenol* 1984; 143: 161–164.
1610. Haas GP, Shumaker BP, Cerny JC. The high incidence of benign testicular tumors. *J Urol* 1987; 138: 1219–1220.
1611. Gooding GAW, Leonhardt W, Stein R. Testicular cysts. US findings. *Radiology* 1987; 163: 537–538.
1612. Rubenstein RA, Dogra VS, Seftel AD, Resnick MI. Benign intrascrotal lesions. *J Urol* 2004; 71: 1765–1772.
1613. Bhatt S, Rubens DJ, Dogra VS. Sonography of benign intrascrotal lesions. *Ultrasound Q* 2006; 22: 121–136.
1614. Nistal M, Íñiguez L, Paniagua R. Cysts of the testicular parenchyma and tunica albuginea. *Arch Pathol Lab Med* 1989; 113: 902–906.
1615. Bryant J. Efferent ductule cyst of tunica albuginea. *Urology* 1986; 27: 172–173.
1616. Tejada E, Eble JN. Simple cyst of the rete testis. *J Urol* 1988; 139: 376–377.
1617. Davis RS. Intratesticular spermatocele. *Urology* 1998; 51: 67–169.
1618. Tosi SE, Richardson J. Simple cyst of the testis: case report and review of literature. *J Urol* 1975; 114: 473–475.
1619. Schmidt SS. Congenital simple cysts of the testis: a hitherto undescribed lesion. *J Urol* 1966; 96: 236–238.
1620. Takihara H, Valvo JR, Tokuhara M, et al. Intratesticular cysts. *Urology* 1982; 20: 80–82.
1621. Hamm B, Fobbe F, Loy V. Testicular cysts: Differentiation with US and clinical findings. *Radiology* 1988; 168: 19–23.
1622. Ceylan H, Karaca I, Sari I, et al. Simple testicular cyst: A rare cause of scrotal swelling in infancy. *Int J Urol* 2004; 11: 352–354.
1623. Lam KY. Bilateral intratesticular cysts. A specific entity. *Scand J Urol Nephrol* 1996; 30: 329–331.
1624. Sahin A, Ozen H, Gedikoglu G, et al. Two simple cysts of the same testis. *Br J Urol* 1994; 73: 107–108.
1625. Frater K. Cysts of the tunica albuginea (cysts of the testis). *J Urol* 1929; 21: 135–136.
1626. Arcadi JA. Cysts of the tunica albuginea testis. *J Urol* 1952; 68: 631–632.
1627. Mennemeyer RP, Mason JT. Non-neoplastic cystic lesions of the tunica albuginea: an electron microscopic and clinical study of 2 cases. *J Urol* 1979; 121: 373–375.
1628. Mancilla-Jiménez R, Matsuda GT. Cysts of the tunica albuginea: report of 4 cases and review of the literature. *J Urol* 1975; 114: 730–733.
1629. Warner KE, Noyes DT, Ross JS. Cysts of the tunica albuginea: a report of 3 cases with a review of the literature. *J Urol* 1984; 132: 131–132.
1630. Köbarth K, Kratzik CH. High resolution ultrasonography in the diagnosis of simple intratesticular cysts. *J Urol* 1992; 70: 546–549.
1631. Rifkin MD, Jacobs JA. Simple testicular cyst diagnosed preoperatively by ultrasound. *J Urol* 1983; 129: 982–983.
1632. Kratzik C, Hainz A, Kuber W, et al. Surveillance strategy for intratesticular cysts: preliminary report. *J Urol* 1990; 143: 313–315.
1633. Altadonna V, Snyder HM, Rosenberg HK, et al. Simple cysts of the testis in children: Preoperative diagnosis by ultrasound and excision with testicular preservation. *J Urol* 1988; 140: 1505–1507.
1634. Nistal M, Jimenez-Hefferman JA. Rete testis dysgenesis. A characteristic lesion of undescended testes. *Arch Pathol Lab Med* 1997; 121: 1259–1264.
1635. Lee KH, Hess RA, Bahr JM, et al. Estrogen receptor alpha has a functional role in the mouse rete testis and efferent ductules. *Biol Reprod* 2000; 63: 1873–1880.
1636. Nistal M, Mate A, Paniagua R. Cystic transformation of the rete testis. *Am J Surg Pathol* 1996; 20: 1231–1239.
1637. Colangelo SM, Fried K, Hyacinthe LM, et al. Tubular ectasia of the rete testis: an ultrasound diagnosis. *Urology* 1995; 45: 532–534.
1638. Pascual Mateo C, Fernandez Gonzalez I, Lujan Galan M, et al. Cystic ectasia of the rete testis. *Arch Esp Urol* 2006; 59: 55–58.
1639. Meyer DR, Huppe T, Lock U, et al. Pronounced cystic transformation of the rete testis. MRI appearance. *Invest Radiol* 1999; 34: 600–603.
1640. Wilschanski M, Corey M, Durie P, et al. The diversity of reproductive tract abnormalities in males with cystic fibrosis. *JAMA* 1996; 276: 607–608.
1641. Tchetgen MB, Wolf JS Jr. Postsurgical changes in the testis: a diagnostic dilemma. *Urology* 1998; 51: 333–334.
1642. Nistal M, Santamaría L, Paniagua R. Acquired cystic transformation of the rete testis secondary to renal failure. *Hum Pathol* 1989; 20: 1065–1070.
1643. Nistal M, Paniagua R. Adenomatous hyperplasia of the rete testis. *J Pathol* 1988; 154: 343–346.
1644. Nistal M, Castillo MC, Regadera J, Garcia-Cabezas MA. Adenomatous hyperplasia of the rete testis. A review and report of new cases. *Histol Histopathol* 2003; 18: 741–752.
1645. Nistal M, García-Villanueva M, Sánchez J. Displasia quística del testículo: anomalía en la diferenciación del parénquima testicular por probable fallo en la conexión entre los conductos de origen mesoneférico y los cordones testiculares. *Arch Esp Urol* 1976; 29: 431–444.
1646. Uguz A, Gonlusen G, Ergin M, Tunali N. Adenomatous hyperplasia of the

- rete testis: report of two cases. *Int Urol Nephrol* 2002; 34: 87–89.
1647. Channer JL, MacIver AG. Glandular changes in the rete testis: metastatic tumour or adenomatous hyperplasia? [Letter] *J Pathol* 1989; 157: 81–83.
1648. Srigley JR, Hartwick RW. Tumors and cysts of the paratesticular region. *Pathol Annu* 1990; 25: 51–108.
1649. Hartwick RW, Ro JY, Srigley JR, et al. Adenomatous hyperplasia of the rete testis. A clinicopathologic study of nine cases. *Am J Surg Pathol* 1991; 15: 350–357.
1650. Nistal M, Gonzalez-Peramato P, Regadera J, et al. Primary testicular germ cell tumors of adult men. *Am J Surg Pathol* 2006; 30: 1260–1268.
1651. Badoual C, Cohen C, Michenet P, et al. Adénome du rete testis. *Ann Pathol* 1999; 19: 80–81.
1652. Nochomovitz LE, Orenstein JM. Adenocarcinoma of the rete testis: case report, ultrastructural observations, and clinicopathologic correlates. *Am J Surg Pathol* 1984; 8: 625–634.
1653. Skinnider BF, Young RH. Infarcted adenomatoid tumor: a report of five cases of a facet of a benign neoplasm that may cause diagnostic difficulty. *Am J Surg Pathol* 2004; 28: 77–83.
1654. Ulbright TM, Gersell DJ. Rete testis hyperplasia with hyaline globule formation. A lesion simulating yolk sac tumor. *Am J Surg Pathol* 1991; 15: 66–74.
1655. Nistal M, Paniagua R. Nodular proliferation of calcifying connective tissue in the rete testis: A study of three cases. *Hum Pathol* 1989; 20: 58–61.