




Management of Chronic Orchialgia: Challenges and Solutions – The Current Standard of Care

This article was published in the following Dove Press journal:
Research and Reports in Urology

Sijo J Parekattil ¹
Onuralp Ergun ²
Ahmet Gudeloglu ²

¹PUR Clinic and University of Central Florida, Clermont, FL, USA; ²Department of Urology, Hacettepe University, Ankara, Turkey

Introduction: Chronic scrotal content pain (CSP) or chronic orchialgia can be debilitating for patients and difficult to treat. There is a paucity of structured treatment algorithms to approach this difficult condition.

Methods: A review of the literature was performed. Conservative treatment options are presented and then targeted surgical interventions that the urologist may perform are then presented in a structured algorithm format. Many of these patients may obtain a significant reduction in pain with some of these treatments.

Results: This review presents the pathophysiology, a new assessment tool, and various treatment options available for CSP patients, such as targeted spermatic cord blocks, targeted and standard microsurgical denervation of the spermatic cord (77–100% success rates), ultrasound-guided peri-spermatic cord and ilioinguinal cryoablation (59–75% success rates), scrotox (botox) (56–72% success rates), targeted ilioinguinal and iliohypogastric peripheral nerve stimulation (72% success rate), radical orchiectomy (20–75% success rate), targeted robotic-assisted intra-abdominal denervation (71% success rate) and vasectomy reversal (69–100% success rates).

Conclusion: A structured and evidence-based approach to help urologists manage patients with chronic orchialgia or scrotal content pain is presented.

Keywords: testicular pain, denervation of the spermatic cord, scrotal content pain, groin pain, peri-spermatic cord cryoablation, botox, stimrouter

Introduction

Chronic orchialgia or chronic scrotal content pain (CSP) is seen in about 2.5–4.8% of all urology clinic visits.¹ This can be a frustrating condition to treat for patients and urologists alike. Many common causes of testicular pain can usually be identified with a thorough physical examination and history. When we talk about CSP, this is usually defined as chronic pain that has been persistent for more than three months and other causes such as an infection, testicular mass, torsion, hydrocele, abscess and referred pain due to some type of upper tract issue have been ruled out.^{2,4} Patients may present as idiopathic pain,¹ post-vasectomy pain,^{5,6} post-inguinal hernia pain,^{7,9} post-traumatic pain,³ post-abdominal surgery pain,^{10,12} post-abdominal radiation pain,¹³ post-cardiac catheterization (inguinal approach) pain,¹⁴ etc. Initially, conservative treatment options be initiated such as medical therapy and/or neuromodulation techniques (pelvic floor therapy, acupuncture, etc.).^{4,15} When these approaches fail, surgical approaches may be considered. Targeted nerve blocks,^{16,17} targeted and standard microsurgical denervation of the spermatic cord (TMDSC & MDSC),^{18,22} ultrasound-guided targeted peri-spermatic cord and/

Correspondence: Sijo J Parekattil
PUR Clinic and University of Central Florida, 2341 Golden Aster Street, Clermont, FL 34711, USA
Tel +1 863-258-4999
Email sijojp@gmail.com

or ilioinguinal cryoablation (UTC),^{23,24} botox ablation (SCROTOX),²⁵ peripheral nerve stimulation,^{26,27} and radical orchiectomy^{28,29} are some of the surgical options available. This review article presents contemporary research publications covering these treatment options and provides a treatment guideline to help the urologist in managing patients who present with CSCP. This paper presents our review strategy, possible pathophysiology for CSCP and possible treatment options in a management algorithm.

Review or Query Strategy

A query on PubMed for the keywords of “chronic orchialgia”, “chronic testicular pain”, “testicular pain” and “orchialgia” was performed on April 1st, 2020. This query resulted in 2399 articles. These articles were then reviewed, and 61 were selected based on the following selection criteria: 1) study had human research review board approval, 2) presented an evidence-based treatment option for CSCP, and 3) presented an evidence-based assessment of CSCP. All data reviewed had human research review board approval.

Pathophysiology

Wallerian degeneration in peripheral nerves has been previously identified as a cause of chronic pain in other areas of the body such as the extremities.^{30,31} Thus, the ligation, ablation or neuro-modulation of these nerve fibers may explain the benefit of various targeted therapies in CSP patients. This would explain why a targeted nerve or spermatic cord anesthetic block prior to targeted cord therapies appears to be predictive of the success of such interventions.^{9,16,17} By temporarily blocking the nerve conduction in these abnormal nerves (nerves with wallerian degeneration), during a targeted anesthetic block, patients are likely to experience temporary relief or reduction in their pain. This kind of response is then likely to correlate to a successful outcome with targeted nerve therapies such as MDSC, UTC, SCROTOX, peripheral nerve stimulation, etc.

Oka et al³² have performed an eloquent study illustrating the complex innervation of the spermatic cord. There is a complex interplay of nerve branches from the ilioinguinal, iliohypogastric, genitofemoral and inferior hypogastric nerves along the spermatic cord. Parekattil et al³³ had identified a trifecta nerve complex that may explain the rationale for pain in CSP patients.³³ This study compared spermatic cord biopsy specimens of men undergoing MDSC (57 cases) for CSP versus a control group of men

without pain undergoing spermatic cord surgery (10 cases: 4 varicocelectomies and 6 radical orchiectomies). Tissue biopsies were obtained from mapped regions of the spermatic cord in all cases. These biopsies were then evaluated (H&E staining) by an independent pathologist. There were a median number of 25 small diameter (<1 mm) nerve fibers identified within the spermatic cord; 84% (48/57) of the CSP patients had Wallerian degeneration in at least one or more of these nerves. Only 20% of the control group patients (2/10) had Wallerian degeneration ($p=0.0008$). There were 3 primary locations (the trifecta nerve complex) for these changes, listed in decreasing order of nerve density: cremasteric muscle fibers, peri-vasal tissues and vasal sheath, and posterior cord lipomatous tissues. Three human cadaver spermatic cord dissections were performed to confirm localization of the nerve distribution identified on pathology mapping. This is the first study to actually define a significant structural difference in the spermatic cord neuro-anatomy between CSP patients and non-CSP controls. There were no complications reported in the control group patients who underwent cord biopsy during varicocelectomy.

Characterization of Pain

CSP patients tend to present with specific pain distributions and characteristics. There have been recent advances in the development of a validated assessment tool to better define and characterize the pain in CSP patients.^{34,35} Polackwich et al³⁴ developed a novel assessment tool utilizing three main patient domains to better encompass the entire patient experience when dealing with CSP. Initially, a 70-item patient questionnaire that focused on seven areas of CSP symptoms: pain, location, urinary symptoms, sexual dysfunction, medical history and quality of life (QOL) impact was utilized. The questionnaire was completed by patients enrolled at two separate medical centers and cluster analysis was performed. One hundred and thirteen CSP patients completed the survey. By cluster analysis, QOL parameters clustered tightly with minimal pain level, pain at night, burning pain, distribution to spermatic cord and groin, erectile dysfunction and premature ejaculation. Patients with CSP had a high incidence of associated symptoms. The most bothersome symptoms with highest QOL impact included burning pain, pain at night, radiation to groin and spermatic cord, erectile dysfunction and low libido. Based on these findings, a candidate orchialgia symptom index (COSI) with domains of pain, sexual symptoms and QOL was

developed. This resulted in a one page, 12 question assessment tool that was quite simple for patients to complete – the COSI.³⁴ This tool was then validated by prospectively testing it on 170 CSP patients at 2 institutions.³⁵ Seventy-eight men repeated the COSI before therapy and 42 repeated it after surgical therapy. Data were analyzed for test/retest internal reliability, internal consistency, floor and ceiling effects, construct validity, responsiveness and linear regression of all questions including age, duration, and prior surgeries. Mean total COSI was 20.0 ± 7.7 (range 1–37) with sub-scores of pain 9.1 ± 3.5 (0–17), sexual symptoms 1.82 ± 1.5 (0–5) and quality of life 9.0 ± 4.0 (0–15). Test/retest reliability was high with mean retest total score of 21.2 ± 7.9 and intraclass correlation coefficient of 0.82. Internal consistency by Cronbach's alpha was 0.86. There were no floor or ceiling effects for total score. Construct validity showed all items contributed to a good fit model ($P = 0.001$). Patient age, duration, and prior surgeries did not influence COSI. Finally, the COSI was responsive to improvement after therapy (mean after treatment 13.5 ± 9.8 , $P = 0.00001$). Thus, the COSI was found to be a valid and clinically relevant symptom index to assess the severity of symptoms and response to therapy in CSP patients.

Treatment Algorithm for Chronic Orchialgia or Chronic Scrotal Content Pain (CSP)

The following algorithm for the assessment, evaluation and treatment of CSP patients is based on a current literature review of published peer reviewed articles on PubMed (National Library of Medicine) focusing on the most current publication timeframe of 2000 to 2020. Figure 1 illustrates the overall assessment and treatment algorithm. The individual treatment modalities are described in detail in the following sections of this review.

Conservative or Non-Surgical Treatment Options

Starke et al¹⁵ had a recent review on medical treatments for CSP. Even though most urologists would empirically treat most CSP patients with antibiotics, only about 22% of these patients may have an infectious etiology, and thus the widespread use of antibiotics for CSP patients may not be warranted.³⁶ Non-steroidal anti-inflammatory drugs (NSAIDs) are one of the first-line treatment options for patients with CSP. Supportive undergarments, hot/cold

packs and warm baths are additional treatment modalities that may help these patients.

Low dose anxiolytics or tricyclic anti-depressants (amitriptyline, doxepin and nortriptyline) may also be used and may provide up to a 51% reduction in pain.^{37,38} Neuromodulating drugs such as gabapentin may also be utilized and provide significant (>50%) reduction in pain in up to 80% of patients.³⁸ There are also a number of homeopathic or natural medications as well that offer neuro-modulatory effects without some of the side effects associated with gabapentin and some of the anxiolytics.^{39,42} One such medication contains palmitic acid mono-ethanolamide (PEA) (Canabrex, Theralogix, Rockville, MD, USA). PEA has been shown to significantly reduce pain in patients with chronic pain in a recent meta-analysis study.³⁹

Vitamin B12 and/or testosterone deficiencies may also lead to CSP.⁴³ Correction of such deficiencies may alleviate pain in some of these patients and may be another non-surgical approach to reducing their pain. Some CSP patients may have bladder neck hypertrophy that could be causing some of their pain.⁴⁴ In these cases, alpha-adrenergic blockade therapy may be helpful. Pelvic floor therapy and acupuncture may also help CSP patients in reducing pain levels.^{45,46}

If conservative treatment fails to provide the CSP patients with satisfactory pain relief, if they have recurrent pain, or if the patients do not want to keep taking medications, or if physical therapy sessions, or if the patients simply would like to try more permanent solutions, then surgical interventions may be pursued.

Targeted Spermatic Cord Block and/or Ilioinguinal Block

If the pain associated with CSP patients has a neurological pathway as suggested above in the pathophysiology section, then a targeted anesthetic nerve block or spermatic cord and/or ilioinguinal block should provide the patient with temporary relief in pain. Thus, the standard of care is to perform such targeted blocks in CSP patients prior to targeted surgical or ablative treatment techniques.^{16,17} The effects of these anesthetic blocks are usually short lived, and the pain usually returns. However, these targeted blocks provide for significant predictive value in response to surgical treatments for CSP patients. Benson et al¹⁶ found that a positive response to an anesthetic spermatic cord block was an independent predictor of response to

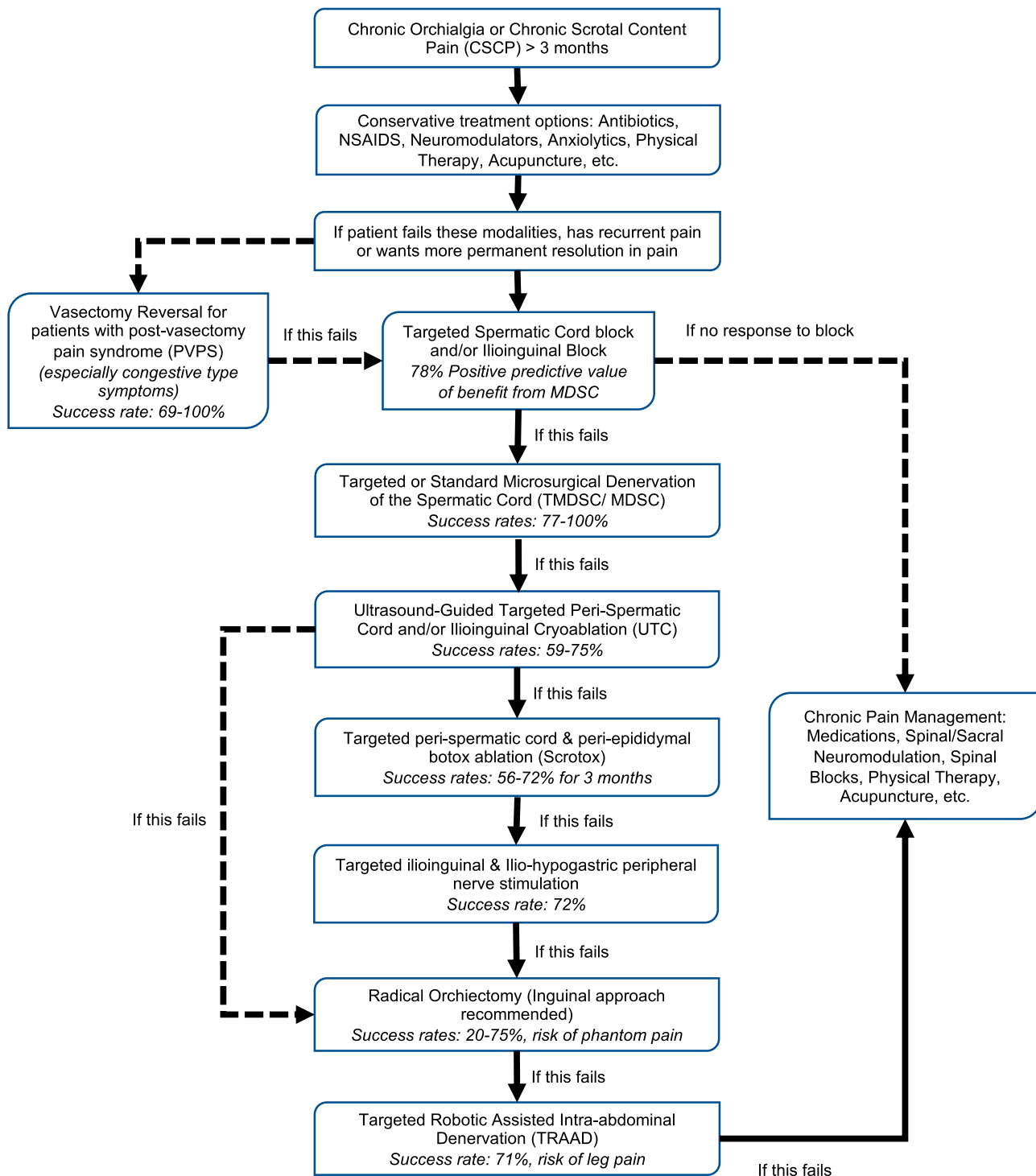


Figure 1 Chronic orchialgia or chronic scrotal content pain (CSP) management algorithm.

microsurgical denervation of the spermatic cord (MDSC) in a study on 74 men who underwent a cord block prior to MDSC. A follow-up study by our group confirmed these findings.¹⁷ Parekattil et al¹⁷ performed a retrospective review of 1261 MDSC cases (1112 patients, 149 bilateral cases) from October 2008 to July 2019. An analysis of

how the patients who had temporary relief in their pain (greater than 50% reduction) after a spermatic cord block (SCB) correlated to their final outcome after MDSC was performed. The outcome after MDSC was graded as complete relief (CR) in pain, greater than 50% reduction in pain (PR) or no response (NR), defined as <50% reduction

in pain. This outcome was based on preoperative and postoperative measurements of pain using a validated quality of life metric (PIQ-6) and the visual analogue pain score (VAS). CR was defined as a 10 point reduction in the PIQ-6 score, 75% reduction in the COSI score, and VAS score less than 2. PR was defined as 5 point reduction in the PIQ-6 score, 50% reduction in the COSI score and VAS score less than 5. NR was defined as less than 5 point reduction in the PIQ-6 score, less than 50% reduction in the COSI and VAS score greater than or equal to 5. The positive predictive value (PPV) of a patient having a response to SCB and then achieving CR or PR was 78%, and achieving CR alone was 41%. The negative predictive value (NPV) of a patient who did not have any relief with SCB, and then achieving NR after MDSC was 57%. This study illustrated that if a patient has no response to SCB, MDSC is less likely to help reduce pain in these patients. However, a positive response to SCB confers a high likelihood of significant reduction in pain after MDSC. Sixty-three patients (5%) reported some scrotal skin discoloration or contusions after SCB. One spermatic cord hematoma was reported (this resolved over a one month period). Ultrasound guidance was not utilized. The technique is described below.

Technique for Targeted Spermatic Cord Block and/or Ilioinguinal Block

Our technique for the spermatic cord block is based on the trifecta-nerve complex described above in the pathophysiology section. Initially, 5cc of the mixture is injecting along to and next to the vas deferens. This is achieved by first palpating the vas deferens in the upper scrotal area and then placing the needle next to the vas and then injecting in one location without withdrawing and reinserting the needle to minimize the risk of vessel injury. This provides anesthesia to the peri-vasal tissues and sheath. Next, the physicians' finger is placed in the external inguinal ring. 27cc of local anesthetic mixture is injected on either side of the physicians finger at the level of the external inguinal ring to bathe the outer areas and cremasteric layer of the spermatic cord with anesthetic while minimizing injury to the testicular arteries and veins. The mixture we utilize comprises: 15cc 2% lidocaine (without epinephrine), 15cc 0.5% Marcaine (without epinephrine) and 2cc 8mg decadron. If we perform a bilateral block, half the solution is utilized on each side. If we perform the block on one side, then the full volume is used on one side. If the patient has groin pain in

addition to testicular pain, and/or pain that radiates to the hip area, then an ilioinguinal block may be performed as well. This block is performed by utilizing 10cc from the total 32cc mixture volume and injecting 2cm medial and inferior to the anterior superior iliac spine about 1–2cm deep to the skin surface. We tend to perform our blocks on patients under intravenous sedation for maximal patient comfort and also for surgical ease.

Targeted or Standard Microsurgical Denervation of the Spermatic Cord (TMDSC or MDSC)

Microsurgical denervation of the spermatic cord (MDSC) is a well-established treatment option for patients with CSP. Numerous groups have published success rates ranging from 77–100% in terms of significant reduction or elimination of pain.^{18,21,22,47,62} The trifecta nerve complex mentioned in the pathophysiology section above explains the benefit of MDSC in CSP patients. Ligation of the nerves with Wallerian degeneration in the trifecta is likely to provide pain relief or reduction in CSP patients undergoing MDSC. The standard MDSC involves ligation of all the structures in the spermatic cord apart from an artery, vein and lymphatic channel. This is quite an aggressive procedure that may result in testicular atrophy, testicular loss, hydrocele or lymphocele in some cases. To minimize this risk, our group has developed a more targeted approach (TMDSC) that only involves the ligation of the trifecta complex: 1) cremasteric muscle layer, 2) the peri-vasal tissues and sheath (we preserve the vas deferens) and 3) the posterior cord lipomatous tissues.¹⁸ Calixte et al¹⁸ reviewed 772 patients (860 cases) who underwent TMDSC from October 2007 to July 2016. Pain was assessed preoperatively and postoperatively using a subjective visual analog scale and objectively with the standardized and validated PIQ-6 (Pain Impact Questionnaire-6) score. During a median follow-up of 24 months (range 1 to 70), 718 cases (83%) showed a significant reduction in pain and 142 (17%) had no change in pain by subjective visual analog scale scoring. Of cases with a significant reduction in pain 426 (49%) had complete resolution (CR) and 292 (34%) had a 50% or greater reduction (PR). Objective PIQ-6 analysis showed a significant reduction in pain in 67% of patients 6 months postoperatively, in 68% at 1 year, in 77% at 2 years, in 86% at 3 years and in 83% at 4 years. CR was defined as a 10 point reduction in the PIQ-6 score, and VAS score less than 2.

PR was defined as 5 point reduction in the PIQ-6 score, and VAS score less than 5. NR was defined as less than 5 point reduction in the PIQ-6 score, less than 50% reduction in the COSI and VAS score greater than or equal to 5. During the 9 year study period, 2 testicular artery injuries occurred during TRMDSC, which were identified intraoperatively. Each testicular artery repair was performed with 7-zero polypropylene interrupted sutures. Arterial flow through the anastomosis was confirmed at the completion of the repair. There has been no evidence of long-term testicular atrophy. This occurred early in the study cohort and with technique refinement the study group have not encountered any such further occurrences. One testis was lost after TMDSC in a patient who had previously sustained severe pelvic injuries, and who underwent several pelvic and groin exploratory procedures prior to TMDSC. The testicular artery and the vasal artery were injured during the prior trauma and reconstructive surgeries. At the time of TRMDSC, there was no flow in the testicular and vasal arteries. A single cremasteric artery with good blood flow was preserved and there was good flow at the end of the case. However, this patient presented about a week later with testicular pain and no flow in that testicle on Doppler ultrasound. He underwent radical orchiectomy and had a significant decrease in pain postoperatively. This study illustrated that TMDSC provided identical outcomes to MDSC with less potential morbidity. Kavoussi et al confirmed these findings in his study comparing 39 men who underwent MDSC to 43 men who underwent TMDSC.⁴⁹ When comparing the MSCD group to the TMSCD group, there was no significant difference in resolution of pain (66.7% vs 69.8%, $P = 0.88$), no difference in partial relief of pain (17.9% vs 23.3%, $P = 0.55$), and no difference in failure to respond rates (15.4% vs 7.0%, $P = 0.22$) between the two groups. There was no difference in mean change of visual analog pain scale scores between the two groups ($P = 0.27$). TMSCD had a shorter operative time (53 min vs 21 min, $P = 0.0001$). TMSCD offers patients comparable outcomes to standard MSCD, with a shorter operative time, a less technically challenging surgery, and potentially less risk to cord structures which should be preserved. Kavoussi et al⁴⁹ did not find any differences in any postoperative complications between the two groups in this study.

Technique for Targeted Microsurgical Denervation of the Spermatic Cord (TMDSC)

The patient is induced under anesthesia in supine position for maximal patient comfort and surgical ease. The patient

is then prepped and draped in standard surgical fashion. A 1–2cm sub-inguinal incision is performed. The spermatic cord is then dissected and brought out through the incision. The cord is then secured over a tongue blade. The microsurgical or robotic-assisted microsurgical platform is now brought in. The cremasteric layer of the spermatic cord is then carefully ligated. A micro doppler (Vascular Technology Inc, Nashua, NH, USA) is utilized to localize the testicular arteries and preserve them. The vas deferens is dissected with care taken to preserve the deferential artery. The peri-vasal tissues and sheath are carefully ligated. The posterior lipomatous cord tissue is carefully ligated. The entire internal spermatic sheath is preserved, so the majority of the spermatic cord is preserved. A bio-protective wrap (Cygnus Wrap, Scendia Biologics Inc., Orlando, FL, USA) is placed around the spermatic cord to reduce postoperative scarring in the area.⁶³ The cord is then released into the wound and the wound is closed in 2 layers: 1) the subcutaneous fat layer with 2–0 quill suture (Quill, Surgical Specialties, Wyomissing, PA, USA) and hydrolyzed collagen powder (Cellerate, Scendia Biologics Inc., Orlando, FL, USA), and 2) the skin layer with 3–0 quill suture (Quill, Surgical Specialties, Wyomissing, PA, USA), zipline wound closure (Zipline, CA, USA) and skin glue.

Ultrasound-Guided Targeted Peri-Spermatic Cord and/or Ilioinguinal Cryoablation (UTC)

In CSP patients who fail to respond to TMDSC/MDSC or CSP patients who would like a less invasive treatment option, ultrasound-guided targeted peri-spermatic cord and/or ilioinguinal cryoablation (UTC) is another effective option.²³ Calixte et al²³ reviewed 279 cases (221 patients: 58 bilateral) undergoing UTC between Nov 2012 to July 2016, who had failed prior TMDSC. UTC was performed using a 16-gauge cryo needle (Endocare, HealthTronics, Austin, TX). Branches of the genitofemoral, ilioinguinal and inferior hypogastric nerves were cryoablated medial and lateral to the spermatic cord at the level of the external inguinal ring. Level of pain was measured preoperatively and postoperatively using the Visual Analog Scale (VAS) and Pain Index Questionnaire (PIQ-6) (QualityMetric Inc., Lincoln, RI). Median follow-up was 36 months (24 to 60). Using subjective VAS outcomes, 75% of the patients had a significant reduction in pain (11% complete resolution and 64% \geq 50% reduction

in pain). Using objective PIQ-6 outcomes, 53% had a significant reduction at 1 month (279 cases), 55% at 3 months (279 cases), 60% at 6 months (279 cases), 63% at 1yr (279 cases), 65% at 2yrs (275 cases), 64% at 3yrs (232 cases), 59% at 4yrs (128 cases) and 64% at 5 yrs (53 cases). CR was defined as a 10 point reduction in the PIQ-6 score, and VAS score less than 2. PR was defined as 5 point reduction in the PIQ-6 score, and VAS score less than 5. NR was defined as less than 5 point reduction in the PIQ-6 score, and VAS score greater than or equal to 5. The only complications were two wound infections and four penile pain cases (resolved in a few months). This study illustrated that UTC is a safe treatment option for the salvage management of persistent CSP in patients who have failed MDSC/TMDSC.

UTC may also be utilized in CSP patients who have residual groin or peri-incisional pain several months after MDSC/TMDSC. If they respond to targeted blocks in these areas, they may then be candidates for more permanent pain relief by performing UTC in these areas.

Technique for Ultrasound-Guided Targeted Peri-Spermatic Cord and/or Ilioinguinal Cryoablation (UTC)

The patient is induced in supine position under intravenous anesthetic sedation to maximize patient comfort.²³ The patient is then prepped and draped in standard surgical fashion. A spermatic cord anesthetic block is administered as described above prior to the initiation of UTC. 1mL of injectable amniotic membrane derivative (Allogen, Scendia Biologics Inc., Orlando, FL, USA) diluted in 3cc of injectable saline is injected as a buffer/spacer agent between the medial edge of the spermatic cord and the lateral margin of the penile corporal body under ultrasound guidance. This is done to minimize any potential irritation of the penile sensory nerves. When we initially performed these cases, we had 4 men develop post-op penile pain that lasted a few months and then resolved. After initiation of this modification, we have not observed any further cases of penile pain. Under real-time ultrasound guidance, a 16-gauge cryo needle (Endocare, HealthTronics, Austin, TX) is then inserted medial and then lateral to the spermatic cord to the level of the external inguinal ring (3–4cm depth of the needle). Cryoablation is performed for 90 seconds at each location, twice, with a passive thaw session in between the ablative sessions.²³ After completion of the treatment, the needle is withdrawn and antibiotic gel applied to the puncture sites. A jock-support and fluff

dressings are usually applied to the scrotum to minimize any post-op swelling.

In CSP patients who may have residual groin pain after MDSC/TMDSC resolves their testicular pain, UTC may be applied to the ilioinguinal nerve to provide pain relief in these higher areas. For this indication, the cryo needle is inserted aiming infero-medially 2cm medial and inferior to the anterior superior iliac spine under ultrasound guidance to ablate the ilioinguinal nerve. Cryoablation is performed for 90 seconds at this location, twice, with a passive thaw session in between the ablative sessions.

In CSP patients who may have chronic peri-incisional pain after MDSC/TMDSC at the sub-inguinal incision site, UTC may be utilized to significantly reduce this pain.⁶⁴ For this indication, the cryo needle is inserted along the length of the incision at a depth of about 1cm. Cryoablation is performed for 90 seconds at this location, twice, with a passive thaw session in between the ablative sessions. The patient may experience some skin erythema and irritation at the wound site, and should be instructed to apply antibiotic cream/gel to the incision site twice a day for 2 weeks.

Targeted Peri-Spermatic Cord and Peri-Epididymal Botox Ablation (Scrotox)

Khambati et al²⁵ have shown that onabotulinumtoxinA (Botox) cord blocks provide pain relief for men with CSP for a 3 month period in a study involving 18 CSP patients. At the 1-month follow-up, pain reduction was reported by 72% of patients (mean VAS score: 7.36 vs 5.61, $P < 0.003$). In addition, there was also a significant reduction in Chronic Epididymitis Symptom Index (CESI) scores (22.19 vs 19.25, $P < 0.04$). At 3 months, 56% had both sustained pain reduction and reduced tenderness based on the VAS score (mean: 7.36 vs 6.02, $P < 0.05$) and physical exam. The CESI score continued to be significantly lower. However, by 6 months, most men had a return to their baseline levels of pain and tenderness.

Dockrey et al⁶⁵ have recently performed a randomized, double-blind, controlled trial that showed no superiority of onabotulinum toxin A plus local anesthesia over local anesthesia alone for pain control in men with CSP. Interestingly, a significant pain improvement was noted in their open label onabotulinum toxin A trial, suggesting a potential placebo effect.

Calixte et al⁶⁶ performed a retrospective review of 44 patients with failed MDSC who underwent Scrotox from July 2013–2016. One hundred units of Botox diluted in

10cc of saline were injected medial and lateral to the spermatic cord at the level of the external inguinal ring. The primary outcome measure was the level of pain. Pain was assessed preoperatively and postoperatively using the subjective visual analog scale (VAS) and an objective standardized externally validated pain assessment tool (PIQ-6). Median follow up was 18 months; 63% of the CSP patients have a significant reduction in pain (CR & PR) based on the subjective VAS. Objective PIQ-6 assessment illustrated a significant reduction (CR & PR) in pain in 27% of patients at 6 months and 40% at 1 year. CR was defined as a 10 point reduction in the PIQ-6 score, and VAS score less than 2. PR was defined as 5 point reduction in the PIQ-6 score, and VAS score less than 5. NR was defined as less than 5 point reduction in the PIQ-6 score, and VAS score greater than or equal to 5. This study found some of these patients were getting a durable pain reduction response out to about 1 year. One note is that this study utilized 100 IU of BOTOX with 10cc saline, contrary to the aforementioned RCT which used local anesthesia plus 200 IU of Onabotulinum toxin A.

Scrotox may be a viable, minimally invasive treatment option for CSP patients, but may require the patient to keep coming back for retreatment given the likelihood of recurrence of pain to baseline pre-treatment levels after 3 to 12 months.

Technique for Targeted Peri-Spermatic Cord and Peri-Epididymal Botox Ablation (Scrotox)

Our technique for Scrotox is based on the trifecta-nerve complex described above in the pathophysiology section. The patient is induced under intravenous anesthetic sedation in supine position. A spermatic cord block is administered as described above in the cord block section. One hundred units of onabotulinumtoxinA (Botox) are diluted into 10cc of injectable saline. This mixture is then injected medial and lateral to the spermatic cord at the level of the external inguinal ring similar to the cord block technique. If the patient has point tenderness or trigger pain at the epididymis, then 2cc of the mixture is injected along the periphery of the epididymis (in this case, the remaining 8cc is then injected medial and lateral to the cord). Ultrasound guidance is utilized to prevent inadvertent injection of botox into any blood vessels.

Targeted Ilioinguinal and Iliohypogastric Peripheral Nerve Stimulation

Peripheral nerve field stimulation has been shown to be effective to treating CSP patients.²⁶ Traditionally, such

techniques are usually employed by pain management specialists. However, with the advent of new minimally invasive technology (Stimrouter, Bioness Inc., Valencia, CA, USA), urologists can now perform testing and placement of a novel implantable stimulation electrode along the course of the ilioinguinal nerve in the groin. This opens a new avenue of treatment options for CSP patients.

Radical Orchiectomy (Inguinal Approach Recommended)

When some of the above targeted therapies for CSP fail, there is the option of orchiectomy. Prior studies have suggested that outcomes are better if an inguinal approach (radical) is utilized over a scrotal approach.^{61,67} This option must only be pursued after a careful discussion with the patient about the pros and cons of such an aggressive approach. There is a small risk of phantom pain after radical orchiectomy and the pain may develop on the contralateral testicle after removal of the painful testicle. The mechanism of this pain is poorly understood and thus, the patient should explore more targeted therapies initially prior to pursuing this course of action. Success rates for significant reduction in pain range in the 20–75% range.⁶⁷

Targeted Robotic-Assisted Intra-Abdominal Denervation (TRAAD)

There are limited options for patients who fail MDSC/TMDSC or patients who have persistent pain after an orchiectomy for CSP. One option for these difficult cases is Targeted robotic-assisted intra-abdominal denervation (TRAAD) of the genitofemoral and inferior hypogastric nerves proximal to the internal inguinal ring. This is similar to what the general surgeons refer to as a tri-neurectomy procedure.⁶⁸ In the tri-neurectomy procedure, the genitofemoral, ilioinguinal and iliohypogastric nerves are all ligated for patients with chronic abdominal pain or chronic groin pain. The success rates range between 70–80%.⁶⁸ However, due to the location of this ligation in the pre-peritoneal space, and the ligation of the ilioinguinal nerve, these patients will have sensory deficits along the skin in the groin and scrotum. This can be quite debilitating in patients if they have persistent pain and also have this sensory loss. This is what led our group to develop the TRAAD technique, where we preserve the ilioinguinal nerve and only ligate the genitofemoral and

inferior hypogastric nerve contributions within the abdomen above the internal inguinal ring.

Calixte et al⁶⁶ performed a retrospective review of 82 patients who underwent TRAAD from June 2009 to April 2019. Selection criteria were as follows: chronic groin pain (>3 months), failed standard pain management treatments (including MDSC), patients who have persistent pain after orchiectomy and negative urologic workup. A robotic platform was utilized (DaVinci, Intuitive Surgical, Sunnyvale, CA). Pain was assessed preoperatively and postoperatively using two assessment tools: 1) the subjective visual analog scale (VAS) and 2) a standardized externally validated pain assessment tool (PIQ-6, QualityMetric Inc., Lincoln, RI). Median operative duration (robot console time) was 20 minutes; 71% (58) of patients had a significant reduction (PR) in pain (>50%); 33% (27) of patients had complete relief (CR) in pain. The mean follow-up was 71 months (4 to 120). CR was defined as a 10 point reduction in the PIQ-6 score, 75% reduction in the COSI score, and VAS score less than 2. PR was defined as 5 point reduction in the PIQ-6 score, 50% reduction in the COSI score and VAS score less than 5. NR was defined as less than 5 point reduction in the PIQ-6 score, less than 50% reduction in the COSI and VAS score greater than or equal to 5. One patient developed pain at the assistant port site and one patient had port site bleeding both were treated conservatively. Two patients developed leg spasms/pain: one resolved with observation; one has persistent leg pain. TRAAD of the genitofemoral and inferior hypogastric nerves is thus a viable treatment option for patients with chronic groin pain refractory to MDSC or orchiectomy.

Technique for Targeted Robotic-Assisted Intra-Abdominal Denervation (TRAAD)

The patient is induced under general anesthesia and positioned in modified dorsal lithotomy position similar to that for a robotic-assisted laparoscopic prostatectomy. The patient is placed in Trendelenburg position and then prepped and draped in standard surgical fashion. Laparoscopic/Robotic port access is obtained and usually 3 ports are utilized. One for the robotic camera, and two instrument arms – the micro-bipolar grasper in the left arm and the curved monopolar scissors in the right arm. Attention is focused on the internal inguinal ring on the side of the afflicted testicle. The gonadal vessels are carefully skeletonized to preserve the vessels, but ligate all the adventitial tissue (contains the genitofemoral nerve

branches). The vas deferens is also carefully dissected free and the peri-vasal tissues ligated (contains branches of the inferior hypogastric nerve plexus). Care is taken to preserve the deferential artery. If TRAAD is being performed in a CSP who has already had an orchiectomy, then the procedure is very simple: the gonadal vessels and the cord leading into the internal inguinal ring are carefully ligated. The vas is also ligated in this case. This completes the procedure and the instruments and ports are all removed. The port sites are then all closed.

Vasectomy Reversal for Patients with Post-Vasectomy Pain Syndrome (PVPS)

A special subset of CSP patients are those that have PVPS. The incidence of PVPS has been reported in a new meta-analysis as higher than previously reported.⁶⁹ Auyeung et al have reported that the incidence of post-vasectomy pain is 15%.⁶⁹ The no-scalpel minimally technique of vasectomy was associated with less PVPS than more traditional scalpel techniques. They found that the incidence of PVPS was 5%. One treatment option with good success rates for these CSP patients is a vasectomy reversal, especially if these patients have more congestive type pain symptoms such as bilateral testicular pain that gets worse after ejaculation. In these patients, vasectomy reversal should be the first-line therapy after conservative treatments have failed. Success of significant reduction in pain from a vasectomy reversal in these CSP patients ranges in the 69–100% range.^{6,70,71} If CSP patients who undergo a vasectomy reversal still have persistent pain, then targeted blocks, MDSC/TMDSC are also viable treatment options.²¹ In CSP patients with PVPS who have more constant, unilateral or nerve-type pain, MDSC/TMDSC may be a better option.⁷²

Chronic Pain Management

When all else fails, and the CSP patient still has pain despite all the above-mentioned treatment options, working with a pain management specialist to explore other options such as: chronic pain medications, spinal and/or sacral neuromodulation, spinal blocks, etc., may be the way forward. The key is to be supportive of the patient and give them hope of future interventions that may become available over time. Physical Therapy, acupuncture, and behavioral therapy are also great adjunctive modalities that can be employed during the entire CSP experience.

Conclusion

CSP is a debilitating and difficult condition to treat. As urologists, we need to provide support and guidance for these patients as they navigate through this myriad of treatments options and most importantly remind them not to give up and work with a collaborating group of caregivers and family to take care of all aspects of their well-being: the physical, mental and emotional realms. This review provides a structured and evidence-based approach to help urologists manage patients with chronic orchialgia or scrotal content pain.

Acknowledgments

The authors would like to thank the numerous patients who have helped provide us with a better understanding of chronic scrotal content pain (CSP) or orchialgia. Through their trials and tribulations, we have been allowed to better understand the pathophysiology of this difficult condition and try to provide treatment options to reduce their pain and suffering.

Disclosure

The authors report no conflicts of interest in this work.

References

- Sigalos JT, Pastuszak AW. Chronic orchialgia: epidemiology, diagnosis and evaluation. *Transl Androl Urol.* 2017;6(Suppl 1):S37–S43. doi:10.21037/tau.2017.05.23
- Khandwala YSZC, Eisenberg ML, Eisenberg ML. Trends in prevalence, management and cost of scrotal pain in the United States between 2007 and 2014. *Urol Pract.* 2018;5(4):272–278. doi:10.1016/j.urpr.2017.06.002
- Jorgensen SG, Oberg S, Rosenberg J. Treatment of longstanding groin pain: a systematic review. *Hernia.* 2019;23(6):1035–1044. doi:10.1007/s10029-019-01919-7
- Ziegelmann MJ, Farrell MR, Levine LA. Evaluation and management of chronic scrotal content pain – a common yet poorly understood condition. *Rev Urol.* 2019;21(2–3):74–84.
- Myers SA, Mershon CE, Fuchs EF. Vasectomy reversal for treatment of the post-vasectomy pain syndrome. *J Urol.* 1997;157(2):518–520. doi:10.1016/S0022-5347(01)65191-7
- Nangia AK, Myles JL, Thomas AJ. Vasectomy reversal for the post-vasectomy pain syndrome: a clinical and histological evaluation. *J Urol.* 2000;164(6):1939–1942. doi:10.1016/S0022-5347(05)66923-6
- Loos MJ, Roumen RM, Scheltinga MR. Classifying post-herniorrhaphy pain syndromes following elective inguinal hernia repair. *World J Surg.* 2007;31(9):1760–1765. doi:10.1007/s00268-007-9121-4
- Massaron S, Bona S, Fumagalli U, Battafarano F, Elmore U, Rosati R. Analysis of post-surgical pain after inguinal hernia repair: a prospective study of 1440 operations. *Hernia.* 2007;11(6):517–525. doi:10.1007/s10029-007-0267-7
- McLoughlin J, Kelley CJ. Study of the effectiveness of bupivacaine infiltration of the ilioinguinal nerve at the time of hernia repair for post-operative pain relief. *Br J Clin Pract.* 1989;43(8):281–283.
- Gjertson CK, Sundaram CP. Testicular pain following laparoscopic renal surgery. *J Urol.* 2008;180(5):2037–2040. doi:10.1016/j.juro.2008.07.045
- Srivastava A, Kapoor R, Srivastava A, Ansari MS, Singh M, Kapoor R. Orchialgia after laproscopic renal surgery: a common problem with questionable etiology. Are there any predictors? *World J Urol.* 2013;31(5):1153–1157. doi:10.1007/s00345-012-0864-7
- Sureka SK, Srivastava A, Agarwal S, et al. Prevention of orchialgia after left-sided laparoscopic donor nephrectomy – a prospective study. *J Endourol.* 2015;29(6):696–699. doi:10.1089/end.2014.0645
- Vistad I, Cvancarova M, Kristensen GB, Fossa SD. A study of chronic pelvic pain after radiotherapy in survivors of locally advanced cervical cancer. *J Cancer Surviv.* 2011;5(2):208–216. doi:10.1007/s11764-011-0172-z
- Ayyaz U, Haq M, Rashid M, et al. Incidence and clinical course of limb dysfunction post cardiac catheterization- a systematic review. *Circ J.* 2018;82(11):2736–2744. doi:10.1253/circj.CJ-18-0389
- Starke NR, Costabile RA. Medical management of chronic orchialgia. *Transl Androl Urol.* 2017;6(Suppl 1):S48–S50. doi:10.21037/tau.2017.05.18
- Benson JS, Abern MR, Larsen S, Levine LA. Does a positive response to spermatic cord block predict response to microdenervation of the spermatic cord for chronic scrotal content pain? *J Sex Med.* 2013;10(3):876–882. doi:10.1111/j.1743-6109.2012.02937.x
- Parekattil SJGA, Ergun O, Etafy M, Calixte N, Brahmbhatt JMR. What is the predictive value of a spermatic cord block prior to microsurgical denervation of the spermatic cord? *AUA Podium Abstract.* 2020;203:1202–e1202.
- Calixte N, Tojuola B, Kartal I, et al. Targeted robotic assisted microsurgical denervation of the spermatic cord for the treatment of chronic orchialgia or groin pain: a single center, large series review. *J Urol.* 2018;199(4):1015–1022. doi:10.1016/j.juro.2017.10.030
- Kavoussi PK. Validation of targeted microsurgical spermatic cord denervation: comparison of outcomes to traditional complete microsurgical spermatic cord denervation. *Asian J Androl.* 2018;21:319.
- Levine LA. Microsurgical denervation of the spermatic cord. *J Sex Med.* 2008;5(3):526–529. doi:10.1111/j.1743-6109.2007.00762.x
- Tan WP, Levine LA. Micro-denervation of the spermatic cord for post-vasectomy pain management. *Sex Med Rev.* 2018;6(2):328–334. doi:10.1016/j.sxmr.2017.06.002
- Tu XA, Gao Y, Zhang YD, et al. Microsurgical denervation of the spermatic cord for treatment of idiopathic chronic orchialgia. *Chin Med J (Engl).* 2012;125(15):2784–2786.
- Calixte N, Kartal IG, Tojuola B, et al. Salvage ultrasound guided targeted cryoablation of the peri-spermatic cord for persistent chronic scrotal content pain after microsurgical denervation of the spermatic cord. *Urology.* 2019;130:181–185. doi:10.1016/j.urology.2019.04.027
- Campos NA, Chiles JH, Plunkett AR. Ultrasound-guided cryoablation of genitofemoral nerve for chronic inguinal pain. *Pain Physician.* 2009;12(6):997–1000.
- Khambati A, Lau S, Gordon A, Jarvi KA. OnabotulinumtoxinA (Botox) nerve blocks provide durable pain relief for men with chronic scrotal pain: a pilot open-label trial. *J Sex Med.* 2014;11(12):3072–3077. doi:10.1111/jsm.12707
- Verrills P, Vivian D, Mitchell B, Barnard A. Peripheral nerve field stimulation for chronic pain: 100 cases and review of the literature. *Pain Med.* 2011;12(9):1395–1405. doi:10.1111/j.1526-4637.2011.01201.x
- Voorbrood CE, Burgmans JP, Van Dalen T, et al. An algorithm for assessment and treatment of postherniorrhaphy pain. *Hernia.* 2015;19(4):571–577. doi:10.1007/s10029-015-1387-0
- Kavoussi PK, Costabile RA. Orchialgia and the chronic pelvic pain syndrome. *World J Urol.* 2013;31(4):773–778. doi:10.1007/s00345-013-1092-5
- Ronka K, Vironen J, Kokki H, Liukkonen T, Paajanen H. Role of orchietomy in severe testicular pain after inguinal hernia surgery: audit of the Finnish Patient Insurance Centre. *Hernia.* 2015;19(1):53–59. doi:10.1007/s10029-013-1150-3

30. Ko MH, Hsieh YL, Hsieh ST, Tseng TJ. Nerve demyelination increases metabotropic glutamate receptor subtype 5 expression in peripheral painful mononeuropathy. *Int J Mol Sci.* 2015;16(3):4642–4665. doi:10.3390/ijms16034642
31. Woolf CJ, Salter MW. Neuronal plasticity: increasing the gain in pain. *Science.* 2000;288(5472):1765–1769. doi:10.1126/science.288.5472.1765
32. Oka S, Shiraishi K, Matsuyama H. Microsurgical anatomy of the spermatic cord and spermatic fascia: distribution of lymphatics, and sensory and autonomic nerves. *J Urol.* 2016;195(6):1841–1847. doi:10.1016/j.juro.2015.11.041
33. Parekattil SJ, Gudeloglu A, Brahmabhatt JV, Priola KB, Vieweg J, Allan RW. Trifecta nerve complex – potential anatomic basis for microsurgical denervation of the spermatic cord for chronic orchialgia. *J Urol.* 2013;190(1):265–270. doi:10.1016/j.juro.2013.01.045
34. Polackwich AS, Arora HC, Li J, et al. Development of a clinically relevant symptom index to assess patients with chronic orchialgia/chronic scrotal content pain. *Transl Androl Urol.* 2018;7(Suppl 2):S163–S168. doi:10.21037/tau.2018.04.10
35. Shoskes DA, Calixte N, Tadros N, Li J, Parekattil S. Validation of the chronic orchialgia symptom index for men with chronic orchialgia/chronic scrotal contents pain. *Urology.* 2018;119:39–43. doi:10.1016/j.urolgy.2018.05.030
36. Strelbel RT, Schmidt C, Beatrice J, Sulser T. Chronic scrotal pain syndrome (CSPS): the widespread use of antibiotics is not justified. *Andrology.* 2013;1(1):155–159. doi:10.1111/j.2047-2927.2012.00017.x
37. Costabile RA, Hahn M, McLeod DG. Chronic orchialgia in the pain prone patient: the clinical perspective. *J Urol.* 1991;146(6):1571–1574. doi:10.1016/S0022-5347(17)38169-7
38. Sinclair AM, Miller B, Lee LK. Chronic orchialgia: consider gabapentin or nortriptyline before considering surgery. *Int J Urol.* 2007;14(7):622–625. doi:10.1111/j.1442-2042.2007.01745.x
39. Artukoglu BB, Beyer C, Zuloff-Shani A, Brener E, Bloch MH. Efficacy of palmitoylethanolamide for pain: a meta-analysis. *Pain Physician.* 2017;20(5):353–362.
40. Galeotti N. Hypericum perforatum (St John's wort) beyond depression: a therapeutic perspective for pain conditions. *J Ethnopharmacol.* 2017;200:136–146. doi:10.1016/j.jep.2017.02.016
41. Teixeira MZ, Podgaec S, Baracat EC. Potentized estrogen in homeopathic treatment of endometriosis-associated pelvic pain: a 24-week, randomized, double-blind, placebo-controlled study. *Eur J Obstet Gynecol Reprod Biol.* 2017;211:48–55. doi:10.1016/j.ejogrb.2017.01.052
42. Oltean H, Robbins C, van Tulder MW, Berman BM, Bombardier C, Gagnier JJ. Herbal medicine for low-back pain. *Cochrane Database Syst Rev.* 2014;12:CD004504.
43. Cui T, Terlecki R. Prevalence of relative deficiencies in testosterone and vitamin b12 among patients referred for chronic orchialgia: implications for management. *Am J Mens Health.* 2018;12(3):608–611. doi:10.1177/1557988316642723
44. Hruz P, Danuser H, Studer UE, Hochreiter WW. Non-inflammatory chronic pelvic pain syndrome can be caused by bladder neck hypertrophy. *Eur Urol.* 2003;44(1):106–110. doi:10.1016/S0302-2838(03)00203-3
45. Passavanti MB, Pota V, Sansone P, Aurilio C, De Nardis L, Pace MC. Chronic pelvic pain: assessment, evaluation, and objectivation. *Pain Res Treat.* 2017;2017:9472925.
46. Zhong LJ, Wang J, Ding XH. Therapeutic effect of electroacupuncture on chronic orchialgia. *Zhongguo Zhen Jiu.* 2011;31(1):40–42.
47. Cassidy DJ. Early experience with microsurgical spermatic cord denervation for chronic orchialgia at a Canadian centre. *Can Urol Assoc J.* 2015;9(1–2):e72–74. doi:10.5489/cuaj.2383
48. Chaudhari R, Sharma S, Khant S, Raval K. Microsurgical denervation of spermatic cord for chronic idiopathic orchialgia: long-term results from an institutional experience. *World J Mens Health.* 2019;37(1):78–84. doi:10.5534/wjmh.180035
49. Kavoussi PK. Validation of targeted microsurgical spermatic cord denervation: comparison of outcomes to traditional complete microsurgical spermatic cord denervation. *Asian J Androl.* 2019;21(4):319–323. doi:10.4103/aja.aja_87_18
50. Kavoussi PK. Microsurgical subinguinal cremaster muscle release for chronic orchialgia secondary to hyperactive cremaster muscle reflex in adults. *Andrologia.* 2020;52(1):e13493. doi:10.1111/and.13493
51. Levine LA, Matkov TG. Microsurgical denervation of the spermatic cord as primary surgical treatment of chronic orchialgia. *J Urol.* 2001;165(6 Pt 1):1927–1929. doi:10.1016/S0022-5347(05)66244-1
52. Levine LA, Matkov TG, Lubenow TR. Microsurgical denervation of the spermatic cord: a surgical alternative in the treatment of chronic orchialgia. *J Urol.* 1996;155(3):1005–1007. doi:10.1016/S0022-5347(01)66369-9
53. Long H, Bai W, Zhang X, Xu T. A clinical study on microsurgical denervation of spermatic cord for refractory chronic orchialgia. *Urol Int.* 2019;103(1):62–67. doi:10.1159/000497281
54. Oomen RJ, Witjens AC, van Wijck AJ, Grobbee DE, Lock TM. Prospective double-blind preoperative pain clinic screening before microsurgical denervation of the spermatic cord in patients with testicular pain syndrome. *Pain.* 2014;155(9):1720–1726. doi:10.1016/j.pain.2014.05.022
55. Strom KH, Levine LA. Microsurgical denervation of the spermatic cord for chronic orchialgia: long-term results from a single center. *J Urol.* 2008;180(3):949–953. doi:10.1016/j.juro.2008.05.018
56. Tatem A, Kovac JR. Chronic scrotal pain and microsurgical spermatic cord denervation: tricks of the trade. *Transl Androl Urol.* 2017;6(Suppl 1):S30–S36. doi:10.21037/tau.2017.05.17
57. Oliveira RG, Camara C, Alves Jde M, Coelho RF, Lucon AM, Srougi M. Microsurgical testicular denervation for the treatment of chronic testicular pain initial results. *Clinics (Sao Paulo).* 2009;64(5):393–396. doi:10.1590/S1807-59322009000500004
58. Larsen SM, Benson JS, Levine LA. Microdenervation of the spermatic cord for chronic scrotal content pain: single institution review analyzing success rate after prior attempts at surgical correction. *J Urol.* 2013;189(2):554–558. doi:10.1016/j.juro.2012.09.026
59. Heidenreich A, Olbert P, Engelmann UH. Management of chronic testalgia by microsurgical testicular denervation. *Eur Urol.* 2002;41(4):392–397. doi:10.1016/S0302-2838(02)00023-4
60. Ahmed I, Rasheed S, White C, Shaikh NA. The incidence of post-vasectomy chronic testicular pain and the role of nerve stripping (denervation) of the spermatic cord in its management. *Br J Urol.* 1997;79(2):269–270. doi:10.1046/j.1464-410X.1997.32221.x
61. Davis BE, Noble MJ, Weigel JW, Foret JD, Mebust WK. Analysis and management of chronic testicular pain. *J Urol.* 1990;143(5):936–939. doi:10.1016/S0022-5347(17)40143-1
62. Devine CJ Jr, Schellhammer PF. The use of microsurgical denervation of the spermatic cord for orchialgia. *Trans Am Assoc Genitourin Surg.* 1978;70:149–151.
63. Lemke A, Ferguson J, Gross K, et al. Transplantation of human amnion prevents recurring adhesions and ameliorates fibrosis in a rat model of sciatic nerve scarring. *Acta Biomater.* 2018;66:335–349. doi:10.1016/j.actbio.2017.11.042
64. Gabriel RA, Finneran JJ, Asokan D, Trescot AM, Sandhu NS, Ilfeld BM. Ultrasound-guided percutaneous cryoneurolysis for acute pain management: a case report. *Case Rep.* 2017;9(5):129–132. doi:10.1213/XAA.0000000000000546
65. Dockray J, Aljumaily A, Lau S, Jarvi KA. A randomized, double-blind, controlled trial shows that onabotulinum toxin a nerve blocks do not provide improved pain control in men with chronic scrotal pain. *J Urol.* 2020;203(4):767–772. doi:10.1097/JU.0000000000000658
66. Calixte N, Brahmabhatt J, Parekattil S. Genital pain: algorithm for management. *Transl Androl Urol.* 2017;6(2):252–257. doi:10.21037/tau.2017.03.03

67. Lowe G. Extirpative surgery for chronic orchialgia: is there a role? *Transl Androl Urol.* 2017;6(Suppl 1):S2–S5. doi:10.21037/tau.2017.03.37
68. Karampinis I, Weiss J, Pilz L, Post S, Herrle F. Transabdominal laparoscopic retroperitoneal neurectomy for chronic pain after inguinal hernia repair and appendectomy – a matched-pair study. *BMC Surg.* 2017;17(1):85. doi:10.1186/s12893-017-0282-2
69. Auyeung AB, Almejally A, Alsaggar F, Doyle F. Incidence of post-vasectomy pain: systematic review and meta-analysis. *Int J Environ Res Public Health.* 2020;17(5):1788. doi:10.3390/ijerph17051788
70. Horovitz D, Tjong V, Domes T, Lo K, Grober ED, Jarvi K. Vasectomy reversal provides long-term pain relief for men with the post-vasectomy pain syndrome. *J Urol.* 2012;187(2):613–617. doi:10.1016/j.juro.2011.10.023
71. Smith-Harrison LI, Smith RP. Vasectomy reversal for post-vasectomy pain syndrome. *Transl Androl Urol.* 2017;6(Suppl 1):S10–S13. doi:10.21037/tau.2017.04.37
72. Tan WP, Levine LA. An overview of the management of post-vasectomy pain syndrome. *Asian J Androl.* 2016;18(3):332–337. doi:10.4103/1008-682X.175090

Research and Reports in Urology

Dovepress

Publish your work in this journal

Research and Reports in Urology is an international, peer-reviewed, open access journal publishing original research, reports, editorials, reviews and commentaries on all aspects of adult and pediatric urology in the clinic and laboratory including the following topics: Pathology, pathophysiology of urological disease; Investigation and

treatment of urological disease; Pharmacology of drugs used for the treatment of urological disease. The manuscript management system is completely online and includes a very quick and fair peer-review system, which is all easy to use. Visit <http://www.dovepress.com/testimonials.php> to read real quotes from published authors.

Submit your manuscript here: <https://www.dovepress.com/research-and-reports-in-urology-journal>