

References

- 1 Sanchez A, Sohier P, Benghanem S *et al*. Digitate papulosquamous eruption associated with severe acute respiratory syndrome coronavirus 2 infection. *JAMA Dermatol* 2020. <https://doi.org/10.1001/jamadermatol.2020.1704>
- 2 Recalcati S, Barbagallo T, Frasin LA *et al*. Acral cutaneous lesions in the time of COVID-19. *J Eur Acad Dermatology Venereol* 2020. <https://doi.org/10.1111/jdv.16533>
- 3 Piccolo V, Neri I, Filippeschi C *et al*. Chilblain-like lesions during COVID-19 epidemic: a preliminary study on 63 patients. *J Eur Acad Dermatology Venereol* 2020. <https://doi.org/10.1111/jdv.16526>
- 4 Fernandez-Nieto D, Jimenez-Cauhe J, Suarez-Valle A *et al*. Characterization of acute acro-ischemic lesions in non-hospitalized patients: a case series of 132 patients during the COVID-19 outbreak. *J Am Acad Dermatol* 2020. <https://doi.org/10.1016/j.jaad.2020.04.093>
- 5 Galván Casas C, Català A, Carretero Hernández G *et al*. Classification of the cutaneous manifestations of COVID-19: a rapid prospective nationwide consensus study in Spain with 375 cases. *Br J Dermatol* 2020. <https://doi.org/10.1111/bjd.19163>
- 6 Guan W, Ni Z, Hu Y *et al*. Clinical characteristics of coronavirus disease 2019 in China. *N Engl J Med* 2020; **382**: 1708–1720.
- 7 Recalcati S. Cutaneous manifestations in COVID-19: a first perspective. *J Eur Acad Dermatology Venereol* 2020; **34**. <https://doi.org/10.1111/jdv.16387>
- 8 de Masson A, Bouazziz J-D, Sulimovic L *et al*. Chilblains are a common cutaneous finding during the COVID-19 pandemic: a retrospective nationwide study from France. *J Am Acad Dermatol* 2020. <https://doi.org/10.1016/j.jaad.2020.04.161>
- 9 Tammaro A, Adebajo GAR, Parisella FR, Pezzuto A, Rello J. Cutaneous manifestations in COVID-19: the experiences of Barcelona and Rome. *J Eur Acad Dermatology Venereol* 2020. <https://doi.org/10.1111/jdv.16530>
- 10 Hedou M, Carsuzaa F, Chary E, Hainaut E, Cazenave-Roblot F, Masson Regnault M. Comment on “Cutaneous manifestations in COVID-19: a first perspective” by Recalcati S. *J Eur Acad Dermatology Venereol* 2020. <https://doi.org/10.1111/jdv.16519>

DOI: 10.1111/jdv.16775

Recent outbreak of chilblain-like lesions is not directly related to SARS-CoV-2 infection

Editor

Throughout March and April 2020, dermatologists have observed an outbreak of chilblains despite climatic conditions not conducive to their apparition. These lesions have occurred simultaneously to the COVID-19 epidemic, suggesting a relationship between their onset and SARS-CoV-2 infection.

Here we describe a series of 10 patients presenting chilblain-like lesions in whom we have searched for evidence of SARS-CoV-2 infection.

Between 17 and 29 April 2020, we have included patients successively referred to our Department for chilblain-like

lesions. Present and past medical history were recorded along with complete skin examination. Blood samples were collected for blood cell count, CRP, liver and renal parameters, antinuclear antibodies (anti-ENA and anti-DNA antibodies if positive immunofluorescence), complement components, ANCA, cryoglobulins, anti-prothrombinase, anticardiolipin antibodies, coagulation factors and D-dimers. Serological status concerning human immunodeficiency virus, hepatitis viruses and SARS-CoV-2 were established using automated assays performed on an Abbott ARCHITECT i2000 (Abbott Diagnostics, Rungis, France). Two biopsies were performed on lesional skin for diagnosis by light microscope examination and for SARS-CoV-2 search by RT-PCR test targeting the RNA-dependent RNA polymerase gene (<https://www.who.int/docs/default-source/coronaviruse/real-time-rt-pcr-assays-for-the-detection-of-sars-cov-2-institut-pasteur-paris.pdf>). We also searched for SARS-CoV-2 on a nasopharyngeal swab using RT-PCR.

Ten patients were included [median age: 33 years (11–57), sex-ratio 1 : 1]. All had erythematous, livedoid and purplish patches and papules on fingers or toes, evolving towards erosions, pigmentation and scaling (Fig. 1, Table 1). In eight patients, lesions began with a burning pain, which shifted towards pruritus in five patients. Lesions started 26.5 days prior to consultation (14–52) and healed within 35 days (27–45) without sequelae in seven patients. Five patients experienced short-duration viral symptoms without fever, anosmia nor ageusia. None of them had contact with a confirmed COVID infected person. Biopsies showed (Fig. 1) inconstant epidermal lesions (apoptotic keratinocytes, epidermal necrosis, basal layer vacuolation, mild spongiosis and parakeratosis), an upper dermis oedema, and a perivascular and periadnexal lymphohistiocytic infiltrate. Vascular lesions were prominent with angiocentrism, angiotropism and endothelium swelling, capillar ectasia and fibrinoid thrombi. All blood sample examinations were normal except for three patients who had positive antinuclear antibodies with anti-nucleolar or anti-centromere patterns. SARS-CoV-2 research on nasopharyngeal swabs and on skin biopsies was negative, and no SARS-CoV-2-specific IgG was detected in any case.

We present a series of 10 consecutive patients with typical clinical and pathological chilblains occurring during the peak of COVID-19 infection. In our area, the weather was warm at that time and all patients lived under lockdown in well-heated houses. In all patients, we failed to demonstrate neither a current nor recent COVID-19 infection nor SARS-CoV-2 presence in skin. The absence of respiratory symptoms and the known rapid clearance of SARS-CoV-2 in moderate infections could explain the negativity of RT-PCR analysis. The absence of specific IgG suggests that a reaction due to COVID-19 is unlikely even though these patients could have only specific IgM. However, IgM peak between days 5 and 12 after infection¹ whereas IgG reach peak concentrations after day 20 and most patients were

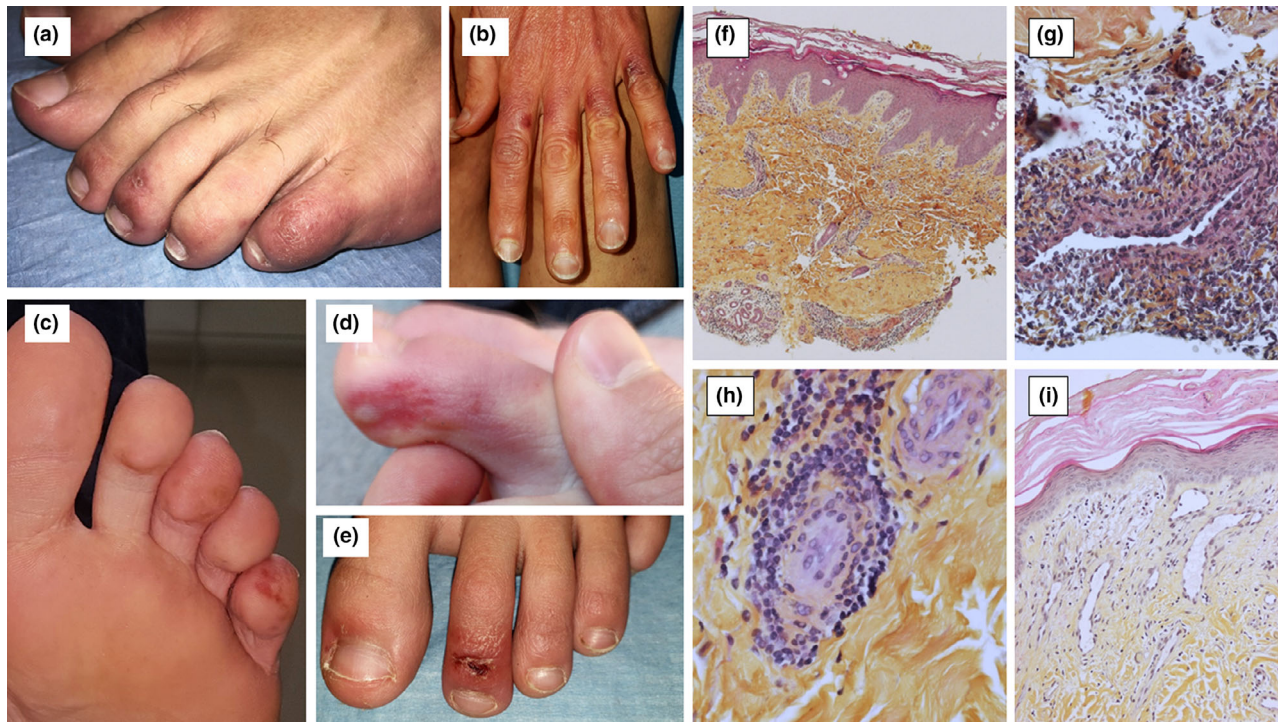


Figure 1 Skin lesions (a: Patient 7; b: Patient 9; c: Patient 10; d: Patient 4; e: Patient 3); Lesional skin biopsies, Haematoxylin, Eosin and Saffron (HES) (f: lymphohistiocytic infiltrate around vessels and eccrine glands, $\times 4$ magnification; g: Angiocentric lymphohistiocytic infiltrate in superficial dermis, $\times 40$ magnification; h: Angiotropism, $\times 40$ magnification; i: Papillary dermis oedema, capillar ectasia and endothelial swelling, $\times 20$ magnification).

tested after 20 days of evolution of skin lesions. Furthermore, the sensitivity² of our test is 100% after day 17. Three of these patients had positive antinuclear antibodies suggesting an undiagnosed autoimmune disease (scleroderma or lupus) but no one presented other clinical symptoms.

Chilblain-like lesions have been reported for several weeks^{3–5} in patients COVID infected or not, suggesting that they could be induced by SARS-CoV-2. Our data do not confirm a direct role of SARS-CoV-2 or an immunological hit-and-run mechanism. Some of these patients might have an authentic systemic disease, fortuitously detected. To conclude, our results do not support a direct effect of SARS-CoV-2 in the observed outbreak of unusual chilblain lesions during the COVID-19 pandemic.

Acknowledgements

The patients in this manuscript have given written informed consent to the publication of their case details. We thank Dr Elodie DEVERS (Department of Dermatology), Dr Carole CHEVENET (Department of Pathology), Dr Anne-Sophie MARCHESSEAU-MERLIN, Dr François MICHEL and Dr Charlotte PIECH, (dermatologists), Pr Marc BERGER and Dr Juliette BERGER (CRB-Auvergne), Pr Marc RUIVARD (Department of Internal Medicine) and Matthieu GEMBARA (manuscript proofreading).

Conflicts of interest


None reported.

Funding source

None.

Author contributions

Dr Rouanet had full access to all of the data of the case series and takes responsibility for the integrity of the data and the accuracy of the data analysis. Acquisition, analysis or interpretation of data: All authors. Drafting of the manuscript: Rouanet and D'Incan. Critical revision of the manuscript for important intellectual content: All authors. Supervision: Rouanet and D'Incan.

J. Rouanet,^{1,*}  E. Lang,¹ F. Beltzung,² B. Evrard,³ C. Henquell,⁴ I. Joulie,¹ M. D'Incan¹

¹Department of Dermatology, CHU, Université Clermont Auvergne, Clermont-Ferrand, France, ²Department of Pathology, CHU, Université Clermont Auvergne, Clermont-Ferrand, France, ³Department of Immunology, CHU, Université Clermont Auvergne, Clermont-Ferrand, France, ⁴Department of Virology, CHU, 3IHP, Université Clermont Auvergne, Clermont-Ferrand, France

*Correspondence: J. Rouanet. E-mail: jrouanet@chu-clermontferrand.fr

Table 1 Patient characteristics

Patient	Medical history		Associated viral symptoms	Time between 1st symptoms and consultation (days)	Skin symptoms duration to healing (days)	Clinical examination		Biology		SARS-CoV-2 PCR	
	Age/Sex	Relevant past medical history				Clinical description	Topography	Antinuclear antibodies (titre)	SARS-CoV-2 serological status	Nasopharyngeal swab	Skin biopsy
1	60/F	Raynaud's disease	None	28	38	Purplish macule	Right index fingertip	Negative	Negative	/	Negative
2	32/H	/	Asthenia	25	35	Erythematous and purplish patches and papules with superficial erosion	Dorsal side of the toes (right I, III, IV, V and left I, II, IV, V)	Negative	Negative	Negative	Negative
3	11/H	/	Asthenia, headaches	28	27	Erythematous purplish patches and papules with superficial erosion and post-inflammatory scaling	Dorsal surface of the toes (both side I and II)	Negative	Negative	/	Negative
4	18/H	/	None	16	27	Erythematous, livedoid and purplish patches and papules with superficial erosion	Dorsal and lateral sides of the toes (left I, II, III, V) and fingers	Positive (1/640) anti-centromere antibodies	Negative	Negative	Negative
5	34/F	Raynaud's disease, chilblains	None	52	>60	Purplish and livedoid macules with post-inflammatory scaling	Dorsal side and fingertips of the all toes	Positive (1/2560) nucleolar fluorescence	/	Negative	Negative
6	57/F	/	None	14	>60	Purplish macules	All fingertips	Positive (1/160) dense cytoplasmic fluorescence	Negative	/	Negative
7	24/H	/	None	22	29	Erythematous and purplish patches and papules with superficial erosion and post-inflammatory scaling	Dorsal side of the toes (right III, IV, V and left II, IV, V)	Negative	Negative	Negative	/
8	50/F	/	Asthenia	37	45	Purplish and livedoid patches	Toe fingertips (left I, II, III)	Negative	Negative	Negative	Negative
9	40/F	Raynaud's disease, chilblains	Headaches	24	>60	Erythematous patches with post-inflammatory scaling	Dorsal side of the fingers with respect of the interphalangeal joints (right II, III, IV, V and left II, III, IV, V)	Negative	Negative	Negative	Negative
10	14/H	/	Cough, asthenia, headaches, myalgia, arthralgia	35	43	Erythematous, livedoid and purplish patches and papules with post-inflammatory pigmentation and scaling	Dorsal surface and fingertips of all toes	Negative	Negative	Negative	Negative

References

- 1 Kontou PI, Braliou GG, Dimou NL, Nikolopoulos G, Bagos PG. Antibody tests in detecting SARS-CoV-2 infection: a meta-analysis. *Diagnostics* 2020; **10**: 319.
- 2 Bryan A, Pepper G, Wener MH *et al.* Performance characteristics of the abbott architect SARS-CoV-2 IgG assay and seroprevalence in Boise, Idaho. *J Clin Microbiol* 2020. In press. <https://doi.org/10.1128/JCM.00941-20>.
- 3 de Masson A, Bouaziz JD, Sulimovic L *et al.* Chilblains are a common cutaneous finding during the COVID-19 pandemic: a retrospective nationwide study from France. *J Am Acad Dermatol* 2020. In press. <https://doi.org/10.1016/j.jaad.2020.04.161>.
- 4 Galvan Casas C, Catala A, Carretero Hernandez G *et al.* Classification of the cutaneous manifestations of COVID-19: a rapid prospective nationwide consensus study in Spain with 375 cases. *Br J Dermatol* 2020. In press. <https://doi.org/10.1111/bjd.19163>.
- 5 Piccolo V, Neri I, Filippeschi C *et al.* Chilblain-like lesions during COVID-19 epidemic: a preliminary study on 63 patients. *J Eur Acad Dermatol Venereol* 2020. In press. <https://doi.org/10.1111/jdv.16526>.

DOI: 10.1111/jdv.16776

Acute acral cutaneous manifestations during the COVID-19 pandemic: a single-centre experience

Editor

Coronavirus disease 2019 (COVID-19), caused by severe acute respiratory syndrome-related coronavirus 2 (SARS-CoV-2), was first reported in China on December 2019. Almost 5 months into the pandemic, little is still known about cutaneous manifestations in COVID-19. In fact, the prevalence of cutaneous signs varies greatly in the literature, ranging from 0.2% to 20.4%.^{1,2}

Given their potential association with COVID-19, acral lesions have received special attention worldwide, both in the medical literature and the media. Our aim is to share our

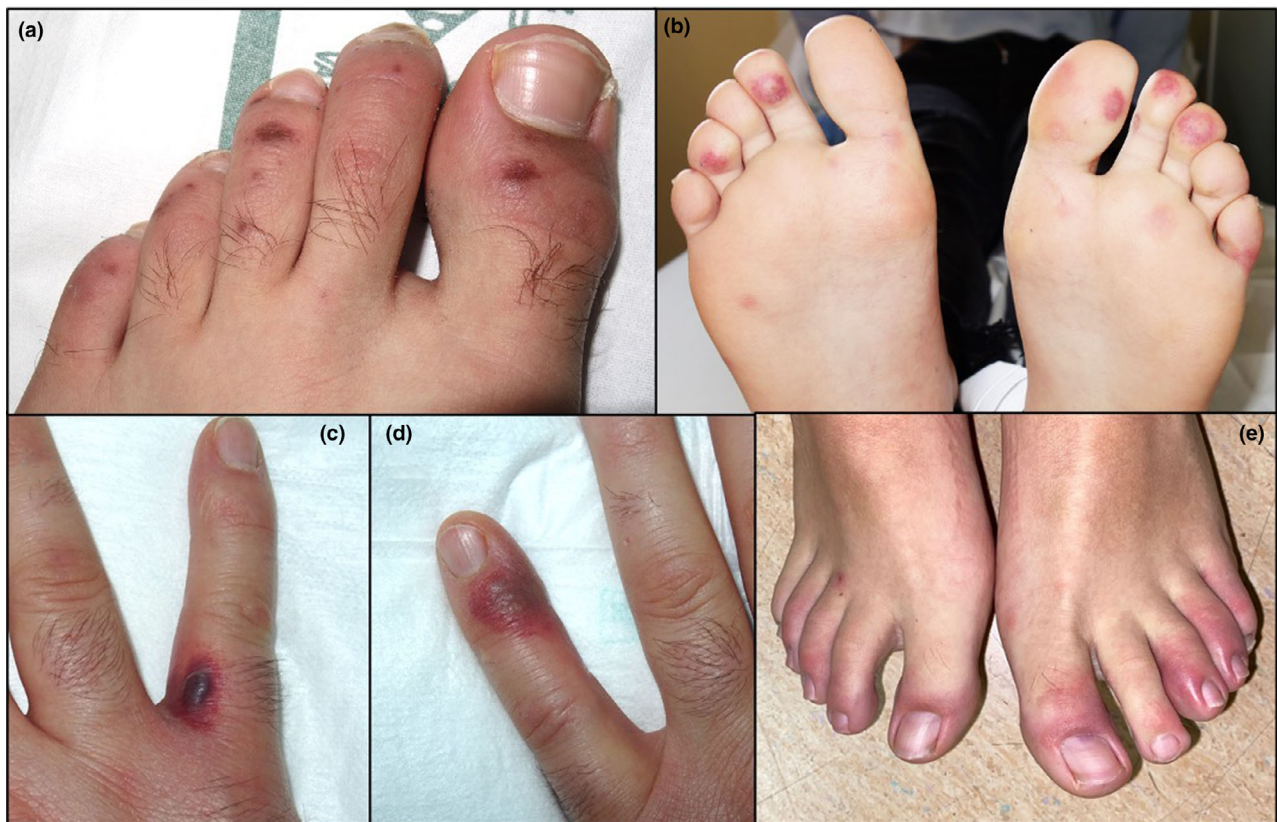

Figure 1 Acral lesions in patients with negative nasopharyngeal PCR and serology for COVID-19: (a) Petechial and purpuric macules on the dorsal aspect of the toes in a 19-year-old male. (b) Erythematous lesions with purpuric hue and digital swelling on the distal aspect of the toes in a 13-year-old female. (c, d) Purpuric macules with haemorrhagic vesicle on the fingers of a 41-year-old male. (e) Erythema and oedema on multiple toes in a 19-year-old male.