



Since January 2020 Elsevier has created a COVID-19 resource centre with free information in English and Mandarin on the novel coronavirus COVID-19. The COVID-19 resource centre is hosted on Elsevier Connect, the company's public news and information website.

Elsevier hereby grants permission to make all its COVID-19-related research that is available on the COVID-19 resource centre - including this research content - immediately available in PubMed Central and other publicly funded repositories, such as the WHO COVID database with rights for unrestricted research re-use and analyses in any form or by any means with acknowledgement of the original source. These permissions are granted for free by Elsevier for as long as the COVID-19 resource centre remains active.

Lack of association between chilblains outbreak and severe acute respiratory syndrome coronavirus 2: Histologic and serologic findings from a new immunoassay



To the Editor: COVID-19, which is due to severe acute respiratory syndrome coronavirus 2 (SARS-CoV-2), was declared a worldwide pandemic on March 11, 2020.^{1,2}

Recently, numerous cases of acute chilblains-like lesions have been reported on social networks from Belgium, France, and Italy. Despite weak evidence, particularly the absence of serologic studies, the hypothesis that these lesions were potentially related to the COVID-19 infection, as a paucisymptomatic form, rapidly grew.³⁻⁵ An alert letter was even sent to the French Ministry of Health and to French dermatologists by the National Union of Dermatologists.

Because 33 patients (14 women, 19 men) with chilblains were referred to our dermatology department within 1 week, we studied the relationship between these lesions and the COVID-19 infection. All patients (mean \pm standard deviation age, 23.4 ± 8.7 y) presented erythematous and purpuric papules localized on the toes alone or toes and fingers (12 patients, 36.4%) (Fig 1). Edema was present in 12 (36.4%) and pruritus or burning sensation in 18 (54.5%) patients. The median delay

between the onset of dermatologic features and the first consultation was 8 days (interquartile range, 6.5-18 d). Chilblains were the only clinical manifestation in 23 cases (69.7%); 10 (30.3%) patients presented other symptoms, which occurred before ($n = 6$), concomitantly with ($n = 1$), or after skin symptoms ($n = 3$): asthenia ($n = 4$), cough ($n = 3$), diarrhea ($n = 3$), fever ($n = 2$), myalgia ($n = 2$), headache ($n = 1$), and odynophagia ($n = 1$). No patient reported contact with COVID-19-infected patients. Three patients had recently been tested for COVID-19 infection and had negative results on sinus reverse-transcription polymerase chain reaction (RT-PCR).

Blood cell count results were normal in 26 patients. A mild lymphopenia (mean, 1.15 ± 0.21 giga per liter) was observed in 7 patients. C-reactive protein and erythrocyte sedimentation rate results were negative for all patients. Two patients had positive results for antinuclear antibodies, and 3 patients had antibodies for a type III cryoglobulinemia.

Histology performed in 5 patients showed lymphocytic infiltrate in the superficial dermis around the vessels and eccrine glands in all cases, reminiscent of idiopathic chilblains. Direct immunofluorescence showed fibrinogen and C3 deposits on endothelial cells in 2 cases. Results of indirect immunofluorescence assay using the serum from a

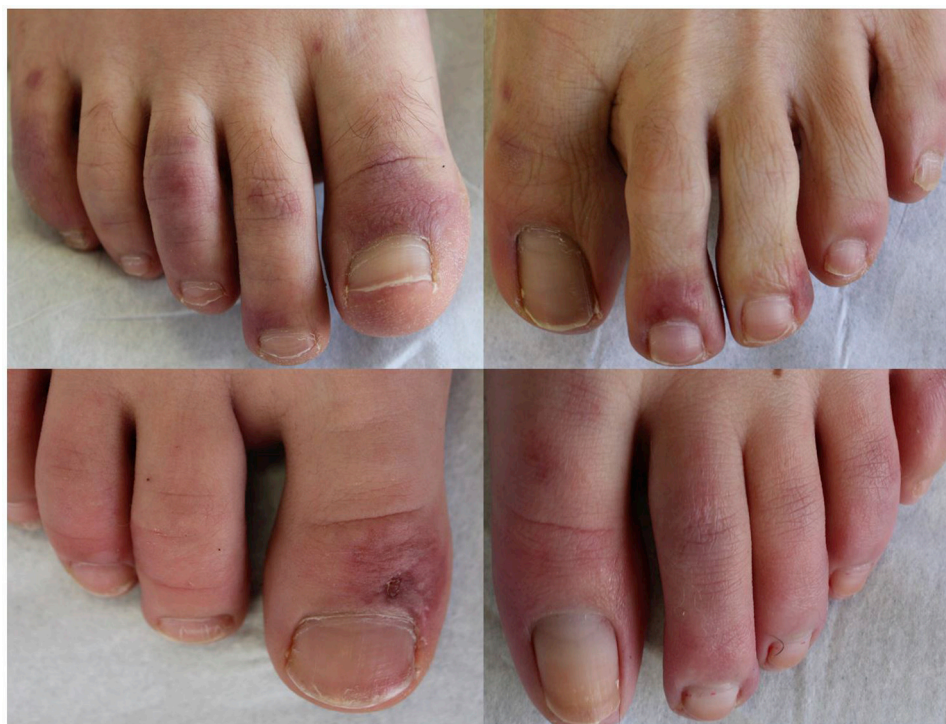

Fig 1. Examples of 4 patients referred for chilblains.

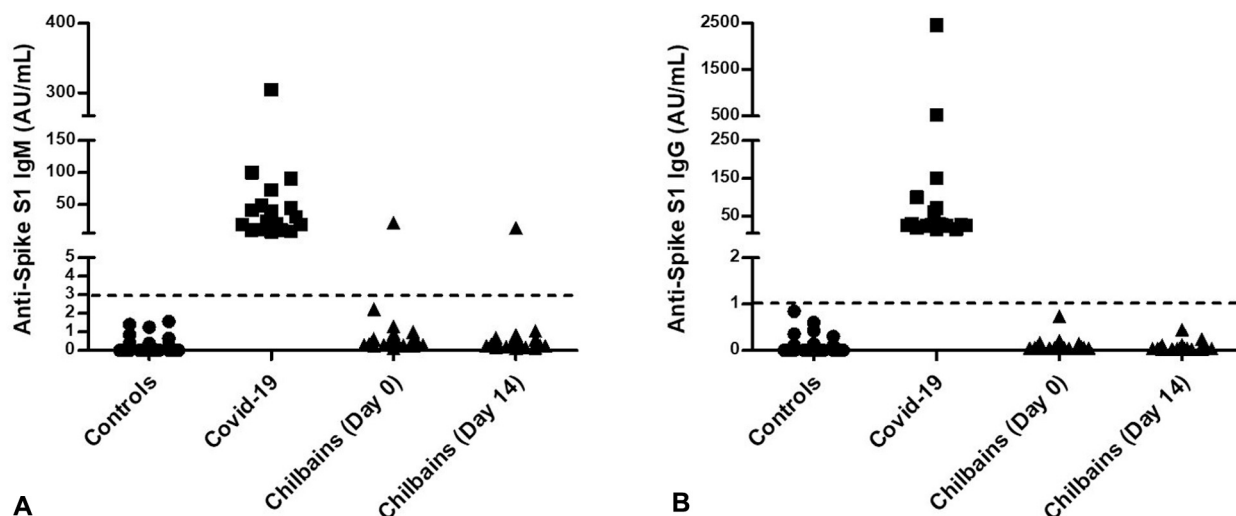


Fig 2. Severe acute respiratory syndrome coronavirus 2 serology. Sera from negative control patients (circles, $n = 130$; health donors of blood collected by the French Établissement Français du Sang before the pandemic), patients with COVID-19 (squares, $n = 18$; patients with reverse-transcription polymerase chain reaction results from Rouen University Hospital), and patients with chilblains (triangles, $n = 33$ at day 0 and $n = 31$ at day 14) were assayed for the presence of anti-Spike S1 antibodies. **A**, Immunoglobulin M. **B**, Immunoglobulin G. The dotted line marks the threshold of positivity of the assay. AU, Arbitrary units; Ig, immunoglobulin.

patient with anti-SARS-CoV-2 immunoglobulin (Ig) G antibodies and RT-PCR on lesional skin were negative.

We developed an ALBIA-Spike S1 for detecting anti-SARS-CoV-2 antibodies that allowed a 96% sensitivity and 98% specificity (Drouot et al, personal communication, May 2020). Test results for anti-SARS-CoV-2 IgG antibodies were negative in all 33 sera, and in 1 of 33, the result was positive for IgM at the first consultation and at the second consultation 14 days later. No seroconversion was observed (Fig 2). Our findings were then confirmed by using the Abbott (Abbott Park, IL) SARS-CoV-2 IgG immunoassay performed on the day 14 sera, without detectable seropositivity.

The present data provide no argument for any link between these chilblains and infection with SARS-CoV-2. Clinical and histologic features were those of idiopathic chilblains. The results of RT-PCR and indirect immunofluorescence on lesional skin, when performed, were negative. None of the 33 sera tested contained anti-SARS-CoV-2 IgG antibodies, and only 1 had IgM twice (3%), consistent with the current estimation of a rate of SARS-CoV-2 infection of 5% to 10% in the general population in France.⁶

We think that this hypothesis of COVID-19-related chilblains could be explained by a cumulation of (1) a temporality bias in this early spring period, when the average temperature differences were the widest; (2) a confounding bias

related to the young age, because paucisymptomatic forms of the infection are observed in young people; and (3) a recruitment bias related to the shortening of dermatology consultation delays due to the quarantine period.

Vivien Hébert, MD,^a Anne-Bénédicte Duval-Modeste, MD,^a Pascal Joly, MD, PhD,^a Véronique Lemée, MD,^b Lucie Cellier, MD,^c Fabienne Jouen, MD,^d Benoit Veber, MD, PhD,^e Laurent Drouot, PhD,^d and Olivier Boyer, MD, PhD^d

From the Normandie University, UNIROUEN, Inserm, U1234, FOCIS Center of Excellence PAn^THER, Rouen University Hospital, Department of Dermatology^d; Department of Virology, Rouen University Hospital^b; Department of Pathology, Rouen University Hospital^c; Normandie University, UNIROUEN, Inserm, U1234, FOCIS Center of Excellence PAn^THER, Department of Immunology and Biotherapy, Rouen University Hospital^d; and Department of Resuscitation, Rouen University Hospital, Rouen, France.^e

Funding sources: None.

Conflicts of interest: None disclosed.

IRB approval status: Institute for Research and Innovation in Biomedicine.

Reprints not available from the authors.

Correspondence to: Vivien Hébert, MD, Clinique dermatologique, CHU de Rouen, 1 rue de Germont, 76031 Rouen, France

E-mail: Vivien.Hebert@chu-rouen.fr

REFERENCES

1. Zhu N, Zhang D, Wang W, et al. A novel coronavirus from patients with pneumonia in China, 2019. *N Engl J Med*. 2020; 382(8):727-733.
2. Huang C, Wang Y, Li X, et al. Clinical features of patients infected with 2019 novel coronavirus in Wuhan, China. *Lancet*. 2020;395(10223):497-506.
3. Bouaziz J, Duong T, Jachiet M, et al. Vascular skin symptoms in COVID-19: a French observational study. *J Eur Acad Dermatol Venereol*. 2020. <https://doi.org/10.1111/jdv.16544>.
4. de Masson A, Bouaziz J-D, Sulimovic L, et al. Chilblains are a common cutaneous finding during the COVID-19 pandemic: a retrospective nationwide study from France. *J Am Acad Dermatol*. 2020;83:667-670.
5. Kolivras A, Dehavay F, Delplace D, et al. Coronavirus (COVID-19) infection-induced chilblains: a case report with histopathological findings. *JAAD Case Rep*. 2020;6:489-492.
6. Institut Pasteur. Une modélisation indique qu'entre 3% et 7% des Français ont été infectés. <https://www.pasteur.fr/fr/espace-presse/documents-presse/covid-19-modelisation-indique-que-pres-6-francais-ont-ete-infectes>; 2020. Accessed April 23, 2020.

<https://doi.org/10.1016/j.jaad.2020.07.048>

No reactivation of tuberculosis in patients with latent tuberculosis infection receiving ixekizumab: A report from 16 clinical studies of patients with psoriasis or psoriatic arthritis



To the Editor: Reactivation of latent tuberculosis infection (LTBI) and/or active tuberculosis (TB) has been associated with certain immunomodulatory therapies for psoriasis (Pso) or psoriatic arthritis (PsA).¹ Ixekizumab (IXE), a high-affinity anti-interleukin (IL)-17A monoclonal antibody, has shown safety and efficacy in patients with these conditions,^{2,3} but more data on the risk of TB infection are needed.

This post hoc analysis of integrated safety data (derived via naive pooling) from 13 clinical trials in Pso^{4,5} and 3 studies of PsA³ evaluated treatment-emergent (TE) LTBI in IXE-treated patients (Fig 1). The purified protein derivative skin test or QuantiFERON-TB Gold assay (Cellestis Inc, Valencia, CA, USA) was used for LTBI assessment. Patients testing negative for LTBI at screening or

less than 3 months before baseline were included in this analysis. Patients with a positive LTBI test result at screening could enroll in the studies after initiating LTBI-specific therapy if they met all other study inclusion criteria, but they were otherwise excluded from this analysis. Annual LTBI testing and discontinuation of patients with TE-LTBI after randomization were required per protocol. Amended protocols allowed patients with TE-LTBI to continue IXE treatment if they received LTBI therapy.

In this analysis, 7016 IXE-treated patients, 5898 with Pso (16,313 patient-years of IXE exposure; 1010 mean days of exposure) and 1118 with PsA (1822 patient-years of IXE exposure; 596 mean days of exposure) were evaluated for TE-LTBI during the study program (Fig 2). A total of 101 (1.7%) patients with Pso developed TE-LTBI; of these, 65 discontinued according to study protocol. Of the 36 patients who remained in the studies, LTBI-specific therapy was initiated in 30 patients, while 6 patients did not receive LTBI-specific treatment (Fig 2). In total, 5 patients with TE-LTBI subsequently discontinued IXE in the Pso studies, 3 patients in the LTBI-treatment group, and 2 in the group without LTBI treatment. Of the 32 (2.9%) patients who developed TE-LTBI in the PsA studies, 20 were discontinued per protocol. Seven of the 12 patients continuing IXE treatment received LTBI therapy (1 patient discontinued IXE); 5 patients were not treated for LTBI (of these, 3 also discontinued IXE). No reactivation of TB was reported in the 6 patients with TE-LTBI in the absence of LTBI-specific therapy during IXE treatment.

This integrated safety analysis, reporting data from one of the largest IXE databases, identified a small number of patients with TE-LTBI, most of whom received LTBI-specific therapy. No cases of reactivation of TB were identified.

Limitations of this analysis are the small number of events, a missing control group, and the limited observation period, preventing long-term risk assessment for active TB. Data interpretation needs to take into consideration that these studies were designed to assess the overall safety and the efficacy of IXE and not to investigate the risk of TB reactivation.

Nevertheless, these data contribute to the growing evidence for the use of therapeutic antibodies targeting IL-17A, such as IXE, in patients with LTBI. Real-world data are needed to address the clinical question of the potential long-term risk for reactivation of TB under anti-IL-17 therapy.