



Since January 2020 Elsevier has created a COVID-19 resource centre with free information in English and Mandarin on the novel coronavirus COVID-19. The COVID-19 resource centre is hosted on Elsevier Connect, the company's public news and information website.

Elsevier hereby grants permission to make all its COVID-19-related research that is available on the COVID-19 resource centre - including this research content - immediately available in PubMed Central and other publicly funded repositories, such as the WHO COVID database with rights for unrestricted research re-use and analyses in any form or by any means with acknowledgement of the original source. These permissions are granted for free by Elsevier for as long as the COVID-19 resource centre remains active.

Image in cardiology

Tako-tsubo syndrome associated with COVID-19

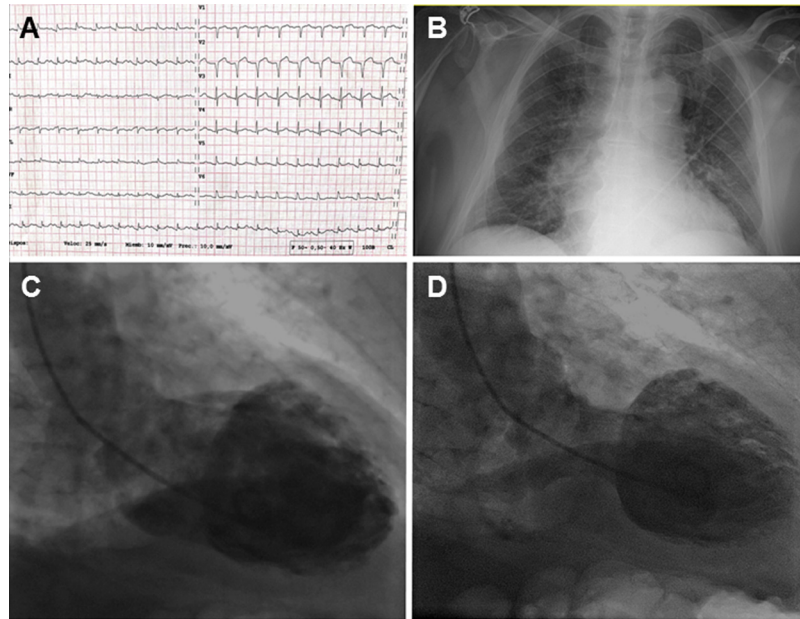
Síndrome de *tako-tsubo* asociado con COVID-19Loreto Oyarzabal,^{a,*} Joan Antoni Gómez-Hospital,^{a,b} and Josep Comin-Colet^a^a Servicio de Cardiología, Hospital Universitario de Bellvitge, Instituto de Investigación Biomédica de Bellvitge (IDIBELL), L'Hospitalet de Llobregat, Barcelona, Spain^b Centro de Investigación Biomédica en Red de Enfermedades Cardiovasculares (CIBERCV), Spain

Figure 1.

An 82-year-old man, with a history of hypertension, diabetes mellitus, dyslipidemia, peripheral artery disease, and chronic renal failure but no prior history of heart disease attended the emergency room of a regional hospital with anginal chest pain consistent with heart failure. The electrocardiogram showed a 1 mm ST segment elevation in leads V₂-V₃ and DI-AVL (figure 1A), and so the infarction protocol was activated. The patient reached the electrophysiology laboratory in Killip class II and a rapid polymerase chain reaction (PCR) test for acute respiratory severe acute respiratory syndrome coronavirus 2 (SARS-CoV-2) was performed as part of the protocol. Coronary angiography showed coronary arteries free of lesions and cardiac ventriculography was performed. This showed a very reduced left ventricular ejection fraction with extensive apical akinesia (figure 1C,D). The PCR result was positive, indicating tako-tsubo syndrome related to viral infection.

The findings of ventriculography were confirmed by echocardiography, and chest x-ray showed signs of mild heart failure, with no evidence of pneumonia (figure 1B). The patient's progression was favorable; heart failure improved and he did not develop lung involvement secondary to the COVID-19 disease. Ten days after admission, he was discharged with only ongoing neurohormonal treatment.

The mechanism by which SARS-Cov-2 infection may cause tako-tsubo syndrome is not clear. However, viral infection has been associated with a state of systemic inflammation and this may be the trigger for the syndrome.

CONFLICTS OF INTEREST

J.A. Gómez-Hospital declares a consultant role for Abbott, Medtronic, Boston, Terumo, IHT. The remaining authors do not declare any conflicts of interest.

* Corresponding author:

E-mail address: lore.oyarz@gmail.com (L. Oyarzabal).

Available online 17 July 2020

<https://doi.org/10.1016/j.rec.2020.06.022>

1885-5857/© 2020 Sociedad Española de Cardiología. Published by Elsevier España, S.L.U. All rights reserved.