



Entrapment neuropathies: a contemporary approach to pathophysiology, clinical assessment, and management

Annina B. Schmid^{a,*}, Joel Fundaun^{a,b}, Brigitte Tampin^{c,d,e}

Abstract

Entrapment neuropathies such as carpal tunnel syndrome, radiculopathies, or radicular pain are the most common peripheral neuropathies and also the most common cause for neuropathic pain. Despite their high prevalence, they often remain challenging to diagnose and manage in a clinical setting. Summarising the evidence from both preclinical and clinical studies, this review provides an update on the aetiology and pathophysiology of entrapment neuropathies. Potential mechanisms are put in perspective with clinical findings. The contemporary assessment is discussed and diagnostic pitfalls highlighted. The evidence for the noninvasive and surgical management of common entrapment neuropathies is summarised and future areas of research are identified.

Keywords: Entrapment neuropathies, Compression neuropathies, Carpal tunnel syndrome, Sciatica, Radiculopathy, Radicular pain, Pathomechanisms, Assessment, Diagnosis, Management, Treatment

1. Introduction

Entrapment neuropathies are caused by compression and/or irritation of peripheral nerves as they travel through narrow anatomical spaces. The most common entrapment neuropathy is carpal tunnel syndrome (CTS) with a lifetime risk of 10%, which increases to a staggering 84% in patients with diabetes.¹³⁵ The second most common entrapment neuropathy is cubital tunnel syndrome.¹⁰⁰ Another common condition is “sciatica,” with reported prevalence values ranging from 1.6% to 43%.⁷⁶ The striking variation in prevalence has been attributed to the varying definitions of “sciatica.”⁷⁶ Indeed, “sciatica” is an arcane term which, depending on its interpretation, may include somatic referred pain, radicular pain (pain evoked by ectopic discharges from a dorsal root or its ganglion),¹⁹ and radiculopathy (conduction block along a spinal nerve or its roots manifesting clinically with dermatomal sensory loss, myotomal weakness, or

Key Points

1. The wide variety of pathomechanisms at play in entrapment neuropathy may account for patient heterogeneity.
2. Contemporary clinical assessment involves a detailed history, clinical examination, and additional tests if required.
3. Noninvasive management is the first-line treatment for patients with entrapment neuropathies.
4. Future research is required to determine whether patient stratification can improve outcomes in patients with entrapment neuropathies.

reflex changes).^{19,129} Here, we use “sciatica” as an umbrella term for all 3 conditions, but use the more accurate descriptions (eg, radiculopathy, radicular pain) when studies specifically defined their patient population.

The aetiology of entrapment neuropathies remains largely unknown. They share several risk factors across conditions, such as increased body mass index,^{115,134} occupational or physical factors,^{78,115} and predisposing systemic diseases such as diabetes or hypothyroidism.^{115,118} Recently, genetic predisposition is emerging as one of the strongest risk factors for entrapment neuropathies.^{2,82,86,165} In addition to rare variants,¹⁵⁸ genome-wide association studies have identified several genetic susceptibility loci for entrapment neuropathies.^{2,82,86,165} Intriguingly, many of the genes are related to connective tissue and extracellular matrix architecture. It currently remains unclear whether these genes increase vulnerability by altering the nerve itself (as a substantial proportion consists of connective tissue) or the environment through which the nerve travels (eg, the tunnels).¹⁶⁵

Sponsorships or competing interests that may be relevant to content are disclosed at the end of this article.

^a Nuffield Department of Clinical Neurosciences, Oxford University, Oxford, United Kingdom, ^b High Country Physical Therapy, Laramie, WY, USA, ^c Department of Physiotherapy, Sir Charles Gairdner Hospital, Perth, Western Australia, Australia, ^d School of Physiotherapy and Exercise Science, Curtin University, Western Australia, Australia, ^e Faculty of Business Management and Social Sciences, Hochschule Osnabrück, University of Applied Sciences, Osnabrück, Germany

*Corresponding author. Address: Nuffield Department of Clinical Neurosciences, John Radcliffe Hospital, West Wing Level 6, OX3 9DU, Oxford, United Kingdom. Tel.: +44 (0)1865 223254. E-mail address: annina.schmid@neuro-research.ch (A.B. Schmid).

Copyright © 2020 The Author(s). Published by Wolters Kluwer Health, Inc. on behalf of The International Association for the Study of Pain. This is an open access article distributed under the Creative Commons Attribution License 4.0 (CCBY), which permits unrestricted use, distribution, and reproduction in any medium, provided the original work is properly cited.

PR9 5 (2020) e829

<http://dx.doi.org/10.1097/PR9.0000000000000829>

Over the past decade, significant advances have been made in our understanding of the pathophysiology of entrapment neuropathies and their assessment and management.

This article summarises the current knowledge and highlights the challenges faced when diagnosing and managing patients with entrapment neuropathies.

2. Pathophysiology

Our understanding of neuropathic pain is largely based on preclinical models involving acute and severe nerve injuries. However, human entrapment neuropathies are quite distinct from these preclinical models because their onset is mostly slow, and the neural injury is often of mild but chronic nature. We¹³⁰ and others^{36,62} have therefore refined animal models that closely mimic human entrapment neuropathies. Below, we summarise the main pathomechanisms that are associated with nerve compression in preclinical and clinical studies (**Fig. 1**) and provide potential links to the clinical presentation.

2.1. Ischaemia, oedema, and intraneural fibrosis

Intraneural ischaemia is typical of mild entrapment neuropathies. Animal models demonstrate that extraneural pressures as low as 20 to 30 mm Hg disrupt intraneural venous circulation.¹²⁵ These pressures are often reached in patients with entrapment neuropathies.^{31,60,132,139} The ensuing reversal of the pressure gradient necessary to assure adequate blood supply could explain the sometimes intermittent paraesthesia, which occur at night, in static positions or with end of range positions (eg, Phalen test for CTS) and may reduce or disappear with movement.

Prolonged ischaemia is likely to induce a compromise of the blood nerve interface^{90,170} with subsequent oedema formation. Clinically, the presence of oedema is apparent by an enlargement of the compressed nerves^{103,169} and increases in signal intensity on specialised magnetic resonance sequences.^{32,83,136} Persistent oedema may eventually lead to intraneural and extraneural

fibrotic changes,⁹² which is a feature of both radiculopathies⁶⁸ and entrapment neuropathies of distal nerve trunks.^{1,28} Extraneural fibrotic changes are thought to explain the reduced gliding of human compressed nerves that is apparent during limb movements.⁴⁶

2.2. Demyelination and axon degeneration

Prolonged ischaemia and mechanical compromise may induce downstream effects such as demyelination and eventually axon degeneration. Focal demyelination is a hallmark of entrapment neuropathies,^{58,63,91,92,107,109,130} which are often characterised by nerve conduction slowing or block.⁹⁵ Ischaemia in the absence of demyelination may, however, also contribute to nerve conduction changes.^{25,73}

Together with demyelination, the architecture of nodes of Ranvier changes after nerve compression,¹³¹ including both downregulation and upregulation of existing ion channels as well as expression of novel channels.^{24,42,49,71,85} Such changes have been implicated with spontaneous ectopic generation of action potentials,^{6,26} and may contribute to spontaneous electric shock-like pain or symptoms provoked upon Tinel testing.

If nerve compression/irritation perseveres, axons may eventually degenerate. It is commonly believed that entrapment neuropathies predominantly affect the large myelinated fibres (eg, demyelination and axon damage)^{36,92} and that small axons are relatively resistant to compression.³⁶ Indeed, large myelinated A β -fibre-mediated numbness to light touch is common as is motor neuron dysfunction apparent by myotomal muscle weakness, atrophy, and reflex changes. Guidelines on the diagnosis of entrapment neuropathies such as CTS or cervical radiculopathy thus focus heavily on large fibre tests.^{5,20} Recent evidence, however, suggests that small nerve fibre function and structure are affected in entrapment neuropathies^{8,29,50,74,80,126,142,146,155,167} and may even precede large fibre changes.^{9,130,131,141} These findings suggest that (early) diagnosis of entrapment neuropathies should include tests for small fibre function.

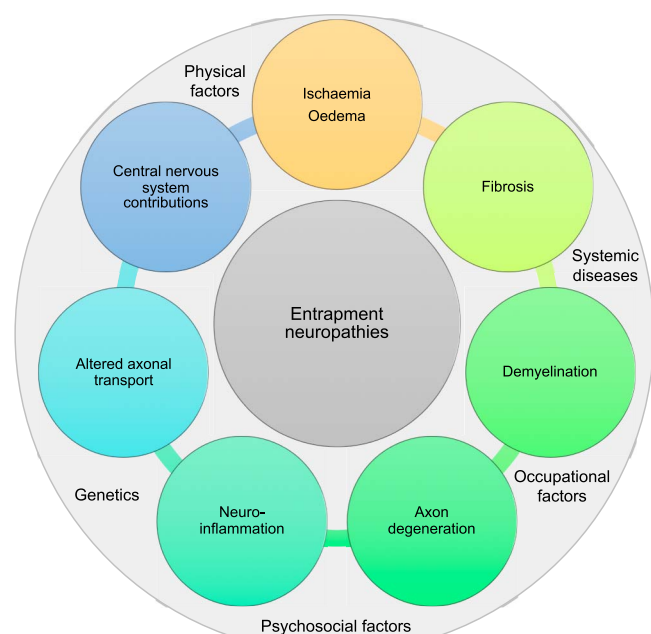


Figure 1. Potential pathomechanisms and risk factors contributing to entrapment neuropathies.

2.3. Neuroinflammation

There is a wealth of preclinical data confirming an important role of neuroinflammation in the generation and maintenance of neuropathic pain [for review, see Refs. 99, 151, 163, 166]. Neuroinflammation is characterised by activation of immune cells (eg, macrophages and T-lymphocytes) at the site of damaged axons. Immune cells release inflammatory mediators (eg, cytokines, chemokines, and lipid mediators), which induce a breakdown of the blood–nerve barrier resulting in further immune cell influx and swelling. Importantly, neuroinflammation sensitises injured and uninjured axons and nociceptors in target tissue, contributing to neuropathic pain initiation and maintenance. Whereas most evidence for a link between neuroinflammation and neuropathic pain stems from acute and severe nerve injury models, there is a growing body of evidence suggesting that neuroinflammation is also a feature of mild chronic nerve compression.^{61,112,130,133} Intriguingly though, the neuroinflammation does not remain restricted to the lesion site, but can be found in associated dorsal root ganglia after peripheral nerve compression¹³⁰ or nerve root compromise.¹¹² Animal models of radiculopathy also demonstrate an activation of glial cells in the dorsal horn of the spinal cord.^{122,123,140} A similar glial cell reaction has also been reported for severe distal nerve injuries involving substantial axonal damage,⁶⁷ whereas compression injuries with

only minimal axonal damage seem insufficient to induce overt spinal cord neuroinflammation.¹³⁰ The presence of local and remote immune inflammation has now been confirmed in patients with lumbar radicular pain using combined positron emission tomography and magnetic resonance imaging (MRI)³ The presence of remote neuroinflammation could explain the often observed spread of symptoms beyond affected dermatomes or innervation territories in patients with entrapment neuropathies^{23,102,172} (see <https://www.youtube.com/watch?v=BZYtAR4zUpq>).

Of note, mild experimental nerve compression can also induce an inflammatory reaction within the epineurium.¹³⁰ Such epineurial inflammation may sensitise the *nervi nervorum*²¹ and induce spontaneous or evoked activity in nociceptive axons resulting in mechanical hypersensitivity despite the absence of frank axonal damage.⁴⁰ Arguably, such extraneural mechanisms may explain why a subgroup of patients with entrapment neuropathies has pain with a predominant nociceptive rather than neuropathic character.

2.4. Changes to axonal transport

Peripheral nerve compression^{7,33–35,76} and inflammation¹⁰ impair retrograde and anterograde axonal transport. Its blockage can result in increased nerve mechanosensitivity,³⁹ presumably by the accumulation and insertion of ion channels at the lesion site (see changes to nodal architecture above), and may contribute to symptoms in patients with entrapment neuropathies.

2.5. Central nervous system contributions

Because the peripheral and central nervous system form a functional entity, injuries of peripheral nerves inevitably initiate central changes. Central changes after severe experimental nerve injury include, but are not limited to, central immune-inflammatory mechanisms,^{81,101,122,123} central sensitisation,⁸⁰ and changes to cortical representations.^{43,104,105,150} Clinical hallmarks of central mechanisms including bilateral sensory deficits in unilateral painful entrapment neuropathies,^{29,37,59,142} widespread hypersensitivity,^{37,53,142,171,172} and impaired conditioned pain modulation¹³⁸ have been described in patients with entrapment neuropathies. Furthermore, cortical changes have been reported including functional and structural changes of the somatosensory cortex in patients with CTS^{43,93,104,150} and changes in cortical morphometry in patients with lumbar radicular pain.⁸⁷ Clinically, such cortical changes may manifest in an impairment in left/right judgement tasks such as found in patients with CTS.¹²⁸

It is subject of ongoing debate, whether central changes are dependent on peripheral drivers or can drive symptoms independently.¹² Patients with entrapment neuropathies have continued abnormal input from the peripheral nervous system (too much or too little), which may perpetuate central adaptations. The importance of peripheral drivers in entrapment neuropathies becomes clear from clinical observations of often immediate relief of focal and widespread symptoms after decompression surgery^{15,145,155} or local steroid injections.⁹⁷

2.6. Psychosocial factors

Psychosocial factors often play a role as risk factors for the development or persistence of pain. To date, the psychosocial contributions to entrapment neuropathies have not been evaluated in detail. A recent systematic review suggests that

there is only limited and inconsistent evidence for a positive association of psychosocial risk factors and CTS.⁹⁶ In patients with “sciatica,” the role of psychosocial features as prognostic factors for conservative management has either not been studied¹¹ or remains controversial.^{57,77} Undoubtedly though, entrapment neuropathies can have strong psychosocial consequences as apparent in lumbar radicular pain affecting many aspects of life, including psychological status.¹²⁴ Future work is required to conclusively determine the role of psychosocial factors in the generation, maintenance, and resolution of symptoms in patients with entrapment neuropathies.

3. Clinical presentation

The diagnosis and management of these patients can be challenging due to the heterogeneity of pathomechanisms and varied clinical presentation. Interestingly, nerve compression may be asymptomatic, as documented by false positive nerve root compression seen on MRI.⁴⁸ In some patients, nerve entrapment may cause pain in the innervation territory of the affected nerve⁵⁵; however, extradermatomal pain distribution is common (CTS up to 70%^{23,172}; radicular pain 64%–70%).¹⁰² Therefore, clinicians should not rule out entrapment neuropathies in the absence of clearly defined dermatomal/peripheral symptom referral patterns. Nerve entrapment may or may not cause nerve fibre damage; it may affect large and/or small fibres, and the extent of sensory fibre damage may account for heterogeneity of symptoms, ie, sensory loss and/or enhanced pain sensitivity.¹³¹ The heterogeneity of pathomechanisms likely explains the identification of subgroups of patients with radicular pain^{13,94,142} with differing somatosensory profiles, based on quantitative sensory testing^{13,142} and neuropathic pain screening tools.⁹⁴

The core sign of nerve damage in entrapment neuropathies is loss of function due to reduced action potential conduction caused by the nerve lesion.¹⁴⁶ Various positive sensory symptoms and signs indicating gain of function have been reported, including paraesthesia, pain attacks, and evoked pain (hyperalgesia and allodynia).⁹⁴ Self-reported pain profiles differ between patients with distal (CTS) vs proximal (radiculopathy) entrapment neuropathies.¹⁴⁶ Patients with radiculopathy show an increased pain attack severity and pressure, potentially reflecting distinct underlying pain mechanisms. Another feature of gain of function seen in patients with nerve-related pain is heightened nerve mechanosensitivity, which is characterised clinically by pain to mechanical provocation of neural structures (eg, elongation of the affected nerve during straight leg raise testing or nerve compression with manoeuvres such as Spurling test.^{4,29,48,108,157} Historically, neural provocation tests were thought to be diagnostic for entrapment neuropathies; however, heightened mechanosensitivity can occur in the absence of a nerve lesion,^{4,143,144,157} and vice versa, patients with confirmed entrapment neuropathies may present without signs of heightened mechanosensitivity.¹⁴ Nevertheless, neural provocation tests form an integral part of the clinical examination (see below) as the presence of heightened mechanosensitivity may guide physiotherapeutic management.¹²⁷

Although entrapment neuropathies are considered the most common cause of neuropathic pain, not all patients have obvious signs of nerve damage. For instance, radicular pain from nerve root compression can exist as a discrete disorder without a nerve root lesion and associated loss of function, ie, radiculopathy.¹⁹ Furthermore, only 30% of patients with cervical radiculopathy are classified as having neuropathic pain based on the painDETECT questionnaire.¹⁴⁴ However, it has to be acknowledged that neuropathic screening tools were developed before the new

definition of neuropathic pain and their validity may be in question.^{143,147,148}

4. Assessment

4.1. Neuropathic pain grading system

The Neuropathic Pain Special Interest Group of the International Association of the Study of Pain introduced a grading system to assist clinicians and researchers determining the certainty of neuropathic pain (Fig. 2).⁵⁵ The level of “probable” neuropathic pain is suggested to be sufficient to initiate pharmacological treatment for neuropathic pain.⁵⁵

The application of the grading system may, however, be problematic in patients with entrapment neuropathies because (1) symptoms often spread beyond the affected dermatome or innervation territories of the affected nerve, (2) patients may have very subtle sensory loss that may not be identified with bedside sensory testing and/or patients may present with mainly gain of function, and (3) diagnostic tests may not be indicated (eg, skin biopsies) or may be negative (see imaging and nerve conduction studies below). It therefore often remains unclear whether patients with entrapment neuropathies should receive management according to the neuropathic pain guidelines.⁴⁴

4.2. Clinical assessment

The examination of patients with suspected entrapment neuropathies comprises a comprehensive subjective assessment, including the localisation and distribution of symptoms on a body chart as well as their quality, intensity, and behaviour over 24 hours. The medical history provides clues about potential mechanisms of injury or causes leading to pain or neurological lesions and disorder progression. The history may also provide important information on psychological or behavioural factors (orange, yellow flags), social and economic factors (blue flags) as well as occupational factors (black flags) that may contribute to

the presentation.⁷² Importantly, clinicians are encouraged to evaluate the presence of differential diagnoses and serious pathologies (red flags) masquerading as entrapment neuropathies (Table 1).⁵⁶

The physical examination includes the assessment of both musculoskeletal and related neural tissue, as well as a detailed neurological bedside examination of sensory and motor function to ascertain the presence of a nerve lesion. Results of medical investigations may assist in the diagnostic work-up. For a detailed discussion on clinical assessment of entrapment neuropathies with a focus on spinally referred pain, please consult the study by Schmid and Tampin.¹²⁹

4.2.1. Neurological examination

Motor function assessment comprises the examination of reflex responses and muscle strength testing. Sensory examination must include the assessment of large and small sensory fibres because both can be affected in patients with nerve entrapment.^{142,146} Figure 3 outlines various tools for bedside sensory testing that assess loss and gain of function in distinct sensory fibre populations. The validity of low-cost bedside sensory testing compared to quantitative sensory testing or skin biopsy has been documented in recent studies.^{120,173}

4.2.2. Neural mechanosensitivity

Several provocation tests are designed to detect nerve mechanosensitivity such as the Tinel sign or Phalen test for CTS or the Spurling test for cervical radiculopathy. However, the measurement properties of these positional tests vary greatly between studies, indicating uncertainty in their diagnostic utility.^{88,153}

The straight leg raise test has been widely used to assess heightened nerve mechanosensitivity in the lower limb.^{38,59} Although the upper-limb analogue (upper-limb neurodynamic test)⁴⁷ is less known in medicine, it is extensively applied in

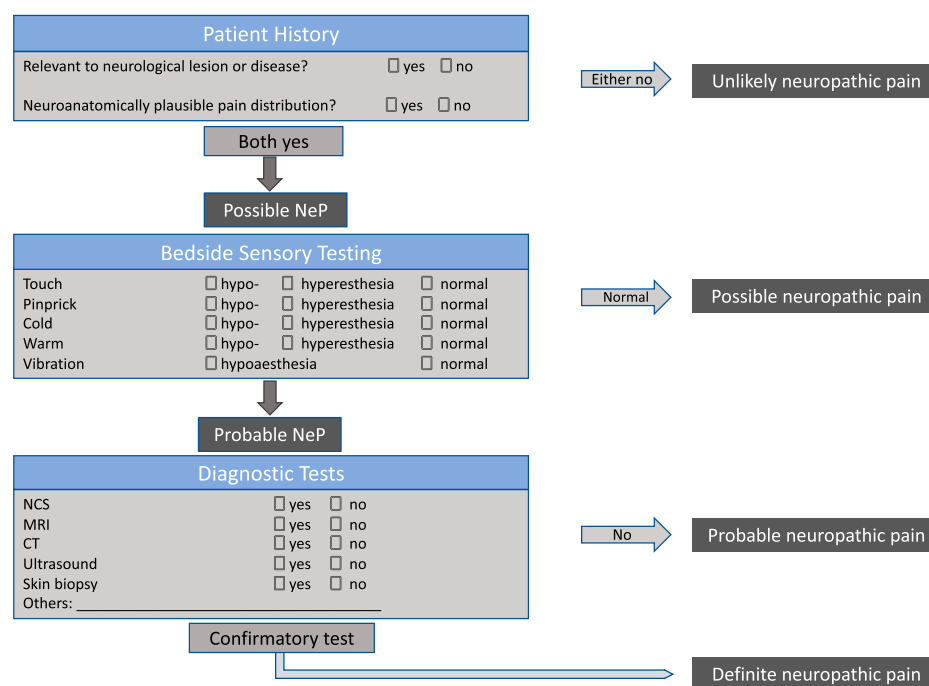


Figure 2. Neuropathic pain grading system adapted from⁵⁵.

Table 1	
Differential diagnoses and serious pathologies potentially masquerading carpal tunnel syndrome or “sciatica.”	
Carpal tunnel syndrome	Sciatica
Cervical radiculopathy	Cauda equina syndrome
Thoracic outlet syndrome	Spinal infection
Pronator teres syndrome	Malignancy
Radial neuropathy	Spinal fracture
Ulnar neuropathy	Metastatic spinal cord compression
Tenosynovitis	Deep vein thrombosis
Raynaud syndrome	Axial spondyloarthritis
Inflammatory arthropathy	Spinal stenosis
Peripheral nerve tumour	Synovial cyst
Multiple sclerosis	Meralgia paraesthetica
Amyotrophic lateral sclerosis	Hip osteoarthritis
Polyneuropathy (eg, diabetic or chronic inflammatory demyelinating polyneuropathy)	Polyneuropathy (eg, diabetic or chronic inflammatory demyelinating polyneuropathy)
Acute compression syndromes (eg, Saturday night palsy)	Compartment syndrome
Multiple sclerosis	Multiple sclerosis

physiotherapy practice.¹⁰⁸ These tests comprise passive joint movements that cause movement/elongation or tension on neural structures. An abnormal response to the tests is defined as at least partial reproduction of the patient’s symptoms with positive structural differentiation.¹⁰⁸ Structural differentiation uses movements at a site remote to the painful area to further load or unload neural structures, thus differentiating symptoms of neural origin from local musculoskeletal origin.⁶⁴ For detailed description of nerve mechanosensitivity testing, we refer the readers to the studies by Butler,²² Schmid and Tampin,¹²⁹ and Tampin.¹⁴⁹

4.2.3. Imaging and nerve conduction studies

Additional examinations such as MRI, ultrasound, or nerve conduction studies may help in the diagnostic workup. Although nerve conduction tests are particularly useful in the diagnosis of distal entrapment neuropathies (CTS and cubital tunnel syndrome), their value for more proximal neuropathies has not been fully established.³⁰ It should be noted that in the early stages of CTS, nerve conduction studies may be unable to detect nerve injury.¹³¹ MRI is commonly used for proximal entrapment neuropathies (eg, “sciatica”), but often results in false negatives






Type of Stimulus	Axon Type	Tool		Sensory Loss	Sensory Gain
Static light touch	Aβ	Q-tip, cotton wool		✓	✓
Vibration	Aβ	Tuning fork		✓	
Dynamic mechanical	Aβ	Brush, cotton wool, Q-tip		✓	✓
Pin prick	Aδ and C	Toothpick, neurotip		✓	✓
Cold/warm detection	Aδ and C	Cold and warm coins/thermo-rollers, tiptherm		✓	

Figure 3. Bedside sensory testing tools.

or positives and the affected level identified on imaging and clinical examination often does not match.¹⁵⁹ Ultrasonography is often preferred over MRI for distal entrapment neuropathies due to its cost-effectiveness, ease of access, and possibility of quick contralateral comparison. The screening for an enlarged nerve diameter might be useful in the diagnosis of CTS¹²¹ or cubital tunnel syndrome.²⁷ In addition to being confirmatory tests, imaging and nerve conduction tests can be important for differential diagnosis and the exclusion of serious pathologies.

5. Natural history, prognosis, and management

Due to the scarcity of evidence in less common entrapment neuropathies, we report findings from CTS and “sciatica” only. For ethical reasons, studying the natural history of entrapment neuropathies is challenging. In CTS patients who have not received treatment over an average of 2 years, ~23% of patients deteriorated, ~29% remained stable, and ~48% showed symptom recovery.¹¹¹ A similar pattern presents in patients with “sciatica,” where the clinical course is generally considered favourable; however, at least one-third will develop persistent pain and disability lasting a year or more.^{65,69,77,156,161,164} Unfortunately, prognostic factors for pain persistence remain elusive¹¹; the most comprehensive cohort study to date in “sciatica” showed only modest associations with poor outcome for shorter pain duration, belief that symptoms will not last long and overall impact of “sciatica.”⁷⁷ Unexpectedly, the strongest predictive factor (odds ratio 5.62, 95% confidence interval 1.76–17.92) was myotomal weakness, which was, however, associated with a good prognosis. Given the failure or only weak predictive ability of traditional prognostic factors (psychosocial features, MRI, pain severity etc), novel approaches must be considered.

5.1. Management

Independent of the type of entrapment neuropathy, clinical guidelines suggest a course of conservative treatment before more invasive options are considered.^{20,120,174}

5.1.1. Physiotherapy/occupational therapy for carpal tunnel syndrome

For mild to moderate CTS, therapy usually includes advice, splinting, electrophysiological agents as well as manual therapy and/or exercises.⁵¹ There is currently limited evidence for a short-term benefit of splinting compared to no treatment.¹¹³ Splinting is recommended at night only.⁵¹ A Cochrane review reported that there is limited evidence for a beneficial effect of exercise and mobilisation in the management of patients with CTS.¹¹⁴ This was supported by another review suggesting that neural mobilisation did not improve clinical outcomes compared to other treatments.¹⁶ However, more recent randomised controlled trials suggest a benefit of more comprehensive hand therapy packages.^{52,54,84} Given the limited literature available for the effectiveness of therapeutic management of CTS, the decision to provide physiotherapy/occupational therapy management should be based on the clinicians’ expertise and patients’ preferences¹¹⁴ while following current treatment recommendations.⁵¹

5.1.2. Physiotherapy for “sciatica”

Physiotherapy is recommended as the first-line treatment for patients with “sciatica.”¹⁰⁶ Based on studies with mostly high risk

of bias and heterogeneity of physiotherapy interventions, we found inadequate evidence to make clinical recommendations on physiotherapy for patients with “sciatica.”⁴¹ Importantly, “sciatica” definitions in available studies varied significantly and the studied populations were heterogeneous making firm conclusions difficult. There is some indication that distinct subgroups of patients may react better to certain physiotherapy treatments. For instance, patients with heightened neural mechanosensitivity seem to benefit most from neural mobilisations compared to patients with radiculopathy or radicular pain.¹²⁷ Large, well-designed trials are required to determine the most effective physiotherapy approach and whether treatment stratification may improve outcome.

5.1.3. Pharmacological interventions

Oral medications do not seem to be beneficial in patients with CTS, with nonsteroidal anti-inflammatories, diuretics, or vitamin B6 not being superior to placebo.¹¹⁰ Local steroid injections seem to have a short-term benefit only, which exceeds the effect of orally taken steroids.⁹⁷ Similar results are reported by several meta-analyses for patients with “sciatica,” suggesting that nonsteroidal anti-inflammatories,¹¹⁹ oral corticosteroids,¹¹⁶ Tumour necrosis factor blockers,¹⁶² opioids,¹¹⁶ and specific neuropathic pain medications (eg, anticonvulsants and antidepressants) do not provide better symptom relief than placebo.¹¹⁶ Again, corticosteroid injections seem to provide a small benefit in the short but not long term.¹¹⁷

This disappointing pharmacological efficacy in patients with entrapment neuropathies may in part be due to our limited understanding of the exact pathomechanisms. Importantly, the heterogeneity of patients within one diagnosis may mask potential beneficial effects of specific subgroups. Future work is required to determine whether stratification methods could be used to identify distinct populations that may benefit from specific pharmacological interventions.

5.1.4. Surgery for carpal tunnel syndrome

Carpal tunnel decompression is the most common upper-limb surgery⁴⁵ and surgery rates are predicted to double over the coming decade,¹⁷ posing a significant challenge to public health systems. The 2 surgical approaches used are endoscopic and open carpal tunnel release, with no strong evidence indicating one technique to be more superior.¹⁶⁰ Although CTS surgery is usually successful, ~25% of patients do not benefit.¹⁸ Potential complications include scar tenderness, persistent symptoms, neurovascular injury, wound complication, and reduced grip strength.⁹⁸ Indications for surgical consultation include moderate-to-severe or deteriorating symptoms, daily symptoms, frequent night waking, persistent symptoms causing functional impairment, not responding to nonsurgical treatments (120), and patients’ preference.¹⁵²

5.1.5. Surgery for “sciatica”

Lumbar microdiscectomy is the most common type of surgery performed to relieve nerve root irritation or compression due to a herniated disk. Pooled data of >13,000 patients undergoing surgery for “sciatica” demonstrated that although surgery is followed by a rapid decrease in pain and disability by 3 months, patients still experienced mild-to-moderate pain and disability 5 years after surgery.⁸⁹ Of note, ~4% of patients are worse after surgery¹³⁷ and reoperation rates of ~12% within 4 years have been reported after discectomy.⁶⁶ Factors associated with

negative postoperative outcomes include intact annulus fibrosus, longer duration of sick-leave, worker's compensation, and greater severity of baseline symptoms.¹⁶⁸ Two systematic reviews suggest that surgery may yield faster pain relief and perceived recovery than physiotherapy or physical activity for patients with "sciatica," however, long-term outcomes are comparable.⁷⁰ Given the nonsuperiority of surgery in the long-term and the significant risks and side effects, conservative management should remain the first-line treatment. However, surgery is indicated in the presence of severe or progressive neurological deficits or persistent symptoms that are unresponsive to conservative treatment.¹⁰⁶ Future research is needed to better understand appropriate patient selection and timelines for surgery to improve outcomes and patient satisfaction.

6. Future challenges and conclusion

The somewhat disappointing evidence of pharmacological, physiotherapeutic and surgical management of entrapment neuropathies clearly highlights that a one-size-fits-all approach is not successful. Considering the distinct pathomechanisms and contributing factors, contemporary management should be personalised, considering the multidimensional profile of an individual patient (eg, different pain mechanisms at play, contextual factors, cognitive emotional drivers, comorbidities, **Fig. 4**).¹⁵⁴ As such, individualised management will vary in patients with entrapment neuropathy and should target the predominant dimensions. For instance, tissue-specific interventions (eg, specific exercises, postural modification, mobilisations, targeted pharmacology, injection, and surgery) may be indicated in patients with clear nociceptive, heightened neural mechanosensitivity or neuropathic components. By contrast, multidisciplinary systemic treatments (eg, cognitive behavioural and functional approaches, general exercise) may be more suitable for patients with strong cognitive-emotional, contextual, and nociplastic drivers. Future research is required to further understand specific drivers at play in individual patients, their utility for predicting outcome and treatment stratification, and the effect of personalised treatment on outcomes before a truly evidence-

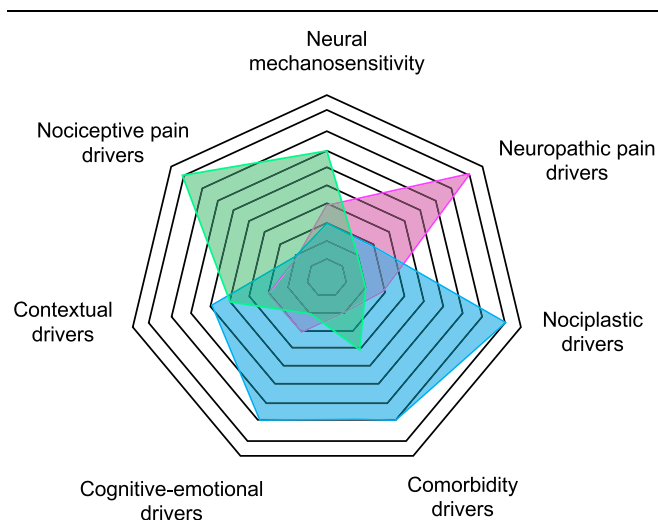


Figure 4. Potential drivers contributing to specific multidimensional profiles in patients with entrapment neuropathies. The spiderweb highlights how distinct drivers may be more prominent in 3 distinct patient presentations (green, blue, and pink). The weighting of these drivers in individual patients may contribute to the design of personalized management for patients with entrapment neuropathies.

based management of patients with entrapment neuropathies is possible.

Disclosures

The authors have no conflict of interest to declare.

A.B. Schmid is supported by the National Institute for Health Research (NIHR) Oxford Biomedical Research Centre (BRC). Brigitte Tampin was supported by the Government of Western Australia, Department of Health, and Raine Medical Research Foundation. The views expressed are those of the authors and not necessarily those of the NHS, the NIHR or the Department of Health.

Article history:

Received 11 October 2019

Received in revised form 4 May 2020

Accepted 30 May 2020

Available online 22 July 2020

References

- Abzug JM, Jacoby SM, Osterman AL. Surgical options for recalcitrant carpal tunnel syndrome with perineural fibrosis. *Hand (N Y)* 2012;7: 23–9.
- Ala-Kokko L. Genetic risk factors for lumbar disc disease. *Ann Med* 2002;34:42–7.
- Albrecht DS, Ahmed SU, Kettner NW, Borra RJH, Cohen-Adad J, Deng H, Houle TT, Opalacz A, Roth SA, Melo MFV, Chen L, Mao J, Hooker JM, Loggia ML, Zhang Y. Neuroinflammation of the spinal cord and nerve roots in chronic radicular pain patients. *PAIN* 2018;159:968–77.
- Allison GT, Nagy BM, Hall T. A randomized clinical trial of manual therapy for cervico-brachial pain syndrome—a pilot study. *Man Ther* 2002;7: 95–102.
- American Academy of Orthopaedic Surgeons. Clinical practice guideline on the diagnosis of carpal tunnel syndrome. Rosemont, 2007.
- Amir R, Michaelis M, Devor M. Membrane potential oscillations in dorsal root ganglion neurons: role in normal electrogenesis and neuropathic pain. *J Neurosci* 1999;19:8589–96.
- Ando Y. Experimental study on chronic entrapment neuropathy [in Japanese]. *Nippon Seikeigeka Gakkai Zasshi* 1990;64:633–47.
- Andrasinova T, Kalikova E, Kopicak R, Srotova I, Vlckova E, Dusek L, Bednarik J, Adamova B. Evaluation of the neuropathic component of chronic low back pain. *Clin J Pain* 2019;35:7–17.
- Arendt-Nielsen L, Gregersen H, Toft E, Bjerring P. Involvement of thin afferents in carpal tunnel syndrome: evaluated quantitatively by argon laser stimulation. *Muscle Nerve* 1991;14:508–14.
- Armstrong BD, Hu Z, Abad C, Yamamoto M, Rodriguez WI, Cheng J, Lee M, Chhith S, Gomariz RP, Waschek JA. Induction of neuropeptide gene expression and blockade of retrograde transport in facial motor neurons following local peripheral nerve inflammation in severe combined immunodeficiency and BALB/C mice. *Neuroscience* 2004; 129:93–9.
- Ashworth J, Konstantinou K, Dunn KM. Prognostic factors in non-surgically treated sciatica: a systematic review. *BMC Musculoskelet Disord* 2011;12:208.
- Baron R, Hans G, Dickenson AH. Peripheral input and its importance for central sensitization. *Ann Neurol* 2013;74:630–6.
- Baron R, Maier C, Attal N, Binder A, Bouhassira D, Cruccu G, Finnerup NB, Haanpaa M, Hansson P, Hulleman P, Jensen TS, Freynhagen R, Kennedy JD, Magerl W, Mainka T, Reimer M, Rice AS, Segerdahl M, Serra J, Sindrup S, Sommer C, Tolle T, Vollert J, Treede RD. Peripheral neuropathic pain: a mechanism-related organizing principle based on sensory profiles. *PAIN* 2017;158:261–72.
- Baselgia LT, Bennett DL, Silbiger RM, Schmid AB. Negative neurodynamic tests do not exclude neural dysfunction in patients with entrapment neuropathies. *Arch Phys Med Rehabil* 2017;98:480–6.
- Baskozos G, Sandy-Hindmarch O, Clark A, Windsor K, Karlsson P, Weir G, McDermott L, Burchall J, Wiberg A, Furniss D, Bennett D, Schmid A. Molecular and cellular correlates of human nerve regeneration: ADCYAP1 encoding PACAP enhances sensory neuron outgrowth. *Brain* 2020;143:2009–26.
- Basson A, Olivier B, Ellis R, Coppieters M, Stewart A, Mudzi W. The effectiveness of neural mobilization for neuromusculoskeletal

- conditions: a systematic review and meta-analysis. *J Orthop Sports Phys Ther* 2017;47:593–615.
- [17] Bebbington E, Furniss D. Linear regression analysis of Hospital Episode Statistics predicts a large increase in demand for elective hand surgery in England. *J Plast Reconstr Aesthet Surg* 2015;68:243–51.
- [18] Bland JD. Treatment of carpal tunnel syndrome. *Muscle Nerve* 2007;36:167–71.
- [19] Bogduk N. On the definitions and physiology of back pain, referred pain, and radicular pain. *PAIN* 2009;147:17–19.
- [20] Bono CM, Ghiselli G, Gilbert TJ, Kreiner DS, Reitman C, Summers JT, Baisden JL, Easa J, Fernand R, Lamer T, Matz PG, Mazanec DJ, Resnick DK, Shaffer WO, Sharma AK, Timmons RB, Toton JF, North American Spine S. An evidence-based clinical guideline for the diagnosis and treatment of cervical radiculopathy from degenerative disorders. *Spine J* 2011;11:64–72.
- [21] Bove GM, Ransil BJ, Lin HC, Leem JG. Inflammation induces ectopic mechanical sensitivity in axons of nociceptors innervating deep tissues. *J Neurophysiol* 2003;90:1949–55.
- [22] Butler DS. The sensitive nervous system. Adelaide: NOIgroup publications, 2000.
- [23] Caliendo P, La Torre G, Aprile I, Pazzaglia C, Commodari I, Tonali P, Padua L. Distribution of paresthesias in Carpal Tunnel Syndrome reflects the degree of nerve damage at wrist. *Clin Neurophysiol* 2006;117:228–31.
- [24] Calvo M, Richards N, Schmid AB, Barroso A, Zhu L, Ivulic D, Zhu N, Anwandter P, Bhat MA, Court FA, McMahan SB, Bennett DL. Altered potassium channel distribution and composition in myelinated axons suppresses hyperexcitability following injury. *Elife* 2016;5:e12661.
- [25] Cappelen-Smith C, Lin CS, Burke D. Activity-dependent hyperpolarization and impulse conduction in motor axons in patients with carpal tunnel syndrome. *Brain* 2003;126:1001–8.
- [26] Chen Y, Devor M. Ectopic mechanosensitivity in injured sensory axons arises from the site of spontaneous electrogenesis. *Eur J Pain* 1998;2:165–78.
- [27] Chen IJ, Chang KV, Wu WT, Ozcakar L. Ultrasound parameters other than the direct measurement of ulnar nerve size for diagnosing cubital tunnel syndrome: a systemic review and meta-analysis. *Arch Phys Med Rehabil* 2019;100:1114–30.
- [28] Chhabra A, Wadhwa V, Thakkar RS, Carrino JA, Dellon AL. Recurrent ulnar nerve entrapment at the elbow: correlation of surgical findings and 3-Tesla magnetic resonance neurography. *Can J Plast Surg* 2013;21:186–9.
- [29] Chien A, Eliav E, Sterling M. Whiplash (grade II) and cervical radiculopathy share a similar sensory presentation: an investigation using quantitative sensory testing. *Clin J Pain* 2008;24:595–603.
- [30] Cho SC, Ferrante MA, Levin KH, Harmon RL, So YT. Utility of electrodiagnostic testing in evaluating patients with lumbosacral radiculopathy: an evidence-based review. *Muscle Nerve* 2010;42:276–82.
- [31] Coppieters MW, Schmid AB, Kubler PA, Hodges PW. Description, reliability and validity of a novel method to measure carpal tunnel pressure in patients with carpal tunnel syndrome. *Man Ther* 2012;17:589–92.
- [32] Cudlip SA, Howe FA, Clifton A, Schwartz MS, Bell BA. Magnetic resonance neurography studies of the median nerve before and after carpal tunnel decompression. *J Neurosurg* 2002;96:1046–51.
- [33] Dahlin LB, McLean WG. Effects of graded experimental compression on slow and fast axonal transport in rabbit vagus nerve. *J Neurol Sci* 1986;72:19–30.
- [34] Dahlin LB, Rydevik B, McLean WG, Sjostrand J. Changes in fast axonal transport during experimental nerve compression at low pressures. *Exp Neurol* 1984;84:29–36.
- [35] Dahlin LB, Sjostrand J, McLean WG. Graded inhibition of retrograde axonal transport by compression of rabbit vagus nerve. *J Neurol Sci* 1986;76:221–30.
- [36] Dahlin LB, Shyu BC, Danielsen N, Andersson SA. Effects of nerve compression or ischaemia on conduction properties of myelinated and non-myelinated nerve fibres. An experimental study in the rabbit common peroneal nerve. *Acta Physiol Scand* 1989;136:97–105.
- [37] de la Llave-Rincon AI, Fernandez-de-Las-Penas C, Fernandez-Carnero J, Padua L, Arendt-Nielsen L, Pareja JA. Bilateral hand/wrist heat and cold hyperalgesia, but not hypoesthesia, in unilateral carpal tunnel syndrome. *Exp Brain Res* 2009;198:455–63.
- [38] Deville WL, van der Windt DA, Dzaferagic A, Bezemer PD, Bouter LM. The test of Lasague: systematic review of the accuracy in diagnosing herniated discs. *Spine (Phila Pa 1976)* 2000;25:1140–7.
- [39] Dilley A, Bove GM. Disruption of axoplasmic transport induces mechanical sensitivity in intact rat C-fibre nociceptor axons. *J Physiol* 2008;586:593–604.
- [40] Dilley A, Lynn B, Pang SJ. Pressure and stretch mechanosensitivity of peripheral nerve fibres following local inflammation of the nerve trunk. *PAIN* 2005;117:462–72.
- [41] Dove L, Jones G, Kelsey L, Cairns M, Schmid AB. How effective is physiotherapy for sciatica? A systematic review and meta-analysis. 7th International Congress on Neuropathic Pain, London, 2019.
- [42] Drummond PD, Drummond ES, Dawson LF, Mitchell V, Finch PM, Vaughan CW, Phillips JK. Upregulation of alpha1-adrenoceptors on cutaneous nerve fibres after partial sciatic nerve ligation and in complex regional pain syndrome type II. *PAIN* 2014;155:606–16.
- [43] Druschky K, Kaltenhauser M, Hummel C, Druschky A, Huk WJ, Stefan H, Neundorfer B. Alteration of the somatosensory cortical map in peripheral mononeuropathy due to carpal tunnel syndrome. *Neuroreport* 2000;11:3925–30.
- [44] Dworkin RH, O'Connor AB, Kent J, Mackey SC, Raja SN, Stacey BR, Levy RM, Backonja M, Baron R, Harke H, Loeser JD, Treede RD, Turk DC, Wells CD. International association for the study of pain neuropathic pain special interest G. Interventional management of neuropathic pain: NeuPSIG recommendations. *PAIN* 2013;154:2249–61.
- [45] Elective JM. Surgery waiting times 2016–2017: Australian hospital statistics. Australian Institute of Health and Wellness. Available at: <https://www.aihw.gov.au/reports/hospitals/elective-surgery-waiting-times-ahs-2016-17/data>. Accessed March 7, 2018.
- [46] Ellis R, Blyth R, Arnold N, Miner-Williams W. Is there a relationship between impaired median nerve excursion and carpal tunnel syndrome? A systematic review. *J Hand Ther* 2017;30:3–12.
- [47] Elvey RL. Physical evaluation of the peripheral nervous system in disorders of pain and dysfunction. *J Hand Ther* 1997;10:122–9.
- [48] Endean A, Palmer KT, Coggon D. Potential of magnetic resonance imaging findings to refine case definition for mechanical low back pain in epidemiological studies: a systematic review. *Spine (Phila Pa 1976)* 2011;36:160–9.
- [49] England JD, Gamboni F, Ferguson MA, Levinson SR. Sodium channels accumulate at the tips of injured axons. *Muscle Nerve* 1994;17:593–8.
- [50] Erdem Tilki H, Coskun M, Unal Akdemir N, Incesu L. Axon count and sympathetic skin responses in lumbosacral radiculopathy. *J Clin Neurol* 2014;10:10–16.
- [51] Erickson M, Lawrence M, Jansen CWS, Coker D, Amadio P, Cleary C. Hand pain and sensory deficits: carpal tunnel syndrome. *J Orthop Sports Phys Ther* 2019;49:CPG1–CPG85.
- [52] Fernandez-de-Las-Penas C, Ortega-Santiago R, de la Llave-Rincon AI, Martinez-Perez A, Fahandezh-Saddi Diaz H, Martinez-Martin J, Pareja JA, Cuadrado-Perez ML. Manual physical therapy versus surgery for carpal tunnel syndrome: a randomized parallel-group trial. *J Pain* 2015;16:1087–94.
- [53] Fernandez-de-las-Penas C, de la Llave-Rincon AI, Fernandez-Carnero J, Cuadrado ML, Arendt-Nielsen L, Pareja JA. Bilateral widespread mechanical pain sensitivity in carpal tunnel syndrome: evidence of central processing in unilateral neuropathy. *Brain* 2009;132:1472–9.
- [54] Fernandez-de-Las-Penas C, Cleland J, Palacios-Cena M, Fuensalida-Novo S, Pareja JA, Alonso-Blanco C. The effectiveness of manual therapy versus surgery on self-reported function, cervical range of motion, and pinch grip force in carpal tunnel syndrome: a randomized clinical trial. *J Orthop Sports Phys Ther* 2017;47:151–61.
- [55] Finnerup NB, Haroutounian S, Kamerman P, Baron R, Bennett DL, Bouhassira D, Cruccu G, Freeman R, Hansson P, Nurmikko T, Raja SN, Rice AS, Serra J, Smith BH, Treede RD, Jensen TS. Neuropathic pain: an updated grading system for research and clinical practice. *PAIN* 2016;157:1599–606.
- [56] Finucane L, Downie A, Mercer C, Greenhalgh S, Boissonnault WG, Pool-Goudzwaard A, Beneciuk JM, Leech R, Selve J. International Framework for red flags for potential serious spinal pathologies. *J Orthop Sports Phys Ther* 2020;50:350–72.
- [57] Fjeld O, Grotle M, Siewers V, Pedersen LM, Nilsen KB, Zwart JA. Prognostic factors for persistent leg-pain in patients hospitalized with acute sciatica. *Spine (Phila Pa 1976)* 2017;42:E272–9.
- [58] Foix C, Marie P. Atrophie isolée de l'éminence thénar d'origine névritique. Rôle du ligament annulaire antérieur du carpe dans la pathogénie de la lésion. *Rev Neurol* 1913;26:647–8.
- [59] Freynhagen R, Rolke R, Baron R, Tolle TR, Rutjes AK, Schu S, Treede RD. Pseudoradicular and radicular low-back pain—a disease continuum rather than different entities? Answers from quantitative sensory testing. *PAIN* 2008;135:65–74.
- [60] Gelberman RH, Hergenroeder PT, Hargens AR, Lundborg GN, Akeson WH. The carpal tunnel syndrome. A study of carpal canal pressures. *J Bone Joint Surg Am* 1981;63:380–3.
- [61] Gupta R, Channual JC. Spatiotemporal pattern of macrophage recruitment after chronic nerve compression injury. *J Neurotrauma* 2006;23:216–26.

- [62] Gupta R, Steward O. Chronic nerve compression induces concurrent apoptosis and proliferation of Schwann cells. *J Comp Neurol* 2003;461:174–86.
- [63] Gupta R, Rowshan K, Chao T, Mozaffar T, Steward O. Chronic nerve compression induces local demyelination and remyelination in a rat model of carpal tunnel syndrome. *Exp Neurol* 2004;187:500–8.
- [64] Hall TM, Elvey RL. Nerve trunk pain: physical diagnosis and treatment. *Man Ther* 1999;4:63–73.
- [65] Haugen AJ, Brox JI, Grovle L, Keller A, Natvig B, Soldal D, Grotle M. Prognostic factors for non-succes in patients with sciatica and disc herniation. *BMC Musculoskelet Disord* 2012;13:183.
- [66] Heindel P, Tuchman A, Hsieh PC, Pham MH, D'Oro A, Patel NN, Jakoi AM, Hah R, Liu JC, Buser Z, Wang JC. Reoperation rates after single-level lumbar discectomy. *Spine (Phila Pa 1976)* 2017;42:E496–501.
- [67] Hu P, Bembrick AL, Keay KA, McLachlan EM. Immune cell involvement in dorsal root ganglia and spinal cord after chronic constriction or transection of the rat sciatic nerve. *Brain Behav Immun* 2007;21:599–616.
- [68] Ido K, Urushidani H. Fibrous adhesive entrapment of lumbosacral nerve roots as a cause of sciatica. *Spinal Cord* 2001;39:269–73.
- [69] Iversen T, Solberg TK, Wilsgaard T, Waterloo K, Brox JI, Ingebrigtsen T. Outcome prediction in chronic unilateral lumbar radiculopathy: prospective cohort study. *BMC Musculoskelet Disord* 2015;16:17.
- [70] Jacobs WC, van Tulder M, Arts M, Rubinstein SM, van Middelkoop M, Ostelo R, Verhagen A, Koes B, Peul WC. Surgery versus conservative management of sciatica due to a lumbar herniated disc: a systematic review. *Eur Spine J* 2011;20:513–22.
- [71] Jiang YQ, Xing GG, Wang SL, Tu HY, Chi YN, Li J, Liu FY, Han JS, Wan Y. Axonal accumulation of hyperpolarization-activated cyclic nucleotide-gated cation channels contributes to mechanical allodynia after peripheral nerve injury in rat. *PAIN* 2008;137:495–506.
- [72] Kendall N, Linton S, Main C. Guide to assessing psychosocial yellow flags in acute low back pain: risk factors for long-term disability and work loss. Wellington: Accident Rehabilitation and Compensation Insurance Corporation of New Zealand and the National Health Committee, 1997.
- [73] Kiernan MC, Mogyros I, Burke D. Conduction block in carpal tunnel syndrome. *Brain* 1999;122(pt 5):933–41.
- [74] Kiyiloglu N. Sympathetic skin response and axon counting in carpal tunnel syndrome. *J Clin Neurophysiol* 2007;24:424; author reply 424.
- [75] Kobayashi S, Kokubo Y, Uchida K, Yayama T, Takeno K, Negoro K, Nakajima H, Baba H, Yoshizawa H. Effect of lumbar nerve root compression on primary sensory neurons and their central branches: changes in the nociceptive neuropeptides substance P and somatostatin. *Spine (Phila Pa 1976)* 2005;30:276–82.
- [76] Konstantinou K, Dunn KM. Sciatica: review of epidemiological studies and prevalence estimates. *Spine (Phila Pa 1976)* 2008;33:2464–72.
- [77] Konstantinou K, Dunn KM, Ogollah R, Lewis M, van der Windt D, Hay EM, Team AS. Prognosis of sciatica and back-related leg pain in primary care: the ATLAS cohort. *Spine J* 2018;18:1030–40.
- [78] Kozak A, Schedlbauer G, Wirth T, Euler U, Westermann C, Nienhaus A. Association between work-related biomechanical risk factors and the occurrence of carpal tunnel syndrome: an overview of systematic reviews and a meta-analysis of current research. *BMC Musculoskelet Disord* 2015;16:231.
- [79] Kuwabara S, Tamura N, Yamanaka Y, Misawa S, Iose S, Bae JS, Hattori T, Asahina M. Sympathetic sweat responses and skin vasomotor reflexes in carpal tunnel syndrome. *Clin Neurol Neurosurg* 2008;110:691–5.
- [80] Latremoliere A, Woolf CJ. Central sensitization: a generator of pain hypersensitivity by central neural plasticity. *J Pain* 2009;10:895–926.
- [81] LeBlanc BW, Zerah ML, Kadasi LM, Chai N, Saab CY. Minocycline injection in the ventral posterolateral thalamus reverses microglial reactivity and thermal hyperalgesia secondary to sciatic neuropathy. *Neurosci Lett* 2011;498:138–42.
- [82] Lemmela S, Solovieva S, Shiri R, Benner C, Heliövaara M, Kettunen J, Anttila V, Ripatti S, Perola M, Seppälä I, Juonala M, Kahonen M, Salomaa V, Viikari J, Raitakari OT, Lehtimäki T, Palotie A, Viikari-Juntura E, Husgafvel-Pursiainen K. Genome-wide meta-analysis of sciatica in Finnish population. *PLoS One* 2016;11:e0163877.
- [83] Lewis AM, Layzer R, Engstrom JW, Barbaro NM, Chin CT. Magnetic resonance neurography in extraspinal sciatica. *Arch Neurol* 2006;63:1469–72.
- [84] Lewis KJ, Coppieters MW, Ross L, Hughes I, Vicenzino B, Schmid AB. Group education, night splinting and home exercises reduce conversion to surgery for carpal tunnel syndrome: a multicentre randomised trial. *J Physiother* 2020;66:97–104.
- [85] Liu X, Zhou JL, Chung K, Chung JM. Ion channels associated with the ectopic discharges generated after segmental spinal nerve injury in the rat. *Brain Res* 2001;900:119–27.
- [86] Lozano-Calderon S, Anthony S, Ring D. The quality and strength of evidence for etiology: example of carpal tunnel syndrome. *J Hand Surg Am* 2008;33:525–38.
- [87] Luchtman M, Steinecke Y, Baecke S, Lutzkendorf R, Bernarding J, Kohl J, Jollenbeck B, Tempelmann C, Ragert P, Firsching R. Structural brain alterations in patients with lumbar disc herniation: a preliminary study. *PLoS One* 2014;9:e90816.
- [88] MacDermid J. Accuracy of clinical tests used in the detection of carpal tunnel syndrome: a literature review. *J Hand Ther* 1991;4:169–76.
- [89] Machado GC, Witzleb AJ, Fritsch C, Maher CG, Ferreira PH, Ferreira ML. Patients with sciatica still experience pain and disability 5 years after surgery: a systematic review with meta-analysis of cohort studies. *Eur J Pain* 2016;20:1700–9.
- [90] Mackinnon SE, Dellon AL, Hudson AR, Hunter DA. Chronic nerve compression—an experimental model in the rat. *Ann Plast Surg* 1984;13:112–20.
- [91] Mackinnon SE, Dellon AL, Hudson AR, Hunter DA. Chronic human nerve compression—a histological assessment. *Neuropathol Appl Neurobiol* 1986;12:547–65.
- [92] Mackinnon SE. Pathophysiology of nerve compression. *Hand Clin* 2002;18:231–41.
- [93] Maeda Y, Kettner N, Sheehan J, Kim J, Cina S, Malatesta C, Gerber J, McManus C, Mezzacappa P, Morse LR, Audette J, Napadow V. Altered brain morphometry in carpal tunnel syndrome is associated with median nerve pathology. *NeuroImage Clin* 2013;2:313–19.
- [94] Mahn F, Hulleman P, Gockel U, Brosz M, Freynhagen R, Tolle TR, Baron R. Sensory symptom profiles and co-morbidities in painful radiculopathy. *PLoS One* 2011;6:e18018.
- [95] Mallik A, Weir AI. Nerve conduction studies: essentials and pitfalls in practice. *J Neurol Neurosurg Psychiatry* 2005;76(suppl 2):ii23–31.
- [96] Mansfield M, Thacker M, Sandford F. Psychosocial risk factors and the association with carpal tunnel syndrome: a systematic review. *Hand (N Y)* 2018;13:501–8.
- [97] Marshall S, Tardif G, Ashworth N. Local corticosteroid injection for carpal tunnel syndrome. *Cochrane Database Syst Rev* 2007:CD001554.
- [98] Middleton SD, Anakwe RE. Carpal tunnel syndrome. *BMJ* 2014;349:g6437.
- [99] Moalem G, Tracey DJ. Immune and inflammatory mechanisms in neuropathic pain. *Brain Res Rev* 2006;51:240–64.
- [100] Mondelli M, Giannini F, Ballerini M, Ginanneschi F, Martorelli E. Incidence of ulnar neuropathy at the elbow in the province of Siena (Italy). *J Neurol Sci* 2005;234:5–10.
- [101] Mor D, Bembrick AL, Austin PJ, Keay KA. Evidence for cellular injury in the midbrain of rats following chronic constriction injury of the sciatic nerve. *J Chem Neuroanat* 2011;41:158–69.
- [102] Murphy DR, Hurwitz EL, Gerrard JK, Clary R. Pain patterns and descriptions in patients with radicular pain: does the pain necessarily follow a specific dermatome? *Chiropr Osteopat* 2009;17:9.
- [103] Nakamichi KI, Tachibana S. Enlarged median nerve in idiopathic carpal tunnel syndrome. *Muscle Nerve* 2000;23:1713–18.
- [104] Napadow V, Kettner N, Ryan A, Kwong KK, Audette J, Hui KK. Somatosensory cortical plasticity in carpal tunnel syndrome—a cross-sectional fMRI evaluation. *Neuroimage* 2006;31:520–30.
- [105] Napadow V, Kettner N, Liu J, Li M, Kwong KK, Vangel M, Makris N, Audette J, Hui KK. Hypothalamus and amygdala response to acupuncture stimuli in carpal tunnel syndrome. *PAIN* 2007;130:254–66.
- [106] National Guideline Centre. NICE guideline NG59: Low back pain and sciatica in over 16s: assessment and management. London, United Kingdom: National Institute for Health and Care Excellence UK, 2016.
- [107] Neary D. The pathology of ulnar nerve compression in men. *Neuropathol Appl Neurobiol* 1975;1:69–88.
- [108] Nee RJ, Jull GA, Vicenzino B, Coppieters MW. The validity of upper-limb neurodynamic tests for detecting peripheral neuropathic pain. *J Orthop Sports Phys Ther* 2012;42:413–24.
- [109] O'Brien JP, Mackinnon SE, MacLean AR, Hudson AR, Dellon AL, Hunter DA. A model of chronic nerve compression in the rat. *Ann Plast Surg* 1987;19:430–5.
- [110] O'Connor D, Marshall S, Massy-Westropp N. Non-surgical treatment (other than steroid injection) for carpal tunnel syndrome. *Cochrane Database Syst Rev* 2003;2003:CD003219.
- [111] Ortiz-Corredor F, Enriquez F, Diaz-Ruiz J, Calambas N. Natural evolution of carpal tunnel syndrome in untreated patients. *Clin Neurophysiol* 2008;119:1373–8.
- [112] Otoshi K, Kikuchi S, Konno S, Sekiguchi M. The reactions of glial cells and endoneurial macrophages in the dorsal root ganglion and their contribution to pain-related behavior after application of nucleus

- pulposus onto the nerve root in rats. *Spine (Phila Pa 1976)* 2010;35:264–71.
- [113] Page MJ, Massy-Westropp N, O'Connor D, Pitt V. Splinting for carpal tunnel syndrome. *Cochrane Database Syst Rev* 2012;7:CD010003.
- [114] Page MJ, O'Connor D, Pitt V, Massy-Westropp N. Exercise and mobilisation interventions for carpal tunnel syndrome. *Cochrane Database Syst Rev* 2012;6:CD009899.
- [115] Parreira P, Maher CG, Steffens D, Hancock MJ, Ferreira ML. Risk factors for low back pain and sciatica: an umbrella review. *Spine J* 2018;18:1715–21.
- [116] Pinto RZ, Maher CG, Ferreira ML, Ferreira PH, Hancock M, Oliveira VC, McLachlan AJ, Koes B. Drugs for relief of pain in patients with sciatica: systematic review and meta-analysis. *BMJ* 2012;344:e497.
- [117] Pinto RZ, Maher CG, Ferreira ML, Hancock M, Oliveira VC, McLachlan AJ, Koes B, Ferreira PH. Epidural corticosteroid injections in the management of sciatica: a systematic review and meta-analysis. *Ann Intern Med* 2012;157:865–77.
- [118] Pourmemari MH, Shiri R. Diabetes as a risk factor for carpal tunnel syndrome: a systematic review and meta-analysis. *Diabet Med* 2016;33:10–16.
- [119] Rasmussen-Barr E, Held U, Grooten WJ, Roelofs PD, Koes BW, van Tulder MW, Wertli MM. Nonsteroidal anti-inflammatory drugs for sciatica: an updated Cochrane review. *Spine (Phila Pa 1976)* 2017;42:586–94.
- [120] Ridehalgh C, Sandy-Hindmarch OP, Schmid AB. Validity of clinical small-fiber sensory testing to detect small-nerve fiber degeneration. *J Orthop Sports Phys Ther* 2018;48:767–74.
- [121] Roll SC, Case-Smith J, Evans KD. Diagnostic accuracy of ultrasonography vs. electromyography in carpal tunnel syndrome: a systematic review of literature. *Ultrasound Med Biol* 2011;37:1539–53.
- [122] Rothman SM, Winkelstein BA. Chemical and mechanical nerve root insults induce differential behavioral sensitivity and glial activation that are enhanced in combination. *Brain Res* 2007;1181:30–43.
- [123] Rothman SM, Nicholson KJ, Winkelstein BA. Time-dependent mechanics and measures of glial activation and behavioral sensitivity in a rodent model of radiculopathy. *J Neurotrauma* 2010;27:803–14.
- [124] Ryan C, Roberts L. Life on hold: the lived experience of radicular symptoms. A qualitative, interpretative inquiry. *Musculoskelet Sci Pract* 2019;39:51–7.
- [125] Rydevik B, Lundborg G, Bagge U. Effects of graded compression on intraneural blood flow. An in vivo study on rabbit tibial nerve. *J Hand Surg Am* 1981;6:3–12.
- [126] Samuelsson L, Lundin A. Thermal quantitative sensory testing in lumbar disc herniation. *Eur Spine J* 2002;11:71–5.
- [127] Schafer A, Hall T, Muller G, Briffa K. Outcomes differ between subgroups of patients with low back and leg pain following neural manual therapy: a prospective cohort study. *Eur Spine J* 2011;20:482–90.
- [128] Schmid AB, Coppieters MW. Left/right judgment of body parts is selectively impaired in patients with unilateral carpal tunnel syndrome. *Clin J Pain* 2012;28:615–22.
- [129] Schmid AB, Tampin B. Spinally referred back and leg pain. In: *Lumbar spine online textbook*. ISftSotL Spine, 2018. Available at: <http://www.wheelessonline.com/ISSLS/section-10-chapter-10-spinally-referred-back-and-leg-pain/>. Accessed 1 September 2019.
- [130] Schmid AB, Coppieters MW, Ruitenbergh MJ, McLachlan EM. Local and remote immune-mediated inflammation after mild peripheral nerve compression in rats. *J Neuropathol Exp Neurol* 2013;72:662–80.
- [131] Schmid AB, Bland JD, Bhat MA, Bennett DL. The relationship of nerve fibre pathology to sensory function in entrapment neuropathy. *Brain* 2014;137:3186–99.
- [132] Seradge H, Jia YC, Owens W. In vivo measurement of carpal tunnel pressure in the functioning hand. *J Hand Surg Am* 1995;20:855–9.
- [133] Shamji MF, Allen KD, So S, Jang L, Adams SB Jr, Schuh R, Huebner J, Kraus VB, Friedman AH, Setton LA, Richardson WJ. Gait abnormalities and inflammatory cytokines in an autologous nucleus pulposus model of radiculopathy. *Spine (Phila Pa 1976)* 2009;34:648–54.
- [134] Shiri R, Pourmemari MH, Falah-Hassani K, Viikari-Juntura E. The effect of excess body mass on the risk of carpal tunnel syndrome: a meta-analysis of 58 studies. *Obes Rev* 2015;16:1094–104.
- [135] Singh R, Gamble G, Cundy T. Lifetime risk of symptomatic carpal tunnel syndrome in Type 1 diabetes. *Diabet Med* 2005;22:625–30.
- [136] Sirvanci M, Kara B, Duran C, Ozturk E, Karatoprak O, Onat L, Ulusoy OL, Mutlu A. Value of perineural edema/inflammation detected by fat saturation sequences in lumbar magnetic resonance imaging of patients with unilateral sciatica. *Acta Radiol* 2009;50:205–11.
- [137] Solberg TK, Nygaard OP, Sjaavik K, Hofoss D, Ingebrigtsen T. The risk of getting worse after lumbar microdiscectomy. *Eur Spine J* 2005;14:49–54.
- [138] Soon B, Vicenzino B, Schmid AB, Coppieters MW. Facilitatory and inhibitory pain mechanisms are altered in patients with carpal tunnel syndrome. *PLoS One* 2017;12:e0183252.
- [139] Takahashi K, Shima I, Porter RW. Nerve root pressure in lumbar disc herniation. *Spine (Phila Pa 1976)* 1999;24:2003–6.
- [140] Takahata S, Takebayashi T, Terasima Y, Tanimoto K, Wada T, Sohma H, Kokai Y, Yamashita T. Activation of glial cells in the spinal cord of a model of lumbar radiculopathy. *J Orthopaedic Sci* 2011;16:313–20.
- [141] Tamburin S, Cacciatori C, Praitano ML, Cazzaroli C, Foscatto C, Fiaschi A, Zanette G. Median nerve small- and large-fiber damage in carpal tunnel syndrome: a quantitative sensory testing study. *J Pain* 2010;12:205–12.
- [142] Tampin B, Slater H, Hall T, Lee G, Briffa NK. Quantitative sensory testing somatosensory profiles in patients with cervical radiculopathy are distinct from those in patients with nonspecific neck-arm pain. *PAIN* 2012;153:2403–14.
- [143] Tampin B, Briffa NK, Slater H. Self-reported sensory descriptors are associated with quantitative sensory testing parameters in patients with cervical radiculopathy, but not in patients with fibromyalgia. *Eur J Pain* 2013;17:621–33.
- [144] Tampin B, Slater H, Briffa NK. Neuropathic pain components are common in patients with painful cervical radiculopathy, but not in patients with nonspecific neck-arm pain. *Clin J Pain* 2013;29:846–56.
- [145] Tampin B, Slater H, Jacques A, Lind C. Association of quantitative sensory testing parameters with clinical outcome in patients with lumbar radiculopathy undergoing microdiscectomy. *European Journal of Pain* 2020. doi:10.1002/ejp.1586 [Epub ahead of print].
- [146] Tampin B, Vollert J, Schmid AB. Sensory profiles are comparable in patients with distal and proximal entrapment neuropathies, while the pain experience differs. *Curr Med Res Opin* 2018;34:1899–1906.
- [147] Tampin B, Broe RE, Seow LL, George SG, Tan J, Menon R, Jacques A, Slater H. Field testing of the revised neuropathic pain grading system in a cohort of patients with neck and upper limb pain. *Scand J Pain* 2019;19:523–32.
- [148] Tampin B, Royle J, Bharat C, Trevenen M, Olsen L, Goucke R. Psychological factors can cause false pain classification on painDETECT. *Scand J Pain* 2019;19:501–12.
- [149] Tampin B. Integration of peripheral nerves in the examination of the locomotor system. In: Hueter-Becker A, Doelken M, editors. *Physical therapy examination and assessment*. Stuttgart: Thieme, 2015. p. 76–104.
- [150] Tecchio F, Padua L, Aprile I, Rossini PM. Carpal tunnel syndrome modifies sensory hand cortical somatotopy: a MEG study. *Hum Brain Mapp* 2002;17:28–36.
- [151] Thacker MA, Clark AK, Marchand F, McMahon SB. Pathophysiology of peripheral neuropathic pain: immune cells and molecules. *Anesth Analg* 2007;105:838–47.
- [152] The Royal College of Surgeons of England and British Orthopaedic Association. *Commissioning guide: Treatment of carpal tunnel syndrome*. London, United Kingdom. 2017.
- [153] Thoomes EJ, van Geest S, van der Windt DA, Falla D, Verhagen AP, Koes BW, Thoomes-de Graaf M, Kuijper B, Scholten-Peeters WGM, Vleggeert-Lankamp CL. Value of physical tests in diagnosing cervical radiculopathy: a systematic review. *Spine J* 2018;18:179–89.
- [154] Tousignant-Laflamme Y, Martel MO, Joshi AB, Cook CE. Rehabilitation management of low back pain—it's time to pull it all together! *J Pain Res* 2017;10:2373–85.
- [155] Tschugg A, Lener S, Hartmann S, Neururer S, Wildauer M, Thome C, Loscher WN. Improvement of sensory function after sequestrectomy for lumbar disc herniation: a prospective clinical study using quantitative sensory testing. *Eur Spine J* 2016;25:3543–9.
- [156] Tubach F, Beaute J, Leclerc A. Natural history and prognostic indicators of sciatica. *J Clin Epidemiol* 2004;57:174–9.
- [157] van der Heide B, Bourgoin C, Eils G, Garnevall B, Blackmore M. Test-retest reliability and face validity of a modified neural tissue provocation test in patients with cervicobrachial pain syndrome. *J Man Manipulative Ther* 2006;14:30–6.
- [158] van Paassen BW, van der Kooij AJ, van Spaendonck-Zwarts KY, Verhamme C, Baas F, de Visser M. PMP22 related neuropathies: charcot-Marie-Tooth disease type 1A and hereditary neuropathy with liability to pressure palsies. *Orphanet J Rare Dis* 2014;9:38.
- [159] van Rijn JC, Klemetso N, Reitsma JB, Majoie CB, Hulsmans FJ, Peul WC, Bossuyt PM, Heeten GJ, Stam J. Symptomatic and asymptomatic abnormalities in patients with lumbosacral radicular syndrome: clinical examination compared with MRI. *Clin Neurol Neurosurg* 2006;108:553–7.

- [160] Vasiliadis HS, Georgoulas P, Shrier I, Salanti G, Scholten RJ. Endoscopic release for carpal tunnel syndrome. *Cochrane Database Syst Rev* 2014;CD008265.
- [161] Vroomen PC, de Krom MC, Slofstra PD, Knottnerus JA. Conservative treatment of sciatica: a systematic review. *J Spinal Disord* 2000;13:463–9.
- [162] Wang YF, Chen PY, Chang W, Zhu FQ, Xu LL, Wang SL, Chang LY, Luo J, Liu GJ. Clinical significance of tumor necrosis factor-alpha inhibitors in the treatment of sciatica: a systematic review and meta-analysis. *PLoS One* 2014;9:e103147.
- [163] Watkins LR, Maier SF. Beyond neurons: evidence that immune and glial cells contribute to pathological pain states. *Physiol Rev* 2002;82:981–1011.
- [164] Weber H, Holme I, Amlie E. The natural course of acute sciatica with nerve root symptoms in a double-blind placebo-controlled trial evaluating the effect of piroxicam. *Spine (Phila Pa 1976)* 1993;18:1433–8.
- [165] Wiberg A, Ng M, Schmid AB, Smillie RW, Baskozos G, Holmes MV, Kunnapuu K, Magi R, Bennett DL, Furniss D. A genome-wide association analysis identifies 16 novel susceptibility loci for carpal tunnel syndrome. *Nat Commun* 2019;10:1030.
- [166] Wieseler-Frank J, Maier SF, Watkins LR. Immune-to-brain communication dynamically modulates pain: physiological and pathological consequences. *Brain Behav Immun* 2005;19:104–11.
- [167] Wilder-Smith EP, Fook-Chong S, Chew SE, Chow A, Guo Y. Vasomotor dysfunction in carpal tunnel syndrome. *Muscle Nerve* 2003;28:582–6.
- [168] Wilson CA, Roffey DM, Chow D, Alkherayf F, Wai EK. A systematic review of preoperative predictors for postoperative clinical outcomes following lumbar discectomy. *Spine J* 2016;16:1413–22.
- [169] Yoon JS, Walker FO, Cartwright MS. Ulnar neuropathy with normal electrodiagnosis and abnormal nerve ultrasound. *Arch Phys Med Rehabil* 2010;91:318–20.
- [170] Yoshii Y, Nishiura Y, Terui N, Hara Y, Saijilafu ON. The effects of repetitive compression on nerve conduction and blood flow in the rabbit sciatic nerve. *J Hand Surg Eur* 2010;35:269–78.
- [171] Zanette G, Marani S, Tamburin S. Extra-median spread of sensory symptoms in carpal tunnel syndrome suggests the presence of pain-related mechanisms. *PAIN* 2006;122:264–70.
- [172] Zanette G, Cacciatori C, Tamburin S. Central sensitization in carpal tunnel syndrome with extraterritorial spread of sensory symptoms. *PAIN* 2010;148:227–36.
- [173] Zhu GC, Bottger K, Slater H, Cook C, Farrell SF, Hailey L, Tampin B, Schmid AB. Concurrent validity of a low-cost and time-efficient clinical sensory test battery to evaluate somatosensory dysfunction. *Eur J Pain* 2019;23:1826–38.
- [174] Zyluk A, Kosowicz L. Regional sympathetic disturbances in carpal tunnel syndrome—a review [in Polish]. *Chir Narzadow Ruchu Ortop Pol* 2008;73:30–6.