

## Autonomic neurocardiogenic syndrome is stonewalled by the universal definition of myocardial infarction

Shams Y-Hassan

**ORCID number:** Shams Y-Hassan (0000-0001-5228-9035).

**Author contributions:** Y-Hassan S designed, edited, and wrote the paper.

**Conflict-of-interest statement:** Authors declare no conflict of interests for this article.

**Open-Access:** This article is an open-access article that was selected by an in-house editor and fully peer-reviewed by external reviewers. It is distributed in accordance with the Creative Commons Attribution NonCommercial (CC BY-NC 4.0) license, which permits others to distribute, remix, adapt, build upon this work non-commercially, and license their derivative works on different terms, provided the original work is properly cited and the use is non-commercial. See: <http://creativecommons.org/licenses/by-nc/4.0/>

**Manuscript source:** Invited manuscript

**Received:** October 30, 2019

**Peer-review started:** October 30, 2019

**First decision:** December 12, 2019

**Revised:** April 27, 2020

**Accepted:** May 14, 2020

**Article in press:** May 14, 2020

**Published online:** June 26, 2020

**P-Reviewer:** Zingarelli A

**S-Editor:** Wang J

**L-Editor:** A

**E-Editor:** Qi LL

**Shams Y-Hassan**, Coronary Artery Disease Area, Heart and Vascular Theme, Karolinska Institutet and Karolinska University Hospital, Stockholm S-141 86, Sweden

**Corresponding author:** Shams Y-Hassan, MBChB, MD, Doctor, Research Scientist, Cardiologist senior consultant, Coronary Artery Disease Area, Heart and Vascular Theme, Karolinska Institutet and Karolinska University Hospital, SE171 76, Stockholm S-141 86, Stockholm, Sweden. [shams.younis-hassan@sll.se](mailto:shams.younis-hassan@sll.se)

### Abstract

Myocardial infarction (MI) is defined as myocardial cell death due to prolonged myocardial ischemia. Clinically, troponin rise and/or fall have become the “defining feature of MI” according to the universal definition of MI (UD-MI). Takotsubo syndrome (TS) and TS-related disease conditions also cause troponin elevation with typical rise and/or fall pattern but through a mechanism other than coronary ischemia. By strict application of the clinical diagnostic criteria for type-1 MI, type-2 MI, type-3 MI, and MI with non-obstructive coronary arteries according to the UD-MI including the fourth one published recently, TS and most of the 26 other causes of troponin elevation mentioned in the fourth UD-MI may erroneously be classified as MI. The existing evidence argues for the case that TS by itself is not a MI. Hyper-activation of the autonomic-sympathetic nervous system including local cardiac sympathetic hyper-activation and disruption with nor-epinephrine churn and spillover is the most probable cause of TS. This autonomic neuro-cardiogenic (ANCA) mechanism results in myocardial “cramp” (stunning), the severity and duration of which depend on the degree of the sympathetic-hyperactivation and nor-epinephrine spillover. The myocardial cramp may squeeze the cytosolic free troponin pools causing mild to moderate troponin elevation in TS and TS-related disease conditions. This ANCA syndrome, which has hitherto been enveloped by the UD-MI over more than one decade, may occur in acute, recurrent, and chronic forms. In this critical review, the controversies of UD-MI, evidence for ANCA syndrome, and a hypothetical mechanism for the troponin elevation in ANCA syndrome are provided.

**Key words:** Universal definition; Myocardial infarction; Takotsubo; Myocardial stunning; Cardiac cramp; Autonomic neurocardiogenic syndrome; Heart failure; Chronic kidney diseases

©The Author(s) 2020. Published by Baishideng Publishing Group Inc. All rights reserved.

**Core tip:** The fourth universal definition of myocardial infarction (MI) needs



reconsideration. Type 2 MI and MI with non-obstructive coronary arteries are not evidence-based. Autonomic neuro-cardiogenic (ANCA) syndrome is the second important cause of troponin elevation after acute coronary ischemia. Troponin release in ANCA syndrome is most probably due to cardiac cramp squeezing the cardiomyocyte causing mild to moderate release of troponin from the cytosolic free pool. ANCA syndrome may occur in an acute form as in takotsubo syndrome. The syndrome may also occur in recurrent or a chronic form as in chronic heart failure with acute exacerbations, and chronic kidney diseases.

**Citation:** Y-Hassan S. Autonomic neurocardiogenic syndrome is stonewalled by the universal definition of myocardial infarction. *World J Cardiol* 2020; 12(6): 231-247

**URL:** <https://www.wjgnet.com/1949-8462/full/v12/i6/231.htm>

**DOI:** <https://dx.doi.org/10.4330/wjc.v12.i6.231>

## INTRODUCTION

Myocardial infarction (MI) is defined as myocardial cell necrosis due to protracted myocardial ischemia. Cardiac troponin (cTn) rise and/or fall have been regarded as the “defining feature of MI” according to the universal definition of MI (UD-MI). The fourth UD-MI classified non-procedure-related MI into type-1 MI (T1MI), type-2 MI (T2MI), and type-3 MI (T3MI)<sup>[1]</sup>. In addition, the term MI with non-obstructive coronary arteries (MINOCA) has been introduced to include patients from both T1MI and T2MI<sup>[1]</sup> and other causes of troponin elevations with non-obstructive coronary arteries. Regrettably; no efforts have been made to elucidate mechanisms other than ischemic causes of cTn elevation. Almost all cTn elevations have been described as MI as seen in T1MI, T2MI, T3MI, and MINOCA. Moreover, the definitions and the criteria of different types of MI are full of controversies. By strict application of the clinical criteria for the 3 types of MI (Table 1), most of the patients who suffer takotsubo syndrome (TS), TS-related disease conditions (described below) and even other non-ischemic conditions as myocarditis will be incorrectly diagnosed as MI. Most of the researchers agree that TS is not an ischemic heart disease<sup>[2,3]</sup>. Even the authors of the fourth UD-MI acknowledge that not all patients included in different types of MI have ischemic heart disease<sup>[1]</sup>. Consequently, it is justified to raise the question, whether all the non-ischemic causes of cTn elevations should be classified as MI? In this critical review, the controversies of the UD-MI and the confusions, which the terms T1MI, T2MI, T3MI, and MINOCA have caused, are explained. In addition, substantial evidences for the autonomic neuro-cardiogenic (ANCA) involvement and the mechanism by which it causes cTn elevation in TS and TS-related disease conditions is highlighted. Evidence for the contention that the ANCA syndrome may occur in acute form as TS and TS-related conditions and in recurrent or chronic forms as in undiagnosed pheochromocytoma, chronic heart failure (CHF) with acute exacerbations, and chronic kidney diseases (CKD) is also provided.

## CONTROVERSIES OF THE FOURTH UNIVERSAL DEFINITION OF MYOCARDIAL INFARCTION

According to the fourth UD-MI, the pathogenesis of T1MI is coronary plaque rupture/erosion with occlusive or non-occlusive thrombus<sup>[1]</sup>. This implies that invasive coronary angiography (CAG) and in some cases intravascular imaging such as intravascular ultrasound or optical coherence tomography should be performed to confirm the diagnosis of T1MI. Strangely, the clinical diagnostic criteria of T1MI in the fourth UD-MI do not mandate invasive CAG (or, as an alternative, non-invasive coronary computed tomography angiography) in all cases (Table 1). This is clear from registry studies, which strictly adhere to the use of the UD-MI. In a study by Baron *et al*<sup>[4]</sup>, 12841 (24.1%) of 53342 classified as T1MI were treated conservatively without performing CAG. How could the authors be convinced of plaque rupture with occlusive or non-occlusive thrombus in such huge numbers of patients when invasive CAG, intravascular ultrasound or optical coherence tomography were not performed, and when TS has an almost identical clinical presentation as that of T1MI<sup>[2,5,6]</sup>? In addition, according to the fourth UD-MI, the pathogenesis of T2MI is due to

**Table 1 Diagnostic criteria for type 1, type 2, and type 3 myocardial infarction according to the fourth universal definition of myocardial infarction**

Criteria for type 1 MI, type 2 MI, type 3 MI according to the fourth universal definition of myocardial infarction <sup>[1]</sup>
<p><b>Type 1 MI</b></p> <p>Detection of a rise and/or fall of cTn values with at least one value above the 99<sup>th</sup> percentile URL and with at least one of the following:</p> <ul style="list-style-type: none"> <li>Symptoms of acute myocardial ischaemia</li> <li>New ischaemic ECG changes</li> <li>Development of pathological Q waves</li> <li>Imaging evidence of new loss of viable myocardium or new regional wall motion abnormality in a pattern consistent with an ischemic etiology</li> <li>Identification of a coronary thrombus by angiography including intracoronary imaging or by autopsy</li> </ul>
<p><b>Type 2 MI</b></p> <p>Detection of a rise and/or fall of cTn values with at least one value above the 99<sup>th</sup> percentile URL, and evidence of an imbalance between myocardial oxygen supply and demand unrelated to coronary thrombosis, requiring at least one of the following:</p> <ul style="list-style-type: none"> <li>Symptoms of acute myocardial ischaemia</li> <li>New ischaemic ECG changes</li> <li>Development of pathological Q waves</li> <li>Imaging evidence of new loss of viable myocardium or new regional wall motion abnormality in a pattern consistent with an ischaemic aetiology</li> </ul>
<p><b>Type 3 MI</b></p> <p>Patients who suffer cardiac death, with symptoms suggestive of myocardial ischaemia accompanied by presumed new ischemic ECG changes or ventricular fibrillation but die before blood samples for biomarkers can be obtained, or before increases in cardiac biomarkers can be identified, or MI is detected by autopsy examination</p>

MI: Myocardial infarction; ECG: Electrocardiogram; cTn: Cardiac troponin; URL: Upper reference limit.

imbalance between myocardial oxygen supply and demand unrelated to coronary thrombosis<sup>[1]</sup>. The diagnosis of supply and/or demand imbalance is a very subjective one and based rather on guesswork than on scientific evidence and hitherto this hypothesis has not been confirmed. Furthermore, after so many years, the investigators of UD-MI have not been able to confirm MI by endomyocardial biopsy or cardiac magnetic resonance (CMR) imaging in most of the patients deemed to have T2MI<sup>[7]</sup>. The highly varied reported incidence of "T2MI" across the studies from 1.6% to 29.6% is an indication for that not all clinicians believe in this diagnosis<sup>[7,8]</sup>. T2MI is really a figment of imagination. By the strict application of the criteria for both "T1MI" and "T2MI", the diagnosis of TS and other non-ischemic causes of troponin elevation would almost disappear<sup>[8]</sup>. Interestingly, even some co-authors of the fourth UD-MI agree entirely with the above-mentioned controversies and confusion, which T2MI have caused. Collinson and Lindahl<sup>[7]</sup> also believe that the term T2MI is confusing and not evidence-based. They have appropriately described T2MI as the "chimera of cardiology". Moreover, the authors have stated that "T2MI has always been defined by what it is not rather than what it is", and that "T2MI as defined according to the UD-MI is a mixed bag of patients, in whom the pathophysiology is different and, in fact in many cases, is unknown". They have concluded that "T2MI should be abandoned and replaced with secondary "myocardial injury"<sup>[7]</sup>; it is perhaps worth to mention, that secondary myocardial injury is also not appropriate

The fourth UD-MI has also introduced the term MINOCA, which might have aggravated the state of confusion for all these types of MI. According to the European society of cardiology (ESC) position paper<sup>[3]</sup> (Table 2), the most common causes of MINOCA are plaque rupture or erosion, coronary artery spasm, thrombo-embolism, spontaneous coronary artery dissection (SCAD), TS, unrecognized myocarditis, and other forms of T2MI (Table 2). In principle, this implies that almost all the conditions causing troponin elevation and included in MINOCA are regarded as MI, because the MI in MINOCA stands for myocardial infarction. Despite all the criteria, the definition, and causes of MINOCA (Table 2), the authors of the ESC position paper acknowledge that cardiac troponin is "organ specific" and not "disease specific" and that elevated cardiac troponin is not necessarily indicative of acute MI but reflects "myocardial injury". Interestingly, in 2013 when John F Beltrame<sup>[9]</sup> introduced the term MINOCA instead of myocardial infarction with normal coronary arteries, he stated that an important first step in the assessment of patients with apparent MINOCA is to exclude the causes of non-ischemic of troponin elevations such as pulmonary embolism, acute or chronic renal failure, acute on chronic heart failure, myocarditis, "cardiomyopathies" (infiltrative, takotsubo, and peripartum), stroke, septic shock, acute respiratory distress syndrome, acute trauma (including iatrogenic),

severe burns, chemotherapeutic agents and strenuous exercise. This contrasts the ESC reported causes of MINOCA<sup>[3]</sup>.

Furthermore, most of the MINOCA patients who were investigated by CMR imaging have shown no signs of MI. Collste *et al*<sup>[10]</sup> reported normal CMR imaging in 102 of 152 patients (67%) with myocardial infarction with normal coronary arteries. Bière *et al*<sup>[11]</sup> reported on CMR imaging findings in 131 patients with MINOCA. There was late gadolinium enhancement (LGE) consistent with MI in only 34 patients (26%). LGE consistent with myocarditis in 47 patients (36%) and there was no LGE in 50 patients (38%). Interestingly, 20 patients with TS were excluded in that study. If TS patients would have been included in that study, only 22.5% of patients with MINOCA in that study would have MI; 77.5% had not MI. In a review of 16 CMR studies (CMR undertaken within 6 wk) in patients with MINOCA, Pasupathy *et al*<sup>[12]</sup> reported CMR findings of MI in 24%, myocarditis in 38%, TS in 16% and no significant abnormality in 21%. Consequently 76% of patients with MINOCA had no MI. Recently, Hausvater *et al*<sup>[13]</sup> reported on 292 patients with MINOCA pooled from three prospective cohort studies and found that 81% of patients had no CMR signs of MI. All these studies confirm that most patients included in MINOCA have no MI.

Interestingly, most of the patients who fulfill the criteria of “NOCA in MINOCA” have no MI<sup>[13]</sup> and some of those who fulfill the criteria of “MI in MINOCA” have obstructive coronary arteries (OCA) and not NOCA<sup>[14]</sup>. One real example for such controversy and the confusion which MINOCA causes is elaborated in [Figure 1](#) and [2](#). TS and SCAD are 2 conditions among the causes of MINOCA according to the ESC position paper. Most of the patients with pure TS have no MI but have “NOCA” as in [Figure 1](#). The reverse is true in patients with SCAD where most of the patients with SCAD have MI and have obstructive coronary artery disease (CAD), consequently no “NOCA” as illustrated in [Figure 2](#). Why should TS be included under MINOCA when TS per se is not a MI?<sup>[2,6]</sup> Or why should SCAD be included under MINOCA whilst most of the cases with SCAD have obstructive CAD<sup>[15,16]</sup>? In VIRGO study<sup>[17]</sup>, 61 of 299 (20%) MINOCA patients had SCAD where 51% of SCAD patients had ST-elevation MI (STEMI) ECG changes, which also indicates OCA and not NOCA. In a recent large study, 29.7% of 750 patients with SCAD had STEMI, which usually indicate a total coronary occlusion due to SCAD<sup>[14]</sup>. In the same study, the median angiographic stenosis in patients with SCAD was 79.0% (65%-100%)<sup>[14]</sup>. The most probable explanation for the classification of SCAD patients under MINOCA is that the diagnosis of SCAD is frequently missed by coronary interventionalists<sup>[15]</sup>. In conclusion almost 80% of patients in different MINOCA studies have no MI, and half of patients with MI have OCA and not NOCA; consequently only 10% of patients included in MINOCA studies fulfill the criteria of both MI and NOCA.

## OTHER ESSENTIAL FINDINGS IN PATIENTS CLASSIFIED AS T2MI AND MINOCA ARGUING AGAINST MI

Patients with “T2MI” and MINOCA are predominantly women, have more comorbidities, show smaller extent of “myocardial necrosis” and more normal coronary arteries<sup>[1,3,18]</sup>. These findings are also characteristic features encountered in patients with TS<sup>[2,6]</sup>. Recently, Nordenskjöld *et al*<sup>[19]</sup> in a study on MINOCA patients reported that lower level of total cholesterol was among the independent predictors for significant increase in major adverse cardiovascular events and long-term mortality. This finding contrasts the known confirmed evidence in large studies that the hypercholesterolemia is an important risk factor for coronary artery disease and that lowering of total cholesterol and LDL reduces the cardiovascular risk in both primary and secondary settings. Because of this, the authors used the term “cholesterol paradox” in MINOCA patients. One conceivable explanation for the “cholesterol paradox” may be the associated co-morbidities such as malignancy and chronic critical illnesses which may act as predisposing factors for TS and that these chronic co-morbidities may explain the lower cholesterol as well as the increased major adverse cardiovascular events and mortality in MINOCA patients. Consequently, the cholesterol paradox in MINOCA patients argues against MI in MINOCA patients. The same group of investigators<sup>[20]</sup> reported on the medical therapy for secondary prevention and long-term outcome in patients with MINOCA and found a neutral effect of dual anti-platelet therapy, arguing against an athero-thrombotic coronary cause of MINOCA. Despite mild-moderate troponin elevation in T2MI and MINOCA, the mortality in T2MI is significantly higher than T1MI during a mean follow up period of 3.2 years in one study<sup>[21]</sup>. The high mortality in that study was attributed mainly to the non-cardiovascular causes of death<sup>[21]</sup>. Furthermore, most of the patients with T2MI or MINOCA have no MI on CMR imaging<sup>[10-13,22]</sup>.



**Table 2 Diagnostic criteria and causes of myocardial infarction with non-obstructive coronary arteries****Diagnostic criteria and causes for myocardial infarction with non-obstructive coronary arteries according to the ESC working group position paper<sup>[3]</sup>****Diagnostic criteria:**

The diagnosis of MINOCA is made immediately upon coronary angiography in a patient presenting with features consistent with an acute myocardial infarction, as detailed by the following criteria:

## (1) AMI criteria

(a) Positive cardiac biomarker (preferably cardiac troponin) defined as a rise and/or fall in serial levels, with at least one value above the 99th percentile upper reference limit

(b) Corroborative clinical evidence of infarction evidenced by at least one of the following:

Symptoms of ischaemia

New or presumed new significant ST-T changes or new LBBB

Development of pathological Q waves

Imaging evidence of new loss of viable myocardium or new RWMA

Intracoronary thrombus evident on angiography or at autopsy

## (2) Non-obstructive coronary arteries on angiography:

Defined as the absence of obstructive CAD on angiography, (*i.e.* no coronary artery stenosis  $\geq$  50%), in any potential infarct-related artery. This includes both patients with:

This includes both patients with:

Normal coronary arteries (no stenosis  $<$  30%)

Mild coronary atheromatosis (stenosis  $>$  30% but  $<$  50%).

No clinically overt specific cause for the acute presentation:

At the time of angiography, the cause and thus a specific diagnosis for the clinical presentation is not apparent

Accordingly, there is a necessity to further evaluate the patient for the underlying cause of the MINOCA presentation

**Causes**

Plaque rupture or erosion

Coronary artery spasm

Thromboembolism

Coronary dissection

Takotsubo syndrome

Unrecognized myocarditis, and

Other forms of type-2 myocardial infarction

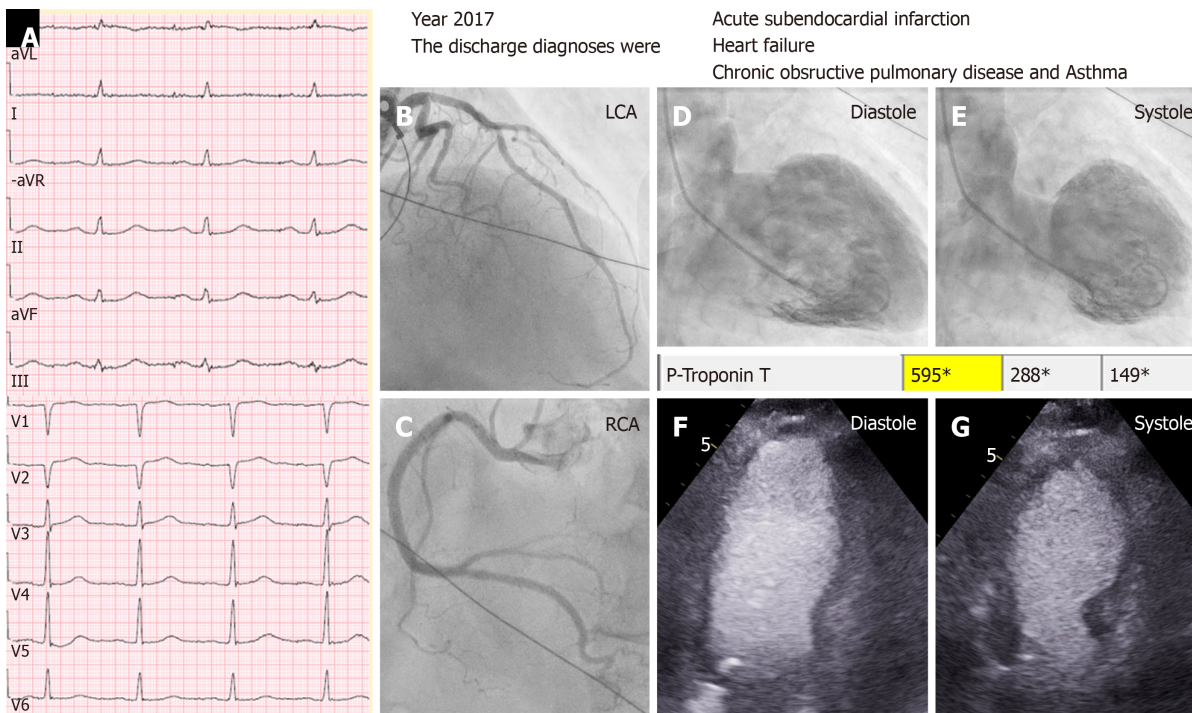
CAD: Coronary artery disease; ESC: European society of cardiology; MINOCA: Non-obstructive coronary arteries; RWMA: Regional wall motion abnormality; LBBB: Left bundle branch block; AMI: Acute myocardial infarction.

## EVIDENCE FOR THE AUTONOMIC NEUROCARDIOGENIC (ANCA) SYNDROME AND ITS ROLE IN CAUSING TROPONIN ELEVATION

Signs of hyperactivation of sympathetic nervous system and cardiac sympathetic disruption has been reported in different cardiac diseases as CHF, CKD complicated by heart failure, and TS. ANCA syndrome is a continuum of syndromes with a constellation of clinical presentation, repolarization ECG changes, troponin elevation, left ventricular wall motion abnormality (LVWMA), and histopathological findings. TS has played a pivotal role and has paved the path to an understanding of this broad continuum of ANCA manifestation, which may occur in acute, recurrent and chronic forms. The evidence for that is discussed below.

## TAKOTSUBO SYNDROME

TS, also known as neurogenic stunned myocardium, is now a recognized acute cardiac disease entity<sup>[2,5]</sup>. The term takotsubo (tako = octopus, tsubo = a pot) was introduced by Sato and Dote in 1990 and 1991 to describe the left ventricular silhouette during systole in patients with clinical features of MI but no obstructive coronary artery disease<sup>[23,24]</sup>. This acute syndrome has clinical and electrocardiographic features resembling that of an acute coronary syndrome (ACS). The main defining feature of TS is the regional LVWMA with a unique circumferential pattern resulting



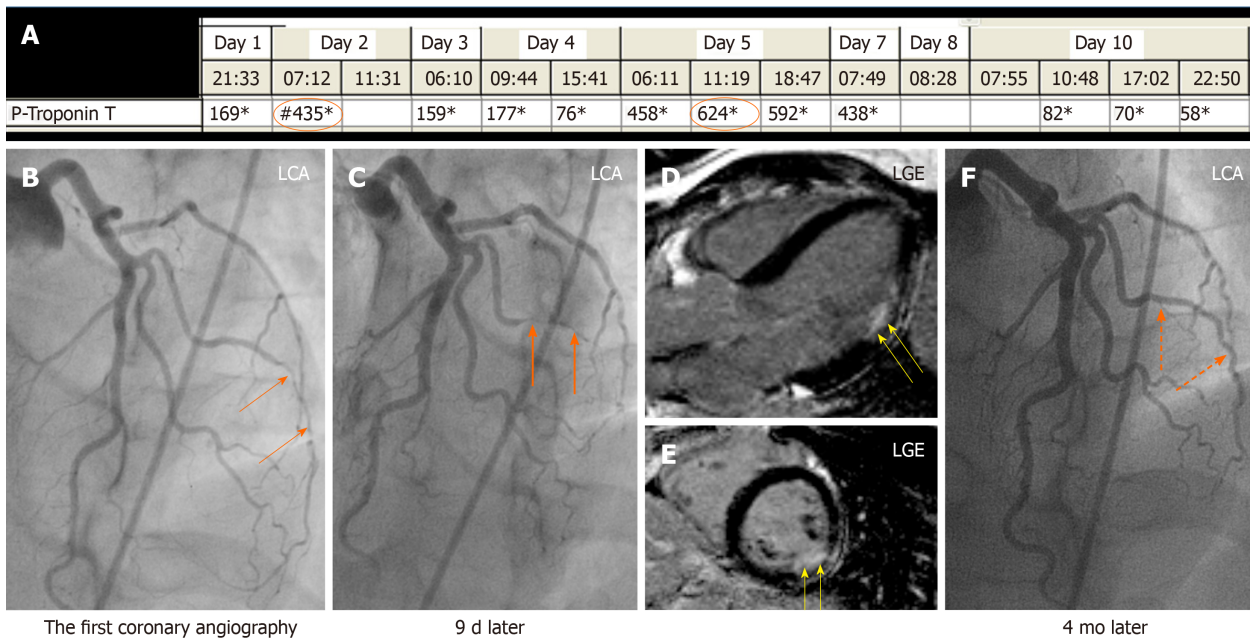
**Figure 1** A case of midventricular takotsubo syndrome discharged under diagnosis of myocardial infarction. A typical mid-ventricular takotsubo syndrome triggered by an emotional stress in a 79-years-old man with chronic co-morbidities in the form of chronic obstructive pulmonary disease and carcinoma of urinary bladder. The case was incorrectly diagnosed as type 2 myocardial infarction according to the universal definition of myocardial infarction as seen in the discharge diagnosis. A: Electrocardiogram during admission; B: Left coronary artery shows moderate stenosis in the left anterior descending artery, which cannot explain the circumferential mid-ventricular left ventricular wall motion abnormality; C: Normal right coronary artery (RCA); D and E: Contrast left ventriculography during diastole and systole showing mid-ventricular ballooning pattern. There was modest elevation of troponin T (595 ng/L); F and G: Echocardiography during diastole and systole confirming the left ventriculography finding of mid-ventricular ballooning.

in a conspicuous ballooning of the left ventricle during systole<sup>[2,6]</sup>. The LVWMA extends beyond the coronary artery supply regions and is transient with almost complete resolution of ventricular dysfunction in hours to weeks<sup>[2,6]</sup>. The LVWMA may be localized to the apical, mid-apical, mid-ventricular, basal or mid-basal segments of the left ventricle<sup>[5]</sup>. Focal and global LVWMA has also been reported<sup>[25-27]</sup>. The right ventricle may be involved in about 30% of the patients with TS<sup>[28]</sup>. The syndrome is preceded by a trigger factor in more than two thirds of patients<sup>[25]</sup>. Emotional trigger factors as death of a close relative or acute grief may trigger the syndrome and hence the term broken heart syndrome<sup>[29]</sup>. Myriads of physical triggers (Figure 3), extending from serious diseases as acute sepsis, subarachnoid hemorrhages to the most physiological processes as pregnancy and sexual intercourse, may also trigger the syndrome<sup>[30,31]</sup>.

TS is a typical example of a disease entity causing troponin elevation with a typical rise and/or fall pattern as that of MI but is not a MI by itself. However, the existing criteria for “T1MI, T2MI, T3MI, and MINOCA” (Tables 1 and 2) may submerge and classify TS as a MI as illustrated in Figure 1. This is also applied on patients with TS-related syndromes *i.e.*, syndrome which have the same pathogenesis of TS described below.

## EVIDENCE FOR THAT TAKOTSUBO SYNDROME IS NOT A MI

TS has a clinical presentation, electrocardiographic changes and troponin elevation pattern like that of an ACS. However, invasive CAG is normal in most cases of TS<sup>[2,32]</sup>. Cardiac image studies (echocardiography, contrast left ventriculography, and CMR imaging) usually disclose LVWMA which extends beyond the coronary artery supply territory especially when the LVWMA involves only the mid-ventricular segments or the basal segments<sup>[5]</sup>. There is great discrepancy between the extensive LVWMA and the modest troponin elevations, which argues against significant necrosis seen in MI<sup>[6]</sup>. The CMR imaging may also show edema corresponding to the segments with LVWMA but there is no late gadolinium enhancement (LGE) in most of the cases, a



**Figure 2** A case of obstructive coronary artery disease due to spontaneous coronary artery dissection. A 35-years-old female patient with a spontaneous coronary artery dissection (SCAD) of the diagonal artery with documented myocardial infarction (MI) by cardiac magnetic resonance imaging and obstructive coronary artery stenosis. A: Recurrent troponin elevation with a rise and/or fall pattern (orange circles); B: A diagonal artery with a peripheral stenosis (thin orange arrows); C: Proximal propagation of diagonal artery narrowing during repeated left coronary artery angiography 9 d later (thick orange arrows); D and E: Cardiac magnetic resonance imaging shows MI corresponding to the diagonal artery supply territory (yellow arrows); F: Follow up left coronary artery angiography 4 mo later reveals complete resolution of the diagonal artery lesion consistent with SCAD (broken orange arrows). Consequently, this patient has documented MI caused by obstructive coronary artery disease due to SCAD. LGE: Late gadolinium enhancement; LGA: Left coronary artery.

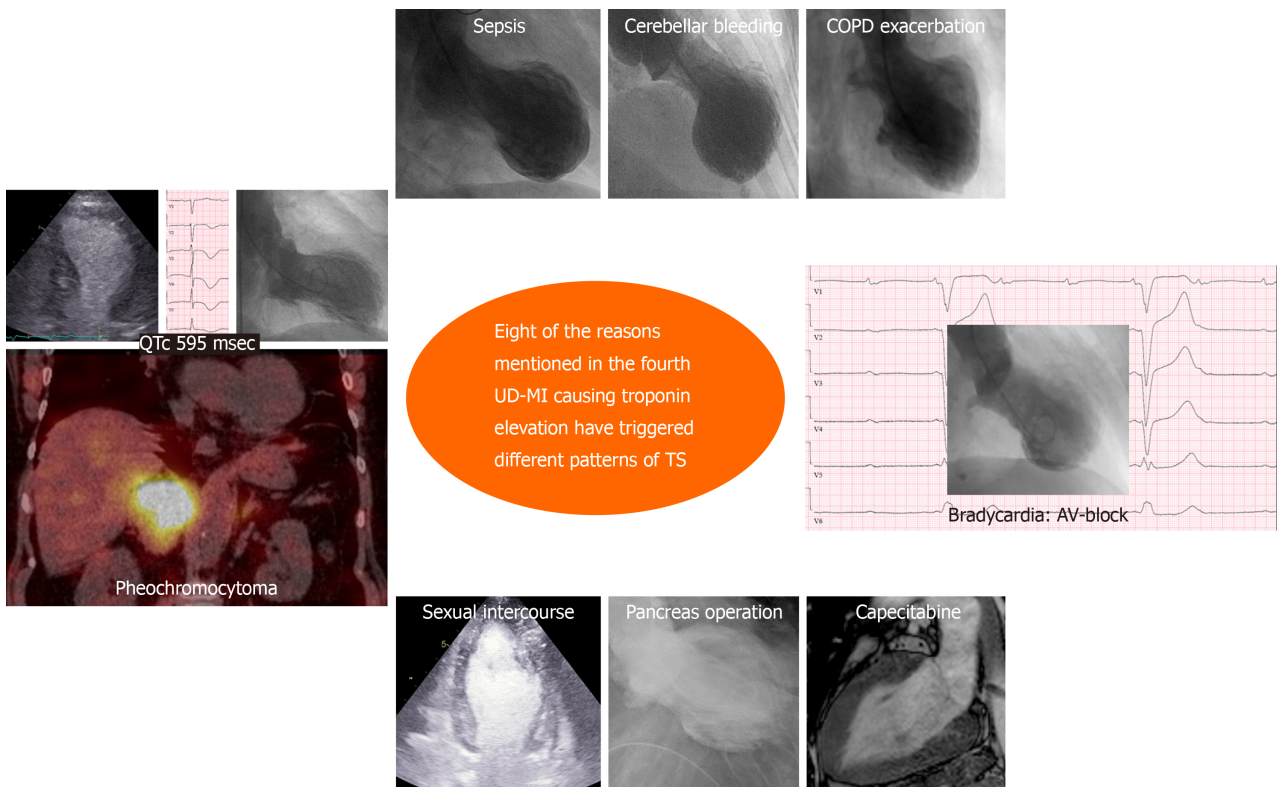
finding argues against MI<sup>[5]</sup>. CMR imaging, if done early during TS, may reveal LGE in the affected hypokinetic segments in about one third of cases<sup>[33]</sup>. However, the signal intensity of LGE in TS is less than that of MI and myocarditis and the LGE is patchy in appearance and in some cases described as myocarditis<sup>[34,35]</sup>; chemical (neuro-mediated by norepinephrine) myocarditis may be a feature of TS<sup>[36]</sup> and may explain the patchy LGE findings in TS; it is usually reversible (neurogenic stunning). Moreover, the most important sign, which challenges MI in TS, is the histopathological finding of contraction band necrosis, which is distinct from coagulation necrosis seen in MI<sup>[37]</sup>.

However, one confounding factor is that ACS irrespective of its cause (atherothrombotic coronary artery disease, SCAD, coronary spasm, or coronary embolism) as any other physical stress may also trigger TS<sup>[38]</sup>. Furthermore, TS may also be complicated by acute MI due to coronary embolism secondary to left ventricular thrombus, which may itself be a complication of TS<sup>[39]</sup>. In such cases, the patients will have features of both MI and TS<sup>[39]</sup>.

## OTHER DISEASE CONDITIONS INVOLVED IN TROPONIN ELEVATION

Apart from the atherosclerotic plaque disruption with thrombosis as a cause of troponin elevations, 26 other disease conditions mentioned in the fourth UD-MI may cause troponin elevation<sup>[1]</sup>. The list may be longer if other causes of troponin elevations are added such as pheochromocytoma and paraganglioma<sup>[31,40]</sup>. TS is mentioned as only one of the 26 disease conditions, which may cause troponin elevation. However, with critical analysis, most of the remaining 25 other mentioned conditions causing troponin elevations may act or have been reported as a trigger factor for TS as sepsis and infectious diseases<sup>[41]</sup>, stroke and subarachnoid hemorrhage<sup>[42]</sup>, chemotherapeutic agents<sup>[26]</sup>, acute critical diseases<sup>[43]</sup>, strenuous exercise, pulmonary embolism, coronary spasm, acute coronary syndrome including SCAD<sup>[2,32,38]</sup>, chronic obstructive pulmonary disease with acute exacerbation, bradycardia and AV-block, and many others<sup>[2,32]</sup>; an example for that is given in figure 3. Some other conditions mentioned causing troponin elevation may be a complication of TS as coronary embolism, brady-arrhythmias, tachy-arrhythmias, hypotension and shock<sup>[2,32,39]</sup>. Consequently, it would be reasonable to conclude that





**Figure 3** Eight clinical conditions causing troponin elevation have triggered different patterns of takotsubo syndrome. Most of the reasons for troponin elevation mentioned in the fourth universal definition of myocardial infarction have been reported to trigger takotsubo syndrome. In this figure, 8 of the mentioned reasons (pheochromocytoma, sepsis, cerebellar bleeding, chronic obstructive pulmonary disease with acute exacerbation, heart block, capecitabine, pancreas operation, and strenuous physical exercise in the form of sexual intercourse) triggering different ballooning’s pattern of takotsubo syndrome are demonstrated.

most of the disease conditions mentioned that cause troponin elevation is directly or indirectly associated to TS or TS-related syndromes discussed below. The mechanism of troponin elevation will be the same as that of TS<sup>[5,44,45]</sup>.

### TS-RELATED DISEASE CONDITIONS

In addition to the distinctive circumferential LVWMA, TS have also other characteristic features namely: The repolarization ECG changes<sup>[46]</sup>; modest troponin elevation with a rise and/or fall pattern; patchy LGE or myocarditis like changes on CMR imaging<sup>[33]</sup>; and the contraction band necrosis on histopathological examination<sup>[37]</sup>. However, all the afore-mentioned constellations of findings are not always found in TS. Many of the clinical diseases reported to cause troponin elevations, as among others stroke, subarachnoid hemorrhage<sup>[42]</sup>, sepsis<sup>[41]</sup>, chronic obstructive pulmonary diseases<sup>[2]</sup>, and pheochromocytoma<sup>[40]</sup> have been reported to trigger TS. However, the same clinical condition may cause repolarization ECG changes, troponin elevations, chemical (norepinephrine) myocarditis on CMR imaging, or contraction band necrosis alone or in combination without any LVWMA<sup>[42]</sup>. One plausible explanation for the absence of LVWMA in TS-related conditions may be the swift reversibility of LVWMA, which can occur within minutes, hours, or days in some cases of TS<sup>[6]</sup>. Typically, among patients with acute subarachnoid hemorrhage<sup>[42]</sup>, up to 70% may show left ventricular diastolic dysfunction. In 67%, ECG changes may be present including repolarization abnormalities, in 30% troponin elevation<sup>[47]</sup>, and only near 20% LVWMA. Consequently, substantial numbers of patients with subarachnoid hemorrhage may be complicated by repolarization ECG changes and troponin elevation without LVWMA. The same pattern of findings is seen in pheochromocytoma-and paraganglioma-induced acute cardiac disease<sup>[31,40,48]</sup>. During the last 10 -15 years, dozens of cases of pheochromocytoma-triggered TS have been reported<sup>[40]</sup>. For more than 50 years, cases of pheochromocytoma-induced acute “focal myocarditis”, confirmed by either endomyocardial, autopsy<sup>[49]</sup>, or by CMR imaging<sup>[35]</sup> have been reported. Critical analysis of some of these reports shows that those patients have features consistent with TS also<sup>[35]</sup>. As late as 2018, Khattak *et al*<sup>[35]</sup> reported on a case



with pheochromocytoma and CMR imaging findings consistent with acute myocarditis at the basal segments of the left ventricle. However, the ECG findings and the hypokinesia of the basal segments with cardiac image studies (echocardiography and CMR) argue strongly for inverted TS. CMR imaging may show patchy LGE in about one third of patients with TS<sup>[33]</sup>. Cases of pheochromocytoma-induced chest pain and ECG findings of MI have also been reported<sup>[50-52]</sup>. Analysis of some of those cases reveals findings consistent with TS. In 1983, McGonigle *et al*<sup>[51]</sup> reported on a case of “recurrent MI” in a patient with pheochromocytoma. During one admission, the patient had reversible marked ST elevation and the coronary arteries were normal. Left ventriculography revealed discrete left ventricular apical “aneurysm” with thrombus in the aneurysmal sac. This case can justifiably be deemed as recurrent TS triggered by pheochromocytoma with our current knowledge about TS<sup>[31]</sup>. Cases of reversible pheochromocytoma-induced cardiomyopathy with features consistent with global TS have also been reported<sup>[31]</sup>. Cases of pheochromocytoma-induced hypercontracted sarcomere and contraction band necrosis as that seen in TS has also been reported<sup>[53]</sup>. A similar pattern of ECG changes, troponin elevations, LVWMA, or histopathologic findings of contraction band necrosis, alone or in different combination is seen in other diseases reported to trigger TS as sepsis<sup>[41,43,54,55]</sup>. Consequently, substantial numbers of disease conditions may cause a continuum of manifestation as troponin elevation, ECG repolarization changes, and other features seen in TS without causing LVWMA; all driven by the same pathophysiology of TS described below and these conditions are coined here as TS-related conditions.

---

## RECURRENT AND CHRONIC ANCA SYNDROME (RECURRENT AND CHRONIC TS)

---

The recurrence rate of TS has ranged from 0 to 22%<sup>[25,56]</sup>. In patients with pheochromocytoma- and paraganglioma triggered TS, a recurrence rate of 17.7% has been reported<sup>[31,40]</sup>, which is most probably due to undiagnosed pheochromocytoma where the trigger factor remains and result in recurrent TS<sup>[31]</sup>. These repeated TS episodes may lead to permanent myocardial damages resulting in “pheochromocytoma induced cardiomyopathy<sup>[57]</sup>. There are two other clinical conditions, which may cause mild to moderate troponin elevation in a chronic form and they are decompensated CHF<sup>[58]</sup> and CKD<sup>[59]</sup>. Acute exacerbation of CHF is a well-known cause of troponin elevation. Critical review of the sequence of events occurring in decompensated CHF reveals events resembling that happen in TS but in chronic form<sup>[58,60]</sup>. In both TS and decompensated CHF, there are evidences for the local cardiac sympathetic disruption and norepinephrine seethe and spillover triggered by a physical stress or an emotional trigger in TS and by multiple trigger factor in decompensated CHF. This sympathetic disruption causes a unique circumferential LVWMA resulting in a conspicuous ballooning of the LV in TS; worsening of LVWMA in CHF causes remodeling of the LV and changing the LV geometry from ellipsoid to spherical shape<sup>[58]</sup>. The LVWMA is transient in TS and the worsening of the LVWMA in CHF is also reversible when properly treated. Both conditions are characterized by modest elevation of the cardiac troponins and marked elevation of NT-pro- BNP. The difference between the two conditions is that the above-mentioned sequence of events occurs acutely in TS and chronically with acute exacerbation in CHF<sup>[2,58]</sup>. Consequently, chronic ANCA with acute exacerbation may be the main pathogenesis for the increased morbidity and mortality in patients with decompensated CHF irrespective of the underlying cause of heart failure<sup>[58]</sup>.

The second chronic condition which may cause chronic troponin elevation is CKD<sup>[59]</sup>. Heart failure and cardiovascular death are common in patients with CKD and extremely prevalent in patients undergoing dialysis<sup>[59]</sup>. Evidences supporting the occurrence of sympathetic over-activity in patients with dialysis and non-dialysis dependent CKD<sup>[59]</sup> are substantial. Several studies have also been reported on reversible segmental LVWMA consistent with myocardial stunning in association with dialysis especially hemodialysis<sup>[61]</sup>. In the literature, the most acceptable underlying cause for the myocardial stunning in CKD is “demand myocardial ischemia”, which has never been confirmed. However, the repeated reversible myocardial stunning and the occurrence of cardiac sympathetic overactivation disruption in patients with CKD can be compared to that occurring in acute TS where the acute circumferential pattern of myocardial stunning is most probably caused by the local cardiac sympathetic disruption and norepinephrine seethe and spillover<sup>[5,45]</sup>.

## EVIDENCES FOR HYPERACTIVATION OF AUTONOMIC (SYMPATHETIC) NERVOUS SYSTEM IN TS AND TS-RELATED SYNDROMES

Evidences for the involvement of the autonomic nervous system including local cardiac sympathetic system in the pathogenesis of TS and TS-related conditions are substantial<sup>[6,45]</sup> and include: (1) The profound suffering that arises from bereavement and induces myocardial stunning in an individual reflects the feeling and the degree of sadness of that individual for the loss of another. This highly argues for the extreme sympathetic stimulation of the myocardium likely mediated via the neurocardiogenic cause of TS<sup>[45]</sup>. (2) Acute brain diseases and injuries or brain death is a well-recognized trigger factor of TS<sup>[42,45]</sup> indicating that TS is a neuro-cardiac disease. (3) The prevalence of diabetes mellitus is low in patients with the first episode of TS<sup>[62]</sup>. Remarkably, the prevalence of diabetes in patients with TS recurrence is also significantly lower compared to those without TS recurrence<sup>[63]</sup>. Autonomic neuropathy as a complication in patients with diabetes mellitus may lead to brain-heart disconnection and may have protective cardiac effects in situations with powerful emotional or physical stress factors<sup>[62]</sup>. (4) Signs of cardiac sympathetic denervation assessed by <sup>123</sup>I-meta-iodobenzylguanidine (<sup>123</sup>I-MIBG) scintigraphy is detected in patients with TS<sup>[64]</sup>. The principal <sup>123</sup>I-MIBG scintigraphic findings are reduced regional uptake of the <sup>123</sup>I-MIBG in the hypokinetic/akinetic left ventricular segments and augmented washout rate of <sup>123</sup>I-MIBG<sup>[64]</sup>. (5) One of the characteristic electrocardiographic changes in TS is sympathetic T-wave changes in the form of T-wave inversion and prolongation of the corrected QT-interval<sup>[46]</sup>. Patients with TS and long QTc may suffer life threatening arrhythmias as torsade's de pointe and asystole, ventricular tachycardia, ventricular fibrillation, usually in the subacute phase of the disease<sup>[65]</sup>. Remarkably, the sympathetic nervous system plays also a central role in the pathogenesis of the congenital long QT syndrome (LQTS). Physical manipulations of the stellate ganglia have produced dramatic ventricular irritability arrhythmia in LQTS and removal of the left stellate ganglion normalized the electrocardiographic abnormalities<sup>[66]</sup>. A distinct regional pattern of impaired cardiac sympathetic function, assessed by <sup>123</sup>I-MIBG scintigraphy, is identified in the majority of symptomatic LQTS patients<sup>[67]</sup>. Interestingly, the episodes of arrhythmias in congenital LQTS are often associated with, if not precipitated by a physical or an emotional<sup>[66]</sup> as that in some patients with TS. (6) Increased nor-epinephrine levels in the coronary sinus have been demonstrated in patients with TS, suggesting increased local myocardial nor-epinephrine release from the cardiac sympathetic nerve terminals<sup>[68]</sup>. Intracranial disease processes including subarachnoid haemorrhage and brain death are well-recognised physical trigger factor for TS. Increased myocardial interstitial, but not plasma, nor-epinephrine release have been proved after brain death induction in pigs<sup>[69]</sup>. The local myocardial nor-epinephrine spill-over may explain the focal myocarditis changes seen in some patients with TS; focal myocarditis in TS has been confirmed both by endomyocardial biopsy<sup>[70]</sup> and even in the form of patchy LGE by CMR imaging<sup>[33,35]</sup>. (7) One of the vital and consistent histopathological changes in TS are the hypercontracted sarcomeres and contraction bands<sup>[37]</sup>. In a baboon model of catastrophic cerebral insult, Novitzky *et al*<sup>[71]</sup> demonstrated that contraction band necrosis could be prevented by cardiac denervation (cardiac sympathectomy) but not by vagotomy. (8) A remarkable finding in 2 of the 3 cases with successful heart transplantation of donor heart afflicted by TS was the documentation of a rapid resolution of LVWMA occurred at the accomplishment of heart transplantation; the simultaneous surgical sympathectomy in association with the donor cardiectomy may have resulted in relief of the myocardial stunning (cardiac cramp) caused by disinhibition of the cardiac sympathetic tone during donor brain death<sup>[5]</sup>. (9) Templin *et al*<sup>[72]</sup> have recently demonstrated evidence for hypoconnectivity of the central brain regions associated with autonomic function and regulation of the limbic system in patients with TS. The investigators deemed that those findings suggest that autonomic-limbic integration might play an important role in the pathophysiology and contribute to the understanding of TS. And (10) The LVWMA in TS has a characteristic systematized pattern. It affects the ventricular myocardium circumferentially with a sharp transition between the normal or hyperkinetic myocardium and the stunned myocardium<sup>[5,73]</sup>. The heart is densely innervated with sympathetic nerves, which are distributed on a regional basis. The pattern of LVWMA in TS appears to follow the anatomical sympathetic innervation from the left and right stellate and caudal ganglia<sup>[5,74]</sup>. The left ventricular systolic dysfunction after subarachnoid haemorrhage was studied in 30 patients by Zaroff *et al*<sup>[75]</sup>. The authors observed that many of regional wall motion patterns did not follow a coronary artery supply territory but correlated with the distribution of the myocardial sympathetic

nerve terminals providing an indirect evidence for a neuro-mediated mechanism of myocardial injury<sup>[75]</sup>. This circumferential pattern of LVWMA is congruent with cardiac nerve distribution<sup>[76,77]</sup>. Details of further evidence for the local cardiac sympathetic nervous system involvement in TS is described elsewhere<sup>[5,6,44,45]</sup>. For these reasons, it will be plausible to coin TS and TS-related disease conditions as ANCA syndrome.

---

## MECHANISM OF TROPONIN ELEVATION IN ANCA SYNDROME (INCLUDING TS)

---

The cardiac specific isoforms, cardiac troponin T and cardiac troponin I, are components of the troponin complex. This consists of proteins attached to the myofibrils of the contractile apparatus in cardiomyocytes, but 6% of cardiac troponin T and 3% of cardiac troponin I exist in an unbound free form in the cytosol<sup>[78]</sup>. The discussed mechanisms of troponin elevation in the literature are: Myocardial ischemia, inflammatory and immunological processes, trauma, drugs and toxins.

Some investigators believe that troponin elevation indicates myocardial injury. However, troponin elevation in association with exercise and even during walking<sup>[78]</sup>, no delayed gadolinium enhancement in the CMR imaging in the almost two thirds of patients with TS<sup>[2]</sup> and in patients classified having so called “T2MI” or “MINOCA”<sup>[10-13]</sup> argue against myocardial injury in every patient with troponin elevation. Exocytosis of the early releasable unbounded cytosolic troponin free pool into the blood stream from hypercontracted cardiomyocytes by neuro-adrenergic stimuli may be the most probable cause of elevated cardiac troponin values in TS and TS-related disease conditions *i.e.*, ANCA syndrome. There are findings in TS that may support the exocytosis mechanism of troponin release (Figure 4). The LVWMA in TS has the characteristic features of myocardial stunning<sup>[5]</sup>, where the myocardium is in a state of cardiac cramp<sup>[79]</sup>, which may cause release of the troponin through squeezing the unbound cytosolic troponin free pool<sup>[79,80]</sup>. This may explain the only mild-moderate elevation of troponin in all TS and TS-related disease conditions and even in decompensated CHF with acute exacerbation and CKD.

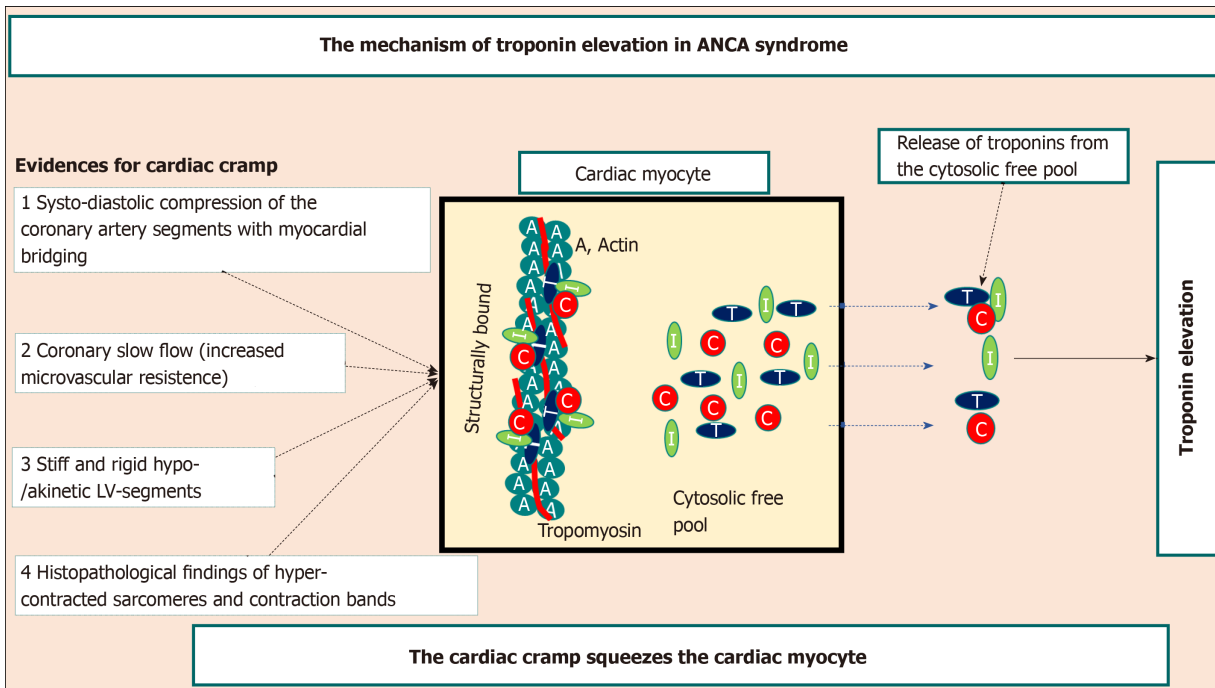
The evidence for the myocardial cramp in TS is discussed in details elsewhere<sup>[5]</sup> and will be briefed here: The systo-diastolic compression of the left anterior descending artery segments with myocardial bridging during the acute and sub-acute stages of TS and the relief of the diastolic compression during recovery of the LVWMA argues for the fact that the myocardial stunning in TS is in a cramp state<sup>[79]</sup> (Figure 5). The evidence of slow flow in the coronary arteries especially in the left anterior descending artery may indicate the increased microvascular resistance to the coronary flow caused by rigid stunned myocardium<sup>[5]</sup> (Figure 6). The valve-like hyperactive motility of the basal segments of the left ventricle in the mid-apical or mid-ventricular TS pattern and the slingshot-like motion of the apical segments in the apical sparing TS pattern is partially attributed to the stiff and rigid hypo-/akinetic involved segments in TS<sup>[5,80]</sup>. One of the important and consistent histo-pathological changes in TS is the presence of contraction bands and hyper-contracted sarcomeres<sup>[37]</sup>. This morphologic histopathologic alteration seems to constitute a spectrum, with mere hypercontraction at one end to cardiac rupture at the other. The hypercontracted sarcomeres may squeeze the unbound cytosolic troponin causing mild-moderate troponin elevation. In advanced and repeated episodes of TS, it may lead to necrosis where the cardiomyocyte dies in tonic state. A typical condition for recurrent TS is that occurring in undiagnosed pheochromocytoma and paraganglioma<sup>[31,40]</sup>, and for repeated myocardial stunning is that occurring in CKD<sup>[59]</sup>.

---

## PROPOSAL FOR THE DIAGNOSIS OF MYOCARDIAL INFARCTION AND THE MAIN CAUSES OF TROPONIN ELEVATION

---

Because of the reasons mentioned above about the different types of MI, the currently used classification of MI needs urgent reassessment. Consequently, to diagnose MI and its differential diagnoses, the following investigations are required: Detection of a rise and/or fall of cTn values with at least one value above the 99<sup>th</sup> percentile upper normal limit, clinical presentation (cardiac signs and symptoms), ECG changes, invasive CAG findings, and cardiac imaging studies such as: Echocardiography, left ventriculography, and in some cases CMR imaging. The working diagnosis should concentrate on the following main causes of troponin elevations: (1) Coronary



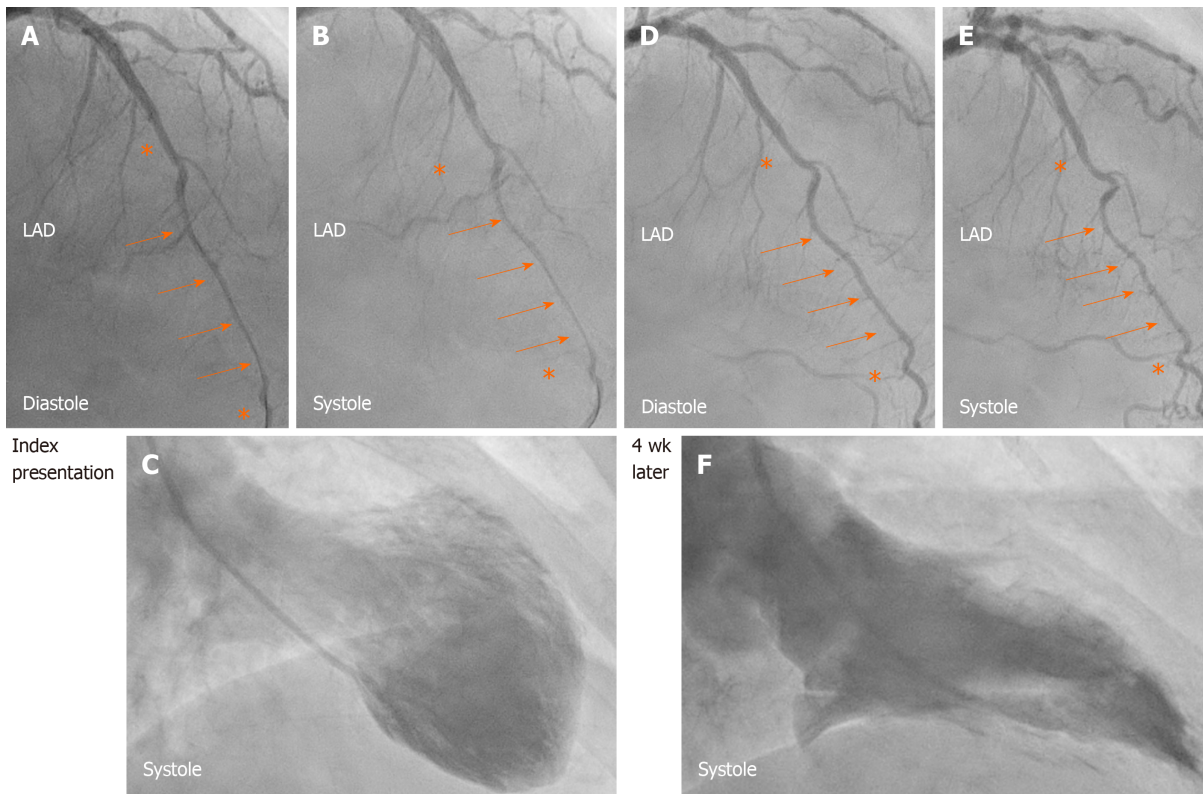
**Figure 4 Mechanism of troponin elevation in autonomic neurocardiogenic syndrome.** Illustration of the hypothetical mechanism of troponin release in autonomic neurocardiogenic syndrome including takotsubo syndrome and takotsubo-related conditions. The systo-diastolic compression of a coronary artery segment specially left anterior descending artery with myocardial bridging, the coronary slow flow due to increased microvascular resistance, the stiff and rigid myocardial stunning, and the hyper-contracted sarcomeres indicate that the affected myocardium in autonomic neurocardiogenic syndrome including takotsubo syndrome is in a state of cardiac cramp. This cardiac cramp may squeeze the cardiac myocyte causing release of troponins from the cytosolic free pool resulting in mild-moderate troponin elevation as demonstrated in the figure. C: Troponin C; I: Troponin I; T: Troponin T; ANCA: Autonomic neurocardiogenic.

ischemic mechanism and consequently MI (caused by coronary atherothrombotic changes, SCAD, coronary thrombo-embolism, epicardial coronary spasm, myocardial bridging with coronary compression, percutaneous coronary intervention-related, or coronary artery bypass graft surgery-related); (2) ANCA causes of troponin elevation (TS and TS-related disease conditions). The research should be concentrated on neurocardiogenic diseases, which has been disregarded and regrettably to say blocked by the UD-MI for many years; (3) Inflammatory and toxic cell destruction; and (4) Other miscellaneous causes.

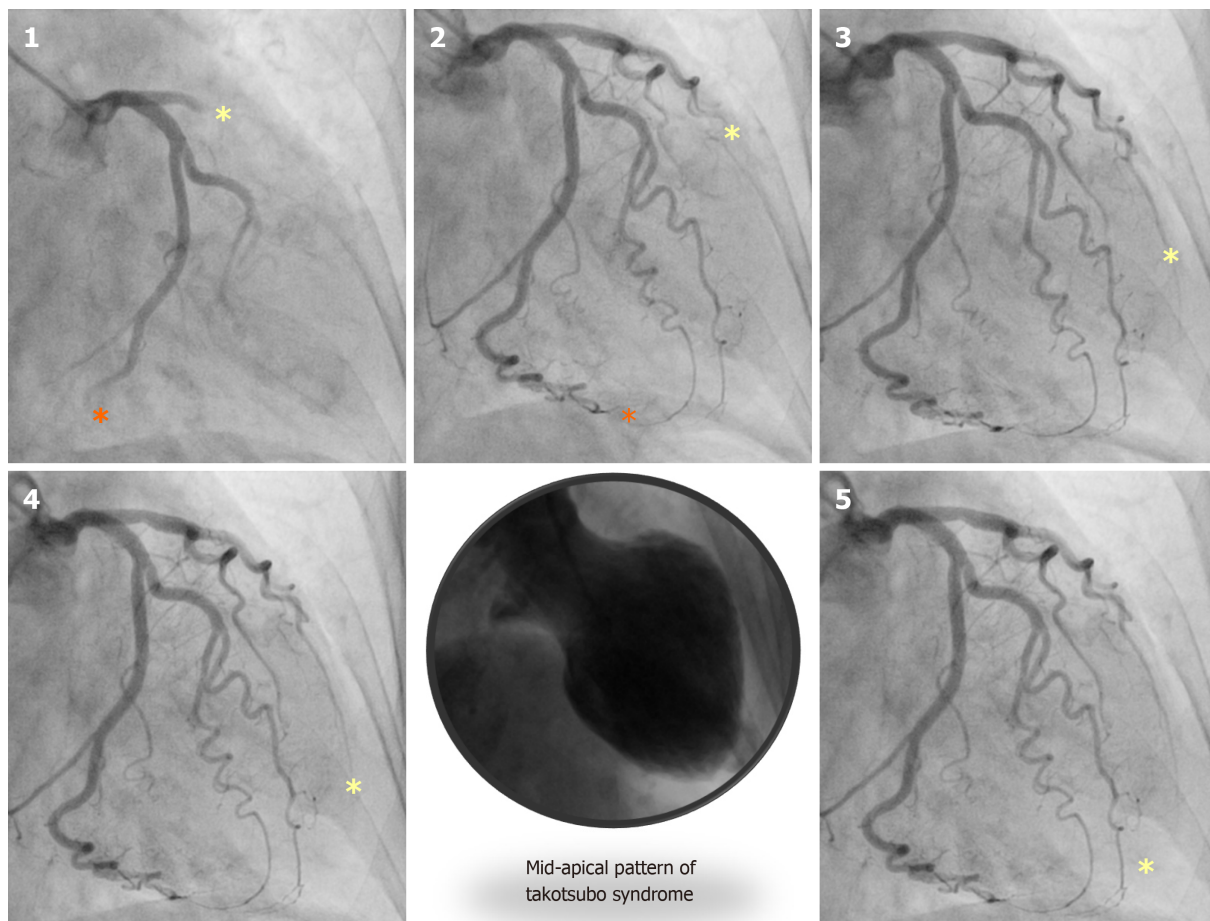
## CONCLUSION

The clinical criteria for the diagnosis of MI according to the fourth UD-MI document show controversial aspects. T2MI and MINOCA are not evidence-based. Most of the cases included under MINOCA have no MI and some of those with MI have missed obstructive instead of nonobstructive coronary arteries. In addition, the UD-MI have blocked thoughts to search for mechanisms other than coronary ischemia that may cause troponin elevation. The clinical diagnostic criteria of T1MI, T2MI, T3MI, and MINOCA need to be revised categorically. ANCA caused troponin elevation is probably the second most common cause of troponin elevation after acute coronary ischemia. The mechanism of troponin elevation in ANCA syndrome is most probably due to cardiac cramp squeezing the cardiomyocyte causing mild to moderate release of troponin from the cytosolic free pool. ANCA syndrome may occur in an acute form as in TS or TS-related disease conditions. The syndrome may also occur in a recurrent or a chronic form as in undiagnosed pheochromocytoma, CHF with acute exacerbations, and in CKD. A proposal for the diagnosis of MI and its differential diagnosis and the main causes of troponin elevation is provided.





**Figure 5** Systo-diastolic compression of a coronary artery segment with myocardial bridging. A, B, and C: Left anterior descending artery (LAD) during diastole (A) and systole (B) in the acute stage of takotsubo syndrome (TS) in a patient where contrast left ventriculography revealed mid-apical pattern of TS (C). During the acute stage of the disease: Note the diastolic and systolic compression of a segment of LAD with myocardial bridging (orange arrows) bordered by normal segments (Asterix) before and after the segment with myocardial bridging. D, E, and F: Four weeks later, there was complete relief of LAD compression during diastole (D, orange arrows) and only mild systolic compression (E, orange arrows) after normalization of left ventricular function (F). This indicates that the stunned myocardium was in a cramp state during the acute-subacute stage of TS. LAD: Left anterior descending artery.



**Figure 6** Slow flow in the left anterior descending artery in a patient with takotsubo syndrome. A case of mid-apical ballooning pattern of takotsubo syndrome (middle, lower panel) showing the marked slow flow in the left anterior descending artery (yellow Asterix) compared to left circumflex artery (orange Asterix) in panel 1 to 5.

## ACKNOWLEDGEMENTS

A special thanks to Dr. Rodney De Palma for reviewing the English language of the manuscript.

## REFERENCES

- 1 **Thygesen K**, Alpert JS, Jaffe AS, Chaitman BR, Bax JJ, Morrow DA, White HD; Executive Group on behalf of the Joint European Society of Cardiology (ESC)/American College of Cardiology (ACC)/American Heart Association (AHA)/World Heart Federation (WHF) Task Force for the Universal Definition of Myocardial Infarction. Fourth Universal Definition of Myocardial Infarction (2018). *Glob Heart* 2018; **13**: 305-338 [PMID: 30154043 DOI: 10.1016/j.gheart.2018.08.004]
- 2 **Ghadri JR**, Wittstein IS, Prasad A, Sharkey S, Dote K, Akashi YJ, Cammann VL, Crea F, Galiuto L, Desmet W, Yoshida T, Manfredini R, Eitel I, Kosuge M, Nef HM, Deshmukh A, Lerman A, Bossone E, Citro R, Ueyama T, Corrado D, Kurisu S, Ruschitzka F, Winchester D, Lyon AR, Omerovic E, Bax JJ, Meimoun P, Tarantini G, Rihal C, Y-Hassan S, Migliore F, Horowitz JD, Shimokawa H, Lüscher TF, Templin C. International Expert Consensus Document on Takotsubo Syndrome (Part I): Clinical Characteristics, Diagnostic Criteria, and Pathophysiology. *Eur Heart J* 2018; **39**: 2032-2046 [PMID: 29850871 DOI: 10.1093/eurheartj/ehy076]
- 3 **Agewall S**, Beltrame JF, Reynolds HR, Niessner A, Rosano G, Caforio AL, De Caterina R, Zimarino M, Roffi M, Kjeldsen K, Atar D, Kaski JC, Sechtem U, Tornvall P; WG on Cardiovascular Pharmacotherapy. ESC working group position paper on myocardial infarction with non-obstructive coronary arteries. *Eur Heart J* 2017; **38**: 143-153 [PMID: 28158518 DOI: 10.1093/eurheartj/ehw149]
- 4 **Baron T**, Hambraeus K, Sundström J, Erlinge D, Jernberg T, Lindahl B; TOTAL-AMI study group. Impact on Long-Term Mortality of Presence of Obstructive Coronary Artery Disease and Classification of Myocardial Infarction. *Am J Med* 2016; **129**: 398-406 [PMID: 26763754 DOI: 10.1016/j.amjmed.2015.11.035]
- 5 **Y-Hassan S**, De Palma R. Contemporary review on the pathogenesis of takotsubo syndrome: The heart shedding tears: Norepinephrine churn and foam at the cardiac sympathetic nerve terminals. *Int J Cardiol* 2017; **228**: 528-536 [PMID: 27875730 DOI: 10.1016/j.ijcard.2016.11.086]
- 6 **Y-Hassan S**, Tornvall P. Epidemiology, pathogenesis, and management of takotsubo syndrome. *Clin*

- Auton Res* 2018; **28**: 53-65 [PMID: 28917022 DOI: 10.1007/s10286-017-0465-z]
- 7 **Collinson P**, Lindahl B. Type 2 myocardial infarction: the chimaera of cardiology? *Heart* 2015; **101**: 1697-1703 [PMID: 26220812 DOI: 10.1136/heartjnl-2014-307122]
- 8 **Y-Hassan S**. In case of strict application, the third universal definition of myocardial infarction will erase takotsubo syndrome as a diagnosis. *Int J Cardiol* 2014; **176**: 1217-1219 [PMID: 25129283 DOI: 10.1016/j.ijcard.2014.07.220]
- 9 **Beltrame JF**. Assessing patients with myocardial infarction and nonobstructed coronary arteries (MINOCA). *J Intern Med* 2013; **273**: 182-185 [PMID: 22998397 DOI: 10.1111/j.1365-2796.2012.02591.x]
- 10 **Collste O**, Sörensson P, Frick M, Agewall S, Daniel M, Henareh L, Ekenbäck C, Eurenus L, Guiron C, Jernberg T, Hofman-Bang C, Malmqvist K, Nagy E, Arheden H, Tornvall P. Myocardial infarction with normal coronary arteries is common and associated with normal findings on cardiovascular magnetic resonance imaging: results from the Stockholm Myocardial Infarction with Normal Coronaries study. *J Intern Med* 2013; **273**: 189-196 [PMID: 22742529 DOI: 10.1111/j.1365-2796.2012.02567.x]
- 11 **Bière L**, Niro M, Pouliquen H, Gourraud JB, Prunier F, Furber A, Probst V. Risk of ventricular arrhythmia in patients with myocardial infarction and non-obstructive coronary arteries and normal ejection fraction. *World J Cardiol* 2017; **9**: 268-276 [PMID: 28400924 DOI: 10.4330/wjcv.v9.i3.268]
- 12 **Pasupathy S**, Air T, Dreyer RP, Tavella R, Beltrame JF. Systematic review of patients presenting with suspected myocardial infarction and nonobstructive coronary arteries. *Circulation* 2015; **131**: 861-870 [PMID: 25587100 DOI: 10.1161/CIRCULATIONAHA.114.011201]
- 13 **Hausvater A**, Pasupathy S, Tornvall P, Gandhi H, Tavella R, Beltrame J, Agewall S, Ekenbäck C, Brolin EB, Hochman JS, Collste O, Reynolds HR. ST-segment elevation and cardiac magnetic resonance imaging findings in myocardial infarction with non-obstructive coronary arteries. *Int J Cardiol* 2019; **287**: 128-131 [PMID: 31003795 DOI: 10.1016/j.ijcard.2019.04.028]
- 14 **Saw J**, Starovoytov A, Humphries K, Sheth T, So D, Minhas K, Brass N, Lavoie A, Bishop H, Lavi S, Pearce C, Renner S, Madan M, Welsh RC, Lutchmedial S, Vijayaraghavan R, Aymong E, Har B, Ibrahim R, Gornik HL, Ganesh S, Buller C, Matteau A, Martucci G, Ko D, Mancini GBJ. Canadian spontaneous coronary artery dissection cohort study: in-hospital and 30-day outcomes. *Eur Heart J* 2019; **40**: 1188-1197 [PMID: 30698711 DOI: 10.1093/eurheartj/ehz007]
- 15 **Y-Hassan S**. Scientific statement on spontaneous coronary artery dissection: care must be taken not to miss the association of spontaneous coronary artery dissection and takotsubo syndrome. *J Thorac Dis* 2018; **10**: S3169-S3175 [PMID: 30370106 DOI: 10.21037/jtd.2018.07.136]
- 16 **Hayes SN**, Kim ESH, Saw J, Adlam D, Arslanian-Engoren C, Economy KE, Ganesh SK, Gulati R, Lindsay ME, Mieres JH, Naderi S, Shah S, Thaler DE, Tweet MS, Wood MJ; American Heart Association Council on Peripheral Vascular Disease; Council on Clinical Cardiology; Council on Cardiovascular and Stroke Nursing; Council on Genomic and Precision Medicine; and Stroke Council. Spontaneous Coronary Artery Dissection: Current State of the Science: A Scientific Statement From the American Heart Association. *Circulation* 2018; **137**: e523-e557 [PMID: 29472380 DOI: 10.1161/CIR.0000000000000564]
- 17 **Safdar B**, Spatz ES, Dreyer RP, Beltrame JF, Lichtman JH, Spertus JA, Reynolds HR, Geda M, Bueno H, Dziura JD, Krumholz HM, D'Onofrio G. Presentation, Clinical Profile, and Prognosis of Young Patients With Myocardial Infarction With Nonobstructive Coronary Arteries (MINOCA): Results From the VIRGO Study. *J Am Heart Assoc* 2018; **7**: e009174 [PMID: 29954744 DOI: 10.1161/JAHA.118.009174]
- 18 **Baron T**, Hambraeus K, Sundström J, Erlinge D, Jernberg T, Lindahl B; TOTAL-AMI study group. Type 2 myocardial infarction in clinical practice. *Heart* 2015; **101**: 101-106 [PMID: 25331532 DOI: 10.1136/heartjnl-2014-306093]
- 19 **Nordenskjöld AM**, Baron T, Eggers KM, Jernberg T, Lindahl B. Predictors of adverse outcome in patients with myocardial infarction with non-obstructive coronary artery (MINOCA) disease. *Int J Cardiol* 2018; **261**: 18-23 [PMID: 29563017 DOI: 10.1016/j.ijcard.2018.03.056]
- 20 **Lindahl B**, Baron T, Erlinge D, Hadziosmanovic N, Nordenskjöld A, Gard A, Jernberg T. Medical Therapy for Secondary Prevention and Long-Term Outcome in Patients With Myocardial Infarction With Nonobstructive Coronary Artery Disease. *Circulation* 2017; **135**: 1481-1489 [PMID: 28179398 DOI: 10.1161/CIRCULATIONAHA.116.026336]
- 21 **Lambrech S**, Sarkisian L, Saaby L, Poulsen TS, Gerke O, Hosbond S, Diederichsen ACP, Thygesen K, Mickley H. Different Causes of Death in Patients with Myocardial Infarction Type 1, Type 2, and Myocardial Injury. *Am J Med* 2018; **131**: 548-554 [PMID: 29274756 DOI: 10.1016/j.amjmed.2017.11.043]
- 22 **Y-Hassan S**. Most of the patients classified under "Myocardial infarction with non-obstructive coronary arteries (MI-NOCA)" have either no MI or no NOCA. *Int J Cardiol* 2019; **294**: 54 [PMID: 31522717 DOI: 10.1016/j.ijcard.2019.06.068]
- 23 **Y-Hassan S**, Yamasaki K. History of takotsubo syndrome: is the syndrome really described as a disease entity first in 1990? Some inaccuracies. *Int J Cardiol* 2013; **166**: 736-737 [PMID: 23073280 DOI: 10.1016/j.ijcard.2012.09.183]
- 24 **Dote K**, Sato H, Tateishi H, Uchida T, Ishihara M. [Myocardial stunning due to simultaneous multivessel coronary spasms: a review of 5 cases]. *J Cardiol* 1991; **21**: 203-214 [PMID: 1841907]
- 25 **Templin C**, Ghadri JR, Diekmann J, Napp LC, Bataiosu DR, Jaguszewski M, Cammann VL, Sarcon A, Geyer V, Neumann CA, Seifert B, Hellermann J, Schwyzer M, Eisenhardt K, Jenewein J, Franke J, Katus HA, Burgdorf C, Schunkert H, Moeller C, Thiele H, Bauersachs J, Tschöpe C, Schultheiss HP, Laney CA, Rajan L, Michels G, Pfister R, Ukena C, Böhm M, Erbel R, Cuneo A, Kuck KH, Jacobschagen C, Hasenfuss G, Karakas M, Koenig W, Rottbauer W, Said SM, Braun-Dullaeus RC, Cuculi F, Banning A, Fischer TA, Vasankari T, Airaksinen KE, Fijalkowski M, Rynkiewicz A, Pawlak M, Opolski G, Dworakowski R, MacCarthy P, Kaiser C, Osswald S, Galiuto L, Crea F, Dichtl W, Franz WM, Empen K, Felix SB, Delmas C, Lairez O, Erne P, Bax JJ, Ford I, Ruschitzka F, Prasad A, Lüscher TF. Clinical Features and Outcomes of Takotsubo (Stress) Cardiomyopathy. *N Engl J Med* 2015; **373**: 929-938 [PMID: 26332547 DOI: 10.1056/NEJMoa1406761]
- 26 **Y-Hassan S**, Tornvall P, Törnerud M, Henareh L. Capecitabine caused cardiogenic shock through induction of global Takotsubo syndrome. *Cardiovasc Revasc Med* 2013; **14**: 57-61 [PMID: 23218901 DOI: 10.1016/j.carrev.2012.10.001]
- 27 **Y-Hassan S**. Broken muscle and heart: daughter, mother, and grandmother. *Eur Heart J* 2019; **40**: 3363 [PMID: 31132086 DOI: 10.1093/eurheartj/ehz340]
- 28 **Eitel I**, von Knobelsdorff-Brenkenhoff F, Bernhardt P, Carbone I, Muellerleile K, Aldrovandi A, Francione M, Desch S, Gutberlet M, Strohm O, Schuler G, Schulz-Menger J, Thiele H, Friedrich MG. Clinical

- characteristics and cardiovascular magnetic resonance findings in stress (takotsubo) cardiomyopathy. *JAMA* 2011; **306**: 277-286 [PMID: 21771988 DOI: 10.1001/jama.2011.992]
- 29 **Cramer MJ**, De Boeck B, Melman PG, Sieswerda GJ. The 'broken heart' syndrome: What can be learned from the tears and distress? *Neth Heart J* 2007; **15**: 283-285 [PMID: 18074000 DOI: 10.1007/BF03086000]
- 30 **Sharkey SW**, Windenburg DC, Lesser JR, Maron MS, Hauser RG, Lesser JN, Haas TS, Hodges JS, Maron BJ. Natural history and expansive clinical profile of stress (tako-tsubo) cardiomyopathy. *J Am Coll Cardiol* 2010; **55**: 333-341 [PMID: 20117439 DOI: 10.1016/j.jacc.2009.08.057]
- 31 **Y-Hassan S**, Falhammar H. Pheochromocytoma- and paraganglioma-triggered Takotsubo syndrome. *Endocrine* 2019; **65**: 483-493 [PMID: 31399912 DOI: 10.1007/s12020-019-02035-3]
- 32 **Ghadri JR**, Wittstein IS, Prasad A, Sharkey S, Dote K, Akashi YJ, Cammann VL, Crea F, Galiuto L, Desmet W, Yoshida T, Manfredini R, Eitel I, Kosuge M, Nef HM, Deshmukh A, Lerman A, Bossone E, Citro R, Ueyama T, Corrado D, Kurisu S, Ruschitzka F, Winchester D, Lyon AR, Omerovic E, Bax JJ, Meimoun P, Tarantini G, Rihal C, Y-Hassan S, Migliore F, Horowitz JD, Shimokawa H, Lüscher TF, Templin C. International Expert Consensus Document on Takotsubo Syndrome (Part II): Diagnostic Workup, Outcome, and Management. *Eur Heart J* 2018; **39**: 2047-2062 [PMID: 29850820 DOI: 10.1093/eurheartj/ehy077]
- 33 **Rolf A**, Nef HM, Möllmann H, Troidl C, Voss S, Conradi G, Rixe J, Steiger H, Beiring K, Hamm CW, Dill T. Immunohistological basis of the late gadolinium enhancement phenomenon in tako-tsubo cardiomyopathy. *Eur Heart J* 2009; **30**: 1635-1642 [PMID: 19389788 DOI: 10.1093/eurheartj/ehp140]
- 34 **Gaikwad N**, Butler T, Maxwell R, Shaw E, Strugnell WE, Chan J, Figtree GA, Slaughter RE, Hamilton-Craig C. Late gadolinium enhancement does occur in Tako-tsubo cardiomyopathy - A quantitative cardiac magnetic resonance and speckle tracking strain study. *Int J Cardiol Heart Vasc* 2016; **12**: 68-74 [PMID: 28616546 DOI: 10.1016/j.ijcha.2016.07.009]
- 35 **Khattak S**, Sim I, Dancy L, Whitelaw B, Sado D. Phaeochromocytoma found on cardiovascular magnetic resonance in a patient presenting with acute myocarditis: an unusual association. *BMJ Case Rep* 2018; **2018**: bcr2017222621 [PMID: 29884661 DOI: 10.1136/bcr-2017-222621]
- 36 **Y-Hassan S**. Myocarditis is an essential feature rather than an exclusion criterion for takotsubo syndrome: Case report. *Int J Cardiol* 2015; **187**: 304-306 [PMID: 25839628 DOI: 10.1016/j.ijcard.2015.03.275]
- 37 **Nef HM**, Möllmann H, Kostin S, Troidl C, Voss S, Weber M, Dill T, Rolf A, Brandt R, Hamm CW, Elsässer A. Tako-Tsubo cardiomyopathy: intraindividual structural analysis in the acute phase and after functional recovery. *Eur Heart J* 2007; **28**: 2456-2464 [PMID: 17395683 DOI: 10.1093/eurheartj/ehl570]
- 38 **Y-Hassan S**. Spontaneous coronary artery dissection and takotsubo syndrome: An often overlooked association; review. *Cardiovasc Revasc Med* 2018; **19**: 717-723 [PMID: 29502960 DOI: 10.1016/j.carrev.2018.02.002]
- 39 **Y-Hassan S**, Holmin S, Abdula G, Böhm F. Thrombo-embolic complications in takotsubo syndrome: Review and demonstration of an illustrative case. *Clin Cardiol* 2019; **42**: 312-319 [PMID: 30565272 DOI: 10.1002/clc.23137]
- 40 **Y-Hassan S**. Clinical Features and Outcome of Pheochromocytoma-Induced Takotsubo Syndrome: Analysis of 80 Published Cases. *Am J Cardiol* 2016; **117**: 1836-1844 [PMID: 27103159 DOI: 10.1016/j.amjcard.2016.03.019]
- 41 **Y-Hassan S**, Settergren M, Henareh L. Sepsis-induced myocardial depression and takotsubo syndrome. *Acute Card Care* 2014; **16**: 102-109 [PMID: 24955937 DOI: 10.3109/17482941.2014.920089]
- 42 **Ripoll JG**, Blackshear JL, Diaz-Gómez JL. Acute Cardiac Complications in Critical Brain Disease. *Neurosurg Clin N Am* 2018; **29**: 281-297 [PMID: 29502718 DOI: 10.1016/j.nec.2017.11.007]
- 43 **Park JH**, Kang SJ, Song JK, Kim HK, Lim CM, Kang DH, Koh Y. Left ventricular apical ballooning due to severe physical stress in patients admitted to the medical ICU. *Chest* 2005; **128**: 296-302 [PMID: 16002949 DOI: 10.1378/chest.128.1.296]
- 44 **Y-Hassan S**. Insights into the pathogenesis of takotsubo syndrome, which with persuasive reasons should be regarded as an acute cardiac sympathetic disease entity. *ISRN Cardiol* 2012; **2012**: 593735 [PMID: 23119184 DOI: 10.5402/2012/593735]
- 45 **Y-Hassan S**. Acute cardiac sympathetic disruption in the pathogenesis of the takotsubo syndrome: a systematic review of the literature to date. *Cardiovasc Revasc Med* 2014; **15**: 35-42 [PMID: 24140050 DOI: 10.1016/j.carrev.2013.09.008]
- 46 **Y-Hassan S**. The pathogenesis of reversible T-wave inversions or large upright peaked T-waves: Sympathetic T-waves. *Int J Cardiol* 2015; **191**: 237-243 [PMID: 25981361 DOI: 10.1016/j.ijcard.2015.04.233]
- 47 **Zhang L**, Wang Z, Qi S. Cardiac Troponin Elevation and Outcome after Subarachnoid Hemorrhage: A Systematic Review and Meta-analysis. *J Stroke Cerebrovasc Dis* 2015; **24**: 2375-2384 [PMID: 26227321 DOI: 10.1016/j.jstrokecerebrovasdis.2015.06.030]
- 48 **Ghadri JR**, Y-Hassan S, Lüscher TF, Templin C. Pheochromocytoma triggers takotsubo syndrome. *Eur Heart J* 2019; **40**: 1990 [PMID: 30903176 DOI: 10.1093/eurheartj/ehz084]
- 49 **Van Vliet PD**, Burchell HB, Titus JL. Focal myocarditis associated with pheochromocytoma. *N Engl J Med* 1966; **274**: 1102-1108 [PMID: 5932021 DOI: 10.1056/NEJM196605192742002]
- 50 **Mattman PE**. Successful removal of a pheochromocytoma four weeks after acute myocardial infarction. *Am J Cardiol* 1961; **8**: 426-430 [PMID: 13768321 DOI: 10.1016/0002-9149(61)90163-1]
- 51 **McGonigle P**, Webb SW, Adgey AA. Phaeochromocytoma: an unusual cause of chest pain. *Br Med J (Clin Res Ed)* 1983; **286**: 1477-1478 [PMID: 6405848 DOI: 10.1136/bmj.286.6376.1477]
- 52 **Nirgiotis JG**, Andrassy RJ. Pheochromocytoma and acute myocardial infarction. *South Med J* 1990; **83**: 1478-1480 [PMID: 2251539 DOI: 10.1097/00007611-199012000-00027]
- 53 **Frustaci A**, Loperfido F, Gentiloni N, Caldarulo M, Morgante E, Russo MA. Catecholamine-induced cardiomyopathy in multiple endocrine neoplasia. A histologic, ultrastructural, and biochemical study. *Chest* 1991; **99**: 382-385 [PMID: 1671211 DOI: 10.1378/chest.99.2.382]
- 54 **Schmittinger CA**, Dünser MW, Torgersen C, Luckner G, Lorenz J, Schmid S, Joannidis M, Moser P, Hasibeder WR, Halabi M, Steger CM. Histologic pathologies of the myocardium in septic shock: a prospective observational study. *Shock* 2013; **39**: 329-335 [PMID: 23376953 DOI: 10.1097/SHK.0b013e318289376b]
- 55 **ver Elst KM**, Spapen HD, Nguyen DN, Garbar C, Huyghens LP, Goris FK. Cardiac troponins I and T are biological markers of left ventricular dysfunction in septic shock. *Clin Chem* 2000; **46**: 650-657 [PMID: 10794747]
- 56 **Akashi YJ**, Nef HM, Lyon AR. Epidemiology and pathophysiology of Takotsubo syndrome. *Nat Rev*



- Cardiol* 2015; **12**: 387-397 [PMID: 25855605 DOI: 10.1038/nrcardio.2015.39]
- 57 **Batisse-Lignier M**, Pereira B, Motreff P, Pierrard R, Burnot C, Vorilhon C, Maqdas S, Roche B, Desbiez F, Clerfond G, Citron B, Lusson JR, Tauveron I, Eschaliere R. Acute and Chronic Pheochromocytoma-Induced Cardiomyopathies: Different Prognoses?: A Systematic Analytical Review. *Medicine (Baltimore)* 2015; **94**: e2198 [PMID: 26683930 DOI: 10.1097/MD.0000000000002198]
- 58 **Y-Hassan S**. Chronic takotsubo syndrome with acute exacerbations may be the villain in the increase of morbidity and mortality in patients with decompensated chronic heart failure. *Int J Cardiol* 2014; **172**: 609-610 [PMID: 24495651 DOI: 10.1016/j.ijcard.2014.01.085]
- 59 **Y-Hassan S**. Acute, repetitive and chronic Takotsubo syndrome in patients with chronic kidney disease: Sympathetic reno-cardial syndrome. *Int J Cardiol* 2016; **222**: 874-880 [PMID: 27522391 DOI: 10.1016/j.ijcard.2016.07.278]
- 60 **Y-Hassan S**. Chronic Takotsubo syndrome with acute exacerbations in decompensated chronic heart failure: surgical cardiac sympathectomy may have a role? *Int J Cardiol* 2014; **174**: 420-421 [PMID: 24794548 DOI: 10.1016/j.ijcard.2014.04.040]
- 61 **Hothi DK**, Rees L, Marek J, Burton J, McIntyre CW. Pediatric myocardial stunning underscores the cardiac toxicity of conventional hemodialysis treatments. *Clin J Am Soc Nephrol* 2009; **4**: 790-797 [PMID: 19339406 DOI: 10.2215/CJN.05921108]
- 62 **Madias JE**. Low prevalence of diabetes mellitus in patients with Takotsubo syndrome: A plausible 'protective' effect with pathophysiologic connotations. *Eur Heart J Acute Cardiovasc Care* 2016; **5**: 164-170 [PMID: 25673782 DOI: 10.1177/2048872615570761]
- 63 **Kato K**, Di Vece D, Cammann VL, Micek J, Szawan KA, Bacchi B, Lüscher TF, Ruschitzka F, Ghadri JR, Templin C, InterTAK Collaborators. Takotsubo Recurrence: Morphological Types and Triggers and Identification of Risk Factors. *J Am Coll Cardiol* 2019; **73**: 982-984 [PMID: 30819368 DOI: 10.1016/j.jacc.2018.12.033]
- 64 **Madias JE**. Do we need MIBG in the evaluation of patients with suspected Takotsubo syndrome? Diagnostic, prognostic, and pathophysiologic connotations. *Int J Cardiol* 2016; **203**: 783-784 [PMID: 26595783 DOI: 10.1016/j.ijcard.2015.11.046]
- 65 **Syed FF**, Asirvatham SJ, Francis J. Arrhythmia occurrence with takotsubo cardiomyopathy: a literature review. *Europace* 2011; **13**: 780-788 [PMID: 21131373 DOI: 10.1093/europace/euq435]
- 66 **Coyer BH**, Pryor R, Kirsch WM, Blount SG Jr. Left stellectomy in the long QT syndrome. *Chest* 1978; **74**: 584-586 [PMID: 738103 DOI: 10.1378/chest.74.5.584]
- 67 **Kies P**, Paul M, Gerss J, Stegger L, Mönnig G, Schober O, Wichter T, Schäfers M, Schulze-Bahr E. Impaired cardiac sympathetic innervation in symptomatic patients with long QT syndrome. *Eur J Nucl Med Mol Imaging* 2011; **38**: 1899-1907 [PMID: 21691919 DOI: 10.1007/s00259-011-1852-7]
- 68 **Kume T**, Kawamoto T, Okura H, Toyota E, Neishi Y, Watanabe N, Hayashida A, Okahashi N, Yoshimura Y, Saito K, Nezu S, Yamada R, Yoshida K. Local release of catecholamines from the hearts of patients with tako-tsubo-like left ventricular dysfunction. *Circ J* 2008; **72**: 106-108 [PMID: 18159109 DOI: 10.1253/circj.72.106]
- 69 **Mertes PM**, Carreaux JP, Jaboin Y, Pinelli G, el Abassi K, Dopff C, Atkinson J, Villemot JP, Bulet C, Boulange M. Estimation of myocardial interstitial norepinephrine release after brain death using cardiac microdialysis. *Transplantation* 1994; **57**: 371-377 [PMID: 8108872 DOI: 10.1097/00007890-199402150-00010]
- 70 **Case records of the Massachusetts General Hospital**. Weekly clinicopathological exercises. Case 18-1986. A 44-year-old woman with substernal pain and pulmonary edema after severe emotional stress. *N Engl J Med* 1986; **314**: 1240-1247 [PMID: 3702920 DOI: 10.1056/NEJM198605083141908]
- 71 **Novitzky D**, Wicomb WN, Cooper DK, Rose AG, Reichart B. Prevention of myocardial injury during brain death by total cardiac sympathectomy in the Chacma baboon. *Ann Thorac Surg* 1986; **41**: 520-524 [PMID: 3707246 DOI: 10.1016/s0003-4975(10)63032-9]
- 72 **Templin C**, Hänggi J, Klein C, Topka MS, Hiestand T, Levinson RA, Jurisic S, Lüscher TF, Ghadri JR, Jäncke L. Altered limbic and autonomic processing supports brain-heart axis in Takotsubo syndrome. *Eur Heart J* 2019; **40**: 1183-1187 [PMID: 30831580 DOI: 10.1093/eurheartj/ehz068]
- 73 **Fujikawa M**, Iwasaka J, Oishi C, Ueyama T, Park H, Yamamoto Y, Otani H, Iwasaka T. Three-dimensional echocardiographic assessment of left ventricular function in takotsubo cardiomyopathy. *Heart Vessels* 2008; **23**: 214-216 [PMID: 18484167 DOI: 10.1007/s00380-007-1033-6]
- 74 **Randall WC**, Szentivanyi M, Pace JB, Wechsler JS, Kaye MP. Patterns of sympathetic nerve projections onto the canine heart. *Circ Res* 1968; **22**: 315-323 [PMID: 5639044 DOI: 10.1161/01.res.22.3.315]
- 75 **Zaroff JG**, Rordorf GA, Ogilvy CS, Picard MH. Regional patterns of left ventricular systolic dysfunction after subarachnoid hemorrhage: evidence for neurally mediated cardiac injury. *J Am Soc Echocardiogr* 2000; **13**: 774-779 [PMID: 10936822 DOI: 10.1067/mje.2000.105763]
- 76 **Marafioti V**, Benfari G. Takotsubo syndrome: a neurocardiac syndrome inside the autonomic nervous system. *Heart Fail Rev* 2019; **24**: 227 [PMID: 30343460 DOI: 10.1007/s10741-018-9748-2]
- 77 **Marafioti V**, Turri G, Carbone V, Monaco S. Association of prolonged QTc interval with Takotsubo cardiomyopathy: A neurocardiac syndrome inside the mystery of the insula of Reil. *Clin Cardiol* 2018; **41**: 551-555 [PMID: 29663451 DOI: 10.1002/clc.22910]
- 78 **Gresslien T**, Agewall S. Troponin and exercise. *Int J Cardiol* 2016; **221**: 609-621 [PMID: 27420587 DOI: 10.1016/j.ijcard.2016.06.243]
- 79 **Y-Hassan S**. Tight coronary artery stenosis and takotsubo syndrome triggered each other: Well-illustrated in a case. *Cardiovasc Revasc Med* 2018; **19**: 2-4 [PMID: 29804797 DOI: 10.1016/j.carrev.2018.05.012]
- 80 **Y-Hassan S**. Myocarditis changes in the stunned myocardial segments in takotsubo syndrome: The role of the pattern of ventricular wall motion abnormality. *Int J Cardiol* 2015; **191**: 267-269 [PMID: 25978612 DOI: 10.1016/j.ijcard.2015.04.275]



Published by Baishideng Publishing Group Inc  
7041 Koll Center Parkway, Suite 160, Pleasanton, CA 94566, USA  
Telephone: +1-925-2238242  
E-mail: [bpgoffice@wjgnet.com](mailto:bpgoffice@wjgnet.com)  
Help Desk: <https://www.f6publishing.com/helpdesk>  
<https://www.wjgnet.com>

