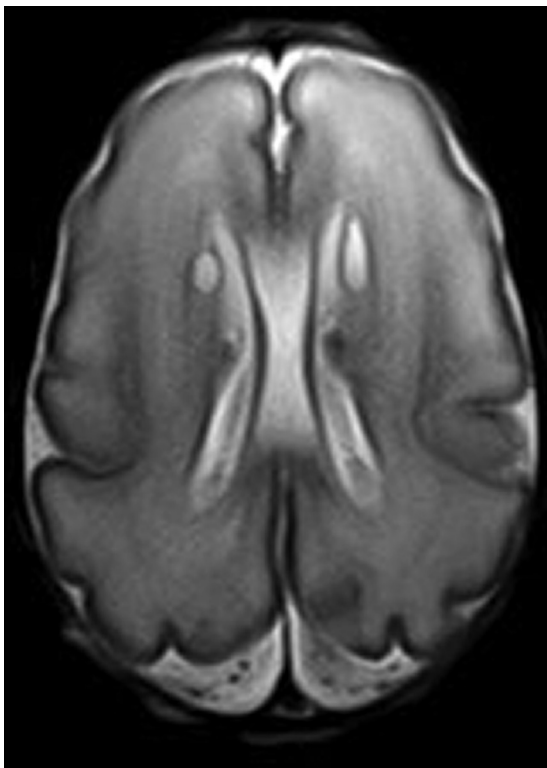


The authors of “Validation of an MRI Brain Injury and Growth Scoring System in Very Preterm Infants Scanned at 29- to 35-Week Postmenstrual Age” (*AJNR Am J Neuroradiol* 2017;38:1435–42, <https://doi.org/10.3174/ajnr.A5191>) wish to clarify for the reader that the image in On-line Fig 2 shows bilateral connatal cysts. The figure, along with its amended legend, is displayed below.

<http://dx.doi.org/10.3174/ajnr.A5448>



ON-LINE FIG 2. Bilateral connatal cysts, classified as cerebral WM, cystic lesion, focal bilateral, score 2 (axial T2).