



Since January 2020 Elsevier has created a COVID-19 resource centre with free information in English and Mandarin on the novel coronavirus COVID-19. The COVID-19 resource centre is hosted on Elsevier Connect, the company's public news and information website.

Elsevier hereby grants permission to make all its COVID-19-related research that is available on the COVID-19 resource centre - including this research content - immediately available in PubMed Central and other publicly funded repositories, such as the WHO COVID database with rights for unrestricted research re-use and analyses in any form or by any means with acknowledgement of the original source. These permissions are granted for free by Elsevier for as long as the COVID-19 resource centre remains active.

the North West. We envisage an increasing role for online education to supplement traditional teaching allowing for greater flexibility and hopefully increased engagement. In this new era of free access to online medical resources and technology-enhanced learning,<sup>9,10</sup> we are confident that our resource and others like it will continue to grow and make a substantial contribution to anaesthetic training in the UK and around the world.

## Acknowledgements

The authors acknowledge the contribution of all those who produced content for the SAVED project during the COVID-19 pandemic, and John-Paul Lomas for his assistance in providing website usage data.

## Declarations of interest

CS is a former member of the editorial board of *BJA Education*. The other authors declare no other competing interests.

## References

- Ortega R, Chen R. Beyond the operating room: the roles of anaesthesiologists in pandemics. *Br J Anaesth* 2020. <https://doi.org/10.1016/j.bja.2020.06.005>. Advance Access published on June 11, 2020
- Illiff HA, Simpson KA, Tomlinson CR, Webb CM. 'Shielded' anaesthetists and intensivists during the COVID-19 pandemic. *Anaesthesia* 2020. <https://doi.org/10.1111/anae.15153>. Advance Access published on July 6
- World Health Organization. *Mental health and psychosocial considerations during the COVID-19 outbreak* March 2020. Available from: <https://apps.who.int/iris/bitstream/handle/10665/331490/WHO-2019-nCoV-MentalHealth-2020.1-eng.pdf>. [Accessed 10 June 2020]
- Johannsson H, Selak T. Dissemination of medical publications on social media – is it the new standard? *Anaesthesia* 2020; **75**: 155–7
- Intensive Care Society. *Education in COVID* June 2020. Available from: <https://youtu.be/elwjDG97GZw>. [Accessed 2 July 2020]
- Muilenburg LY, Berge ZL. Student barriers to online learning: a factor analytic study. *Distance Educ* 2005; **26**: 29–48
- Wong AVK, Olusanya O. Burnout and resilience in anaesthesia and intensive care medicine. *BJA Educ* 2017; **17**: 334–40
- Song D, Bonk CJ. Motivational factors in self-directed informal learning from online learning resources. *Cogent Educ* 2016; **3**: 1–11
- Carroll CL, Bruno K, vonTschudi M. Social media and free open access medical education: the future of medical and nursing education? *Am J Crit Care* 2016; **25**: 93–6
- Wang JJ, Deng A, Tsui BCH. COVID-19: novel pandemic, novel generation of medical students. *Br J Anaesth* 2020. <https://doi.org/10.1016/j.bja.2020.06.005>. Advance Access published on June 2

doi: 10.1016/j.bja.2020.07.046

Advance Access Publication Date: 7 August 2020

© 2020 British Journal of Anaesthesia. Published by Elsevier Ltd. All rights reserved.

# Bedside monitoring of lung perfusion by electrical impedance tomography in the time of COVID-19

Bijan Safaee Fakhr<sup>1,2</sup>, Caio C. Araujo Morais<sup>1,2</sup>, Roberta R. De Santis Santiago<sup>1,2</sup>, Raffaele Di Fenza<sup>1,2</sup>, Lauren E. Gibson<sup>1,2</sup>, Paula A. Restrepo<sup>1,2</sup>, Marvin G. Chang<sup>1,2</sup>, Edward A. Bittner<sup>1,2</sup>, Riccardo Pinciroli<sup>1,2</sup>, Florian J. Fintelmann<sup>2,3</sup>, Robert M. Kacmarek<sup>1,2,4</sup> and Lorenzo Berra<sup>1,2,4,\*</sup>

<sup>1</sup>Department of Anaesthesia, Critical Care and Pain Medicine, Massachusetts General Hospital, Boston, MA, USA, <sup>2</sup>Harvard Medical School, Boston, MA, USA, <sup>3</sup>Department of Radiology, Massachusetts General Hospital, Boston, MA, USA and <sup>4</sup>Respiratory Care Department, Massachusetts General Hospital, Boston, MA, USA

\*Corresponding author. E-mail: [lberra@mgh.harvard.edu](mailto:lberra@mgh.harvard.edu)

**Keywords:** COVID-19; electrical impedance tomography; lung perfusion; mechanical ventilation; pulmonary embolism; ventilation/perfusion matching

Editor—Coronavirus disease 2019 (COVID-19) results in a broad spectrum of clinical presentations, including viral pneumonia and acute respiratory distress syndrome (ARDS).<sup>1</sup> Increasingly compelling evidence suggests that the underlying pathophysiology of severe COVID-19 pneumonia is microvascular thrombosis.<sup>2,3</sup> Although the pulmonary

vasculature can be seen in exquisite detail with computed tomography pulmonary angiography (CTPA), routine CTPA is neither feasible nor recommended in COVID-19 patients.<sup>4</sup> Therefore, tools enabling bedside evaluation of lung perfusion, including monitoring the response to therapeutic

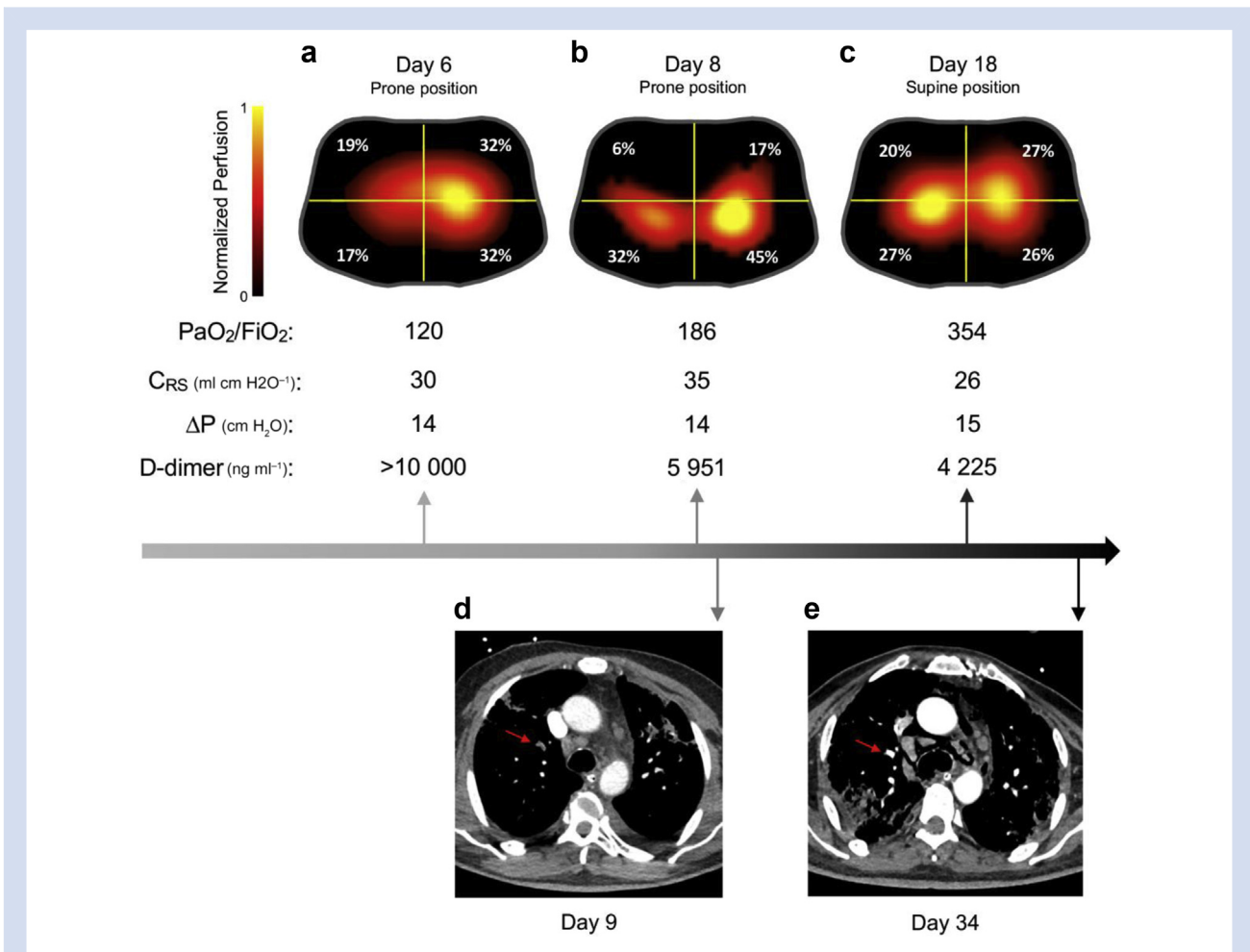
interventions such as anticoagulation, are increasingly important during this pandemic.

Electrical impedance tomography (EIT) is a noninvasive, bedside, radiation-free technology that allows clinicians to monitor and optimise ventilation strategies in real time.<sup>5,6</sup> More recently, EIT has been used to assess regional lung perfusion in critically ill patients.<sup>6–8</sup> In a swine study, EIT was equivalent to high-sensitivity positron emission tomography in detecting alterations in lung perfusion.<sup>9</sup> An observational study of 68 patients with acute respiratory failure showed that the evaluation of dead space with EIT (with a cut-off of 30.4%) results in a sensitivity of 90.9% and a specificity of 98.6% for diagnosis of pulmonary embolism.<sup>7</sup>

An available EIT method for generating lung perfusion maps is a first-pass kinetic approach performed by rapid injection of 10 ml hypertonic sodium chloride as a contrast agent through a central venous catheter during an end-expiratory hold manoeuvre on the mechanical ventilator.<sup>6</sup> It is ideally suited to study the causes of refractory hypoxaemia, and to monitor disease progression and the response to intervention

in this patient population.<sup>10</sup> Here, we describe the use of EIT to diagnose a significant lung perfusion defect and to monitor response to anticoagulation over time until normalisation of lung perfusion. Confirmation of pulmonary thrombosis and its resolution was obtained using CTPA.

A 66-yr-old man, who consented to this correspondence, presented to the emergency department with progressively worsening shortness of breath, cough, and fever suggestive for COVID-19 pneumonia. He was severely dyspnoeic, requiring 6 L min<sup>-1</sup> of oxygen by nasal prongs (?) to maintain an oxygen saturation of 92–93%. His D-dimer was increased (7473 ng ml<sup>-1</sup>), consistent with the acute inflammatory process of COVID-19, and suspicion for pulmonary embolism was low. Deterioration of the patient and increasing oxygen requirement resulted in tracheal intubation for respiratory failure (arterial partial pressure of oxygen [PaO<sub>2</sub>]/fraction of inspired oxygen [FiO<sub>2</sub>] ratio, 247 mm Hg), and he was admitted to the ICU. Real-time reverse transcriptase–polymerase chain reaction testing for severe acute respiratory syndrome coronavirus 2 (SARS-CoV-2) was positive. On hospital day 6, because of progressive



**Fig 1.** Serial lung perfusion evaluation in a COVID-19 patient. (a–c) Electrical impedance tomography (EIT) perfusion images obtained at days 6, 8, and 18. Images were generated with Enlight 1800 (Timpel SA, São Paulo, Brazil) using the first-pass kinetics method. The lung is divided into four quadrants (regions of interest). Colour scale was adjusted by linear normalisation. (d) Axial CT pulmonary angiography image shows segmental and subsegmental pulmonary emboli in the right upper lobe (red arrow). (e) Axial CT pulmonary angiography image shows resolution of the pulmonary artery filling defect (red arrow) in comparison with the previous image. Day, day from admission to emergency department; C<sub>RS</sub>, respiratory system compliance; ΔP, driving pressure.

deterioration in gas exchange ( $P_{aO_2}/F_{iO_2}=120$  mm Hg) despite lung-protective measures including pronation and the initiation of inhaled nitric oxide (iNO), EIT was used to evaluate regional ventilation and pulmonary blood flow distribution.

The patient was evaluated in the prone position while receiving 40 ppm iNO and lung-protective mechanical ventilation with PEEP of 14 cm H<sub>2</sub>O. EIT showed homogenous ventilation, with dead space estimated at 66% of the tidal volume, and imbalanced perfusion distribution, with a significant discrepancy between the left (64%) and right (36%) lungs (Fig. 1a). Our findings were consistent with a major perfusion impairment, likely caused by pulmonary thrombosis (D-dimer  $>10\,000$  ng ml<sup>-1</sup>). Echocardiography revealed an increased right ventricular systolic pressure ( $>35$  mm Hg) and signs of right ventricular strain despite iNO administration, suggesting the presence of pulmonary hypertension. A bubble test excluded an intracardiac shunt. As a result, the ICU team started therapeutic anticoagulation with continuous infusion of unfractionated heparin i.v. A second EIT (Fig. 1b) was performed on day 8 and was followed by CTPA (Fig. 1d) that confirmed segmental and subsegmental right upper lobe pulmonary perfusion defects, matching the location of the deficit indicated by EIT. Over the subsequent 10 days, the patient improved clinically, with a reduction in D-dimer and an improvement in oxygenation ( $P_{aO_2}/F_{iO_2}=354$  mm Hg). A tracheostomy was performed on day 17, and repeat EIT (Fig. 1c) showed homogenous lung perfusion and subsequent CTPA on day 34 (Fig. 1e) confirmed resolution of the pulmonary artery filling defects. The D-dimer continued to decrease to 3222 ng ml<sup>-1</sup>. Ventilatory settings and respiratory mechanics remained virtually unchanged throughout. At hospital day 58, the tracheostomy was closed with oxygen therapy via nasal cannula (1–3 L min<sup>-1</sup>), with discharge to a pulmonary rehabilitation centre after 68 days of hospitalisation.

Recent radiological, physiological, and pathological studies suggest a possible central role for pulmonary vascular alterations in the pathophysiology of COVID-related hypoxaemia.<sup>2,3</sup> We found that EIT detected imbalance in lung perfusion despite even distribution of ventilation in a patient who was later confirmed to have pulmonary thrombosis. EIT was also effective in showing resolution of the perfusion defects following treatment. Follow-up CTPA provided evidence for resolution of clots, confirming what was observed with the EIT.

EIT is a radiation-free, noninvasive bedside technique that allows individualised ventilation setting,<sup>6</sup> identification of perfusion impairment that might require CTPA,<sup>7</sup> and multiple assessments of pulmonary perfusion over time to determine response to therapies.

## Declarations of interest

LB is supported by US NIH/NHLBI grant K23HL128882, receives devices and equipment from Praxair Inc. and Masimo Corp., and has a grant from iNO Therapeutics LLC. This study was supported by the Reginald Jenney Endowment Chair at Harvard

Medical School to LB, by LB Sundry Funds at Massachusetts General Hospital, and by laboratory funds of the Anesthesia Center for Critical Care Research of the Department of Anesthesia, Critical Care and Pain Medicine at Massachusetts General Hospital. RMK is a consultant for Medtronic, Orange Med, and has received research grants from Medtronic and Venner Medical (Dänischenhagen, Germany). All other authors have no conflicts to declare.

## References

- Guan W-J, Ni Z-Y, Hu Y, et al. Clinical characteristics of coronavirus disease 2019 in China. *N Engl J Med* 2020; **80**: 656–65
- Ackermann M, Verleden SE, Kuehnel M, et al. Pulmonary vascular endothelialitis, thrombosis, and angiogenesis in Covid-19. *N Engl J Med* 2020; **383**: 120–8
- Gattinoni L, Coppola S, Cressoni M, Busana M, Rossi S, Chiumello D. Covid-19 does not lead to a ‘typical’ acute respiratory distress syndrome. *Am J Respir Crit Care Med* 2020; **201**: 1299–300
- ACR Recommendations for the use of chest radiography and computed tomography (CT) for suspected COVID-19 infection. Available from: <https://www.acr.org/Advocacy-and-Economics/ACR-Position-Statements/Recommendations-for-Chest-Radiography-and-CT-for-Suspected-COVID19-Infection> (accessed 12 May 2020).
- Girrbach F, Petroff D, Schulz S, et al. Individualised positive end-expiratory pressure guided by electrical impedance tomography for robot-assisted laparoscopic radical prostatectomy: a prospective, randomised controlled clinical trial. *Br J Anaesth* 2020. Available from: <http://www.sciencedirect.com/science/article/pii/S0007091220304232>. [Accessed 23 July 2020]
- Bachmann MC, Morais C, Bugedo G, et al. Electrical impedance tomography in acute respiratory distress syndrome. *Crit Care* 2018; **22**: 263
- He H, Chi Y, Long Y, et al. Bedside evaluation of pulmonary embolism by saline contrast electrical impedance tomography method: a prospective observational study. *Am J Respir Crit Care Med Am Thorac Soc – AJRCCM* 2020. Available from: <https://www.atsjournals.org/doi/10.1164/rccm.202005-1780LE>. [Accessed 26 July 2020]
- Grassi LG, Santiago R, Florio G, Berra L. Bedside evaluation of pulmonary embolism by electrical impedance tomography. *Anesthesiology* 2020; **132**: 896
- Bluth T, Kiss T, Kircher M, et al. Measurement of relative lung perfusion with electrical impedance and positron emission tomography: an experimental comparative study in pigs. *Br J Anaesth* 2019; **123**: 246–54
- Zarantonello F, Andreatta G, Sella N, Navalesi P. Prone position and lung ventilation/perfusion matching in acute respiratory failure due to COVID-19. *Am J Respir Crit Care Med* 2020; **202**: 278–9

doi: 10.1016/j.bja.2020.08.001

Advance Access Publication Date: 7 August 2020

© 2020 British Journal of Anaesthesia. Published by Elsevier Ltd. All rights reserved.