

[CASE REPORT]

Monomicrobial Fournier's Gangrene Caused by Panton-Valentine Leukocidin-negative Methicillin-susceptible *Staphylococcus aureus* ST8 in Japan

Hirofumi Yamagishi, Kenichi Kawahori, Noriaki Ohkiba,
Nozomi Murooka and Takeshi Inazawa

Abstract:

Methicillin-resistant *Staphylococcus aureus* USA300, belonging to sequence type (ST) 8, is a rare cause of necrotizing fasciitis in the USA. We herein report a case of monomicrobial Fournier's gangrene caused by an ST8, methicillin-susceptible *Staphylococcus aureus* (designated ksw1). Whole-genome sequencing and analyses for virulence determinants revealed that, unlike USA300, ksw1 lacked virulence genes, such as Panton-Valentine leukocidin and SCCmec, while harboring the toxic shock syndrome toxin-1 gene. These genomic features correlate with ST8 CA-MRSA/J, which is the major genotype of ST8 in Japan.

Key words: Fournier's gangrene, methicillin-susceptible *Staphylococcus aureus* ST8, Panton-Valentine leukocidin, toxic shock syndrome toxin-1

(Intern Med 59: 1769-1772, 2020)

(DOI: 10.2169/internalmedicine.4334-19)

Introduction

Fournier's gangrene is characterized by necrotizing fasciitis of the perineal, perianal or genital regions (1, 2). Diabetes mellitus is well known to be a particularly important risk factor for Fournier's gangrene (2, 3). Fournier's gangrene is typically caused by polymicrobial infection (2). It has been increasingly reported that monomicrobial infection of community-associated methicillin-resistant *Staphylococcus aureus* (CA-MRSA) can cause necrotizing fasciitis (4).

In the USA, the most predominant CA-MRSA strain, USA300, belongs to multilocus sequence type (ST) 8 and typically harbors virulence genes, such as the Panton-Valentine leukocidin genes *lukF-PV* and *lukS-PV* (*luk_{PV}SF*), and staphylococcal cassette chromosome *mec* (SCCmec) type IV carrying penicillin and cephem resistance gene *mecA* (4).

In Japan, the strain ST8 has not been well characterized (5) despite several studies showing evidence of USA 300 infection (6-10). We herein report a case of monomicrobial Fournier's gangrene caused by a strain of methicillin-

susceptible *S. aureus* ST8 (designated ksw1) that lacked the Panton-Valentine leukocidin gene while harboring the toxic shock syndrome toxin-1 gene.

Case Report

A 66-year-old man presented with a 1-month history of left buttock pain. His medical records indicated type 2 diabetes mellitus that had not been treated for 30 years. The patient had never been abroad. A clinical examination revealed tachycardia (100 beats per minute) with a normal blood pressure (105/55 mmHg) and slight pyrexia (38.1°C). His body mass index was 18.64 kg/m² (height, 167 cm; body weight, 52.0 kg). A physical examination revealed an open wound with purulent discharge on his left buttock (Figure a). A laboratory examination indicated leucocytosis (white blood cell count, 23,820/μL), elevated level of C-reactive protein (C-reactive protein, 25.08 mg/dL), mildly elevated level of muscle-derived enzymes (aspartate aminotransferase, 90 U/L; lactate dehydrogenase, 433 U/L; creatine kinase, 322 U/L), normal level of serum creatinine (creatinine, 0.59 mg/dL) and hyperglycemia (blood glucose,

Department of Endocrinology and Metabolism, Kashiwa Municipal Hospital, Japan

Received: December 12, 2019; Accepted: February 16, 2020; Advance Publication by J-STAGE: April 16, 2020

Correspondence to Dr. Hirofumi Yamagishi, crocchetta.di.riso@gmail.com

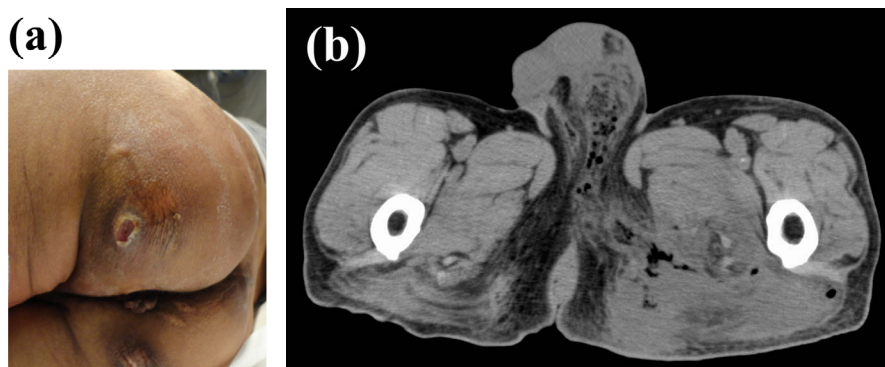


Figure. (a) Open wound on the left buttock of the patient. (b) CT scan of subcutaneous emphysema. CT: computed tomography

238 mg/dL; hemoglobin A1c, 8.6%). Furthermore, computed tomography (CT) demonstrated subcutaneous emphysema extending from the left scrotum and inguinal region to the left thigh (Figure b). The CT findings indicated the possibility of Fournier's gangrene. In accordance with this observation, intravenous tazobactam/piperacillin (4.5 g, thrice daily) was initiated, and exploratory surgery was conducted. Concurrently, insulin therapy was started to manage his hyperglycemia. Intraoperative findings revealed subcutaneous abscess in the left buttock with necrotizing muscle fascia, symptomatically confirming Fournier's gangrene. Accordingly, extensive debridement was conducted.

Gram staining of the intraoperative purulence demonstrated clusters of Gram-positive cocci, indicating the involvement of *S. aureus*. Therefore, intravenous vancomycin was added. Monomicrobial *S. aureus* was isolated from the blood and intraoperative purulence samples. This isolate was tested for antimicrobial susceptibility by the microliquid dilution method using an autoSCAN-4 (Beckman Coulter, Brea, USA) and the CLSI M100-S26 interpretive criteria and was found to be resistant to penicillin and ampicillin while retaining susceptibility to the other 14 antimicrobials examined (sulbactam/ampicillin, cefazolin, cefotiam, cefmetazole, flomoxef, gentamicin, arbekacin, erythromycin, minocycline, vancomycin, sulfamethoxazole/trimethoprim, fosfomycin, imipenem/cilastatin and levofloxacin). Based on the results of an antimicrobial susceptibility test, antimicrobials were replaced with intravenous cefazolin (1 g thrice daily) and clindamycin (600 mg twice daily). Repeated CT revealed a residual lesion in the left scrotum. Accordingly, additional debridement was performed on day 19 of admission. After the second debridement, antimicrobials were replaced with levofloxacin (500 mg once daily) administered orally and discontinued 3 days after the surgery.

The genome of the *S. aureus* strain isolated from the intraoperative purulence (ksw1) was sequenced with an MiSeq sequencer (illumina, San Diego, USA), and genome assembly was performed with a CLC Genomics Workbench 11. Multilocus sequence typing (11) and *spa* (protein A gene) typing (12) were conducted, and the genotype was determined to be ST8/*spa*1 (t622). We further performed gene

annotation with the Pathosystems Resource Integration Center (PATRIC, <http://www.patricbrc.org>) (13) and searched for SCCmec using the SCCmecFinder (<http://cge.cbs.dtu.dk/services/SCCmecFinder>) (14). We compared the virulence factors between ksw1, USA300 strain FPR3757 (GenBank accession number: CP000255) (15) and ST8 CA-MRSA/J strain NN50 (Genbank accession number: BAEA 01000000) (16), which is the major genotype of ST8 in Japan (Table). The ksw1 lacked *luk_{PV}SF* and harbored the toxic shock syndrome toxin-1 gene, like ST8 CA-MRSA/J, but lacked SCCmec. For further confirmation, we conducted polymerase chain reaction (PCR) for *luk_{PV}SF* genes using two primer sets: Fw (5'-CATCAACAGGAGGTAATGG) and Rv (5'-CAGAATAAATGTTTCCAGCAGC). We did not detect a 751-bp PCR product that could have been generated if the strain harbors *luk_{PV}SF* genes. This confirms that the strain lacks *luk_{PV}SF* genes. The genome sequence of the isolated strain has been deposited in the public sequence repository DNA Data Bank of Japan, DDBJ (<http://www.ddbj.nig.ac.jp>), under the accession number: PRJDB8899 (DDBJ BioProject), SAMD00193980 (ksw1) (DDBJ BioSample).

Discussion

We encountered a case of monomicrobial Fournier's gangrene caused by Panton-Valentine leukocidin-negative methicillin-susceptible *S. aureus* ST8 in a patient with type 2 diabetes mellitus. The clinical course of necrotizing fasciitis caused by CA-MRSA is reported to be subacute, with symptoms presenting an average of six days before admission (4). In the present case, left buttock pain had been noticed one month before admission, and a residual lesion in the left scrotum developed over two weeks after the first debridement. Therefore, the clinical course of the present case is considerably persistent.

The isolated strain ksw1 was found to share its ST8 with USA300, the most predominant CA-MRSA strain in the USA and known to cause skin and soft tissue infection. Epidemiological studies have demonstrated an association between CA-MRSA and the presence of *luk_{PV}SF* genes and SCCmec type IV (17-19). Panton-Valentine leukocidin is a

Table. The Comparison of Multilocus Sequence Types and Virulence Factors between Ksw1, ST8 CA-MRSA/J and USA300.

| Type, virulence gene, drug resistance | ksw1 | ST8 CA-MRSA/J -MM50 | USA300 -FPR3757 |
|---------------------------------------|---|---|---|
| Type | | | |
| ST | 8 | 8 | 8 |
| <i>spa</i> | 1 (t622) | 1 (t1767) | 1 (t008) |
| SCC <i>mec</i> | - | IV | IVa |
| virulence genes | | | |
| leukocidins | | | |
| <i>lukPVSF</i> | - | - | + |
| <i>lukED</i> | + | + | + |
| phenol-soluble modulins | | | |
| <i>hld</i> | | | |
| hemolysins | + | + | + |
| <i>hla</i> | + | + | + |
| <i>hlb</i> | + | + | + |
| <i>hlg</i> | + | + | + |
| <i>tsst-1</i> | + | + | - |
| enterotoxins | <i>sec, sel, sep</i> | <i>sec, sel, sep</i> | <i>sek, seq</i> |
| adhesins | <i>ebpS, sdrC, sdrD, sdrE, icaA, icaB, icaC, icaD, icaR, clfB</i> | <i>ebpS, sdrC, sdrD, sdrE, icaA, icaB, icaC, icaD, icaR, clfB</i> | <i>ebpS, sdrC, sdrD, sdrE, icaA, icaB, icaC, icaD, icaR, clfB</i> |
| others | <i>sak, scn</i> | <i>sak, scn</i> | <i>sak, scn, chp</i> |
| drug resistance | PCG, ABPC | PCG, DMPPC, EM, GM ¹ | β lactams, EM, CLDM, TC, CPF, MUP |

¹ Computational Prediction. PCG: benzylpenicillin, ABPC: ampicillin, DMPPC: methicillin, EM: erythromycin, GM: gentamicin, CLDM: clindamycin, TC: tetracycline, CPF: ciprofloxacin, MUP: mupirocin

cytotoxin that induces apoptosis of human neutrophils, and intradermal injection of purified Pantone-Valentine leukocidin to rabbits reportedly induces tissue necrosis (20, 21). Therefore, Pantone-Valentine leukocidin has been considered to be responsible for the enhanced virulence of CA-MRSA strains. However, several experimental studies in animal models of skin and soft tissue infection have shown a minimal effect of Pantone-Valentine leukocidin (22-24). Furthermore, five cases of invasive infection reported in South Korea were found to be caused by Pantone-Valentine leukocidin-negative CA-MRSA (25). This evidence negates the significant role of Pantone-Valentine leukocidin as a virulence factor in skin and soft tissue infections caused by CA-MRSA. Interestingly, our observations also indicate that Pantone-Valentine leukocidin is dispensable in causing necrotizing fasciitis.

The virulence factor composition of *ksw1* differed considerably from that of the USA300 strain. Besides lacking Pantone-Valentine leukocidin, *ksw1* was found to harbor the toxic shock syndrome toxin-1 gene. Regarding the virulence factor composition, *ksw1* showed high similarities to ST8 CA-MRSA/J, a major genotype of ST8 CA-MRSA in Japan (16). Furthermore, the *spa* type of *ksw1*, 1 (t622) includes variant strains of ST8 CA-MRSA/J (16). More detailed studies involving comparative genomics, especially of the gene structure including SCC*mec*, are desired.

This research was conducted in Kashiwa Municipal Hospital, Chiba, Japan.

The authors state that they have no Conflict of Interest (COI).

References

- Sorensen MD, Krieger JN, Rivara FP, et al. Fournier's gangrene: population based epidemiology and outcomes. *J Urol* **181**: 2120-2126, 2009.
- Eke N. Fournier's gangrene: a review of 1726 cases. *Br J Surg* **87**: 718-728, 2000.
- Nisbet AA, Thompson IM. Impact of diabetes mellitus on the presentation and outcomes of Fournier's gangrene. *Urology* **60**: 775-779, 2002.
- Miller LG, Perdreau-Remington F, Rieg G, et al. Necrotizing fasciitis caused by community-associated methicillin-resistant *Staphylococcus aureus* in Los Angeles. *N Engl J Med* **352**: 1445-1453, 2005.
- Kawaguchiya M, Urushibara N, Ghosh S, et al. Genetic diversity of emerging Pantone-Valentine leukocidine/arginine catabolic mobile element (ACME)-positive ST8 SCC*mec*-IVa methicillin-resistant *Staphylococcus aureus* (MRSA) strains and ACME-positive CC5 (ST5/ST764) MRSA in northern Japan. *J Med Microbiol* **62**: 1852-1863, 2013.
- Shibuya Y, Hara M, Higuchi W, et al. Emergence of the community-acquired methicillin-resistant *Staphylococcus aureus* USA300 clone in Japan. *J Infect Chemother* **14**: 439-441, 2008.
- Higashiyama M, Ito T, Han X, et al. Epidural abscess caused by community-associated methicillin-resistant *Staphylococcus aureus* strain USA300 in Japan. *J Infect Chemother* **16**: 345-349, 2010.
- Higuchi W, Takano T, Iwao Y, et al. Emergence of the community-acquired methicillin-resistant *Staphylococcus aureus* USA300 clone in a Japanese child, demonstrating multiple divergent strains in Japan. *J Infect Chemother* **16**: 292-297, 2010.

9. Yabe S, Takano T, Higuchi W, et al. Spread of the community-acquired methicillin-resistant *Staphylococcus aureus* USA300 clone among family members in Japan. *J Infect Chemother* **16**: 372-374, 2010.
10. Nagao M, Iimura Y, Suzuki M, et al. First outbreak of methicillin-resistant *Staphylococcus aureus* USA300 harboring the Panton-Valentine leukocidin genes among Japanese health care workers and hospitalized patients. *Am J Infect Control* **38**: e37-e39, 2010.
11. Enright MC, Day NP, Davis CE, et al. Multilocus sequence typing for characterization of methicillin-resistant and methicillin-susceptible clones of *Staphylococcus aureus*. *J Clin Microbiol* **38**: 1008-1015, 2000.
12. Bartels MD, Petersen A, Worning P, et al. Comparing whole-genome sequencing with Sanger sequencing for *spa* typing of methicillin-resistant *Staphylococcus aureus*. *J Clin Microbiol* **52**: 4305-4308, 2014.
13. Wattam AR, Brettin T, Davis JJ, et al. Assembly, annotation, and comparative genomics in PATRIC, the all bacterial bioinformatics resource center. *Methods Mol Biol* **1704**: 79-101, 2018.
14. Kaya H, Hasman H, Larsen J, et al. SCCmecFinder, a web-based tool for typing of staphylococcal cassette chromosome *mec* in *Staphylococcus aureus* using whole-genome sequence data. *mSphere* **3**: e00612-e00617, 2018.
15. Diep BA, Gill SR, Chang RF, et al. Complete genome sequence of USA300, an epidemic clone of community-acquired methicillin-resistant *Staphylococcus aureus*. *Lancet* **367**: 731-739, 2006.
16. Iwao Y, Ishii R, Tomita Y, et al. The emerging ST8 methicillin-resistant *Staphylococcus aureus* clone in the community in Japan: associated infections, genetic diversity, and comparative genomics. *J Infect Chemother* **18**: 228-240, 2012.
17. Vandenesch F, Naimi T, Enright MC, et al. Community-acquired methicillin-resistant *Staphylococcus aureus* carrying Panton-Valentine leukocidin genes: worldwide emergence. *Emerg Infect Dis* **9**: 978-984, 2003.
18. Naimi TS, LeDell KH, Como-Sabetti K, et al. Comparison of community- and health care-associated methicillin-resistant *Staphylococcus aureus* infection. *JAMA* **290**: 2976-2984, 2003.
19. Diep BA, Sensabaugh GF, Somboona NS, et al. Widespread skin and soft-tissue infections due to two methicillin-resistant *Staphylococcus aureus* strains harboring the genes for Panton-Valentine leukocidin. *J Clin Microbiol* **42**: 2080-2084, 2004.
20. Cribier B, Prévost G, Couppie P, et al. *Staphylococcus aureus* leukocidin: a new virulence factor in cutaneous infections? An epidemiological and experimental study. *Dermatology* **185**: 175-180, 1992.
21. Genestier AL, Michallet MC, Prevost G, et al. *Staphylococcus aureus* Panton-Valentine leukocidin directly targets mitochondria and induces Bax-independent apoptosis of human neutrophils. *J Clin Invest* **115**: 3117-3127, 2005.
22. Yoong P, Torres VJ. The effects of *Staphylococcus aureus* leukotoxins on the host: cell lysis and beyond. *Curr Opin Microbiol* **16**: 63-69, 2013.
23. Otto M. MRSA virulence and spread. *Cell Microbiol* **14**: 1513-1521, 2012.
24. Otto M. Community-associated MRSA: what makes them special? *Int J Med Microbiol* **303**: 324-330, 2013.
25. Lee SS, Kim YJ, Chung DR, et al. Invasive infection caused by a community-associated methicillin resistant *Staphylococcus aureus* strain not carrying Panton-Valentine leukocidin in South Korea. *J Clin Microbiol* **48**: 311-313, 2010.

The Internal Medicine is an Open Access journal distributed under the Creative Commons Attribution-NonCommercial-NoDerivatives 4.0 International License. To view the details of this license, please visit (<https://creativecommons.org/licenses/by-nc-nd/4.0/>).