



CLINICAL REPORT

Extension of the phenotypic spectrum of *GLE1*-related disorders to a mild congenital form resembling congenital myopathy

Mathieu Cerino^{1,2,3,4}  | Chloé Di Meglio⁵ | Francesca Albertini⁵ | Frédérique Audic⁵ | Florence Riccardi^{1,2,3} | Christophe Boulay⁵ | Nicole Philip^{1,2,3} | Marc Bartoli^{1,3}  | Nicolas Lévy^{1,2,3} | Martin Krahn^{1,2,3} | Brigitte Chabrol^{3,5}

¹Aix Marseille Univ, Inserm, U1251-MMG, Marseille Medical Genetics, Marseille, France

²APHM, Hôpital Timone Enfants, Département de Génétique Médicale, Marseille, France

³GIPTIS (Genetics Institute for Patients, Therapies Innovation and Science), Marseille, France

⁴APHM, Hôpital de la Conception, Laboratoire de Biochimie, Marseille, France

⁵APHM, Hôpital Timone Enfants, Service de Neurologie Pédiatrique, Marseille, France

Correspondence

Mathieu Cerino, Aix Marseille Univ, Inserm, U1251-MMG, Marseille Medical Genetics, Faculté de Médecine, 27 Bd Jean Moulin, 13385 Marseille, France.
Email: mathieu.cerino@univ-amu.fr

Funding information

This study was supported by GIPTIS (Genetics Institute for Patients, Therapies Innovation & Science); National Research Agency, Investment for the Future (Grant No. ANR-10-INBS-09); AFM-Telethon (under grant agreement #19272); Fondation Maladies Rares; FHU A*MIDEX project MARCHE n.ANR-11-IDEX-001-02 funded by the “Investissement d’avenir” French government program, managed by the French National Research Agency (ANR); APHM; INSERM and the

Abstract

Background: *GLE1* (GLE1, RNA Export Mediator, OMIM#603371) variants are associated with severe autosomal recessive motor neuron diseases, that are lethal congenital contracture syndrome 1 (LCCS1, OMIM#253310) and congenital arthrogyrosis with anterior horn cell disease (CAAHD, OMIM#611890).

The clinical spectrum of *GLE1*-related disorders has been expanding these past years, including with adult-onset amyotrophic lateral sclerosis (ALS) *GLE1*-related forms, especially through the new molecular diagnosis strategies associated with the emergence of next-generation sequencing (NGS) technologies. However, despite this phenotypic variability, reported congenital or ALS adult-onset forms remain severe, leading to premature death.

Methods: Through multidisciplinary interactions between our Neuropediatric and Medical Genetics departments, we were able to diagnose two siblings presenting with congenital disorder, using an NGS approach accordingly to the novel French national recommendations.

Results: Two siblings with very similar clinical features, meaning neuromuscular disorder of neonatal onset with progressive improvement, were examined in our Neuropediatrics department. The clinical presentation evoked initially congenital myopathy with autosomal recessive inheritance. However, additional symptoms such as mild dysmorphic features including high anterior hairline, downslanted palpebral fissures, anteverted nares, smooth philtrum with thin upper-lip, narrow mouth and microretrognathia or delayed expressive language and postnatal growth retardation were suggestive of a more complex clinical presentation and molecular diagnosis. Our NGS approach revealed an unexpected molecular diagnosis for these two siblings, meaning the presence of the homozygous c.1808G>T *GLE1* variant.

Abbreviations: ALS, Amyotrophic Lateral Sclerosis; AMC, Arthrogyrosis Multiplex Congenita; CAAHD, Congenital Arthrogyrosis with Anterior Horn Cell Disease; HGVS, Human Genome Variation Society; IP6, Inositol hexakisPhosphate; LAAHD, Lethal Arthrogyrosis with Anterior Horn Cell Disease; LCCS1, Lethal Congenital Contracture Syndrome 1; mRNP, messenger RiboNucleoProtein; NGS, Next-Generation Sequencing.

This is an open access article under the terms of the Creative Commons Attribution-NonCommercial-NoDerivs License, which permits use and distribution in any medium, provided the original work is properly cited, the use is non-commercial and no modifications or adaptations are made.

© 2020 The Authors. *Molecular Genetics & Genomic Medicine* published by Wiley Periodicals LLC.

European Community Seventh Framework Programme Grant FP7/2007–2013 (NEUROMICS; Grant No. 2012–305121).

Conclusions: We here report the mildest phenotype ever described, in two siblings carrying the homozygous c.1808G>T *GLE1* variant, further widening the clinical spectrum of *GLE1*-related diseases. Moreover, by reflecting current medical practice, this case report confirms the importance of establishing regular multidisciplinary meetings, essential for discussing such difficult clinical presentations to finally enable molecular diagnosis, especially when NGS technologies are used.

KEYWORDS

congenital, *GLE1*, mild, mutation, myopathy, NGS

1 | INTRODUCTION

GLE1 (GLE1, RNA Export Mediator, OMIM#603371) variants are associated with severe autosomal recessive motor neuron diseases, that are lethal congenital contracture syndrome 1 (LCCS1, OMIM#253310) and lethal arthrogryposis with anterior horn cell disease (LAAHD) (Mäkelä-Bengts et al., 1998; Nousiainen et al., 2008).

The clinical spectrum of *GLE1*-related disorders has been expanding these past years, considering new molecular diagnosis strategies related to the emergence of next-generation sequencing (NGS) technologies.

Indeed, description of cases with survival beyond the perinatal period broaden the clinical spectrum and led to the nomenclature modification of LAAHD to congenital arthrogryposis with anterior horn cell disease (CAAHD, OMIM#611890) (Paakkola et al., 2018; Said et al., 2017; Smith et al., 2017; Tan et al., 2017). Therefore, it appears more accurate to define *GLE1*-related disorders under a larger designation of arthrogryposis multiplex congenita (AMC) (Smith et al., 2017).

Interestingly, the clinical spectrum of *GLE1*-related variants is not only congenital but also associated with adult-onset amyotrophic lateral sclerosis (ALS) (Aditi, Glass, Dawson, & Wenthe, 2016; Kaneb et al., 2015). This is not surprising as the *GLE1* codes for two isoforms (hGLE1A and hGLE1B) with multiple independent roles, from nuclear export mRNA regulation to initiation and termination of translation (Alcázar-Román, Bolger, & Wenthe, 2010; Bolger, Folkmann, Tran, & Wenthe, 2008; Bolger & Wenthe, 2011; Folkmann et al., 2013; Kaneb et al., 2015; Murphy & Wenthe, 1996).

Indeed, *GLE1* plays an essential role in RNA-dependent DEAD-box ATPases modulations implicated in messenger ribonucleoprotein (mRNP) complexes regulation, thus having a critical effect in mRNA's processing (Jarmoskaite & Russell, 2014). Over the past years, numerous genes encoding mRNP components and regulators were associated with ALS such as TAR DNA-binding protein (*TARDBP*) (Sreedharan et al., 2008), Fused in Sarcoma (*FUS*) (Kwiatkowski

et al., 2009; Vance et al., 2009), *hnRNPA1* and *hnRNPA2* (Kim et al., 2013).

Therefore, it is comprehensible that variants of such genes, by playing a direct or indirect upstream role in mRNA expression, may have an impact on several underlying pathophysiological mechanisms logically displaying phenotypic heterogeneity.

GLE1 variants seem to make no exception to this rule with variable effects on motor neurons resulting in a large phenotypical spectrum.

Nevertheless, despite this phenotypic variability, reported congenital or ALS adult-onset forms remain severe, leading to premature death. Here, we describe two siblings with a much milder and atypical *GLE1*-associated phenotype, combining moderate cognitive impairment and neuromuscular impairment (initially considered as a congenital myopathy).

2 | METHODS

Through multidisciplinary interactions between the Neuropediatric and Genetics departments we included DNA of two affected siblings for genetic analysis, using NGS approach accordingly to the novel French national recommendations (Krahn et al., 2019).

This family gave informed consent, according to the Declaration of Helsinki, for molecular diagnosis of all four individuals explored (the two asymptomatic parents and two affected siblings). We also obtained consent for medical publication (including pictures of the siblings).

Genetic analysis consisted in clinical exome sequencing using the ClearSeq Inherited Disease Panel (Agilent technologies, CA, USA) on an Ion Proton platform (ThermoFisher Scientific, CA, USA). Sequencing data interpretation was initially focused on 44 genes associated with neuromuscular disorders (Supporting Information) (Kaplan & Hamroun, 2013), before extending analysis to other lists of genes following the novel French national recommendations (Krahn et al., 2019).

NGS findings were systematically confirmed, as well as variant familial segregation analysis performed by targeted Sanger sequencing on a 3500XL Genetic Analyzer® (ThermoFisher Scientific).

For the sequence variant nomenclature, we followed the Human Genome Variation Society (HGVS) recommendations and used the *GLE1* transcript reference NM_001003722.1.

3 | RESULTS

The two affected siblings are born from healthy Caucasian (with Flemish origin) consanguineous parents (second cousins). Patient II.1 (Figure 1a,b) was born at 41 week of gestation with normal birth parameters: weight: 3,590 g (50th centile), length: 54 cm (95th centile) and head circumference: 36.5cm (81st centile). Neonatal adaptation was normal (APGAR score: 10–10). He had clenched fists with adductus thumbs and hypomobility and slow spontaneous movement. Within the first month of life, he presented feeding difficulties that improved with thickened food. In the first year of life, flexion contractures of his upper and lower limbs were noticed. He could stand at 12 months and was able to walk at 3 years old. Expressive language was also delayed as he said only few words at 3 years of age.

At the last examination, he was 6 years and 10 months old. He weighed 16.4 kg and was 102.7 cm tall (both < -2 standard deviation). He had postnatal growth retardation that has started since he was 15 months old. He had no microcephaly: his head circumference was 51 cm (-1 standard deviation). He had mild dysmorphic features including high anterior hairline, downslanted palpebral fissures, anteverted nares, smooth philtrum with thin upper-lip, narrow mouth, and microretrognathia. He walked with triple lower limb joints contracture but sometimes fell. He had peroneal muscle atrophy,

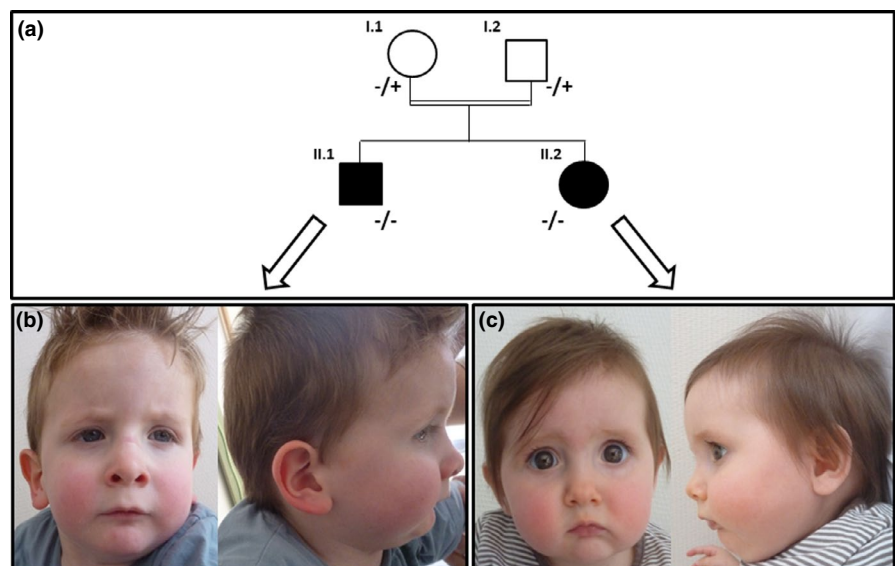
patellar hyperreflexia, and hyperlordosis. He was able to say short sentences. He wore glasses for hypermetropia.

Many complementary investigations were performed. He had normal brain MRI scan with spectroscopy at 2 years old. Electroneuromyography (EMG) at 2.5 years showed rich EMG signals reflecting a myogenic pattern but also associated with a neurogenic component (decreased nerve conduction velocity and amplitude, especially for peroneal nerves). Creatine kinase level was normal (79 UI/L). Specific assays for diagnosis of mucopolysaccharidoses were normal including skeletal X-ray that has been done because of hepatomegaly (which disappeared spontaneously after 3 years old). Skeletal muscle biopsy at 3.5 years old evidenced no specific abnormalities: few fibers with vacuolation on electron microscopy and mild increase of PAS positive material. Other analyses were normal, in particular immunohistochemistry. Peripheral blood karyotyping was normal.

Patient II.2 (Figure 1a,c), the younger sister of the proband, was born at 39 weeks of gestation, after uneventful pregnancy, with normal birth parameters: weight 2,730 g (11st centile), length 50 cm (68th centile) and head circumference 35cm (75th centile). Neonatal adaptation was normal (APGAR score: 10–10). During neonatal period, nystagmus and vertical talus feet have been observed with improvement after few weeks. At 13 months old, she had thoracolumbar kyphosis, preserved deep tendon reflexes and hips movement disability. Two short respiratory arrests have been reported at 6 months and 12 months old due to swallowing disorders. She quickly recovered and improved with swallow therapy.

At last examination, she was 4 years old. She weighed 12 kg (< -2 standard deviation) and was 92.6 cm tall (< -2 standard deviation). She had no microcephaly: her head circumference was 48.5 cm (normal). She was able to walk on all fours, to stand and to walk with support. She could say

FIGURE 1 (a) Pedigree and familial segregation analysis of c.1808G>T [p.(Arg603Leu)] *GLE1* variant. (+) indicates non mutated allele and (-) indicates mutated allele for the c.1808G>T [p.(Arg603Leu)] *GLE1* variant. (b) Pictures face and profile of patient II.1 at 30 months old. (c) Pictures face and profile of patient II.2 at 10 months old. The two siblings have mild shared dysmorphic features including high anterior hairline, downslanted palpebral fissures, anteverted nares, smooth philtrum with thin upper-lip, narrow mouth and microretrognathia.



small sentences with good vocabulary. She also wore glasses for hypermetropia.

Her clinical presentation was similar to her brother regarding lower limb: triple lower limb joints contracture, patellar hyperreflexia but no Achilles tendon reflexes and kyphosis aspect. She also had dysmorphic features similar to her brother (Figure 1b,c). Cardiac ultrasound and examination were normal. Array-CGH was performed and did not evidence any anomaly. Fewer investigations have been performed on patient II.2 as exhaustive analyses have been done for patient II.1.

In summary, the two siblings had very similar clinical features: neuromuscular disorder of neonatal onset with progressive improvement. This clinical presentation evoked congenital myopathy with autosomal recessive inheritance.

After the first genetic testings (karyotype and array-CGH), we performed targeted sequencing of 44 genes associated with neuromuscular disorders (Kaplan & Hamroun, 2013) in patient II.1 (propositus), following our diagnosis strategy (Supporting information). This analysis did not reveal any convincing molecular diagnosis.

However, considering the atypical clinical presentation, we decided in agreement with the clinicians to broaden the molecular analysis. This strategy follows the recent and novel NGS strategy recommendations (Krahn et al., 2019). A multidisciplinary team meeting allowed discussing the clinical presentation and regular follow-up data of the two siblings: diagnosis of arthrogryposis was evoked. Indeed, patients were both born with some arthrogryposis features as clenched fists with adductus thumbs, hypomobility and/or vertical talus feet. Therefore, by focusing on the appropriate genes list, that is the "Fœtal and Neonatal Arthrogryposes - Unique exhaustive genes list" (Krahn et al., 2019), we identified an homozygous *GLE1* variant, c.1808G>T [p.(Arg603Leu)], located in exon 13, for patient II.1. Segregation analysis showed that it is inherited from healthy heterozygous parents and that patient II.2 also carries this homozygous variant (Figure 1a). To our knowledge, this variant has never been reported at homozygous status in individuals. It has a very low frequency in the general population (allele frequency = 3.98×10^{-6} ; GnomAD, <http://gnomad.broadinstitute.org/>, 30 June 2019) and it is predicted to be damaging by several bioinformatics tools [PolyPhen2 (Adzhubei et al., 2010), Mutation Taster (Schwarz, Cooper, Schuelke, & Seelow, 2014) and UMD-predictor (Salgado et al., 2016)].

According to the ACMG classification, it is a likely pathogenic (class 4) variant (Richards et al., 2015). Interestingly, this specific c.1808G>T *GLE1* variant has been reported as pathogenic once in patients database [Clinvar (Landrum et al., 2018)] and recently in the literature, associated with another likely pathogenic *GLE1* variant on the second allele (compound heterozygous status) (Tan et al., 2017). The phenotype associated with this initial description is also a

moderate clinical presentation but not as mild as the one we report for these two siblings (Table 1).

4 | DISCUSSION

We here describe a relatively moderate congenital phenotype associated with the homozygous c.1808G>T [p.(Arg603Leu)] *GLE1* genotype, for two siblings. To date, only nine patients have been reported in the literature for *GLE1*-associated congenital disorders.

The phenotype associated with this c.1808G>T homozygous *GLE1* genotype, could even be considered as the mildest described to date, based on literature reports (Table 1) (Paakkola et al., 2018; Said et al., 2017; Smith et al., 2017).

Indeed, *GLE1* variants were initially associated with severe autosomal recessive motor neuron diseases either for lethal congenital forms (Mäkelä-Bengts et al., 1998; Nousiainen et al., 2008) or later-onset ALS forms (Aditi, Glass, Dawson, & Wenthe, 2016; Kaneb et al., 2015), leading in both cases to premature death. Even if the recently expanding *GLE1* phenotype spectrum includes less severe clinical presentations, the case we report here, associated with a c.1808G>T [p.(Arg603Leu)] *GLE1* homozygous genotype, constitutes the mildest phenotype reported to date, in comparison with previously reported congenital moderate phenotypes (Table 1) (Paakkola et al., 2018; Said et al., 2017; Smith et al., 2017; Tan et al., 2017).

Interestingly, this c.1808G>T *GLE1* variant has already been described in a compound heterozygous association with the c.1997G>T [p.(Gly666Val)] variant with a milder phenotype as usually observed for *GLE1* variants (Tan et al., 2017).

Tan and colleagues reasonably hypothesized that the c.1997G>T [p.(Gly666Val)] *GLE1* variant could be responsible for this milder phenotype as the p.Gly666 residue is present only in the hGLE1B isoform. However, we report here a milder phenotype than the one described by Tan and colleagues for two siblings with the homozygous c.1808G>T *GLE1* variant. Our report confirms that the c.1808G>T [p.(Arg603Leu)] *GLE1* variant seems also associated with a moderate pathogenic effect leading to a milder phenotype. This p.(Arg603Leu) variant is located near the carboxy-terminus end of the protein, in the region of the *GLE1* protein implicated in inositol hexakisphosphate (IP₆) binding domain. Therefore, future research should focus on the possible impact of this specific *GLE1* variant on the interaction with IP₆ and the potential consequences on mRNA export and translation termination (Alcázar-Román, Bolger, & Wenthe, 2010; Alcázar-Román, Tran, Guo, & Wenthe, 2006).

Furthermore, this case report also emphasizes the utility of NGS technologies to elucidate atypical and/or overlapping phenotypes.

Indeed, as this clinical case demonstrates, a well-established gene panel NGS approach associated with a sequential

TABLE 1 Clinical features for *GLE1* variants recently associated with congenital phenotypes

Clinical features	Smith et al., 2017		Said et al., 2017		Paakkola et al. 2018		Tan et al., 2017		Our patients	
	Case 1	Case 2	A	B	Patient 1	Patient 2	One patient	Patient II.1	Patient II.2	
Age onset	NR	Prenatal	Birth	Birth	Birth	Birth	Prenatal	Birth	Birth	
Birth weight (g)	NR	2,955	2,480	2,930	3,210	3,210	2,675 (36gw)	3,590	2,730	
Birth head circumference (cm)	NR	NR	35	34.5	36	36.5	33.5	36.5	35	
Neonatal respiratory distress	+	+	+	NR	+	+	+	-	-	
Gastrostomy tube feeding	-	+	-	-	+	+	+	-	-	
Dysmorphic features	+	+	+	+	+	+	+	+	+	
Head circumference outcome	NR	Microcephaly	NR	Normal	NR	NR	Normal	Normal	Normal	
Walk	NR	-	+	-	NR	NR	-	abnormal	abnormal	
Language	NR	Sign language	+	+	NR	NR	Sign language	Language delay	Language delay	
Intercurrent disease	NR	NR	NR	Frequent pneumonia	Pneumonia	Pneumonia, progressive neurological symptoms	NR	-	-	
Outcome Age at last examination	Died at 2 w	Improvement 12 y	Improvement 4 y 8 m	Died 4 y	Died 6 m	Died 6 m	Improvement 26 m	Improvement 5 y	Improvement 3 y	
<i>GLE1</i> variant (NM_001003722.1)	Compound heterozygous c.100-7_100-3delTCTCT c.1882-2A>G	Homozygous c.2078C>T	Homozygous c.1706G>A c.1750C>T	Compound heterozygous c.1706G>A c.1750C>T	Homozygous c.2015T>C	Homozygous c.2015T>C	Compound heterozygous c.1808G>T c.1997G>T	Homozygous c.1808G>T	Homozygous c.1808G>T	
Muscle biopsy	-	No specific abnormalities	NR	NR	Neurogenic atrophy Atrophic and hypertrophic muscle fibers	Neurogenic atrophy Atrophic and hypertrophic muscle fibers	Neurogenic atrophy Atrophic and hypertrophic muscle fibers	No specific abnormalities	NR	

Abbreviations: gw, gestational week; m, months; NR, not reported; w, weeks; y, years.

gene filtering clinically oriented strategy can be sufficient to resolve these types of complex diagnosis (Krahn et al., 2019).

Moreover, by reflecting current medical practice, this case report confirms the importance of establishing regular multi-disciplinary meetings, essential for discussing such difficult clinical presentations to finally enable molecular diagnosis. Thus, leading sometimes to the reassessment of the initial clinical indication, as in our context the widening of *GLE1*-associated phenotypical indication to congenital slowly progressing muscle disease, as previously suggested by Tan and colleagues (Tan et al., 2017).

This description also reveals the importance of taking into account the mutational *GLE1* combination to better comprehend clinical presentation as well as the severity and evolution of the disease. In the present case, the homozygous c.1808G>C *GLE1* genotype seems to be associated with a milder phenotype, thus further expanding the *GLE1* clinical spectrum.

Finally, to complete Smith and colleagues' hypothesis of a single entity for AMC (Smith et al., 2017), involving the *GLE1* mutational combination evaluation, we believe that the influence of possible modifier genes should also be considered to explain the *GLE1*-associated phenotypical heterogeneity, from extremely severe lethal forms to milder clinical presentations such as the one described here.

ACKNOWLEDGMENTS

We sincerely thank Karine Bertaux, Cécile Mouradian, Pierre Cacciagli, Jean-Pierre Desvignes, David Salgado, and Christophe Béroud for their contribution to this work. We would like to thank GIPTIS (Genetics Institute for Patients, Therapies Innovation and Science) for its generous support. We also wish to thank the patients, families and health professionals whose participation, through the FILNEMUS and Anddi-Rares networks, made possible this research.

CONFLICT OF INTEREST

The authors have no conflict of interest to disclose.

AUTHOR CONTRIBUTION

CDM, FAu, FAI, CB, NP, and BC performed a history and physical exam on the patient. MC, CDM, FAu, FR, MB, NL, MK, and BC performed literature review and assisted in manuscript preparation. MC, MB, NL, and MK contributed to data acquisition and analysis. MC, MK, MB belong to the Translational Neuromyology team within MMG, where this study took place. All authors read and approved the final manuscript.

ETHICAL APPROVAL

Written informed consent obtained by parent/guardian of patients.

DATA AVAILABILITY STATEMENT

All relevant data are within the paper and its Supporting Information file. Due to ethical and legal restrictions from Assistance Publique – Hôpitaux de Marseille related to protecting participant privacy, all additional data are available upon request pending ethical approval. Please submit all requests to initiate the data access process to the corresponding author, Dr. Cerino (mathieu.cerino@univ-amu.fr).

ORCID

Mathieu Cerino  <https://orcid.org/0000-0002-4992-5157>

Marc Bartoli  <https://orcid.org/0000-0003-3339-9858>

REFERENCES

- Aditi, Glass, L., Dawson, T. R., & Wente, S. R. (2016). An amyotrophic lateral sclerosis-linked mutation in *GLE1* alters the cellular pool of human *Gle1* functional isoforms. *Advances in Biological Regulation*, 62, 25–36. <https://doi.org/10.1016/j.jbior.2015.11.001>
- Adzhubei, I. A., Schmidt, S., Peshkin, L., Ramensky, V. E., Gerasimova, A., Bork, P., ... Sunyaev, S. R. (2010). A method and server for predicting damaging missense mutations. *Nature Methods*, 7(4), 248–249. <https://doi.org/10.1038/nmeth0410-248>
- Alcázar-Román, A. R., Bolger, T. A., & Wente, S. R. (2010). Control of mRNA export and translation termination by inositol hexakisphosphate requires specific interaction with *Gle1*. *The Journal of Biological Chemistry*, 285(22), 16683–16692. <https://doi.org/10.1074/jbc.M109.082370>
- Alcázar-Román, A. R., Tran, E. J., Guo, S., & Wente, S. R. (2006). Inositol hexakisphosphate and *Gle1* activate the DEAD-box protein *Dbp5* for nuclear mRNA export. *Nature Cell Biology*, 8(7), 711–716. <https://doi.org/10.1038/ncb1427>
- Bolger, T. A., Folkmann, A. W., Tran, E. J., & Wente, S. R. (2008). The mRNA export factor *Gle1* and inositol hexakisphosphate regulate distinct stages of translation. *Cell*, 134(4), 624–633. <https://doi.org/10.1016/j.cell.2008.06.027>
- Bolger, T. A., & Wente, S. R. (2011). *Gle1* is a multifunctional DEAD-box protein regulator that modulates *Ded1* in translation initiation. *The Journal of Biological Chemistry*, 286(46), 39750–39759. <https://doi.org/10.1074/jbc.M111.299321>
- Folkmann, A. W., Collier, S. E., Zhan, X., Aditi, , Ohi, M. D., & Wente, S. R. (2013). *Gle1* functions during mRNA export in an oligomeric complex that is altered in human disease. *Cell*, 155(3), 582–593. <https://doi.org/10.1016/j.cell.2013.09.023>
- Jarmoskaite, I., & Russell, R. (2014). RNA helicase proteins as chaperones and remodelers. *Annual Review of Biochemistry*, 83, 697–725. <https://doi.org/10.1146/annurev-biochem-060713-035546>
- Kaneb, H. M., Folkmann, A. W., Belzil, V. V., Jao, L.-E., Leblond, C. S., Girard, S. L., ... Dion, P. A. (2015). Deleterious mutations in the essential mRNA metabolism factor, *hGle1*, in amyotrophic lateral sclerosis. *Human Molecular Genetics*, 24(5), 1363–1373. <https://doi.org/10.1093/hmg/ddu545>
- Kaplan, J.-C., & Hamroun, D. (2013). The 2014 version of the gene table of monogenic neuromuscular disorders (nuclear genome). *Neuromuscular Disorders: NMD*, 23(12), 1081–1111.
- Kim, H. J., Kim, N. C., Wang, Y.-D., Scarborough, E. A., Moore, J., Diaz, Z., ... Taylor, J. P. (2013). Mutations in prion-like domains in

- hnRNPA2B1 and hnRNPA1 cause multisystem proteinopathy and ALS. *Nature*, 495(7442), 467–473. <https://doi.org/10.1038/nature11922>
- Krahn, M., Biancalana, V., Cerino, M., Perrin, A., Michel-Calemard, L., Nectoux, J., ... Cossée, M. (2019). A National French consensus on gene lists for the diagnosis of myopathies using next-generation sequencing. *European Journal of Human Genetics: EJHG*, 27(3), 349–352. <https://doi.org/10.1038/s41431-018-0305-1>
- Kwiatkowski, T. J., Bosco, D. A., LeClerc, A. L., Tamrazian, E., Vanderburg, C. R., Russ, C., ... Brown, R. H. (2009). Mutations in the FUS/TLS gene on chromosome 16 cause familial amyotrophic lateral sclerosis. *Science*, 323(5918), 1205–1208. <https://doi.org/10.1126/science.1166066>
- Landrum, M. J., Lee, J. M., Benson, M., Brown, G. R., Chao, C., Chitipiralla, S., ... Maglott, D. R. (2018). ClinVar: Improving access to variant interpretations and supporting evidence. *Nucleic Acids Research*, 46(D1), D1062–D1067. <https://doi.org/10.1093/nar/gkx1153>
- Mäkelä-Bengs, P., Järvinen, N., Vuopala, K., Suomalainen, A., Ignatius, J., Sipilä, M., ... Peltonen, L. (1998). Assignment of the disease locus for lethal congenital contracture syndrome to a restricted region of chromosome 9q34, by genome scan using five affected individuals. *American Journal of Human Genetics*, 63(2), 506–516. <https://doi.org/10.1086/301968>
- Murphy, R., & Wenthe, S. R. (1996). An RNA-export mediator with an essential nuclear export signal. *Nature*, 383(6598), 357–360. <https://doi.org/10.1038/383357a0>
- Nousiainen, H. O., Kestilä, M., Pakkasjärvi, N., Honkala, H., Kuure, S., Tallila, J., ... Peltonen, L. (2008). Mutations in mRNA export mediator GLE1 result in a fetal motoneuron disease. *Nature Genetics*, 40(2), 155–157. <https://doi.org/10.1038/ng.2007.65>
- Paakkola, T., Vuopala, K., Kokkonen, H., Ignatius, J., Valkama, M., Moilanen, J. S., ... Uusimaa, J. (2018). A homozygous I684T in GLE1 as a novel cause of arthrogryposis and motor neuron loss. *Clinical Genetics*, 93(1), 173–177. <https://doi.org/10.1111/cge.13086>
- Richards, S., Aziz, N., Bale, S., Bick, D., Das, S., Gastier-Foster, J., ... ACMG Laboratory Quality Assurance Committee, (2015). Standards and guidelines for the interpretation of sequence variants: A joint consensus recommendation of the American College of Medical Genetics and Genomics and the Association for Molecular Pathology. *Genetics in Medicine*, 17(5), 405–424. <https://doi.org/10.1038/gim.2015.30>
- Said, E., Chong, J. X., Hempel, M., Denecke, J., Soler, P., Strom, T., ... Lessel, D. (2017). Survival beyond the perinatal period expands the phenotypes caused by mutations in GLE1. *American Journal of Medical Genetics. Part A*, 173(11), 3098–3103. <https://doi.org/10.1002/ajmg.a.38406>
- Salgado, D., Desvignes, J.-P., Rai, G., Blanchard, A., Miltgen, M., Pinard, A., ... Bérout, C. (2016). UMD-predictor: A high-throughput sequencing compliant system for pathogenicity prediction of any human cDNA substitution. *Human Mutation*, 37(5), 439–446. <https://doi.org/10.1002/humu.22965>
- Schwarz, J. M., Cooper, D. N., Schuelke, M., & Seelow, D. (2014). MutationTaster2: Mutation prediction for the deep-sequencing age. *Nature Methods*, 11(4), 361–362. <https://doi.org/10.1038/nmeth.2890>
- Smith, C., Parboosingh, J. S., Boycott, K. M., Bönnemann, C. G., & Mah, J. K., Care4Rare Canada Consortium, ... Bernier, F. P. (2017). Expansion of the GLE1-associated arthrogryposis multiplex congenita clinical spectrum. *Clinical Genetics*, 91(3), 426–430. <https://doi.org/10.1111/cge.12876>
- Sreedharan, J., Blair, I. P., Tripathi, V. B., Hu, X., Vance, C., Rogelj, B., ... Shaw, C. E. (2008). TDP-43 mutations in familial and sporadic amyotrophic lateral sclerosis. *Science*, 319(5870), 1668–1672. <https://doi.org/10.1126/science.1154584>
- Tan, Q.-K.-G., McConkie-Rosell, A., Juusola, J., Gustafson, K. E., Pizoli, C. E., Buckley, A. F., & Jiang, Y.-H. (2017). The importance of managing the patient and not the gene: Expanded phenotype of GLE1-associated arthrogryposis. *Cold Spring Harbor Molecular Case Studies*, 3(6), pii: a002063. <https://doi.org/10.1101/mcs.a002063>
- Vance, C., Rogelj, B., Hortobagyi, T., De Vos, K. J., Nishimura, A. L., Sreedharan, J., ... Shaw, C. E. (2009). Mutations in FUS, an RNA processing protein, cause familial amyotrophic lateral sclerosis type 6. *Science*, 323(5918), 1208–1211. <https://doi.org/10.1126/science.1165942>

SUPPORTING INFORMATION

Additional Supporting Information may be found online in the Supporting Information section.

How to cite this article: Cerino M, Di Meglio C, Albertini F, et al. Extension of the phenotypic spectrum of GLE1-related disorders to a mild congenital form resembling congenital myopathy. *Mol Genet Genomic Med*. 2020;8:e1277. <https://doi.org/10.1002/mgg3.1277>